



Universiteit
Leiden
The Netherlands

Editor's note to the September 2021 issue

Reiber, J.H.C.

Citation

Reiber, J. H. C. (2021). Editor's note to the September 2021 issue. *International Journal Of Cardiovascular Imaging*, 37(9), 2589-2589. doi:10.1007/s10554-021-02381-2

Version: Publisher's Version

License: [Creative Commons CC BY 4.0 license](#)

Downloaded from: <https://hdl.handle.net/1887/3277700>

Note: To cite this publication please use the final published version (if applicable).



Editor's note to the September 2021 issue

Johan H. C. Reiber¹

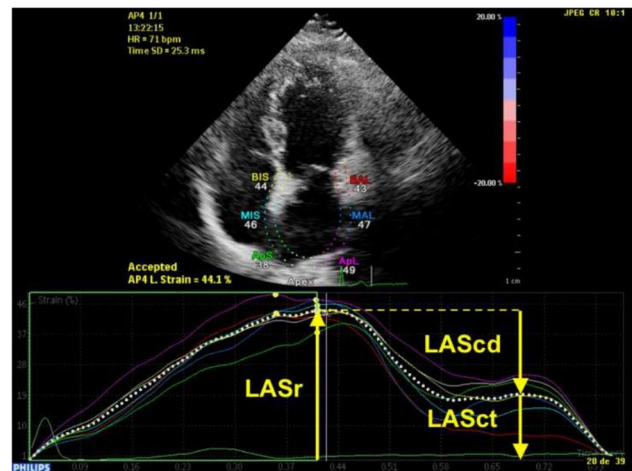
Published online: 14 August 2021

© The Author(s), under exclusive licence to Springer Nature B.V. 2021

Dear reader,

Apparently, our Journal has become attractive, actually already for quite some time, for submissions in the field of echocardiography, given the large number of submissions that we are receiving and are also accepting for publications. And in the echocardiography field, strain analysis has been a major topic of research and clinical application, which also has spread to magnetic resonance imaging and computed tomography. In addition, strain analysis is not limited to the left and right ventricles, but also to the atrium.

For this September 2021 issue, I have therefore selected and would like to recommend the paper entitled “Left atrial strain in the assessment of diastolic function: providing new insights into primary myocardial dysfunction in Marfan syndrome” by García-Izquierdo, E and colleagues from the Departments of Cardiology and Cardiac Surgery, Hospital Universitario Puerta de Hierro Majadahonda, Madrid, Spain [1]. They studied 127 adult patients with Marfan syndrome and 38 healthy controls, performed detailed echocardiograms and selected left atrial reservoir strain (LASr) as a surrogate of impaired relaxation. They found that LASr is reduced in patients with Marfan compared to controls, and correlated with impaired myocardial relaxation, rather than elastic properties of the aorta; this may represent an early stage of LV diastolic dysfunction. This is a well performed study and there is novelty associated with it, as diastolic function using a new parameter, such as this left atrial strain, has not been explored earlier in this patient population.



I wish you much pleasure in reading this and other papers in this issue of the International Journal of Cardiovascular Imaging.

Johan HC Reiber, PhD.
Editor-in-chief.

Reference

1. García-Izquierdo E, Moñivas-Palmero V, Forteza A et al (2021) Left atrial strain in the assessment of diastolic function: providing new insights into primary myocardial dysfunction in Marfan syndrome. *Int J Cardiovasc Imaging*. <https://doi.org/10.1007/s10554-021-02247-7>

Publisher's Note Springer Nature remains neutral with regard to jurisdictional claims in published maps and institutional affiliations.

✉ Johan H. C. Reiber
J.H.C.Reiber@lumc.nl

¹ Department of Radiology, Leiden University Medical Center, Leiden, The Netherlands