



Universiteit
Leiden
The Netherlands

Computed tomography-derived transesophageal echocardiographic views step forward for procedural planning of transcatheter tricuspid valve annuloplasty

Fortuni, F.; Hirasawa, K.; Marques, A.I.; Pio, S.M.; Chimed, S.; Lustosa, R.; ... ; Delgado, V.

Citation

Fortuni, F., Hirasawa, K., Marques, A. I., Pio, S. M., Chimed, S., Lustosa, R., ... Delgado, V. (2021). Computed tomography-derived transesophageal echocardiographic views step forward for procedural planning of transcatheter tricuspid valve annuloplasty. *Circulation: Cardiovascular Imaging*, 14(1), 114-117. doi:10.1161/CIRCIMAGING.120.011107

Version: Publisher's Version
License: [Creative Commons CC BY 4.0 license](https://creativecommons.org/licenses/by/4.0/)
Downloaded from: <https://hdl.handle.net/1887/3279651>

Note: To cite this publication please use the final published version (if applicable).

CARDIOVASCULAR IMAGES

Computed Tomography-Derived Transesophageal Echocardiographic Views Step Forward for Procedural Planning of Transcatheter Tricuspid Valve Annuloplasty

Transthoracic and transesophageal echocardiography (TEE) and multidetector row computed tomography (MDCT) are pivotal in the selection of patients and preprocedural planning of transcatheter valvular interventions.¹⁻³ For transcatheter tricuspid valve (TV) annuloplasty with the Cardioband system (Edwards Lifesciences, Irvine, CA), high spatial resolution data acquired with MDCT permit accurate measurement of the dimensions of the TV annulus to select the device size and assessment of the distance between the TV annulus and the right coronary artery (Figure 1).¹ Echocardiography is the mainstay imaging modality to grade tricuspid regurgitation severity and to assess its mechanism. To guide the procedure, TEE and fluoroscopy are the imaging techniques of choice. However, TEE has lower spatial resolution compared with MDCT and does not allow to identify the course of the right coronary artery along the TV annulus. Furthermore, considered the relative far position of the TV from the TEE probe, in most patients it might be difficult to image the location where the anchors of the Cardioband system should be placed. A dedicated software (3mensio, Pie Medical Imaging BV) for post-processing MDCT data permits to reproduce TEE views, which may be compared with the TEE images during the intervention. This novel tool may facilitate preprocedural planning and also the communication between interventionalists and imagers. Specifically, for transcatheter TV annuloplasty, it may help to better understand the individual anatomy of the TV annulus and allows to place the anchors of the device and identify the best TEE views to guide the procedure (Figure 2 and Video 1 in the [Data Supplement](#)).

We present a case of a 78-year-old patient with residual severe secondary tricuspid regurgitation after transcatheter edge-to-edge TV repair and New York Heart Association class III heart failure symptoms who underwent transcatheter TV annuloplasty because of high operative risk. In the preoperative TEE evaluation, the imaging of the anterior portion of the TV annulus was particularly challenging. The MDCT-derived TEE views were determinant in identifying the best TEE probe position and angulation to visualize the predicted location of the anchors (Figure 3A and 3B). The procedure was successful with a significant reduction of the annular diameter and tricuspid regurgitation grade (Figure 3C) that was accompanied by an improvement in heart failure symptoms 1 month after the procedure.

Federico Fortuni, MD
Kensuke Hirasawa^{ORCID}, MD, PhD
Ana I. Marques^{ORCID}, MD
Stephan M. Pio, MD
Surenjav Chimed, MD
Rodolfo Lustosa, MD
Catherina Tjahjadi, MD
Xu Wang, MD
Jeroen J. Bax, MD, PhD
Nina Ajmone Marsan, MD, PhD
Victoria Delgado^{ORCID}, MD, PhD

ARTICLE INFORMATION

The Data Supplement is available at <https://www.ahajournals.org/doi/suppl/10.1161/CIRCIMAGING.120.011107>.

Correspondence

Victoria Delgado, MD, Department of Cardiology, Heart Lung Center, Albinusdreef 2 2300 RC Leiden, the Netherlands. Email v.delgado@lumc.nl

Key Words: echocardiography
■ fluoroscopy ■ multidetector
computed tomography ■ tricuspid valve

© 2021 American Heart Association, Inc.

<https://www.ahajournals.org/journal/circimaging>

Affiliations

Department of Cardiology, Leiden University Medical Center, The Netherlands (F.F., K.H., S.M.P., S.C., R.L., C.T., X.W., J.J.B., N.A.M., V.D.). Department of Molecular Medicine, Unit of Cardiology, University of Pavia, Italy (F.F.). Department of Cardiology, Hospital Garcia de Orta, Almada, Portugal (A.I.M.).

Sources of Funding

None.

Disclosures

Dr Lustosa received funding from the European Society of Cardiology in form of an ESC Research Grant. The reference of application number is R-2018-17759. Dr Pio received funding from the European Society of Cardiology in form of an ESC Training Grant. The reference of application number is T-2018-17405. The Department of Cardiology of the Leiden University Medical Center received research grants from Abbott Vascular, Bioventrix, Medtronic, Biotronik, Boston

Scientific, GE Healthcare and Edwards Lifesciences. Drs Bax and Ajmone Marsan received speaking fees from Abbott Vascular. Dr Delgado received speaker fees from Abbott Vascular, Medtronic, MSD, Edwards Lifesciences, and GE Healthcare. The other authors report no conflicts.

REFERENCES

1. Naoum C, Blanke P, Cavalcante JL, Leipsic J. Cardiac computed tomography and magnetic resonance imaging in the evaluation of mitral and tricuspid valve disease: implications for transcatheter interventions. *Circ Cardiovasc Imaging*. 2017;10:e005331. doi: 10.1161/CIRCIMAGING.116.005331
2. Hahn RT. State-of-the-art review of echocardiographic imaging in the evaluation and treatment of functional tricuspid regurgitation. *Circ Cardiovasc Imaging*. 2016;9:e005332. doi: 10.1161/CIRCIMAGING.116.005332
3. Dulgheru R, Pibarot P, Sengupta PP, Piérard LA, Rosenhek R, Magne J, Donal E, Bernard A, Fattouch K, Cosyns B, et al. Multimodality imaging strategies for the assessment of aortic stenosis: viewpoint of the Heart Valve Clinic International Database (HAVEC) Group. *Circ Cardiovasc Imaging*. 2016;9:e004352. doi: 10.1161/CIRCIMAGING.115.004352

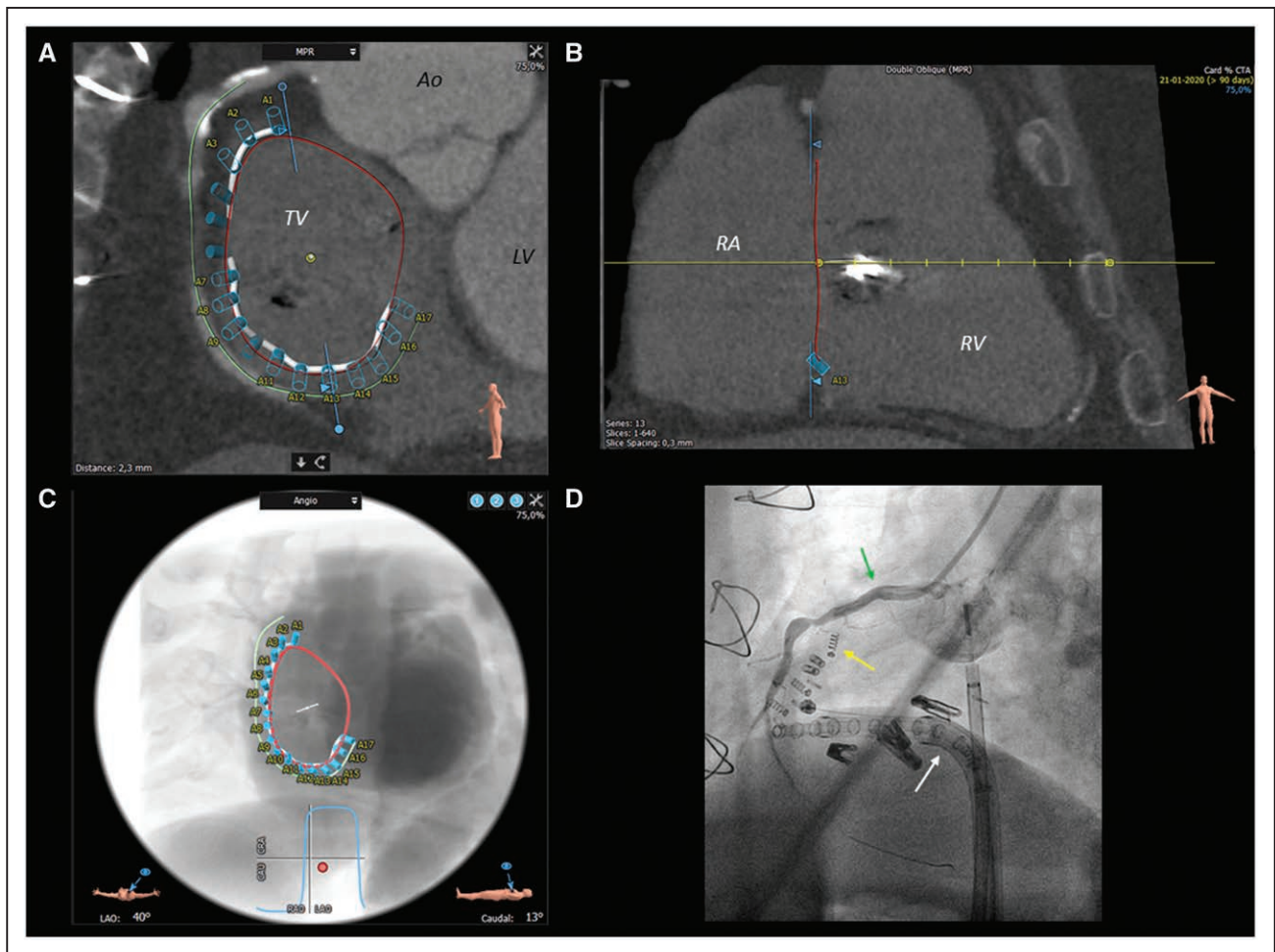


Figure 1. Key steps for preprocedural planning of transcatheter tricuspid valve (TV) annuloplasty.

A, A multidetector row computed tomography view of the TV plane. The TV annulus (red circle) and the right coronary artery (green line) can be manually defined to predict the best location for the anchors of the Cardioband system (A1–A17). The plane to best visualize the TV can be adjusted on the corresponding sagittal view (**B**). **C**, Displays a predicted left anterior oblique (LAO) fluoroscopic view with the structures that have been previously defined and that corresponds well to the intraoperative fluoroscopic view (**D**), where the right coronary artery (green arrow), anchors (yellow arrow), and delivery system (white arrow) can be identified. Ao indicates aorta; CAU, caudal; CRA, cranial; LV, left ventricle; MPR, multiplanar reconstruction; RA, right atrium; and RV, right ventricle.

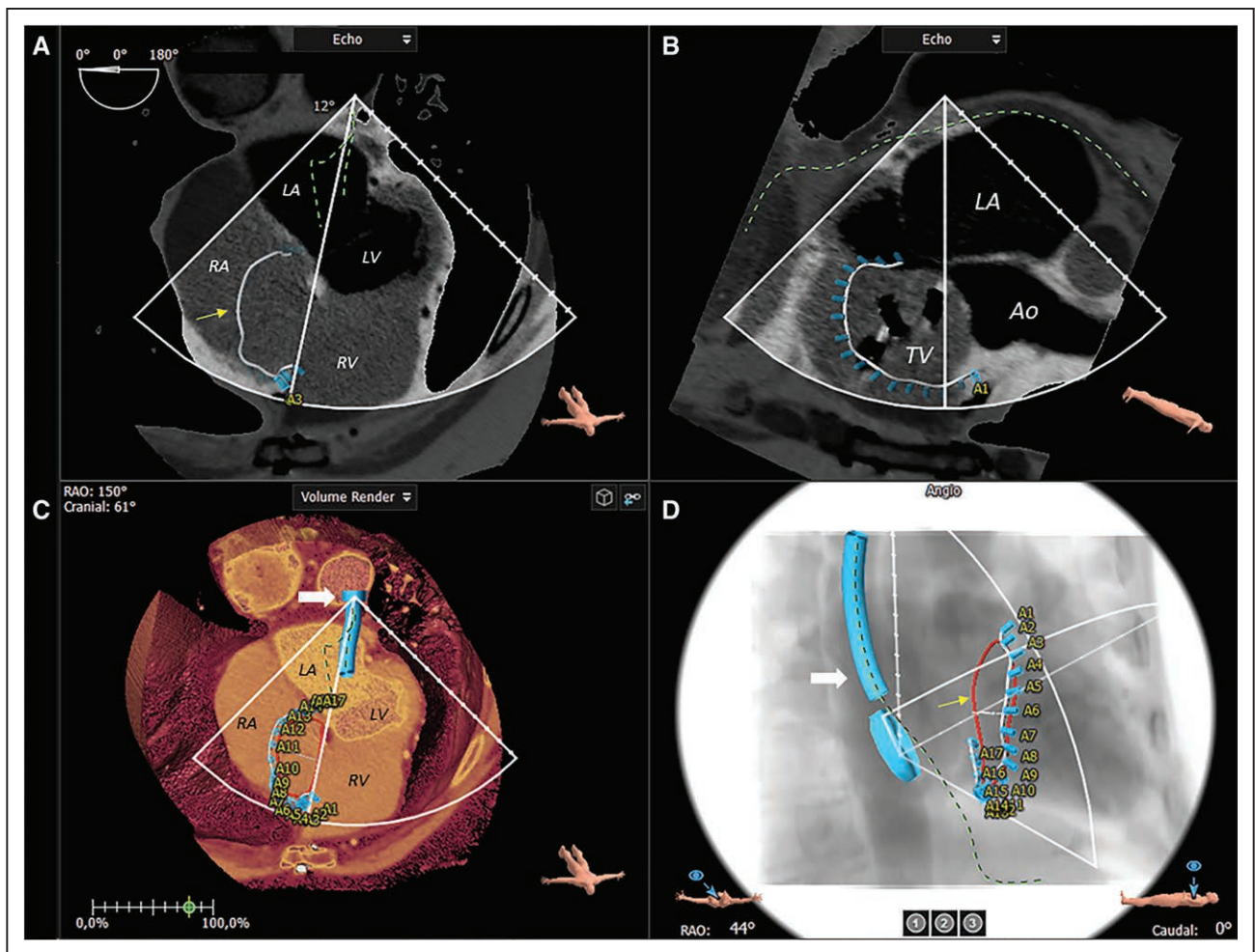


Figure 2. Computed tomography-derived transesophageal echocardiography (TEE) views for preprocedural planning of transcatheter tricuspid valve (TV) annuloplasty.

The software for postprocessing multidetector row computed tomography (MDCT) data permit to trace the TV annulus (yellow arrow), right coronary artery, predict the position of the anchors (A1–A17) of the Cardioband system, and identify the best TEE views to image them. **A**, Shows the mid-esophageal 4-chamber MDCT-derived TEE view focused on the right chambers. The cursor may be placed across the TV to obtain an orthogonal view to display a modified mid-esophageal bicaval view of the TV (**B**). **C**, Shows the 3-dimensional rendering of the heart with the TEE probe (white arrow) located posteriorly at the mid-esophageal level, while (**D**) shows the predicted position of the TEE probe on the fluoroscopic projection during the procedure. A indicates anchor; Ao, aorta; LA, left atrium; LV, left ventricle; RA, right atrium; RAO, right anterior oblique; and RV, right ventricle.

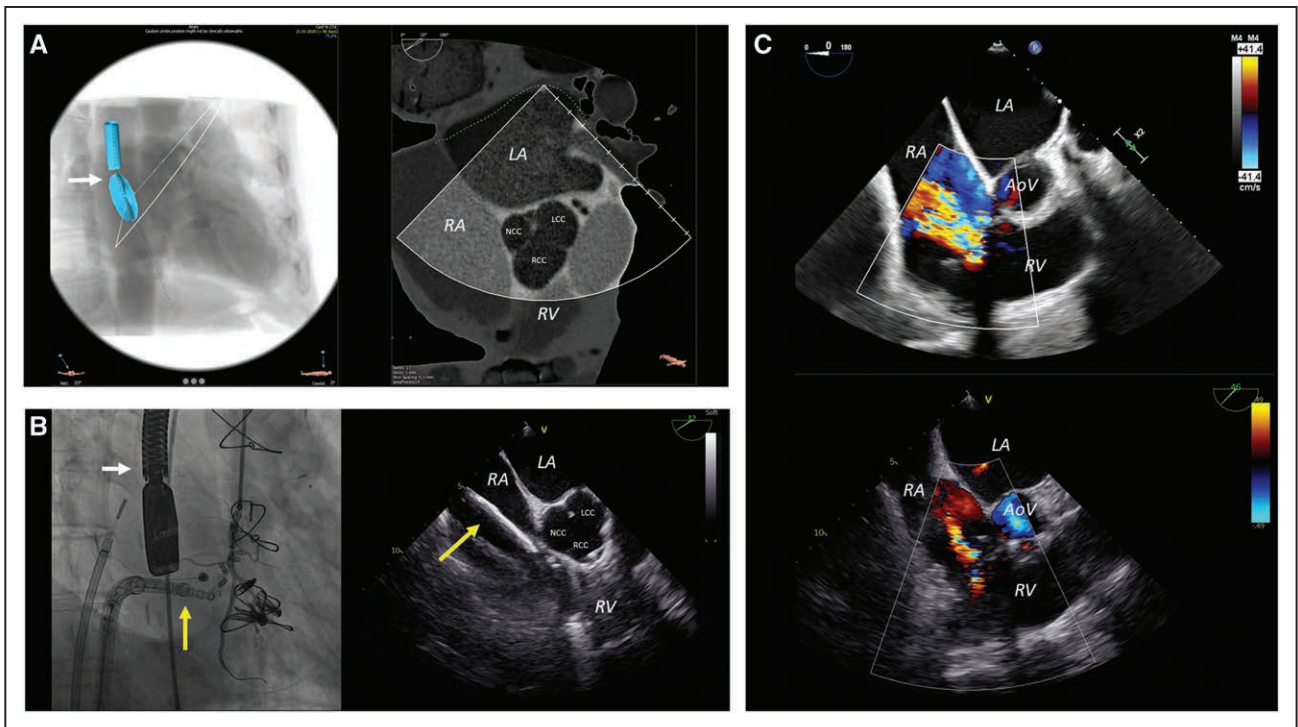


Figure 3. Computed tomography-derived transesophageal echocardiography (TEE) views to guide transcatheter tricuspid valve (TV) annuloplasty. The software allows to postprocess multidetector row computed tomography data (A), place the virtual TEE probe (white arrow), and adjust the settings to derive the best TEE view to image the location where the anchors should be placed. B, Shows the corresponding intraprocedural fluoroscopic and TEE views where the catheter (yellow arrow) approaching the TV annulus to place one of the first anchors can be identified. C, Demonstrates the reduction of tricuspid regurgitation grade from severe (upper image) to moderate (lower image) after successful transcatheter TV annuloplasty. AoV indicates aortic valve; LA, left atrium; LCC, left coronary cusp; NCC, noncoronary cusp; RA, right atrium; RCC, right coronary cusp; and RV, right ventricle.