Universiteit
Leiden
The Netherlands

Identifying patients with epilepsy at high risk of cardiac death: signs, risk factors and initial management of high risk of cardiac death

Surges, R.; Shmuely, S.; Dietze, C.; Ryvlin, P.; Thijs, R.D.

Citation

Surges, R., Shmuely, S., Dietze, C., Ryvlin, P., & Thijs, R. D. (2021). Identifying patients with epilepsy at high risk of cardiac death: signs, risk factors and initial management of high risk of cardiac death. *Epileptic Disorders*, *23*(1), 17-39. doi:10.1684/epd.2021.1254

Version:	Publisher's Version
License:	Creative Commons CC BY-NC-ND 4.0 license
Downloaded from:	https://hdl.handle.net/1887/3251152

Note: To cite this publication please use the final published version (if applicable).

Seminar of Epileptology

Epileptic Disord 2021; 23 (1): 17-39

Epileptic Disorders

Identifying patients with epilepsy at high risk of cardiac death: signs, risk factors and initial management of high risk of cardiac death

Rainer Surges [1], Sharon Shmuely [2,3], Christoph Dietze [2], Philippe Ryvlin [4], Roland D. Thijs [2,3,5]

[1] Department of Epileptology, University of Bonn Medical Centre, Venusberg-Campus 1, 53127 Bonn, Germany
[2] Stichting Epilepsie Instellingen Nederland - SEIN, Achterweg 5, 2103 SW, Heemstede, The Netherlands
[3] NIHR University College London Hospitals Biomedical Research Centre, UCL Queen Square Institute of Neurology, Queen Square, London WC1N 3BG, UK
[4] Department of Clinical Neurosciences, CHUV, rue du Bugnon 21, 1011, Lausanne, Switzerland
[5] Department of Neurology, Leiden University Medical Centre, Albinusdreef 2, 2333 ZA, Leiden, The Netherlands

Received June 16, 2020;
Accepted October 14, 2020

ABSTRACT – People with epilepsy have a three-fold increased risk of dying prematurely, and a significant proportion is due to sudden cardiac death or acute myocardial infarctions. The causes of increased cardiovascular morbidity and mortality in epilepsy are manifold and include acute or remote effects of epileptic seizures, the longstanding epilepsy itself or antiseizure treatments. Seizure-related cardiac arrhythmias are common and comprise bradyarrhythmia and asystole, atrial fibrillation and ventricular tachycardia. The most frequent clinically relevant seizure-related arrhythmia is ictal asystole that may require implantation of a cardiac pacemaker, whereas seizure-related ventricular tachycardias are only rarely reported. Takotsubo cardiomyopathy and myocardial infarction are rare complications and predominantly described in association with tonic-clonic seizures. Epilepsy-related cardiac complications include a disturbed cardiac autonomic nervous system and acquired dysfunction of the heart (recently defined as ‘epileptic heart’), probably contributing to the abnormalities of cardiac repolarisation and elevated risk of sudden cardiac death in people with epilepsy. If successful, the use of antiseizure medication prevents seizure-related cardiac arrhythmias and remote cardiac complications. However, enzyme-inducing antiseizure medications have a negative impact on cardiovascular risk factors, which may further be aggravated by weight gain linked to specific antiseizure drugs. Given the severe consequences of cardiac risks, the aim of this educational review is to explain the many facets of cardiac complications and their underlying causes, and to enable the reader to recognize and manage these risks with the goal to mitigate the cardiac risks in people with epilepsy. Features of syncope are explained in detail, as syncope of all origins can be mistaken as epileptic seizures in people with or without epilepsy, and ictal syncope (*i.e.* seizure-induced syncope) can easily be ignored.

Key words: cardiac arrhythmias; coronary artery disease; electrocardiogram; antiseizure medication; antiepileptic drugs; syncope; sudden cardiac death; premature mortality

ILAE ACADEMY

CC BY NC ND

• Correspondence:
Rainer Surges
Department of Epileptology,
University of Bonn Medical
Centre,
Venusberg-Campus 1,
53127 Bonn, Germany
<rainer.surges@ukbonn.de>

doi:10.1684/epd.2021.1254

Learning objectives [1]

- Acquire competency to distinguish syncope from epileptic seizures.
- Understand and explain the manifold cardiac complications and their causes in people with epilepsy (PWE).
- Acquire competency to recognize and anticipate cardiac complications in PWE by thorough history taking, analysing clinical signs of seizures and making use of basic tools such as 12-lead ECG and simultaneous one-lead ECG during EEG recordings.
- Understand and recognize the potential contribution of antiseizure treatments to cardiac complications in PWE.
- Acquire competency to take actions to manage and to reduce the risk of cardiac complications in PWE.

People with epilepsy (PWE) have a 2-3-fold increased risk of dying prematurely as compared to the general population, which is, in a significant proportion (15%), due to sudden cardiac death (SCD) or acute myocardial infarctions [2-6]. This may be partly explained by higher prevalence of comorbid cardiac conditions and a higher burden of cardiovascular risk factors [7, 8]. For instance, PWE are more often obese, physically inactive and current smokers, and their cardiovascular risk profile (*i.e.* hypercholesterolaemia, diabetes mellitus, metabolic syndrome) is worse than in the general population [9-12]. Intriguingly, reports of cardiac arrhythmias and cardiac pathology at post-mortem evaluation in PWE suggest a cardiac component to the pathology of sudden unexpected death in epilepsy (SUDEP) or that at least in some cases, SCD and SUDEP are overlapping entities [13], underscoring the clinical importance to understand the signs and symptoms of cardiac complications in PWE. In addition, the increased mortality of status epilepticus may also be linked to cardiovascular complications, as recently reviewed [14]. The causes of elevated cardiovascular morbidity and mortality in PWE are manifold and include detrimental effects of epileptic seizures, treatment and epilepsy itself [15-19]. Given the potentially severe consequences of cardiac conditions, we summarize in this educational review the many facets of cardiac complications and their underlying causes, and explain how to recognize and manage them to mitigate the cardiac risks in PWE.

The spectrum of cardiac complications in epilepsy

PWE can of course suffer from all types of cardiac pathology including infection and inflammation of the pericardium, myocardium and endocardium, abnormalities of the cardiac valves, coronary artery disease (CAD), and cardiac arrhythmias. The risk of the two latter, however, is significantly elevated in PWE [16, 19], prompting the need for systematic assessment of putative causes and related signs in PWE.

CAD is due to obstructions of the coronary arteries, leading to insufficient blood flow and impaired oxygen supply, which in turn causes reversible or irreversible myocardial ischaemia. Classic signs of symptomatic CAD include chest pain, elevations of circulating cardiac injury markers such as troponin, and typical ECG alterations such as ST segment elevation. Seizure-related sustained, generalized muscle activity along with profound cardiorespiratory dysfunction bear, in the presence of CAD, an elevated risk of myocardial ischaemia (see section on *Seizure-related cardiac complications*).

Cardiac arrhythmias are due to altered electrical properties of cardiac tissue leading to disturbed excitation and conduction in the atria and ventricles; heartbeats can be slowed (bradyarrhythmia, asystole) or accelerated (tachycardia), regular or irregular, and the coordinated contractions of atria and ventricles can be disturbed (*table 1*). Typical clinical manifestations include palpitations, symptoms and signs due to syncope (see below). Cardiac arrhythmias may also manifest indirectly by embolic events (*e.g.* thromboembolic stroke due to atrial fibrillation). ECG recordings are key to the diagnosis of cardiac arrhythmias, and the interpretation of a 12-lead ECG is part of the general skills of physicians (*figure 1, table 2*). Most, if not all forms of cardiac arrhythmias were described in PWE in the absence of, or in association with seizures (*figure 2*) [17, 20]. If the extent and duration of these cardiac alterations are large and long enough, they lead to a significant reduction of cardiac output with a subsequent drop in systemic arterial blood pressure (BP). This, in turn, causes hypoperfusion of body organs including the brain, heart and kidneys (*figure 2*). If the hypoperfusion is sufficiently long or sustained, this leads to irreversible damage of all end organs and to death. In contrast, a transitory drop of global cerebral perfusion is linked to a transient loss of consciousness (TLOC) only, which is called syncope (see below). As symptoms of syncope resemble those of epileptic seizures, it can be challenging to make the correct diagnosis of syncope especially in PWE. At the same time, syncope of different origins can be mistaken for epileptic seizures, leading to

▼ **Table 1.** Description and definition of selected ECG features and their abnormalities. For further reading see [142].

ECG features and cardiac abnormalities	Description / definition
Sinus rhythm	Regular RR intervals between 600-1000 ms Every P wave is followed by a QRS complex
Tachycardia and tachyarrhythmia (RR intervals < 600 ms)	
Tachycardia with narrow QRS complexes (<120 ms)	Regular RR intervals: sinus tachycardia, atrioventricular nodal re-entry tachycardia, atrial flutter Irregular RR intervals: atrial fibrillation
Tachycardia with wide QRS complexes (>120 ms)	Regular RR intervals: sinus tachycardia with pre-existing aberrant conduction Regular or irregular RR intervals: ventricular tachycardia, ventricular flutter Ventricular fibrillation without organised QRS complexes
Bradycardia and bradyarrhythmia (RR intervals > 1000 ms)	
Bradycardia	Wide QRS complexes and regular RR intervals: sinus bradycardia with pre-existing aberrant conduction, ventricular escape rhythm Narrow QRS complexes and irregular RR intervals: atrial fibrillation, sick sinus Narrow QRS complexes and regular RR intervals: sinus bradycardia (sick sinus, sleep), atrioventricular block
Bradycardia due to atrioventricular (AV) block	2nd degree AV-block Type I (Wenckebach): PR interval gradually increases until one QRS complex is blocked Type II (Mobitz): PR interval normal, but not every P wave is followed by QRS complex (2:1, 3:1, …) 3rd degree AV-block: complete block, AV dissociation
Conduction interval abnormalities	
PR interval	PR interval >200 ms: 1st degree AV-block PR interval <120 ms (plus 'delta wave'): pre-excitation syndrome (Wolff-Parkinson-White syndrome)
Wide QRS complex (> 120 ms)	Left bundle branch block (LBBB): RsR' in V6 Right bundle branch block (RBBB): RsR' in V1 Intraventricular conduction delay: not RBBB or LBBB
Repolarisation abnormalities	
QT interval	QT intervals depend on sex, age and heart rate [141] Need to be corrected for heart rate using different formulas (*e.g.* Bazett, Fridericia, Framingham or Hodges)
QT interval prolongation	Corrected QT intervals (Fridericia) >465 ms in women and >457 ms in men, when heart rate 60-99 bpm [141] Many reasons, *e.g.* various medications, post-myocardial infarction, genetic long QT syndrome Elevated risk of Torsade de Pointes and subsequent ventricular fibrillation
QT interval shortening	Genetic short QT syndromes with corrected QTc <320 ms Acquired/non-familiar short QT with corrected QT <400 ms have a 2-fold increased risk for sudden cardiac death due to ventricular tachycardia or fibrillation
QT dispersion (QTd)	Difference between shortest/longest QT interval on 12-lead ECG Reflects regional heterogeneity of cardiac repolarisation QTd >50 ms associated with increased risk of sudden cardiac death
T-wave alternans (TWA)	Beat-to-beat alternation of morphology/amplitude of ST segment/T-wave Reflects temporal-spatial heterogeneity of cardiac repolarisation The higher TWA, the more likely onset of ventricular tachyarrhythmia

▼ **Table 1.** Description and definition of selected ECG features and their abnormalities. For further reading see [142] (continued).

ECG features and cardiac abnormalities	Description / definition
ST segment abnormalities	
ST elevation	Elevated in myocardial infarction, pericarditis, left ventricular hypertrophy, early repolarisation Myocardial infarction: Elevation >0.1 mV in limb leads or >0.2 mV in precordial leads
ST depression	Abnormal >0.1 mV in V5-V6, or >0.15 mV in AVF or III Can mirror ischaemia (‘reciprocal’ ST elevation) Can occur in left ventricular hypertrophy, digoxin intoxication
Negative T wave	Not the same polarity as the QRS complex May indicate subendocardial ischemia or be associated with left ventricular hypertrophy

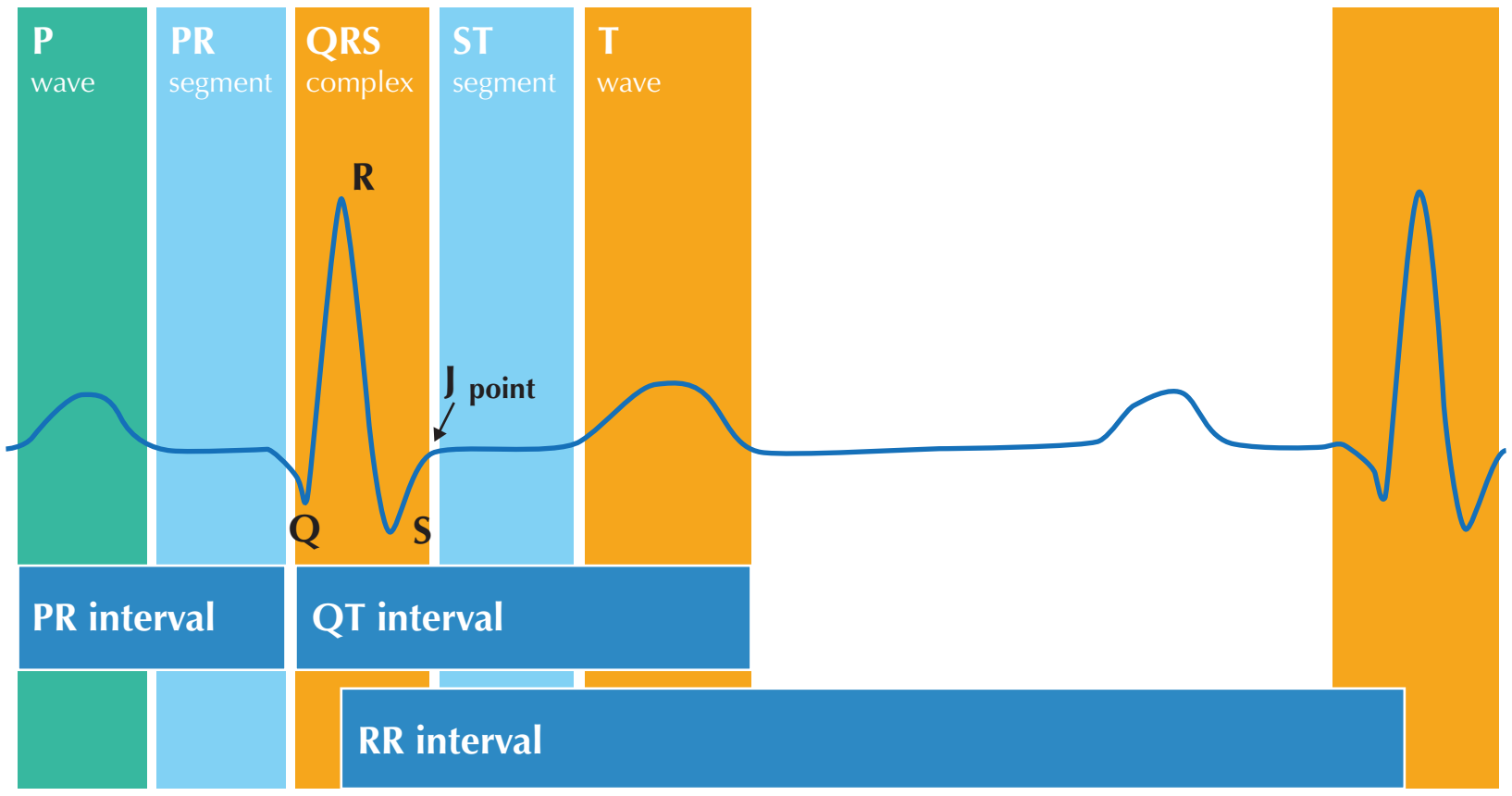

P wave	**≤ 80 ms**
PR interval	**120-200 ms**
QRS complex	**80-120 ms**
ST segment	**≤ 0.1 mV mV/0.2 mV (40 ms after J point limb/precordial leads)**
QTc interval	**374 - 465 ms (females), 368 - 457 ms (males)**
RR interval	**600 - 1000 ms (Heart rate 60 - 100 bpm)**

■ **Figure 1.** ECG features and reference values. QTc intervals corrected with Fridericia’s formula [141].

the false diagnosis of epilepsy. Maybe the most difficult challenge is to make the correct diagnosis of ictal syncope, *i.e.* syncope that is induced by an epileptic seizure (see below), which is typically made in the setting of continuous video-EEG monitoring (VEM).

Syncope

Syncope results from global cerebral hypoperfusion which, in turn, is caused by a temporary low systemic arterial BP. The decrease in BP may provoke a range

Table 2. Overview of diagnostic tools and description of typical clinical constellation when these tools are helpful.

Diagnostic tool	Typical clinical constellation when tool is recommended
12-lead ECG	All patients at the time of epilepsy diagnosis Patients with polypharmacotherapy including drugs with potential cardiac effects, *e.g.* a combination of sodium channels blockers, but also patients with other drugs prescribed for arterial hypertension or cardiac arrhythmia Patients with (suspected) syncope
Holter recordings (usually 24-72 hours)	Patients with suspected paroxysmal arrhythmias
Implantable loop recorders (long-term) or ECG patches*	Patients with (very) rare episodes of suspected syncope (or seizures) or to monitor patients with ictal asystole without pacemaker implantation
Video-EEG monitoring along with one-lead ECG	Patients with suspected ictal asystole (or syncope)
Serum markers of cardiac injury (*e.g.* troponin)	Cardiac complaints following a TCS (irrespective of the age) Following a TCS in people older than 70 years or with known cardiac diseases

ECG patches allow non-invasive multiday monitoring up to 3 to 4 weeks, thereby increasing the chance of capturing arrhythmias, seizures and syncope [143, 144].

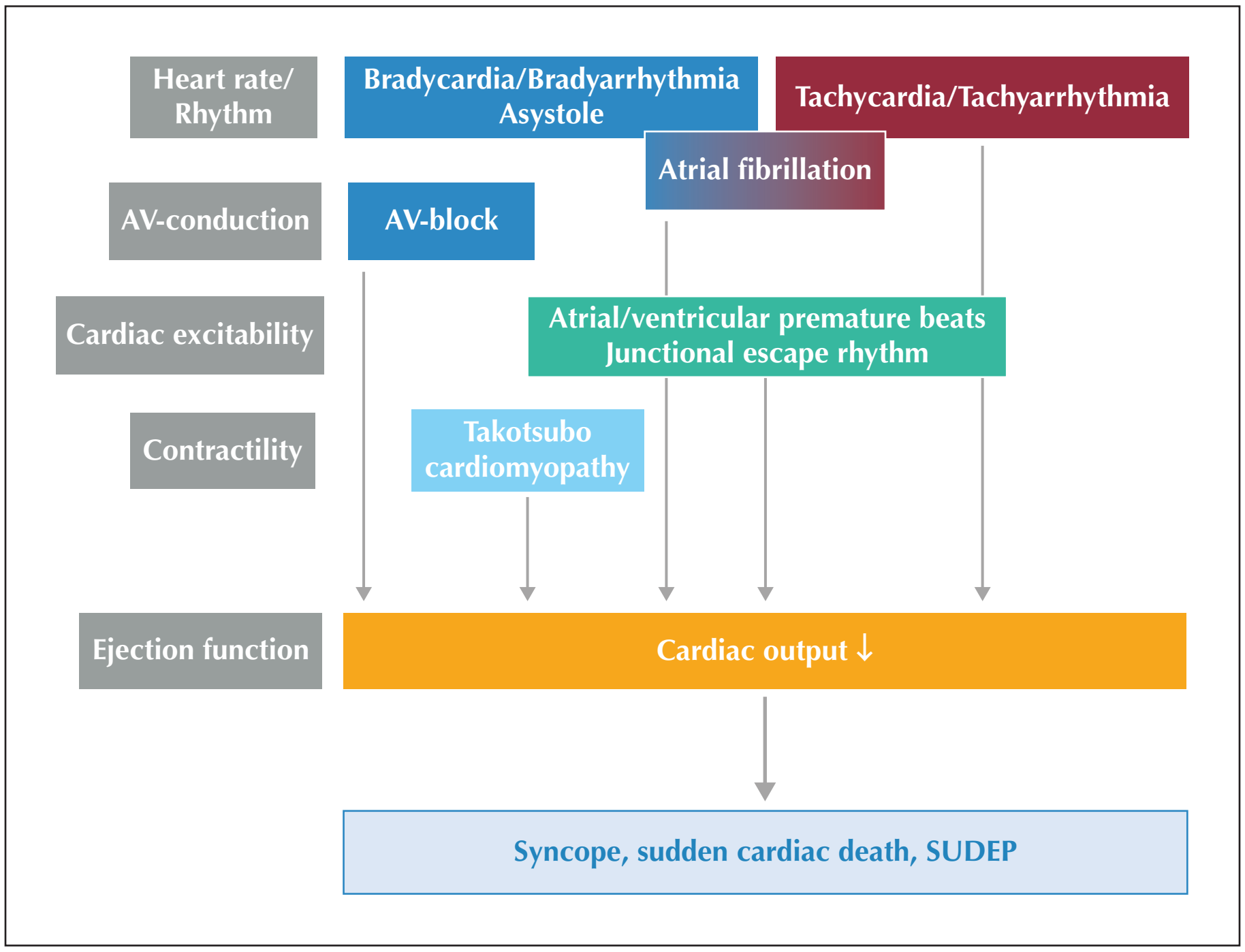
Heart rate/ Rhythm
Bradycardia/Bradyarrhythmia Asystole
Tachycardia/Tachyarrhythmia
Atrial fibrillation
AV-conduction
AV-block
Cardiac excitability
Atrial/ventricular premature beats Junctional escape rhythm
Contractility
Takotsubo cardiomyopathy
Ejection function
Cardiac output ↓
Syncope, sudden cardiac death, SUDEP

Figure 2. Seizure-related cardiac complications and consequences.

of symptoms and signs, dependent on the severity and the speed of the BP drop and the ability of the cerebral autoregulation to compensate for the low BP [21]. The symptoms and signs of syncope can be categorized into two groups. The first group comprises the consequences of the cerebral or retinal hypoperfusion due to the failure of the systemic perfusion. These features are similar for all causes of syncope. The second group are the complaints specific to the form of syncope and will be detailed later.

Patients will only report symptoms of cerebral or retinal hypoperfusion if the fall in arterial pressure is slow enough to perceive symptoms and to "store" the sensations for later recall [22]. Conversely, if the fall in arterial BP is too steep, syncope may occur without prodromes. Subjects may even be unable to recall loss of consciousness (LOC) ('amnesia for amnesia') and thus present with unexplained falls. This presentation is more common in the elderly. As BP decreases, subjects often report 'light-headedness' or dizziness as the first symptom of low cerebral perfusion. Other descriptions include 'fading out' or 'emptiness in the head'. If BP drop is slow, blurred vision and loss of peripheral vision may ensue as a second symptom relating to retinal hypoperfusion. Some subjects report "grey out" (loss of colour vision) or "black out" (darkened vision). Hearing loss may occur following loss of vision. With further BP decline, subjects have difficulty concentrating and become unaware of their surroundings. A brief period of staring and an inability to act may occur prior to complete syncope [22]. Eventually, when BP reaches the critical closing pressure, patients will fall and lose consciousness. LOC usually ensues when systolic BP is 60 mm Hg or lower but may also occur at higher BP when the BP drop is steep [23].

The clinical signs are linked to the severity of the cerebral hypoperfusion and reflected by the EEG patterns seen in syncope. Mild cerebral hypoperfusion will cause a generalized "slow" EEG pattern (a short-lasting period of abnormal delta waves), whereas in severe hypoperfusion, a "slow-flat-slow" pattern is seen; the generalized slow pattern is followed by a generalized flattening of the EEG, in turn, followed by a slow pattern of delta waves as the cerebral perfusion restores and then return to a normal EEG pattern. The EEG flattening is mostly seen in syncope involving asystole (*e.g.* cardioinhibitory vasovagal syncope), but can also occur in vasovagal syncope without asystole, other arrhythmias and in orthostatic hypotension [23]. The EEG only reflects the cortical brain functions. Signs during a flat EEG can thus not be explained by cortical functions and likely point towards brain stem activity. Signs of brainstem dysfunction appear later than signs of cortical dysfunction, probably because the brainstem is more resistant to ischaemia. Some clinical signs are mostly seen during the slow phase of the EEG, some mostly during the flattening of EEG and some clinical features are present during both phases [21].

LOC usually starts in the slow phase. Eye opening and loss of muscle tone (*e.g.* head dropping) and a vacant expression often constitute the very first signs and are usually followed by many other motor phenomena, varying between subjects and between events [22]. Myoclonic jerks are seen in about half of the subjects and usually appear after the subject has fallen [24]. The jerks are strongly associated with the slow phase of the EEG. If a second bout of myoclonic jerks occurs, this starts during the second slow phase. The jerks rarely occur during the flat EEG, thus indicating that their presence signifies decreased but not complete shut-down of cortical activity. The number of jerks is rarely more than 10 [24]. The jerks are typically asynchronous and can be restricted to one side. The eyes are often closed before LOC, but open at onset of unconsciousness, with the pupils mostly directed upwards. If head turning is present, it starts quite early relative to the slow phase. Oral automatisms are seen in about half of the subjects and may occur both during the slow phase of the EEG and during the flat phase [21]. Snoring, gasping, roving eye movements, making sounds and posturing are strongly associated with EEG flattening and thus probably reflect brainstem activity. The duration of unconsciousness rarely exceeds one minute. Eyewitnesses may, however, report longer durations due to the emotional impact of the situation [25]. Subjects rarely bite their tongue; if tongue biting occurs, it is the consequence of the fall and concerns the tip of the tongue. Urine incontinence may occur during syncope, but faecal incontinence is rare [26].

In all forms of syncope, patients recover quickly and are almost immediately clear-headed. If any disorientation occurs, it would likely last <10 seconds. The only exceptions to the rule might be those who are kept upright during the event and thus suffer from a more severe and prolonged period of brain anoxia [27], or when an abrupt fall will be responsible for a significant head trauma. The duration of syncope is usually too short to cause observable brain damage. It has, however, been demonstrated that the risk of white matter lesions is slightly increased in those with frequent (more than five events of) syncope [28].

Reflex or vasovagal syncope (VVS)

The signs and symptoms of VVS can be divided into two groups. The first concerns the symptoms and signs due to retinal and cerebral hypoperfusion, as described before. The second group is due to the underlying cause: an abnormal reflex of the otherwise normal autonomic nervous system. This 'vasovagal' reflex is characterized by vagally (parasympathetically) mediated bradycardia or even asystole with or without withdrawal of the sympathetically driven vasoconstriction. These changes in autonomic activity cause a specific set of signs and symptoms, labelled as 'autonomic activation', including perspiration, facial pallor, nausea, vomiting, and pupillary dilatation. Autonomic activation is often reported by younger subjects with VVS but less often by the elderly, due to the inability to recall or identify these symptoms or due to mere absence of these signs in the elderly.

It is essential to always enquire about the circumstances in patients with TLOC as VVS never occurs randomly [26]. It is usually precipitated by emotional triggers (*e.g.* fear, pain, emotional distress or their anticipation) or triggers that facilitate venous pooling (*e.g.* upon standing, prolonged standing, heat, cessation of exercise, coughing, defecation, swallowing, micturition) or stimulate the carotid sinus (pressure on the neck). At times, various triggers may have a cumulative effect (*e.g.* watching an emotional scene on the television in a sitting position as an orthostatic trigger). Warning symptoms (including autonomic activation) start on average between 30-60 seconds before the actual onset of unconsciousness but may vary between individuals. Sweating, pupillary dilatation and deathly pallor are frequent early signs [21, 23]. Patients may be able to prevent actual syncope if they recognise these symptoms at an early stage and if they act immediately by sitting, squatting or lying down. Counterpressure manoeuvres (*e.g.* leg crossing) are also effective to prevent further TLOC. In some patients, the BP remains low after the patient has regained consciousness, resulting in a recurring tendency to faint every time he or she is returned to the upright position ('status vasovagalis') [27]. A noticeable scarlet flush can occur after VVS if the BP recovery is very rapid (cardioinhibitory vasovagal syncope), but is also seen in those with an arrhythmogenic syncope [23].

Case 1

A 25-year-old woman suffered since adolescence from recurrent episodes characterized by an non-specific feeling in the head ("something is wrong, something will happen") followed by loss of consciousness. During these episodes, she frequently fell without injuries. Witnesses reported motor phenomena such as generalized stiffening or myoclonic jerks, and on one occasion she had enuresis, but never a tongue bite. Upon recovery, she often heard very loud noises, she had a feeling of warmth and was often fearful for several seconds. The episodes mostly (if not always) occurred in the context of fear or pain. The duration of the episodes was estimated between 1-2 minutes with a frequency of 2-3 per year. Brain MRI and routine EEG examinations were normal. Epilepsy of unknown aetiology was suspected and she was put on 150 mg lamotrigine.

The patient was seizure-free for more than a year before admission for further evaluation. A venous puncture was performed during video-EEG monitoring which provoked an habitual episode. She had her typical "cephalic aura" followed by loss of consciousness. Her arms stiffened with some posturing (slowly raised), followed by a flaccid phase without apparent movements, transitioning again into stiffening of the torso and both arms. Upon recovery of consciousness, she presented with a fearful face, but could adequately respond within 20 seconds. The simultaneous one-channel ECG recordings showed a progressive decline of heart rate, followed by an asystole of 21 seconds, before regular QRS complexes occurred again. The EEG displayed typical signs of syncope with generalized slowing and rhythmic delta activity for some seconds, followed by a flat EEG, generalized rhythmic delta activity and again physiological resting activity.

It was concluded that the patient suffered from recurrent vasovagal syncope linked to emotional triggers, and lamotrigine was tapered off.

Orthostatic hypotension

Orthostatic hypotension (OH) may cause syncope but often the core symptom is orthostatic intolerance with recurrent presyncope due to prolonged severe hypotension. As in VVS, it is essential to enquire about triggering factors [26]. All triggers that are relevant in VVS may trigger OH, expect for emotional precipitants and those related to the stimulation of the carotid sinus. Some presyncopal symptoms are unique for OH, such as the "loss of ability to act". This is a state in which the BP is too low to think clearly but not low enough to cause LOC. Eyewitnesses may notice a vacant expression and an inability to respond. Often, these events go unrecognised, especially in those with comorbid movement disorders, *e.g.* Parkinson's disease. Another clinical feature specific to neurogenic OH is the 'coat hanger sign'; pain in the neck radiating to the occipital region and shoulders caused by local ischaemia in the upright position. Pain in the lower back, buttocks and chest during orthostatic stress has also been described in OH but the underlying mechanism is unclear. All symptoms resolve when lying down. Transient ischaemic attacks may occur during periods of hypotension, especially if the patient has carotid occlusive disease (hypotensive transient ischaemic attack).

Cardiac syncope

Cardiac syncope can be caused by arrhythmias, structural heart disease or disorders of the great vessels and cardiopulmonary disease (*e.g.* acute aortic dissection). Cardiac syncope usually causes an abrupt TLOC without any specific precipitating event. Exceptions to the rule include syncope *during* exertion, startling (*e.g.* via an alarm clock) or having cold water on the face [26]. TLOC in the supine position should also raise suspicion for a cardiac cause as it makes VVS or OH less likely given the absence of an orthostatic trigger. Due to the abrupt onset of syncope, patients with an arrhythmogenic cause of syncope usually experience no prodromes or a very short prodromal phase. Patients with syncope secondary to structural cardiac, cardiopulmonary and great vessel disease may, however, experience longer prodromal symptoms. These symptoms may relate to cerebral hypoperfusion or hint towards the underlying cause (shortness of breath, chest pain). The duration of the LOC strongly correlates with the duration of the cardiac standstill or loss of cardiac output. Recovery is marked by facial flushing if the systemic circulation is rapidly restored *e.g.* in those with a transient AV block [21, 23].

Contrasts with epilepsy

Generalized or focal to bilateral tonic-clonic seizures (TCS) could be misdiagnosed as reflex syncope, as motor phenomena also frequently occur in the latter. Nonetheless, the semiology differs between the two, and one important feature is the number of jerks; fewer myoclonic jerks are seen in vasovagal syncope than in epileptic seizures. In this regard, the "10/20 rule" has been proposed [24]. There is a lack of overlap in the number of jerks between VVS and epileptic seizures, with less than 10 jerks pointing towards reflex syncope and more than 20 jerks towards a TCS. The motor phenomena start in syncope after the fall of the patient, whereas in TCS, the jerks may start before the onset of unconsciousness. The presence of urine incontinence does not discriminate between syncope and seizures [26]. A lateral tongue bite, a long period of postictal coma, confusion or amnesia are, however, strong clues favouring TCS [26]. The typical clinical features of syncope and the clues to distinguish syncope from TCS are summarized in *table 3*.

Seizure-related cardiac complications

Epileptic seizures, focal and generalized, are known to induce autonomic imbalance [29]. Activation and inhibition of the sympathetic and parasympathetic branches of the central autonomic nervous system commonly occur during and after seizures [30], involving the areas that control heart activity including the insula and hippocampus [31-33]. During most seizures, sympathetic outflow increases, which is reflected by tachycardia, tachypnoea, increased blood pressure, facial flushing, pupillary dilatation and diaphoresis [30]. Parasympathetic activation can also predominate, which involves bradycardia, bradypnea, miosis and increased salivation [30].

Ictal tachycardia

Seizure-related cardiac and respiratory changes were extensively studied in the last decade, in particular because of their potential role in SUDEP and seizure detection. Peri-ictal cardiac arrhythmias are common (*figure 2*) [20]. The commonest arrhythmia is ictal tachycardia. Ictal tachycardia is seen in up to 80% of all seizures and in 82% of PWE [34, 35]. Ictal tachycardia is usually asymptomatic (thus no true complication), and potentially helpful to automatically detect seizures based on heart rate features using wearable devices [36].

Ictal bradyarrhythmia

Bradycardia and asystole can be caused by silencing sinus node activity in the right atrium or by blocking the atrioventricular (AV) conduction system. Ictal asystole is defined in most studies as heart rate with RR intervals longer than 3 seconds. It was reported to occur in 0.32% of people with difficult-to-treat focal epilepsy admitted for VEM, mostly in people with temporal lobe epilepsy [20]. Suppression of sinus node activity appears to be the predominant cause of ictal asystole, but complete AV block was also described during focal seizures in a few non-SUDEP cases [20]. Ictal asystole can cause falls and injuries due to seizure-induced syncope. For many years, ictal asystole was thought to be a possible mechanism of SUDEP. In all but one of the reported cases, however, the ictal asystole was self-limiting [20]. In this one case, the asystole lasted for 44 seconds, after which the person was resuscitated successfully [37]. The case was classified as 'near-SUDEP' [38]. The longest ictal asystole reported lasted 96 seconds and was self-limiting [39]. One case with ictal asystole fell victim to SUDEP despite a well-functioning pacemaker, suggesting ictal asystole was benign and did not cause death [40]. This case suggests that terminal asystole in SUDEP is not primarily a cardiac mechanism.

Ictal asystole with subsequent syncope ('ictal syncope') is characterised by sudden loss of muscle tone during a focal seizure with impaired awareness, commonly originating in the temporal lobe [20, 41]. Serious injury may occur, contrary to VVS, as individuals will not be able to experience any of the classic prodromal signs [21]. It is difficult to make the correct diagnosis of ictal asystole, but the onset of new symptoms (*e.g.* unusual pallor, flaccid falls with injuries) after the habitual aura should prompt further examinations. The recurrence risk of ictal asystole amounts to 40%, underscoring the need for a timely diagnosis [42]. It is estimated that recording of at least three habitual seizures during VEM is required to allow an accurate diagnosis [42]. Because of the frequent falls and injuries, prevention of ictal syncope is important. Retrospective studies suggest that improving seizure control may prevent ictal asystole [43-45]. If the person is refractory to medical treatment and not suitable for epilepsy surgery, implantation

▼ **Table 3.** Symptoms and signs before, during and after transient loss of consciousness (TLOC) including clues for syncope vs. tonic-clonic seizures.

	Before TLOC		During TLOC					After TLOC	
	Prodromal signs due to hypoperfusion	**Other clues specific to cause**	**Fall**	**Movements**	**Number of jerks**	**Duration of TLOC**	**Eyes**	**Post ictal state**	**Other clues specific to cause**
Reflex syncope	Mostly present	Circumstances: emotions, pain, upon standing, prolonged standing, heat, post-exercise, coughing, defecation, swallowing, micturition, pressure on the neck Autonomic activation	Mostly flaccid fall, rarely keeling over stiff	Mostly asynchronous; symmetric or asymmetric; starts after onset of TLOC. Head may turn.	<10	<60 s	Eyes nearly always open, often upwards deviation	Quick and complete recovery; disorientation <10 s	Flushing (in those with arrhythmia or cardioinhibitory vasovagal syncope)
Syncope due to orthostatic hypotension	Mostly present	Circumstances: upon standing, prolonged standing, heat, post-exercise, post-prandial 'Coat hanger sign', 'Inability to act', TIA due to OH especially in the context of carotid occlusive disease							
Cardiac syncope	Rarely present only if the decrease in cardiac output is slow	Palpitations, symptoms of heart failure (*e.g.* dyspnoea) Circumstances: syncope while supine, *during* exertion, startling or having cold water in the face							
Generalized or focal to bilateral tonic-clonic seizures	Not present	Focal seizure (*e.g.* impaired awareness) in those with focal epilepsy; generalised seizure (*e.g.* myoclonus) in those with generalised epilepsy	Tonic phase epilepsy: keeling over stiff	Mostly synchronous; symmetric or asymmetric, starts before or after onset of TLOC	>20	Mostly up to 1 min but may last longer	Eyes nearly always open, often horizontal or upwards deviation	Comatose or immediate sleep, confusion or prolonged amnesia	Lateral tongue biting (rarely bilateral)

TIA: transient ischaemic attacks.

of a cardiac pacemaker should be considered to reduce risk of falls and injuries [45-47]. Contrary to the self-limiting nature of ictal asystole, 54% of reported postictal asystole cases died from SUDEP [20]. Postictal bradyarrhythmias are exceedingly rare and always accompanied or preceded by decreased respiratory rate and apnoea [20, 48, 49]. Although postictal bradyarrhythmias seem to play a crucial role in the cascade of events leading to SUDEP, they seem strongly linked to respiratory dysfunction [49, 50].

Case 2

A 56-year-old woman suffered from difficult-to-treat temporal lobe epilepsy of unknown origin for seven years. Seizures were characterized by sudden loss of awareness without aura, followed by oro-alimentary and manual automatisms and postictal disorientation without speech disturbances. Sometimes, atonic falls were observed by family members.

She was referred for pre-surgical assessment. Brain MRI showed a slight enlargement and signal enhancement of the right temporo-mesial structures. Cerebral FDG-PET displayed moderate temporal hypometabolism on both sides, and neuropsychological testing did not reveal localizing clues. Interictal EEG showed sleep-activated sharp waves in the anterior temporal region on both sides. Prolonged video-EEG monitoring was performed to record seizures. On Day 5, a habitual temporal lobe seizure, with sudden onset of staring, oro-alimentary and manual automatisms, occurred. The seizure started with rhythmic delta activity in the right temporal region with rapid involvement of the contralateral temporal lobe. About 25 seconds after seizure onset, the heart rate progressively declined, followed by an asystole of 30 seconds, before regular QRS complexes re-occurred. These cardiac changes were accompanied by EEG signs typically linked to syncope (generalized rhythmic delta activity, flat EEG, rhythmic delta activity). During the syncopal period, she fell flaccidly onto the bed. The next morning, she suffered from another habitual temporal lobe seizure, again with self-limiting ictal asystole, but this time with a consecutive fall to the floor without injury.

It is important to note that recurrent ictal asystole was only recognised following video-EEG monitoring and that she previously reported falls during her habitual seizures. Because of the medical refractoriness and the rather low chance of achieving seizure freedom upon medical treatment, she was offered a cardiac pacemaker. After implantation, she never experienced falls again during focal seizures. Further intracranial presurgical investigations were denied.

Atrial fibrillation

Atrial fibrillation is characterized by an irregular, slow, or rapid beating of the atrial heart chambers. It may only manifest with palpitations but can also induce dyspnoea or syncope due to impaired cardiac output (if heart rate is low or too fast). Importantly, atrial fibrillation is also an important risk factor for thromboembolic ischaemic stroke because of the desynchronised atrial contractions, allowing formation of cardiac thrombi, requiring appropriate anticoagulation [51]. In general, atrial fibrillation was described in up to about 10% of people with epilepsy; seizure-related atrial fibrillation was mostly described after (focal to) bilateral TCS [20, 52, 53]. Long-term administration of beta-blockers (used for rate and rhythm control) should be considered in cases with difficult-to-treat epilepsy and seizure-induced atrial fibrillation [51, 53].

Ictal ventricular tachycardia or fibrillation

Seizure-induced ventricular tachycardia or fibrillation (VT/VF) were described in six cases that led to SUDEP or near-SUDEP [54-59]. In all these cases, VT/VF occurred directly after a TCS. Signs of a prior myocardial infarction were found in only one SUDEP case (chest pain during a seizure cluster leading up to the fatal seizure) [54]. In the remaining five cases, no underlying cardiac pathology was detected, suggesting that seizure-related alterations of electrical properties have facilitated onset of VT/VF. Indeed, profound changes of cardiac repolarisation indices, known as established markers of elevated risk of VT/VF and SCD, occur especially in association with TCS [60, 61]. This is probably linked to the strong sympathetic activation and massive catecholamine release (up to three-fold) during TCS [62]. The catecholamine levels normalise within two hours after the TCS, indicating a transient hyperadrenergic state [62]. Transient abnormal prolongation of QT intervals occurs in about 6% of the seizures in 12% of the patients, and abnormal shortening of the QT interval are commonly observed in the aftermaths of most focal to bilateral TCS [60, 61]. Furthermore, T-wave alternans (TWA) (see section on *Epilepsy-related cardiac complications*) is significantly increased following TCS, possibly increasing the risk of VT/VF and SCD [63]. Fortunately, seizure-induced VT/VF seems very rare. There could be, however, a publication bias, as fatal VT/VF cases may not be categorised as SUDEP. In a prospective study of (out-of-hospital) cardiac arrests after VT/VF, it was found that the risk of VT/VF was three-fold higher in PWE than the general population [5]. Most of those VT/VF cases occurred in patients with (pre-existing or acute) heart conditions, but some were unexplained and could be classified as near-SUDEP or SUDEP [64]. SCD and SUDEP thus seem to partly overlap.

Acute myocardial injury and infarction

It is plausible to assume that generalized onset and focal to bilateral TCS favour cardiac oxygen deprivation by inducing strong muscle activity, apnoea and prominent, sustained sinus tachycardia [35, 61] In line with this assumption, transitory ECG changes, possibly indicating cardiac ischaemia such as ST segment depression and T wave inversion, were described particularly in association with focal to bilateral TCS, although such ECG signs appear to be rather infrequent [60, 62, 65, 66]. Elevated levels of high-sensitivity Troponin T (hsTNT), reflecting cardiac injury, however, were found in about a quarter of TCS in younger PWE undergoing VEM [62]. Intriguingly, none of the patients in this prospective clinical study had apparent cardiac complaints and no cardiac diseases were known or found in those with elevated hsTNT. Instead, the hsTNT levels were associated with high dopamine levels, indicating that the release of catecholamines and strong sympathetic activation were involved. In contrast, clinical TCS features were not linked to signs of cardiac injury [62].

These observations suggest that asymptomatic increases of cardiac injury markers in association with epileptic seizures can be interpreted as a mild form of neurogenic stress (Takotsubo) cardiomyopathy. Takotsubo cardiomyopathy is linked to very high catecholamine levels that induce cardiac contraction band necrosis [67]. The typical features of Takotsubo cardiomyopathy include chest pain, elevated troponin levels, transient ventricular motion abnormalities, and ECG alterations, similar to those of acute myocardial infarction in the absence of CAD [68]. The symptoms are commonly reversible, and the prognosis is mostly favourable. In the setting of emergency departments, elevations of troponin levels (cardiac troponin I or hsTNT) were found in 6-12% of TCS, especially in patients of older age (70 years or older), with cardiovascular risk factors or CAD [69-72]. Acute myocardial infarctions were only diagnosed in 2.2% of the patients referred to emergency departments because of TCS [69, 72]. Takotsubo cardiomyopathy can occur in the context of all forms of cerebral injuries, but in PWE, it usually occurs in association with TCS or status epilepticus [73].

Altogether, these findings underscore that troponin elevations linked to TCS need to be considered in greater detail. In the absence of CAD and in younger patients without cardiovascular risk factors, the TCS-related catecholamine release may lead to neurogenic stress without cardiac complaints or clinically manifest as Takotsubo cardiomyopathy, whereas in the elderly or patients with CAD, TCS may cause myocardial infarction.

How to manage seizure-related cardiac complications

Seizure-related arrhythmias may be recorded incidentally during VEM or shortly following a TCS after admission. Clinical clues that should prompt further investigations include onset of new seizure-related symptoms such as LOC that differ from the usual loss of awareness and unusual (atonic) falls. Seizure freedom will help to prevent seizure-related arrhythmias but cannot always be achieved. If refractoriness is already proven and epilepsy surgery not feasible, implantation of a cardiac pacemaker in patients with ictal bradyarrhythmia and a defibrillator in those with ventricular tachyarrhythmia is advisable. In PWE of all ages with new chest pain, with known CAD or in patients older than 70 years, it is advisable to determine troponin levels and perform a 12-lead ECG after TCS to exclude myocardial infarction and Takotsubo cardiomyopathy (*table 4*).

Epilepsy-related cardiac complications

Epilepsy is associated with a three-fold increased risk of sudden cardiac arrest, compared to the general population [5]. Importantly, about two thirds of the witnessed cases of sudden cardiac arrest in PWE were reported without evidence of a habitual seizure prior to the cardiac event, indicating that potentially lethal cardiac arrhythmias do not necessarily require epileptic seizures as a proximate trigger [74]. Hence, it is important to identify interictal cardiac findings in PWE that may predispose to SCD. These interictal epilepsy-related alterations, in turn, may be related to the functional or structural origin in the brain (central autonomic nervous system) or heart, and may be due to cerebral damage or specific localisation of the seizure-generating networks, intrinsic or genetic factors (*e.g.* inherited channelopathies), effects of antiseizure medication (ASM; see section Treatment-related cardiac complications) or remote effects of recurrent seizures.

Cardiac autonomic dysfunction

There is unequivocal evidence that interictal cardiac autonomic function is altered in PWE. For instance, interictal sympathetic tone tends to be enhanced whereas parasympathetic tone appears impaired, resulting in decreased heart rate variability (HRV) [75-77]. In non-epilepsy populations, decreased HRV is associated with elevated cardiovascular mortality [78]. Decreased HRV is found to be most severe in those with temporal lobe epilepsy and people with difficult-to-treat

▼ **Table 4.** Practical recommendations for the management of cardiac complications in different scenarios.

Clinical scenario	What to exclude or prevent?	How to make the diagnosis?	What to do?
Time of epilepsy diagnosis	Inherited cardiac arrhythmias (e.g. long / short QT syndromes) that may co-exist or lead to false diagnosis of epilepsy	12-lead ECG	Referral to cardiologist if confirmed
Intention to modify antiseizure drug treatment involving sodium channel blockers in patients with other negative dromotropic or chronotropic substances (*e.g.* antihypertensive or antiarrhythmic drugs), high doses of sodium channel blockers or combination of sodium channel blockers	Sinus node dysfunction, AV-block or ventricular tachyarrhythmias	12-lead ECG	Reconsider antiseizure treatment strategy (or antihypertensive treatment)
Episodes with loss of consciousness in the absence of habitual seizure symptoms	Interictal syncope due to treatment- or epilepsy-related cardiac arrhythmias	12-lead ECG (if VNS, then 12-lead ECG during on- and off-phase), Holter recording / loop recorder (if very rare), transthoracic echocardiography	Treatment-related: reconsider antiseizure treatments or modification of VNS Epilepsy-related or unclear origin: referral to cardiologist
Onset of new or unusual seizure-related symptoms, *e.g.* loss of consciousness (different from usual loss of awareness) or (atonic) falls	Ictal cardiac arrhythmias	VEM with recording of at least three habitual seizures	Full seizure control. If not achievable, consider implantation of cardiac pacemaker (if ictal bradyarrhythmia) or defibrillator (if ictal/postictal VT/VF)
Incidentally monitored ictal or postictal bradyarrhythmia or tachyarrhythmia during VEM or in the emergency department			Full seizure control. If not achievable, consider implantation of cardiac pacemaker (if ictal bradyarrhythmia) or defibrillator (if ictal/postictal VT/VF)
Incidentally monitored or suspected peri-ictal atrial fibrillation		12-lead ECG, Holter recording or loop recorder	Full seizure control. If sustained atrial fibrillation: Consider rhythm control and anticoagulation (referral to cardiologist)

▼ **Table 4.** Practical recommendations for the management of cardiac complications in different scenarios (Continued).

Clinical scenario	What to exclude or prevent?	How to make the diagnosis?	What to do?
New onset of chest pain after seizures during VEM Admission to the emergency department because of TCS in an elderly patient or a patient with known CAD	Acute myocardial infarction Takotsubo cardiomyopathy	12-lead ECG, troponin blood levels	Referral to cardiologist

epilepsies [76]. The origins of autonomic dysregulation in epilepsy are unclear, but it is likely that brain areas controlling cardiac autonomic function are functionally or structurally affected by the seizure-generating networks, while peripheral components of the autonomic nervous system might also be affected during the course of the disease.

The 'epileptic heart'

The duration of epilepsy appears to be linked to the development of cardiac diseases, as the prevalence of heart diseases is higher in PWE compared to people without epilepsy at all ages, and the age-related increase tends to be greater in PWE [79]. This observation supports the hypothesis that cardiac damage is incrementally acquired due to epilepsy-related autonomic dysfunction and to effects of recurrent seizures with myocardial catecholaminergic toxicity, as well as subtle ischaemic injury of cardiomyocytes and small cardiac nerves fibres [80]. Epileptic seizures, especially TCS, lead to sustained hypoxemia in the presence of strong and non-physiological generalized muscle activity, accompanied with a massive release of catecholamines, altogether leading to release of inflammatory factors and metabolic alterations [62, 81, 82]. This, in turn, causes cardiac stress even in the absence of acute cardiac complaints, as documented by asymptomatic release of hsTNT [62]. The structural correlate of such repetitive cardiac injuries may be cardiac fibrosis, which is found in about one third of PWE in post mortem analysis [13, 83].

In line with these observations, Verrier and colleagues have recently proposed the concept of the 'epileptic heart', defined as "a heart and coronary vasculature damaged by chronic epilepsy as a result of repeated surges in catecholamines and hypoxemia leading to electrical and mechanical dysfunction" [13]. Structural and functional heart properties can also be assessed at a more macroscopic level by echocardiography, and specific findings of systolic and diastolic dysfunction or hypertrophy are linked to an increased SCD risk [84, 85]. In adults with temporal lobe epilepsy, left ventricle stiffness was increased with higher pressure compared to healthy controls, which was probably related to altered cardiac autonomic activity and possibly cardiac fibrosis, promoting systolic and diastolic dysfunction and arrhythmogenesis [86]. Echocardiographic studies in children with epilepsy have also shown greater thickness of carotid intima-media and epicardial adipose tissue in epilepsy versus non-epilepsy (particularly in those epilepsy patients on polytherapy vs monotherapy), left ventricle myocardial deformation and impaired systolic and diastolic functions in children with ASMs and without seizures in the last six months versus healthy controls, and left ventricle function deterioration (contraction time, relaxation time, performance index and ejection time) in untreated 'idiopathic epilepsy' versus healthy controls [87, 88].

What are the potential consequences of this incremental damage? Subtle perivascular and interstitial fibrotic microlesions in the heart could contribute to or cause disturbed conduction of cardiac excitation, heterogeneous cardiac repolarisation and heterotopic excitation, thereby serving as potential sites for the generation and maintenance of fatal arrhythmias such as VT/VF. Apart from (micro-)structural damage of the heart, emerging data from animal studies of acquired epilepsies also demonstrate changes of cardiac ion channel expression levels (*e.g. SCN1A, SCN5A, HCN2*) that translate into altered electrical properties of the heart, strengthening the notion of the 'epileptic heart' [89].

Altered cardiac repolarisation indices

Taken together, cardiac microlesions, altered expression of cardiac ion channels and enhanced sympathetic tone may also favour abnormally altered cardiac repolarisation features (*table 1*) and onset of potentially lethal VT/VF [90]. Indeed, interictal prolongation of QT intervals (corrected for heart rate [QTc]) is more common in PWE compared to people without epilepsy [6, 91-94]. Some studies reported similar QTc durations in both people with and without epilepsy [95, 96], while others found QTc shortening [97, 98]. Older PWE and those with difficult-to-treat epilepsies, in particular, are at higher risk of development of QTc prolongation compared to people without epilepsy [6, 94]. Furthermore, ventricular late potentials were found in 22 of 45 PWE compared with one of 19 controls [99], and QT dispersion, as a measure of regional heterogeneity of cardiac repolarization, was reported in up to one third of PWE [18]. The latter may be of particular interest, because abnormal QT dispersion is thought to facilitate onset of VT/VF when abnormal QT shortening occurs, which could be a possible explanation for onset of VT/VF in association with TCS [90].

T wave alternans (TWA) is another marker of cardiac repolarisation which has recently gained attention in the field of epileptology [100]. TWA is the beat-to-beat fluctuation of morphology and amplitude of the ST segment or T wave, reflects temporal-spatial heterogeneity of cardiac repolarization and predicts cardiovascular mortality and SCD in people with cardiovascular disease [101]. The higher the level of TWA, the more likely is the onset of ventricular tachyarrhythmia [101]. TWA values in PWE were found to be elevated above the 47-μV abnormality cut-off point in most patients (82-100%) [102, 103]. Furthermore, TWA levels appear to depend on the duration of epilepsy, again supporting the notion of acquired cardiac damage. People with chronic epilepsy displayed higher TWA levels than those with newly diagnosed epilepsy, and TWA levels of adults with newly diagnosed epilepsy did not differ from healthy controls [104]. Importantly, PWE had reduced TWA levels and increased HRV upon vagus nerve stimulation (VNS), suggesting that VNS can considerably reverse or compensate epilepsy-related cardiac dysfunction [102, 103]. A prospective study in subjects with chronic heart failure supports the notion that VNS has cardioprotective effects, as those treated with VNS had reduced TWA levels, improved baroreflex sensitivity and fewer episodes with VT [105]. Whether these effects (partially) explain why long-term VNS treatment reduces SUDEP risk, however, remains to be elucidated [106].

Inherited cardiac dysfunction

In addition to acquired cardiac diseases, PWE with sudden cardiac arrest due to VT/VF were also shown more often to have pre-existing congenital or inherited heart diseases than controls [64]. Genetic defects may cause a multiple malformation syndrome affecting the development of the heart and brain or congenital heart disease, or abnormal cardiovascular function may lead to poor (intrauterine) brain growth. Alternatively, ion channel mutations may induce both cardiac arrhythmias and epilepsy. For instance, severe QTc prolongation and certain epilepsy syndromes are associated with sodium and potassium channel mutations. An ion channel mutation expressed in brain and heart, a cardiocerebral channelopathy, might lead to a propensity for seizures and cardiac arrhythmias. Numerous cardiocerebral channelopathies are known including pathogenic variants in the long QT gene family (*i.e.* *SCN5A*, *KCNQ1* and *KCNH2*) that are associated with epilepsy (*i.e.* self-reported diagnosis and ASM use) [107-112]. Cardiac channelopathy genes not associated with long QT, such as *RYR2* and *HCN1-4*, may predispose to epilepsy, as indicated by mouse model studies [113-116]. Likewise, gene mutations typically associated with epilepsy such as *SCN8A*, *CDKL5*, *CNTNAP2* and *GRIN2A* may also cause cardiac arrhythmias, further underscoring the concept of genetic pleiotropy and cardio-cerebral channelopathies [117, 118]. Mutations in some of these cardio-cerebral genes were also found in people who died suddenly, stressing the potential contribution of cardio-cerebral phenotypes to SUDEP [117, 119].

How to manage epilepsy-related cardiac complications

A 12-lead ECG is advisable in all patients at the time of first epilepsy diagnosis to identify constellations suggestive of inherited cardiac arrhythmia (*e.g.* long / short QT syndromes) and to mitigate the risk of false diagnosis of epilepsy. Given the possible presence of both entities, *i.e.* acquired or genetically caused epilepsy and cardiac arrhythmias, one should be aware that the presence of abnormal QT intervals on 12-lead ECG does not exclude epilepsy. Further examinations, *e.g.* prolonged EEG recordings, may be required if (additional) epilepsy is suspected. In PWE who report new onset of palpitations, episodes with LOC in the absence of typical seizure symptoms or other cardiac complaints, a 12-lead ECG should be performed. If treatment-related causes of cardiac complications are excluded (see next section), referral to a cardiologist for further examinations (Holter recordings, echocardiography, implantation of a loop recorder) is recommendable (*table 4*).

Treatment-related cardiac complications

PWE chronically receive ASM or neuromodulatory devices including VNS. Given the broad spectrum of direct seizure- and epilepsy- related cardiac effects in the continuous presence of antiseizure therapies, it can be challenging to identify treatment-related cardiac complications.

Cardiac complications of antiseizure medication

ASM seem to be an independent risk factor for SCD, especially in patients taking sodium channel blocking agents, even in the absence of epilepsy [16, 120]. Many ASM predominantly act on excitatory voltage-gated sodium channels, but may also bind to various other targets. For instance, carbamazepine, lamotrigine and phenytoin which are considered as classic sodium channel blockers also inhibit calcium channels, whereas levetiracetam appears to mediate its antiseizure effects via binding to the presynaptic synaptic vesicle protein 2A, but also acts on calcium channels [121]. Importantly, voltage-gated sodium and calcium channels are expressed both in the brain and heart with distinct preferential expression patterns according to the channel type. Since binding affinities are not absolute for "brain channel subtypes", ASM might lead to cardiac dysfunction and cardiac arrhythmias indirectly via modulating the central autonomic nervous system and via direct binding to cardiac tissue. Preclinical data have also shown that some ASM (lamotrigine, phenobarbital, phenytoin) inhibit the cardiac rapid-delayed rectifier potassium ion current [122, 123], which could cause prolongation of QT intervals and possibly facilitate VF/VT [124]. In this context, one may also discuss safety issues of ASM in epilepsy populations with inherited and acquired cardiac disease, as data are lacking on binding affinities and effects of ASM on mutant cardiac channels associated with arrhythmias. Indeed, in a recent cohort study on people with genetic long QT syndromes, the use of ASM was associated with an increased risk of cardiac events, especially in people with long QT syndrome type 2 [125]. Cardiac events were more frequent in female patients and upon sodium channel blocking agents, whilst co-administration of beta-adrenergic blocker medication attenuated the risk of cardiac events [125].

Given these considerations, one might expect frequently occurring new-onset cardiac arrhythmias in PWE after starting *e.g.* "sodium channel blockers". In the randomized controlled trials for drug approval and additional safety studies of the different sodium channel blocking agents, however, most ASMs were shown to be safe (and those drugs with strong effects on cardiac conduction and repolarisation were not approved). In line with this, ASMs usually do not exert clinically relevant effects on cardiac repolarisation properties and QT intervals [90]. In the case of pre-existing conduction abnormalities (*e.g.* higher-grade AV-block), however, sodium channel inhibitors may be contraindicated, as the risk of deteriorating the conduction deficits to a full block is elevated. Importantly, at very high doses, after ingestion ("overdose") or in combination with other sodium channel blocking agents or ASMs at higher daily doses, sodium channel inhibitors were reported to cause cardiac arrhythmias, independently of pre-existing cardiac diseases. The use of carbamazepine, lacosamide, lamotrigine and phenytoin was mostly associated with bradyarrhythmias (such as sinus node dysfunction and AV block), but also with ventricular tachyarrhythmia and atrial fibrillation [126-131].

The reports on ASM-induced alterations of cardiac autonomic control and HRV are controversial, but according to a meta-analysis including six original studies, there is no apparent effect of ASM on HRV [132]. In contrast, ASM intake and poor circulating cardiovascular risk factors were shown to be unequivocally linked, especially with enzyme-inducing ASMs (*i.e.* carbamazepine, phenytoin, phenobarbital, primidone) which worsen the lipid profile and other serological markers associated with vascular risk via induction of the hepatic cytochrome P450 system [133, 134]. These alterations, in turn, favour accelerated atherosclerosis, reflected, for instance, by the finding that duration of intake of enzyme-inducing ASMs was associated with the thickness of the intima media of the common carotid artery, an established vascular risk marker [135]. Some ASMs (*e.g.* gabapentin, pregabalin and valproate) are also associated with weight gain, which increases the risk of developing non-alcoholic fatty liver disease and metabolic syndrome, thereby further worsening cardiovascular risks [15].

Cardiac complications of vagus nerve stimulation

VNS involves a device that is implanted under the skin of the chest which is connected to the vagus nerve in the mid-cervical region. The device delivers periodically (*e.g.* every five minutes) an electrical current lasting for 30 seconds to the vagus nerve. In PWE, the left vagus nerve is usually chosen because it predominantly contains afferent fibres projecting to the brain and less efferent fibres projecting to the heart, thereby mitigating cardiac complications and enhancing potential CNS effects. Little is known about the exact mechanisms leading to improved seizure control upon VNS, but these are likely to involve significant changes of neurotransmitter levels in the brain [136], leading to a reduction in seizure frequency of at least 50% in 30 up to 50% of PWE [137]. Newer VNS devices can also apply additional pulses upon a seizure-related increase in heart rate, as detected by a closed loop system, which may interrupt seizure activity and shorten seizure duration [138].

The reports on cardiac autonomic control and HRV upon VNS are mixed, and a meta-analysis including five studies has not revealed a clear effect of VNS on HRV [132]. One might expect an elevated risk of bradycardia and asystole upon VNS, but because of the implantation of the left vagus nerve (with few fibres projecting to the AV node only) and the systematic testing of cardiac effects during the implantation procedure, VNS-induced cardiac complications are very rare. Indeed, only a few cases with delayed onset (several years after VNS implantation) of episodic bradycardia and syncope during the on-phase of the VNS were reported [139]. It is important to note that cholinergic innervation (by vagus nerve fibres) is not only present in the sinoatrial and AV node, but also in the human ventricular conducting system, allowing modulation of electrical properties of the cardiac ventricles [140]. Indeed, TWA levels were significantly reduced upon VNS (see also the section *Epilepsy-related cardiac complications*), suggesting that VNS stabilizes electrical properties of the heart and possibly mitigates the risk of VT/VF and SCD [102, 103]. This, however, needs to be confirmed in larger populations.

How to manage treatment-related cardiac complications

ASMs are required for antiseizure treatment. If successful, the use of ASMs prevents seizure-related cardiac arrhythmias and remote cardiac complications ('epileptic heart'). However, enzyme-inducing ASMs should be avoided at least in those with cardiovascular risk profiles, as these drugs may aggravate cardiovascular risk factors including weight gain linked to specific ASMs. In patients with new onset of syncope or episodes of TLOC in the absence of habitual seizure-related symptoms, a 12-lead ECG (or Holter recordings) is advisable to search for ASM-induced arrhythmias. If a modification of antiseizure drug treatment involving sodium channel blockers is intended, a 12-lead ECG (before and *e.g.* two weeks after the modification), to exclude AV block or sinus node dysfunction, is advisable for the following constellations: patients with other cardioactive substances (*e.g.* antihypertensive or antiarrhythmic drugs), or in those with high doses or a combination of sodium channel blockers. Rare episodic bradycardia or asystole should be considered in patients with VNS if they report onset of new symptoms or LOC in the absence of typical seizures (*table 4*). ■

Key points

- People with epilepsy have a 2-3-fold increased risk of dying prematurely, which is due to sudden cardiac death or acute myocardial infarctions in a considerable proportion of patients.
- Cardiac complications in people with epilepsy can be caused by epileptic seizures, treatment, or epilepsy itself.
- Syncope can be mistaken for epileptic seizures, which hampers the timely diagnosis of cardiac complications in people with epilepsy or leads to false diagnosis in people without epilepsy.
- Ictal asystole is the most frequent clinically relevant arrhythmia, occurs predominantly with focal seizures in temporal lobe epilepsy, has a high recurrence risk, and may require cardiac pacemaker implantation if seizure freedom cannot be achieved.
- Seizure-related ventricular tachycardia is rarely reported and only in the context with tonic-clonic seizures.
- Seizure-related myocardial infarction is rare and predominantly occurs with tonic-clonic seizures in elderly patients or in those with known coronary artery disease.
- Two thirds of sudden cardiac arrests in people with epilepsy are reported in the absence of seizures, indicating that potentially lethal cardiac arrhythmias do not require epileptic seizures as a proximate trigger.
- Epilepsy-related interictal cardiac complications include altered cardiac autonomic function with decreased heart rate variability and abnormalities of cardiac repolarisation features, possibly facilitating onset of ventricular tachyarrhythmias.
- Antiseizure medication may prevent seizure-related cardiac arrhythmias and remote cardiac complications ('epileptic heart').
- Enzyme-inducing antiseizure medication should be avoided at least in those with cardiovascular risk profiles, as these drugs may aggravate cardiovascular risk factors including weight gain linked to specific ASMs; sodium channel blockers at very high doses or in combination can lead to potentially life-threatening cardiac arrhythmia, mostly bradyarrhythmias, but also atrial and ventricular tachyarrhythmias.

Supplementary data.
Supplementary didactic slides are available on the www.epilepticdisorders.com website.

Acknowledgements and disclosures.
PR has received speaker or consultant fees from UCB pharma, Eisai pharmaceutical, LivaNova and GW pharmaceuticals. RS has received speaker fees or honorary for serving on the advisory board for Bial, Desitin, Eisai, LivaNova, Novartis and UCB Pharma, and research support from the Federal Ministry of Health, Federal Ministry of Education and Research, and the Boll foundation (Kerpen, Germany). RDT receives research support from Medtronic, Dutch National Epilepsy Fund, The Netherlands Organization for Health Research and Development (ZonMW), Christelijke Vereniging voor de Verpleging van Lijders aan Epilepsie NUTS Ohra Fund, and the AC Thomson Foundation, and reports consultancy and lecturing fees from Theravance Biopharma, Medtronic, UCB and Novartis and research support from Medtronic. CD and SS report no disclosures.

References for further reading.

van Dijk JG, Thijs RD, van Zwet E, Tannemaat MR, van Niekerk J, Benditt DG, *et al*. The semiology of tilt-induced reflex syncope in relation to electroencephalographic changes. *Brain* 2014; 137: 576-85.

Palma JA, Benarroch EE. Neural control of the heart: recent concepts and clinical correlations. *Neurology* 2014; 83: 261-71.

Van der Lende M, Surges R, Sander JW, Thijs RD. Cardiac arrhythmias during or after epileptic seizures. *J Neurol Neurosurg Psychiatry* 2016; 87: 69-74.

Brigo F, Lochner P, Nardone R, Manganotti P, Lattanzi S. Increased risk of stroke and myocardial infarction in patients with epilepsy: a systematic review of population-based cohort studies. *Epilepsy Behav* 2020; 104: 106307.

Mintzer S, Skidmore CT, Abidin CJ, Morales MC, Chervoneva I, Capuzzi DM, *et al*. Effects of antiepileptic drugs on lipids, homocysteine, and C-reactive protein. *Ann Neurol* 2009; 65: 448-56.

References

1. Blümcke I, Arzimanoglou A, Beniczky S, Wiebe S. Roadmap for a competency–based educational curriculum in epileptology: report of the Epilepsy Education Task Force of the International League Against Epilepsy. *Epileptic Disord* 2019; 21: 129-40.

2. Neligan A, Bell GS, Johnson AL, Goodridge DM, Shorvon SD, Sander JW. The long–term risk of premature mortality in people with epilepsy. *Brain* 2011; 134: 388-95.

3. Olesen JB, Abildstrøm SZ, Erdal J, Gislason GH, Weeke P, Andersson C, *et al*. Effects of epilepsy and selected antiepileptic drugs on risk of myocardial infarction, stroke, and death in patients with or without previous stroke: a nationwide cohort study. *Pharmacoepidemiol Drug Saf* 2011; 20: 964-71.

4. Janszky I, Hallqvist J, Tomson T, Ahlbom A, Mukamal KJ, Ahnve S. Increased risk and worse prognosis of myocardial infarction in patients with prior hospitalization for epilepsy—the Stockholm Heart Epidemiology Program. *Brain* 2009; 132: 2798-804.

5. Bardai A, Lamberts RJ, Blom MT, Spanjaart AM, Berdowski J, van der Staal SR, *et al*. Epilepsy is a risk factor for sudden cardiac arrest in the general population. *PLoS One* 2012; 7: e42749.

6. Lamberts RJ, Blom MT, Novy J, Belluzzo M, Seldenrijk A, Penninx BW, *et al*. Increased prevalence of ECG markers for sudden cardiac arrest in refractory epilepsy. *J Neurol Neurosurg Psychiatry* 2015; 86: 309-13.

7. Keezer MR, Sisodiya SM, Sander JW. Comorbidities of epilepsy: current concepts and future perspectives. *Lancet Neurol* 2016; 15: 106-15.

8. Shmuely S, van der Lende M, Lamberts RJ, Sander JW, Thijs RD. The heart of epilepsy: current views and future concepts. *Seizure* 2016; 44: 176-83.

9. Kobau R, Zahran H, Thurman DJ, Zack MM, Henry TR, Schachter SC, *et al*. Epilepsy surveillance among adults–19 States. Behavioral Risk Factor Surveillance System, 2005. *MMWR Surveill Summ* 2008; 57: 1-20.

10. Elliott JO, Moore JL, Lu B. Health status and behavioral risk factors among persons with epilepsy in Ohio based on the 2006 Behavioral Risk Factor Surveillance System. *Epilepsy Behav* 2008; 12: 434-44.

11. Gaitatzis A, Carroll K, Majeed A, J WS. The epidemiology of the comorbidity of epilepsy in the general population. *Epilepsia* 2004; 45: 1613-22.

12. Vooturi S, Jayalakshmi S. Metabolic syndrome in people with epilepsy. *Epilepsy Behav* 2020; 106: 106992.

13. Verrier RL, Pang TD, Nearing BD, Schachter SC. The epileptic heart: concept and clinical evidence. *Epilepsy Behav* 2020; 105: 106946.

14. Oduah MT, Iwanowski P. Cardiovascular complications of epileptic seizures. *Epilepsy Behav* 2020; 111: 107185.

15. Katsiki N, Mikhailidis DP, Nair DR. The effects of antiepileptic drugs on vascular risk factors: a narrative review. *Seizure* 2014; 23: 677-84.

16. Bardai A, Blom MT, van Noord C, Verhamme KM, Sturkenboom MC, Tan HL. Sudden cardiac death is associated both with epilepsy and with use of antiepileptic medications. *Heart* 2015; 101: 17-22.

17. Surges R, Thijs RD, Tan HL, Sander JW. Sudden unexpected death in epilepsy: risk factors and potential pathomechanisms. *Nat Rev Neurol* 2009; 5: 492-504.

18. Surges R, Sander JW. Sudden unexpected death in epilepsy: mechanisms, prevalence, and prevention. *Curr Opin Neurol* 2012; 25: 201-7.

19. Brigo F, Lochner P, Nardone R, Manganotti P, Lattanzi S. Increased risk of stroke and myocardial infarction in patients with epilepsy: a systematic review of population–based cohort studies. *Epilepsy Behav* 2020; 104: 106307.

20. Van der Lende M, Surges R, Sander JW, Thijs RD. Cardiac arrhythmias during or after epileptic seizures. *J Neurol Neurosurg Psychiatry* 2016; 87: 69-74.

21. van Dijk JG, Thijs RD, van Zwet E, Tannemaat MR, van Niekerk J, Benditt DG, *et al*. The semiology of tilt–induced reflex syncope in relation to electroencephalographic changes. *Brain* 2014; 137: 576-85.

22. van Dijk JG, van Rossum IA, Thijs RD. Timing of circulatory and neurological events in syncope. *Front Cardiovasc Med* 2020; 7: 36.

23. Wieling W, Thijs RD, van Dijk N, Wilde AA, Benditt DG, van Dijk JG. Symptoms and signs of syncope: a review of the link between physiology and clinical clues. *Brain* 2009; 132: 2630-42.

24. Shmuely S, Bauer PR, van Zwet EW, van Dijk JG, Thijs RD. Differentiating motor phenomena in tilt–induced syncope and convulsive seizures. *Neurology* 2018; 90: e1339-46.

25. Thijs RD, Wagenaar WA, Middelkoop HA, Wieling W, van Dijk JG. Transient loss of consciousness through the eyes of a witness. *Neurology* 2008; 71: 1713-8.

26. Thijs RD, Bloem BR, van Dijk JG. Falls, faints, fits and funny turns. *J Neurol* 2009; 256: 155-67.

27. Thijs RD, Wieling W, van Dijk JG. Status vasovagalis. *Lancet* 2009; 373: 2222.

28. Kruit MC, Thijs RD, Ferrari MD, Launer LJ, van Buchem MA, van Dijk JG. Syncope and orthostatic intolerance increase risk of brain lesions in migraineurs and controls. *Neurology* 2013; 80: 1958-65.

29. Baumgartner C, Koren J, Britto–Arias M, Schmidt S, Pirker S. Epidemiology and pathophysiology of autonomic seizures: a systematic review. *Clin Auton Res* 2019; 29: 137-50.

30. Devinsky O, Hesdorffer DC, Thurman DJ, Lhatoo S, Richerson G. Sudden unexpected death in epilepsy: epidemiology, mechanisms, and prevention. *Lancet Neurol* 2016; 15: 1075-88.

31. Surges R, Jordan A, Elger CE. Ictal modulation of cardiac repolarization, but not of heart rate, is lateralized in mesial temporal lobe epilepsy. *PLoS One* 2013; 8: e64765.

32. Palma JA, Benarroch EE. Neural control of the heart: recent concepts and clinical correlations. *Neurology* 2014; 83: 261-71.

33. Chouchou F, Mauguière F, Vallayer O, Catenoix H, Isnard J, Montavont A, *et al*. How the insula speaks to the heart: cardiac responses to insular stimulation in humans. *Hum Brain Mapp* 2019; 40: 2611-22.

34. Sevcencu C, Struijk JJ. Autonomic alterations and cardiac changes in epilepsy. *Epilepsia* 2010; 51: 725-37.

35. Eggleston KS, Olin BD, Fisher RS. Ictal tachycardia: the head–heart connection. *Seizure* 2014; 23: 496-505.

36. Jeppesen J, Fuglsang–Frederiksen A, Johansen P, Christensen J, Wüstenhagen S, Tankisi H, *et al*. Seizure detection using heart rate variability: a prospective validation study. *Epilepsia* 2020. doi: 10.1111/epi.16511. Epub ahead of print.

37. Lanz M, Oehl B, Brandt A, Schulze–Bonhage A. Seizure induced cardiac asystole in epilepsy patients undergoing long term video–EEG monitoring. *Seizure* 2011; 20: 167-72.

38. Nashef L, So EL, Ryvlin P, Tomson T. Unifying the definitions of sudden unexpected death in epilepsy. *Epilepsia* 2012; 53: 227-33.

39. Chaila E, Bhangu J, Tirupathi S, Delanty N. Ictal bradycardia and asystole associated with intractable epilepsy: a case series. *Br J Cardiol* 2010; 17: 245-48.

40. Bank AM, Dworetzky BA, Lee JW. Sudden unexpected death in epilepsy in a patient with a cardiac pacemaker. *Seizure* 2018; 61: 38-40.

41. Schuele SU, Bermeo AC, Alexopoulos AV, Locatelli ER, Burgess RC, Dinner DS, *et al*. Video–electrographic and clinical features in patients with ictal asystole. *Neurology* 2007; 69: 434-41.

42. Hampel KG, Thijs RD, Elger CE, Surges R. Recurrence risk of ictal asystole in epilepsy. *Neurology* 2017; 89: 785-91.

43. Bestawros M, Darbar D, Arain A, Abou–Khalil B, Plummer D, Dupont WD, *et al*. Ictal asystole and ictal syncope: insights into clinical management. *Circ Arrhythm Electrophysiol* 2015; 8: 159-64.

44. Kohno R, Abe H, Akamatsu N, Benditt DG. Long–term follow–up of ictal asystole in temporal lobe epilepsy: is permanent pacemaker therapy needed? *J Cardiovasc Electrophysiol* 2016; 27: 930-6.

45. Strzelczyk A, Cenusa M, Bauer S, Hamer HM, Mothersill IW, Grunwald T, *et al*. Management and long–term outcome in patients presenting with ictal asystole or bradycardia. *Epilepsia* 2011; 52: 1160-7.

46. Moseley BD, Ghearing GR, Munger TM, Britton JW. The treatment of ictal asystole with cardiac pacing. *Epilepsia* 2011; 52: e16-9.

47. Duplyakov D, Golovina G, Lyukshina N, Surkova E, Elger CE, Surges R. Syncope, seizure–induced bradycardia and asystole: two cases and review of clinical and pathophysiological features. *Seizure* 2014; 23: 506-11.

48. Jin L, Zhang Y, Wang XL, Zhang WJ, Liu YH, Jiang Z. Postictal apnea as an important mechanism for SUDEP: a near–SUDEP with continuous EEG–ECG–EMG recording. *J Clin Neurosci* 2017; 43: 130-2.

49. Ryvlin P, Nashef L, Lhatoo SD, Bateman LM, Bird J, Bleasel A, *et al*. Incidence and mechanisms of cardiorespiratory arrests in epilepsy monitoring units (MORTEMUS): a retrospective study. *Lancet Neurol* 2013; 12: 966-77.

50. Kim Y, Bravo E, Thirnbeck CK, Smith–Mellecker LA, Kim SH, Gehlbach BK, *et al*. Severe peri–ictal respiratory dysfunction is common in Dravet syndrome. *J Clin Invest* 2018; 128: 1141-53.

51. European Heart Rhythm Association;European Association for Cardio–Thoracic Surgery, Camm AJ, Kirchhof P, Lip GY, Schotten U, *et al*. Guidelines for the management of atrial fibrillation: the task force for the management of atrial fibrillation of the European Society of Cardiology (ESC). *Eur Heart J* 2010; 31:2369-429.

52. Desai R, Rupareliya C, Patel U, Naqvi S, Patel S, Lunagariya A, *et al*. Burden of arrhythmias in epilepsy patients: a nationwide inpatient analysis of 1.4 million hospitalizations in the United States. *Cureus* 2017; 9: e1550.

53. Surges R, Moskau S, Viebahn B, Schoene–Bake JC, Schwab JO, Elger CE. Prolonged atrial fibrillation following generalized tonic–clonic seizures. *Seizure* 2012; 21: 643-5.

54. Dasheiff RM, Dickinson LJ. Sudden unexpected death of epileptic patient due to cardiac arrhythmia after seizure. *Arch Neurol* 1986; 43: 194-6.

55. Espinosa PS, Lee JW, Tedrow UB, Bromfield EB, Dworetzky BA. Sudden unexpected near death in epilepsy: malignant arrhythmia from a partial seizure. *Neurology* 2009; 72: 1702-3.

56. Ferlisi M, Tomei R, Carletti M, Moretto G, Zanoni T. Seizure induced ventricular fibrillation: a case of near–SUDEP. *Seizure* 2013; 22: 249-51.

57. Jeppesen J, Fuglsang–Frederiksen A, Brugada R, Pedersen B, Rubboli G, Johansen P, *et al*. Heart rate variability analysis indicates preictal parasympathetic overdrive preceding seizure–induced cardiac dysrhythmias leading to sudden unexpected death in a patient with epilepsy. *Epilepsia* 2014; 55: e67-71.

58. Kuttab HI, Harris EA, Tataris KL, Tao J, Beiser DG. Cardiac arrhythmia following an epileptic seizure. *Clin Pract Cases Emerg Med* 2019; 3: 354-6.

59. Seo MH, Sung WY. A case of near–sudden unexpected death in epilepsy due to ventricular fibrillation. *Open Access Emerg Med* 2019; 11: 161-6.

60. Surges R, Adjei P, Kallis C, Erhuero J, Scott CA, Bell GS, *et al*. Pathologic cardiac repolarization in pharmacoresistant epilepsy and its potential role in sudden unexpected death in epilepsy: a case–control study. *Epilepsia* 2010; 51: 233-42.

61. Surges R, Scott CA, Walker MC. Enhanced QT shortening and persistent tachycardia after generalized seizures. *Neurology* 2010; 74: 421-6.

62. Nass RD, Motloch LJ, Paar V, Lichtenauer M, Baumann J, Zur B, *et al*. Blood markers of cardiac stress after generalized convulsive seizures. *Epilepsia* 2019; 60: 201-10.

63. Strzelczyk A, Adjei P, Scott CA, Bauer S, Rosenow F, Walker MC, *et al*. Postictal increase in T–wave alternans after generalized tonic–clonic seizures. *Epilepsia* 2011; 52: 2112-7.

64. Lamberts RJ, Blom MT, Wassenaar M, Bardai A, Leijten FS, de Haan GJ, *et al*. Sudden cardiac arrest in people with epilepsy in the community: circumstances and risk factors. *Neurology* 2015; 85: 212-8.

65. Opherk C, Coromilas J, Hirsch LJ. Heart rate and EKG changes in 102 seizures: analysis of influencing factors. *Epilepsy Res* 2002; 52: 117-27.

66. Tigaran S, Mølgaard H, McClelland R, Dam M, Jaffe AS. Evidence of cardiac ischemia during seizures in drug refractory epilepsy patients. *Neurology* 2003; 60: 492-5.

67. Pelliccia F, Kaski JC, Crea F, Camici PG. Pathophysiology of Takotsubo syndrome. *Circulation* 2017; 135: 2426-41.

68. Bybee KA, Prasad A. Stress–related cardiomyopathy syndromes. *Circulation* 2008; 118: 397-409.

69. Sieweke N, Allendörfer J, Franzen W, Feustel A, Reichenberger F, Pabst W, *et al*. Cardiac Troponin I elevation after epileptic seizure. *BMC Neurol* 2012; 12: 58.

70. Fawaz A, Nasreddine W, Makke Y, Atweh S, Wazne J, Arabi M, *et al*. Association of cardiovascular risk factors and troponin elevation after generalized tonic–clonic seizures. *Seizure* 2014; 23: 146-50.

71. Chatzikonstantinou A, Ebert AD, Hennerici MG. Temporal seizure focus and status epilepticus are associated with high–sensitive troponin I elevation after epileptic seizures. *Epilepsy Res* 2015; 115: 77-80

72. Nass RD, Meiling S, Andrié RP, Elger CE, Surges R. Laboratory markers of cardiac and metabolic complications after generalized tonic–clonic seizures. *BMC Neurol* 2017; 17: 187.

73. Stöllberger C, Wegner C, Finsterer J. Seizure–associated Takotsubo cardiomyopathy. *Epilepsia* 2011; 52: e160-7.

74. Stecker EC, Reinier K, Uy–Evanado A, Teodorescu C, Chugh H, Gunson K, *et al*. Relationship between seizure episode and sudden cardiac arrest in patients with epilepsy: a community–based study. *Circ Arrhythm Electrophysiol* 2013; 6: 912-6.

75. Myers KA, Bello–Espinosa LE, Symonds JD, Zuberi SM, Clegg R, Sadleir LG, *et al*. Heart rate variability in epilepsy: a potential biomarker of sudden unexpected death in epilepsy risk. *Epilepsia* 2018; 59: 1372-80.

76. Myers KA, Sivathamboo S, Perucca P. Heart rate variability measurement in epilepsy: how can we move from research to clinical practice?. *Epilepsia* 2018; 59: 1-10.

77. Suorsa E, Korpelainen JT, Ansakorpi H, Huikuri HV, Suorsa V, Myllylä VV, *et al*. Heart rate dynamics in temporal lobe epilepsy–a long–term follow–up study. *Epilepsy Res* 2011; 93: 80-3.

78. Task Force of the European Society of Cardiology, the North American Society of Pacing, Electrophysiology. Heart rate variability: standards of measurement, physiological interpretation and clinical use. *Circulation* 1996; 93: 1043-65.

79. Zack M, Luncheon C. Adults with an epilepsy history, notably those 45-64 years old or at the lowest income levels, more often report heart disease than adults without an epilepsy history. *Epilepsy Behav* 2018; 86: 208-10.

80. Fialho GL, Wolf P, Walz R, Lin K. Epilepsy and ultra–structural heart changes: the role of catecholaminergic toxicity and myocardial fibrosis. What can we learn from cardiology? *Seizure* 2019; 71: 105-9.

81. Li G, Bauer S, Nowak M, Norwood B, Tackenberg B, Rosenow F, *et al*. Cytokines and epilepsy. *Seizure* 2011; 20: 249-56.

82. Nass RD, Zur B, Elger CE, Holdenrieder S, Surges R. Acute metabolic effects of tonic–clonic seizures. *Epilepsia Open* 2019; 4: 599-608.

83. Devinsky O, Kim A, Friedman D, Bedigian A, Moffatt E, Tseng ZH. Incidence of cardiac fibrosis in SUDEP and control cases. *Neurology* 2018; 91: e55-61.

84. Konety SH, Koene RJ, Norby FL, Wilsdon T, Alonso A, Siscovick D, *et al*. Echocardiographic predictors of sudden cardiac death: the atherosclerosis risk in communities study and cardiovascular health study. *Circ Cardiovasc Imaging* 2016; 9: 10.

85. Fialho GL, Pagani AG, Wolf P, Walz R, Lin K. Echocardiographic risk markers of sudden death in patients with temporal lobe epilepsy. *Epilepsy Res* 2018; 140: 192-7.

86. Fialho GL, Wolf P, Walz R, Lin K. Increased cardiac stiffness is associated with autonomic dysfunction in patients with temporal lobe epilepsy. *Epilepsia* 2018; 59: e85-90.

87. Calik M, Ozkan HY, Ethemoglu O, Koca B, Kazanasmaz H, Karacan N, *et al*. The measurement of both carotid intima–media thickness and epicardial adipose tissue thickness in children with epilepsy receiving antiepileptic drug therapy. *Epilepsy Behav* 2018; 85: 110-4.

88. Tosun O, Karatoprak E. Analysis of tissue Doppler parameters and 24–hour heart rate variations in children with newly diagnosed untreated idiopathic epilepsy in interictal period. *Epilepsy Behav* 2019; 90: 11-4.

89. Li MCH, O'Brien TJ, Todaro M, Powell KL. Acquired cardiac channelopathies in epilepsy: evidence, mechanisms, and clinical significance. *Epilepsia* 2019; 60: 1753-67.

90. Surges R, Taggart P, Sander JW, Walker MC. Too long or too short? New insights into abnormal cardiac repolarization in people with chronic epilepsy and its potential role in sudden unexpected death. *Epilepsia* 2010; 51: 738-44.

91. Drake ME, Reider CR, Kay A. Electrocardiography in epilepsy patients without cardiac symptoms. *Seizure* 1993; 2: 63-5.

92. Neufeld G, Lazar JM, Chari G, Kamran H, Akajagbor E, Salciccioli L, *et al*. Cardiac repolarization indices in epilepsy patients. *Cardiology* 2009; 114: 255-60.

93. Dogan EA, Dogan U, Yildiz GU, Akilli H, Genc E, Genc BO, *et al*. Evaluation of cardiac repolarization indices in well–controlled partial epilepsy: 12–Lead ECG findings. *Epilepsy Res* 2010; 90: 157-63.

94. Kishk NA, Sharaf Y, Ebraheim AM, Baghdady Y, Alieldin N, Afify A, *et al*. Interictal cardiac repolarization abnormalities in people with epilepsy. *Epilepsy Behav* 2018; 79: 106-11.

95. Akalin F, Tirtir A, Yilmaz Y. Increased QT dispersion in epileptic children. *Acta Paediatr* 2003; 92: 916-20.

96. Krishnan V, Krishnamurthy KB. Interictal 12–lead electrocardiography in patients with epilepsy. *Epilepsy Behav* 2013; 29: 240-6.

97. Ramadan M, El–Shahat N, Omar A, Gomaa M, Belal T, Sakr S, *et al*. Interictal electrocardiographic and echocardiographic changes in patients with generalized tonic–clonic seizures. *Int Heart J* 2013; 54: 171-5.

98. Teh HS, Tan HJ, Loo CY, Raymond AA. Short QTc in epilepsy patients without cardiac symptoms. *Med J Malaysia* 2007; 62: 104-8.

99. Rejdak K, Rubaj A, Głowniak A, Furmanek K, Kutarski A, Wysokiński A, *et al*. Analysis of ventricular late potentials in signal–averaged ECG of people with epilepsy. *Epilepsia* 2011; 52: 2118-24.

100. Verrier RL, Klingenheben T, Malik M, El–Sherif N, Exner DV, Hohnloser SH, *et al*. Microvolt T–wave alternans: physiologic basis, methods of measurement, and clinical utility. Consensus guideline by the International Society for Holter and Noninvasive Electrocardiology. *J Am Coll Cardiol* 2011; 44: 1309-24.

101. Verrier RL, Ikeda T. Ambulatory ECG–based T–wave alternans monitoring for risk assessment and guiding medical therapy: mechanisms and clinical applications. *Prog Cardiovasc Dis* 2013; 56: 172-85.

102. Schomer AC, Nearing BD, Schachter SC, Verrier RL. Vagus nerve stimulation reduces cardiac electrical instability assessed by quantitative T–wave alternans analysis in patients with drug–resistant focal epilepsy. *Epilepsia* 2014; 55: 1996-2002.

103. Verrier RL, Nearing BD, Olin B, Boon P, Schachter SC. Baseline elevation and reduction in cardiac electrical instability assessed by quantitative T–wave alternans in patients with drug–resistant epilepsy treated with vagus nerve stimulation in the AspireSR E–36 trial. *Epilepsy Behav* 2016; 62: 85-9.

104. Pang TD, Nearing BD, Krishnamurthy KB, Olin B, Schachter SC, Verrier RL. Cardiac electrical instability in newly diagnosed/chronic epilepsy tracked by Holter and ECG patch. *Neurology* 2019; 93: 450-8.

105. Libbus I, Nearing BD, Amurthur B, KenKnight BH, Verrier RL. Autonomic regulation therapy suppresses quantitative T–wave alternans and improves baroreflex sensitivity in patients with heart failure enrolled in the ANTHEM–HF study. *Heart Rhythm* 2016; 13: 721-8

106. Ryvlin P, So EL, Gordon CM, Hesdorffer DC, Sperling MR, Devinsky O, *et al*. Long–term surveillance of SUDEP in drug–resistant epilepsy patients treated with VNS therapy. *Epilepsia* 2018; 59: 562-72.

107. Anderson JH, Bos JM, Cascino GD, Ackerman MJ. Prevalence and spectrum of electroencephalogram–identified epileptiform activity among patients with long QT syndrome. *Heart Rhythm* 2014; 11: 53-7.

108. Auerbach DS, McNitt S, Gross RA, Zareba W, Dirksen RT, Moss AJ. Genetic biomarkers for the risk of seizures in long QT syndrome. *Neurology* 2016; 87: 1660-8.

109. Aurlien D, Leren TP, Tauboll E, Gjerstad L. New SCN5A mutation in a SUDEP victim with idiopathic epilepsy. *Seizure* 2009; 18: 158-60.

110. Heron SE, Hernandez M, Edwards C, Edkins E, Jansen FE, Scheffer IE, *et al*. Neonatal seizures and long QT syndrome: a cardiocerebral channelopathy? *Epilepsia* 2010; 51: 293-6.

111. Keller DI, Grenier J, Christé G, Dubouloz F, Osswald S, Brink M, *et al*. Characterization of novel KCNH2 mutations in type 2 long QT syndrome manifesting as seizures. *Can J Cardiol* 2009; 25: 455-62.

112. Partemi S, Cestèle S, Pezzella M, Campuzano O, Paravidino R, Pascali VL, *et al*. Loss–of–function KCNH2 mutation in a family with long QT syndrome, epilepsy, and sudden death. *Epilepsia* 2013; 54: e112-6.

113. Benarroch EE. HCN channels: function and clinical implications. *Neurology* 2013; 80: 304-10.

114. Lehnart SE, Mongillo M, Bellinger A, Lindegger N, Chen BX, Hsueh W, *et al*. Leaky Ca2+ release channel/ryanodine receptor 2 causes seizures and sudden cardiac death in mice. *J Clin Invest* 2008; 118: 2230-45.

115. Ludwig A, Budde T, Stieber J, Moosmang S, Wahl C, Holthoff K, *et al*. Absence epilepsy and sinus dysrhythmia in mice lacking the pacemaker channel HCN2. *EMBO J* 2003; 22: 216-24.

116. Rivolta I, Binda A, Masi A, DiFrancesco JC. Cardiac and neuronal HCN channelopathies. *Pflugers Arch* 2020; 472: 931-51.

117. Coll M, Striano P, Ferrer–Costa C, Campuzano O, Matés J, Del Olmo B, *et al*. Targeted next–generation sequencing provides novel clues for associated epilepsy and cardiac conduction disorder/SUDEP. *PLoS One* 2017; 12: e0189618.

118. Frasier CR, Wagnon JL, Bao YO, McVeigh LG, Lopez–Santiago LF, Meisler MH, *et al*. Cardiac arrhythmia in a mouse model of sodium channel SCN8A epileptic encephalopathy. *Proc Natl Acad Sci USA* 2016; 113: 12838-43.

119. Bagnall RD, Crompton DE, Petrovski S, Lam L, Cutmore C, Garry SI, *et al*. Exome–based analysis of cardiac arrhythmia, respiratory control, and epilepsy genes in sudden unexpected death in epilepsy. *Ann Neurol* 2016; 79: 522-34.

120. Hookana E, Ansakorpi H, Kortelainen ML, Junttila MJ, Kaikkonen KS, Perkiömäki J, *et al*. Antiepileptic medications and the risk for sudden cardiac death caused by an acute coronary event: a prospective case–control study. *Ann Med* 2016; 48: 111-7.

121. Surges R, Volynski KE, Walker MC. Is levetiracetam different from other antiepileptic drugs? Levetiracetam and its cellular mechanism of action in epilepsy revisited. *Ther Adv Neurol Disord* 2008; 1: 13-24.

122. Danielsson BR, Lansdell K, Patmore L, Tomson T. Phenytoin and phenobarbital inhibit human HERG potassium channels. *Epilepsy Res* 2003; 55: 147-57.

123. Danielsson BR, Lansdell K, Patmore L, Tomson T. Effects of the antiepileptic drugs lamotrigine, topiramate and gabapentin on hERG potassium currents. *Epilepsy Res* 2005; 63: 17-25.

124. Redfern WS, Carlsson L, Davis AS, Lynch WG, MacKenzie I, Palethorpe S, *et al*. Relationships between preclinical cardiac electrophysiology, clinical QT interval prolongation and torsade de pointes for a broad range of drugs: evidence for a provisional safety margin in drug development. *Cardiovasc Res* 2003; 58: 32-45.

125. Auerbach DS, Biton Y, Polonsky B, McNitt S, Gross RA, Dirksen RT, *et al*. Risk of cardiac events in Long QT syndrome patients when taking antiseizure medications. *Transl Res* 2018; 191: 81-92.e7.

126. Craig S. Phenytoin poisoning. *Neurocrit Care* 2005; 3: 161-70.

127. Degiorgio CM. Atrial flutter/atrial fibrillation associated with lacosamide for partial seizures. *Epilepsy Behav* 2010; 18: 322-4.

128. DeGiorgio AC, Desso TE, Lee L, DeGiorgio CM. Ventricular tachycardia associated with lacosamide co–medication in drug–resistant epilepsy. *Epilepsy Behav Case Rep* 2012; 1: 26-8.

129. Kaufman KR, Velez AE, Wong S, Mani R. Low–dose lacosamide–induced atrial fibrillation: case analysis with literature review. *Epilepsy Behav Case Rep* 2012; 1: 22-5.

130. Hulbert J, Elger CE, Meyer R, Surges R. Antiepileptic drugs impair shortening of isolated cardiomyocytes. *Front Neurol* 2017; 8: 133.

131. Corbellini ÁB, Torre PP, Hristova VN, Sanz BZ, García ACC, Jorge FR, *et al*. Cardioembolic acute cerebral micro–infarcts in the context of atrial fibrillation after low–dose intravenous infusion of lacosamide. *Epileptic Disord* 2020; 22: 83-9.

132. Lotufo PA, Valiengo L, Benseñor IM, Brunoni AR. A systematic review and meta–analysis of heart rate variability in epilepsy and antiepileptic drugs. *Epilepsia* 2012; 53: 272-82.

133. Mintzer S, Skidmore CT, Abidin CJ, Morales MC, Chervoneva I, Capuzzi DM, *et al*. Effects of antiepileptic drugs on lipids, homocysteine, and C–reactive protein. *Ann Neurol* 2009; 65: 448-56.

134. Mintzer S, Yi M, Hegarty S, Maio V, Keith S. Hyperlipidemia in patients newly treated with anticonvulsants: a population study. *Epilepsia* 2020; 61: 259-66.

135. Chuang YC, Chuang HY, Lin TK, Chang CC, Lu CH, Chang WN, *et al*. Effects of long–term antiepileptic drug monotherapy on vascular risk factors and atherosclerosis. *Epilepsia* 2012; 53: 120-8.

136. Panebianco M, Zavanone C, Dupont S, Restivo DA, Pavone A. Vagus nerve stimulation therapy in partial epilepsy: a review. *Acta Neurol Belg* 2016; 116: 241-8.

137. Ghani S, Vilensky J, Turner B, Tubbs RS, Loukas M. Meta-analysis of vagus nerve stimulation treatment for epilepsy: correlation between device setting parameters and acute response. *Childs Nerv Syst* 2015; 31: 2291-304.

138. Boon P, Vonck K, van Rijckevorsel K, El Tahry R, Elger CE, Mullatti N, *et al*. A prospective, multicenter study of cardiac–based seizure detection to activate vagus nerve stimulation. *Seizure* 2015; 32: 52-61.

139. Kato H, Fujimoto A, Okanishi T, Sugiura R, Ijima K, Enoki H. New onset syncopal events following vagus nerve stimulator implantation might be key to preventing vagus nerve stimulation–induced symptomatic bradycardia – a case report and review. *Epilepsy Behav Case Rep* 2018; 10: 57-60.

140. Kent KM, Epstein SE, Cooper T, Jacobowitz DM. Cholinergic innervation of the canine and human ventricular conducting system. Anatomic and electrophysiologic correlations. *Circulation* 1974; 50: 948-55.

141. Luo S, Michler K, Johnston P, Macfarlane PW. A comparison of commonly used QT correction formulae: the effect of heart rate on the QTc of normal ECGs. *J Electrocardiol* 2004; 37: 81-90.

142. Dubin D. *Rapid interpretation of EKG's: An interactive course (sixth edition)*. Tampa, Fla.: Cover Pub. Co., 2000.

143. Verrier RL, Nearing BD, Pang TD, Schachter SC. Monitoring risk for sudden cardiac death: is there a role for EKG patches?. *Curr Opin Biomed Eng* 2019; 11: 117-23.

144. Chua SK, Chen LC, Lien LM, Lo HM, Liao ZY, Chao SP, *et al*. Comparison of arrhythmia detection by 24–hour Holter and 14–day continuous electrocardiography patch monitoring. *Acta Cardiol Sin* 2020; 36: 251-9.

TEST YOURSELF

(1) Which statement is correct? The risk of premature mortality in people with epilepsy is:

A. Not elevated
B. Is only slightly increased
C. Increased 1.5-fold
D. Is increased 2-3-fold
E. Is increased 5-fold

(2) Which statement is incorrect? Cardiac complications in people with epilepsy can be:

A. caused by acute seizures
B. caused by antiseizure medication
C. caused by remote seizure effects
D. caused by inherited channelopathies
E. not caused by vagus nerve stimulation

(3) Which statement is incorrect? The following cardiac complications can be causally related to epilepsies:

A. Myocarditis
B. Bradyarrhythmias
C. Myocardical infarction
D. Takotsubo cardiomayopathy
E. Ventricular tachycardia

(4) Which symptom does not typically occur during syncope?

A. Flaccid fall
B. Generalized stiffening
C. Groaning together with closed eyes
D. Myoclonic jerks
E. Prodromal feelings

(5) Which statement is incorrect? What diagnostic approaches or tools are useful to assess cardiac complications in people with epilepsy?

A. 12-lead ECG
B. Holter recordings
C. Video-EEG monitoring
D. In-depth history taking
E. Cardiac I123-meta-iodobenzylguanidine single-photon emission computed tomography (MIBG-SPECT)

(6) Which statement is correct? The following cardiac disturbances occur during epileptic seizures?

A. Tachycardia
B. Bradycardia
C. AV block
D. Lengthening of corrected QT intervals.
E. All of the above

(7) Which statement is correct? Ictal asystole ...

A. usually occurs in people with frontal lobe epilepsy
B. almost never occurs in people with temporal lobe epilepsy
C. is the leading cause of SUDEP
D. tends to recur
E. does not lead to falls and injuries

(8) Which statement is incorrect?

A. Signs of altered cardiac repolarisation are relatively frequent in people with epilepsy
B. Epileptic seizures can transiently lengthen or shorten corrected QT intervals beyond normal limits
C. Sudden cardiac arrest in people with epilepsy mostly occurs without evidence of a prior seizure
D. Antiseizure medication is the major cause of abnormal cardiac repolarisation
E. T wave alternans can be modulated by vagus nerve stimulation

(9) Which statement is incorrect in the context of seizure-related cardiac injury?

A. Epileptic seizures, especially tonic-clonic seizures, lead to a massive release of catecholamines
B. Seizure-related hypoxemia, catecholamines and other metabolic factors can induce subtle cardiac injury
C. High-sensitivity troponin is found in about 25% of patients following a tonic-clonic seizure
D. Takotsubo cardiomyopathy predominantly occurs with prolonged absence seizures
E. People older than 70 years, with a cardiovascular risk profile or coronary artery disease, have an elevated risk of seizure-related myocardial infarction

(10) Which statement is incorrect in the context of antiseizure medication and cardiac complications?

A. Most antiseizure drugs have multiple cellular targets
B. Antiseizure medication is linked to an increased risk of sudden cardiac death even in the absence of epilepsy
C. Sodium channels blockers frequently lead to bradyarrhythmia even in patients on monotherapy
D. The combination of antiseizure drugs and sodium channel blockers at higher doses facilitate the onset of cardiac arrhythmias
E. Enzyme-inducing antiseizure medication worsens the serum lipid profile

(11) What are the main causes of cardiac complications in people with epilepsy?

(12) When is it meaningful to search or anticipate cardiac complications in people with epilepsy?

(13) How should cardiac complications be managed?

Note: Reading the manuscript provides an answer to all questions. Correct answers may be accessed on the website, www.epilepticdisorders.com, under the section "The EpiCentre".