



**Universiteit
Leiden**
The Netherlands

Neurological and vascular complications of primary and secondary brain tumours: EANO-ESMO Clinical Practice Guidelines for prophylaxis, diagnosis, treatment and follow-up

Roth, P.; Pace, A.; Rhun, E. le; Weller, M.; Ay, C.; Moyal, E.C.J.; ... ; ESMO Guidelines Comm

Citation

Roth, P., Pace, A., Rhun, E. le, Weller, M., Ay, C., Moyal, E. C. J., ... Preusser, M. (2021). Neurological and vascular complications of primary and secondary brain tumours: EANO-ESMO Clinical Practice Guidelines for prophylaxis, diagnosis, treatment and follow-up. *Annals Of Oncology*, 32(2), 171-182. doi:10.1016/j.annonc.2020.11.003

Version: Publisher's Version
License: [Creative Commons CC BY 4.0 license](https://creativecommons.org/licenses/by/4.0/)
Downloaded from: <https://hdl.handle.net/1887/3251137>

Note: To cite this publication please use the final published version (if applicable).

SPECIAL ARTICLE

Neurological and vascular complications of primary and secondary brain tumours: EANO-ESMO Clinical Practice Guidelines for prophylaxis, diagnosis, treatment and follow-up[†]

P. Roth¹, A. Pace², E. Le Rhun^{1,3,4,5,6}, M. Weller¹, C. Ay⁷, E. Cohen-Jonathan Moyal^{8,9}, M. Coomans¹⁰, R. Giusti¹¹, K. Jordan¹², R. Nishikawa¹³, F. Winkler^{14,15,16}, J. T. Hong¹⁷, R. Ruda¹⁸, S. Villà¹⁹, M. J. B. Taphoorn^{10,20}, W. Wick¹⁴ & M. Preusser²¹, on behalf of the EANO Executive Board^{*}, ESMO Guidelines Committee^{*}

¹Department of Neurology and Brain Tumor Center, University Hospital and University of Zurich, Zurich, Switzerland; ²Neuroncology Unit, IRCCS Regina Elena Cancer Institute, Rome, Italy; ³Université Lille, U-1192, Lille; ⁴Inserm, U-1192, Lille; ⁵Centre Hospitalier Universitaire CHU, Lille, General and Stereotaxic Neurosurgery Service, Lille; ⁶Oscar Lambret Center, Breast Cancer Department, Lille, France; ⁷Division of Haematology and Haemostaseology, Department of Medicine I, Comprehensive Cancer Center Vienna, Vienna, Austria; ⁸Radiation Oncology Department, Institut Claudius Regaud, Université Paul Sabatier, Toulouse; ⁹Institut Universitaire du Cancer de Toulouse IUCT Oncopole, Toulouse, France; ¹⁰Department of Neurology, Leiden University Medical Center, Leiden, The Netherlands; ¹¹Medical Oncology Unit, Azienda Ospedaliero Universitaria Sant'Andrea, Rome, Italy; ¹²Department of Medicine V, Hematology, Oncology and Rheumatology, University of Heidelberg, Heidelberg, Germany; ¹³Department of Neuro-Oncology/Neurosurgery, Saitama Medical University International Medical Center, Saitama, Japan; ¹⁴Department of Neurology and Neurooncology Program, National Center for Tumor Diseases, Heidelberg University Hospital, Heidelberg; ¹⁵Clinical Cooperation Unit Neurooncology, German Cancer Research Center (DKFZ), Heidelberg; ¹⁶German Cancer Consortium (DKTK), Heidelberg, Germany; ¹⁷Department of Neurosurgery, Eunpyeong St. Mary's Hospital, Seoul, The Catholic University of Korea, Republic of Korea; ¹⁸Department of Neuro-Oncology, City of Health and Science and University of Turin, Turin, Italy; ¹⁹Catalan Institute of Oncology, HU Germans Trias, Badalona, Universitat Autònoma de Barcelona, Barcelona, Spain; ²⁰Department of Neurology, Haaglanden Medical Center, The Hague, The Netherlands; ²¹Division of Oncology, Department of Medicine I, Medical University of Vienna, Vienna, Austria



Available online 24 November 2020

Key words: brain tumour, brain metastasis, complications, oedema, seizures, thrombosis

INTRODUCTION

The central nervous system (CNS) is affected by a large variety of primary brain tumours and by metastases of cancers originating from other organs. Brain tumours carry a high morbidity and are associated with a range of complications that are rare in cancers affecting other anatomical locations. Neurological symptoms and signs are related to the anatomical area of the CNS involved. There is no symptom or sign specific to primary or secondary brain tumours. Focal or lateralised effects of local tissue destruction include hemiparesis, aphasia and visual field deficits. These lateralised symptoms often present subacutely and show a progressive course over some days or weeks. Leptomeningeal disease typically

leads to multifocal signs and symptoms. Most frequently, patients present with headaches, nausea and vomiting, mental changes, gait difficulties, cranial nerve palsies and focal or irradiating (radicular) neck and back pain.¹

Unspecific symptoms of raised intracranial pressure are headache, with or without nausea and vomiting, cognitive impairment, personality changes and gait disturbances. These symptoms are caused by direct pressure of the growing tumour and oedema, or impairment of cerebrospinal fluid (CSF) circulation with consecutive hydrocephalus. The typical holocephalic or unilateral throbbing brain tumour-related headaches are accentuated after supine position, e.g. in the morning, and improve over a period of upright time during the day.²

A detailed neurological examination is recommended and a standard evaluation form, e.g. as proposed for the quantitative assessment of brain tumour-related signs and symptoms, with the Neurologic Assessment in Neuro-Oncology (NANO) criteria should be used.³ The form should also be used for the clinical evaluation of patients during follow-up. In addition to overall survival (OS), assessing clinical benefit, especially in patients with brain tumours, constitutes an important endpoint in clinical trials.⁴

The complications associated with brain tumours require specific management strategies for optimal prevention,

*Correspondence to: ESMO Guidelines Committee, ESMO Head Office, Via Geneva 4, 6900 Lugano, Switzerland

Email: clinicalguidelines@esmo.org (ESMO Guidelines Committee).

*EANO Office, c/o WMA GmbH | Alser Strasse 4, 1090 Vienna, Austria
Email: office@eano.eu (EANO Executive Board).

[†] These Guidelines were developed by the European Society for Medical Oncology (ESMO) and the European Association of Neuro-Oncology (EANO). The two societies nominated authors to write the guidelines as well as reviewers to comment on them. These guidelines were approved by the EANO Executive Board and the ESMO Guidelines Committee in July 2020.

0923-7534/© 2020 European Society for Medical Oncology. Published by Elsevier Ltd. All rights reserved.

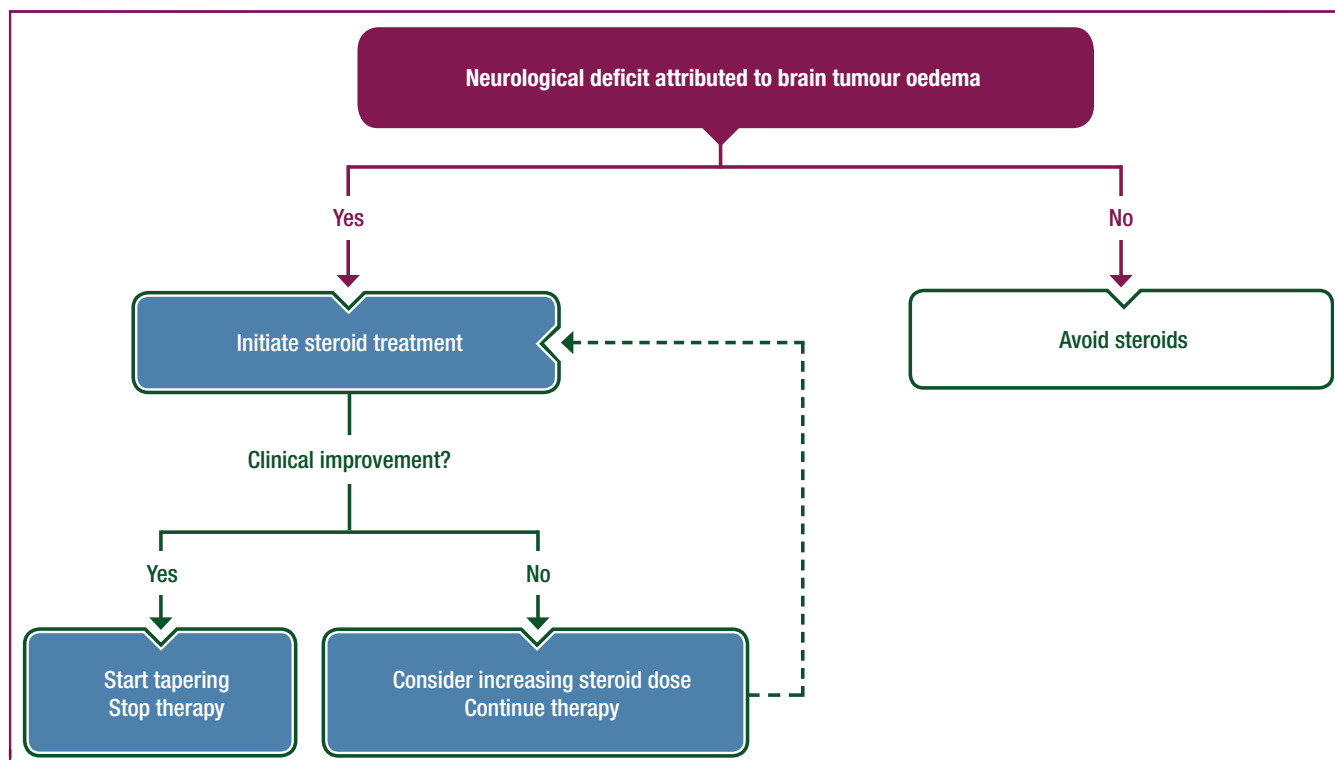


Figure 1. Clinical management of brain oedema in patients with brain tumours.

diagnosis, therapy and follow-up, and necessitate multidisciplinary cooperation. The current European Association of Neuro-Oncology (EANO)-European Society for Medical Oncology (ESMO) joint guidelines summarise recommendations for the clinical management of the most important complications observed in brain tumour patients and cover brain oedema, seizures, neurocognitive impairment, venous thromboembolism, stroke, intracranial haemorrhage, metastatic spinal cord compression (MSCC) and supportive and end-of-life care. Due to the lack of high-level evidence on these topics, most recommendations are based on expert opinion and consensus. They aim at guiding clinical management of brain tumour patients and end-of-life care and serve as a helpful resource for physicians and health care providers. For the future, prospective clinical trials specifically enrolling brain tumour patients are needed to better define diagnostic and therapeutic measures of complications in this patient group.

BRAIN OEDEMA

Incidence and epidemiology

Primary and secondary brain tumours are frequently surrounded by oedema. This condition is almost entirely found in malignant neoplasms but occurs also in the context of benign tumours such as meningiomas. As a consequence, the vast majority of brain tumour patients will receive anti-oedema treatment at some point during the disease course.⁵ Some therapeutic interventions, mainly radiotherapy (RT) but also some systemic treatments, may

further enhance the oedema surrounding the tumour, leading to increased mass effect and symptom burden.⁶ The recognition of tumour-associated oedema and subsequent initiation of adequate therapeutic measures, with consideration of the overall oncological therapeutic goals, is an important step in the supportive treatment of brain tumour patients aimed at restoring and maintaining the patients' quality of life (QoL) and functional autonomy.

Diagnosis

The diagnosis of tumour-associated oedema is typically made by magnetic resonance imaging (MRI). If the patient is unable to undergo MRI or for other reasons, computed tomography (CT) will also identify oedema. Importantly, the need for anti-oedema treatment is not simply defined by the extent of oedema but should be primarily based on the patient's clinical condition.

Management and monitoring

Anti-oedema treatment should be considered in brain tumour patients requiring relief from neurological deficits (Figure 1). Steroids are the mainstay for anti-oedema treatment. They act rapidly, can be administered orally or intravenously and are not expensive. Despite their prevalent use, only few data from randomised trials assessing the anti-oedema activity of steroids in brain tumour patients are available. Dexamethasone is the most frequently administered drug.⁷ It has potent glucocorticoid activity but hardly any mineralocorticoid effects, which avoids

undesirable alterations of blood electrolyte levels. Furthermore, because of its long biological half-life, a single daily administration is sufficient. Standard doses are in the range of 4-16 mg/day. A randomised trial comparing 4 and 8 mg of dexamethasone as well as 4 and 16 mg per day in patients with metastatic brain tumours did not show a superior effect of the higher doses on the patients' condition as defined by the Karnofsky performance score (KPS). However, patients receiving higher dexamethasone doses were more likely to suffer from side-effects.⁸ There are few alternatives to steroids for this indication. Limited evidence on the anti-oedema activity of boswellic acids, angiotensin-II inhibitors, hyperosmolar agents or corticorelin acetate does not support their regular use.⁹⁻¹²

Follow-up and long-term implications

Clinically-asymptomatic patients seldom require anti-oedema treatment with steroids. Because of their possible interaction with other agents such as antiepileptic drugs or immunotherapeutics,¹³ a critical evaluation of steroid administration is mandatory. The prophylactic use of steroids, e.g. perioperatively or during RT of patients with primary or secondary brain tumours, is increasingly discouraged.¹⁴ The renewed strong interest in steroids and their effect on brain tumour patients results from strong evidence linking steroid use to inferior survival in glioblastoma,¹⁵ and the current interest in immunotherapy approaches for primary and metastatic brain tumours in which steroid use may be detrimental.^{16,17} Patients with clinical symptoms should be treated as long as a clinical benefit can be assumed. Long-term steroid use is associated with significant side-effects such as an increased risk for the development of pneumocystis jiroveci pneumonia (PJP), diabetes, arterial hypertension, osteoporosis, myopathy and psychiatric adverse effects, among others.¹⁸ Therefore, patients should be closely monitored with regular clinical examinations to decide whether tapering should be considered. No precise rules have been established to define the ideal tapering schedule. Typically, a dose reduction over 2-4 weeks will be appropriate but patients with long-term steroid use may require an even longer period until complete tapering.

Recommendations

- Diagnosis of brain oedema should be carried out using T2-weighted or FLAIR MRI sequences [EANO: IV, n/a; ESMO: V, n/a].
- Anti-oedema treatment should only be considered in brain tumour patients requiring relief from neurological deficits [EANO: IV; ESMO: V].
- Dexamethasone is the drug of choice for the treatment of symptomatic tumour-associated brain oedema [EANO: IV, B; ESMO: V, B].
- The initial dexamethasone dose is typically in the range of 4-16 mg/day given as a single daily intravenous (i.v.) or oral administration. The steroid dose should be tapered to the lowest dose needed to control clinical symptoms [EANO: IV, n/a; ESMO: V, n/a].

- Appropriate PJP prophylaxis, e.g. with trimethoprim-sulfamethoxazole, should be considered in patients requiring steroid treatment of >4 weeks, in those undergoing RT or chemotherapy (ChT) in parallel, or with a lymphocyte count <1000/ μ l [EANO: IV, B; ESMO: V, B].

SEIZURES

Incidence and epidemiology

It has traditionally been assumed that the lifetime risk for seizures in adult patients with diffuse gliomas exceeds 50%, notably in patients with World Health Organization (WHO) grade II and III tumours,¹⁹ with a possible link to the presence of isocitrate dehydrogenase (IDH) mutations.²⁰ A third of patients with meningiomas suffer from seizures before the first surgical intervention and long-lasting tumour control is associated with freedom from seizures.²¹ Only 20% of patients with newly-diagnosed brain metastases present with seizures, and tumour control is probably the most important predictor of seizure control.²² For seizures in brain tumour patients, according to the nomenclature proposed by the International League against Epilepsy (ILAE), the most common types will now be referred to as 'focal' seizures and focal to bilateral tonic-clonic seizures.²³ The Response Assessment in Neuro-Oncology Group (RANO) has acknowledged the central role of seizure control for QoL of patients and caregivers and developed guidance on how to implement seizure control as an efficacy endpoint into clinical trials.²⁴

Diagnosis

In the absence of a history of a primary or metastatic brain tumour, new onset of epileptic seizures in adults requires neuroimaging, that is, contrast-enhanced cerebral MRI, unless there are contraindications, to rule out an intracranial neoplasm. Systemic cancer patients without a history of brain metastases should also be assessed by neuroimaging when developing seizures. Alternative aetiologies include treatment-associated neurotoxicity, infectious diseases, paraneoplastic syndromes, metabolic disturbances and cerebrovascular disease.²⁵ New-onset or less well-controlled seizures in patients with primary brain tumours are often indicative of progression; therefore, neuroimaging should be considered even if there is otherwise no change in neurological status. Electroencephalography (EEG) may help in the initial assessment of patients with suspected seizures and can be used to estimate future seizure risk or for the differential diagnosis of altered neurocognitive function or vigilance. An EEG is important to rule out nonconvulsive status epilepticus (NCSE) with worsening neurological symptoms or vigilance problems. EEG will also help to distinguish epileptic seizures from psychogenic seizures.

Management and monitoring

Therapeutic interventions against brain tumours are important contributors of seizure control. This concerns not only surgery, but also RT and ChT.²⁶ The vast majority of brain tumour patients who experience a seizure should be

placed on anticonvulsant secondary prophylaxis, at least transiently (Figure 2). If surgery is carried out, and if a near gross total resection is achieved, efforts at tapering and stopping anticonvulsant drugs should be undertaken within weeks after surgery, provided there is no recurrent tumour growth. If only a biopsy or partial resection are carried out, with subsequent RT or ChT-induced tumour regression, tapering and stopping can also be considered.

The choice of anticonvulsant agents has become wider with more drugs available over recent years.²⁷ However, there is lack of robust, randomised, controlled evidence to support the choice of the optimal antiepileptic drug for the treatment of seizures in patients with brain tumours. Of the traditional drugs, valproic acid still has a firm place in some centres, given its efficacy and overall good tolerability. There is no evidence of a higher rate of perisurgical bleeding complications with valproic acid prophylaxis. Valproic acid must not be used in females who may become pregnant and interactions with other drugs need to be checked on a regular basis. Phenytoin, phenobarbital and carbamazepine are no longer recommended as agents of first choice because of their side-effect profile and drug interactions, especially with steroids and various cytotoxic and targeted agents. Levetiracetam has become the drug of first choice at most neuro-oncology centres in recent years, although psychiatric side-effects in some patients remain a concern.²⁸ Lamotrigine has good antiseizure activity but requires a period of several weeks until sufficient drug levels are reached. Lacosamide may assume a larger role as an add-on treatment for patients whose seizure disorder is not controlled by monotherapy.²⁹ Patients and caregivers should be instructed how to behave and whom to contact in case of recurrent seizures.

Follow-up

Brain tumour patients with a history of seizures are questioned on the occurrences of potential seizures at each follow-up visit. Serum levels of anticonvulsant drugs can be determined to explore failure to control the epileptic activity, to assess compliance and for the differential diagnosis of potential drug-related side-effects.

Recommendations

- New-onset seizures in cancer patients without a history of brain tumour should trigger neurological work-up, including cerebral MRI [EANO: IV, B; ESMO: V, n/a].
- Since worsening of a pre-existing seizure disorder in brain tumour patients often heralds tumour progression, repeat MRI and other potentially necessary work-up such as blood and CSF examination should be considered [EANO: IV, B; ESMO: V, n/a].
- Primary anticonvulsant prophylaxis is not indicated in brain tumour patients [EANO: I, D; ESMO: I, D].
- Levetiracetam and lamotrigine are preferred options of first choice because of their efficacy and overall good tolerability [EANO: IV, n/a; ESMO: V, n/a].

- Brain tumour patients who have suffered epileptic seizures and are not candidates for surgery should receive secondary prophylaxis until local control has been achieved [EANO: IV, n/a; ESMO: V, n/a].
- Enzyme-inducing anticonvulsants should be avoided in patients with brain tumours [EANO: III, D; ESMO: III, D].
- Judgements on the competency to drive need to adhere to national guidelines and law and should consider not only epilepsy but also other aspects of neurological and neurocognitive function [EANO: IV n/a; ESMO: V, n/a].

NEUROCOGNITIVE IMPAIRMENT

Incidence and epidemiology

Cognitive impairment, including deficits in domains such as memory, attention and executive functioning, has a large impact on the QoL of brain tumour patients.^{30,31} It is caused by the tumour itself, as well as by antitumour treatment, supportive treatment and patient characteristics such as age and response to psychological stress. Cognitive impairment is already present in 90% of patients with a primary brain tumour³² and in 91% of patients with brain metastases³³ before treatment. Even patients with benign meningiomas show subtle cognitive deficits.³⁴

Diagnosis and pathology

Various factors including tumour location, size and histology are associated with the extent and severity of cognitive impairment. Apart from local damage, brain tumours also cause global cognitive dysfunctioning by disruption of cognitive networks. Memory and executive functioning are the most frequently impaired domains.³⁵ Antitumour treatment with surgery, RT or ChT may affect cognitive functioning, both in a positive as well as in a negative way. Resection of the tumour may result in cognitive improvement by relieving elevated intracranial pressure. Conversely, damaging the surrounding tissue may cause transient or permanent cognitive deficits.³⁶ RT-induced cognitive impairment can be subclassified by its temporal evolution. Short-term cognitive deficits, presenting during and shortly after RT, may result from elevated intracranial pressure and fatigue. Delayed side-effects, which may develop months to years after RT, range from local radionecrosis to diffuse leukoencephalopathy and cerebral atrophy, and may be associated with irreversible cognitive decline that can ultimately lead to dementia.^{37,38} Demyelination and small vessel damage are likely the cause of this syndrome. Neural stem cells residing in the hippocampus and subventricular zone are suspected to be a critical target of RT-associated cognitive decline.³⁹ Systemic ChT may also cause acute and short-term cognitive side-effects⁴⁰; moreover, long-term ChT-related changes in cognitive functioning have been summarised under the concept of the chemobrain.⁴¹

Cognitive impairment is measured with validated neuropsychological tests that evaluate different domains of cognitive functioning, including attention, processing speed,

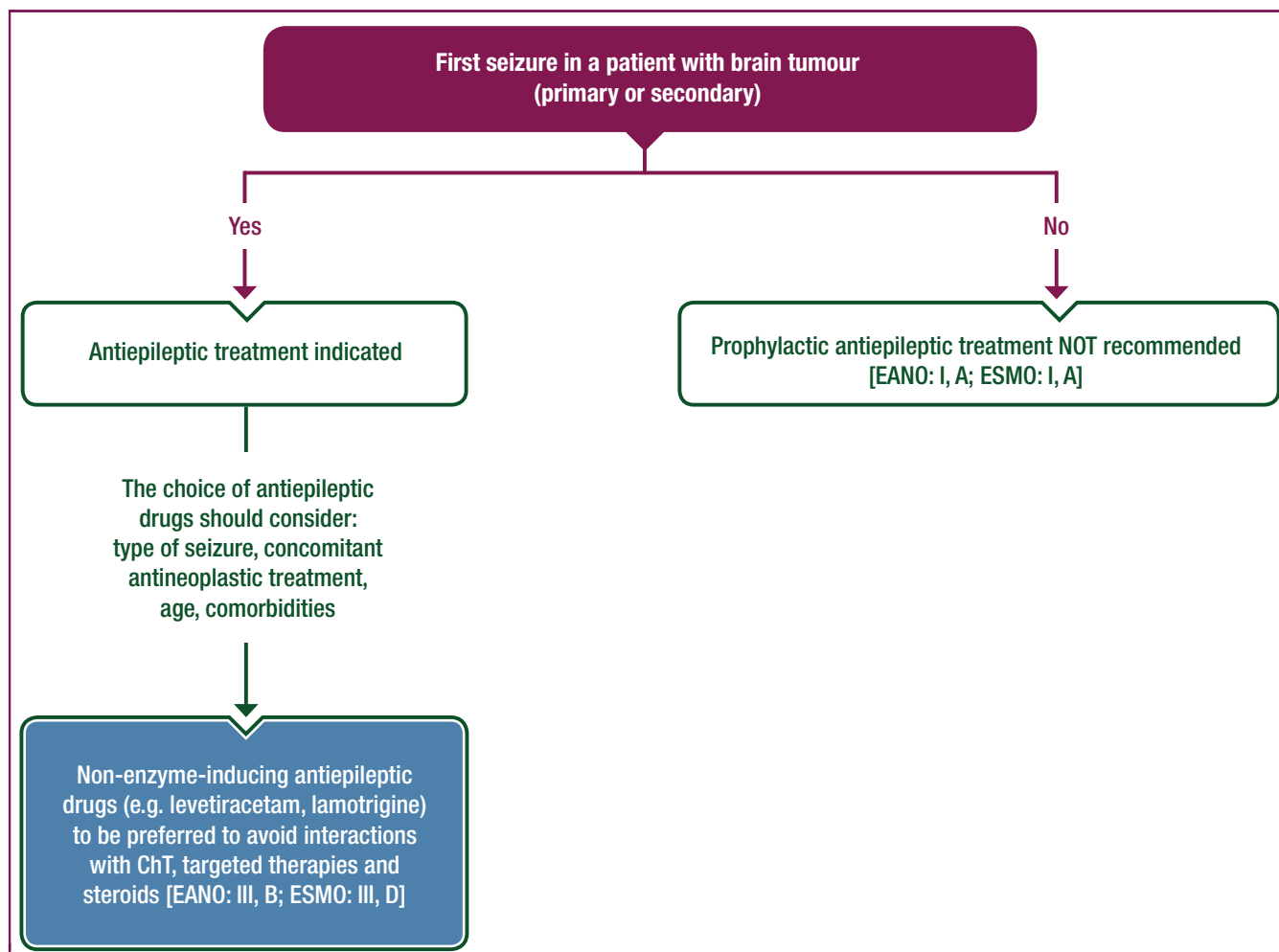


Figure 2. Clinical management of seizures in patients with brain tumours.
ChT, chemotherapy.

memory, visuospatial functioning and executive functioning. Among validated neuropsychological tests are the Hopkins verbal learning test for verbal memory, the Rey–Osterrieth complex figure test (visuoconstruction, visual memory), the controlled oral word association test (verbal fluency), the Stroop test (interference, executive functioning) and the trail making test (attention, executive functioning). Self-perceived cognitive functioning, which is only moderately correlated with objective cognitive functioning,⁴² reflects cognitive complaints experienced by patients and is assessed with validated questionnaires, such as the cognitive failures questionnaire and the medical outcomes study subjective cognitive functioning scale.

Treatment

Preventing cognitive side-effects due to antitumour treatment may primarily be achieved by administering treatment strategies that have a less detrimental effect on cognition. Intraoperative techniques such as awake craniotomy or mapping of eloquent brain functions may preserve cognitive and neurological integrity.⁴³ Limited dose per fraction and lower overall radiation dose, focal RT instead of whole brain radiotherapy (WBRT) and hippocampal sparing during

WBRT⁴⁴ may reduce the risk of cognitive deficits.^{38,45,46} Proton RT in selected brain tumour patients may contribute to preservation of cognitive functioning by sparing normal tissue to a larger extent than traditional photon treatment.⁴⁷ However, at this point, for most brain tumour types such as diffuse gliomas, there are no solid data from randomised trials on the use of proton RT available. Therefore, it remains to be seen if future studies will demonstrate that proton therapy is superior to conventional RT in terms of efficacy or toxicity.⁴⁸

Cognitive side-effects that may occur due to antiepileptic therapy⁴⁹ can partly be overcome by dose adjustments, withdrawal when safely possible or replacement by alternative antiepileptic drugs. Pharmacological intervention studies have investigated the use of methylphenidate,⁵⁰ donepezil,^{51,52} memantine⁵³ and a combination of methylphenidate and modafinil⁵⁴ to improve cognitive functioning. Although some studies have reported a beneficial effect, limitations in methods and study design, such as the lack of a control group, impede generalisation of the results.

Rehabilitation programmes, including cognitive rehabilitation and exercise training, may reduce cognitive deficits.^{55–58} A large randomised study that aimed at improving

cognitive functioning by offering a cognitive rehabilitation programme showed a subjective improvement in patients with WHO grade II and grade III gliomas as well as an improved attention and verbal memory 6 months after treatment, compared with the waiting-list control group.⁵⁸

Follow-up

Monitoring patients' cognitive functioning during the course of the disease provides information on the impact of a specific treatment strategy. As cognitive deficits may present later in the disease, regular monitoring and long-term follow-up are essential for both clinical trials and in clinical practice.

Recommendations

- Antitumour treatment strategies that prevent or minimise cognitive impairment should be prioritised [EANO: IV, n/a; ESMO: V, n/a].
- Rehabilitation should be considered, especially in young patients with a favourable prognosis, and in stable brain tumour patients with cognitive complaints and deficits [EANO: IV, n/a; ESMO: V, n/a].
- Regular monitoring and long-term follow-up of patients' cognitive functioning is essential, both in clinical trials and in clinical practice [EANO: IV, n/a; ESMO: V, n/a].

VENOUS THROMBOEMBOLISM AND STROKE

Incidence and epidemiology

The risk of venous thromboembolism (VTE) is increased in cancer patients, with a particularly high risk in brain tumour patients.^{59,60} An incidence of 22%-30% of symptomatic VTE has been reported in contemporary cohorts of glioblastoma patients.^{61,62} The probability of VTE is high already at diagnosis and during the initial phase of chemoradiotherapy. Recurrent VTE may be observed in a third (27%) of glioblastoma patients.⁶¹ In an analysis of three randomised trials, patients with newly-diagnosed glioblastoma, treated with therapeutic anticoagulation between the start of concomitant temozolomide with RT and the start of maintenance temozolomide, had profoundly decreased survival. No decrease in survival was observed in patients treated with prophylactic doses of anticoagulants or with antiplatelet agents. It remains unclear whether venous thromboembolic events caused this survival difference.⁶³ VTE has been less investigated in patients with brain metastases; however, a retrospective study reported an incidence of 20%.⁶⁴ The incidence is probably underestimated, and an increasing number of asymptomatic VTEs, incidentally found on CT scans done for tumour staging or other reasons such as imaging for exclusion of suspected VTE or pulmonary embolism (PE), have been reported.⁶⁵

Potential risk factors among glioma patients include age, leg paresis, higher WHO grade of the tumour, high levels of circulating P-selectin or high expression of podoplanin in the tumour, intraluminal thrombosis as well as high leukocyte

and low platelet counts.⁶⁶⁻⁶⁸ In contrast, IDH mutant gliomas may have a lower VTE risk. Treatment-related factors such as cancer surgery, including neurosurgical interventions, irradiation, ChT and steroid administration, the presence of indwelling catheters and supportive treatments such as frequent transfusions add to VTE risk.⁶⁹ While bevacizumab may increase the risk of VTE in the general population of cancer patients by 33%,⁷⁰ no increased risk has been observed in the phase III trials exploring bevacizumab in newly-diagnosed or recurrent glioblastoma.⁷¹⁻⁷³

Diagnosis

The diagnosis of VTE can be challenging because symptoms and signs may be unspecific and brain tumour patients often have neurological deficits, which can be clinically more dominant and mask VTE-related symptoms and signs. Classic symptoms include leg swelling, erythema and pain of the limb for deep vein thrombosis (DVT), and tachycardia, thoracic pain, shortness of breath or haemoptysis for PE. Of note, in most patients with a diagnosis of unsuspected or incidental PE, fatigue was the leading symptom.^{74,75} The diagnostic approach to cancer patients with suspected PE or DVT has not been specifically investigated. Therefore, general diagnostic work-up including assessment of the clinical pre-probability of VTE, D-dimer testing⁷⁶ and imaging have to be applied in clinical practice to rule out DVT and/or PE. Compression ultrasound is the method of choice to diagnose DVT and CT pulmonary angiogram for PE (Figure 3). However, there is a need for further research to establish validated algorithms for the diagnostic work-up of a suspected DVT and/or PE in patients with cancer, including brain tumours.

Primary thromboprophylaxis

Pharmacological thromboprophylaxis is the mainstay in the prevention of VTE. Non-pharmacological methods for the perioperative prophylaxis of VTE include early mobilisation, compression stockings and external pneumatic compression devices. Mechanical and pharmacological approaches may be combined to reduce the risk of VTE.^{77,78} In general, patients with cancer, with and without metastatic disease, who are hospitalised with acute illness or confined to bed due to immobility are recommended to receive prophylactic thromboprophylaxis for the duration of the hospital stay.^{79,80} The administration of low-molecular weight heparin (LMWH) or unfractionated heparin reduces the risk of postoperative VTE in patients undergoing a surgical procedure by 50%, without increasing the risk for major intracranial haemorrhage.⁷⁹⁻⁸² Pharmacological thromboprophylaxis in brain tumour patients should be initiated within 24 hours after surgery.⁸³ Patients affected by other cancers undergoing major surgery should receive prophylactic treatment, preferably with LMWH for 7-10 days after standard surgery, but up to 1 month in cases of major abdominal or pelvic surgery.^{79,80} For brain tumour patients undergoing a neurosurgical intervention, the optimal duration of prophylaxis has not been defined. Whether the recommendations regarding prolonged use of primary

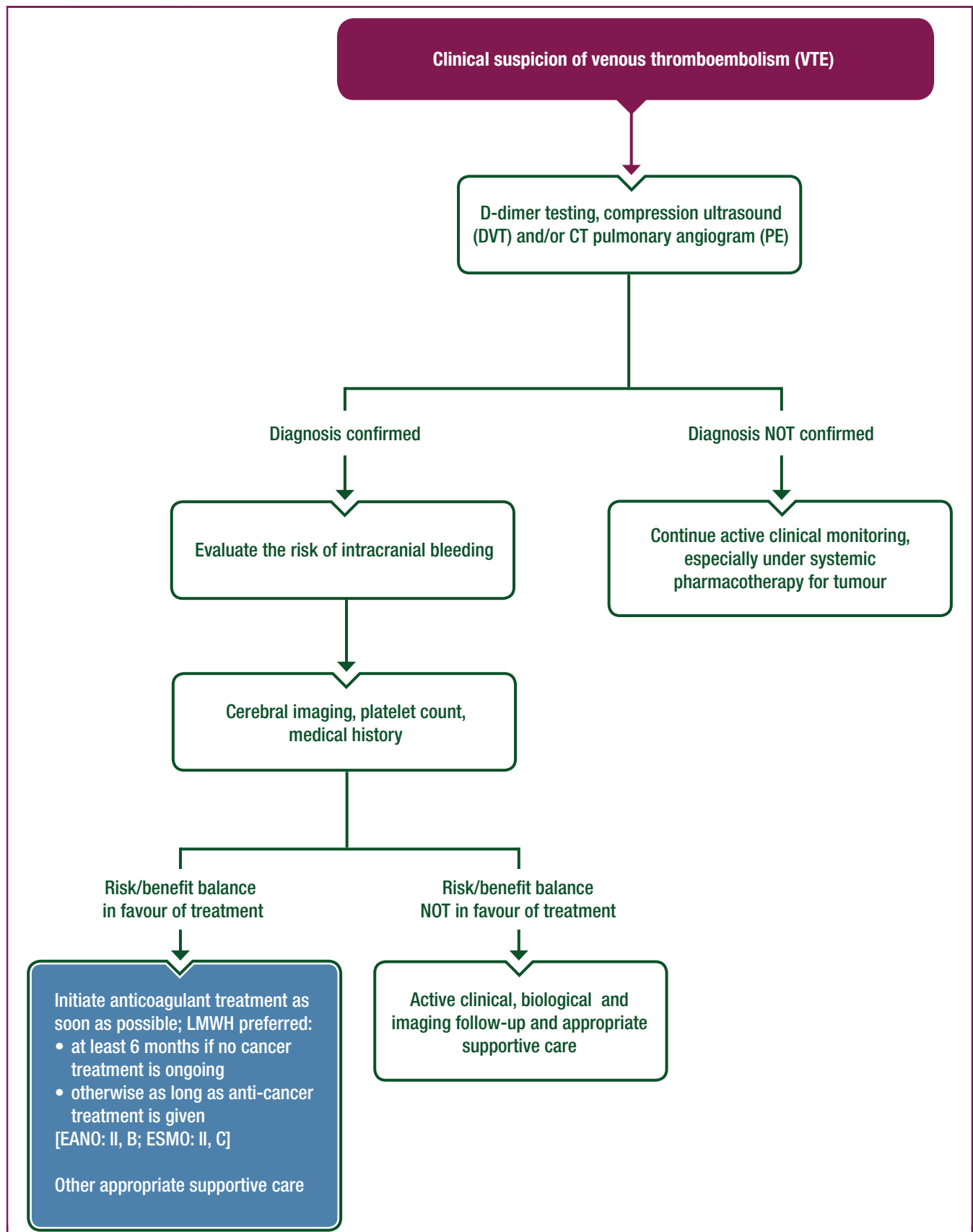


Figure 3. Clinical management of venous thromboembolism in patients with brain tumours.

CT, computer tomography; DVT, deep vein thrombosis; LMWH, low-molecular weight heparin; PE, pulmonary embolism; VTE, venous thromboembolism.

thromboprophylaxis beyond hospital discharge for up to 1 month can be extrapolated to patients with brain tumours upon surgery remains therefore elusive. Only one randomised trial explored the role of LMWH for primary prevention of VTE in patients with newly-diagnosed grade III or grade IV glioma, but no firm conclusion could be drawn as the trial was stopped prematurely.⁸⁴

Two randomised placebo-controlled trials, AVERT and CASSINI, evaluated the efficacy and safety of primary prophylaxis with a direct oral anticoagulant (DOAC) for 6 months in ambulatory patients at intermediate to high risk of VTE.^{85,86} Pooled analyses demonstrate a relative risk reduction of VTE by 45% and low risk of major bleeding.⁸⁷ Patients with primary brain tumours or brain metastasis only were eligible in the AVERT study, comparing apixaban 2.5 mg twice daily with placebo. OS did not differ between groups receiving primary thromboprophylaxis with DOAC versus placebo. More data are needed to draw firm conclusions and to demonstrate the clinical benefit and safety of primary thromboprophylaxis with a DOAC in patients with primary and secondary brain tumours.

Treatment of VTE

Once the diagnosis of VTE has been confirmed, anticoagulation should start immediately. Parenteral anticoagulants (e.g. LMWH) are recommended for treatment and secondary prevention of VTE in patients with active cancer for 3-6 months, including those with brain tumours.⁸⁸⁻⁹³ LMWHs are more effective in reducing the risk of VTE recurrence than vitamin K antagonists without increasing the risk of major bleeding.⁸⁹

The incidence of intracranial haemorrhage in patients treated with therapeutic anticoagulation may be increased for glioma patients.⁹⁴ In glioblastoma patients, an incidence of intracranial haemorrhage of 3%-5% has been reported under prophylactic LMWH.^{84,95,96} In contrast, the risk of intracranial haemorrhage for patients with brain metastases treated with therapeutic anticoagulation is probably not increased.^{64,94,97} The institution of anticoagulation in patients with asymptomatic bleeding on MRI requires a careful risk/benefit assessment. Other risk factors for intracranial haemorrhage should be considered; in particular, anticoagulation should be managed and adjusted to the platelet count.⁹⁸ More detailed information on the management of intracranial haemorrhage is available in the [Supplementary Material](https://doi.org/10.1016/j.annonc.2020.11.003), available at <https://doi.org/10.1016/j.annonc.2020.11.003>.

The evidence for duration of treatment >6 months is scarce.^{99,100} After 6 months of treatment, anticoagulation can be stopped in patients who are in complete remission and should be continued in patients with active cancer or those receiving ongoing anticancer treatment.

The efficacy and safety of DOAC versus LMWH for treatment and secondary prevention of VTE in patients with cancer have been investigated in two randomised controlled trials (RCTs), the HOKUSAI VTE cancer (edoxaban versus dalteparin) and the SELECT-D study (rivaroxaban

versus dalteparin).^{101,102} Edoxaban and rivaroxaban were equally or slightly more effective for the prevention of VTE recurrence but conferred a higher risk of major bleeding than dalteparin, particularly in patients with gastrointestinal cancer. Brain tumour patients were underrepresented or not included in these two trials; thus, more research is needed to provide insight into the efficacy and safety of DOAC in patients with brain tumours. In the absence of specific data for the cancer patient population, intracranial venous sinus occlusion should be treated with LMWH, although high quality evidence is missing.¹⁰³

Ischaemic stroke

The risk of stroke in cancer patients is higher than in the general population.¹⁰⁴⁻¹⁰⁶ In glioma patients, strokes are not associated with the WHO grade and do not differ between histological subtypes.¹⁰⁷ In primary brain tumour patients, the main causes of ischaemic stroke include postoperative ischaemic stroke and stroke as a possible late consequence of RT and hypercoagulable states.^{107,108} Bevacizumab may moderately increase the risk of stroke.^{71-73,107} No specific data are available on brain metastasis patients. In glioma patients, 15%-25% of strokes are asymptomatic and are diagnosed on MRI only.^{109,110} The interpretation of brain MRI can be challenging when changes in diffusion-weighted imaging are close to the tumour area where post-therapeutic changes remain a differential diagnosis.^{107,108}

The management depends on the underlying cause, the neurological condition of the patient and the prognosis associated with the brain tumour. Patients with malignant intracranial tumours were commonly excluded from trials evaluating i.v. or local thrombolysis. The use of thrombolytic agents such as recombinant tissue plasminogen activator in patients with malignant brain tumours can therefore not be generally recommended. Antiplatelet drugs should be considered for secondary prophylaxis as in the general ischaemic stroke patient population.

Other vascular complications

Other vascular complications include thrombotic microangiopathy, posterior reversible leukoencephalopathy syndrome, radiation-induced vasculopathy including stroke-like migraine attacks after RT (SMART) syndrome, moyamoya-like vasculopathy and microbleeds.

Recommendations

- Routine primary thromboprophylaxis in the ambulatory setting is not recommended for all brain tumour patients [EANO: IV, n/a; ESMO: V, C].
- Primary thromboprophylaxis should be considered for hospitalised brain cancer patients with acute medical illness or immobilisation [EANO: IV, C; ESMO: V, C].
- LMWH should be considered as the first line of primary thromboprophylaxis of VTE for patients with brain tumours after brain tumour surgery [EANO: II, B; ESMO: II, C].

- Primary thromboprophylaxis should be initiated within 24 hours after brain surgery for brain tumour patients [EANO: III, C; ESMO: V, C].
- Therapeutic doses of LMWH should be used for treatment of VTE in brain tumour patients [EANO: IV, C; ESMO: V, C].
- DOAC (edoxaban and rivaroxaban) should not be routinely considered as an alternative for brain tumour patients with VTE [EANO: IV, C; ESMO: V, C].
- The duration of therapeutic anticoagulation for treatment of VTE should be 6 months for brain tumour patients who are in complete remission and should be prolonged in patients with active cancer or those receiving ongoing anti-cancer treatment [EANO: IV, C; ESMO: V, C].
- Antiplatelet drugs should be considered for secondary prophylaxis of stroke in patients with brain tumours unless there is an underlying cause such as atrial fibrillation that requires therapeutic anticoagulation according to standard stroke guidelines. [EANO: IV, n/a; ESMO: V, C].

The management of metastatic spinal cord compression as well as recommendations regarding supportive therapy and end-of life care in brain tumour patients are described in the [Supplementary Material](https://doi.org/10.1016/j.annonc.2020.11.003), available at <https://doi.org/10.1016/j.annonc.2020.11.003>.

METHODOLOGY

These clinical practice guidelines were developed in accordance with the ESMO standard operating procedures for Clinical Practice Guidelines development (<http://www.esmo.org/Guidelines/ESMO-Guidelines-Methodology>). The relevant literature has been selected by the expert authors. Levels of evidence and grades of recommendation have been applied using the system shown in [Supplementary Tables S3, S4 and S5](https://doi.org/10.1016/j.annonc.2020.11.003), available at <https://doi.org/10.1016/j.annonc.2020.11.003>.^{111,112} Statements without grading were considered justified standard clinical practice by the experts and the EANO Faculty and ESMO Faculty. This manuscript has been subjected to an anonymous peer review process.

ACKNOWLEDGEMENTS

The authors thank Dr Franziska Schlieter for editorial assistance. The ESMO Guidelines Committee thank the EANO Faculty, the ESMO Faculty and other experts who provided critical reviews of these ESMO Clinical Practice Guidelines. They also thank the European Cancer Patient Coalition and the following patient organisation for their review: The Glioma Center.

FUNDING

No external funding has been received for the preparation of these guidelines. Production costs have been covered by ESMO from central funds.

DISCLOSURE

PR has received honoraria for lectures or advisory board participation from Bristol-Myers Squibb, Covagen, Debiopharm, Merck Sharp and Dohme, Novocure, QED and Virometix and research support from Merck Sharp and Dohme; AP has received honoraria for advisory board participation from AbbVie; ELR has received research grants from Mundipharma and Amgen and honoraria for lectures or advisory board participation from AbbVie, Daiichi Sankyo, Mundipharma and Novartis; MW has received research grants from AbbVie, Adastral Pharmaceuticals, Bayer, Merck, Sharp and Dohme, Merck (EMD), Novocure, OGD2 Pharma, PIQR Therapeutics and Roche and honoraria for lectures or advisory board participation or consulting from AbbVie, Bristol-Myers Squibb, Celgene, Merck, Sharp and Dohme, Merck (EMD), Novocure, Orbus, Pfizer, Progenics, Roche and Tocagen; CA has received honoraria for lectures, consultancy or advisory board participation from Bayer, Bristol-Myers Squibb, Boehringer Ingelheim, Daiichi Sankyo, Pfizer and Sanofi; EC-JM has reported advisory board and/or has received honoraria from Merck Serono, Accuray and Brainlab and research grants from Merck Serono and AstraZeneca; RG has received honoraria for lectures, consultancy or advisory board participation from Kiowa Kirin, Angelini Pharma, Bristol-Myers Squibb, Boehringer Ingelheim, Merck, Sharp and Dohme, Roche and AstraZeneca; KJ has reported advisory board and/or honoraria for presentations for Merck, Sharp and Dohme, Helsinn, Tesaro, Amgen, Hexal, Pfizer, Voluntas and Kreussler Pharma; RN has received research support from Merck, Sharp and Dohme, Chugai and Eisai and honoraria for lectures, consultancy or advisory board participation from Chugai, Eisai, ONO, AbbVie, Daiichi Sankyo and Novocure; RR has received honoraria for lectures or advisory board participation from UCB and Novocure; MP has received research support from Boehringer Ingelheim, GlaxoSmithKline, Merck, Sharp and Dohme and Roche and honoraria for lectures, consultancy or advisory board participation from Bristol-Myers Squibb, Novartis, Gerson Lehrman Group, CMC Contrast, GlaxoSmithKline, Mundipharma, Roche, AstraZeneca, AbbVie, Lilly, MEDahead, Daiichi Sankyo and Merck, Sharp and Dohme; MC, FW, SV, MJB, YKH and WW have declared no conflicts of interest.

REFERENCES

1. Le Rhun E, Weller M, Brandsma D, et al. EANO-ESMO Clinical Practice Guidelines for diagnosis, treatment and follow-up of patients with leptomeningeal metastasis from solid tumours. *Ann Oncol*. 2017;28:iv84-iv99.
2. Comelli I, Lippi G, Campana V, et al. Clinical presentation and epidemiology of brain tumors firstly diagnosed in adults in the emergency department: a 10-year, single center retrospective study. *Ann Transl Med*. 2017;5:269.
3. Nayak L, DeAngelis LM, Brandes AA, et al. The Neurologic Assessment in Neuro-Oncology (NANO) scale: a tool to assess neurologic function for integration into the Response Assessment in Neuro-Oncology (RANO) criteria. *Neuro Oncol*. 2017;19:625-635.

4. Reardon DA, Galanis E, DeGroot JF, et al. Clinical trial end points for high-grade glioma: the evolving landscape. *Neuro Oncol.* 2011;13:353-361.
5. Hempen C, Weiss E, Hess CF. Dexamethasone treatment in patients with brain metastases and primary brain tumors: do the benefits outweigh the side-effects? *Support Care Cancer.* 2002;10:322-328.
6. Roth P, Regli L, Tonder M, Weller M. Tumor-associated edema in brain cancer patients: pathogenesis and management. *Expert Rev Anticancer Ther.* 2013;13:1319-1325.
7. Ryan R, Booth S, Price S. Corticosteroid-use in primary and secondary brain tumour patients: a review. *J Neurooncol.* 2012;106:449-459.
8. Vecht CJ, Hovestadt A, Verbiest HB, et al. Dose-effect relationship of dexamethasone on Karnofsky performance in metastatic brain tumors: a randomized study of doses of 4, 8, and 16 mg per day. *Neurology.* 1994;44:675-680.
9. Kirste S, Treier M, Wehrle SJ, et al. Boswellia serrata acts on cerebral edema in patients irradiated for brain tumors: a prospective, randomized, placebo-controlled, double-blind pilot trial. *Cancer.* 2011;117:3788-3795.
10. Carpentier AF, Ferrari D, Bailon O, et al. Steroid-sparing effects of angiotensin-II inhibitors in glioblastoma patients. *Eur J Neurol.* 2012;19:1337-1342.
11. Recht L, Mechtler LL, Wong ET, et al. Steroid-sparing effect of corticosteroid acetate in peritumoral cerebral edema is associated with improvement in steroid-induced myopathy. *J Clin Oncol.* 2013;31:1182-1187.
12. Senders JT, Muskens IS, Cote DJ, et al. Thirty-day outcomes after craniotomy for primary malignant brain tumors: a national surgical quality improvement program analysis. *Neurosurgery.* 2018;83:1249-1259.
13. Arbour KC, Mezquita L, Long N, et al. Impact of baseline steroids on efficacy of programmed cell death-1 and programmed death-ligand 1 blockade in patients with non-small-cell lung cancer. *J Clin Oncol.* 2018;36:2872-2878.
14. Marantidou A, Levy C, Duquesne A, et al. Steroid requirements during radiotherapy for malignant gliomas. *J Neurooncol.* 2010;100:89-94.
15. Pitter KL, Tamagno I, Alikhanyan K, et al. Corticosteroids compromise survival in glioblastoma. *Brain.* 2016;139:1458-1471.
16. Okada H, Weller M, Huang R, et al. Immunotherapy response assessment in neuro-oncology: a report of the RANO working group. *Lancet Oncol.* 2015;16:e534-e542.
17. Rulli E, Legramandi L, Salvati L, Mandala M. The impact of targeted therapies and immunotherapy in melanoma brain metastases: a systematic review and meta-analysis. *Cancer.* 2019;125:3776-3789.
18. Roth P, Wick W, Weller M. Steroids in neurooncology: actions, indications, side-effects. *Curr Opin Neurol.* 2010;23:597-602.
19. van Breemen MS, Wilms EB, Vecht CJ. Epilepsy in patients with brain tumors: epidemiology, mechanisms, and management. *Lancet Neurol.* 2007;6:421-430.
20. Chen H, Judkins J, Thomas C, et al. Mutant IDH1 and seizures in patients with glioma. *Neurology.* 2017;88:1805-1813.
21. Wirsching HG, Morel C, Gmur C, et al. Predicting outcome of epilepsy after meningioma resection. *Neuro Oncol.* 2016;18:1002-1010.
22. Wu A, Weingart JD, Gallia GL, et al. Risk factors for preoperative seizures and loss of seizure control in patients undergoing surgery for metastatic brain tumors. *World Neurosurg.* 2017;104:120-128.
23. Fisher RS, Cross JH, French JA, et al. Operational classification of seizure types by the International League Against Epilepsy: position paper of the ILAE commission for classification and terminology. *Epilepsia.* 2017;58:522-530.
24. Avila EK, Chamberlain M, Schiff D, et al. Seizure control as a new metric in assessing efficacy of tumor treatment in low-grade glioma trials. *Neuro Oncol.* 2017;19:12-21.
25. Weller M, Stupp R, Wick W. Epilepsy meets cancer: when, why, and what to do about it? *Lancet Oncol.* 2012;13:e375-382.
26. Ruda R, Soffietti R. What is new in the management of epilepsy in gliomas? *Curr Treat Options Neurol.* 2015;17:351.
27. Vecht C, Royer-Perron L, Houillier C, Huberfeld G. Seizures and anti-convulsants in brain tumours: frequency, mechanisms and antiepileptic management. *Curr Pharm Des.* 2017;23:6464-6487.
28. Rossetti AO, Jeckelmann S, Novy J, et al. Levetiracetam and pregabalin for antiepileptic monotherapy in patients with primary brain tumors. A phase II randomized study. *Neuro Oncol.* 2014;16:584-588.
29. Ruda R, Pellerino A, Franchino F, et al. Lacosamide in patients with gliomas and uncontrolled seizures: results from an observational study. *J Neurooncol.* 2018;136:105-114.
30. Aaronson NK, Taphoorn MJ, Heimans JJ, et al. Compromised health-related quality of life in patients with low-grade glioma. *J Clin Oncol.* 2011;29:4430-4435.
31. Waagemans ML, van Nieuwenhuizen D, Dijkstra M, et al. Long-term impact of cognitive deficits and epilepsy on quality of life in patients with low-grade meningiomas. *Neurosurgery.* 2011;69:72-78. discussion 78-79.
32. Tucha O, Smely C, Preier M, Lange KW. Cognitive deficits before treatment among patients with brain tumors. *Neurosurgery.* 2000;47:324-333. discussion 333-324.
33. Meyers CA, Smith JA, Bezjak A, et al. Neurocognitive function and progression in patients with brain metastases treated with whole-brain radiation and motexafin gadolinium: results of a randomized phase III trial. *J Clin Oncol.* 2004;22:157-165.
34. van Nieuwenhuizen D, Ambachtsheer N, Heimans JJ, et al. Neurocognitive functioning and health-related quality of life in patients with radiologically suspected meningiomas. *J Neurooncol.* 2013;113:433-440.
35. Wefel JS, Noll KR, Scheurer ME. Neurocognitive functioning and genetic variation in patients with primary brain tumours. *Lancet Oncol.* 2016;17:e97-e108.
36. Talacchi A, Santini B, Savazzi S, Gerosa M. Cognitive effects of tumour and surgical treatment in glioma patients. *J Neurooncol.* 2011;103:541-549.
37. Sheline GE, Wara WM, Smith V. Therapeutic irradiation and brain injury. *Int J Radiat Oncol Biol Phys.* 1980;6:1215-1228.
38. Taphoorn MJ, Klein M. Cognitive deficits in adult patients with brain tumours. *Lancet Neurol.* 2004;3:159-168.
39. Monje ML, Mizumatsu S, Fike JR, Palmer TD. Irradiation induces neural precursor-cell dysfunction. *Nat Med.* 2002;8:955-962.
40. Schagen SB, Klein M, Reijneveld JC, et al. Monitoring and optimising cognitive function in cancer patients: present knowledge and future directions. *EJC Suppl.* 2014;12:29-40.
41. Schagen SB, Wefel JS. Chemotherapy-related changes in cognitive functioning. *EJC Suppl.* 2013;11:225-232.
42. Gehring K, Taphoorn MJ, Sitskoorn MM, Aaronson NK. Predictors of subjective versus objective cognitive functioning in patients with stable grades II and III glioma. *Neurooncol Pract.* 2015;2:20-31.
43. De Witt Hamer PC, Robles SG, Zwiderman AH, et al. Impact of intraoperative stimulation brain mapping on glioma surgery outcome: a meta-analysis. *J Clin Oncol.* 2012;30:2559-2565.
44. Gondi V, Tolakanahalli R, Mehta MP, et al. Hippocampal-sparing whole-brain radiotherapy: a "how-to" technique using helical tomotherapy and linear accelerator-based intensity-modulated radiotherapy. *Int J Radiat Oncol Biol Phys.* 2010;78:1244-1252.
45. Klein M, Heimans JJ, Aaronson NK, et al. Effect of radiotherapy and other treatment-related factors on mid-term to long-term cognitive sequelae in low-grade gliomas: a comparative study. *Lancet.* 2002;360:1361-1368.
46. Habets EJ, Dirven L, Wiggeraad RG, et al. Neurocognitive functioning and health-related quality of life in patients treated with stereotactic radiotherapy for brain metastases: a prospective study. *Neuro Oncol.* 2016;18:435-444.
47. Sherman JC, Colvin MK, Mancuso SM, et al. Neurocognitive effects of proton radiation therapy in adults with low-grade glioma. *J Neurooncol.* 2016;126:157-164.
48. Thurin E, Nystrom PW, Smits A, et al. Proton therapy for low-grade gliomas in adults: a systematic review. *Clin Neurol Neurosurg.* 2018;174:233-238.
49. Klein M, Engelberts NH, van der Ploeg HM, et al. Epilepsy in low-grade gliomas: the impact on cognitive function and quality of life. *Ann Neurol.* 2003;54:514-520.

50. Meyers CA, Weitzner MA, Valentine AD, Levin VA. Methylphenidate therapy improves cognition, mood, and function of brain tumor patients. *J Clin Oncol*. 1998;16:2522-2527.
51. Shaw EG, Rosdhal R, D'Agostino RB Jr, et al. Phase II study of donepezil in irradiated brain tumor patients: effect on cognitive function, mood, and quality of life. *J Clin Oncol*. 2006;24:1415-1420.
52. Rapp SR, Case LD, Peiffer A, et al. Donepezil for irradiated brain tumor survivors: a phase III randomized placebo-controlled clinical trial. *J Clin Oncol*. 2015;33:1653-1659.
53. Brown PD, Pugh S, Laack NN, et al. Memantine for the prevention of cognitive dysfunction in patients receiving whole-brain radiotherapy: a randomized, double-blind, placebo-controlled trial. *Neuro Oncol*. 2013;15:1429-1437.
54. Gehring K, Patwardhan SY, Collins R, et al. A randomized trial on the efficacy of methylphenidate and modafinil for improving cognitive functioning and symptoms in patients with a primary brain tumor. *J Neurooncol*. 2012;107:165-174.
55. Gehring K, Sitskoorn MM, Aaronson NK, Taphoorn MJ. Interventions for cognitive deficits in adults with brain tumours. *Lancet Neurol*. 2008;7:548-560.
56. Zucchella C, Capone A, Codella V, et al. Cognitive rehabilitation for early post-surgery in patients affected by primary brain tumor: a randomized, controlled trial. *J Neurooncol*. 2013;114:93-100.
57. Yang S, Chun MH, Son YR. Effect of virtual reality on cognitive dysfunction in patients with brain tumor. *Ann Rehabil Med*. 2014;38:726-733.
58. Gehring K, Sitskoorn MM, Gundy CM, et al. Cognitive rehabilitation in patients with gliomas: a randomized, controlled trial. *J Clin Oncol*. 2009;27:3712-3722.
59. Walker AJ, Card TR, West J, et al. Incidence of venous thromboembolism in patients with cancer - a cohort study using linked United Kingdom databases. *Eur J Cancer*. 2013;49:1404-1413.
60. Petterson TM, Marks RS, Ashrani AA, et al. Risk of site-specific cancer in incident venous thromboembolism: a population-based study. *Thromb Res*. 2015;135:472-478.
61. Edwin NC, Khoury MN, Sohal D, et al. Recurrent venous thromboembolism in glioblastoma. *Thromb Res*. 2016;137:184-188.
62. Yust-Katz S, Mandel JJ, Wu J, et al. Venous thromboembolism (VTE) and glioblastoma. *J Neurooncol*. 2015;124:87-94.
63. Le Rhun E, Genbrugge E, Stupp R, et al. Associations of anticoagulant use with outcome in newly diagnosed glioblastoma. *Eur J Cancer*. 2018;101:95-104.
64. Donato J, Campigotto F, Uhlmann EJ, et al. Intracranial hemorrhage in patients with brain metastases treated with therapeutic enoxaparin: a matched cohort study. *Blood*. 2015;126:494-499.
65. Liebman HA, O'Connell C. Incidental venous thromboembolic events in cancer patients: what we know in 2016. *Thromb Res*. 2016;140(suppl 1):S18-S20.
66. Riedl J, Preusser M, Nazari PM, et al. Podoplanin expression in primary brain tumors induces platelet aggregation and increases risk of venous thromboembolism. *Blood*. 2017;129:1831-1839.
67. Thaler J, Ay C, Kaider A, et al. Biomarkers predictive of venous thromboembolism in patients with newly diagnosed high-grade gliomas. *Neuro Oncol*. 2014;16:1645-1651.
68. Mir Seyed Nazari P, Riedl J, Pabinger I, Ay C. The role of podoplanin in cancer-associated thrombosis. *Thromb Res*. 2018;164(suppl 1):S34-S39.
69. Ay C, Pabinger I, Cohen AT. Cancer-associated venous thromboembolism: burden, mechanisms, and management. *Thromb Haemost*. 2017;117:219-230.
70. Nalluri SR, Chu D, Keresztes R, et al. Risk of venous thromboembolism with the angiogenesis inhibitor bevacizumab in cancer patients: a meta-analysis. *JAMA*. 2008;300:2277-2285.
71. Chinot OL, Wick W, Mason W, et al. Bevacizumab plus radiotherapy-temozolomide for newly diagnosed glioblastoma. *N Engl J Med*. 2014;370:709-722.
72. Gilbert MR, Sulman EP, Mehta MP. Bevacizumab for newly diagnosed glioblastoma. *N Engl J Med*. 2014;370:2048-2049.
73. Wick W, Gorlia T, Bendszus M, et al. Lomustine and bevacizumab in progressive glioblastoma. *N Engl J Med*. 2017;377:1954-1963.
74. O'Connell CL, Boswell WD, Duddalwar V, et al. Unsuspected pulmonary emboli in cancer patients: clinical correlates and relevance. *J Clin Oncol*. 2006;24:4928-4932.
75. O'Connell C. Incidentally found pulmonary embolism: what's the clinician to do? *Hematology Am Soc Hematol Educ Program*. 2015;2015:197-201.
76. Righini M, Le Gal G, De Lucia S, et al. Clinical usefulness of D-dimer testing in cancer patients with suspected pulmonary embolism. *Thromb Haemost*. 2006;95:715-719.
77. Iorio A, Agnelli G. Low-molecular-weight and unfractionated heparin for prevention of venous thromboembolism in neurosurgery: a meta-analysis. *Arch Intern Med*. 2000;160:2327-2332.
78. Marras LC, Geerts WH, Perry JR. The risk of venous thromboembolism is increased throughout the course of malignant glioma: an evidence-based review. *Cancer*. 2000;89:640-646.
79. Lyman GH, Bohlke K, Khorana AA, et al. Venous thromboembolism prophylaxis and treatment in patients with cancer: American Society of Clinical Oncology Clinical Practice Guideline update 2014. *J Clin Oncol*. 2015;33:654-656.
80. Mandala M, Falanga A, Roila F, Group EGW. Management of venous thromboembolism (VTE) in cancer patients: ESMO Clinical Practice Guidelines. *Ann Oncol*. 2011;22(Suppl 6):vi85-vi92.
81. Semrad TJ, O'Donnell R, Wun T, et al. Epidemiology of venous thromboembolism in 9489 patients with malignant glioma. *J Neurosurg*. 2007;106:601-608.
82. Gerber DE, Grossman SA, Streiff MB. Management of venous thromboembolism in patients with primary and metastatic brain tumors. *J Clin Oncol*. 2006;24:1310-1318.
83. Agnelli G, Piovella F, Buoncristiani P, et al. Enoxaparin plus compression stockings compared with compression stockings alone in the prevention of venous thromboembolism after elective neurosurgery. *N Engl J Med*. 1998;339:80-85.
84. Perry JR, Julian JA, Laperriere NJ, et al. PRODIGE: a randomized placebo-controlled trial of dalteparin low-molecular-weight heparin thromboprophylaxis in patients with newly diagnosed malignant glioma. *J Thromb Haemost*. 2010;8:1959-1965.
85. Carrier M, Abou-Nassar K, Mallick R, et al. Apixaban to prevent venous thromboembolism in patients with cancer. *N Engl J Med*. 2019;380:711-719.
86. Khorana AA, Soff GA, Kakkar AK, et al. Rivaroxaban for thromboprophylaxis in high-risk ambulatory patients with cancer. *N Engl J Med*. 2019;380:720-728.
87. Wang TF, Zwicker JI, Ay C, et al. The use of direct oral anticoagulants for primary thromboprophylaxis in ambulatory cancer patients: guidance from the SSC of the ISTH. *J Thromb Haemost*. 2019;17(10):1772-1778.
88. Ay C, Kamphuisen PW, Agnelli G. Antithrombotic therapy for prophylaxis and treatment of venous thromboembolism in patients with cancer: review of the literature on current practice and emerging options. *ESMO Open*. 2017;2:e000188.
89. Lee AY, Levine MN, Baker RI, et al. Low-molecular-weight heparin versus a coumarin for the prevention of recurrent venous thromboembolism in patients with cancer. *N Engl J Med*. 2003;349:146-153.
90. Meyer G, Marjanovic Z, Valcke J, et al. Comparison of low-molecular-weight heparin and warfarin for the secondary prevention of venous thromboembolism in patients with cancer: a randomized controlled study. *Arch Intern Med*. 2002;162:1729-1735.
91. Deitcher SR, Kessler CM, Merli G, et al. Secondary prevention of venous thromboembolic events in patients with active cancer: enoxaparin alone versus initial enoxaparin followed by warfarin for a 180-day period. *Clin Appl Thromb Hemost*. 2006;12:389-396.
92. Lee AYY, Kamphuisen PW, Meyer G, et al. Tinzaparin vs warfarin for treatment of acute venous thromboembolism in patients with active cancer: a randomized clinical trial. *JAMA*. 2015;314:677-686.
93. Posch F, Konigsbrugge O, Zielinski C, et al. Treatment of venous thromboembolism in patients with cancer: a network meta-analysis comparing efficacy and safety of anticoagulants. *Thromb Res*. 2015;136:582-589.
94. Zwicker JI, Karp Leaf R, Carrier M. A meta-analysis of intracranial hemorrhage in patients with brain tumors receiving therapeutic anticoagulation. *J Thromb Haemost*. 2016;14:1736-1740.

95. Perry SL, Bohlin C, Reardon DA, et al. Tinzaparin prophylaxis against venous thromboembolic complications in brain tumor patients. *J Neurooncol.* 2009;95:129-134.
96. Robins HI, O'Neill A, Gilbert M, et al. Effect of dalteparin and radiation on survival and thromboembolic events in glioblastoma multiforme: a phase II ECOG trial. *Cancer Chemother Pharmacol.* 2008;62:227-233.
97. Hunter BD, Minichiello T, Bent S. Anticoagulation for the treatment of venous thromboembolism in patients with brain metastases: a meta-analysis and systematic review. *J Thromb Thrombolysis.* 2017;44:392-398.
98. Samuelson Bannow BT, Lee A, Khorana AA, et al. Management of cancer-associated thrombosis in patients with thrombocytopenia: guidance from the SSC of the ISTH. *J Thromb Haemost.* 2018;16:1246-1249.
99. Francis CW, Kessler CM, Goldhaber SZ, et al. Treatment of venous thromboembolism in cancer patients with dalteparin for up to 12 months: the DALTECAN Study. *J Thromb Haemost.* 2015;13:1028-1035.
100. Jara-Palomares L, Solier-Lopez A, Elias-Hernandez T, et al. Tinzaparin in cancer associated thrombosis beyond 6months: TICAT study. *Thromb Res.* 2017;157:90-96.
101. Raskob GE, van Es N, Verhamme P, et al. Edoxaban for the treatment of cancer-associated venous thromboembolism. *N Engl J Med.* 2018;378:615-624.
102. Young AM, Marshall A, Thirlwall J, et al. Comparison of an oral factor xa inhibitor with low molecular weight heparin in patients with cancer with venous thromboembolism: results of a randomized trial (SELECT-D). *J Clin Oncol.* 2018;36:2017-2023.
103. Ferro JM, Bousser MG, Canhao P, et al. European Stroke Organization guideline for the diagnosis and treatment of cerebral venous thrombosis - endorsed by the European Academy of Neurology. *Eur J Neurol.* 2017;24:1203-1213.
104. Navi BB, Singer S, Merkle AE, et al. Cryptogenic subtype predicts reduced survival among cancer patients with ischemic stroke. *Stroke.* 2014;45:2292-2297.
105. Selvik HA, Thomassen L, Logallo N, Naess H. Prior cancer in patients with ischemic stroke: the Bergen NORSTROKE study. *J Stroke Cerebrovasc Dis.* 2014;23:919-925.
106. De Stefano V. Arterial thrombosis and cancer: the neglected side of the coin of Trousseau syndrome. *Haematologica.* 2018;103:1419-1421.
107. Seidel C, Hentschel B, Simon M, et al. A comprehensive analysis of vascular complications in 3,889 glioma patients from the German Glioma Network. *J Neurol.* 2013;260:847-855.
108. Obeid M, Ulane C, Rosenfeld S. Pearls & Oysters: large vessel ischemic stroke secondary to glioblastoma multiforme. *Neurology.* 2010;74:e50-51.
109. Kreis TN, Toothaker T, Karimi S, DeAngelis LM. Ischemic stroke in patients with primary brain tumors. *Neurology.* 2008;70:2314-2320.
110. Kamiya-Matsuoka C, Cachia D, Yust-Katz S, et al. Ischemic stroke in patients with gliomas at The University of Texas-M.D. Anderson Cancer Center. *J Neurooncol.* 2015;125:143-148.
111. Brainin M, Barnes M, Baron JC, et al. Guidance for the preparation of neurological management guidelines by EFNS scientific task forces—revised recommendations 2004. *Eur J Neurol.* 2004;11:577-581.
112. Dykewicz CA, Centers for Disease Control and Prevention, Infectious Diseases Society of America, American Society of Blood and Marrow Transplantation. Summary of the guidelines for preventing opportunistic infections among hematopoietic stem cell transplant recipients. *Clin Infect Dis.* 2001;33:139-144 (adapted from: Gross PA, Barrett TL, Dellinger EP, et al. Purpose of quality standards for infectious diseases. *Clin Infect Dis.* 1994;19:1421).