



**Universiteit
Leiden**
The Netherlands

Spontaneous twin anemia polycythemia sequence: diagnosis, management, and outcome in an international cohort of 249 cases

Tollenaar, L.S.A.; Slaghekke, F.; Lewi, L.; Colmant, C.; Lanna, M.; Weingertner, A.S.; ... ; Lopriore, E.

Citation

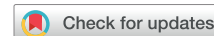Tollenaar, L. S. A., Slaghekke, F., Lewi, L., Colmant, C., Lanna, M., Weingertner, A. S., ... Lopriore, E. (2021). Spontaneous twin anemia polycythemia sequence: diagnosis, management, and outcome in an international cohort of 249 cases. *American Journal Of Obstetrics And Gynecology*, 224(2), 213.e1-213.e11. doi:10.1016/j.ajog.2020.07.041

Version: Publisher's Version
License: [Creative Commons CC BY 4.0 license](https://creativecommons.org/licenses/by/4.0/)
Downloaded from: <https://hdl.handle.net/1887/3270933>

Note: To cite this publication please use the final published version (if applicable).

OBSTETRICS

Spontaneous twin anemia polycythemia sequence: diagnosis, management, and outcome in an international cohort of 249 cases



Lisanne S. A. Tollenaar, BSc; Femke Slaghekke, MD, PhD; Liesbeth Lewi, MD, PhD; Claire Colmant, MD, PhD; Mariano Lanna, MD, PhD; Anne Sophie Weingertner, MD, PhD; Greg Ryan, MB; Silvia Arévalo, MD, PhD; Philipp Klaritsch, MD, PhD; Manuela Tavares de Sousa, MD, PhD; Asma Khalil, MD, PhD; Ramesha Papanna, MD, PhD; Glenn J. Gardener, MD, PhD; Elisa Bevilacqua, MD, PhD; Kirill V. Kostyukov, MD, PhD; Mert O. Bahtiyar, MD, PhD; Mark D. Kilby, MD, DSc; Eleonor Tiblad, MD, PhD; Dick Oepkes, MD, PhD; Enrico Lopriore, MD, PhD

BACKGROUND: Twin anemia polycythemia sequence is a chronic form of unbalanced fetofetal transfusion through minuscule placental anastomoses in monochorionic twins, leading to anemia in the donor and polycythemia in the recipient. Owing to the low incidence of twin anemia polycythemia sequence, data on diagnosis, management, and outcome are limited.

OBJECTIVE: This study aimed to investigate the diagnosis, management, and outcome in a large international cohort of spontaneous twin anemia polycythemia sequence.

STUDY DESIGN: Data from the international twin anemia polycythemia sequence registry, retrospectively collected between 2014 and 2019, were used for this study. A total of 17 fetal therapy centers contributed to the data collection. The primary outcomes were perinatal mortality and severe neonatal morbidity. Secondary outcomes included a risk factor analysis for perinatal mortality and severe neonatal morbidity.

RESULTS: A total of 249 cases of spontaneous twin anemia polycythemia sequence were included in this study, 219 (88%) of which were diagnosed antenatally and 30 (12%) postnatally. Twin anemia polycythemia sequence was diagnosed antenatally at a median gestational age of 23.7 weeks (interquartile range, 9.7–28.8; range, 15.1–35.3). Antenatal management included laser surgery in 39% (86 of 219), expectant management in 23% (51 of 219), delivery in 16% (34 of 219), intrauterine transfusion (with partial exchange transfusion) in 12% (26 of 219), selective feticide in 8% (18 of 219), and termination of pregnancy in 1% (3 of 219) of cases. Perinatal mortality rate was 15% (72 of 493) for the total group, 22% (54 of 243) for donors, and 7% (18 of 242) for recipients

($P < .001$). Severe neonatal morbidity occurred in 33% (141 of 432) of twins with twin anemia polycythemia sequence and was similar for donors (32%; 63 of 196) and recipients (33%; 75 of 228) ($P = .628$). Independent risk factors for spontaneous perinatal mortality were donor status (odds ratio, 3.8; 95% confidence interval, 1.9–7.5; $P < .001$), antenatal twin anemia polycythemia sequence stage (odds ratio, 6.3; 95% confidence interval, 1.4–27.8; $P = .016$ [stage 2]; odds ratio, 9.6; 95% confidence interval, 2.1–45.5; $P = .005$ [stage 3]; odds ratio, 20.9; 95% confidence interval, 3.0–146.4; $P = .002$ [stage 4]), and gestational age at birth (odds ratio, 0.8; 95% confidence interval, 0.7–0.9; $P = .001$). Independent risk factors for severe neonatal morbidity were antenatal twin anemia polycythemia sequence stage 4 (odds ratio, 7.9; 95% confidence interval, 1.4–43.3; $P = .018$) and gestational age at birth (odds ratio, 1.7; 95% confidence interval, 1.5–2.1, $P < .001$).

CONCLUSION: Spontaneous twin anemia polycythemia sequence can develop at any time in pregnancy from the beginning of the second trimester to the end of the third trimester. Management for twin anemia polycythemia sequence varies considerably, with laser surgery being the most frequent intervention. Perinatal mortality and severe neonatal morbidity were high, the former especially so in the donor twins.

Key words: diagnosis, intrauterine transfusion, laser surgery, management, monochorionic twins, neonatal morbidity, perinatal mortality, registry, twin anemia polycythemia sequence, twin-twin transfusion syndrome

Twin anemia polycythemia sequence (TAPS) is a chronic form of unbalanced fetofetal transfusion through minuscule placental anastomoses in

monochorionic twins, leading to anemia in the TAPS donor and polycythemia in the TAPS recipient.¹ In contrast to twin-twin transfusion syndrome (TTTS), TAPS develops in the absence of twin oligohydramnios-polyhydramnios sequence (TOPS). TAPS can occur spontaneously in up to 5% of monochorionic twins.² The optimal antenatal treatment for TAPS has yet to be determined, but options include expectant management, preterm delivery, intrauterine transfusion (IUT) with or without a partial exchange transfusion (PET), fetoscopic

laser surgery, and selective feticide.^{3,4} Perinatal outcome in TAPS may vary between isolated hemoglobin differences to severe cerebral injury and perinatal death.^{5,6} Because of the low incidence of TAPS, studies investigating perinatal outcome are limited, with current data based on small cohort studies. Limited knowledge on optimal management and short- and long-term outcomes restricts adequate parental counseling and informed decision making. To improve our knowledge on TAPS, we set up the TAPS Registry, a large international collaboration aimed

Cite this article as: Tollenaar LSA, Slaghekke F, Lewi L, et al. Spontaneous twin anemia polycythemia sequence: diagnosis, management, and outcome in an international cohort of 249 cases. *Am J Obstet Gynecol* 2021;224:213.e1-11.

0002-9378

© 2020 The Authors. Published by Elsevier Inc. This is an open access article under the CC BY license (<http://creativecommons.org/licenses/by/4.0/>).
<https://doi.org/10.1016/j.ajog.2020.07.041>

AJOG at a Glance

Why was this study conducted?

This study aimed to investigate the diagnosis, management, and outcome in spontaneous twin anemia polycythemia sequence (TAPS).

Key findings

Spontaneous TAPS can develop from 15 to 35 weeks' gestation. Perinatal mortality occurred in 15% of twins with TAPS and was significantly ($P < .01$) higher in donors than in recipients (22% vs 7%, respectively). Severe neonatal morbidity occurred in 33% of the twins and was strongly predicted by high antenatal TAPS stage and low gestational age at birth.

What does this add to what is known?

This large international study reports that spontaneous TAPS can develop across a wide range of gestation and is associated with high rates of perinatal mortality and severe neonatal morbidity, the former especially so in the donor twins.

at collecting data on diagnosis, treatment, and outcome in TAPS twins.

In this study, the data from this TAPS Registry were used as follows: (1) to examine the characteristics of diagnosis, management, and outcome in twins with spontaneous TAPS, (2) to compare the perinatal outcomes between donors and recipients, and (3) to investigate potential risk factors for adverse perinatal outcomes. To date, TAPS is believed to be a mild form of fetofetal transfusion pathology,⁷ which mainly develops after viable gestation. We hypothesize that spontaneous TAPS may develop earlier in pregnancy and may be associated with higher adverse outcome rates that are currently assumed.

Methods

The TAPS Registry was established in 2014 and used a web-based registry for anonymous data collection (www.tapsregistry.org). Fetal therapy centers across the world were invited to participate. Participating centers were supplied with personal credentials to enter data of their TAPS cases into the online registry. Between 2014 and 2019, 17 fetal therapy centers contributed to the retrospective data collection (Supplemental Table 1).

Monochorionic twin pregnancies diagnosed as having spontaneous TAPS were eligible for this study. Cases with postlaser TAPS (TAPS after incomplete laser for TTTS) were excluded from this study and are described in a separate

study.⁸ Antenatal diagnosis for TAPS was based on discordant middle cerebral artery peak systolic velocity (MCA-PSV) measurements, with an increased MCA-PSV in the TAPS donor, suggestive of fetal anemia, combined with a decreased MCA-PSV measurement in the TAPS recipient, suggestive of fetal polycythemia, and without signs of TOPS.⁹ TAPS was staged according to Slaghekke et al.⁹ In brief, TAPS stage 1 was defined as an MCA-PSV of >1.5 multiples of the median (MoM) in the donor and <1.0 MoM in the recipient. Stage 2 was based on an MCA-PSV of >1.7 for the donor, combined with an MCA-PSV of <0.8 in the recipient. Stage 3 was defined as cardiac compromise of the donor (critically abnormal flow in the umbilical artery, umbilical vein, or ductus venosus). In the case of stage 4, fetal hydrops was seen in the donor twin. In stage 5, fetal demise in one or both twins occurred. TAPS was diagnosed postnatally in cases with an intertwin hemoglobin difference of >8.0 g/dL with at least 1 of the following: a reticulocyte count ratio of >1.7 or the presence of only minuscule vascular anastomoses (diameter of <1 mm) detected through color-dye injection of the placenta.^{10,11}

The following data were retrieved from the medical records: gravidity, parity, location of the placenta, gestational age (GA) at diagnosis, TAPS stage at diagnosis,⁹ the presence of starry-sky liver in the recipient or the difference in

placental echogenicity, and mode of delivery. The following types of management were recorded: expectant management, delivery (defined as a delivery within 7 days after diagnosis), IUT (\pm PET), laser surgery, selective feticide, and termination of pregnancy (TOP). Because TAPS cases can be managed according to different strategies in the same pregnancy, management group assignment was based on the first treatment that was performed. In addition, information on placental color-dye injection was collected, including the type, number, and size of anastomoses. For perinatal outcome, the following parameters were obtained: donor or recipient status, birthweight, hemoglobin and reticulocyte values, treatment with blood transfusion or PET at day 1, presence of severe neonatal morbidities, and occurrence of perinatal mortality.

The primary outcomes were perinatal mortality and severe neonatal morbidity. Perinatal mortality was defined as fetal demise or neonatal death within 28 days after birth. Because fetal demise is intentional in the context of selective feticide or TOP, a distinction is made between spontaneous and intended fetal demise. Severe neonatal morbidity was a composite measurement and defined as the presence of at least 1 of the following, detected within 28 days after birth or before discharge to home: respiratory distress syndrome requiring mechanical ventilation and surfactant, patent ductus arteriosus requiring treatment, necrotizing enterocolitis at \geq stage 2,¹² retinopathy of prematurity at \geq stage 3,¹³ ischemic limb injury, or severe cerebral injury. Severe cerebral injury was diagnosed in case of 1 of the following abnormalities were detected on cerebral imaging: intraventricular hemorrhage at \geq stage 3,¹⁴ ventricular dilatation (including posthemorrhagic ventricular dilatation),¹⁵ cystic periventricular leukomalacia at \geq grade 2,¹⁶ porencephalic or parenchymal cysts, arterial infarction, or other severe cerebral lesions associated with adverse outcome. The following parameters were determined: reticulocyte count ratio, the presence of

severe or mild fetal growth restriction (FGR) (defined as a birthweight at less than the 3rd or 10th percentile, respectively¹⁷) and postnatal TAPS stage.¹⁸ The reticulocyte count ratio was calculated by dividing the highest reticulocyte count (‰) by the lowest reticulocyte count (‰). Reticulocyte counts were obtained from the umbilical cord blood or heel stick or venous puncture of each twin at day 1.

Secondary outcomes included diagnosis- and therapy-related characteristics, hematological and placental characteristics, and a risk factor analysis for spontaneous perinatal mortality and severe neonatal morbidity. For the risk factor analysis for spontaneous mortality, cases with intentional fetal demise due to selective feticide or TOP were excluded. The following parameters were investigated in the univariate risk analysis for spontaneous perinatal mortality: GA at TAPS diagnosis, antenatal TAPS stage, TAPS donor or recipient status, type of antenatal management, and GA at birth. For antenatal TAPS stage, the highest antenatal TAPS stage that was seen during pregnancy was selected. In the case of TAPS stage 5, the highest TAPS stage before stage 5 was used. For the risk factor analysis for severe neonatal morbidity, 2 more parameters were added: severe FGR and the presence of postnatal TAPS.

Statistical analyses were performed using SPSS version 25.0 (IBM, Armonk, New York). The sample size for this study was based on convenience. Data are reported as means±standard deviation or as medians or interquartile ranges (IQRs) or ranges (minimum–maximum), as appropriate. In addition, $P < .05$ indicated statistical significance. Differences between donors and recipients were calculated using the paired t test for normally distributed continuous outcomes and the generalized estimated equation module for categorical outcomes. Potential risk factors were checked for correlation using Spearman's rank test (R). Correlation coefficient R of $>(-)0.7$ was considered to indicate a strong relationship between the factors. Potential risk factors for perinatal mortality and severe neonatal

TABLE 1
Baseline characteristics of spontaneous TAPS twins

	Spontaneous TAPS (N=249 pregnancies, 498 fetuses)
Gravidity	2 (1–3)
Parity	1 (0–1)
Antenatal diagnosis of TAPS	219/249 (88)
Location of placenta ^a	
Anterior	127/236 (54)
Posterior	104/236 (44)
Other	5/236 (2)

Data are presented as n/N (%) or median (IQR).

IQR, interquartile range; TAPS, twin anemia polycythemia sequence.

^a In 13 cases, position of the placenta was unknown. Other types of placental positions included partly anterior and partly posterior (n=2), lateral left (n=2), and lateral right (n=1).

Tollenaar et al. Spontaneous TAPS: diagnosis management and outcome in 249 cases. *Am J Obstet Gynecol* 2021.

morbidity were studied in a univariable logistic regression model. A multivariable logistic regression model was applied to the variables that indicated significant association in the univariable analysis. Results are expressed as odds ratios (ORs) with 95% confidence intervals (CIs).

Results

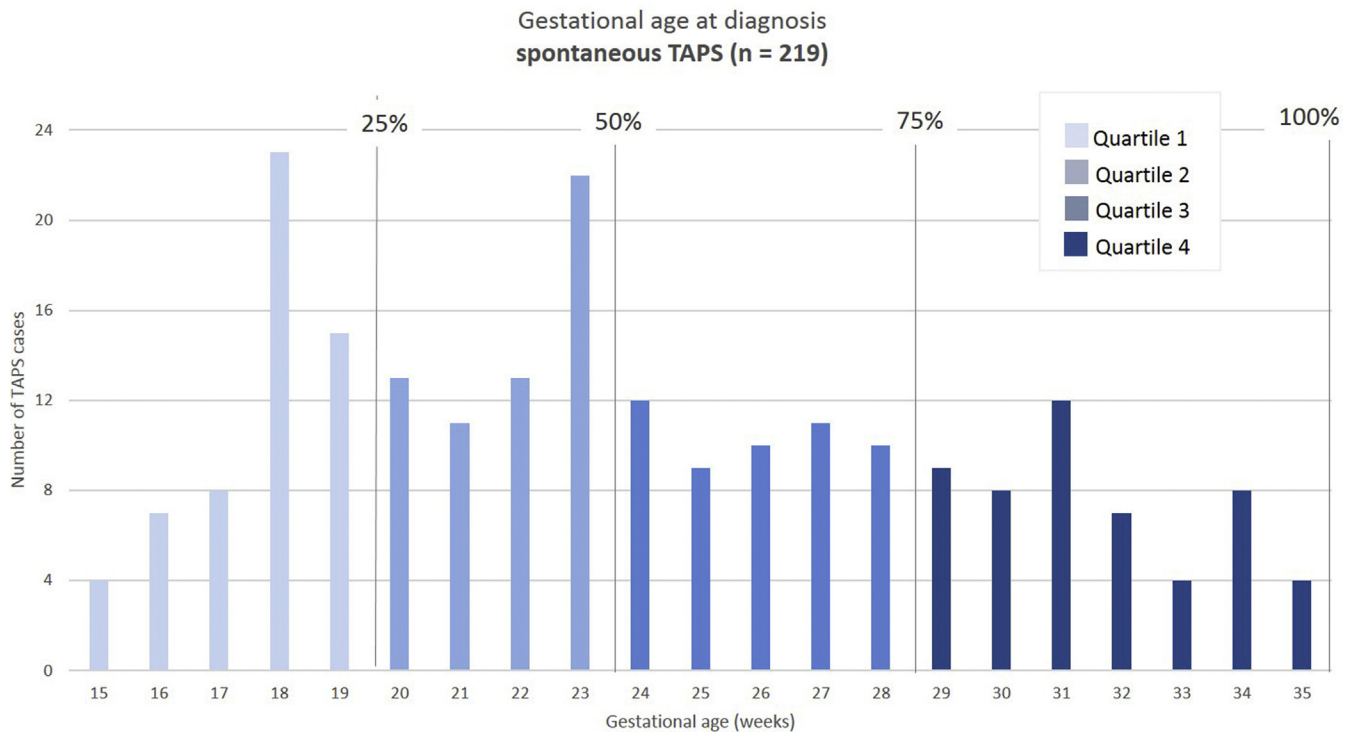
Of the 422 TAPS cases entered in the TAPS Registry, 249 (59%) were spontaneous TAPS and included in this study, whereas 173 (41%) were post-laser TAPS and excluded from the study. The number of spontaneous TAPS cases per fetal therapy center is presented in [Supplemental Table 1](#). TAPS was diagnosed antenatally in 88% (219 of 249) of the group and postnatally in 12% (30 of 249) ([Table 1](#)). The median GA at diagnosis was 23.7 weeks (IQR, 19.7–28.8) and ranged widely from 15.1 to 35.3 weeks ([Figure](#)). In antenatally detected TAPS, 39% (86 of 219) were treated with laser surgery, 24% (52 of 219) were managed expectantly, 16% (34 of 219) had a delivery, 13% (26 of 219) received IUT (±PET), 8% (18 of 219) were treated with selective feticide, and 1% (3 of 219) underwent a TOP ([Table 2](#)).

Color-dye injection of the placenta was performed in 44% (109 of 249) of the cases ([Table 3](#)). In total, 24% (26

of 109) of placentas belonged to TAPS cases treated with laser surgery and 76% (83 of 109) belonged to TAPS cases that were not treated with laser surgery. In placentas not treated with laser, the median total number of anastomoses was 3 (1–6), and 84% (70 of 83) of the placentas indicated arteriovenous (AV) or venoarterial (VA) anastomosis, or both. Arterioarterial (AA) and venovenous (VV) anastomoses were detected in 19% (16 of 83) and 7% (6 of 83) of the group, respectively. In 3 TAPS cases, the placenta demonstrated only 1 AA or VV anastomosis at the vascular equator. A total of 7 placentas did not indicate any anastomoses after placental injection. Although 3 cases had spontaneous resolution of TAPS during pregnancy, 1 case had normal hemoglobin values despite an antenatal diagnosis of TAPS, and the 3 remaining cases presented with severe postnatal TAPS (\geq stage 4). In total, 94% (74 of 76) of the placentas with anastomoses indicated only minuscule anastomoses. Residual anastomoses were detected in 11% (3 of 26) of placentas treated with laser. In all 3 cases, residual anastomoses were small and the twins had evidence of antenatal and postnatal TAPS.

Perinatal outcomes for the total group of TAPS twins and for donors

FIGURE
Gestational age at diagnosis in twins with spontaneous TAPS



TAPS, twin anemia polycythemia sequence.

Tollenaar et al. Spontaneous TAPS: diagnosis management and outcome in 249 cases. *Am J Obstet Gynecol* 2021.

and recipients separately are presented in Table 4. The median GA at birth for TAPS twins was 32.3 weeks (IQR, 30.1–34.9; range, 18.7–39.6). The donors were more often severely growth restricted than the recipients (49% [98 of 200] vs 11% [26 of 228]; $P<.001$). Fetal demise occurred in 11% (54 of 494) of the group, either spontaneously in 5% (24 of 494) or intended in 6% (30 of 494). The donors had a higher risk for fetal demise than the recipients, both for spontaneous fetal demise (8% [19 of 242] vs 2% [5 of 241]; $P=.002$) and intended fetal demise (10% [24 of 242] vs 3% [6 of 242]; $P<.001$). Overall perinatal mortality occurred in 15% (72 of 493) of TAPS twins, in 22% (54 of 243) of the donors and 7% (18 of 242) of the recipients ($P<.001$). Spontaneous perinatal mortality was observed in 9% (42 of 493) of the group, in 12% (30 of 243) of the donors and in 5% (12 of 242) of the recipients ($P<.001$).

The rate of neonatal mortality was 4% (18 of 439) and was comparable between the donors and recipients (6% [11 of 200] vs 3% [7 of 231], respectively; $P=.159$). Severe neonatal morbidity was diagnosed in 33% (141 of 432) of TAPS twins and was similar for donors (32%; 63 of 196) and recipients (33%; 75 of 228) ($P=.628$). In twins who were diagnosed as having TAPS at birth (43%; 108 of 249), intertwin hemoglobin difference was 14.3 mmol/L (IQR, 11.7–17.8) and the reticulocyte count ratio was 3.9 (IQR, 2.5–5.3). The donors needed a blood transfusion at birth in 76% (81 of 108) and the recipients a PET in 51% (51 of 108). In twins diagnosed as having TAPS at birth, 17% (18 of 108) had postnatal TAPS stage 1, 28% (30 of 108) stage 2, 24% (26 of 108) stage 3, 19% (21 of 108) stage 4, and 12% (13 of 108) stage 5.

Details on univariable and multivariable risk factor analysis for perinatal

mortality and severe neonatal morbidity are presented in Supplemental Tables 2 and 3. Multivariable analysis indicated that donor status (OR, 3.8; 95% CI, 1.9–7.5; $P<.001$), antenatal TAPS stage (OR, 6.3; 95% CI, 1.4–27.8 [stage 2]; $P=.016$; OR, 9.6; 95% CI, 2.1–45.5; $P=.005$ [stage 3]; OR, 20.9; 95% CI, 3.0–146.4; $P=.002$ [stage 4]), and GA at birth (OR, 0.8; 95% CI, 0.7–0.9; $P=.001$) were independent risk factors for spontaneous perinatal mortality. For severe neonatal morbidity, multivariable analysis indicated that TAPS stage 4 (OR, 7.9; 95% CI, 1.4–43.3; $P=.018$) and GA at birth (OR, 1.7; 95% CI, 1.5–2.1; $P<.001$) were independently associated with severe neonatal morbidity.

Comment Principal findings

This was a large international study investigating management and outcome

in spontaneous TAPS. We found that TAPS can develop across a wide range of gestations. Management varied considerably, with fetoscopic laser surgery being the most frequent intervention. In this cohort, perinatal outcome was poor, particularly because of a high perinatal mortality rate in donor twins. These findings stress the need for increased awareness by clinicians concerning the severity of TAPS. Adaptation of guidelines to ensure early diagnosis and prospective, well-controlled studies to determine the most optimal diagnostic criteria and management strategy are needed.

Results

Studies investigating perinatal outcome in TAPS are scarce, and the majority combine outcome of spontaneous and post-laser TAPS twins. In a recent long-term outcome study, fetal demise occurred in 3% and neonatal mortality in 2% of spontaneous TAPS twins, which is roughly comparable to the 5% and 4% in this study, respectively.¹⁹ This study also reported that spontaneous TAPS donors have a 4-fold higher odds of neurodevelopmental impairment than recipients. This study found that TAPS donors not only have a more detrimental outcome in the long-term but are also at increased risk for mortality antenatally. In addition, almost half of the donors in our cohort were severely growth restricted, in contrast to 12% of recipients, which might contribute to an impaired outcome. In this cohort, GA at birth was a strong predictor for both perinatal mortality and severe neonatal morbidity, indicating that prolonging pregnancy is crucial to improve outcome in TAPS twins. It is unclear what the best management option in TAPS twins is. In this study, the type of antenatal management was not a risk factor for perinatal mortality or severe neonatal morbidity. An in-depth evaluation of outcomes after different management strategies in 370 cases with spontaneous and post-laser TAPS is described in a separate study.²⁰

In line with previous smaller studies, in this study we found that the vast majority (94%) of TAPS placentas

	Spontaneous TAPS (N=249 pregnancies, 498 fetuses)
GA at diagnosis (wk)	23.7 (19.7–28.8; 15.1–35.3)
TAPS stage at diagnosis	
1	80/219 (37)
2	91/219 (42)
3	38/219 (17)
4	10/219 (5)
5	0/219 (0)
Highest TAPS stage during pregnancy	
1	64/219 (29)
2	88/219 (40)
3	52/219 (24)
4	12/219 (6)
5	3/219 (1)
Presence of additional ultrasound markers ^a	
Starry-sky liver (recipient)	93/200 (47)
Difference in placental echogenicity	96/220 (44)
Antenatal management	
Expectant management	51/219 (23)
Delivery ^b	34/219 (16)
IUT (±PET)	26/219 (12)
Laser surgery	86/219 (39)
Selective feticide	18/219 (9)
Termination of pregnancy	3/219 (1)
Female ^c	251/468 (53)
Cesarean ^d	330/488 (68)

Data are presented as median (IQR) or n/N (%).

GA, gestational age; IQR, interquartile range; IUT, intrauterine transfusion; PET, partial exchange transfusion; TAPS, twin anemia polycythemia.

^a The presence of a starry-sky liver and difference in placental echogenicity was assessed in 200 and 220 cases, respectively; ^b One case that had a delivery at 27 weeks' gestation based on TAPS stage 3 was a monoamniotic twin; ^c In 30 fetuses, gender is unknown. One case was a male-female pair; ^d In 10 fetuses, mode of delivery is unknown.

Tollenaar et al. Spontaneous TAPS: diagnosis management and outcome in 249 cases. *Am J Obstet Gynecol* 2021.

indicated only minuscule anastomoses.¹ Our data also revealed that AA anastomoses do not prevent the development of TAPS, because they were observed in 19% of TAPS placentas, which is higher than the 11% reported before.²¹ Moreover, in this study we found that VV anastomoses can also be present in TAPS placentas.²² Of interest, there were 3 TAPS placentas that indicated only 1 minuscule AA or VV anastomosis. It is

postulated that these bidirectional anastomoses act like an AV anastomosis (allowing unidirectional flow) under certain circumstances. Of note, 7 TAPS cases had no placental anastomoses. In 3 cases, TAPS resolved during pregnancy, likely as a result of spontaneous thrombosis in an AV anastomosis.²³ Three other placentas belonged to severe postnatal TAPS cases. Possibly, deep-hidden anastomoses were responsible

TABLE 3
Characteristics of spontaneous TAPS placentas (not treated with laser)

	Injected TAPS placentas (N=83)
Total number of anastomoses	3 (1–6)
Number of AV anastomoses	2 (1–3)
Number of VA anastomoses	1 (0–2)
Number of AA anastomoses	0 (0–0)
Number of VV anastomoses	0 (0–0)
Presence of anastomoses	
Presence of AV/VA anastomoses	70/83 (84)
Presence of AA anastomoses	16/83 (19)
Presence of VV anastomoses	6/83 (7)
Type of anastomoses per placenta	
No anastomoses	7/83(8)
AV (1 direction)	21/83 (25)
AVs (both directions)	34/83 (41)
AV/VA and AA	13/83 (16)
AV/VA and VV	4/83 (5)
Only AA	2/83 (2)
Only VV	1/83 (1)
AV/VA, AA, and VV	1/83 (1)
All anastomoses diameter at <1 mm ^a	74/76 (97)

Data are presented as median (IQR) or n/N (%).

AA, arterioarterial; AV, arteriovenous; IQR, interquartile range; TAPS, twin anemia polycythemia; TTTS, twin-twin transfusion syndrome; VA, venoarterial; VV, venovenous.

^a Reported only in cases with anastomoses; the 10 cases without anastomoses were excluded.

Tollenaar et al. Spontaneous TAPS: diagnosis management and outcome in 249 cases. *Am J Obstet Gynecol* 2021.

for the unbalanced blood flow.²⁴ Alternatively, minuscule anastomoses may not have been seen because of suboptimal color-dye injection, which is known to be technically challenging in TAPS placentas.²⁵

Clinical implications

Until now, information regarding the time of onset of TAPS was limited and based mostly on small cohort studies. To develop adequate TAPS screening guidelines, using routine MCA-PSV Doppler measurements, knowledge concerning the time of onset of TAPS is essential. Our findings indicate that TAPS can develop from 15 weeks to 35 weeks' gestation. Because 3 of the 4 cases detected at 15 weeks were at stage 2 or higher, it is likely that TAPS manifested even earlier. Currently,

there is no consensus on when to start with MCA-PSV surveillances to check for the presence of TAPS. The International Society of Ultrasound in Obstetrics and Gynecology twin guideline recommends biweekly MCA-PSV screening starting from 20 weeks' gestation, especially in cases treated with laser surgery for TTTS.²⁶ The Society for Maternal-Fetal Medicine does not recommend MCA-PSV screening at all, because of the lack of evidence that routine screening improves perinatal outcome in TAPS.²⁷ This study indicated that an advanced antenatal TAPS stage was a significant risk factor for perinatal mortality and severe neonatal morbidity. Therefore, we can speculate that a timely detection allowing antenatal intervention could improve the

outcome. Based on the mounting evidence of serious effects of TAPS,¹⁹ we suggest that to improve early detection and possibly outcome, routine MCA-PSV examination should be included in the standard biweekly work-up starting in the early second trimester.

Strengths and limitations

Caution is needed when interpreting the findings of our study owing to the limitations associated with retrospective study designs. Notably, this study depended on local registrations of tertiary fetal therapy centers. Therefore, our outcome could be biased toward severe cases of TAPS, because they are more likely to be referred by peripheral clinics. Furthermore, this study concerned a heterogenous population, and cases differed in GA at diagnosis, severity of TAPS, and type of treatment, which might have influenced the outcome. Finally, maternal demographics and comorbidities were not elaborately studied, and therefore, the overall risk for complications outside of TAPS could not be taken in to account. Nonetheless, this large international study presents new important information that has potential implications for the future care of monochorionic twins.

Conclusions

Spontaneous TAPS can occur across a wide GA range, is managed heterogeneously, and is associated with high rates of adverse perinatal outcome, particularly in donor twins. Because perinatal outcome is greatly dependent on TAPS stage, timely detection allowing consideration of antenatal treatment is of utmost importance. To adequately investigate the best treatment for TAPS, an international randomized controlled trial is needed.²⁸ ■

Acknowledgments

We thank the following contributors: Johanna M. Middeldorp, MD, PhD; Monique C. Haak, MD, PhD; Frans J.C.M. Klumper, MD; Joost Akkermans, MD, PhD; Isabel Couck, MD, PhD; Yves Ville, MD, PhD; Daniela Casati, MD, PhD; Romain Favre, MD, PhD; Sebastian R. Hobson, MD, PhD; Carlota Rodo, MD, PhD; Patrick Greimel, MD, PhD; Kurt Hecher, MD, PhD;

TABLE 4
Perinatal outcome for spontaneous twin anemia polycythemia sequence

	Spontaneous TAPS (n=249 pregnancies, 498 fetuses)	TAPS donors ^a (n=244 fetuses)	TAPS recipients ^a (n=244 fetuses)	P value
GA at birth (wk)	32.3 (30.1–34.9; 18.7–39.6)	—	—	—
Fetal demise ^b	54/494 (11)	43/243 (18)	11/243 (5)	<.001 ^f
Spontaneous	24/494 (5)	19/243 (8)	5/243 (2)	.002 ^f
Intended	30/494 (6)	24/243 (10)	6/243 (3)	<.001 ^f
Neonatal mortality ^c	18/439 (4)	11/200 (6)	7/231 (3)	.161
Perinatal mortality (overall) ^c	72/493 (15)	54/243 (22)	18/242 (7)	<.001 ^f
Perinatal mortality (spontaneous) ^c	42/493 (9)	30/243 (12)	12/242 (5)	<.001 ^f
Severe neonatal morbidity ^d	141/432 (33)	63/196 (32)	74/228 (33)	.652
Respiratory distress syndrome	118/432 (27)	51/196 (26)	64/228 (28)	.413
Patent ductus arteriosus	34/432 (8)	15/196 (8)	19/228 (8)	.671
Necrotizing enterocolitis	15/432 (4)	7/196 (4)	8/228 (4)	.905
Retinopathy of prematurity	7/432 (2)	3/196 (2)	4/228 (2)	.778
Severe cerebral injury	15/432 (4)	4/196 (2)	11/228 (5)	.109
Ischemic limb injury	0/432 (0)	0/196 (0)	0/196 (0)	1.000
Birthweight (g) ^d	1645±609	1483±566	1765±620	<.001 ^f
Severe growth restriction (bw at <p3) ^e	126/434 (29)	98/200 (49)	26/228 (11)	<.001 ^f
Mild growth restriction (bw at <p10) ^e	211/434 (49)	135/200 (68)	71/228 (31)	<.001 ^f

Data are presented as mean±SD medians (IQR) or n/N (%).

bw, birthweight; GA, gestational age; TAPS, twin anemia polycythemia sequence; SD, standard deviation.

^a In 5 of 249 cases, the donor-recipient status was unknown; ^b A total of 4 missing values; ^c A total of 5 missing values (same as ^a plus 1 missing value from a liveborn recipient with unknown neonatal mortality information); ^d A total of 12 missing values (same as ^b, plus 4 cases with unknown neonatal morbidity information and 3 cases who died shortly after birth); ^e A total of 9 missing values (as in ^a plus 5 cases with unknown birthweights); ^f Statistical significance.

Tollenaar et al. Spontaneous TAPS: diagnosis management and outcome in 249 cases. *Am J Obstet Gynecol* 2021.

Basky Thilaganathan, MD, PhD; Eric P. Bergh, MD, PhD; Andrew Carlin, MD, PhD; Kristina A. Gladkova, MD, PhD; Joshua A. Copel, MD, PhD.

References

- Lopriore E, Middeldorp JM, Oepkes D, Kanhai HH, Walther FJ, Vandenbussche FP. Twin anemia-polycythemia sequence in two monochorionic twin pairs without oligo-polyhydramnios sequence. *Placenta* 2007;28:47–51.
- Lewi L, Jani J, Blickstein I, et al. The outcome of monochorionic diamniotic twin gestations in the era of invasive fetal therapy: a prospective cohort study. *Am J Obstet Gynecol* 2008;199:514.e1–8.
- Tollenaar LS, Slaghekke F, Middeldorp JM, et al. Twin anemia polycythemia sequence: current views on pathogenesis, diagnostic criteria, perinatal management, and outcome. *Twin Res Hum Genet* 2016;19:222–33.
- Hill KM, Masoudian P, Fung-Kee-Fung K, El Demellawy D. Intrauterine interventions for the treatment of twin anemia-polycythemia sequence: a systematic review. *J Obstet Gynaecol Can* 2019;41:981–91.

- Lopriore E, Slaghekke F, Oepkes D, Middeldorp JM, Vandenbussche FP, Walther FJ. Clinical outcome in neonates with twin anemia-polycythemia sequence. *Am J Obstet Gynecol* 2010;203:54.e1–5.
- Lopriore E, Slaghekke F, Kersbergen KJ, et al. Severe cerebral injury in a recipient with twin anemia-polycythemia sequence. *Ultrasound Obstet Gynecol* 2013;41:702–6.
- Ashwal E, Yinon Y, Fishel-Bartal M, et al. Twin anemia-polycythemia sequence: perinatal management and outcome. *Fetal Diagn Ther* 2016;40:28–34.
- Tollenaar LSA, Lopriore E, Faiola S, et al. Post-laser twin anemia polycythemia sequence: management and outcome in a large international cohort of 164 cases. *J Clin Med* 2020;9:1759.
- Slaghekke F, Pasma S, Veujoz M, et al. Middle cerebral artery peak systolic velocity to predict fetal hemoglobin levels in twin anemia-polycythemia sequence. *Ultrasound Obstet Gynecol* 2015;46:432–6.
- Lopriore E, Slaghekke F, Oepkes D, Middeldorp JM, Vandenbussche FP, Walther FJ. Hematological characteristics in neonates with

twin anemia-polycythemia sequence (TAPS). *Prenat Diagn* 2010;30:251–5.

- Lopriore E, Slaghekke F, Middeldorp JM, et al. Accurate and simple evaluation of vascular anastomoses in monochorionic placentas using colored dye. *J Vis Exp* 2011;55:e3208.
- Bell MJ, Ternberg JL, Feigin RD, et al. Neonatal necrotizing enterocolitis. Therapeutic decisions based upon clinical staging. *Ann Surg* 1978;187:1–7.
- An international classification of retinopathy of prematurity. The Committee for the Classification of Retinopathy of Prematurity. *Arch Ophthalmol* 1984;102:1130–4.
- Volpe JJ. Intraventricular hemorrhage and brain injury in the premature infant. Diagnosis, prognosis, and prevention. *Clin Perinatol* 1989;16:387–411.
- Levene MI. Measurement of the growth of the lateral ventricles in preterm infants with real-time ultrasound. *Arch Dis Child* 1981;56:900–4.
- de Vries LS, Eken P, Dubowitz LM. The spectrum of leukomalacia using cranial ultrasound. *Behav Brain Res* 1992;49:1–6.

17. Hoftiezer L, Hof MHP, Dijs-Elsinga J, Hogeveen M, Hukkelhoven CWPM, van Lingen RA. From population reference to national standard: new and improved birthweight charts. *Am J Obstet Gynecol* 2019;220:383.e1–17.
18. Slaghekke F, Kist WJ, Oepkes D, et al. Twin anemia-polycythemia sequence: diagnostic criteria, classification, perinatal management and outcome. *Fetal Diagn Ther* 2010;27:181–90.
19. Tollenaar LSA, Lopriore E, Slaghekke F, et al. High risk of long-term impairment in donor twins with spontaneous twin anemia polycythemia sequence. *Ultrasound Obstet Gynecol* 2020;5:39–46.
20. Tollenaar LSA, Slaghekke F, Lewi L, et al. Treatment and outcome in 370 cases with spontaneous and post-laser twin anemia polycythemia sequence managed in 17 different fetal therapy centers. *Ultrasound Obstet Gynecol* 2020 [Epub ahead of print].
21. van Meir H, Slaghekke F, Lopriore E, van Wijngaarden WJ. Arterio-arterial anastomoses do not prevent the development of twin anemia-polycythemia sequence. *Placenta* 2010;31:163–5.
22. de Villiers SF, Slaghekke F, Middeldorp JM, Walther FJ, Oepkes D, Lopriore E. Placental characteristics in monochorionic twins with spontaneous versus post-laser twin anemia-polycythemia sequence. *Placenta* 2013;34:456–9.
23. Lopriore E, Hecher K, Vandenbussche FP, van den Wijngaard JP, Klumper FJ, Oepkes D. Fetoscopic laser treatment of twin-to-twin transfusion syndrome followed by severe twin anemia-polycythemia sequence with spontaneous resolution. *Am J Obstet Gynecol* 2008;198:e4–7.
24. Lewi L, Jani J, Cannie M, et al. Intertwin anastomoses in monochorionic placentas after fetoscopic laser coagulation for twin-to-twin transfusion syndrome: is there more than meets the eye? *Am J Obstet Gynecol* 2006;194:790–5.
25. Zhao DP, Dang Q, Haak MC, et al. ‘Superficial’ anastomoses in monochorionic placentas are not always superficial. *Placenta* 2015;36:1059–61.
26. Khalil A, Rodgers M, Baschat A, et al. ISUOG Practice Guidelines: role of ultrasound in twin pregnancy. *Ultrasound Obstet Gynecol* 2016;47:247–63.
27. Society for Maternal-Fetal Medicine, Simpson LL. Twin-twin transfusion syndrome. *Am J Obstet Gynecol* 2013;208:3–18.
28. The TAPS Trial - Fetoscopic Laser Surgery for Twin Anemia Polycythemia Sequence. Available at: <https://clinicaltrials.gov/ct2/show/NCT04432168> Accessed August 25, 2020.

Author and article information

From the Division of Fetal Therapy, Department of Obstetrics (Ms Tollenaar and Drs Slaghekke and Oepkes), and Division of Neonatology, Department of Pediatrics (Dr Lopriore), Leiden University Medical Center, Leiden, the Netherlands; Department of Obstetrics and Gynecology, University Hospitals Leuven, Leuven, Belgium (Dr Lewi); Department of Obstetrics and Maternal-Fetal Medicine, Hôpital Necker-Enfants Malades, AP-HP, Paris, France (Dr Colmant); Fetal Therapy Unit “U. Nicolini,” Vittore Buzzi Children’s Hospital, University of Milan, Milan, Italy (Dr Lanna); Department of Obstetrics and Gynecology, Strasbourg University Hospital, Strasbourg Cedex, France (Dr Weingartner); Fetal Medicine Unit, Ontario Fetal Centre, Mount Sinai Hospital, University of Toronto, Canada (Dr Ryan); Maternal-Fetal Medicine Unit, Department of Obstetrics, Vall d’Hebron University Hospital, Barcelona, Spain (Dr Arévalo); Division of Obstetrics and Maternal-Fetal Medicine, Department of Obstetrics and Gynecology, Medical University of Graz, Graz, Austria (Dr Klaritsch); Department of Obstetrics and Fetal Medicine, University Medical Center Hamburg-Eppendorf, Hamburg, Germany (Dr Tavares de Sousa); Fetal Medicine Unit, Department of Obstetrics and Gynaecology, St George’s University Hospitals National Health Service Foundation Trust, London, United Kingdom (Dr Khalil); Department of Obstetrics, The Fetal Center, Children’s Memorial Hermann Hospital, Department of Obstetrics, Gynecology, and Reproductive Sciences, McGovern Medical School, University of Texas Health Science Center, Houston, TX (Dr Papanna); Department of Maternal Fetal Medicine, Mater Mothers’ Hospital Brisbane, South Brisbane, Queensland, Australia (Dr Gardener); Department of Obstetrics and Gynecology, University Hospital Brugmann, Université Libre de Bruxelles, Brussels, Belgium (Dr Bevilacqua); Academician V.I. Kulakov Research Center of Obstetrics, Gynecology, and Perinatology, Ministry of Health of the Russian Federation, Moscow, Russia (Dr Kostyukov); Department of

Obstetrics, Gynecology, and Reproductive Sciences, Yale School of Medicine, New Haven, CT (Dr Bahtiyar); Fetal Medicine Centre, Birmingham Women’s and Children’s National Health Service Foundation Trust, University of Birmingham, Birmingham, United Kingdom (Dr Kilby); and Center for Fetal Medicine, Karolinska University Hospital, Stockholm, Sweden (Dr Tiblad).

Received April 10, 2020; revised June 26, 2020; accepted July 22, 2020.

Contributor affiliations: From the Division of Fetal Therapy, Department of Obstetrics (Drs Middeldorp, Haak, Klumper, and Akkermans), Leiden University Medical Center, Leiden, the Netherlands; Department of Obstetrics and Gynecology, University Hospitals Leuven, Leuven, Belgium (Dr Couck); Department of Obstetrics and Maternal-Fetal Medicine, Hôpital Necker-Enfants Malades, AP-HP, Paris, France (Dr Ville); Fetal Therapy Unit “U. Nicolini,” Vittore Buzzi Children’s Hospital, University of Milan, Milan, Italy (Dr Casati); Department of Obstetrics and Gynecology, Strasbourg University Hospital, Strasbourg Cedex, France (Dr Favre); Fetal Medicine Unit, Department of Obstetrics and Gynecology, Mount Sinai Hospital, University of Toronto, Toronto, Canada (Dr Hobson); Maternal-Fetal Medicine Unit, Department of Obstetrics, Vall d’Hebron University Hospital, Barcelona, Spain (Dr Rodo); Division of Obstetrics and Maternal-Fetal Medicine, Department of Obstetrics and Gynecology, Medical University of Graz, Graz, Austria (Dr Greimel); Department of Obstetrics and Fetal Medicine, University Medical Center Hamburg-Eppendorf, Hamburg, Germany (Dr Hecher); Fetal Medicine Unit, Department of Obstetrics and Gynaecology, St George’s University Hospitals National Health Service Foundation Trust, London, United Kingdom (Dr Thilaganathan); Department of Obstetrics, the Fetal Center, Children’s Memorial Hermann Hospital, Department of Obstetrics, Gynecology, and Reproductive Sciences, McGovern Medical School, University of Texas Health Science Center, Houston, TX (Dr Bergh); Department of Obstetrics and Gynecology, University Hospital Brugmann, Université Libre de Bruxelles, Brussels, Belgium (Dr Carlin); Academician V.I. Kulakov Research Center of Obstetrics, Gynecology, and Perinatology, Ministry of Health of the Russian Federation, Moscow, Russia (Dr Gladkova); Department of Obstetrics, Gynecology, and Reproductive Sciences, Yale School of Medicine, New Haven, CT (Dr Copel).

The authors report no conflict of interest.

Corresponding author: Lisanne S.A. Tollenaar, BSc. l.s.a.tollenaar@lumc.nl

SUPPLEMENTAL TABLE 1

Spontaneous TAPS cases per center

Center	Country	Spontaneous TAPS cases
Leiden University Medical Center	The Netherlands	70
Leuven University Hospital	Belgium	30
Necker-Enfants Malades Hospital, Paris	France	23
Hospital Universitari Vall d'Hebron, Barcelona	Spain	16
University Medical Center Hamburg-Eppendorf	Germany	15
Center Medico-Chirurgical Obstetrical, Strasbourg	France	13
Medical University of Graz	Austria	13
Ontario Fetal Centre, Mount Sinai Hospital, University of Toronto, Canada	Canada	12
Children's Hospital V. Buzzi, Milan	Italy	11
University of Texas McGovern Medical School at Houston	United States of America	10
Saint George's Hospital, London	United Kingdom	9
Mater Hospital, Brisbane	Australia	8
Brugmann University Hospital	Belgium	7
Yale New Haven Hospital	United States of America	6
Karolinska University Hospital, Stockholm	Sweden	3
V.I. Kulakov National Medical Research Center of Obstetrics, Gynecology, and Perinatology, Moscow	Russia	2
Birmingham Women's and Children's NHS Foundation Trust	United Kingdom	1

TAPS, twin anemia polycythemia sequence.

Tollenaar et al. Spontaneous TAPS: diagnosis management and outcome in 249 cases. *Am J Obstet Gynecol* 2021.

SUPPLEMENTAL TABLE 2

Univariable and multivariable risk analysis for spontaneous perinatal mortality in spontaneous twin anemia polycythemia sequence

	Death ^a (n=42/463)	Alive ^a (n=421/463)	Univariable analysis OR (95% CI)	SE	P value	Multivariable ^d analysis OR (95% CI)	SE	P value
GA at diagnosis of TAPS	22.7±4.8	24.7±5.4	0.9 (0.8–1.0)	0.05	.124			
Antenatal TAPS stage								
1	2/126 (2)	124/126 (98)	— ^b					
2	17/162 (11)	145/162 (89)	7.2 (1.5–32.2)	0.8	.009 ^e	6.3 (1.4–27.8)	0.8	.016 ^e
3	14/91 (15)	77/91 (85)	11.3 (2.5–50.5)	0.8	.002 ^e	9.6 (2.1–45.5)	0.8	.005 ^e
4	8/15 (35)	18/15 (65)	32.5 (5.7–186.7)	0.9	<.001 ^e	20.9 (3.0–146.4)	1.0	.002 ^e
Recipient ^c	12/236 (5)	224/236 (95)	— ^b					
Donor ^c	30/219 (14)	189/219 (86)	3.0 (1.7–5.4)	0.3	<.001 ^e	3.8 (1.9–7.5)	0.3	<.001 ^e
Antenatal therapy								
Expectant management	12/101 (10)	89/101 (88)	— ^b					
Delivery	5/68 (7)	63/68 (93)	0.6 (0.2–1.8)	0.6	.334			
IUT (±PET)	2/52 (4)	50/52 (96)	0.3 (0.1–1.4)	0.9	.118			
Laser surgery	21/163 (13)	142/163 (87)	1.1 (0.5–2.5)	0.4	.865			
Selective feticide (cotwin)	2/17 (11)	17/19 (89)	0.9 (0.2–4.3)	0.8	.855			
GA at birth	29.5±4.7	32.6±2.9	0.8 (0.7–0.9)	0.1	<.001 ^e	0.8 (0.7–0.9)	0.1	.001 ^e

Values are odds ratios (OR) (95% confidence intervals [CIs]), standard error (SE), and P value.

GA, gestational age; IUT, intrauterine transfusion; PET, partial exchange transfusion; SMM, severe neonatal morbidity; TAPS, twin anemia polycythemia sequence.

^a A total of 30 cases were excluded as mortality occurred in context of selective feticide or termination of pregnancy, from the 648 cases 5 cases have missing values; ^b Set as a reference; ^c In 5 cases, donor-recipient status was unknown; ^d Antenatal TAPS stage, donor status, and GA at birth were not correlated (antenatal TAPS stage and donor status [R<0.000; P=.998], antenatal TAPS stage and GA at birth [R<0.001; P=1.000], and GA at birth and donor status [R<0.000; P=.997]), so all parameters were included in multivariable analysis; ^e Statistical significance.

Tollenaar et al. Spontaneous TAPS: diagnosis management and outcome in 249 cases. Am J Obstet Gynecol 2021.

SUPPLEMENTAL TABLE 3

Univariable and multivariable risk analysis for severe neonatal morbidity in spontaneous twin anemia polycythemia sequence

	SNM ^a (n=141/432)	No SNM ^a (n=291/432)	Univariable analysis, OR (95% CI)	SE	P value	Multivariable analysis, OR (95% CI)	SE	P value ^b
GA at diagnosis of TAPS	25.4±5.2	24.5±5.6	1.0 (0.9–1.0)	0.02	.300	—	—	—
Antenatal TAPS stage								
1	40/123 (33)	83/123 (67)	—					
2	44/148 (30)	104/148 (70)	0.9 (0.5–1.7)	0.3	.651	0.7 (0.3–1.6)	0.4	.414
3	31/82 (38)	51/82 (62)	1.1 (0.6–2.4)	0.4	.749	1.0 (0.4–3.0)	0.5	.953
4	14/19 (74)	5/19 (26)	4.4 (1.2–16.0)	0.7	.026	7.9 (1.4–43.3)	0.8	.018 ^e
Recipient ^c	74/226 (33)	153/226 (67)	— ^b					
Donor ^c	63/196 (32)	133/196 (68)	1.1 (0.8–1.3)	0.1	.628	—	—	—
Antenatal management								
Expectant management	26/93 (28)	67/93 (72)	— ^b					
Delivery	32/68 (47)	35/68 (53)	2.3 (1.0–5.6)	0.4	.046	0.5 (0.1–1.5)	0.5	.252
IUT (±PET)	22/50 (44)	28/50 (56)	1.9 (0.8–4.6)	0.5	.150	1.3 (0.4–4.0)	0.6	.695
Laser surgery	44/145 (31)	108/145 (69)	1.2 (0.5–2.4)	0.4	.661	1.6 (0.6–4.9)	0.6	.370
Selective feticide	4/17 (24)	13/17 (76)	0.8 (0.2–2.8)	0.6	.710	— ^d		
GA at birth	30.1±2.7	33.6±2.3	1.7 (1.5–1.9)	0.1	<.001 ^e	1.7 (1.5–2.1)	0.1	<.001 ^e
Severe growth restriction, no	99/304 (33)	205/304 (67)	— ^b					
Severe growth restriction, yes	41/122 (34)	81/122 (66)	1.0 (0.7–1.5)	0.2	.842	-	-	-
Postnatal TAPS, no	40/156 (26)	116/156 (74)	— ^b					
Postnatal TAPS, yes	81/211 (38)	130/211 (62)	1.9 (1.0–3.3)	0.3	.039 ^e	2.1 (0.9–5.0)	0.4	.068

There was no strong correlation between antenatal TAPS stage, antenatal management, GA at birth, and postnatal TAPS (GA at birth and postnatal TAPS [R<0.001; P=1.000]; antenatal TAPS stage and postnatal TAPS [R=-0.155; P=.006]; antenatal management [R=-0.493; P<.001]; GA at birth and antenatal TAPS stage [R=-0.209; P<.001]; GA at birth and antenatal management [R=0.154; P=.002]; antenatal management and antenatal TAPS stage [R=0.307; P<.001]), so all were included in multivariable analysis.

Values are presented as odds ratios (OR) (95% confidence intervals [CI]), standard error (SE), and P value.

GA, gestational age; IUT, intrauterine transfusion; PET, partial exchange transfusion; SNM, severe neonatal morbidity; TAPS, twin anemia polycythemia sequence.

^a A total of 12 neonates with missing neonatal outcome; ^b Set as a reference; ^c In 5 cases, donor-recipient status was unknown; ^d Group too small to calculate OR in multivariable analysis; ^e Statistical significance.

Tollenaar et al. Spontaneous TAPS: diagnosis management and outcome in 249 cases. Am J Obstet Gynecol 2021.