



Universiteit
Leiden
The Netherlands

Pulmonary infarction in acute pulmonary embolism

Kaptein, F.H.J.; Kroft, L.J.M.; Hammerschlag, G.; Ninaber, M.K.; Bauer, M.P.; Huisman, M.V.; Klok, F.A.

Citation

Kaptein, F. H. J., Kroft, L. J. M., Hammerschlag, G., Ninaber, M. K., Bauer, M. P., Huisman, M. V., & Klok, F. A. (2021). Pulmonary infarction in acute pulmonary embolism. *Thrombosis Research*, 202, 162-169. doi:10.1016/j.thromres.2021.03.022

Version: Publisher's Version

License: [Creative Commons CC BY 4.0 license](#)

Downloaded from: <https://hdl.handle.net/1887/3230165>

Note: To cite this publication please use the final published version (if applicable).



Pulmonary infarction in acute pulmonary embolism

F.H.J. Kaptein^a, L.J.M. Kroft^b, G. Hammerschlag^c, M.K. Ninaber^d, M.P. Bauer^e, M. V. Huisman^a, F.A. Klok^{a,*}

^a Department of Medicine – Thrombosis and Hemostasis, Leiden University Medical Center, Leiden, the Netherlands

^b Department of Radiology, Leiden University Medical Center, Leiden, the Netherlands

^c Department of Respiratory and Sleep Medicine, The Royal Melbourne Hospital, Melbourne, Australia

^d Department of Pulmonology, Leiden University Medical Center, Leiden, the Netherlands

^e Department of Medicine – Acute Medicine, Leiden University Medical Center, Leiden, the Netherlands

ARTICLE INFO

Keywords:

Pulmonary embolism
Pulmonary infarction
Hemorrhage
Diagnostic imaging
Prognosis

ABSTRACT

Pulmonary infarction results from occlusion of the distal pulmonary arteries leading to ischemia, hemorrhage and ultimately necrosis of the lung parenchyma. It is most commonly caused by acute pulmonary embolism (PE), with a reported incidence of around 30%. Following an occlusion of the pulmonary artery, the bronchial arteries are recruited as primary source of perfusion of the pulmonary capillaries. The relatively higher blood pressure in the bronchial circulation causes an increase in the capillary blood flow, leading to extravasation of erythrocytes (i.e. alveolar hemorrhage). If this hemorrhage cannot be resorbed, it results in tissue necrosis and infarction. Different definitions of pulmonary infarction are used in literature (clinical, radiological and histological), although the diagnosis is nowadays mostly based on radiological characteristics. Notably, the infarcted area is only replaced by a fibrotic scar over a period of months. Hence and formally, the diagnosis of pulmonary infarction cannot be confirmed upon diagnosis of acute PE. Little is known of the impact and relevance of pulmonary infarction in acute PE, and whether specific management strategies should be applied to prevent and/or treat complications such as pain, pneumonia or post-PE syndrome. In this review we will summarize current knowledge on the pathophysiology, epidemiology, diagnosis and prognosis of pulmonary infarction in the setting of acute PE. We highlight the need for dedicated studies to overcome the current knowledge gaps.

1. Introduction

Pulmonary infarction results from occlusion of the distal pulmonary arteries leading to ischemia, hemorrhage and ultimately necrosis of the lung parenchyma. It is most often caused by acute pulmonary embolism (PE), a frequently occurring and potentially life-threatening disease. (1) The reported annual incidence of PE varies between 75 and 269 cases per 100,000 persons, and mortality rates as high as 28% have been described. (1–4) Although the dual blood supply to the lungs, i.e. the pulmonary and the bronchial circulation, is thought to be protective against pulmonary ischemia, pulmonary infarction can be found in 10 to 50% of all patients with PE. (5) This wide range is the result of the difference in definition of pulmonary infarction used in literature, which varies from pulmonary infarction as a clinical syndrome to a radiological finding or a histological phenomenon. Literature on this complication is limited, and pulmonary infarction is scarcely addressed in PE guidelines,

if at all. Nevertheless, recognizing pulmonary infarction is clinically relevant, both during the diagnostic phase as well as for making management decisions. For instance, patients with pulmonary infarction secondary to acute PE may be more likely to present with pleuritic chest pain and fever, and may more often require hospitalization and targeted (intravenous) analgesic drugs to manage pain.

In this review we will summarize current knowledge on the pathophysiology, epidemiology, diagnosis and prognosis of pulmonary infarction in the setting of acute PE (Fig. 1).

1.1. Pathophysiology

The lungs receive deoxygenated blood from the pulmonary arteries (low pressure, high flow circulation) and oxygenated blood from the bronchial arteries (at systemic pressure, i.e. 6 times that of the pulmonary arteries). The function of the pulmonary circulation is mainly gas

Abbreviations: PE, pulmonary embolism; CTPA, computed tomography pulmonary angiography.

* Corresponding author at: Department of Medicine – Thrombosis and Hemostasis, Leiden University Medical Center, Leiden, the Netherlands.

E-mail address: f.a.klok@LUMC.nl (F.A. Klok).

<https://doi.org/10.1016/j.thromres.2021.03.022>

Received 27 January 2021; Received in revised form 5 March 2021; Accepted 24 March 2021

Available online 1 April 2021

0049-3848/© 2021 The Author(s). Published by Elsevier Ltd. This is an open access article under the CC BY license (<http://creativecommons.org/licenses/by/4.0/>).

exchange, whereas the bronchial circulation supplies the bronchial walls, the visceral pleura and the lung parenchyma with oxygenated blood (next to direct passive diffusion of oxygen in the latter). (6) This dual blood supply has been thought to be protective against ischemic injuries of the lungs. Animal models have shown that lung tissue may stay viable after ligation of the supplying pulmonary artery, where perfusion is maintained by the bronchial circulation: the bronchial arteries undergo smooth muscle wall hypertrophy and dilate to direct more oxygenated blood to ischemic lung tissue, and eventually increase in number. (7,8) Even so, obstruction of a pulmonary artery by acute PE can cause pulmonary infarction.

Already in 1856 Virchow described necrosis of the lung in areas distal to pulmonary embolic obstruction. (9) Hampton and Castleman demonstrated that (embolic) obstruction of a pulmonary artery may lead to a sequence that begins with hemorrhage into, and edema of, the alveoli in areas distal to the obstruction. (10) In some cases this is reversible: the intra-alveolar blood is resorbed in 2–4 days, without necrosis or residual damage (intra-alveolar hemorrhage or ‘incomplete infarction’). If not absorbed, the extravasated erythrocytes may begin to break down into hemosiderin within 1–2 days, at which point actual necrosis of the surrounding lung parenchyma begins, and ‘true’ infarction develops. The infarcted area is replaced by a fibrotic scar over a period of weeks (histologically) to months (radiologically) (Fig. 2). (10,11)

As initial studies showed a higher occurrence of pulmonary infarction in patients with a compromised cardiac function, it was hypothesized that chronic pulmonary venous hypertension and impaired forward flow through bronchial arteries are major contributing factors

to impaired resolution of alveolar hemorrhage and thus progression to local necrosis. (10–14)

Dalen et al. showed that emboli in distal pulmonary branches were more likely to cause pulmonary infarction than more extensive and/or central obstructions. (11) Virchow described that after ligating a main pulmonary artery, the collateral flow from the bronchial circulation enters the pulmonary circulation distal to the site of obstruction (as they anastomose at the pre-pulmonary-capillary level), supporting Dalen’s observation. (9) In a central pulmonary artery occlusion, the high-pressure inflow from the bronchial arteries is distributed throughout the entire arterial bed of that lung, which allows to absorb this abrupt influx of bronchial blood. However, in distal PE, the pressure of bronchial arterial inflow into the embolized area may be much greater than this small segment of the pulmonary arterial tree can accommodate (Fig. 1). At the same time, transient capillary ischemia (as the collateral circulation may not be immediately functional) leads to increased vascular permeability. Endothelial cells are known to be very susceptible for hypoxia (15), however, as the alveoli remain ventilated in PE (i.e. continued oxygen availability), the endothelial barrier dysfunction may be the result of an ischemia-induced inflammatory response. (16,17) The increased blood flow together with the locally increased vascular permeability causes extravasation of red blood cells into the alveoli. (11) The resulting intra-alveolar hemorrhage resembles an infarct, but the tissue structures are preserved and the preexisting lung architecture may be restored after resorption of the blood. However, if the intra-alveolar hemorrhage cannot be resorbed (due to inadequate blood flow), tissue infarction occurs, as was shown in animal models and autopsy studies. (9,10) Hence, although vascular obstruction usually leads to

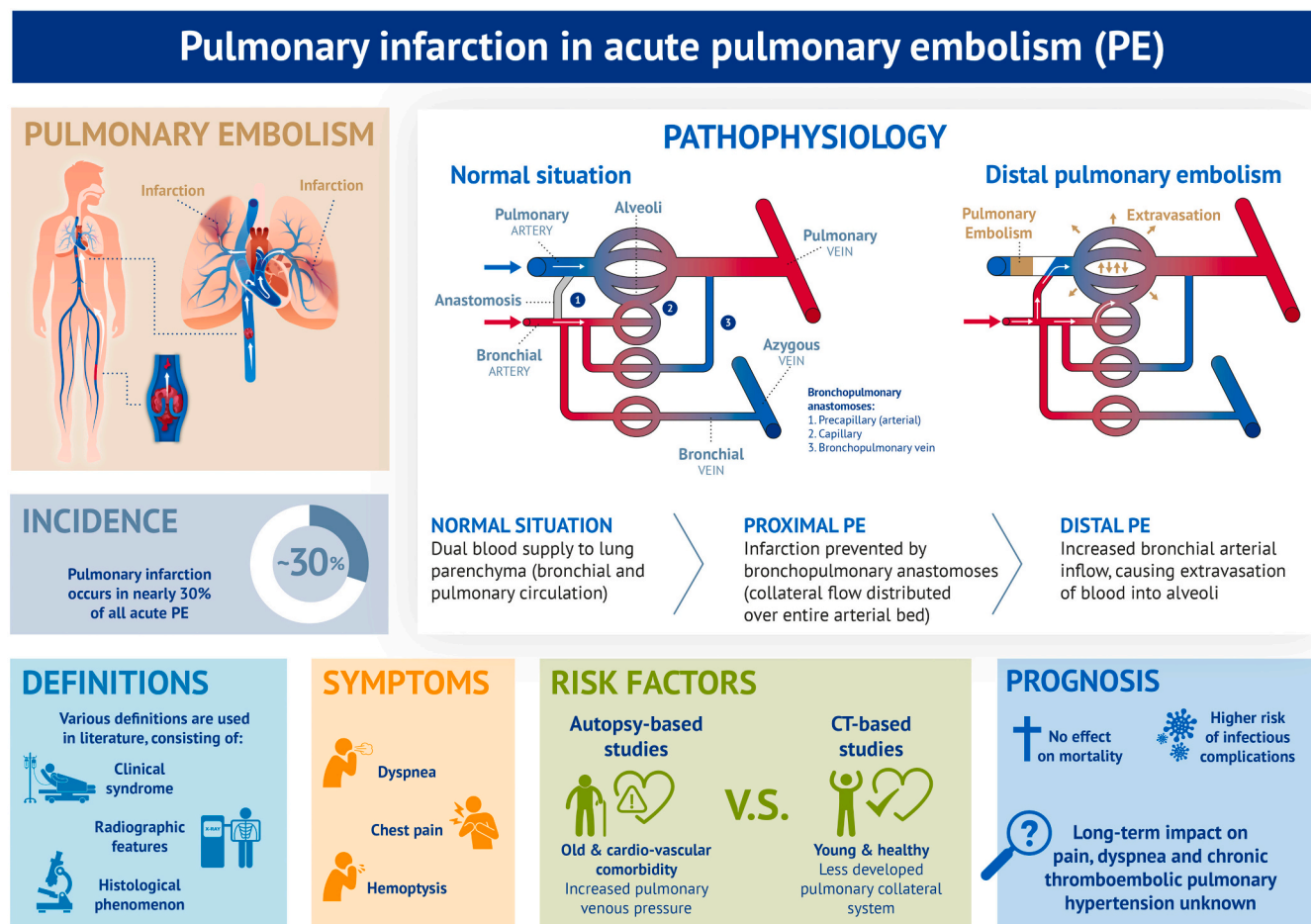


Fig. 1. Central illustration regarding the pathophysiology, epidemiology, symptoms and prognosis of pulmonary infarction in acute pulmonary embolism.

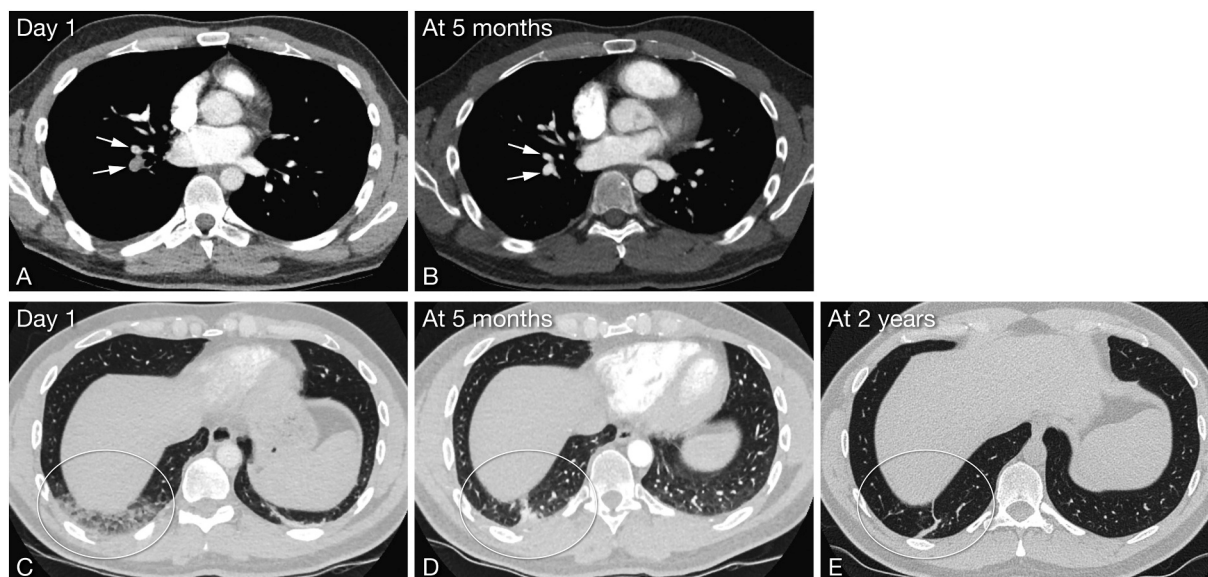


Fig. 2. Pulmonary infarction on computed tomography pulmonary angiography.

1. Computed tomography axial images in soft tissue setting (A, B) and lung setting (C–E). A: Day 1 at presentation, pulmonary embolism in right lower lobe pulmonary arteries. B: 5 months later the pulmonary embolism has resolved. C: Day 1 at presentation, regional consolidation in the posterior segment of the right lower lobe (encircled), and band-like atelectasis in the posterior segment of the left lower lobe. D: 5 months later, residual consolidation in the posterior segment of the right lower lobe as sign of infarction. The atelectasis in the posterior segment of the left lower lobe has resolved. E: At 2 years, residual scar after lung infarction. Note that the residual scar is much smaller than the original consolidation.

hypoperfusion and consequently tissue infarction, pulmonary infarction seems actually rather the result of local hyperperfusion.

Autopsy studies indeed confirmed that most pulmonary infarctions occurred in PE with their most proximal end reaching into smaller (subsegmental) arteries (<3 mm in diameter). (13) More studies found an association with smaller, more distal embolic obstructions and pulmonary infarction, in both histological (12) and radiological (18) pulmonary infarction diagnoses. This corresponds with the finding that pulmonary infarctions are usually adjacent to the pleura.

Following the described pathophysiology, the presence and extent of local collateral circulation was recognized to play a vital role whether or not infarction occurs. (9,11,13) It is thought that, although these bronchopulmonary anastomoses are present in every individual, they are usually not functional in healthy conditions. (13,19) When changes in hydrostatic pressure in the lung vasculature are perceived, for example when the pressure within a pulmonary artery falls considerably distal to an embolic obstruction, it is thought that an increase in bronchial blood flow, together with an increase in vasoactive substances (e.g. nitric oxide) cause these anastomoses to dilate, allowing blood supply by the bronchial circulation. (8,19,20)

1.2. Definition of pulmonary infarction

Although ‘pulmonary infarction’ implies necrosis of lung tissue, the definition of pulmonary infarction in the PE literature is actually heterogeneous. In general, three different types of definitions have been used: a histological phenomenon, a radiological finding and a clinical syndrome, the latter two not necessarily reflecting tissue necrosis.

The histological definition is primarily based on autopsy findings. The classical diagnostic feature of acute pulmonary infarction is a well-defined area of ‘coagulative necrosis’ of lung parenchyma within a zone of hemorrhage, usually adjacent to the pleura. Coagulative necrosis is a morphological pattern, where protein denaturation is the predominant necrotic process with only little enzymatic degradation, leading to longer preserved tissue architecture following cell death (days to weeks). Atypical reactive alveolar lining cells and metaplastic cells adjacent to the infarction are common. The adjacent pleural surface is

frequently covered by a fibrinous exudate (pleuritis). Thrombi may not always be readily recognizable histologically. (10,21,22)

Nowadays, both in the literature and in daily practice, pulmonary infarction is generally diagnosed based on characteristic radiographic features, usually combined with associated clinical symptoms. These latter findings differ between the various imaging modalities, and will be discussed in detail below (see ‘Diagnosis’). (23–25) It is important to realize that in the acute phase of PE, an accurate differentiation between alveolar hemorrhage and true necrosis cannot be made with current imaging studies. (10,11,26) Therefore, if no follow-up imaging is performed to confirm the presence of fibrotic scars, the incidence of pulmonary infarction is overestimated.

In some papers pulmonary infarction refers to a clinical syndrome, as proposed by Stein and colleagues in 1981. They classified the clinical presentation of acute PE in three different ‘syndromes’: 1) pulmonary infarction, characterized by pleuritic pain and/or hemoptysis; 2) circulatory collapse, covering syncope and shock; and 3) isolated dyspnea. Patients were classified into one of these syndromes according to their most severe clinical characteristic. (27) Pleuritic pain and in lesser extent hemoptysis, although with low specificity and sensitivity, indeed correlate to the finding of pulmonary infarction on imaging or autopsy. (11,28,29)

It is evident that these different definitions may cause confusion, and lead to a difficult comparison of the available literature on pulmonary infarction in PE.

1.3. Epidemiology

Acute thromboembolic PE is the most common cause of pulmonary infarction, accounting for around two-thirds of the cases. (21) Other causes of pulmonary infarction include septic or tumor emboli, sickle cell disease, vasculitis or iatrogenic injury (Table 1). (25)

The prevalence of pulmonary infarction in PE varies greatly in literature. Based on autopsy findings, pulmonary infarction is present in 15–68% of patients with PE. (13,30) In CT-based studies, pulmonary infarction has been described to accompany PE in 9–36% of patients. (5,18,28,29,31,32) Notably, these studies were all performed in the

Table 1
Causes of pulmonary infarction.

Intravascular	Embolic infarction	Thromboembolism Septic emboli Tumor thrombi Other emboli: fat, air, amniotic fluid, cement etc.
	In situ occlusive infarction	Sickle cell disease Vasculitis Leukostasis (as in hematologic malignancies) ARDS
	Angioinvasion	Angioinvasive infections (e.g. <i>Aspergillus</i> , <i>Mycobacterium</i>) Malignant invasion
Iatrogenic		Malpositioning of Schwann-Ganz catheters Anastomotic stenosis after lung transplantation
	Pulmonary venous infarction	Radiofrequency ablation of left atrium Fibrosing mediastinitis Post-lung transplantation
Extravascular	Compression	Malignancy (e.g. lung cancer, lymphoma) Aneurysm
	Torsion	Post-thoracic surgery

acute setting, without confirmation by follow-up scans. Pulmonary infarction as a clinical syndrome (according to Steins definition) accounted for 50–65% of all PE cases. (33,34)

Interestingly, an association between the presence of cardiac disease (especially congestive heart failure) and the development of pulmonary infarction has been consistently reported. The proposed underlying mechanism is increased pulmonary venous pressure and decreased forward flow in the bronchial circulation. (11–14) Other described risk factors in the original reports were the presence of shock (13), chronic pulmonary disease (14) and malignancy (13,14). Contrarily, more recent studies have suggested that younger patients without comorbid cardiopulmonary disease are at highest risk for developing pulmonary infarction, because of their less evolved collateral system. (18,28,29) It was suggested that patients with chronic cardiopulmonary diseases have a more developed collateral circulation, due to ischemic reconditioning from an increase in collateral angiogenesis in response to chronic hypoxia, which would protect them against developing pulmonary infarction in acute PE. (29,35) A different hypothesis is that the ability of nitric oxide (NO) production decreases with age, with higher availability of NO being associated with more functional anastomoses with exceeding influx of bronchial flow. (36) Other risk factors for pulmonary infarction in PE that have been described are smoking and increased body height. (28) Smoking causes an inflammatory response and increased permeability of the alveolar-capillary barrier, which is thought to increase the risk of infarction. (21,28) The mechanism that underlies the association with body height is still unclear. (28) Moreover, in addition to being a potential direct cause of pulmonary infarction, sickle cell disease is also a risk factor in developing infarction in PE, as PE leads to hypoxia and vasoconstriction, which induces sickling and retention of sickled red blood cells in the peripheral pulmonary vasculature. (37)

The conflicting risk factors found in historical studies versus more recent literature are likely caused by difference in the applied definition of pulmonary infarction: the original studies were often autopsy studies, where only necrosis of lung parenchyma was included, whereas the recent studies used CT-based diagnoses in the acute phase (with no differentiation between tissue necrosis and alveolar hemorrhage). Furthermore, it was proposed that PE with pulmonary infarction is unlikely to be fatal in patients without comorbidity, as it is associated with small distal emboli. Although this was not studied, it can be argued that otherwise healthy people with distal acute PE are less likely to die from PE and subsequently be less subjected to autopsy than older patients with cardiopulmonary comorbidities who develop PE, which could be a major confounder when studying this association. (11,29,34)

2. Diagnosis

2.1. Clinical symptoms and signs

General symptoms of PE (with or without infarction) include dyspnea, chest pain, syncope, hemoptysis, signs of deep-vein thrombosis (DVT) and palpitations. (27,38–40) For pulmonary infarction in PE, a classical triad of hemoptysis, pleuritic chest pain and a pleural friction rub has been proposed, based on its pathophysiological mechanism. (41) Hemoptysis in PE occurs as a result of the alveolar hemorrhage. Hence, hemoptysis could be expected to be present in almost all PE patients with infarction. It is however only described in 13–19% of the patients with a CT-based diagnosis of pulmonary infarction in PE (5,11,28), and even less in autopsy studies (5%) (21). Since the extravasation of blood into the alveoli may extend to the pleura, inflammation of the (insensitive) visceral pleura causes irritation of the parietal pleura, which leads to pleuritic chest pain and a pleural friction rub. Pleuritic chest pain is indeed the most frequent observed symptom in CT-defined pulmonary infarction in PE, along with dyspnea. It was shown that it does occur more in PE patients with than without infarction: 29% versus 6% respectively in one study (31) and with an odds ratio of 2.9 (95%CI 1.7–5.2) in another (29). The presence of a pleural friction rub in PE with versus without infarction has not yet been properly studied, but one study found a prevalence of 5% in PE patients with infarction, versus no cases in those without infarction. (33) Furthermore, it was described that PE with infarction (based on CT) is less often an incidental finding than PE without infarction (11 vs. 35% respectively). (5) Nevertheless, pulmonary infarction seems to be overrepresented among patients with a delayed PE diagnosis, as it may mimic alternative diagnoses. (42) In distal PE, dyspnea may be absent, and chest wall tenderness may be observed, indicating a musculoskeletal origin. The exact pathogenesis of the latter is unclear, but irritation of the intercostal nerves (innervating both the parietal pleura and thoracic skin) could lead to hyperesthesia in the cutaneous branches, or local pressure to the chest wall during deep palpation could stretch the inflamed parietal pleura and thereby elicit pain. (42,43)

In conclusion, symptoms and findings on physical examination are neither sensitive nor specific for pulmonary infarction. The incidence of the proposed ‘classical triad’ has not been studied but is likely to be seldom found. However, if this triad is present, a PE diagnosis should be considered.

2.2. Imaging studies

Few studies have focused on the diagnostic accuracy of imaging features for pulmonary infarction in the setting of acute PE. We will describe these results in detail for chest radiography, ventilation-perfusion imaging and computed tomography (Table 2).

2.2.1. Chest radiograph

Chest radiographs are abnormal in most cases of pulmonary infarction in PE, but the findings are neither sensitive nor specific. (44) The first described radiologic appearance of pulmonary infarction in PE was the Hampton’s hump: a wedge-shaped consolidation with a convex medial border that is always peripherally arranged along the surface of the visceral pleura. (10) The value of this finding has only been investigated for diagnosing PE (not for pulmonary infarction in PE), with a sensitivity of 24% and specificity of 82% (with pulmonary angiography as diagnostic reference). (45) Atelectasis with elevated hemidiaphragm was found to be indicative of pulmonary infarction in PE (sensitivity 39%, specificity 91%, with autopsy as reference). (46) Furthermore, pleural effusion, especially small and unilateral, is often considered to be the classical chest X-ray finding of pulmonary infarction in PE (sensitivity 18%, specificity 88%, with autopsy as reference). (46,47) The ‘melting sign’ describes the resolution of pulmonary hemorrhage, where the consolidation tends to gradually melt away toward the pleural

Table 2
Imaging modalities for pulmonary infarction in acute pulmonary embolism.

Imaging modality	Findings	Advantages	Disadvantages
Chest radiography	<ul style="list-style-type: none"> – Pleural based consolidation (Hampton's hump) – Pleural effusion – Atelectasis – Elevated hemidiaphragm 	<ul style="list-style-type: none"> – Cheap – Rapid – Widely available – No contrast – Little radiation – Can be performed at bedside 	<ul style="list-style-type: none"> – Non-specific
CT	<ul style="list-style-type: none"> – Hampton's hump – Internal lucency in peripheral consolidation due to necrosis – Presence of an enlarged vessel at the apex of a consolidation ('vessel sign') – Foci of hypo-enhancement in the consolidation – Pleural effusion 	<ul style="list-style-type: none"> – Modality of choice for diagnosing PE – Direct PE diagnosis – Diagnostic for alternative pathology – 3D imaging volume 	<ul style="list-style-type: none"> – Radiation exposure – Contrast medium related complications (allergy, renal failure) – Difficult to perform in instable patients
Dual energy CT/ subtracting CT V/Q scan	<ul style="list-style-type: none"> – Perfusion defect on iodine map with correlating parenchymal, segmental consolidation – 'Triple-match': area of matched ventilation and perfusion defects, corresponding to a radiographic parenchymal opacity 	<ul style="list-style-type: none"> – Detection of smaller vascular occlusions and parenchymal lesions – Can be used for PE diagnosis – No iodine contrast 	<ul style="list-style-type: none"> – Special hardware needed for DECT – Not standardized yet – Non-specific – Radioactive contrast material – Availability dependent on local circumstances

Note: CT: computed tomography; PE: pulmonary embolism; V/Q: ventilation/perfusion; DECT: Dual energy computed tomography.

surface. This differs from other infectious/inflammatory processes that typically resolve in an irregular manner. (48) Of note, the literature discussed in this paragraph is outdated and the level of detail achieved using advanced computed tomography (CT) techniques completely surpasses that of chest radiography. Hence, in current clinical practice chest X-ray has a very limited role in the diagnostic work-up in patients with suspected PE or pulmonary infarction, although it is still often applied preceding CT. (44)

2.2.2. V/Q scintigraphy

The ventilation-perfusion (V/Q) lung scan is a noninvasive technique that has been widely used in the diagnosis of suspected PE for decades, but is nowadays mostly performed in patients with contraindications for CT pulmonary angiography (CTPA). (49) In patients with acute PE without infarction, the ventilation study is usually normal, with absent or decreased perfusion due to the vascular occlusion (i.e. a V/Q mismatch). When PE is complicated by infarction, a 'triple match sign' may be found: a radiographic opacity accompanied by a defect on both the perfusion and ventilation lung scan, which are equal in size to the opacity. (50,51) However, this finding is non-specific, as a 'triple match' can also reflect other parenchymal disorders as atelectasis and pneumonia, which are more common.

2.2.3. Computed tomography

In recent years, CT has become the imaging modality of choice in suspected PE. (38) Several chest CT findings have been evaluated for their ability to diagnose pulmonary infarction. The wedge-shaped, broad pleural-based parenchymal density with convex, bulging borders and linear strand directed from the apex of the density toward the hilum (corresponding with Hampton's hump on chest radiography) has been described to be a 'typical' CT feature of pulmonary infarction. (23,52) However, this finding lacks both sensitivity (52%) and specificity (60%), with a clinico-radiological diagnosis as reference (i.e. peripheral consolidation with adjacent PE with pleuritic pain or hemoptysis). (24) It was reported that 95% of the pulmonary infarctions had foci of diminished enhancement (as a direct reflection of decreased perfusion of the lungs). (31) A central lucency within peripheral consolidation is now thought to be particularly specific for pulmonary infarction (24,31,53), which reflects necrosis with secondary cavitation (24). This finding has a specificity of 98% and a sensitivity of 46% (clinico-radiological diagnosis as reference). (24) Other CT findings described in pulmonary infarction are pleural effusion and atelectasis, comparable with plain chest radiographs. (25,47)

An often used definition of pulmonary infarction in PE on CT is the presence of a peripheral wedge-shaped consolidation in a region of (sub)

segmental PE (Fig. 2). (24) Some argue that demonstration of a thrombus is not required because, as discussed previously, histological studies showed that infarcts usually occur in the setting of emboli in small distal arteries (<3 mm), which may be below the level of detection on CT. (31,47) As many signs of pulmonary infarction on CT do not require contrast administration (except for the visualization of the embolus itself, and the decreased enhancement of the parenchymal opacity), these can be a clue to the diagnosis of PE in non-contrast enhanced CT examinations.

New techniques for pulmonary perfusion imaging are promising for the visualization of pulmonary infarcts and vascular occlusions. (25) Dual Energy CT (using two different X-ray energy spectra) allows to form a conventional CTPA plus a static iodine map. The latter represents a surrogate measure of microvascular circulation and perfusion, and leads to better detection of peripheral occlusions. (54) In the acute phase, the iodine map usually depicts relative oligemia in PE, as is the case in patients with alveolar hemorrhage. In the subacute and chronic phase, pulmonary infarction mostly shows as a complete absence of iodine because of the resulting fibrotic scar. (55) The segmental distribution of the perfusion lesions may aid in the differentiation of infarction from other entities such as pneumonia or tumor. (25) Iodine maps can also be constructed by subtraction CT (subtraction of a low-dose pre-contrast scan from the contrast-enhanced scan), which is thought to give similar results in diagnosing PE (56), but specific assessment of pulmonary infarction has not been studied yet.

3. Treatment and prognosis

There is no specific treatment for pulmonary infarction. The focus should be on treating the underlying acute PE with anticoagulation with supportive care where relevant, including adequate analgesia. As hemoptysis in PE is usually mild to moderate and self-limiting, anticoagulation is not contra-indicated, and can be administered with adequate monitoring. (57,58) Nonsteroidal anti-inflammatory drugs are commonly prescribed as initial therapy for pain control, as they do not suppress the respiratory drive or cough reflex, and may have a beneficial effect on the pleuritic inflammation. However, in severe cases, narcotic analgesics may be required. (59–61)

The clinical and radiological features of pulmonary infarction in PE can be unspecific, and the diagnosis may be incidentally unrecognized or difficult to differentiate from infection or malignancy. (41) The exact frequency of this diagnostic confusion is unknown, as it has not been systematically studied in large cohorts. However, re-evaluations of small patient cohorts with a delayed PE diagnosis and signs of pulmonary infarction showed that 34–52% of the patients were initially diagnosed

with a pneumonia, and 11% with possible/probable lung cancer. (42,62) Especially when patients present with solitary or multiple nodules/masses, with clinical predisposing factors as a smoking history, a malignancy was often suspected. Of note, even the pathological (especially cytological) features of pulmonary infarction may mimic lung cancer: malignant appearing cells in all respiratory secretions can be found, which are thought to reflect reparative hyperplasia in response to hypoxia-mediated cell damage. (63,64) Distinguishing atypical pneumocytes from adenocarcinoma is a well-known challenging problem in pulmonary clinical cytopathology (65), and should always be correlated closely with all available information (clinical, radiological and historical). (64) As the latter can be very unspecific in pulmonary infarction, awareness of this problem is important. (22,66) When a PE diagnosis is considered, cytology should be performed again at a later date. Occasionally, a surgical biopsy is required for the definitive diagnosis. (64)

Several studies assessed the mortality in PE patients with infarction. In pulmonary infarction as a clinical syndrome, a lower in-hospital mortality (0% in pulmonary infarction vs. 25% in circulatory collapse and 14% in isolated dyspnea) (67) and 15-day mortality (2.5% in pulmonary infarction vs. 6.2% in circulatory collapse and 6.7% in isolated dyspnea) (34) were shown as compared to other clinical PE syndromes. As the clinical syndrome is based on pleuritic chest pain and hemoptysis, it is thought that these patients present earlier to medical care, and reflect smaller, more peripheral emboli, explaining the lower mortality. When using a CT-based diagnosis, most studies did not find any difference in in-hospital mortality (5,32,68), 30-day (69) and 90-day mortality (68,70) between PE with or without infarction. The 90-day (based on the clinical syndrome) and 12-month (CT-based diagnosis) incidence of recurrent PE recurrence was the same for PE patients with and without pulmonary infarction. (5,34)

It was reported that about half of the patients diagnosed with infarcts in PE (on angiography) in the acute phase, showed complete clearance of the radiographic lesions, generally within 3 months. This would distinguish alveolar hemorrhage from true infarctions, and may implicate overestimating the infarction incidence if follow-up imaging is not performed. Residual abnormalities on chest radiographs were predominantly linear scars, and to lesser extent pleural diaphragmatic adhesions or localized pleural thickenings. All residual lesions were diminutive compared to the original abnormality. On follow-up perfusion scans, only in 16% of patients complete clearance of infarcts was seen (up to 1-year follow-up). The persisting perfusion defects were considerably smaller than at diagnosis, too, and were thought to have no clinical consequences. (71,72)

Little research has been conducted into the effects of pulmonary infarction on pulmonary function. It was reported that in hypoxemic patients with an acute PE diagnosis, those with infarction (based on chest radiography) had a decreased inspiratory capacity and could not reverse shunting in contrast to those without infarcts. However, these deviations gradually recede over about a month after PE. (20) Unless the infarct is massive, there is little impact on the pulmonary reserve. It is thought that there is no difference whether a lesion heals slowly leaving a peripheral scar (true infarction), or more quickly as the alveolar hemorrhage resolves completely. (31)

Pulmonary infarction may be complicated by cavitation due to necrosis or secondary infection with abscess formation. Cavities may rupture through the visceral pleura, resulting in bronchopleural fistula or pleural empyema in case of infection. The infarcted tissue is an ideal culture medium and may become infected via the tracheobronchial tree or due to circulating organisms if transient bacteremia occurs. (73–75) The prevalence of cavitation in PE-related pulmonary infarction is 3.4–7%. (74–76) The mean time to cavitation has been reported to be 14–18 days. (74,75) The main clinical symptoms are fever, purulent sputum and leukocytosis. Predisposing factors for abscess formation may be larger infarction, coexistent congestion or atelectasis, dental or oropharyngeal infection, positive pressure ventilation, central venous

catheters and an immunocompromised state. (76,77) The incidence of empyema and bronchopleural fistula is unknown, but is thought to be extremely rare nowadays. Some advocate an aggressive surgical approach in management of cavitary infarcts together with antithrombotic treatment. (73) Small lesions without additional complicating factors may be treated with (intensive) medical treatment alone, but in ongoing sepsis or other complications surgery has to be considered. (77)

Studies on the impact of pulmonary infarction in patients with acute PE have focused on mortality, recurrent PE and the occurrence of cavitation and infectious complications. Other patient-relevant outcomes as the need for analgesic drugs, oxygen therapy and hospitalization in PE patients with pulmonary infarction have not been studied yet, nor its impact on quality of life and the incidence of the post-PE syndrome and chronic thromboembolic pulmonary hypertension. (78–80) These topics are important for functional recovery and should be subject of future research.

4. Conclusion

Vascular obstruction of the pulmonary arteries paradoxically leads to local hyperperfusion and alveolar bleeding, which may induce alveolar necrosis and pulmonary infarction. Recognizing pulmonary infarction is relevant as it may be an important diagnostic clue to acute PE, patients may require specific treatment (e.g. analgesia) and the clinical course may be complicated by fever and pain. Furthermore, pulmonary infarction may be complicated by cavitation and abscess formation. However, as the clinical and radiological signs of pulmonary infarction are unspecific, differentiation from alternative diagnoses can be difficult. It is important to realize that ‘infarction’ implicates tissue necrosis, although the term pulmonary infarction in both literature and daily practice is confusingly used in cases of alveolar hemorrhage as well. The diagnosis of ‘true’ infarction can only be confirmed by follow-up imaging.

The impact of pulmonary infarction on mortality and short-term prognosis seems limited in PE, however the long-term effects are largely unknown. Several aspects of pulmonary infarction in acute PE are therefore to be clarified in future studies. In particular, there is a need for the evaluation of the long-term impact of pulmonary infarction on (persistent) pain, dyspnea, post-PE syndrome and chronic thromboembolic pulmonary hypertension.

Declaration of competing interest

Frederikus Klok reports research grants from Bayer, Bristol-Myers Squibb, Boehringer-Ingelheim, MSD, Daiichi-Sankyo, Actelion, the Dutch thrombosis association, The Netherlands Organisation for Health Research and Development and the Dutch Heart foundation. Menno Huisman reports receiving research grants from ZonMW, Boehringer Ingelheim Bayer Health Care and Pfizer-Bristol-Myers Squibb. He has received consultancy and lecture fees from Pfizer-Bristol-Myers Squibb, Boehringer Ingelheim, Bayer Health Care and Aspen. The other authors report no disclosures.

Acknowledgments

None.

Funding

This research did not receive any specific grant from funding agencies in the public, commercial, or not-for-profit sectors.

References

- [1] M.V. Huisman, S. Barco, S.C. Cannegieter, G. Le Gal, S.V. Konstantinides, P. H. Reitsma, et al., Pulmonary embolism, *Nat. Rev. Dis. Primers*. 4 (1) (2018) 18028.
- [2] G.E. Raskob, P. Anghaisuksiri, A.N. Blanco, H. Buller, A. Gallus, B.J. Hunt, et al., Thrombosis: a major contributor to global disease burden, *Thromb. Res.* 134 (5) (2014) 931–938.
- [3] S. Barco, S.H. Mahmoudpour, L. Valerio, F.A. Klok, T. Munzel, S. Middeldorp, et al., Trends in mortality related to pulmonary embolism in the European region, 2000–15: analysis of vital registration data from the WHO mortality database, *Lancet Respir. Med.* 8 (3) (2020) 277–287.
- [4] S. Barco, L. Valerio, W. Ageno, A.T. Cohen, S.Z. Goldhaber, B.J. Hunt, et al., Age-sex specific pulmonary embolism-related mortality in the USA and Canada, 2000–18: an analysis of the WHO mortality database and of the CDC multiple cause of death database, *Lancet Resp Med.* 9 (1) (2021) 33–42.
- [5] S.I. Cha, K.M. Shin, J. Lee, Y. Hwangbo, S.S. Yoo, J. Lee, et al., Clinical relevance of pulmonary infarction in patients with pulmonary embolism, *Thromb. Res.* 130 (3) (2012) e1–e5.
- [6] A. Loer Stephan, W.L. Scheeren Thomas, J. Tarnow, FRCA, How much oxygen does the human lung consume? *Anesthesiology*. 86 (3) (1997) 532–537.
- [7] W.E. Bloomer, W. Harrison, G.E. Lindskog, A.A. Liebow, Respiratory function and blood flow in the bronchial artery after ligation of the pulmonary artery, *Am. J. Phys.* 157 (2) (1949) 317–328.
- [8] K.K. Pump, The bronchial arteries and their anastomoses in the human lung, *Diseases of the chest*. 43 (1963) 245–255.
- [9] R. Virchow, *Gesammelte Abhandlungen zur wissenschaftlichen Medicin*: Meidinger, 1856.
- [10] A. Hampton, Correlation of postmortem chest teleroentgenograms with autopsy findings, with special reference to pulmonary embolism and infarction, *Am. J. Roentgenol.* 43 (1940) 305–325.
- [11] J.E. Dalen, C.I. Haffajee, J.S. Alpert 3rd, J.P. Howe, I.S. Ockene, J.A. Paraskos, Pulmonary embolism, pulmonary hemorrhage and pulmonary infarction, *N. Engl. J. Med.* 296 (25) (1977) 1431–1435.
- [12] D.E. Schraufnagel, M.S. Tsao, Y.T. Yao, N.S. Wang, Factors associated with pulmonary infarction. A discriminant analysis study, *Am. J. Clin. Pathol.* 84 (1) (1985) 15–18.
- [13] M.S. Tsao, D. Schraufnagel, N.S. Wang, Pathogenesis of pulmonary infarction, *Am. J. Med.* 72 (4) (1982) 599–606.
- [14] M. Morpurgo, C. Schmid, The spectrum of pulmonary embolism. Clinicopathologic correlations, *Chest*. 107 (1 Suppl) (1995) 18s–20s.
- [15] C.A. Wagenvoort, Pathology of pulmonary thromboembolism, *Chest*. 107 (1, Supplement) (1995), 10S-7S.
- [16] I. Matot, Y. Manevich, A.-B. Al-Mehdi, C. Song, A.B. Fisher, Fluorescence imaging of lipid peroxidation in isolated rat lungs during nonhypoxic lung ischemia, *Free Radic. Biol. Med.* 34 (6) (2003) 785–790.
- [17] S. Chatterjee, G.F. Nieman, J.D. Christie, A.B. Fisher, Shear stress-related mechanosignaling with lung ischemia: lessons from basic research can inform lung transplantation, *Am. J. Physiol. Lung Cell. Mol. Physiol.* 307 (9) (2014) (L668–L80).
- [18] J. Kirchner, A. Obermann, S. Stuckradt, C. Tushaus, J. Goltz, D. Liermann, et al., Lung infarction following pulmonary embolism: a comparative study on clinical conditions and CT findings to identify predisposing factors, *Rofo*. 187 (6) (2015) 440–444.
- [19] P. Marchand, J.C. Gilroy, V.H. Wilson, An anatomical study of the bronchial vascular system and its variations in disease, *Thorax*. 5 (3) (1950) 207–221.
- [20] J.E. Wilson 3rd, A.K. Pierce, R.L. Johnson Jr., E.R. Winga, W.R. Harrell, G.C. Curry, et al., Hypoxemia in pulmonary embolism, a clinical study, *J. Clin. Invest.* 50 (3) (1971) 481–491.
- [21] J.G. Parambil, C.D. Savci, H.D. Tazelaar, J.H. Ryu, Causes and presenting features of pulmonary infarctions in 43 cases identified by surgical lung biopsy, *Chest*. 127 (4) (2005) 1178–1183.
- [22] C.J. George, H.D. Tazelaar, S.J. Swensen, J.H. Ryu, Clinicoradiological features of pulmonary infarctions mimicking lung cancer, *Mayo Clin. Proc.* 79 (7) (2004) 895–898.
- [23] H. Ren, J.E. Kuhlman, R.H. Hruban, E.K. Fishman, P.S. Wheeler, G.M. Hutchins, CT of inflation-fixed lungs: wedge-shaped density and vascular sign in the diagnosis of infarction, *J. Comput. Assist. Tomogr.* 14 (1) (1990) 82–86.
- [24] M.P. Revel, R. Triki, G. Chatellier, S. Couchon, N. Haddad, A. Hernigou, et al., Is it possible to recognize pulmonary infarction on multisection CT images? *Radiology*. 244 (3) (2007) 875–882.
- [25] T.J.P. Bray, K.H. Mortensen, D. Gopalan, Multimodality imaging of pulmonary infarction, *Eur. J. Radiol.* 83 (12) (2014) 2240–2254.
- [26] R.S. Fraser, L.N. Müller, N. Colman, P.D. Paré, Fraser and Paré's *Diagnosis of Diseases of the Chest*, 4th ed., 1999. Saunders. Philadelphia. (1773–843).
- [27] P.D. Stein, P.W. Willis 3rd, D.L. DeMets, History and physical examination in acute pulmonary embolism in patients without preexisting cardiac or pulmonary disease, *Am. J. Cardiol.* 47 (2) (1981) 218–223.
- [28] M. Miniati, M. Bottai, C. Ciccotosto, L. Roberto, S. Monti, Predictors of pulmonary infarction, *Medicine (Baltimore)* 94 (41) (2015), e1488.
- [29] M. Islam, J. Filopei, M. Frank, N. Ramesh, S. Verzosa, M. Ehrlich, et al., Pulmonary infarction secondary to pulmonary embolism: an evolving paradigm, *Respirology*. 23 (9) (2018) 866–872.
- [30] D.G. Freiman, J. Suyemoto, S. Wessler, Frequency of pulmonary thromboembolism in man, *N. Engl. J. Med.* 272 (24) (1965) 1278–1280.
- [31] H. He, M.W. Stein, B. Zalta, L.B. Haramati, Pulmonary infarction: spectrum of findings on multidetector helical CT, *J. Thorac. Imaging* 21 (1) (2006) 1–7.
- [32] C.M. Heyer, S.P. Lemburg, H. Knoop, T. Holland-Letz, V. Nicolas, D. Roggenland, Multidetector-CT angiography in pulmonary embolism-can image parameters predict clinical outcome? *Eur. Radiol.* 21 (9) (2011) 1928–1937.
- [33] P.D. Stein, J.W. Henry, Clinical characteristics of patients with acute pulmonary embolism stratified according to their presenting syndromes, *Chest*. 112 (4) (1997) 974–979.
- [34] J.L. Lobo, V. Zorrilla, F. Aizpuru, F. Uresandi, F. Garcia-Bragado, F. Conget, et al., Clinical syndromes and clinical outcome in patients with pulmonary embolism: findings from the RIETE registry, *Chest*. 130 (6) (2006) 1817–1822.
- [35] A.B. Malik, S.E. Tracy, Bronchovascular adjustments after pulmonary embolism, *J. Appl. Physiol.* 49 (3) (1980) 476–481.
- [36] A.C. Torregrossa, M. Aranke, N.S. Bryan, Nitric oxide and geriatrics: implications in diagnostics and treatment of the elderly, *J. Geriatr. Cardiol.* 8 (4) (2011) 230–242.
- [37] D.R. Lakkireddy, R. Patel, K. Basarakodu, J. Vacek, Fatal pulmonary artery embolism in a sickle cell patient: case report and literature review, *J. Thromb. Thrombolysis* 14 (1) (2002) 79–83.
- [38] M.V. Huisman, F.A. Klok, How I diagnose acute pulmonary embolism, *Blood*. 121 (22) (2013) 4443–4448.
- [39] M.V. Huisman, F.A. Klok, Diagnostic management of acute deep vein thrombosis and pulmonary embolism, *J. Thromb. Haemost.* 11 (3) (2013) 412–422.
- [40] M.V. Huisman, S. Barco, S.C. Cannegieter, G. Le Gal, S.V. Konstantinides, P. H. Reitsma, et al., Pulmonary embolism, *Nat Rev Dis Primers*. 4 (2018) 18028.
- [41] M. Miniati, Pulmonary infarction: an often unrecognized clinical entity, *Semin. Thromb. Hemost.* 42 (8) (2016) 865–869.
- [42] J. Torres-Macho, A.B. Mancebo-Plaza, A. Crespo-Giménez, M.R.S. de Barros, C. Bibiano-Guillén, R. Fallos-Martí, et al., Clinical features of patients inappropriately undiagnosed of pulmonary embolism, *Am. J. Emerg. Med.* 31 (12) (2013) 1646–1650.
- [43] I. Dreyfuss, D.S. Weiland, [ill]est wall tenderness as a [ill]tfall in the diagnosis of [ill]lmonary embolism: Report of Two Cases, *Arch. Intern. Med.* 144 (10) (1984) 2057.
- [44] L.M. van der Pol, C. Tromeur, L.M. Faber, T. van der Hulle, L.J.M. Kroft, A.T. A. Mairuhu, et al., Chest X-ray not routinely indicated prior to the years algorithm in the diagnostic management of suspected pulmonary embolism, *TH Open*. 3 (1) (2019) (e22–e7).
- [45] D.F. Worsley, A. Alavi, J.M. Aronchick, J.T. Chen, R.H. Greenspan, C.E. Ravin, Chest radiographic findings in patients with acute pulmonary embolism: observations from the PIOPED study, *Radiology*. 189 (1) (1993) 133–136.
- [46] S. Talbot, B.S. Worthington, E.J. Roebuck, Radiographic signs of pulmonary embolism and pulmonary infarction, *Thorax*. 28 (2) (1973) 198–203.
- [47] L.A. Latson, A. Godelman, L.B. Haramati, Imaging of pulmonary infarction, *Clin. Pulm. Med.* 17 (6) (2010) 282–289.
- [48] M.E. Woensler, I. Sanders, G.W. White, The melting sign in resolving transient pulmonary infarction, *Am. J. Roentgenol. Radium Therapy, Nucl. Med.* 111 (4) (1971) 782–790.
- [49] R. da Silva, M. Shah, L.M. Freeman, Ventilation-perfusion (V/Q) lung scintigraphy: a long journey to a renewed position of prominence in diagnosing pulmonary embolism, *Clin. Transl. Imaging*. 2 (5) (2014) 369–378.
- [50] D.F. Worsley, C.K. Kim, A. Alavi, H.I. Palevsky, Detailed analysis of patients with matched ventilation-perfusion defects and chest radiographic opacities, *J. Nucl. Med.* 34 (11) (1993) 1851–1853.
- [51] C.K. Kim, D.F. Worsley, A. Alavi, Ventilation-perfusion-chest radiograph match is less likely to represent pulmonary embolism if perfusion is decreased rather than absent, *Clin. Nucl. Med.* 25 (9) (2000) 665–669.
- [52] A.A. Shah, S.D. Davis, G. Gamsu, L. Intriери, Parenchymal and pleural findings in patients with and patients without acute pulmonary embolism detected at spiral CT, *Radiology*. 211 (1) (1999) 147–153.
- [53] J. Balakrishnan, M.A. Mezziane, S.S. Siegelman, E.K. Fishman, Pulmonary infarction: CT appearance with pathologic correlation, *J. Comput. Assist. Tomogr.* 13 (6) (1989) 941–945.
- [54] A. Gorgos, M. Remy-Jardin, A. Duhamel, J.B. Faivre, N. Tacelli, V. Delannoy, J. Remy, Evaluation of peripheral pulmonary arteries at 80 kV and at 140 kV: dual-energy computed tomography assessment in 51 patients, *J. Comput. Assist. Tomogr.* 33 (6) (2009) 981–986.
- [55] X. Chai, L.J. Zhang, B.M. Yeh, Y.E. Zhao, X.B. Hu, G.M. Lu, Acute and subacute dual energy CT findings of pulmonary embolism in rabbits: correlation with histopathology, *Br. J. Radiol.* 85 (1013) (2012) 613–622.
- [56] D. Grob, E. Smit, J. Prince, J. Kist, L. Stöger, B. Geurts, et al., Iodine maps from subtraction CT or dual-energy CT to detect pulmonary emboli with CT angiography: a multiple-observer study, *Radiology*. 292 (1) (2019) 197–205.
- [57] S. Garwood, C. Strange, S.A. Sahn, Chapter 47 - massive hemoptysis, in: J. E. Parrillo, R.P. Dellinger (Eds.), *Critical Care Medicine*, Third edition, Mosby, Philadelphia, 2008, pp. 929–948.
- [58] V.F. Tapson, A.S. Weinberg, Treatment, Prognosis, and Follow-up of Acute Pulmonary Embolism in Adults: UpToDate, Waltham, MA, Accessed on March 3, 2021.
- [59] B.V. Reamy, P.M. Williams, M.R. Odom, Pleuritic chest pain: sorting through the differential diagnosis, *Am. Fam. Physician* 96 (5) (2017) 306–312.
- [60] P.V. Sacks, D. Kanarek, Treatment of acute pleuritic pain. Comparison between indomethacin and a placebo, *Am. Rev. Respir. Dis.* 108 (3) (1973) 666–669.
- [61] R.W. Lee, L.E. Hodgson, M.B. Jackson, N. Adams, Problem based review: pleuritic chest pain, *Acute Med.* 11 (3) (2012) 172–182.
- [62] M. Miniati, A 48-year-old man with a pleural-based consolidation, *CMAJ*. 185 (12) (2013) 1059–1062.

- [63] D.A. Kaminsky, G. Leiman, False-positive sputum cytology in a case of pulmonary infarction, *Respir. Care* 49 (2) (2004) 186–188.
- [64] W.G. Scoggins, R.H. Smith, W.J. Frable, W.J. O'Donohue Jr., False-positive cytological diagnosis of lung carcinoma in patients with pulmonary infarcts, *Ann. Thorac. Surg.* 24 (5) (1977) 474–480.
- [65] W.W. Johnston, I.I. Type, Pneumocytes in cytologic specimens: a diagnostic dilemma, *Am. J. Clin. Pathol.* 97 (5) (1992) 608–609.
- [66] S.A. Yousem, The surgical pathology of pulmonary infarcts: diagnostic confusion with granulomatous disease, vasculitis, and neoplasia, *Mod. Pathol.* 22 (5) (2009) 679–685.
- [67] A. Ghuyens, B. Ghaye, V. Willems, B. Lambermont, P. Gerard, R.F. Dondelinger, et al., Computed tomographic pulmonary angiography and prognostic significance in patients with acute pulmonary embolism, *Thorax*. 60 (11) (2005) 956–961.
- [68] T. Chengsupanimit, B. Sundaram, W.B. Lau, S.W. Keith, G.C. Kane, Clinical characteristics of patients with pulmonary infarction - a retrospective review, *Respir. Med.* 139 (2018) 13–18.
- [69] H.S. Sen, Ö. Abakay, M.G. Cetincakmak, C. Sezgi, S. Yilmaz, M. Demir, et al., A single imaging modality in the diagnosis, severity, and prognosis of pulmonary embolism, *Biomed Res. Int.* 2014 (2014), 470295.
- [70] N. Akhouni, T.F. Langroudi, H. Rajebi, S. Haghi, M. Paraham, S. Karami, et al., Computed tomography pulmonary angiography for acute pulmonary embolism: prediction of adverse outcomes and 90-day mortality in a single test, *Pol. J. Radiol.* 84 (2019) (e436-e46).
- [71] P.J. McGoldrick, T.G. Rudd, M.M. Figley, J.P. Wilhelm, What becomes of pulmonary infarcts? *Am. J. Roentgenol.* 133 (6) (1979) 1039–1045.
- [72] A.A. Frazier, J.R. Galvin, T.J. Franks, M.L. Rosado-de-Christenson, From the archives of the AFIP, *RadioGraphics*. 20 (2) (2000) 491–524.
- [73] I.A. May, P.C. Samson, A. Mittal, Surgical management of the patient with complications of pulmonary infarction due to nonseptic pulmonary emboli, *Am. J. Surg.* 124 (2) (1972) 223–228.
- [74] L.S. Libby, T.E. King, F.M. LaForce, M.I. Schwarz, Pulmonary cavitation following pulmonary infarction, *Medicine (Baltimore)* 64 (5) (1985) 342–348.
- [75] A.G. Wilson, A.E. Joseph, R.J. Butland, The radiology of aseptic cavitation in pulmonary infarction, *Clin. Radiol.* 37 (4) (1986) 327–333.
- [76] Levin L, Kernohan JW, Moersch HJ. Pulmonary abscess secondary to bland pulmonary infarction. *Diseases of the Chest*. 14(2):218-32.
- [77] M.D. Butler, F.H. Biscardi, D.C. Schain, J.E. Humphries, O. Blow, W.D. Spotnitz, Pulmonary resection for treatment of cavitary pulmonary infarction, *Ann. Thorac. Surg.* 63 (3) (1997) 849–850.
- [78] F.A. Klok, T. van der Hulle, P.L. den Exter, M. Lankeit, M.V. Huisman, S. Konstantinides, The post-PE syndrome: a new concept for chronic complications of pulmonary embolism, *Blood Rev.* 28 (6) (2014) 221–226.
- [79] A.K. Sista, F.A. Klok, Late outcomes of pulmonary embolism: the post-PE syndrome, *Thromb. Res.* 164 (2018) 157–162.
- [80] G. Boon, S. Barco, L. Bertolotti, W. Ghanima, M.V. Huisman, S.R. Kahn, et al., Measuring functional limitations after venous thromboembolism: optimization of the post-VTE functional status (PVFS) scale, *Thromb. Res.* 190 (2020) 45–51.