



**Universiteit
Leiden**
The Netherlands

Developing and validating the Cutaneous WARTS (CWARTS) diagnostic tool: a novel clinical assessment and classification system for cutaneous warts

Hogendoorn, G.K.; Bruggink, S.C.; Hermans, K.E.; Kouwenhoven, S.T.P.; Quint, K.D.; Wolterbeek, R.; ... ; Bavinck, J.N.B.

Citation

Hogendoorn, G. K., Bruggink, S. C., Hermans, K. E., Kouwenhoven, S. T. P., Quint, K. D., Wolterbeek, R., ... Bavinck, J. N. B. (2018). Developing and validating the Cutaneous WARTS (CWARTS) diagnostic tool: a novel clinical assessment and classification system for cutaneous warts. *British Journal Of Dermatology*, 178(2), 527-534. doi:10.1111/bjd.15999

Version: Not Applicable (or Unknown)
License: [Leiden University Non-exclusive license](#)
Downloaded from: <https://hdl.handle.net/1887/95957>

Note: To cite this publication please use the final published version (if applicable).

Developing and validating the Cutaneous WARTS (CWARTS) diagnostic tool: a novel clinical assessment and classification system for cutaneous warts*

G.K. Hogendoorn,¹ S.C. Bruggink,² K.E. Hermans,² S.T.P. Kouwenhoven,^{3,4} K.D. Quint,^{3,4} R. Wolterbeek,⁵ J.A.H. Eekhof,² M.N.C. de Koning,⁶ R. Rissmann,¹ J. Burggraaf¹ and J.N. Bouwes Bavinck^{1,3}

¹Centre for Human Drug Research, Leiden, the Netherlands

Departments of ²Public Health and Primary Care, ³Dermatology and ⁵Medical Statistics and Bioinformatics, Leiden University Medical Centre, Leiden, the Netherlands

⁴Department of Dermatology, Roosevelt Clinics, Leiden, the Netherlands

⁶DDL Diagnostic Laboratory, Rijswijk, the Netherlands

Linked Comment: Micali and Lacarrubba. *Br J Dermatol* 2018; 178:330.

Summary

Correspondence

Jan N. Bouwes Bavinck.

E-mail: j.n.bouwes_bavinck@lumc.nl

Accepted for publication

14 July 2017

Funding sources

The authors received funding from The Dutch Organisation for Health Research and Development (ZonMw). ZonMw had no influence on the analysis and writing of the paper.

Conflicts of interest

None declared.

*Plain language summary available online

DOI 10.1111/bjd.15999

Background The clinical appearance of cutaneous warts is highly variable and not standardized.

Objectives To develop and validate a reproducible clinical tool for the standardized assessment of cutaneous warts to distinguish these lesions accurately.

Methods Nine morphological characteristics were defined and validated regarding intra- and interobserver agreement. Based on literature and semistructured interviews, a systematic dichotomous assessment tool, the Cutaneous WARTS (CWARTS) diagnostic tool was developed. The validation consisted of two independent parts performed with photographs from the recent WARTS-2 trial. In part A, the CWARTS diagnostic tool was tested by 28 experienced physicians who assessed photographs of 10 different warts to investigate interobserver concordance. In part B, morphological characteristics were validated by masked and independent scoring of 299 photographs by six different observers. Part B also entailed reassessment of the photographs after at least 1 week. The primary outcome measurement was the intraclass correlation coefficient (ICC).

Results Presence of black dots (capillary thrombosis) had the greatest ICC (0.85) for interobserver agreement in part A, followed by arrangement (0.65), presence of border erythema (0.64) and sharpness of the border (0.60). In part B, results were similar for interobserver agreement with presence of black dots having the highest ICC (0.68), followed by border erythema (0.64), arrangement (0.58) and colour (0.55). For intraobserver agreement, presence of black dots had the highest agreement (0.70), followed by presence of border erythema (0.694) and colour (0.59).
Conclusions Wart phenotype can be reliably assessed using the CWARTS diagnostic tool.

What's already known about this topic?

- Cutaneous warts are a major public health concern because of their high prevalence, recurrence and only moderately effective treatment options.
- Warts are characterized by a wide spectrum of morphological features.

What does this study add?

- Improved agreement among healthcare providers on the definition of warts and clinical classification was established.

- This study introduces and validates the Cutaneous WARTS (CWARTS) diagnostic tool, a new clinical diagnostic tool for warts.
- The CWARTS diagnostic tool will improve head-to-head comparisons of alternative treatment strategies in future studies.

Cutaneous warts are a common ailment in both children and adults with a high prevalence of 3%–13% in the general population,^{1–3} and up to 33% in primary school children.⁴ Although they are benign and resolve spontaneously, they may grow into fulminant masses that persist for months to years, which affects quality of life. Moderate to extreme discomfort is reported in 52% of patients and in 34% social and leisure activities are affected.⁵ Warts are caused by human papillomaviruses (HPV) that inoculate the viable epidermis via defects in the epidermis. To date, over 350 different HPV genotypes have been established.⁶ After infection, warts appear as hyperkeratotic papillomas within 2–9 months. One can distinguish common warts, plantar warts, flat warts, filiform warts, periungual warts and genital warts. In this study we focused on common and plantar warts, and periungual warts were also included in the study.

The clinical appearance of common and plantar warts varies depending on the HPV-genotype and clinical location.⁷ Common warts are described as elevated, scaly, rough, brown- to skin-coloured, spiny papules or nodules and plantar warts as thick, endophytic, hyperkeratotic, papules with capillary thrombosis.⁸

In order to describe cutaneous warts in detail, a dedicated tool would be helpful for classification purposes. Some time ago, Jablonska *et al.* attempted to develop a clinical classification of warts, in order to enhance the prediction of natural course and treatment outcomes.⁸ However, constructive supportive data for this classification system were lacking and, therefore, this classification system was not generally accepted nor used extensively.

In order to create a classification system, morphological characteristics need to be validated thoroughly and the tool needs to withstand testing in clinical practice. As no standardized tool to evaluate and describe common and plantar warts accurately is currently available we aimed to develop such a novel clinical tool for the phenotypical assessment of cutaneous warts. Morphological characteristics of wart lesions were defined and explored in a small exploratory study, referred to as a pilot, with a small set of photographs for interobserver concordance. Subsequently, the characteristics were validated in a much larger set of photographs and validated for intra- and interobserver agreement.

Materials and methods

Development of the clinical assessment tool

As available literature did not provide a systematic approach to describe warts clinically, we first aimed to define accurately

specific morphological characteristics, using the Dutch 'PRO-VOKE' systematic approach to describe skin lesions (File S1, Appendix S1; see Supporting Information). Based on descriptive studies,⁸ systematic approaches to other dermatologic diseases^{9–11} and semistructured interviews with experienced clinicians, a list of wart characteristics was defined (Table S1; see Supporting Information). The semistructured interviews resulted in a list of possible criteria for the diagnoses of warts (Table S2; see Supporting Information). These criteria were used in pilots with two general practitioners (GPs) and one dermatologist and resulted in the selection of 11 characteristics (Fig. S1; see Supporting Information). Final selection of appropriate wart characteristics was performed by the two GPs and one dermatologist (Fig. 1). Based on this selection, a clinical diagnostic and classification tool was developed called the Cutaneous WARTS (CWARTS) diagnostic tool, which was subsequently validated in two parts.

Source of photographs

For the purpose of this study, digital photographs from the WARTS-2 trial were obtained from a representative subpopulation (356 warts in 164 patients). The WARTS-2 trial was a multicentre, randomized trial to investigate the treatment of cutaneous warts in primary care that has been reported in detail by Bruggink *et al.*¹² Warts more than 1 cm in diameter were excluded and all other inclusion and exclusion criteria and the protocol specification can be found elsewhere.¹²

Photographs of warts were obtained after informed consent from the patient at baseline using the Dino-Lite digital microscope (ANMO Electronics Corporation, Hsinchu City, Taiwan), set to a fixed scale of 20 (resulting in a scale of 5.7 : 1). Photographs were printed on photo quality paper size A7 and assessed for morphological characteristics. The study was approved by the medical ethical committee of the Leiden University Medical Centre and conducted in accordance with the principles of the Declaration of Helsinki (version 2008) and the Medical Research Involving Human Subjects Act.

Validation of the clinical assessment tool

Validation of the characteristics consisted of two parts. Part A was an initial exploratory study with 28 physicians. In total, 18 dermatologists (eight consultants and 10 dermatology registrars) and 10 GPs with different backgrounds assessed 10 different standardized photographs of warts independently (five common and five plantar warts) to test the initial set of morphological characteristics and their concordance. All observers were given a short training session with example

	A	B	Example 1	Example 2	Wart 1	Wart 2	Wart 3	Wart 4	Wart 5	Wart 6	Wart 7	Wart 8	Wart 9	Wart 10
1. Arrangement	<i>Solitary</i>	<i>Confluent</i>	A	B										
2. Level	<i>Elevated</i>	<i>Skin level</i>	B	B										
3. Aspect	<i>Lobes/Rough</i>	<i>Not lobed/Smooth</i>	B	A										
4. Border	<i>Sharp</i>	<i>Not sharp</i>	A	B										
5. White skin flakes	<i>Yes</i>	<i>No</i>	B	A										
6. Black dots	<i>Yes</i>	<i>No</i>	B	A										
7. Colour	<i>Skin colour/Light/Yellow</i>	<i>Red</i>	A	A										
8. Border erythema	<i>Yes</i>	<i>No</i>	A	B										
9. Callus	<i>Yes</i>	<i>No</i>	B	A										
Comments:														

Fig 1. Clinical assessment form for physicians in part A of the study using the final version of the Cutaneous WARTS (CWARTS) diagnostic tool.

photographs with a variety of characteristics (Fig. 2). A two-way random intraclass correlation coefficient (ICC) with absolute agreement and 95% confidence interval was calculated to assess interobserver agreement. The P-values were two-sided and the alpha level was set at 0.05. All statistics were performed using IBM SPSS Statistics version 23 (IBM, Armonk, NY, U.S.A.).

In part B, 299 standardized wart photographs from the WART2-trial were blindly and independently assessed by six researchers with different medical backgrounds but all with clinical experience; a GP, a trained medical student, a trained research physician, a dermatology registrar and two dermatologists. Three observers from part A participated in the second part and had prior training, and the other three observers had received minimal training prior to the electronic wart assessment with the novel tool.

Interobserver agreement and 95% confidence interval between all six researchers were assessed using a two-way random ICC with absolute agreement. The ICC is used to assess the consistency, or conformity, of measurements made by multiple observers measuring the same quantity. In addition, intraobserver agreement was calculated, from four researchers, using a three-way (partially nested) random ICC with absolute agreement. The 95% confidence intervals and P-values were calculated with a delta method manually derived estimator of the standard error of the Fisher z-transformed intraobserver ICC.

Results

Development phase

Eleven characteristics of warts with binary scoring options were defined, of which two characteristics had to be measured objectively at baseline: size and periungual location. The nine

other characteristics were subjected to individual interpretation, i.e. arrangement (confluent/solitary), level (skin level/elevated), aspect (lobed or rough/not lobed or smooth), border (sharp/not sharp), white skin flakes (yes/no), black dots (capillary thrombosis, yes/no), colour [not red (skin colour/light/yellow)/red], border erythema (yes/no) and callus (yes/no). These nine characteristics were elaborated into a binary diagnostic model, which was assessed using standardized photographs of warts (Figs 1 and 2).

Validation part A: interobserver agreement exploratory study

The results of the initial, exploratory validation study are detailed in Table 1. Presence of black dots (capillary thrombosis) had an excellent agreement for both common and plantar warts, with ICCs, respectively, being 0.85 and 0.82. For sharpness of the border the agreement for both common (ICC 0.59) and plantar warts (ICC 0.42) was moderate. Arrangement (ICC 0.65), border erythema (ICC 0.64), aspect (ICC 0.60) and white skin flakes (ICC 0.51) were all characteristics with a moderate to strong agreement, but only when common and plantar warts were taken together. If the assessments of these characteristics were analysed for common and plantar warts, separately, the ICC was much lower, because of the low variance among these characteristics in the two separate wart groups. The small sample set also had limitations for some other characteristics, callus, colour and level, that cannot be interpreted correctly because of lack of variance.

Validation part B study population demographics, inter- and intraobserver agreement

For part B, 356 warts from 164 patients were photographed, representing 72% of all their warts. Fifteen photographs

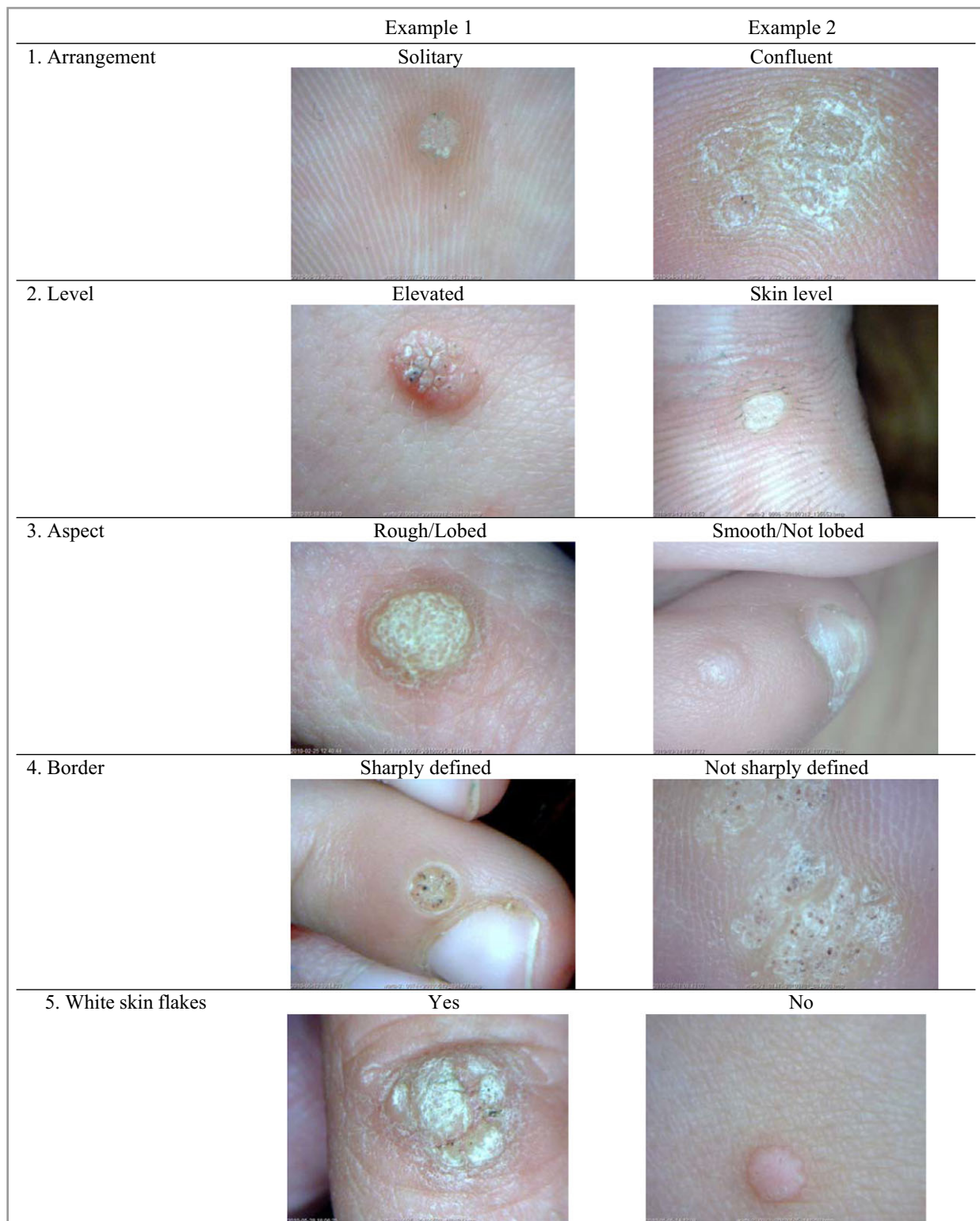


Fig 2. Examples of characteristics.

(4.2%), were excluded as a result of poor photo quality and 42 photographs were not used because they showed multiple warts on the same photograph, leaving a total of 299 photographs for analysis.

On average patients had 3.05 ± 2.8 warts. Of the 157 patients with complete data, 98 (62.4%) patients were female and 59 (37.6%) male. The mean age was 22.8 ± 18.1 years with a median of 15.0 years. The warts

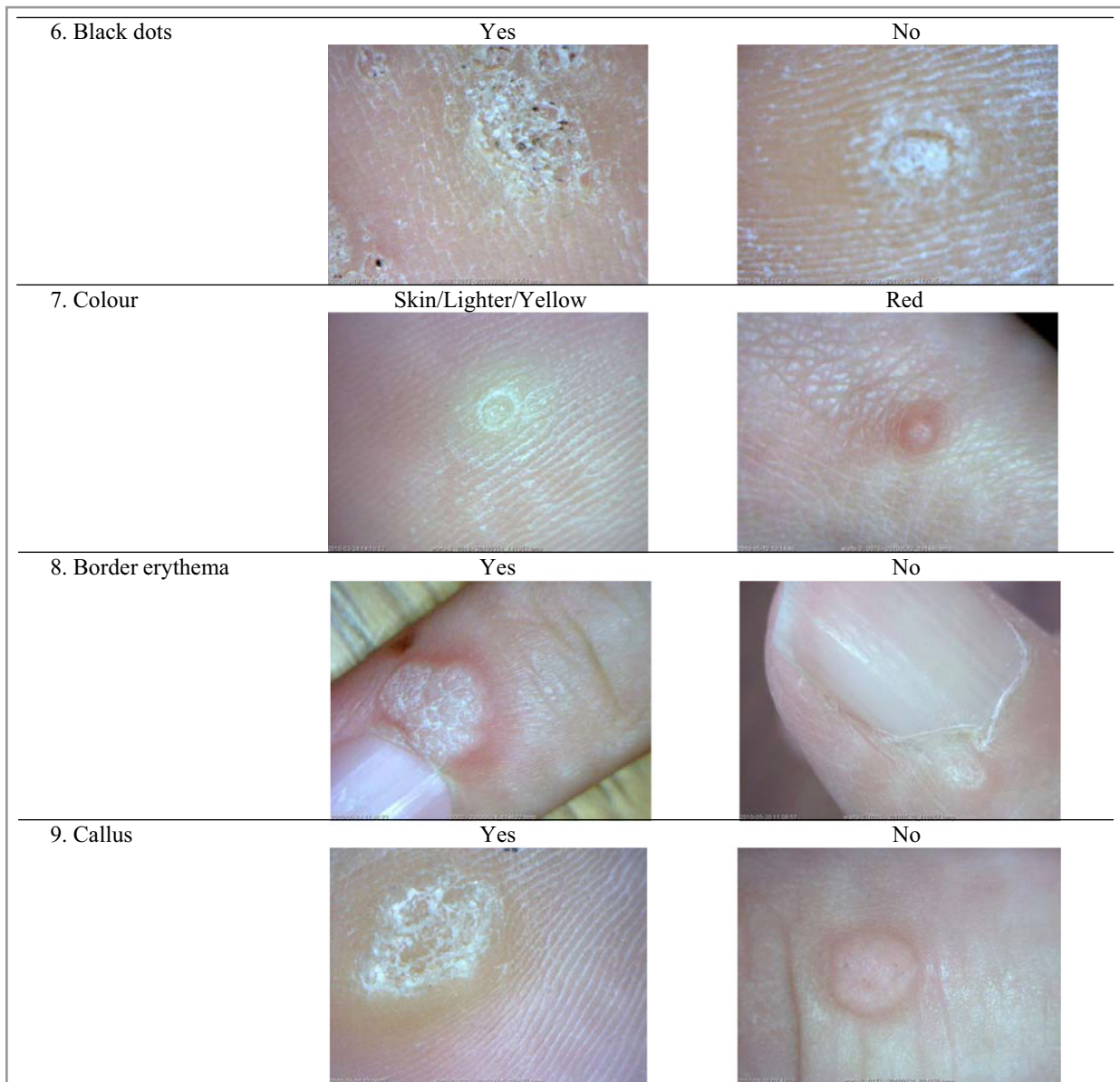


Fig 2. Continued

were equally distributed over both locations with 47% common and 53% plantar warts. Of the common warts, 45% were located on the dorsum of the hands, 23% on the palmar side of the hands, 17% on the dorsum of the feet and 15% elsewhere.

In total, 1794 observations from six different researchers of 299 warts were compared in order to investigate interobserver agreement using intraclass coefficients. Results for interobserver agreement are shown in Table 2. Agreement differed per characteristic and also per location. In general, agreement in common warts was slightly higher than in plantar warts, with a mean ICC of 0.47 and 0.38, respectively.

A strong interobserver agreement was found for black dots (ICC 0.68) and border erythema (ICC 0.64). Observers had moderate agreement on arrangement (0.58), colour (ICC

0.55), aspect (ICC 0.48) and white skin flakes (ICC 0.46). Level (ICC 0.26), border (ICC 0.16) and callus (ICC 0.02) had only slight to fair agreement. Altogether there was a moderate to strong interobserver agreement for six out of nine characteristics when common warts were considered and for five out of nine characteristics when plantar warts were considered (Table 2).

In order to investigate intraobserver agreement, four observers scored 299 warts twice with a 1- to 7-week interval (2392 observations in total). ICCs were calculated and results are shown in Table 3. Overall ICC for all observers was 0.50, with individual ICCs ranging from 0.54 to 0.96. In general, researchers were slightly more consistent in their assessment of common warts (mean ICC 0.67) than plantar warts (mean ICC 0.49), except for the characteristic aspect.

Table 1 Validation part A, interobserver agreement among 28 physicians (n = 10 warts)^a

Characteristic	All common warts (n = 140)			All plantar warts (n = 140)			Total (n = 280)		
	A	B	ICC (95% CI)	A	B	ICC (95% CI)	A	B	ICC (95% CI)
Arrangement (A: solitary, B: confluent)	135	5	0.04 (-0.02-0.99)	103	37	0.17 (0.03-0.90)**	238	42	0.65 (0.45-0.86)**
Level (A: elevated, B: skin level)	127	13	0.00 (-0.03-0.62)	93	47	0.22 (0.05-0.93)**	220	60	0.20 (0.09-0.48)**
Aspect (A: lobes/rough, B: not lobed/smooth)	86	54	0.66 (0.26-1.0)**	124 ^c	15 ^c	0.02 (-0.01-0.92)	210 ^d	69 ^d	0.60 (0.39-0.85)**
Border (A: sharp, B: not sharp)	122	18	0.59 (0.20-0.99)**	87	53	0.42 (0.14-0.97)**	209	71	0.60 (0.40-0.83)**
White skin flakes (A: yes, B: no)	76	64	0.00 (-0.05-0.96)	113	27	0.54 (0.22-0.98)**	189	91	0.51 (0.31-0.78)**
Black dots (A: yes, B: no)	53	87	0.85 (0.51-1.0)**	107	33	0.82 (0.54-0.99)**	160	120	0.85 (0.72-0.95)**
Colour (A: skin colour/light/yellow, B: red)	103 ^b	32 ^b	0.11 (-0.01-0.99)	112 ^c	27 ^c	0.41 (0.09-0.99)**	215 ^e	59 ^e	0.35 (0.17-0.70)**
Border erythema (A: yes, B: no)	49 ^c	90 ^c	0.00 (-0.04-0.92)	23	117	0.00 (-0.03-0.59)	72 ^d	207 ^d	0.64 (0.45-0.86)**
Callus (A: yes, B: no)	60	80	0.01 (-0.03-0.98)	117	23	0.15 (0.02-0.89)**	177	103	0.30 (0.15-0.60)**

CI, confidence interval. ^aTwo-way random intraclass correlation (ICC), type absolute agreement. < 0 less than chance agreement; 0.01-0.20 slight agreement; 0.21-0.40 fair agreement; 0.41-0.60 moderate agreement; 0.61-0.80 substantial/strong agreement; 0.81-0.99 excellent agreement. As a result of missing data: ^bn = 135; ^cn = 139; ^dn = 279; ^en = 274. **P < 0.01.

Table 2 Validation part B, interobserver agreement, six researchers (n = 299 warts)^a

Characteristic	All common warts (n = 840)			All plantar warts (n = 954)			Total (n = 1794)		
	A	B	ICC (95% CI)	A	B	ICC (95% CI)	A	B	ICC (95% CI)
Arrangement (A: solitary, B: confluent)	669	171	0.47 (0.39-0.54)**	719	235	0.68 (0.62-0.73)**	1388	406	0.58 (0.54-0.63)**
Level (A: elevated, B: skin level)	640	200	0.31 (0.23-0.40)**	543	411	0.19 (0.11-0.28)**	1183	611	0.26 (0.91-0.34)**
Aspect (A: lobes/rough, B: not lobed/smooth)	582	258	0.43 (0.34-0.52)**	894	60	0.43 (0.36-0.51)**	1476	318	0.48 (0.43-0.54)**
Border (A: sharp, B: not sharp)	673	167	0.27 (0.20-0.35)**	775 ^b	178 ^b	0.09 (0.05-0.15)**	1448 ^c	345 ^c	0.16 (0.12-0.21)**
White skin flakes (A: yes, B: no)	492	348	0.51 (0.42-0.59)**	709	245	0.40 (0.31-0.50)**	1057	737	0.46 (0.39-0.53)**
Black dots (A: yes, B: no)	517	323	0.68 (0.62-0.74)**	692	262	0.61 (0.54-0.67)**	1209	585	0.68 (0.64-0.72)**
Colour (A: skin colour/light/yellow, B: red)	618	222	0.60 (0.53-0.67)**	810	144	0.45 (0.38-0.53)**	1428	366	0.55 (0.49-0.60)**
Border erythema (A: yes, B: no)	436	404	0.59 (0.51-0.66)**	159	795	0.56 (0.50-0.63)**	595	1199	0.64 (0.58-0.69)**
Callus (A: yes, B: no)	459	381	0.37 (0.28-0.47)**	728 ^b	225 ^b	0.01 (-0.03-0.05)	1109 ^c	684 ^c	0.02 (-0.01-0.06)

CI, confidence interval. ^aTwo-way random intraclass correlation (ICC), type absolute agreement. < 0 less than chance agreement; 0.01-0.20 slight agreement; 0.21-0.40 fair agreement; 0.41-0.60 moderate agreement; 0.61-0.80 substantial/strong agreement; 0.81-0.99 excellent agreement. As a result of missing data: ^bn = 953; ^cn = 1793. **P < 0.01.

Strong intraobserver agreement was found for the characteristics black dots (ICC 0.70) and border erythema (ICC 0.69) for both common and plantar warts. For colour (ICC 0.59), aspect (ICC 0.54), arrangement (ICC 0.54) and white skin flakes (ICC 0.58) agreement was moderate. In common and plantar warts a moderate to strong agreement on level (ICC 0.49 and 0.61, respectively) was observed. A moderate agreement was observed for callus (ICC 0.57) in common warts, but agreement in plantar warts was only slight (ICC 0.02).

Altogether there was moderate to strong intraobserver agreement for eight out of nine characteristics when common warts were considered and for seven out of nine characteristics when plantar warts were considered (Table 3).

Discussion

In this study, a large group of GPs and dermatologists agreed on a definition of wart characteristics. Based on literature and

Table 3 Validation part B, intraobserver agreement, four researchers (n = 299 warts)^a

Characteristic	All common warts (n = 1120)			All plantar warts (n = 1272)			Total (n = 2392)		
	A	B	ICC (95% CI)	A	B	ICC (95% CI)	A	B	ICC (95% CI)
Arrangement (A: solitary, B: confluent)	904	216	0.49 (0.41–0.56)**	958	314	0.59 (0.52–0.65)**	1862	530	0.54 (0.49–0.60)**
Level (A: elevated, B: skin level)	856	264	0.49 (0.28–0.65)**	641	631	0.61 (0.24–0.82)**	1497	895	0.56 (0.30–0.75)**
Aspect (A: lobes/rough, B: not lobed/smooth)	853	267	0.54 (0.46–0.61)**	1199	73	0.51 (0.44–0.58)**	2052	340	0.54 (0.49–0.59)**
Border (A: sharp, B: not sharp)	944	176	0.25 (0.16–0.34)**	1139 ^b	132 ^b	0.11 (0.05–0.17)**	2083 ^c	308 ^c	0.17 (0.11–0.23)**
White skin flakes (A: yes, B: no)	626	494	0.61 (0.54–0.68)**	836	436	0.60 (0.49–0.69)**	1462	930	0.58 (0.52–0.64)**
Black dots (A: yes, B: no)	497	623	0.70 (0.64–0.75)**	958	314	0.63 (0.56–0.70)**	1455	937	0.70 (0.65–0.74)**
Colour (A: skin colour/light/yellow, B: red)	867	253	0.64 (0.58–0.70)**	1133	139	0.52 (0.44–0.59)**	2000	392	0.59 (0.55–0.65)**
Border erythema (A: yes, B: no)	600	520	0.65 (0.58–0.71)**	211	1061	0.62 (0.55–0.67)**	811	1581	0.69 (0.64–0.73)**
Callus (A: yes, B: no)	505	615	0.57 (0.38–0.71)**	909 ^b	362 ^b	0.02 (0.00–0.06)	1414 ^c	977 ^c	0.04 (0.00–0.83)

CI, confidence interval. ^aTwo-way random intraclass correlation (ICC), type absolute agreement. < 0 less than chance agreement; 0.01–0.20 slight agreement; 0.21–0.40 fair agreement; 0.41–0.60 moderate agreement; 0.61–0.80 substantial/strong agreement; 0.81–0.99 excellent agreement. As a result of missing data: ^bn = 1271; ^cn = 2391. **P < 0.01.

semistructured interviews with experienced physicians, a systematic dichotomous assessment tool named the CWARTS diagnostic tool was developed and validated.

Our results show that for most morphological wart characteristics there is moderate agreement between and within observers. This suggests that scoring of these characteristics in clinical practice will be reliable. The most reliable characteristic is black dots (capillary thrombosis) with an excellent level of agreement among 28 physicians and a strong intraobserver agreement with four observers. The presence of border erythema, white skin flakes and the arrangement and aspect of the wart were all characteristics with moderate inter- and intraobserver agreement. Only low inter- and intraobserver agreement was found for the level of the wart and the presence of callus.

Agreement on border and colour was different in part A and B: in part A, border had moderate interobserver agreement and colour only a little agreement, whereas in part B, this was vice versa. The difference could be because of low variability in the colour and border of the warts that were used in part A, as variability of a measurement is required to test interobserver agreement. Intraobserver agreement for colour was moderate and for border slight.

Our results are similar to other dermatological reliability studies. The ICC of wart characteristics was slightly lower compared with the interobserver agreement of Fitzpatrick skin type (ICC 0.9), but in the skin-type study only three observers were compared.¹³ The interobserver agreement was stronger for more morphological characteristics compared with actinic keratosis.¹⁴ Chen *et al.* found that four out of seven characteristics in actinic keratosis had an ICC below 0.40.¹⁴ For total

count of actinic keratosis, a similar ICC was found: 0.66. Similar ICCs were found by Tan *et al.* in a study for redness in rosacea with an overall inter- and intraobserver reliability of 0.601 and 0.658, respectively.¹⁵

The low agreement for level and callus could be explained by the fact that warts were assessed from photographs. Despite this limitation, using photographs also has obvious benefits as a standardized camera makes it possible to assess all warts under the same resolution, distance and light conditions, which makes the wart characteristics more comparable.

In validation part A, a large number of observers were included, which improved the reliability of the results. For part B a larger set of warts was included, which increased variability of the measurements and consequently improved reliability of the ICC. A possible limitation of part B is the small number of raters; this was because of practical feasibility. To minimize risk of selection bias observers from different sites (part A) or with different levels of experience (part B) were included. For intraobserver agreement the risk of recall bias was reduced by using an assessment-free interval of at least 1 week and including a large set of photographs.

The dichotomous design limits the options to describe the warts. However, its dichotomous design makes it a very pragmatic, fast and feasible assessment to identify warts. In future research the assessment tool needs to be validated for predicting treatment response. It would also be interesting to investigate interobserver agreement between photographs and clinical assessment.

In conclusion, we successfully developed a new assessment tool to characterize cutaneous warts – the CWARTS diagnostic tool. This simple, standardized tool can be easily implemented

in clinical practice. In combination with genotyping of 23 wart-associated HPV types, the CWARTS diagnostic tool was recently used to assess whether patient and morphological wart characteristics can predict the HPV type in a specific wart and whether these characteristics as well as the HPV type can predict a favourable treatment result.¹⁶

Acknowledgments

The authors thank all the participating patients and family practices from the Leiden Primary Care Research Network (LEON), the research nurses Corrie Vlieland and Irene Barnhorn-Bakker for collecting the photographs and all observers who assessed the photographs.

References

- Beliaeva TL. The population incidence of warts. *Vestn Dermatol Venerol* 1990; **2**:55–8 (in Russian).
- Kilkenny M, Marks R. The descriptive epidemiology of warts in the community. *Australas J Dermatol* 1996; **37**:80–6.
- Kyriakis K, Pagana G, Michailides C *et al.* Lifetime prevalence fluctuations of common and plane viral warts. *J Eur Acad Dermatol Venerol* 2007; **21**:260–2.
- Van Haalen FM, Bruggink SC, Gussekloo J *et al.* Warts in primary schoolchildren: prevalence and relation with environmental factors. *Br J Dermatol* 2009; **161**:148–52.
- Ciconte A, Campbell J, Tabrizi S *et al.* Warts are not merely blemishes on the skin: a study on the morbidity associated with having viral cutaneous warts. *Australas J Dermatol* 2003; **44**:169–73.
- Bzhalava D, Muhr LS, Lagheden C *et al.* Deep sequencing extends the diversity of human papillomaviruses in human skin. *Sci Rep* 2014; **4**:5807.
- Kwok CS, Gibbs S, Bennett C *et al.* Topical treatments for cutaneous warts. *Cochrane Database Syst Rev* 2012; **9**:CD001781.
- Jablonska S, Orth G, Obalek S *et al.* Cutaneous warts. Clinical, histologic, and virologic correlations. *Clin Dermatol* 1985; **3**:71–82.
- Quaedvlieg PJ, Tirsi E, Thissen MR *et al.* Actinic keratosis: how to differentiate the good from the bad ones? *Eur J Dermatol* 2006; **16**:335–9.
- Rao BK, Ahn CS. Dermatoscopy for melanoma and pigmented lesions. *Dermatol Clin* 2012; **30**:413–34.
- Sidoroff A, Halevy S, Bavinck JN *et al.* Acute generalized exanthematous pustulosis (AGEP) – a clinical reaction pattern. *J Cutan Pathol* 2001; **28**:113–19.
- Bruggink SC, Gussekloo J, Egberts PF *et al.* Monochloroacetic acid application is an effective alternative to cryotherapy for common and plantar warts in primary care: a randomized controlled trial. *J Invest Dermatol* 2015; **135**:1261–7.
- Jacobs LC, Hamer MA, Verkouteren JA *et al.* Perceived skin colour seems a swift, valid and reliable measurement. *Br J Dermatol* 2015; **173**:1084–6.
- Chen SC, Hill ND, Veledar E *et al.* Reliability of quantification measures of actinic keratosis. *Br J Dermatol* 2013; **169**:1219–22.
- Tan J, Liu H, Leyden JJ *et al.* Reliability of Clinician Erythema assessment grading scale. *J Am Acad Dermatol* 2014; **71**:760–3.
- Hogendoorn GK, Bruggink SC, de Koning MNC *et al.* Morphological characteristics and HPV genotype predict the treatment response in cutaneous warts. *Br J Dermatol* 2017; <https://doi.org/10.1111/bjd.15758>

Supporting Information

Additional Supporting Information may be found in the online version of this article at the publisher's website:

File S1 Development of the clinical assessment tool.

Appendix S1 Explanation of the acronym 'PROVOKE'.

Table S1 First version of a list with wart characteristics based on 'PROVOKE'.

Table S2 Second version of a list with wart characteristics based on 'PROVOKE'.

Fig S1. Pre-final version of the Cutaneous WARTS (CWARTS) diagnostic tool.

Video S1 Author video.

Powerpoint S1 Journal Club Slide Set