Universiteit Leiden
The Netherlands

New approaches to imaging and treatment of ocular melanoma

Brouwer, N.J.

Citation
Brouwer, N. J. (2022, April 13). *New approaches to imaging and treatment of ocular melanoma*. Retrieved from https://hdl.handle.net/1887/3283451

Version:	Publisher's Version
License:	Licence agreement concerning inclusion of doctoral thesis in the Institutional Repository of the University of Leiden
Downloaded from:	https://hdl.handle.net/1887/3283451

Note: To cite this publication please use the final published version (if applicable).

NEW APPROACHES TO IMAGING AND TREATMENT OF OCULAR MELANOMA

Niels Johan Brouwer

NEW APPROACHES TO IMAGING AND TREATMENT OF OCULAR MELANOMA

Niels Johan Brouwer

New approaches to imaging and treatment of ocular melanoma
Thesis, Leiden University, The Netherlands

Author: Niels Brouwer
ISBN: 978-94-93108-32-5
Cover design: James Jardine | www.jamesjardine.nl
Layout: James Jardine | www.jamesjardine.nl
Printing: Ridderprint | www.ridderprint.nl

The research described in this thesis was financially supported by
MD/PhD-programme grant (Leiden University Medical Center), European Commission Horizon 2020 program UM Cure (Project number: 667787), China Scholarship Council (JC), Dutch Cancer Society funding (UL 2013-5757), Uveal Melanoma Bontius Fund, Stichting Leids Oogheelkundig Ondersteuningsfonds (LOOF), Stichting Nelly Reef Fund, Foundation "De Drie Lichten", Stichting Blindenhulp, Stichting tot Verbetering van het Lot der Blinden, Rotterdamse Stichting Blindenbelangen, Landelijke Stichting voor Blinden en Slechtzienden (LSBS), Stichting PG Binkhorst, Leids Universiteits Fonds / P.A. Jager-van Gelder Fonds, Algemene Nederlandse Vereniging Ter Voorkoming van Blindheid (ANVVB), Stichting Blinden Penning, Novartis Foundation, Stichting Nederlands Oogheelkundig Onderzoek (SNOO), Mr. O. Roell (Oxymap T1 device), Laméris Ootech BV (Nidek OCTA device)

Financial support for the printing of this thesis was kindly provided by
Stichting LOOF, Landelijke Stichting voor Blinden en Slechtzienden (LSBS), Stichting Blindenhulp, Stichting tot Verbetering van het Lot der Blinden, Rotterdamse Stichting Blindenbelangen, Bayer, Chipsoft, Horus Pharma BV, Low Vision Totaal, Rockmed BV, Santen Pharmaceutical Co. Ltd, Synga Medical, Théa Pharma BV, Tramedico, Vitaminen op Recept

All funding organisations provided unrestricted grands and had no role in the design or conduct of this research.

© Niels Johan Brouwer, 2022 (nielsj.brouwer@hotmail.com). All rights reserved. No part of this thesis may be reproduced in any form without written permission from the author.

NEW APPROACHES TO IMAGING AND TREATMENT OF OCULAR MELANOMA

Proefschrift

ter verkrijging van
de graad van doctor aan de Universiteit Leiden,
op gezag van rector magnificus prof.dr.ir. H. Bijl,
volgens besluit van het college voor promoties
te verdedigen op woensdag 13 april 2022
klokke 15.00 uur

door

Niels Johan Brouwer
Geboren te 's-Gravenhage
In 1990

Promotoren

Prof. dr. M.J. Jager
Prof. dr. G.P.M. Luyten

Promotiecommissie

Prof. dr. N.E. Schalij-Delfos	
Prof. dr. S. Heegaard	*University of Copenhagen, Denmark*
Prof. dr. L.M. Heindl	*University of Cologne, Germany*
Dr. N.C. Naus	*Erasmus University Medical Center, The Netherlands*
Prof. dr. D.G. Vavvas	*Massachusetts Eye and Ear Infirmary / Harvard University, USA*

**"Alles wat teveel is,
is strijdig met de natuur"**

(Hippocrates van Kos, ca 460-370 v Chr.)

Voor mijn ouders

Contents

Background

1 General Introduction and Outline of Thesis 11

PART I: Conjunctival Melanoma

2 Current Treatments

2.1 Treatment of Conjunctival Melanoma in a Dutch Referral Centre 33
Br J Ophthalmol 2018; 102(9):1277-1282

2.2 Lack of Tumour Pigmentation in Conjunctival Melanoma is Associated with Light Iris Colour and Worse Prognosis 49
Br J Ophthalmol 2019; 103(3):332-337

2.3 Pigmentation of Conjunctival Melanoma Recurrences and Outcome 67
Graefes Arch Clin Exp Ophthalmol 2019; 257(8):1783-1788

3 Treatment Targets

3.1 Conjunctival Melanoma: New Insights in Tumour Genetics and Immunology leading to New Therapeutic Options 81
Progress in Ret Eye Res 2022; 86:100971

3.2 PD-L1/PD-1 Expression and Tumor-Infiltrating Lymphocytes in Conjunctival Melanoma 169
Oncotarget 2017; 8(33):54722-54734

PART II: Uveal Melanoma

4 Treatment Targets

4.1 Targeting the YAP/TAZ Pathway in Uveal and Conjunctival Melanoma with Verteporfin 197
Invest Ophthalmol Vis Sci 2021; 62(4);3

4.2 Tumour Angiogenesis in Uveal Melanoma Is Related to Genetic Evolution 227
Cancers (Basel) 2019; 11(7). pii: E979

5 Imaging Techniques

5.1 Retinal Oximetry is Altered in Eyes with Choroidal Melanoma but not in Eyes with Choroidal Nevi 251
Retina 2020; 40(11):2207-2215

5.2 Anterior Segment OCTA of Melanocytic Lesions of the Conjunctiva and Iris 273
Am J Ophthalmol 2020; 222:137-147

Clinical cases

6 Clinical Cases

6.1 Conjunctival Metastasis of a Cutaneous Melanoma 297
Ocul Oncol Pathol 2018; 4(2):107-111

6.2 Development of Ocular Rosacea following Combined Ipilimumab and Nivolumab Treatment for Metastatic Malignant Skin Melanoma 307
Ocul Oncol Pathol 2017; 3(3):188-192

6.3 Two Late Recurrences of Conjunctival Melanoma 317
Ocul Oncol Pathol 2019; 5(4):262-266

6.4 Multiple Pigmented Conjunctival Lesions following Intravitreal Injections in a Patient with Uveal Melanoma 327
Ocul Oncol Pathol 2017; 3(2):113-116

General Discussion and Appendices

7 Summary and General Discussion 337

8 Appendices

8.1 Dutch Summary 355
8.2 Acknowledgements 369
8.3 Curriculum Vitae 373
8.4 List of Publications 375

BACKGROUND

Chapter 1: Background

1. General Introduction and Outline of Thesis



1

General Introduction and Outline of Thesis

GENERAL INTRODUCTION

Ocular Melanoma

Melanoma is a malignancy of melanocytes. Since melanocytes are naturally present in the eye, melanoma may develop as a primary ocular disease. Notable for ophthalmology, it is one of the few conditions that is not only sight-threatening but also life-threatening.

The caption 'ocular melanoma' is commonly used as synonym for *uveal melanoma* (UM), which refers to the most prevalent kind of melanoma of the eye.[1] The uvea concerns the intraocular tissues of the choroid, ciliary body and iris, all of which can harbour a primary melanoma. The word 'uvea' is derived from the Greek word for grape, following the appearance of the eye when the sclera (outer layer) has been removed. Distinct from the uvea, melanoma may develop in the conjunctiva as well, resulting in *conjunctival melanoma* (CoM). While UM and CoM both affect the eye, they differ significantly in genetic background, behaviour, and the required therapeutic approach, as will be discussed in this thesis.

The first reports of melanoma (of any origin) date back to the ancient Greeks, with presumably Hippocrates of Cos in the 5th century BC describing dark skin lesions.[2] Around the 18th century AD, reports on several melanoma patients emerged in the European literature. In 1806, Laennec provided the first detailed presentation of skin melanoma, naming it 'melanosis'.[3] In 1838, the word 'melanoma' was first introduced by Carswell.[4] The famous physician Virchow provided a further classification of melanocytic tumours in 1869.[5] The first report on the natural history of UM was presented in the early 19th century by Scottish surgeons Wardrop and Burns, linking liver lesions to a dark brown intraocular tumour in the same patient.[6,7] Notably, this resulted from cadaveric work as the invention of the ophthalmoscope by von Helmholtz in 1851 was a prerequisite for in vivo work on intraocular UM.[8] Some debate exists on the first report of extraocular CoM,[9,10] but likely this was presented by Travers in 1820.[11] Decades later in 1868, Stellwag von Carion identified the pigment-loaded cells that constitute CoM.[12]

In the roughly two centuries that passed since the first descriptions of UM and CoM, much has been learned about melanoma as a disease. Ocular oncology has evolved into a fruitful field of study, collaborating with other fields such as pathology, medical/radiation oncology, immunology, and radiology. Technological advances in general medicine as well as in ophthalmology proper, lead to better diagnostic procedures, staging, and therapeutic possibilities. Unfortunately, both CoM and UM remain malicious diseases, requiring further studies for better patient care.

This chapter provides an introduction to *extraocular* CoM (Part I) as well as *intraocular* UM (Part II). At the end of the chapter, the aims and outline of the thesis will be discussed.

Part I - Conjunctival melanoma

Epidemiology

CoM is a rare ocular tumour that accounts for about 5% of all primary ocular melanoma.[1,13] The incidence ranges between 0.3 and 0.8 per million adults in Caucasians.[14-17] It is the second most prevalent malignancy of the conjunctiva, after squamous cell carcinoma (also known as 'ocular surface squamous neoplasia, OSSN').[18] CoM is typically a disease of people of Caucasian descent,[19] but may occur in any race. The incidence has been rising in the last few decades, which possibly relates to increased ultraviolet (UV)-radiation exposure.[15]

Pathophysiology

The conjunctiva is a mucous membrane that covers the bulbar surface of the eye and inner parts of the eyelids, with melanocytes located in its basal layers. The number, characteristics, and pigment production of melanocytes can vary, resulting in a range of melanocytic diseases.[20] Benign melanocytic disease includes 'hypermelanosis', i.e. increased melanin production without melanocyte alterations, 'naevus' with increased clusters of melanocytes without malignancy, and 'primary acquired melanosis' (PAM) with a range of melanocyte alterations. When melanocytic growth extends beyond the basement membrane into deeper tissues, a lesion is deemed a 'melanoma'.

CoM is thought to originate from PAM (in approximately 74%), from a nevus (in 7%) or de novo (i.e. without a known precursor lesion, in 19%).[21]

The genetic background of CoM resembles that of cutaneous melanoma. Mutations are seen in *BRAF*, *NRAS* and *TERT* promotor genes, while mutations that are commonly seen in UM (such as in *GNAQ/11* and *BAP1*, as discussed in Part II) are absent.[22,23] *BRAF* mutations activate the MAPK pathway,[24] while *NRAS* mutations activate the MAPK and PI3K/AKT pathway,[25] both promoting cell proliferation.

As in cutaneous melanoma,[26] the presence of inflammation in CoM appears to be favourable for clinical outcome,[27,28] suggesting that immune cells have a role in tumour surveillance in this malignancy. However, the individual roles of the plethora of immune cell types and components that can be identified in the tumour micro environment of CoM is not fully understood.

Clinical presentation

CoM typically presents as a thickened, pigmented lesion on the conjunctival surface, with notable 'feeder' or 'sentinel' vessels (Figure 1). There is a wide range of presentations, however, as any part of the conjunctiva can be affected, with nodular or flat disease, and lesions can range from amelanotic and pink to black. Some lesions are easily discovered; other lesions (with a pale appearance or

located at the tarsal conjunctiva) are difficult to detect, causing delayed presentation. Often, CoM is accompanied by a component of PAM, and as PAM may cause widespread pigmentation of the eye, it may be difficult to delineate the exact border of infiltrative disease.

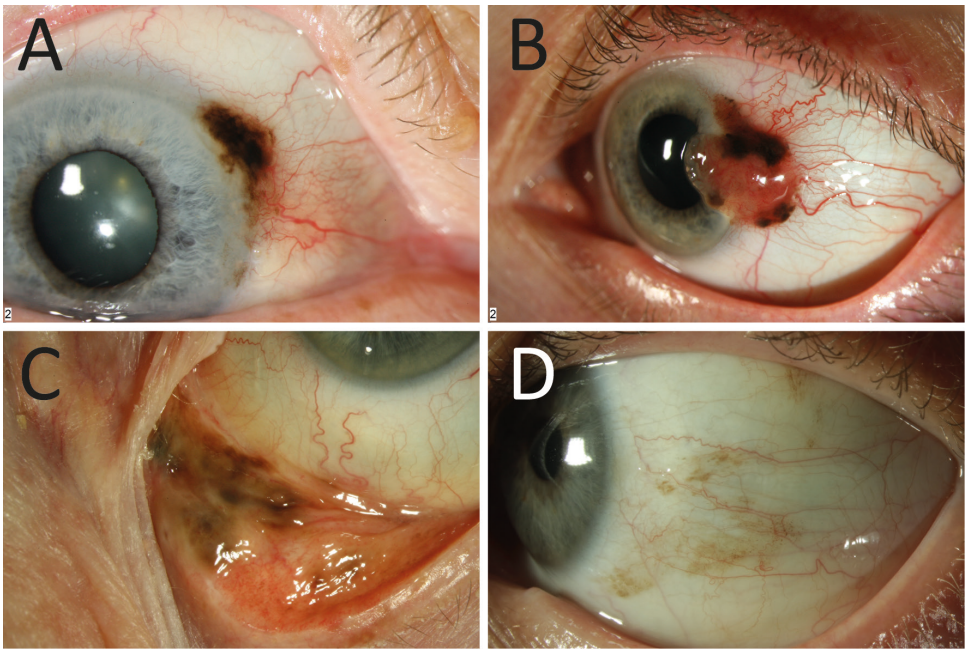

Figure 1. Clinical presentation of CoM. (A) Pigmented lesion near the limbus of the eye. (B) Mixed-pigmented lesions near the limbus of the eye, with growth extending into the cornea. Notice the vessels approaching the lesion. (C) Pigmented lesion at tarsal and forniceal conjunctiva. (D) Faint pigmentation at bulbar conjunctiva, which proved to be CoM in an area of PAM with severe atypia.

Diagnosis

The diagnosis of CoM is based on histology. Tissue can be obtained via several techniques: excisional biopsies are preferred over incisional biopsies, to prevent iatrogenic tumour spread.[29] Imaging techniques are not commonly applied to differentiate lesions, but anterior segment OCT or ultrasound investigation may be used to determine invasion into deeper ocular structures.[30] It is difficult to properly image thick lesions or those located in the caruncular area or plica, however, and improvements in spatial resolution and tissue penetrance will be needed before imaging can play a larger role in the diagnostic process of conjunctival lesions.

Conjunctival melanomas are currently staged by the 8th ed TNM (tumour-node-metastasis) classification, as presented by the American Joint Committee on Cancer (AJCC).[31] This scoring

system has been validated by an international collaboration on CoM and proved to predict recurrences and mortality.[32] Currently, the most important parameters to predict clinical outcome are tumour basal diameter, thickness, location on the eye (bulbar / non-bulbar) and local invasion;[17,21,33,34] the value of other parameters such as ulceration and necrosis is unclear. As expected with a multitude of studies on small numbers, various studies have conflicting findings. A recent development is the study of genetic markers (including gene mutations and miRNA expression) for prognostication,[35-37] but this requires further confirmation.

Treatment

Localized CoM is preferably treated with surgical excision and adjuvant therapy (i.e. cryotherapy, topical chemotherapy, and/or radiotherapy).[38] In our institution, plaque brachytherapy is the currently-preferred method for adjuvant radiation of bulbar lesions;[39] topical mitomycin-c can be added if PAM is present as well.[40] Widespread lesions cannot be treated with such an approach, and require extensive surgery (such as orbital exenteration)[41] or external radiotherapy[42]. Treatment options for metastatic disease are limited, and follow developments from cutaneous melanoma. Up till a few years ago, this consisted of conventional systemic chemotherapy with unfortunately poor results. Newly-introduced targeted therapy[43,44] and immunotherapy[45,46] are now used more often in CoM, with promising results, as the genetic and immunologic profile of CoM and cutaneous melanoma appear to be much alike.

Up to date, evidence for CoM therapy has been obtained by case-series and case reports. We do not know of (reported) trials dedicated to CoM. Treatment strategies may therefore vary between clinicians, and many topics (such as the use of adjuvant therapy, or sentinel lymph node biopsies[47]) are under debate.

Outcome

Local recurrences of CoM are common: the 5-yr estimate is 36-45%, but the recurrence rate may be as high as 61%.[14,17,21] Recurrences may be derived from residual cells after earlier treatment, or be new developments from precursor lesions such as PAM.

The conjunctiva has lymphatic drainage and CoM may therefore give rise to lymphatic dissemination. Regional spread of CoM has been reported in 11-52% of patients at 5 years.[48-50] The lymph nodes are believed to be the first site of metastasis in many CoM cases,[48] but distant metastasis without prior lymph node involvement may occur as well.

Systemic metastasis may occur with a 5-yr estimate of 10-16% and a 10-yr estimate of 17-26%.[49,51] The most frequent sites of distant metastases are the lungs, liver, brain and skin.[17,48,49,51,52]

The visual outcome of CoM patients is commonly not influenced by the disease itself, but may be affected by local therapy (such as corneal damage due to surgery or limbal stem cell deficiency due to topical chemotherapy) or by last-resort therapy such as removal of the eye.

Part II - Uveal melanoma

Epidemiology

Uveal melanoma (UM) is the most common intraocular primary malignancy in adults. It comprises melanoma of the choroid (90%), ciliary body (6%) and iris (4%).[53] The incidence of UM in total ranges from 5.1 to 8.6 per million in Caucasian adults.[54,55] It is most prevalent in persons of (northern) European ancestry, and has a south-to-north increasing gradient in America as well as Europe.[55,56] The incidence has been relatively stable over the last few decades,[55,57] suggesting (unlike what is observed in CoM) no strong relation with UV exposure.

Pathophysiology

Melanocytes are present throughout the uveal tract, and malignant transformation of these underlies the development of UM.[58] UM is usually initiated by mutations in *GNAQ/11*, which occur in almost 90% of cases.[59,60] Mutations in *GNAQ/11* are involved in several processes of cell growth and proliferation[59] including in activation of the YAP1 ("hippo") pathway[61,62]. Interestingly, mutations in *GNAQ/11* are already present in choroidal nevi,[63] so for malignant transformation, a second mutation is required. Common 'secondary' mutations in UM are those in the *BAP1*, *EIF1AX* or *SF3B1* genes.[58,64]

Important events in UM behaviour are occurrence of chromosomal aberrations (copy number variations).[65] Frequently observed changes are loss of chromosome 3 or gain of chromosome 8q (both related to worse clinical outcome), and gain of chromosome 6p (related to a favourable outcome).[66]

A decade ago it was discovered that the BAP1 protein (encoded by the *BAP1* gene on chromosome 3) is a major player in UM behaviour.[67] BAP1 is a deubiquitinating protein which functions in cell cycle regulation, DNA damage repair and regulation of gene expression.[68] Loss of BAP1 protein expression is related to an unfavourable outcome and is often assessed in patient care to provide information on prognosis.[69,70]

Tumour micro environment / angiogenesis

In UM, the tumour micro environment involves immune cells and extracellular structures such as blood vessels. Both the immune system and angiogenesis are portrayed as a 'hallmark of cancer',[71] which is especially important in UM as the eye is an immune-privileged site,[72] and UM are highly-vascularized.

The presence of immune cells has long been known to relate to an unfavourable prognosis in UM,[73-75] which is exactly opposite to what is seen in cutaneous (and conjunctival) melanoma. Tumour-infiltrating leukocytes (TILs) produce several pro-inflammatory cytokines, that may stimulate UM growth.[76] Important players in the tumour microenvironment are macrophages, of which the M2 type is known to stimulate angiogenesis via production of Vascular Endothelial Growth Factor (VEGF). Vessels provide nutrients and oxygen to proliferating cells, and provide a route for hematogenic dissemination. Unsurprisingly, a high vascular density is known to relate to worse survival in UM.[77,78]

There is a close relation between the immune environment and UM genetic make-up: monosomy 3 is related to an increased presence of TILs.[78] BAP1 loss and gain of chromosome 8q are related to increased inflammation.[79]

Clinical presentation

The clinical presentation of UM depends on the originating site in either the anterior or posterior segment of the eye. *Iris lesions* can often be readily observed as a pigmented nodule, or by deformation of the pupillary margin (Figure 2). Despite rarely causing other symptoms, they are often diagnosed early by their presentation. *Ciliary body and choroidal lesions* are usually not visible from the outside and are detected by coincidence during ophthalmological inspection (in one third of cases), or following the development of secondary symptoms.[80] These symptoms include decreased visual acuity, metamorphopsia, or increased floaters; this is due to subretinal fluid (SRF), retinal detachment, haemorrhage or the physical presence of a nodule in the eye. The common presentation of choroidal melanoma is that of an (un)pigmented lesion that is seen by fundoscopy (Figure 3).

Clinically, it may be challenging to differentiate a melanoma from a nevus. Choroidal nevi are a common finding, seen in approximately 5% of Caucasians,[81] and they may transform into melanoma in about 1:9000 cases per year.[82] A set of clinical parameters has been defined to identify choroidal nevi with increased risk for transformation into melanoma.[83] These factors are Thickness (>2mm), Subretinal Fluid, Symptoms, Orange pigment, Margin near the optic nerve, Ultrasonographic Hollowness, Halo absent, Drusen absent; together they form the mnemonic *'To Find Small Ocular Melanoma Using Helpful Hints Daily'*.

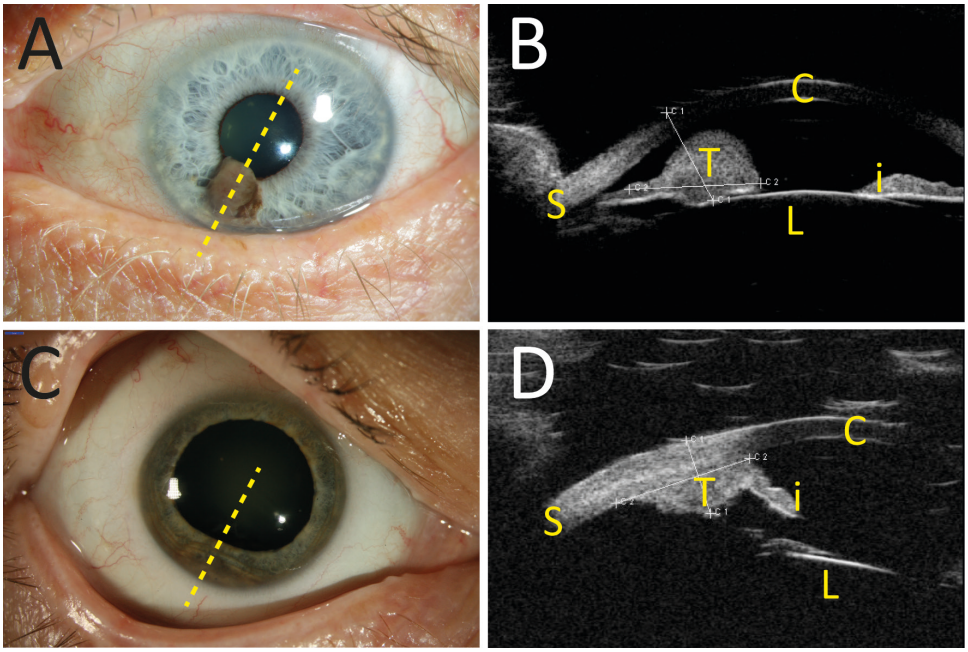

Figure 2. Clinical presentation of iris melanoma and ciliary body melanoma. (A) Pigmented lesion of the iris. The dotted line indicates the cross section as presented by ultrasonography in panel B. (B) Ultrasound image of the same patient as in A. note the nodular configuration, limited to iris tissue. (C) Pigmented lesion of the ciliary body, inferior. The dotted line indicates the cross section as presented by ultrasonography in panel D. (D) Ultrasound image of the same patient as in B. Note that the lesion originates from ciliary body tissue, and is located behind the iris.

Abbreviations: C=cornea, S=sclera, i=iris, L=lens, T=tumour.

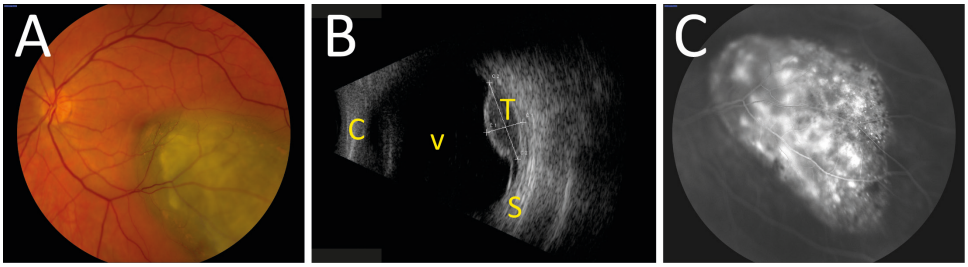

Figure 3. Clinical presentation of choroidal melanoma. (A) Pigmented lesion of the choroid, located in the posterior pole. (B) Ultrasound image of the same patient as in A. Note the dome-shaped configuration and internal 'dark' or 'low' reflectivity of the tumour lesion. (C) Fluorescein angiography of the same patient as in A. Note the vascular pattern and 'pinpoint leakage' of the lesion, which is indicative for melanoma.

Abbreviations: C=cornea, S=sclera, V=vitreous, T=tumour

Diagnosis

The diagnosis of UM is usually based on clinical characteristics (as obtained with fundoscopy), and auxiliary tests such as fluorescein angiography (FA) and ultrasound imaging. Using FA, vascular patterns and leakage are assessed that differentiate between various choroidal lesions.[84] Ultrasound imaging provides information on lesion size, extent, and internal structure (Figure 3). Some centers apply tissue biopsies as a routine investigation.[85,86] While advantageous for diagnostic and prognostic purposes, this is an invasive procedure and it is not routinely practiced in The Netherlands.

UM's are staged by the AJCC TNM staging system for choroidal/ciliary body or iris lesions,[87] based on tumour dimensions and anatomical extent. When tissue material is obtained (after biopsy or enucleation), the prognosis can be refined using the tumour's status of chromosome 3 and 8q,[88] its gene expression profile (GEP, class 1 and 2),[89] or immunohistochemical staining for the BAP1 protein.[70] A schematic approach to categorize UM based on their genetic background, presence of inflammation, and prognostic outcome results into A-, B-, C- and D-type tumours (Table 1).[90]

Table 1. Uveal Melanoma categories and corresponding chromosome aberrations and outcome. [Adapted from Jager et al 2018.[90]]

	A	B	C	D
Metastases risk	Low	Intermediate	High	High
mRNA GEP	Class 1	Class 1	Class 2	Class 2
Chromosome 3	Disomy	Disomy	Monosomy	Monosomy
Chromosome 8q	Normal	Partial gain	Partial gain	Multiple gain
Chromosome 6p	Partial/total gain	Gain	No change	No change
Inflammation	None	None	Some	Much

Abbreviations: GEP= gene expression profile

Treatment

The most common treatments of UM are radiotherapy or enucleation. Less common approaches are local resection, transpupillary thermo therapy, photodynamic therapy, or the recently-introduced nanoparticle AU-011.[58]

Radiotherapy can be administered as brachytherapy (using plaques with an I-125, Ru-106, Pd-103 or other isotope sutured to the eye) or as external radiotherapy (using electron or proton beam devices). A benefit from this approach is that the eye is preserved. Depending on the location of the tumour and radiation source, however, several adverse events may occur. Common events are radiation retinopathy, cataract, or neovascular glaucoma. The underlying mechanism of several events

is vascular damage,[91] which may occur directly via DNA damage,[92] or indirectly via production of free radicals and inflammatory cytokines.[93-95] Anti-VEGF medication is used as therapy for several adverse events, the value of preventive use for retinal damage is under investigation.[96,97]

Removal of the eye is the indicated procedure in cases where the tumour is too large to irradiate, when earlier treatment failed, or when severe adverse events of other therapies have occurred or are to be expected.

Unfortunately, there is currently no successful treatment for metastatic UM. Several therapies that are successful for cutaneous melanoma, such as targeted therapy and checkpoint inhibitors, showed no benefit for UM.[98] Possibly this is due to differences in the immune environment.[99] Conventional chemotherapy is similarly of little benefit.[58] Individual patients with limited metastatic disease to the liver may benefit from regional approaches such as surgical resection or intra-arterial chemotherapy. These procedures, as well as several other therapies based on checkpoint inhibition, reduction of angiogenesis or T cell therapies are under investigation.[58]

Outcome

The primary outcome measure for UM patients is development of metastases. Lacking proper treatment this is closely related to survival. A well-reported figure is that up to 50% of UM patients die from metastases,[100] and this has not changed over the last five decades.[101] There is a considerable spread of metastatic potential based upon tumour dimensions and genetic profile. Based on the TNM staging criteria for choroidal tumours, the 5y/10y risk for metastasis development is 8/15% in T1 lesions, 14/25% in T2 lesions, 31/49% in T3 lesions, and 51/63% in T4 lesions.[102] The prognosis of iris melanoma is more favourable with a 5y/10y metastasis risk for T1 lesions of 2/5%, for T2 lesions of 9/14%, and for T4 lesions of 33%/unknown.[103]

A secondary outcome measure for UM patients is visual outcome. Visual outcome can be severely threatened in UM; e.g. by the direct position of the tumour affecting the visual axis, and by adverse events of therapy (including radiation retinopathy or loss of the eye with enucleation).

THESIS AIMS AND OUTLINE

This thesis aims to evaluate new imaging techniques to diagnose ocular melanoma lesions, and to identify new treatment targets for ocular melanoma in a preclinical phase. A central theme is angiogenesis, which is studied at a basal level with genetics and histology, as well as at a clinical level with vascular imaging techniques. The first part of this thesis focusses on the understanding of CoM, and continues with potential new therapies. The second part of this thesis focusses on the understanding of UM, and continues with the clinical evaluation of vascular imaging techniques. Some projects of this thesis address both CoM and UM; these are discussed in the part that fits their content best (Figure 4).

Part I – Conjunctival melanoma

The need for better therapies in CoM follows the substantial rates of recurrences and metastases in these patients. Only a few large series with long-term follow-up data on CoM have been reported, as the disease is rare and follow-up in many countries is scattered over local hospitals. We evaluated the current treatment of CoM patients in our institution, benefitting from our position as a national referral center with systematic follow-up (**chapter 2.1**)**.** Triggered by the various clinical presentations of CoM, and the knowledge that melanin pigment has a role in melanoma development on a genetic level (see chapter 3.1), we determined whether clinical pigment characteristics are related to CoM behaviour of the primary tumour (**chapter 2.2**), and its recurrences (**chapter 2.3**).

Recent developments in oncology led to the introduction of two new classes of drugs: 'targeted therapy' aimed at genetic mutations, and 'immunotherapy' aimed at the interaction between the host's immune system and tumour cells. These two drugs revolutionized the therapy of cutaneous melanoma patients. In 2018, the Nobel Prize in Physiology or Medicine was awarded for the *'Discovery of cancer therapy by inhibition of negative immune regulation'*. Several studies identified similarities in the genetic background and immune environment between cutaneous and conjunctival melanoma, prompting the question whether the new drugs are useful to treat CoM. In **chapter 3.1,** we summarize the current knowledge of the genetic background and immunologic microenvironment of CoM, and discuss the first observations from targeted therapy and immunotherapy in patients with CoM. One type of immunotherapy is based on inhibition of the PD-1/PD-L1 pathway; we set out to study this pathway in CoM tissue and performed in vitro tests to determine the feasibility of this new therapeutic approach (**chapter 3.2**).

Part II – Uveal melanoma

Uveal melanoma has a distinct position compared to cutaneous and conjunctival melanoma by having a different genetic background and interaction with the immune system (see chapter 3.1). The earlier mentioned targeted and immunotherapies have – unfortunately – as yet not been

successful in UM, leading to an urgent need for better therapies. Most UM carry a mutation in *GNAQ/11*, which is known to activate the YAP1 pathway. The YAP1 pathway is a regulator of cell growth and was found to stimulate tumour growth of various cancers. Interestingly, the readily-available ophthalmic drug verteporfin can inhibit YAP1 activity. We studied the significance of the YAP1 pathway in UM, and tested whether verteporfin would inhibit the growth of UM and CoM cell lines in vitro; we analyzed the role of the genetic background in the treatment response (**chapter 4.1**).

An important parameter in the development and behaviour of UM is angiogenesis: vessels are needed to provide nutrients and oxygen to a proliferating tumour, and vessels provide a route for tumour cells to disseminate. Several drugs can target vessel growth and new drugs have been developed to target specific parts of angiogenesis such as by ischemic mediator HIF1a. Angiogenesis is stimulated by the tumour micro environment, as immune cells can produce pro-inflammatory and pro-angiogenic cytokines. Recent work showed a relation between the genetic evolution of UM and the presence of different immune cells. [79] We hypothesized that the genetic status of UM relates to angiogenesis as well, and compared the vascular density in UM tissue and the expression of several angiogenesis-related genes (**chapter 4.2**).

Blood vessels are not only important for ocular melanoma on a microscopic scale, but translate into clinical practice for diagnostic purposes and evaluation of therapy. Tumour vessels, as a differentiating feature between malignant and benign choroidal lesions, are commonly assessed with fluorescein angiography. We wondered whether not only the presence of vessels, but also the oxygen content of vessels can be used diagnostically, as this may provide information on the metabolism of (tumour) cells. We hypothesized that the oxygen metabolism in melanoma eyes is different from that in eyes with a nevus, and therefore studied oximetry in eyes with choroidal lesions (**chapter 5.1**).

The role for vascular imaging to diagnose and differentiate lesions of the iris and conjunctiva is currently limited. Fluorescein angiography has been used to study iris lesions, but the diagnostic value of many parameters remained unclear; conjunctival tumour vessels have been studied even less with this technique as dye easily leaks out of conjunctival vessels. A new imaging technique to study ocular vessels is OCT-angiography (OCTA), with the beneficial properties of being non-invasive and non-dye dependent. We tested the feasibility of this technique to study iris and conjunctiva lesions, with the ultimate aim to differentiate between benign and malignant tumours (**chapter 5.2**).

In summary, this thesis reports on several studies investigating the genetic, immunologic and vascular characteristics of CoM and UM, and the application of new imaging techniques to differentiate between benign and malignant lesions.

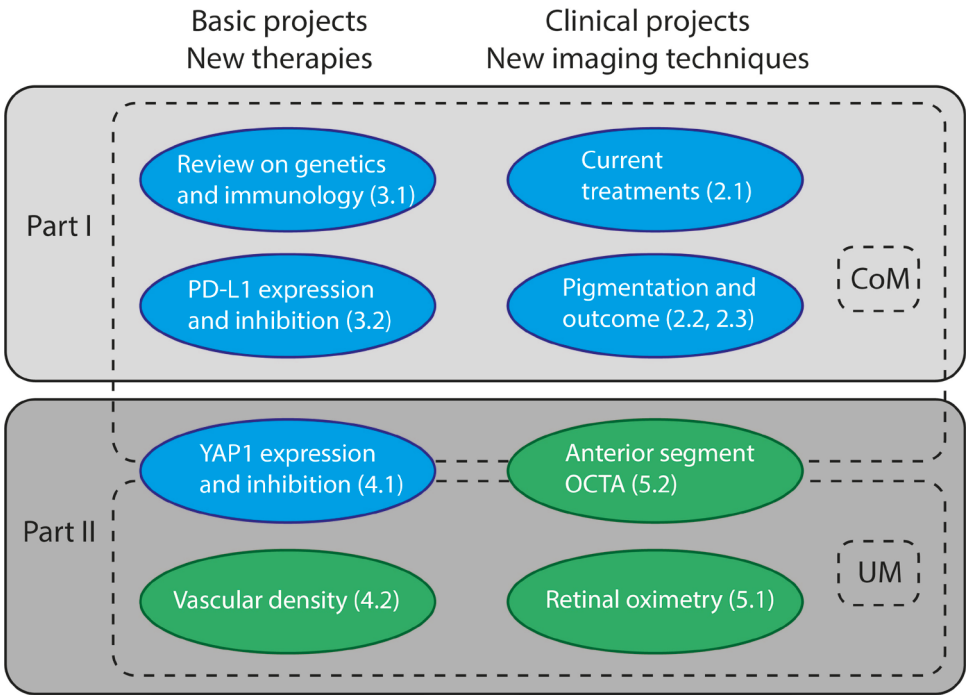

Figure 4. Projects of this Thesis. The outline of this thesis in part I and II is presented, together with the partially overlapping division in CoM and UM. Each oval shape represents a project, numbers refer to the chapters of this thesis. Projects related to angiogenesis are depicted in green, projects related to treatment of patients are depicted in blue.

REFERENCES

1. McLaughlin CC, Wu XC, Jemal A, et al. Incidence of noncutaneous melanomas in the U.S. *Cancer.* 2005;103(5):1000-1007.
2. Rebecca VW, Sondak VK, Smalley KS. A brief history of melanoma: from mummies to mutations. *Melanoma Res.* 2012;22(2):114-122.
3. Laennec RTH. Sur les melanoses. *Bulletin de la Faculté de Médecine de Paris.* Vol 1. Paris1806:24-26.
4. Carswell R. *Pathological Anatomy, Illustrations of the Elementary Forms of Disease.* London: Longman; 1838.
5. Virchow RLK. *Pathologie des tumeurs.* Paris: Baillière; 1869.
6. Burns A. *Observations on the surgical anatomy of the head and neck: illustrated by cases and engravings.* Edinburgh: Bryce & Co; 1811.
7. Wardrop J. *Observations on fungus hæmatodes or soft cancer, in several of the most important organs of the human body; containing also a comparative view of the structure of fungus hæmatodes and cancer. With cases and dissections.* Edinburgh: Geroge Ramsay; 1809.
8. von Helmholtz H. *Beschreibung eines Augen-Spiegels : zur Untersuchung der Netzhaut im lebenden Auge.* Berlin: A. Förstnersche Verlagsbuchhandlung; 1851.
9. Jay B. Naevi and Melanomata of the Conjunctiva. *Br J Ophthalmol.* 1965;49:169-204.
10. Seregard S. Conjunctival melanoma. *Surv Ophthalmol.* 1998;42(4):321-350.
11. Travers B. *A Synopsis of the Diseases of the Eye, and their Treatment.* London: Longman; 1820.
12. Stellwag von Carion C. *Treatise on the Diseases of the Eye.* New York: Wood; 1868.
13. Isager P, Osterlind A, Engholm G, et al. Uveal and conjunctival malignant melanoma in Denmark, 1943-97: incidence and validation study. *Ophthalmic Epidemiol.* 2005;12(4):223-232.
14. Tuomaala S, Eskelin S, Tarkkanen A, Kivela T. Population-based assessment of clinical characteristics predicting outcome of conjunctival melanoma in whites. *Invest Ophthalmol Vis Sci.* 2002;43(11):3399-3408.
15. Yu GP, Hu DN, McCormick S, Finger PT. Conjunctival melanoma: is it increasing in the United States? *Am J Ophthalmol.* 2003;135(6):800-806.
16. Triay E, Bergman L, Nilsson B, All-Ericsson C, Seregard S. Time trends in the incidence of conjunctival melanoma in Sweden. *Br J Ophthalmol.* 2009;93(11):1524-1528.
17. Missotten GS, Keijser S, De Keizer RJ, De Wolff-Rouendaal D. Conjunctival melanoma in the Netherlands: a nationwide study. *Invest Ophthalmol Vis Sci.* 2005;46(1):75-82.
18. Shields CL, Chien JL, Surakiatchanukul T, et al. Conjunctival Tumors: Review of Clinical Features, Risks, Biomarkers, and Outcomes--The 2017 J. Donald M. Gass Lecture. *Asia Pac J Ophthalmol (Phila).* 2017;6(2):109-120.
19. Hu DN, Yu G, McCormick SA, Finger PT. Population-based incidence of conjunctival melanoma in various races and ethnic groups and comparison with other melanomas. *Am J Ophthalmol.* 2008;145(3):418-423.
20. Jakobiec FA. Conjunctival Primary Acquired Melanosis: Is It Time for a New Terminology? *Am J Ophthalmol.* 2016;162:3-19 e11.
21. Shields CL, Markowitz JS, Belinsky I, et al. Conjunctival melanoma: outcomes based on tumor origin in 382 consecutive cases. *Ophthalmology.* 2011;118(2):389-395 e381-382.
22. Griewank KG, Westekemper H, Murali R, et al. Conjunctival melanomas harbor BRAF and NRAS mutations and copy number changes similar to cutaneous and mucosal melanomas. *Clin Cancer Res.* 2013;19(12):3143-3152.
23. Griewank KG, Murali R, Schilling B, et al. TERT promoter mutations in ocular melanoma distinguish between conjunctival and uveal tumours. *Br J Cancer.* 2013;109(2):497-501.
24. Garnett MJ, Marais R. Guilty as charged: B-RAF is a human oncogene. *Cancer Cell.* 2004;6(4):313-319.

25. Davies MA. The role of the PI3K-AKT pathway in melanoma. *Cancer J.* 2012;18(2):142-147.
26. Clark WH, Jr., Elder DE, Guerry Dt, et al. Model predicting survival in stage I melanoma based on tumor progression. *J Natl Cancer Inst.* 1989;81(24):1893-1904.
27. Crawford JB. Conjunctival melanomas: prognostic factors a review and an analysis of a series. *Trans Am Ophthalmol Soc.* 1980;78:467-502.
28. Folberg R, McLean IW, Zimmerman LE. Malignant melanoma of the conjunctiva. *Hum Pathol.* 1985;16(2):136-143.
29. Damato B, Coupland SE. An audit of conjunctival melanoma treatment in Liverpool. *Eye (Lond).* 2009;23(4):801-809.
30. Bianciotto C, Shields CL, Guzman JM, et al. Assessment of anterior segment tumors with ultrasound biomicroscopy versus anterior segment optical coherence tomography in 200 cases. *Ophthalmology.* 2011;118(7):1297-1302.
31. Coupland SE, Barnhill RL, Conway M, et al. Conjunctival Melanoma. In: Amin MB ES, Green F, ed. *AJCC Canger Staging Manual, 8th ed*. New York: Springer; 2017:795-803.
32. Jain P, Finger PT, Damato B, et al. Multicenter, International Assessment of the Eighth Edition of the American Joint Committee on Cancer Cancer Staging Manual for Conjunctival Melanoma. *JAMA Ophthalmol.* 2019;137(8):905-911.
33. Tuomaala S, Toivonen P, Al-Jamal R, Kivela T. Prognostic significance of histopathology of primary conjunctival melanoma in Caucasians. *Curr Eye Res.* 2007;32(11):939-952.
34. van Ipenburg JA, Naus NC, Dubbink HJ, et al. Prognostic value of TERT promoter mutations in conjunctival melanomas in addition to clinicopathological features. *Br J Ophthalmol.* 2020:[Online ahead of print].
35. van Ipenburg JA, Gillis Ing AJM, Dorssers LCJ, et al. MicroRNA Profiling in Benign and Malignant Conjunctival Melanocytic Lesions. *Ophthalmology.* 2020;127(3):432-434.
36. Mikkelsen LH, Andersen MK, Andreasen S, et al. Global microRNA profiling of metastatic conjunctival melanoma. *Melanoma Res.* 2019;29(5):465-473.
37. Larsen AC, Dahl C, Dahmcke CM, et al. BRAF mutations in conjunctival melanoma: investigation of incidence, clinicopathological features, prognosis and paired premalignant lesions. *Acta Ophthalmol.* 2016;94(5):463-470.
38. Wong JR, Nanji AA, Galor A, Karp CL. Management of conjunctival malignant melanoma: a review and update. *Expert Rev Ophthalmol.* 2014;9(3):185-204.
39. Brouwer NJ, Marinkovic M, Peters FP, et al. Management of conjunctival melanoma with local excision and adjuvant brachytherapy. *Eye (Lond).* 2021;35(2):490-498.
40. Brouwer NJ, Marinkovic M, van Duinen SG, et al. Treatment of conjunctival melanoma in a Dutch referral centre. *Br J Ophthalmol.* 2018;102(9):1277-1282.
41. Paridaens AD, McCartney AC, Minassian DC, Hungerford JL. Orbital exenteration in 95 cases of primary conjunctival malignant melanoma. *Br J Ophthalmol.* 1994;78(7):520-528.
42. Wuestemeyer H, Sauerwein W, Meller D, et al. Proton radiotherapy as an alternative to exenteration in the management of extended conjunctival melanoma. *Graefes Arch Clin Exp Ophthalmol.* 2006;244(4):438-446.
43. Griewank KG, Westekemper H, Schilling B, et al. Conjunctival melanomas harbor BRAF and NRAS mutations--response. *Clin Cancer Res.* 2013;19(22):6331-6332.
44. Weber JL, Smalley KS, Sondak VK, Gibney GT. Conjunctival melanomas harbor BRAF and NRAS mutations--Letter. *Clin Cancer Res.* 2013;19(22):6329-6330.
45. Finger PT, Pavlick AC. Checkpoint inhibition immunotherapy for advanced local and systemic conjunctival melanoma: a clinical case series. *J Immunother Cancer.* 2019;7(1):83.
46. Sagiv O, Thakar SD, Kandl TJ, et al. Immunotherapy With Programmed Cell Death 1 Inhibitors for 5 Patients With Conjunctival Melanoma. *JAMA Ophthalmol.* 2018;136(11):1236-1241.

47. Mor JM, Rokohl AC, Koch KR, Heindl LM. Sentinel lymph node biopsy in the management of conjunctival melanoma: current insights. *Clin Ophthalmol.* 2019;13:1297-1302.
48. Esmaeli B, Wang X, Youssef A, Gershenwald JE. Patterns of regional and distant metastasis in patients with conjunctival melanoma: experience at a cancer center over four decades. *Ophthalmology.* 2001;108(11):2101-2105.
49. Tuomaala S, Kivela T. Metastatic pattern and survival in disseminated conjunctival melanoma: implications for sentinel lymph node biopsy. *Ophthalmology.* 2004;111(4):816-821.
50. Shields CL, Kaliki S, Al-Dahmash SA, Lally SE, Shields JA. American Joint Committee on Cancer (AJCC) clinical classification predicts conjunctival melanoma outcomes. *Ophthal Plast Reconstr Surg.* 2012;28(5):313-323.
51. Shields CL. Conjunctival melanoma: risk factors for recurrence, exenteration, metastasis, and death in 150 consecutive patients. *Trans Am Ophthalmol Soc.* 2000;98:471-492.
52. Werschnik C, Lommatzsch PK. Long-term follow-up of patients with conjunctival melanoma. *Am J Clin Oncol.* 2002;25(3):248-255.
53. Shields CL, Kaliki S, Furuta M, Mashayekhi A, Shields JA. Clinical spectrum and prognosis of uveal melanoma based on age at presentation in 8,033 cases. *Retina.* 2012;32(7):1363-1372.
54. Singh AD, Turell ME, Topham AK. Uveal melanoma: trends in incidence, treatment, and survival. *Ophthalmology.* 2011;118(9):1881-1885.
55. Virgili G, Gatta G, Ciccolallo L, et al. Incidence of uveal melanoma in Europe. *Ophthalmology.* 2007;114(12):2309-2315.
56. Yu GP, Hu DN, McCormick SA. Latitude and incidence of ocular melanoma. *Photochem Photobiol.* 2006;82(6):1621-1626.
57. Aronow ME, Topham AK, Singh AD. Uveal Melanoma: 5-Year Update on Incidence, Treatment, and Survival (SEER 1973-2013). *Ocul Oncol Pathol.* 2018;4(3):145-151.
58. Jager MJ, Shields CL, Cebulla CM, et al. Uveal melanoma. *Nat Rev Dis Primers.* 2020;6(1):24.
59. Van Raamsdonk CD, Bezrookove V, Green G, et al. Frequent somatic mutations of GNAQ in uveal melanoma and blue naevi. *Nature.* 2009;457(7229):599-602.
60. Van Raamsdonk CD, Griewank KG, Crosby MB, et al. Mutations in GNA11 in uveal melanoma. *N Engl J Med.* 2010;363(23):2191-2199.
61. Yu FX, Luo J, Mo JS, et al. Mutant Gq/11 promote uveal melanoma tumorigenesis by activating YAP. *Cancer Cell.* 2014;25(6):822-830.
62. Feng X, Degese MS, Iglesias-Bartolome R, et al. Hippo-independent activation of YAP by the GNAQ uveal melanoma oncogene through a trio-regulated rho GTPase signaling circuitry. *Cancer Cell.* 2014;25(6):831-845.
63. Vader MJC, Madigan MC, Versluis M, et al. GNAQ and GNA11 mutations and downstream YAP activation in choroidal nevi. *Br J Cancer.* 2017;117(6):884-887.
64. Yavuzyigitoglu S, Koopmans AE, Verdijk RM, et al. Uveal Melanomas with SF3B1 Mutations: A Distinct Subclass Associated with Late-Onset Metastases. *Ophthalmology.* 2016;123(5):1118-1128.
65. Smit KN, Jager MJ, de Klein A, Kili E. Uveal melanoma: Towards a molecular understanding. *Prog Retin Eye Res.* 2019:100800.
66. Dogrusöz M, Jager MJ. Genetic prognostication in uveal melanoma. *Acta Ophthalmol.* 2018;96(4):331-347.
67. Harbour JW, Onken MD, Roberson ED, et al. Frequent mutation of BAP1 in metastasizing uveal melanomas. *Science.* 2010;330(6009):1410-1413.
68. Carbone M, Yang H, Pass HI, et al. BAP1 and cancer. *Nat Rev Cancer.* 2013;13(3):153-159.
69. van Essen TH, van Pelt SI, Versluis M, et al. Prognostic parameters in uveal melanoma and their association with BAP1 expression. *Br J Ophthalmol.* 2014;98(12):1738-1743.

70. Koopmans AE, Verdijk RM, Brouwer RW, et al. Clinical significance of immunohistochemistry for detection of BAP1 mutations in uveal melanoma. *Mod Pathol.* 2014;27(10):1321-1330.
71. Hanahan D, Weinberg RA. Hallmarks of cancer: the next generation. *Cell.* 2011;144(5):646-674.
72. Niederkorn JY. Immune escape mechanisms of intraocular tumors. *Prog Retin Eye Res.* 2009;28(5):329-347.
73. Davidorf FH, Lang JR. Lymphocytic infiltration in choroidal melanoma and its prognostic significance. *Trans Ophthalmol Soc U K.* 1977;97(3):394-401.
74. de la Cruz PO, Jr., Specht CS, McLean IW. Lymphocytic infiltration in uveal malignant melanoma. *Cancer.* 1990;65(1):112-115.
75. de Waard-Siebinga I, Hilders CG, Hansen BE, van Delft JL, Jager MJ. HLA expression and tumor-infiltrating immune cells in uveal melanoma. *Graefes Arch Clin Exp Ophthalmol.* 1996;234(1):34-42.
76. Bronkhorst IH, Jager MJ. Inflammation in uveal melanoma. *Eye (Lond).* 2013;27(2):217-223.
77. Makitie T, Summanen P, Tarkkanen A, Kivela T. Microvascular density in predicting survival of patients with choroidal and ciliary body melanoma. *Invest Ophthalmol Vis Sci.* 1999;40(11):2471-2480.
78. Bronkhorst IH, Vu TH, Jordanova ES, et al. Different subsets of tumor-infiltrating lymphocytes correlate with macrophage influx and monosomy 3 in uveal melanoma. *Invest Ophthalmol Vis Sci.* 2012;53(9):5370-5378.
79. Gezgin G, Dogrusöz M, van Essen TH, et al. Genetic evolution of uveal melanoma guides the development of an inflammatory microenvironment. *Cancer Immunol Immunother.* 2017;66(7):903-912.
80. Damato EM, Damato BE. Detection and time to treatment of uveal melanoma in the United Kingdom: an evaluation of 2,384 patients. *Ophthalmology.* 2012;119(8):1582-1589.
81. Qiu M, Shields CL. Choroidal Nevus in the United States Adult Population: Racial Disparities and Associated Factors in the National Health and Nutrition Examination Survey. *Ophthalmology.* 2015;122(10):2071-2083.
82. Singh AD, Kalyani P, Topham A. Estimating the risk of malignant transformation of a choroidal nevus. *Ophthalmology.* 2005;112(10):1784-1789.
83. Shields CL, Furuta M, Berman EL, et al. Choroidal nevus transformation into melanoma: analysis of 2514 consecutive cases. *Arch Ophthalmol.* 2009;127(8):981-987.
84. Bakri SJ, Sculley L, Singh AD. Diagnostic techniques. In: Singh AD, Damato BE, Pe'er J, Murphree AL, Perry JD, eds. *Clinical Ophthalmic Oncology*. Edinburgh, UK: Elsevier-Saunders; 2007:175-180.
85. Shields JA, Shields CL, Ehya H, Eagle RC, Jr., De Potter P. Fine-needle aspiration biopsy of suspected intraocular tumors. The 1992 Urwick Lecture. *Ophthalmology.* 1993;100(11):1677-1684.
86. Singh AD, Medina CA, Singh N, et al. Fine-needle aspiration biopsy of uveal melanoma: outcomes and complications. *Br J Ophthalmol.* 2016;100(4):456-462.
87. Kivela T, Simpson ER, Grossniklaus HE, et al. Uveal Melanoma. In: Amin MB ES, Green F, ed. *AJCC Cancer Staging Manual, 8th ed*. New York: Springer; 2017:805-817.
88. Dogrusoz M, Bagger M, van Duinen SG, et al. The Prognostic Value of AJCC Staging in Uveal Melanoma Is Enhanced by Adding Chromosome 3 and 8q Status. *Invest Ophthalmol Vis Sci.* 2017;58(2):833-842.
89. Onken MD, Worley LA, Char DH, et al. Collaborative Ocular Oncology Group report number 1: prospective validation of a multi-gene prognostic assay in uveal melanoma. *Ophthalmology.* 2012;119(8):1596-1603.
90. Jager MJ, Brouwer NJ, Esmaeli B. The Cancer Genome Atlas Project: An Integrated Molecular View of Uveal Melanoma. *Ophthalmology.* 2018;125(8):1139-1142.
91. Archer DB, Amoaku WM, Gardiner TA. Radiation retinopathy--clinical, histopathological, ultrastructural and experimental correlations. *Eye (Lond).* 1991;5 (Pt 2):239-251.
92. Archer DB, Gardiner TA. Ionizing radiation and the retina. *Curr Opin Ophthalmol.* 1994;5(3):59-65.
93. Boyd SR, Tan D, Bunce C, et al. Vascular endothelial growth factor is elevated in ocular fluids of eyes harbouring uveal melanoma: identification of a potential therapeutic window. *Br J Ophthalmol.* 2002;86(4):448-452.

94. Lee CS, Jun IH, Kim TI, et al. Expression of 12 cytokines in aqueous humour of uveal melanoma before and after combined Ruthenium-106 brachytherapy and transpupillary thermotherapy. *Acta Ophthalmol.* 2012;90(4):e314-320.
95. Chen MX, Liu YM, Li Y, Yang X, Wei WB. Elevated VEGF-A & PLGF concentration in aqueous humor of patients with uveal melanoma following Iodine-125 plaque radiotherapy. *Int J Ophthalmol.* 2020;13(4):599-605.
96. Shields CL, Dalvin LA, Chang M, et al. Visual Outcome at 4 Years Following Plaque Radiotherapy and Prophylactic Intravitreal Bevacizumab (Every 4 Months for 2 Years) for Uveal Melanoma: Comparison With Nonrandomized Historical Control Individuals. *JAMA Ophthalmology.* 2020;138(2):136-146.
97. Powell BE, Finger PT. Anti-VEGF Therapy Immediately after Plaque Radiation Therapy Prevents or Delays Radiation Maculopathy. *Ophthalmol Retina.* 2020;4(5):547-550.
98. Heppt MV, Steeb T, Schlager JG, et al. Immune checkpoint blockade for unresectable or metastatic uveal melanoma: A systematic review. *Cancer Treat Rev.* 2017;60:44-52.
99. Niederkorn JY. Ocular immune privilege and ocular melanoma: parallel universes or immunological plagiarism? *Front Immunol.* 2012;3:148.
100. Damato B. Progress in the management of patients with uveal melanoma. The 2012 Ashton Lecture. *Eye (Lond).* 2012;26(9):1157-1172.
101. Roelofsen CDM, Wierenga APA, van Duinen S, et al. Five Decades of Enucleations for Uveal Melanoma in One Center: More Tumors with High Risk Factors, No Improvement in Survival over Time. *Ocul Oncol Pathol.* 2021;7(2):133-141.
102. Shields CL, Kaliki S, Furuta M, et al. American Joint Committee on Cancer classification of posterior uveal melanoma (tumor size category) predicts prognosis in 7731 patients. *Ophthalmology.* 2013;120(10):2066-2071.
103. Shields CL, Di Nicola M, Bekerman VP, et al. Iris Melanoma Outcomes Based on the American Joint Committee on Cancer Classification (Eighth Edition) in 432 Patients. *Ophthalmology.* 2018;125(6):913-923.

PART I: CONJUNCTIVAL MELANOMA

Chapter 2: Current Treatments

2.1 Treatment of Conjunctival Melanoma in a Dutch Referral Centre
2.2 Lack of Tumour Pigmentation in Conjunctival Melanoma is Associated with Light Iris Colour and Worse Prognosis
2.3 Pigmentation of Conjunctival Melanoma Recurrences and Outcome

Chapter 3: Treatment Targets

3.1 Conjunctival Melanoma: New Insights in Tumour Genetics and Immunology leading to New Therapeutic Options
3.2 PD-L1/PD-1 Expression and Tumor-Infiltrating Lymphocytes in Conjunctival Melanoma

2.1

Treatment of Conjunctival Melanoma in a Dutch Referral Centre

Niels J. Brouwer[1], Marina Marinkovic[1], Sjoerd G. van Duinen[2], Jaco C. Bleeker[1], Martine J. Jager[1], Gregorius P.M. Luyten[1]

Br J Ophthalmol 2018; 102(9):1277-1282

1. Department of Ophthalmology, Leiden University Medical Center, Leiden, The Netherlands
2. Department of Pathology, Leiden University Medical Center, Leiden, The Netherlands

ABSTRACT

Aims: To evaluate the treatment of conjunctival melanoma at a large Dutch referral centre and to make recommendations for clinical management.

Methods: A retrospective review was performed of clinical and histological data of 70 patients treated for a primary conjunctival melanoma between 2001 and 2014 at the LUMC, Leiden, The Netherlands. Detailed follow-up data were available for all patients.

Results: The mean follow-up time was 70.2 months. The overall 5-year recurrence rate was 29%, the 5-year metastasis rate 12%, and the 5-year melanoma-related survival 90%. Treatment with excision alone had a significantly higher 5-year recurrence rate than (the combination of) other treatments (HR 3.73, 95% CI 1.19 to 11.6, p=0.02). Initial treatment in an ocular oncology centre was associated with fewer recurrences compared with initial treatment by a local ophthalmologist of a referring centre (HR 0.32, 95% CI 0.11 to 0.94, p=0.04), despite similar tumour baseline characteristics.

Conclusion: Conjunctival melanoma is a rare disease with a high recurrence rate. A treatment strategy with local excision and adjuvant therapy gave a good clinical outcome, excision alone as a treatment should be considered obsolete. Initial treatment in a large referral centre improves clinical outcome, and patients should be referred to a specialised centre as soon as possible.

INTRODUCTION

Conjunctival melanoma (CM) is a rare ocular malignancy with an incidence of 0.3-0.8 per million in Caucasians.[1-4] Although the disease remains uncommon in other ethnicities, a rising incidence in Caucasians has been reported.[1,2,4,5] CM originates from melanocytes of the conjunctiva and can develop in association with primary acquired melanosis (PAM) (in up to 74% of cases), nevi (7%) or de novo (19%).[6] The clinical presentation of CM may vary, and melanoma may be localised in any part of the bulbar, forniceal, or tarsal conjunctiva. The presenting lesion may be amelanotic, brownish or black.

Primary CM is generally treated with wide local excision, followed by adjuvant treatment, such as cryotherapy, brachytherapy or topical chemotherapy.[7] More extensive surgical procedures such as exenteration are used as a last resort therapy. Other treatments such as electron beam radiotherapy and proton beam irradiation are used but the available literature regarding their use is limited.[7] Newer treatments as targeted therapy and immunotherapy for metastases are under investigation, although no proven treatment for distant metastasis is available yet. The local recurrence rate – despite treatment – is high (61% of patients after 5 years), and a melanoma-related death of up to 14% after 5 years has been reported.[8] Different factors affect clinical outcome, most of which are related to tumour location, thickness and histopathological characteristics.[6,8-10]

In this study, we describe the clinical outcome of 70 patients with CM seen at a national referral centre for ocular malignancies in The Netherlands. The study group consists of first-presenting primary tumours, with a complete follow-up. We set out to determine which treatments had the best outcome and to make recommendations for clinical management based on our data and experience.

METHODS

Patient selection

We identified patients with CM seen or treated at our institution for a first presentation of CM between January 2001 and December 2014 by searching the institutional cancer registration system and institutional pathology reports. Patients referred for a recurrence were not included. In total, 70 patients with histologically proven invasive primary CM were included in this study. Patients with only non-invasive in situ melanoma of the conjunctiva were excluded. The pathological examination was performed by an experienced ophthalmological pathologist; material obtained in other centres was reviewed in our institution.

Clinical and histological data

A retrospective review of clinical records, pathology reports and photographic images was performed. Baseline characteristics collected at presentation included patient age at diagnosis, tumour size and localisation. Based on data from pathology reports, medical files, and (colour) photographs, tumour size and localisation were identified. CM of the cornea, limbus or bulbar conjunctiva was categorised as 'epibulbar', with CM at other sites being categorised as 'non-epibulbar'. Cell type (spindle/epithelioid), presence of mitoses, ulceration, and extension into lateral or deep margin were obtained from pathology reports and by review of pathology samples. Follow-up data included type and number of received treatments and clinical outcome (local recurrence, metastasis, death). The location of the first received treatment was categorised as 'ocular oncology centre' (our institution) or 'local ophthalmologist of a referring centre' (elsewhere). Local recurrence was defined as the recurrence of histologically proven invasive CM. Metastases were identified with imaging techniques, including ultrasound (US), MRI, CT, or pathological analysis of suspected lesions. The seventh edition of the American Joint Committee on Cancer tumour, node, metastases (AJCC TNM) staging was used to stage all tumours.[11]

Statistical analysis

Univariate Cox regression analyses were done and Kaplan-Meier (KM) survival curves were generated to analyse clinical outcome. HRs with corresponding 95% CIs were provided. KM analyses were tested for significance with log-rank tests.

Differences between categorical data were evaluated using Pearson's x^2 test or Fisher exact test. Differences between numerical data were analysed with the Mann-Whitney U test.

A P-value < 0.05 was considered statistically significant for all analyses. Data analyses were performed with SPSS software V.23.0.

RESULTS

Clinical presentation

Baseline characteristics of the included patients are presented in table 1. Seventy patients (35 males, 35 females) with a mean age at diagnosis of 60.3 years were included (median: 60.3 years). Tumour location was epibulbar in 54 cases (77%), and non-epibulbar in 16 cases (23%). The mean 'largest basal diameter' at presentation was available in 50 cases with a mean of 9.0 mm (median: 7.1 mm). Tumour thickness was available in 54 cases with a mean of 2.3 mm (median: 1.2 mm). According to the seventh edition of the AJCC TNM classification, 77% of the cases were graded as T1 and 23% as T2. No lymph node metastases (N1) or distant metastases (M1) were present at baseline.

Table 1. Patient and tumour characteristics.

	Overall	Recurrence		Metastasis		Melanoma-Related Death		Exenterations	
Item	**Cases (%)**	**Cases (%)**	**p**	**Cases (%)**	**p**	**Cases (%)**	**p**	**Cases (%)**	**p**
Overall	**70 (100)**	**20 (29)**		**9 (13)**		**9 (13)**		**11 (16)**	
Sex									
Male	35 (50)	10 (29)	1.00	6 (17)	0.48*	5 (14)	1.00*	7 (20)	0.32
Female	35 (50)	10 (29)		3 (9)		4 (11)		4 (11)	
Age at diagnosis									
<60 years	35 (50)	8 (23)	0.29	2 (6)	0.15*	2 (6)	0.15*	4 (11)	0.32
≥60 years	35 (50)	12 (34)		7 (20)		7 (20)		7 (20)	
Side									
Left (OS)	33 (47)	10 (30)	0.76	4 (12)	1.00*	5 (15)	0.73*	6 (18)	0.59
Right (OD)	37 (53)	10 (27)		5 (14)		4 (11)		5 (14)	
Location									
Epibulbar	54 (77)	17 (32)	0.53*	6 (11)	0.42*	5 (9)	0.20*	3 (6)	<0.001
Non-epibulbar	16 (23)	3 (19)		3 (19)		4 (25)		8 (50)	
cTNM									
T1	54 (77)	17 (32)	0.53*	6 (11)	0.42*	5 (9)	0.20*	3 (6)	<0.001
T2	16 (23)	3 (19)		3 (19)		4 (25)		8 (50)	
PAM									
Present	65 (93)	20 (31)	0.31*	8 (12)	0.51*	8 (12)	0.51*	11 (17)	1.00*
Absent	0 (0)	0 (0)		0 (0)		0 (0)		0 (0)	
Unknown	5 (7)	0 (0)		1 (20)		1 (20)		0 (0)	
Initial treatment									
Our institution	48 (69)	10 (21)	0.03	6 (13)	1.00*	7 (15)	0.71*	10 (21)	0.15*
Elsewhere	22 (31)	10 (46)		3 (14)		2 (9)		1 (5)	
Period									
2001 to 8/2012	53 (76)	17 (32)	0.36*	8 (15)	0.44*	9 (17)	0.10*	6 (11)	0.12*
9/2012 to 2014	17 (24)	3 (18)		1 (6)		0 (0)		5 (29)	
Thickness (mm)									
<2	36 (51)	10 (28)	0.41	4 (11)	1.00*	4 (11)	0.67*	2 (6)	0.004*
≥2	18 (26)	7 (39)		2 (11)		3 (17)		7 (39)	

*P values are calculated with Pearson's x^2 tests, unless indicated with * for Fisher's exact tests.*
cTNM, clinical tumour, node, metastases stage; PAM, primary acquired melanosis.

Treatments

Data on initial treatment following diagnosis of the CM was available for all patients (table 2). In total, 48 patients (69%) received the first treatment for their CM in an ocular oncology centre, and 22 patients (31%) received their first treatment from the local ophthalmologist of the referring

centre. Patient characteristics did not differ between the two groups in mean age, tumour size or thickness; a trend was observed for more stage 1 (epibulbar) melanoma in the referred patients (p=0.063) (supplementary table 1). Treatment for the primary CM consisted most often of surgical excision with adjuvant therapy, being cryotherapy (10%, n =7), chemotherapy (1%, n=1,), ruthenium plaque (16%, n=11), strontium brachytherapy (30%, n=21) or iridium brachytherapy (3%, n=2). Other treatments were excision alone (26%, n=18), exenteration (9%, n=6), or external beam radiotherapy (6%, n=4). Patients who received their first treatment elsewhere all underwent local excision (without other treatment) before they were referred to our institution. After intake, 15 patients received adjuvant re-excision, cryotherapy, brachytherapy or a combination of those. Seven patients received no further treatment as already months had passed without clinical changes, or as the exact location of the primary lesion could not be determined any more. Treatments for first recurrences were most often excision with ruthenium (21%, n=4) or excision with strontium (27%, n=5). Last resort therapy for recurrences was external beam irradiation (n=1, 5%) or exenteration (n=3, 16%). At the end of follow-up, an exenteration was performed in 11 cases (16%).

Table 2. Initial treatments for conjunctival melanoma in respect to period and clinical outcome.

	Total	2001 to August 2012	September 2012 to 2014	Recurrence	Metastasis	Melanoma-Related Death	Exenteration
Item	**Cases (%)**	**Cases (%)**	**Cases (%)**	**Cases (%)**	**Cases (%)**	**Cases (%)**	**Cases (%)**
Overall	**70 (100)**	**53 (100)**	**17 (100)**	**20 (29)**	**9 (13)**	**9 (13)**	**11 (16)**
Excision alone	18 (26)	16 (30)	2 (12)	9 (50)	1 (6)	2 (11)	0 (0)
Excision + cryotherapy	7 (10)	7 (13)	0 (0)	1 (14)	2 (25)	2 (25)	1 (13)
Excision + mitomycin	1 (1)	1 (2)	0 ()	1 (100)	0 (0)	0 (0)	0 (0)
Excision + ruthenium	11 (16)	0 (0)	11 (65)	3 (27)	1 (9)	0 (0)	1 (9)
Excision + strontium	21 (30)	21 (40)	0 (0)	4 (19)	2 (10)	2 (10)	1 (5)
Excision + iridium	2 (3)	2 (4)	0 (0)	1 (50)	1 (50)	1 (50)	1 (50)
External beam radiation	4 (6)	4 (8)	0 (0)	1 (25)	2 (50)	2 (50)	1 (25)
Exenteration	6 (9)	2 (4)	4 (24)	0 (0)	0 (0)	0 (0)	6 (100)

Clinical outcome

Follow-up data was available for all patients with a mean of 70.2 months (median 56.7, range 3.3-172.3). No patient was lost to follow-up, and follow-up data of >1 year were available for 68 patients (97%). In total, 20 patients developed a local recurrence (29%), with a 5-year recurrence rate of

29%. Distant metastases were found in nine cases (13%), which were located in the liver (n=4), lung (n=3), brain (n=1) or elsewhere (n=4), with an overall 5-year metastasis rate of 12% (10-years: 23%). Regional (lymph node) metastases were detected in seven patients (10%), of whom 5 (71%) developed distant metastases later on; four patients (6% of all patients) developed distant metastases without (known) prior lymph node involvement. At the end of follow-up, 21 patients had died (30%) of whom 9 had died from melanoma-related causes, 4 from other causes, and 8 due to an unknown cause. Proven melanoma-related mortality at the end of follow up is therefore 13%, with a 5-year melanoma-related survival of 90% (10 years: 74%). The 5-year overall survival is 72% (10 years: 58%). With KM analysis, at 5-years, the exenteration rate was 14% (10 years: 20%).

Median visual acuity (VA, Snellen value) at baseline was 1.00 (mean: 0.96). The VA at the end of follow-up had remained the same in 54 cases (77%), had decreased due to treatment in 13 cases (19%) and due to other causes in 3 cases (4%). Overall, median VA at the end of follow up was 1.00 (mean: 0.84). Without exenterations (n=11), median VA was 1.00 (mean 0.99) (supplementary table 2).

Outcome analysis

We analysed the value of several parameters as potential predictive factors for the four main endpoints of this study (local recurrence, metastasis, melanoma-related survival and exenteration), as demonstrated in table 3. A higher stage according to the TNM classification was associated with an increased risk for exenteration (HR 17.0, 95% CI 3.7 to 77.9, p<0.001). Treatment with excision alone had a significantly higher 5-year recurrence rate than (the combination of) other treatments (HR 3.73, 95% CI 1.19 to 11.6, p=0.02). The recurrence rate was less for patients treated directly at our ocular oncology centre compared with patients receiving their first treatment elsewhere (HR 0.32, 95% CI 0.11 to 0.94, p=0.04). Tumour thickness >2.0 mm was significantly associated with the risk of eventual exenteration (HR 10.8, 95% CI 2.0 to 59.9, p=0.006). Patients with a local recurrence were at higher risk of death due to melanoma (HR 6.71, 95% CI 1.49 to 30.4, p=0.013), and a trend towards a higher risk for metastasis was observed (HR 3.83, 95% CI 0.91 to 16.1, p=0.067). Cell type (spindle/epithelioid), mitoses (no/yes), ulceration (no/yes), extensions into lateral margin (no/yes) and extension into deep margin (no/yes) were not significantly related to the outcome in our cohort.

DISCUSSION

We evaluated the clinical outcome of 70 patients with CM treated at our institution and obtained follow-up data of all patients. The mean follow-up time was 70.2 months. We observed a 5-year local recurrence rate of 29%, a 5-year metastasis rate of 12% and a 5-year melanoma-related survival of 90%. Patients receiving their first treatment at an ocular oncology centre had significantly fewer recurrences than patients receiving their first treatment by the local ophthalmologist of the referring centre, despite similar baseline characateristics.

Our results compare favourably to other reports with regard to the main clinical outcome parameters. The 5-year recurrence rate of 29% is favourable compared with the ranges of 26-61% reported by other groups[6,8,10,12,13] while the 5-year metastasis rate of 12% is comparable to the rates in other reports (11-16%).[12,14] Our 10-year metastasis rate of 23% is within the range of 18-26% reported in the literature,[12,14] as is the 5-year melanoma-related survival of 90% (reported ranges of 68-93%[1,8,9,12,13]). The rate of initial exenterations is somewhat low (9%), though wide ranges have been reported of 3-17%.[8-10,15,16] The eventual rate (11%) is comparable to others, ranging from 10% to 37%, with various follow-up times.[1,6,12,17]

A variety of treatments was available for our patients. A comparison between treatment options for clinical outcome is hampered by the small numbers in certain treatment groups, but a favourable outcome was detected for patients treated with adjuvant brachytherapy (either strontium or ruthenium plaque therapy) compared with the other groups (table 2). A clear worse recurrence rate was found for patients treated with excision alone compared with patients receiving other treatments (table 3). Although CM has the reputation of a sight-threatening disease,[18] VA remained good for all patients treated with non-exenteration (supplementary table 2). This quantifies an earlier suggestion by Damato.[19]

Table 3. Clinical outcome and prognostic values.

	Local Recurrence		Metastasis		Melanoma-Related Death		Exenteration	
Item	**HR (95% CI)**	**P value**	**HR (95% CI)**	**P value**	**HR (95% CI)**	**P value**	**HR (95% CI)**	**P value**
Sex								
Male	Ref	1.00	Ref	0.29	Ref	0.72	Ref	0.33
Female	1.00 (0.35 to-2.82)		2.21 (0.51-9.64)		1.29 (0.32-5.28)		1.94 (0.51-7.33)	
Age								
<60 years	Ref	0.29	Ref	0.09	Ref	0.09	Ref	0.33
≥60 years	1.76 (0.61-5.05)		4.13 (0.79-21.48)		4.13 (0.79-21.5)		1.94 (0.51-7.33)	
Location								
Epibulbar	Ref	0.33	Ref	0.43	Ref	0.11	Ref	<0.001
Non-epibulbar	0.50 (0.13-2.00)		1.85 (0.41-8.40)		3.27 (0.76-14.0)		17.0 (3.7-77.9)	
cTNM								
T1	Ref	0.33	Ref	0.43	Ref	0.11	Ref	<0.001
T2	0.50 (0.13-2.00)		1.85 (0.41-8.40)		3.27 (0.76-14.0)		17.0 (3.7-77.9)	
Initial location								
Our Institution	0.32 (0.11-0.94)	0.04	0.91 (0.20-4.01)	0.90	1.71 (0.33-8.98)	0.53	5.5 (0.66-46.21)	0.12
Elsewhere	Ref		Ref		Ref		Ref	
Period								
2001 to August 2012	Ref	0.26	Ref	0.34	NA		Ref	0.09
Sept2012 to 2014	0.45 (0.12-1.79)		0.35 (0.04-3.04)				3.3 (0.85-12.5)	
Treatment								
Excision alone	3.73 (1.19-11.6)	0.02	0.32 (0.04-2.79)	0.30	0.80 (0.15-4.28)	0.80	NA	
Other	Ref		Ref		Ref			
Thickness (mm)								
<2	Ref	0.41	Ref	1.00	Ref	0.57	Ref	0.006
≥2	1.66 (0.50-5.47)		1.00 (0.17-6.05)		1.60 (0.32-8.07)		10.8 (2.0-59.9)	
Recurrence								
No	NA		Ref	0.07	Ref	0.01	Ref	0.19
Yes			3.83 (0.91-16.1)		6.71 (1.49-30.4)		2.44 (0.65-9.18)	

cTNM, clinical tumour, node, metastases system; NA, not applicable; Ref, reference value.

This study shows a better outcome for patients receiving their first treatment in an ocular oncology centre compared with patients first treated elsewhere (figure 1). This is interesting since no significant differences in maximum tumour size (p=0.36), thickness (p=0.96) or stage (p=0.063) were observed between these two groups, and all patients were referred because of a primary tumour, not a recurrence (supplementary table 1). Iatrogenic tumour seeding may be the cause of this observation, as noticed by Damato and Coupland after an audit of CM patients at their institution in Liverpool,[19] since less experienced surgeons may be less knowledgeable in their approach to this rare disease. A second cause that we propose may be treatment delay and information loss during the referral. Without extensive (photographic) documentation prior to surgery, it is generally difficult to plan appropriate adjuvant therapy and follow-up. By the design of this study – retrospectively including patients who were referred to our institution - we could not rule out a selection bias in patients who were treated elsewhere first, but as the (estimated) majority of Dutch patients with CM will be seen in our centre, we feel that this bias is limited. Like Damato and Coupland, we advise that patients with a lesion suspicious of CM are referred to a specialised centre, preferably without any prior surgery or biopsy. This referral should be accompanied with extensive documentation of the original lesion, and, if applicable, with presurgery photographs.

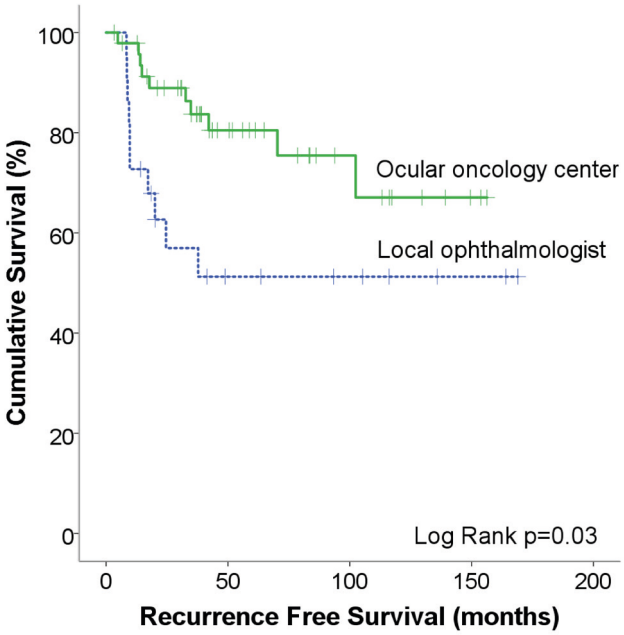

Figure 1. Kaplan-Meier analysis of the recurrence-free survival according to the institute of initial treatment; our institution (ocular oncology centre) versus elsewhere (local ophthalmologist).

In our institution, all patients with suspected ocular malignancies are seen by an ocular oncologist. The mainstay of our current treatment of smaller CM is wide local excision (margins of 2 mm) with adjuvant brachytherapy. During surgery, we apply formalin in a 4% solution with a cotton tip for 20 seconds to the lesion prior to excision. This is believed to cause fixation and to prevent tumour seeding, performed in our institution for many years.[20] Removal of the melanoma is performed using a no-touch technique. At the end of the procedure, the wound is closed when possible, especially if brachytherapy is planned. Larger wound surfaces and especially those in the nasal angle or fornices are covered with amniotic membrane to prevent the development of symblepharon; in smaller wounds, this is not necessary.The excised material is reviewed with immunohistochemical stainings by an experienced ophthalmo-pathologist to confirm diagnosis and assess tissue margins. Brachytherapy is usually applied in a second procedure with several days in between, after pathology has confirmed the diagnosis and has shown all conjunctival surgical margins to be free of tumour. For brachytherapy, we use Ruthenium-106 plaques (BEBIG, Berlin, Germany). Treatment aim is 100Gy at 2mm; this depth is default since no tumour thickness is left after surgery. Larger CM - not fully coverable with a Ruthenium-106 plaque - is treated with exenteration or external radiotherapy, though the latter should be considered as palliative procedure only. For cryotherapy, the double freeze-thaw procedure is used both on the conjunctival and/or limbal margins and the scleral bed. Excision alone should be considered obsolete. Excision with only cryotherapy or mitomycin C has become less common in our institution. In September 2012, strontium brachytherapy was largely abandoned in our centre for logistical reasons. Proton beam irradiation is currently not available in the Netherlands allthough a specialised centre will open shortly. We do not perform sentinel lymph node biopsies as a regular procedure, common greyscale US examination of the cervical/neck lymph nodes is performed every six months, however. A cytological puncture of the lymph nodes is performed if US examination reveals suspicious nodes.

At diagnosis, our systemic work up consists of X-ray imaging of the chest to detect possible pulmonary metastases and analysis of liver function and enzymes for hepatic metastases, in addition to the earlier mentioned US of the cervical/neck lymph nodes. We did not perform systemic screening as a regular procedure during follow-up of the studied period, but have since changed our protocol. Our follow-up regimen now consists of an outpatient clinic visit after 2, 4, 6, and 8 weeks, then once every 3 months for the first year, and once every 6 months thereafter. This is as suggested by Westekemper *et al*, though more frequent in the first visits.[21] Key points of the visit are slit-lamp examination with evertion of the eyelid, and clinical (ocular) photography; photography is always performed at intake, after treatment and at multiple moments during follow-up. Preferably, patients are seen by the same ophthalmologist at every visit enabling detection of small changes in appearance of the conjunctiva, and we would recommend that this follow-up is performed in the tertiary centre. All patients are discussed in a multi-disciplinary meeting with the ocular oncologists

and a radiotherapist. Currently, if PAM is present in areas besides the CM, topical treatment with mitomycin C (drops of 0.04%, four times daily, in two consecutive series of 14 days with 1 week in between) is applied. This was not yet part of the regular protocol during this study however.

This study describes the most recent cohort of patients with CM in The Netherlands. Availability of detailed follow-up data is a strong feauture of this study, as no patient was lost to follow-up. This can be explained by the relatively small size of the Netherlands and the dense, organised structure of healthcare with a national cancer registry. Although we describe one of the larger cohorts of CM patients, sample sizes are still small and this urges a critical view of the data analysis. It should be also noted that our cohort only contained T1 and T2 CM, although no selection regarding tumour stage was applied. Together with the high percentage of co-occurring PAM in our cohort (93%), a known precursor of CM, these issues might have hampered our statistical power to detect prognostic factors. The incidence of CM in the Netherlands could not be determined by this study, but is estimated to be in the range of 0.3-0.8/million, based on data from Scandinavian countries and the USA.[1-4]

In conclusion, CM is a rare ocular malignancy and continues to have a high local recurrence rate and a high mortality. With a current treatment strategy of local excision and adjuvant brachytherapy as the mainstay, we achieved a good clinical outcome comparable to other groups. VA is unthreatened in CM, apart from cases where there is a need for exenteration. Our study confirms the recommendation that patients with a lesion suspicious for CM should be referred as soon as possible to a reference centre for diagnosis and treatment, as this significantly improves clinical outcome. If patients are treated elsewhere first, we stress the importance of presurgery documentation, with photography, to allow proper adjuvant treatment and follow-up.

ACKNOWLEDGEMENTS

The authors thank all employees of their institution involved in the care and scientific research of ocular oncology patients for the contribution to this study.
Contributors: Design of the study: NJB, MM, MJJ. Data acquisition: NJB, MM, SGD. Data interpretation and critical revision and approval of the manuscript: all authors. Drafting the manuscript: NJB.
Funding: NJB received a MD/PhD programme grant from the Leiden University Medical Center.
Competing interests: None declared.
Ethics approval: The institutional medical ethics committee agreed with this retrospective study; the study adhered to the tenets of the declaration of Helsinki.
Provenance and peer review: Not commissioned; externally peer reviewed.

REFERENCES

1. Tuomaala S, Eskelin S, Tarkkanen A, Kivela T. Population-based assessment of clinical characteristics predicting outcome of conjunctival melanoma in whites. *Invest Ophthalmol Vis Sci.* 2002;43(11):3399-3408.
2. Yu GP, Hu DN, McCormick S, Finger PT. Conjunctival melanoma: is it increasing in the United States? *Am J Ophthalmol.* 2003;135(6):800-806.
3. Isager P, Osterlind A, Engholm G, et al. Uveal and conjunctival malignant melanoma in Denmark, 1943-97: incidence and validation study. *Ophthalmic Epidemiol.* 2005;12(4):223-232.
4. Triay E, Bergman L, Nilsson B, All-Ericsson C, Seregard S. Time trends in the incidence of conjunctival melanoma in Sweden. *Br J Ophthalmol.* 2009;93(11):1524-1528.
5. Hu DN, Yu G, McCormick SA, Finger PT. Population-based incidence of conjunctival melanoma in various races and ethnic groups and comparison with other melanomas. *Am J Ophthalmol.* 2008;145(3):418-423.
6. Shields CL, Markowitz JS, Belinsky I, et al. Conjunctival melanoma: outcomes based on tumor origin in 382 consecutive cases. *Ophthalmology.* 2011;118(2):389-395 e381-382.
7. Wong JR, Nanji AA, Galor A, Karp CL. Management of conjunctival malignant melanoma: a review and update. *Expert Rev Ophthalmol.* 2014;9(3):185-204.
8. Missotten GS, Keijser S, De Keizer RJ, De Wolff-Rouendaal D. Conjunctival melanoma in the Netherlands: a nationwide study. *Invest Ophthalmol Vis Sci.* 2005;46(1):75-82.
9. Anastassiou G, Heiligenhaus A, Bechrakis N, et al. Prognostic value of clinical and histopathological parameters in conjunctival melanomas: a retrospective study. *Br J Ophthalmol.* 2002;86(2):163-167.
10. Paridaens AD, Minassian DC, McCartney AC, Hungerford JL. Prognostic factors in primary malignant melanoma of the conjunctiva: a clinicopathological study of 256 cases. *Br J Ophthalmol.* 1994;78(4):252-259.
11. Edge SB BD, Compton CC. Malignant melanoma of the conjunctiva. In: Edge SB BD, Compton CC, ed. *AJCC Cancer Staging Manual*. 7 ed. New York: Springer; 2010:539-546.
12. Shields CL. Conjunctival melanoma: risk factors for recurrence, exenteration, metastasis, and death in 150 consecutive patients. *Trans Am Ophthalmol Soc.* 2000;98:471-492.
13. Werschnik C, Lommatzsch PK. Long-term follow-up of patients with conjunctival melanoma. *Am J Clin Oncol.* 2002;25(3):248-255.
14. Tuomaala S, Kivela T. Metastatic pattern and survival in disseminated conjunctival melanoma: implications for sentinel lymph node biopsy. *Ophthalmology.* 2004;111(4):816-821.
15. Shields CL, Shields JA, Gunduz K, et al. Conjunctival melanoma: risk factors for recurrence, exenteration, metastasis, and death in 150 consecutive patients. *Arch Ophthalmol.* 2000;118(11):1497-1507.
16. Larsen AC, Dahmcke CM, Dahl C, et al. A Retrospective Review of Conjunctival Melanoma Presentation, Treatment, and Outcome and an Investigation of Features Associated With BRAF Mutations. *JAMA Ophthalmol.* 2015;133(11):1295-1303.
17. Seregard S, Kock E. Conjunctival malignant melanoma in Sweden 1969-91. *Acta Ophthalmol (Copenh).* 1992;70(3):289-296.
18. Lim LA, Madigan MC, Conway RM. Conjunctival melanoma: a review of conceptual and treatment advances. *Clin Ophthalmol.* 2013;6:521-531.
19. Damato B, Coupland SE. An audit of conjunctival melanoma treatment in Liverpool. *Eye (Lond).* 2009;23(4):801-809.
20. Oosterhuis JA, de Wolff-Rouendaal D. Local metastasis in conjunctival melanoma. *Doc Ophthalmol.* 1983;56(1-2):55-59.
21. Westekemper H, Schallenberg M, Tomaszewski A, et al. [Malignant epibulbar tumours: new strategies in diagnostics and therapy]. *Klin Monbl Augenheilkd.* 2011;228(9):780-792.

SUPPLEMENTARY MATERIAL

Supplementary Table 1. Location of initial treatment.

	Overall	Initial location: Other	Initial location: Our Institution	
Item	**Cases**	**Cases (%)**	**Cases (%)**	**P value**
Overall	**70 (100)**	**22 (31)**	**48 (69)**	
Sex				0.61
-Male	35 (50)	10 (45)	25 (52)	
-Female	35 (50)	12 (55)	23 (48)	
Age at diagnosis				1.00
-<60 years	35 (50)	11 (50)	24 (50)	
-≥60 years	35 (50)	11 (50)	24 (50)	
Side				0.85
-OS	33 (47)	10 (45)	23 (48)	
-OD	37 (53)	12 (55)	25 (52)	
Location				0.063
-Epibulbar	54 (77)	20 (91)	34 (71)	
-Non-epibulbar	16 (23)	2 (9)	14 (29)	
cTNM				0.063
-T1	54 (77)	20 (91)	34 (71)	
-T2	16 (23)	2 (9)	14 (29)	
PAM				0.32*
-Present	65 (93)	19 (86)	46 (96)	
-Absent	0 (0)	0 (0)	0 (0)	
-Unknown	5 (7)	3 (14)	2 (4)	
Period				0.42
2001 - 08/2012	53 (7)	18 (82)	35 (73)	
-09/2012 - 2014	17 (24)	4 (18)	13 (27)	
Thickness				0.68
-Less 2mm	36 (51)	12 (71)	24 (65)	
-2mm or more	18 (26)	5 (29)	13 (35)	
LBD (mean, SD)	9.0 (6.1)	6.3 (3.3)	9.3 (6.3)	0.19**
Thickness (mean, SD)	2.3 (2.80)	2.1 (1.9)	2.3 (3.1)	0.59**

cTNM, clinical TNM stage; LBD, largest basal diameter; SD, Standard Deviation.
*P values are calculated with Pearson Chi-Square tests, unless indicated with * for Fisher Exact tests and ** for Mann-Whitney U tests.*

Supplementary Table 2. Visual Acuity at baseline and end of follow-up.

Item	Overall Cases (%)	Initial location: Elsewhere	Initial location: Our Institution	P value
VA initial		N=22	N=48	
-Mean, Snellen [SD]	0.96 [0.30]	0.92 [0.16]	0.98 [0.34]	0.15
-Median, Snellen	1.00	0.95	1.00	
VA at end of Follow-Up - overall				
-Mean, Snellen [SD]	0.84 [0.47]	0.93 [0.34]	0.79 [0.51]	0.57
-Median, Snellen	1.00	1.00	1.00	
VA at end of Follow-Up – excl exenterations		N=21	N=38	
-Mean, Snellen, [SD]	0.99 [0.32]	0.97 [0.28]	1.00 [0.35]	0.51
-Median, Snellen	1.00	1.00	1.00	
VA loss at end of Follow-Up				
-No loss	54 (77)	19 (86)	35 (73)	
-Loss by exenteration	11 (15)	1 (5)	10 (21)	
-Loss by other treatment	2 (3)	2 (9)	0 (0)	
-Loss by other cause	3 (4)	0 (0)	3 (6)	

VA, Visual Acuity.
P values were obtained by Mann-Whitney U test.

2.2

Lack of Tumour Pigmentation in Conjunctival Melanoma is Associated with Light Iris Colour and Worse Prognosis

Niels J. Brouwer[1], Marina Marinkovic[1], Gregorius P.M. Luyten[1], Carol L. Shields[2]*, Martine J. Jager[1]*
*CLS and MJJ share senior authorship

Br J Ophthalmol 2019; 103(3):332-337.

1. Department of Ophthalmology, Leiden University Medical Center, Leiden, The Netherlands
2. Ocular Oncology Service, Wills Eye Hospital, Thomas Jefferson University, Philadelphia, Pennsylvania, U.S.A.

ABSTRACT

Aim: To investigate whether differences in iris colour, skin colour and tumour pigmentation are related to clinical outcome in conjunctival melanoma.

Methods: Data of 70 patients with conjunctival melanoma from the Leiden University Medical Centre (Leiden, The Netherlands) and 374 patients from the Wills Eye Hospital (Philadephia, USA) were reviewed. The relation between iris colour, skin colour, and tumour pigmentation versus clinical parameters and outcome was investigated using univariate and multivariate regression analyses.

Results: A light iris colour (blue, grey, green) was present in 261 (59%) of all patients and a dark colour (hazel, brown) in 183 (41%). A low tumour pigmentation was detected in 130 (40%) and a high pigmentation in 197 (60%) patients. Low tumour pigmentation was associated with light iris colour (p=0.021) but not related to skin colour (p=0.92). In univariate analysis, neither iris nor skin colour was related to clinical outcome, while a low tumour pigmentation was related to metastasis formation (HR 2.37, p=0.004) and death (HR 2.42, p=0.020). In multivariate analysis, low tumour pigmentation was related to the development of recurrences (HR 1.63, p=0.043), metastasis formation (HR 2.48, p=0.004) and death (HR 2.60, p=0.014).

Conclusion: Lightly pigmented tumours occurred especially in individuals with lightly coloured irises. While iris colour or skin colour was not significantly related to clinical outcome, a low tumour pigmentation was related to a worse outcome in patients with conjunctival melanoma. The amount and type of melanin in conjunctival melanocytes may be involved in the pathogenesis and behaviour of selected conjunctival melanoma.

INTRODUCTION

Conjunctival melanoma (CoM) is a rare but lethal malignancy of the eye, with a 10-year melanoma-related mortality of approximately 30%.[1-3] As few treatment options exist for advanced stages of CoM, it is important to investigate the mechanisms contributing to this disease and the development of metastases.

A pathway of interest is that of pigment and melanin synthesis. The role of these factors in tumour development and metastasis formation has been investigated in cutaneous and uveal melanoma (UM), and various pathways have been proposed to be involved.[4] Ocular melanin consists of two types: eumelanin and pheomelanin, which have different biological characteristics:[5] eumelanin has a brown/black colour and helps to protect against ultraviolet (UV) radiation-mediated damage, while pheomelanin has a yellow/red colour and has been associated with the induction of genotoxic stress, which is associated with DNA damage.[6-8] The colour of the iris and the skin is determined by the amount and type of melanin.[5,9]

Cutaneous and uveal melanomas typically occur in light-skinned people, and the incidence of both malignancies is higher in individuals with light-coloured irises.[10,11] A light iris colour has been associated with a higher risk of metastatic death in UM, but the mechanisms responsible need to be elucidated.[12] No conclusive results have been published on the association between iris colour, skin colour and the development of CoM. Pigmentation of the tumours themselves was investigated as well: amelanotic cutaneous melanoma has a significantly worse survival compared with melanotic cutaneous melanoma,[13] and one analysis found that low tumour pigmentation was similarly associated with a worse clinical outcome in UM.[14] Low tumour pigmentation has been associated with a worse prognosis in CoM,[15] but this was investigated in a limited number of patients as the disease is so rare.

The aim of this study is to evaluate the association between iris colour, skin colour, tumour pigmentation and clinical outcome in patients with CoM. We hypothesize that the presence of (dark-coloured) eumelanin, as opposed to (light-coloured) pheomelanin, may protect against the development of CoM recurrences and metastases. We therefore expect to find that light iris colour, light skin colour and low tumour pigmentation are associated with a worse clinical outcome in patients with CoM.

METHODS

Patient data

A retrospective analysis on data sets from the Leiden University Medical Center (LUMC, Leiden, The Netherlands) and the Wills Eye Hospital (WEH, Philadelphia, USA) was performed. The Leiden group consisted of 70 patients with histopathologically confirmed primary CoM, diagnosed between 2001 and 2014.[16] The WEH group consisted of 374 patients with histopathologically confirmed primary CoM, diagnosed between 1970 and 2003. The WEH group is part of a larger study group described earlier by Shields *et al*,[17] from which the patients with available data on eye colour were selected.

Statistics

The two data sets were analysed together to obtain enough cases for statistical analysis. Descriptive statistics of both the separate and combined data sets are provided. Categorical data were analysed with Pearson's X^2 tests. Numerical data were analysed with the Mann-Whitney U test. Outcome variables (local recurrence, distant metastasis, melanoma-related death, exenteration) were analysed with univariate and multivariate regression analyses. Two multivariate models were tested. In the first multivariate model, we investigated if the pigment-related variables (iris colour, skin colour, tumour pigmentation) were independently related to the outcome. The variables were entered without any selection criteria. A variable for institution was added to adjust for (unmeasured) differences between the two data sets. In the second multivariate model, we entered all variables with a $p<0.10$ from the univariate analysis using forward selection, to identify a model of significant parameters with a $p<0.05$. The HRs and 95% CIs were provided for all regression analyses.

Clinical characteristics

Iris colour was categorised as either 'light' (blue/grey/green) or 'dark' (hazel/brown). This division is based on the published melanin content of iridal melanocytes in different iris colours, with significantly higher eumelanin, a higher eumelanin/pheomelanin ratio and more total melanin in darker irises compared with lighter irises.[5] Tumour pigmentation was categorised visually as 'low pigmented' (non-pigmented/mixed) or 'high pigmented' (pigmented) (figure 1). Skin colour was categorised as 'fair' (fair/white) or 'non-fair' (tinted/olive/dark). Tumour location on the eye was categorized as 'epibulbar' for CoM only affecting the cornea, limbus or epibulbar conjunctiva, and 'non-epibulbar' for CoM affecting other areas on the eye. As this is a secondary analysis of two data sets, all parameters had been recorded earlier based on patient medical files including available medical photographs.

Figure 1. Three conjunctival melanomas with various degrees of pigmentation: (A) Pigmented lesion, (B) mixed lesion and (C) Non-pigmented lesion.

RESULTS

Patient characteristics

A total of 444 patients were included in this study, with 374 patients coming from the WEH, and 70 from the LUMC (table 1). Data on iris colour and skin colour were available for all patients, tumour pigmentation was known in 327 (74%) cases. Mean age at diagnosis was 59.5 years. The mean tumour thickness was 1.77 mm. Most tumours were epibulbar (63%). Patients from the Leiden group presented more often with an epibulbar tumour location compared with the WEH group (p=0.005), but they were similar with regard to other clinical parameters (online supplementary table 1).

Eye colour and skin colour

Light iris colour was detected in 59% of all patients, with a fair skin tone in 88%. Patients from the Leiden group more often had light-coloured irises (p<0.001) and a fair skin (p=0.035) compared with the WEH group (online supplementary table 1).

In the WEH group, a larger maximum basal diameter of the melanoma was associated with darker eye colour (p=0.02), and a non-epibulbar location was observed more frequently in patients with non-fair skin (p=0.005), while this could not be detected for the Leiden patients.

Tumour pigmentation

No or mixed tumour pigmentation was found in 40% of all patients. There was no significant difference in the percentage of lightly pigmented versus highly pigmented tumours between the Leiden group and the WEH group (p=0.31). Overall, there were no differences in clinical characteristics at baseline between lightly pigmented versus highly pigmented tumours. Low tumour pigmentation was related to light iris colour (p=0.022), but not to skin colour (p=0.92) (table 1).

Table 1. Patient and tumour characteristics of the total study group, consisting of 70 cases from the LUMC (Leiden, The Netherlands) and 374 cases from the WEH (Philadelphia, USA)

	Total	Light eye colour	Dark eye colour		Low pigmentation	High pigmentation	
Parameters	**Cases (%)**	**Cases (%)**	**Cases (%)**	**P value**	**Cases (%)**	**Cases (%)**	**P value**
Total	**444 (100)**	**261 (59)**	**183 (41)**		**130 (40)**	**197 (60)**	
Sex							
Male	217 (49)	131 (50)	86 (47)	0.51	56 (43)	98 (50)	0.24
Female	227 (51)	130 (50)	97 (53)		74 (57)	99 (50)	
Age at diagnosis (year)							
<60	202 (45)	115 (44)	87 (48)	0.47	59 (45)	75 (38)	0.19
≥60	242 (55)	146 (56)	96 (52)		71 (55)	122 (62)	
Age at diagnosis (year)							
Mean (SD)	59.5 (17.5)	60.1 (17.5)	58.5 (17.4)	0.37	60.6 (16.7)	62.0 (16.9)	0.38
Side							
Right (OD)	239 (54)	137 (52)	81 (44)	0.50	77 (59)	106 (54)	0.33
Left (OS)	205 (46)	124 (48)	102 (56)		53 (41)	91 (46)	
Location							
Epibulbar	215 (63)	138 (66)	77 (57)	0.08	80 (63)	119 (61)	0.75
Non-epibulbar	128 (37)	70 (34)	58 (43)		48 (38)	77 (39)	
Thickness (mm)							
Mean (SD)	1.77 (2.1)	1.80 (2.4)	1.73 (1.5)	0.30	1.69 (2.5)	1.90 (2.0)	0.50
Tumour LBD (mm)							
Mean (SD)	10.6 (8.1)	9.75 (7.7)	11.9 (8.5)	0.016	10.4 (7.8)	10.8 (8.3)	0.98
Iris colour							
Blue/green/grey	261 (59)	NA	NA	NA	86 (66)	105 (53)	0.021
Hazel/brown	183 (41)				44 (34)	92 (47)	

Table 1. Continued.

Parameters	Total	Light eye colour	Dark eye colour	P value	Low pigmentation	High pigmentation	P value
	Cases (%)	Cases (%)	Cases (%)		Cases (%)	Cases (%)	
Skin colour							
Fair	392 (88)	250 (96)	142 (78)	<0.001	113 (87)	172 (87)	0.92
Non-fair	52 (12)	11 (4)	41 (22)		17 (13)	25 (13)	
Institution							
WEH	374 (84)	202 (77)	172 (94)	<0.001	113 (87)	163 (83)	0.31
LUMC	70 (16)	59 (23)	11 (6)		17 (13)	34 (17)	
Recurrence							
Yes	177 (40)	106 (41)	71 (39)	0.70	67 (52)	81 (41)	0.064
Metastasis							
Yes	62 (14)	34 (13)	28 (15)	0.50	31 (24)	23 (12)	0.004
Melanoma-related death							
Yes	36 (8)	20 (8)	16 (9)	0.68	19 (15)	13 (7)	0.017
Exenteration							
Yes	50 (11)	28 (11)	22 (12)	0.67	24 (19)	23 (12)	0.09

LBD, largest basal diameter; LUMC, Leiden University Medical Center; NA, Not Applicable; OD, oculus dexter; OS, oculus sinister; WEH, Will's Eye Hospital.

Outcome analysis

The mean overall follow-up time was 56.3 months. A total of 177 patients (40%) developed a recurrence, 50 patients (11%) had an exenteration performed during follow-up, 62 patients (14%) developed a metastasis, and 36 patients (8%) died of a melanoma-related cause (table 1). Patients from the Leiden group less frequently developed a recurrence compared with patients from the WEH group (p=0.035), but the groups were similar for other clinical outcome measures (online supplementary table 1).

With univariate analysis (table 2), iris colour and skin colour were not significantly associated with the outcome measures, while low tumour pigmentation was significantly associated with the development of metastases (HR 2.37, p=0.004), and more melanoma-related deaths (HR 2.42, p=0.020); low pigmented tumours tended to have more frequent recurrences (HR 1.52, p=0.064) and a greater number of exenteration (HR 1.71, p=0.089). Follow-up time of lightly pigmented versus highly pigmented tumours was equal, with a mean of 57.9 and 55.2 months, respectively (p=0.42).

In the first multivariate model, the parameters of pigmentation (iris colour, skin colour, tumour pigmentation) were analysed together with an adjustment variable for institution (table 3). Low tumour pigmentation was related to more metastases (HR 2.45, p=0.004), and more melanoma-related deaths (HR 2.76, p=0.010), while there were trends for more recurrences (HR 1.51, p=0.082), and a greater number of exenteration (HR 1.80, p=0.068). Iris colour was not related to any of the outcome measures, but light skin colour showed a trend with more melanoma-related deaths (HR 6.19, p=0.082).

In the second multivariate model, we included parameters with a p<0.10 from the univariate analysis, using forward selection (table 2). As iris colour and skin colour were not related with p<0.10 to any of the outcome measures in univariate analysis, they were not analysed in the second multivariate model. Low tumour pigmentation was significantly related to more recurrences (HR 1.63, p=0.043), metastases (HR 2.48, p=0.004) and melanoma-related deaths (HR 2.60, p=0.014), but not to exenteration.

Table 2. Univariate and multivariate analyses of clinical outcome

	Recurrence			Metastasis			Melanoma-Related Death			Exenteration		
	HR	95% CI	P value	HR	95% CI	P value	HR	95% CI	P value	HR	95%CI	P value
Univariate analysis												
Iris colour*	1.08	0.73 to 1.59	0.70	0.83	0.48 to 1.42	0.50	0.87	0.44 to 1.72	0.68	0.88	0.49 to 1.59	0.67
Tumour pigmentation†	1.52	0.98 to 2.38	0.064	2.37	1.31 to 4.29	0.004	2.42	1.15 to 5.10	0.020	1.71	0.92 to 3.19	0.089
Skin colour‡	1.07	0.59 to 1.94	0.83	1.05	0.45 to 2.44	0.91	5.00	0.67 to 37.3	0.12	0.66	0.29 to 1.50	0.32
Institution§	0.55	0.32 to 0.97	0.037	0.89	0.42 to 1.91	0.77	1.90	0.85 to 4.23	0.12	1.60	0.78 to 3.30	0.20
Location on eye¶	1.67	1.07 to 2.59	0.023	3.53	1.93 to 6.46	<0.001	4.06	1.91 to 8.65	<0.001	4.44	2.30 to 8.60	<0.001
Age**	1.89	1.28 to 2.79	0.001	1.50	0.86 to 2.60	0.15	1.74	0.85 to 3.58	0.13	1.72	0.93 to 3.19	0.09
Thickness	1.03	0.87 to 1.22	0.76	1.01	0.79 to 1.30	0.91	1.03	0.78 to 1.35	0.84	1.48	1.14 to 1.92	0.003
LBD	1.02	0.99 to 1.05	0.22	0.99	0.96 to 1.03	0.79	0.96	0.91 to 1.02	0.19	1.04	1.00 to 1.08	0.03
Multivariate analysis (forward selection, variables with p<0.10 in univariate analysis)												
Tumour Pigmentation †	1.63	1.02 to 2.60	0.043	2.48	1.33 to 4.64	0.004	2.60	1.22 to 5.57	0.014	NA		
Location¶	1.67	1.05 to 2.67	0.031	3.43	1.83 to 6.46	<0.001	3.61	1.66 to 7.85	0.001	NA		
Age**	1.80	1.12 to 2.88	0.015	NA			NA			NA		
Institution§	0.32	0.16 to 0.66	0.002	NA			NA			NA		

** Light versus dark (ref).*
† Lightly/mixed pigmented versus highly pigmented (ref).
‡ Fair versus non-fair (ref).
§ Leiden versus Philadelphia (ref).
¶ Non-epibulbar versus epibulbar (ref).
***Age ≥60 years versus <60 year (ref).*
LBD, largest basal diameter; NA, not applicable, ref, reference.

Table 3. Multivariate analysis of pigment-related variables with clinical outcome

Univariate analysis	Recurrence			Metastasis			Melanoma-Related Death			Exenteration		
	HR	95% CI	P value	HR	95% CI	P value	HR	95% CI	P value	HR	95%CI	P value
Multivariate analysis (pigment-related variables, adjusted for institution)												
Iris Colour*	0.88	0.55-1.43	0.61	0.75	0.40-1.42	0.38	0.56	0.25-1.25	0.16	0.80	0.41-1.59	0.53
Tumour Pigmentation†	1.51	0.95-2.39	0.082	2.45	1.34-4.48	0.004	2.76	1.28-5.95	0.010	1.80	0.96-3.40	0.068
Skin Colour‡	1.33	0.66-2.66	0.42	1.44	0.55-3.80	0.46	6.19	0.79-48.4	0.082	0.71	0.29-1.73	0.45
Institution§	0.29	0.14-0.59	0.001	0.71	0.28-1.80	0.47	1.87	0.72-4.85	0.20	1.55	0.68-3.56	0.30

** Light versus dark (ref).*
† Lightly/mixed pigmented versus highly pigmented (ref).
‡ Fair versus non-fair (ref).
§ Leiden versus Philadelphia (ref).
95% CI=95% Confidence Interval; HR, Hazard Ratio; Ref, reference

DISCUSSION

We investigated the association between tumour pigmentation, iris colour, skin colour and clinical outcome in CoM. Low tumour pigmentation was significantly associated with a greater risk for recurrence, metastasis and melanoma-related death, even after adjustment for other clinical parameters and hospital. Iris colour or skin colour were not significantly related to outcome. Low tumour pigmentation was significantly related to light iris colour in patients with CoM, but not to skin colour.

To our knowledge, only one study reported on iris colour and clinical outcome in CoM.[18] Our current study is an extension of that study, increasing the number of patients from 150 to 444. Similar to the observation in the smaller group, we did not detect an independent relation between iris colour and outcome in CoM. This differs from findings in UM, where patients with blue/grey iris colour had a significantly increased risk of metastatic death compared with patients with darker irises.[12,19]

Our study showed an association between low tumour pigmentation and a greater risk for recurrences, metastases and metastatic deaths. The association between low tumour pigmentation and recurrence has been reported before in a smaller study, unadjusted for other parameters,[15] and a trend for this association was reported to occur in a Danish study.[20] The association between a low tumour pigmentation and the development of metastasis or death was shown earlier with univariate analysis for a set including the WEH patients,[17] but was not detected by the two other studies, which could relate to the considerably smaller sample sizes, having 69 and 127 patients, respectively.[15,20]

We did not observe a significant relation between low tumour pigmentation and risk of exenteration, which had been observed previously in a smaller case series.[21] As that study was adjusted for different variables and included fewer cases (n=151), this may explain why we currently have a different observation. As the decision to perform an exenteration is based on various (clinical) factors, it might be difficult to identify unbiased prognostic parameters.

Interestingly, tumour pigmentation was still related to clinical outcome in a multivariate analysis which included the three investigated pigment-related parameters (iris colour, skin colour, tumour pigmentation) (table 3).

To our knowledge, this is the first report to find an association between low tumour pigmentation and light iris colour in CoM, as has already been observed in choroidal and iris melanoma.[19 22,23]

Interestingly, we did not detect a relationship between low tumour pigmentation and skin colour in CoM, which we had expected because of the functional similarity of the conjunctiva and the skin.

Clinical outcome was also not related to skin colour in our study group. It may be concluded that a possible relationship is absent or too weak to be of clinical relevance, or that the (lack of) variation in our population did not allow a proper analysis.

In the study of different types of melanocytes, it is important to recall that conjunctival, uveal (including iridal) and cutaneous melanocytes are all assumed to be derived from the same embryonic cells.[24] They originate in the neural crest, with precursor cells following different migration routes to the distinct anatomical locations. Conjunctival melanocytes migrate to the surface ectoderm-derived epithelium and show functional similarities to melanocytes in the skin, such as transferring melanin to surrounding cells. Uveal melanocytes migrate to deeper, mesoderm-derived tissues and are adjacent to the neuro-ectoderm-derived retinal pigment epithelium (RPE) cells.[24,25] Although conjunctival, uveal and cutaneous melanomas are all derived from the neural crest, it is as yet unknown how the genetic differences – with e.g. different mutations in CoM compared with UM - originate.

We propose that the amount and type of melanin present in the melanocytes of the conjunctiva relate to the development and behaviour of CoM. Melanin can be divided into two types: brown/black eumelanin and yellow/red pheomelanin, with different characteristics.[6] Dark-coloured irises have uveal melanocytes that contain more total melanin, and have a higher eumelanin/pheomelanin ratio, compared with melanocytes of light-coloured irises.[5] A similar effect has been found in skin melanocytes, with more total melanin and relatively less pheomelanin in darker skin.[9] Conjunctival melanocytes were similarly found to contain more melanin in eyes with dark irises, although the eumelanin/pheomelanin ratio is unknown.[24]

By the design of the study, lacking a good comparison, we cannot conclude if eye colour or skin colour predisposes to the development of CoM. However, light-coloured eyes could be more prone to development of CoM because of the relatively large amount of pheomelanin in the melanocytes, together with a lack of total pigment to protect against UV damage. Larsen *et al*[20,26] demonstrated recently that UV-induced *BRAF* mutations occurred more frequently in CoM in sun-exposed (epibulbar or caruncular) sites, and in mixed or non-pigmented lesions. Skin colour or iris colour was not investigated in relation to *BRAF* mutations, however. It would be of interest to study the mechanisms in pigmentation and (UV-induced) mutations to investigate a potential causality.

This study does allow to elaborate on the mechanisms of CoM behaviour once it has developed. First, a disbalance of pheomelanin and eumelanin may promote aggressive outgrowth leading to worse clinical behaviour. This is with the assumption that low tumour pigmentation reflects a low eumelanin/pheomelanin ratio, as is suspected by the dark colour of eumelanin compared with the lightly coloured pheomelanin.

A second mechanism to be considered is that changes in melanin relate to other, genetic, aberrations of the tumour. As such, the pigmentation is not causative of behaviour, but indicative of other mechanisms. Following further malignant changes in melanocytes, the ability to produce pigment may be lost, resulting in amelanotic lesions.

A third factor that should be considered, is that external factors are involved. It is harder to determine the tumour margins in lightly pigmented lesions, making it more difficult to identify and treat affected areas of the conjunctiva. As primary tumour treatment is an important prognostic parameter in CoM,[16,18] this could have led to suboptimal treatment of lightly pigmented lesions, and residual melanoma cells might have caused the higher recurrence and metastasis rates.

A clinical implication of our findings is that clinicians must be more aware of the worse prognosis of lightly pigmented CoM. With tumour margins more difficult to assess in the absence of pigment, a wider surgical approach could be justified in removing such lesions, with more extensive (adjuvant) treatment. As lightly pigmented lesions develop more often in patients with a light iris colour, this calls for even more caution in patients with lightly coloured eyes.

A strength of this study is the large sample size, allowing multivariate analysis. Two models could be presented, with adjustment for other parameters. Also, we were able to investigate eye colour, tumour pigmentation and skin colour together, which is interesting as these parameters all depend on similar pathways of melanin production. Recently, a study was published on clinical parameters that were associated with outcome in CoM in the Leiden group, identifying the hospital of initial treatment and the type of treatment as prognostically important for the development of recurrences.[16] Prior to this, an analysis of patients that included the WEH group, identified other parameters such as tumour origin and location as being related to metastasis development.[17] We compared as many of the different parameters as possible with tumour pigmentation, but not all parameters were available. Unfortunately, we were not able to test for genetic aberrations or determine the cellular contents of melanin in our cases; our findings warrant further investigation, however.

In conclusion, we found that low tumour pigmentation is related to light iris colour and a worse clinical outcome in CoM. Iris colour or skin colour was not related to clinical outcome. Our findings suggest a role for the amount and type of melanin present in the melanocytes of the conjunctiva in the behaviour of CoM. Future research should elucidate the exact – and sequential – molecular pathways that relate pigmentation to tumour behaviour.

Contributors: Design of the study: all authors. Data acquisition: NJB, MM, CLS. Data interpretation: all authors. Drafting and critical revision and approval of the manuscript: all authors.
Funding: NJB received an MD/PhD programme grant from the LUMC. The sponsor or funding organization had no role in the design or conduct of this research.
Competing interests: None declared.
Patient consent: Not required.
Ethics approval: The institutional medical ethics committee of the Leiden University Medical Center decided that this retrospective study did not require their approval under Dutch law. The study adhered to the tenets of the Declaration of Helsinki.
Provenance and peer review: Not commissioned; externally peer reviewed.

REFERENCES

1. Missotten GS, Keijser S, De Keizer RJ, De Wolff-Rouendaal D. Conjunctival melanoma in the Netherlands: a nationwide study. *Invest Ophthalmol Vis Sci.* 2005;46(1):75-82.
2. Paridaens AD, Minassian DC, McCartney AC, Hungerford JL. Prognostic factors in primary malignant melanoma of the conjunctiva: a clinicopathological study of 256 cases. *Br J Ophthalmol.* 1994;78(4):252-259.
3. Werschnik C, Lommatzsch PK. Long-term follow-up of patients with conjunctival melanoma. *Am J Clin Oncol.* 2002;25(3):248-255.
4. Slominski RM, Zmijewski MA, Slominski AT. The role of melanin pigment in melanoma. *Exp Dermatol.* 2015;24(4):258-259.
5. Wakamatsu K, Hu DN, McCormick SA, Ito S. Characterization of melanin in human iridal and choroidal melanocytes from eyes with various colored irides. *Pigment Cell Melanoma Res.* 2008;21(1):97-105.
6. Ito S, Wakamatsu K. Quantitative analysis of eumelanin and pheomelanin in humans, mice, and other animals: a comparative review. *Pigment Cell Res.* 2003;16(5):523-531.
7. Mitra D, Luo X, Morgan A, et al. An ultraviolet-radiation-independent pathway to melanoma carcinogenesis in the red hair/fair skin background. *Nature.* 2012;491(7424):449-453.
8. de Lange MJ, Razzaq L, Versluis M, et al. Distribution of GNAQ and GNA11 Mutation Signatures in Uveal Melanoma Points to a Light Dependent Mutation Mechanism. *PLoS One.* 2015;10(9):e0138002.
9. De Leeuw SM, Smit NP, Van Veldhoven M, et al. Melanin content of cultured human melanocytes and UV-induced cytotoxicity. *J Photochem Photobiol B.* 2001;61(3):106-113.
10. Olsen CM, Carroll HJ, Whiteman DC. Estimating the attributable fraction for melanoma: a meta-analysis of pigmentary characteristics and freckling. *Int J Cancer.* 2010;127(10):2430-2445.
11. Weis E, Shah CP, Lajous M, Shields JA, Shields CL. The association between host susceptibility factors and uveal melanoma: a meta-analysis. *Arch Ophthalmol.* 2006;124(1):54-60.
12. Schmidt-Pokrzywniak A, Kalbitz S, Kuss O, et al. Assessment of the effect of iris colour and having children on 5-year risk of death after diagnosis of uveal melanoma: a follow-up study. *BMC Ophthalmol.* 2014;14:42.
13. Moreau JF, Weissfeld JL, Ferris LK. Characteristics and survival of patients with invasive amelanotic melanoma in the USA. *Melanoma Res.* 2013;23(5):408-413.
14. Shields CL, Kaliki S, Cohen MN, et al. Prognosis of uveal melanoma based on race in 8100 patients: The 2015 Doyne Lecture. *Eye (Lond).* 2015;29(8):1027-1035.
15. Anastassiou G, Heiligenhaus A, Bechrakis N, et al. Prognostic value of clinical and histopathological parameters in conjunctival melanomas: a retrospective study. *Br J Ophthalmol.* 2002;86(2):163-167.
16. Brouwer NJ, Marinkovic M, van Duinen SG, et al. Treatment of conjunctival melanoma in a Dutch referral centre. *Br J Ophthalmol.* 2017:Published online first: 9 November 2017. doi:2010.1136/bjophthalmol-2017-311082.
17. Shields CL, Markowitz JS, Belinsky I, et al. Conjunctival melanoma: outcomes based on tumor origin in 382 consecutive cases. *Ophthalmology.* 2011;118(2):389-395 e381-382.
18. Shields CL. Conjunctival melanoma: risk factors for recurrence, exenteration, metastasis, and death in 150 consecutive patients. *Trans Am Ophthalmol Soc.* 2000;98:471-492.
19. Regan S, Judge HE, Gragoudas ES, Egan KM. Iris color as a prognostic factor in ocular melanoma. *Arch Ophthalmol.* 1999;117(6):811-814.
20. Larsen AC, Dahmcke CM, Dahl C, et al. A Retrospective Review of Conjunctival Melanoma Presentation, Treatment, and Outcome and an Investigation of Features Associated With BRAF Mutations. *JAMA Ophthalmol.* 2015;133(11):1295-1303.
21. Shields JA, Shields CL, Gunduz K, Cater J. Clinical features predictive of orbital exenteration for conjunctival melanoma. *Ophthal Plast Reconstr Surg.* 2000;16(3):173-178.

22. Rootman J, Gallagher RP. Color as a risk factor in iris melanoma. *Am J Ophthalmol.* 1984;98(5):558-561.
23. Wierenga APA, Dogrusöz M, Kroes W, et al. Tumor pigmentation in Uveal melanoma is related to eye color [abstract]. *Investigative Ophthalmology & Visual Science.* 2017;58(8):4417-4417.
24. Hu DN, McCormick SA, Seedor JA, Ritterband DC, Shah MK. Isolation, purification and cultivation of conjunctival melanocytes. *Exp Eye Res.* 2007;84(4):655-662.
25. Iwamoto S, Burrows RC, Grossniklaus HE, et al. Immunophenotype of conjunctival melanomas: comparisons with uveal and cutaneous melanomas. *Arch Ophthalmol.* 2002;120(12):1625-1629.
26. Larsen AC, Dahl C, Dahmcke CM, et al. BRAF mutations in conjunctival melanoma: investigation of incidence, clinicopathological features, prognosis and paired premalignant lesions. *Acta Ophthalmol.* 2016;94(5):463-470.

SUPPLEMENTARY MATERIAL

Supplementary table 1. Patient and tumour characteristics of the two analysed groups of patients with histologically-proved conjunctival melanoma.

	Total	Leiden	Philadelphia	
Parameter	**Cases (%)**	**Cases (%)**	**Cases (%)**	**P-value**
Total	**444 (100)**	**70 (16)**	**374 (84)**	
Sex				
male	217 (49)	35 (50)	182 (49)	0.84
female	227 (51)	35 (50)	192 (51)	
Age at diagnosis (year)				
<60	202 (45)	35 (50)	167 (45)	0.41
≥60	242 (55)	35 (50)	207 (55)	
Age at diagnosis (year)				
mean (SD)	59.5 (17.5)	60.3 (18.3)	59.3 (17.3)	0.71
Side				
right (OD)	239 (54)	37 (53)	202 (54)	0.86
left (OS)	205 (46)	33 (47)	172 (46)	
Location				
epibulbar	215 (63)	54 (77)	161 (59)	0.005
non-epibulbar	128 (37)	16 (23)	112 (41)	
Thickness (mm)	(n=130)	(n=54)	(n=76)	
mean (SD)	1.77 (2.1)	2.25 (2.8)	1.43 (1.3)	0.14
Tumour LBD (mm)	(n=320)	(n=50)	(n=270)	
mean (SD)	10.63 (8.1)	8.97 (6.1)	10.94 (8.4)	0.30
Pigmentation				
non/mixed pigmented	130 (40)	17 (33)	113 (41)	0.31
pigmented	197 (60)	34 (67)	163 (59)	
Iris colour				
blue/green/grey	261 (59)	59 (84)	202 (54)	<0.001
hazel/brown	183 (41)	11 (16)	172 (46)	
Skin colour				
fair	392 (88)	67 (96)	325 (87)	0.035
non-fair	52 (12)	3 (4)	49 (13)	
Recurrence				
yes	177 (40)	20 (29)	157 (42)	0.035
Metastasis				
yes	62 (14)	9 (13)	53 (14)	0.77
Melanoma-related death				
yes	36 (8)	9 (13)	27 (7)	0.11
Exenteration				
yes	50 (11)	11 (16)	39 (10)	0.20

LBD, largest basal diameter; SD, Standard Deviation.

2.3

Pigmentation of Conjunctival Melanoma Recurrences and Outcome

Niels J. Brouwer[1], Marina Marinkovic[1], Gregorius P.M. Luyten[1], Carol L. Shields[2], Martine J. Jager[1]

Graefes Arch Clin Exp Ophthalmol 2019; 257(8):1783-1788.

1. Department of Ophthalmology, Leiden University Medical Center, Leiden, The Netherlands
2. Ocular Oncology Service, Wills Eye Hospital, Thomas Jefferson University, Philadelphia, Pennsylvania, U.S.A.

ABSTRACT

Purpose: In primary conjunctival melanoma (CoM), one of the characteristics that is associated with an increased risk of metastases and death is a lack of tumour pigmentation. The aim of this study was to investigate whether the degree of pigmentation of CoM recurrences relates similarly to clinical outcome.

Methods: A data set of 177 patients with a CoM recurrence from the Wills Eye Hospital (USA) and the Leiden University Medical Center (The Netherlands) was analysed. The relation between clinical tumour pigmentation of the recurrences, the characteristics of the primary lesions and clinical outcome was investigated.

Results: In 117 (66%) of 177 patients with a CoM recurrence, tumour pigmentation was known: 71 patients (61%) had recurrences with low pigmentation. Primary lesions had low pigmentation in 39% of cases, which is significantly different ($p=0.001$). However, low tumour pigmentation of recurrences correlated with low tumour pigmentation of the primary lesion ($p<0.001$). No association was observed between pigmentation of the recurrences and iris colour ($p=0.66$). Low pigmentation of the recurrences was not significantly associated with an increased risk for metastases (HR 1.96, $p=0.12$) or death (HR 1.79, $p=0.27$), whereas primary tumours with low pigmentation did show a greater risk for metastases (HR 2.82, $p=0.016$) and death (HR 2.90, $p=0.037$).

Conclusions: CoM recurrences are more often lightly pigmented compared to primary lesions. A correlation exists between the degree of pigmentation of primary and recurrent lesions, but recurrences can appear with any degree of pigmentation. Unlike primary CoM, the level of pigmentation of CoM recurrences is not related to metastasis or death.

INTRODUCTION

Conjunctival melanoma (CoM) is a rare ocular malignancy that arises from melanocytes in the basal layer of the conjunctiva. It comprises about 5% of all ocular melanoma[1] and has an incidence of 0.6 to 0.8 per million in Caucasians.[2,3] CoM has a high recurrence rate, at 26-61% in 5 years.[3-7] Treatment for smaller CoM consists of local excision with adjuvant therapy (e.g. cryotherapy, topical chemotherapy and/or radiotherapy), while more extensive procedures such as orbital exenteration are required for larger or advanced CoM.[8] Despite treatment of the primary lesion, metastatic disease can develop and can be fatal with a 10-year melanoma-related mortality of up to 29%.[7,9]

To identify which mechanisms play a role in melanoma development and the formation of metastases, we recently studied tumour pigmentation in primary CoM.[10] A light tumour pigmentation was associated with a higher frequency of recurrences (HR 1.63, p=0.043), metastases (HR 2.48, p=0.004) and melanoma-related deaths (HR 2.60, p=0.014). It was furthermore noticed that iris colour and pigmentation of the primary tumour were associated (p=0.021), as light tumour pigmentation was found more frequently in eyes with a light-coloured iris. Based on these findings, we hypothesised that the amount and type of melanin present in conjunctival melanocytes may play a role in the development and behaviour of CoM. Further, it may be that lightly coloured tumours are sometimes missed or misdiagnosed.

In clinical practice, it has been observed that CoM recurrences are frequently amelanotic, even though the original lesions can be pigmented (Figure 1).[5] This is clinically important as the recurrences may simulate other conjunctival disease, delaying proper diagnosis and treatment. Exemplary lesions that can appear as an amelanotic conjunctival mass are pyogenic granuloma, pinguecula or pterygium, or malignancies such as ocular surface squamous neoplasia or lymphoma.[5,11] It remains unclear how often CoM recurrences are amelanotic and how this relates to clinical outcome. As we demonstrated a relation between pigmentation of primary CoM and clinical behaviour, we wondered if pigmentation of recurrent CoM could also relate to outcome.

The aim of this study was to determine whether pigmentation of CoM recurrences resembles the corresponding primary lesion, and whether pigmentation of CoM recurrences is related to clinical outcome.

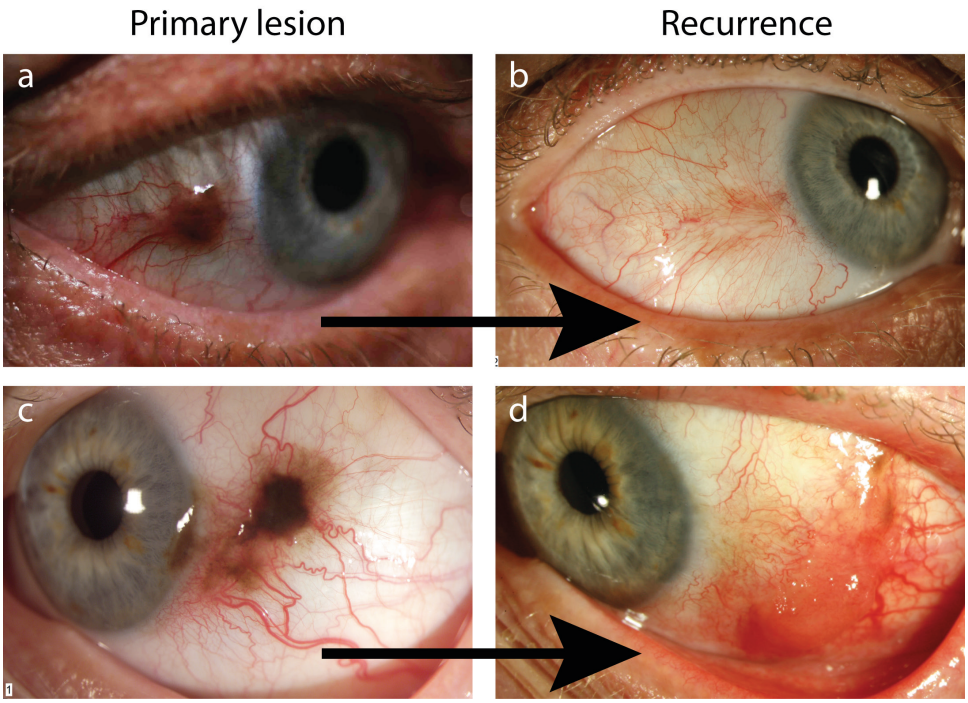

Figure 1. Corresponding primary and recurrent lesions of conjunctival melanoma with different pigmentation. Both patient 1 (**a, b**) and patient 2 (**c, d**) presented with a primary lesion with high pigmentation and developed a recurrence with low pigmentation. Lightly pigmented recurrences may be difficult to detect or can be confused with other ocular diseases.

Patient 1 was treated for the primary CoM with local excision only. The recurrence developed after 9 months. Patient 2 was treated for the primary CoM with local excision and adjuvant brachytherapy. The recurrence developed after 6 years

METHODS

A data set of 444 patients diagnosed with primary CoM from the Wills Eye Hospital (Philadelphia, USA) and the Leiden University Medical Center (Leiden, The Netherlands) was analysed. Patient and tumour characteristics of this combined set have been previously published.[10] In short, all patients had histopathologically-confirmed CoM, the mean age of these patients was 59.5 years (SD 17.5), 51% was female, the mean tumour thickness was 1.77 mm (SD 2.1) and 63% of lesions were epibulbar. We identified 177 patients (40%) who developed a local recurrence of CoM and reviewed the data of these patients, with an emphasis on tumour pigmentation. Tumour pigmentation of the primary lesions was classified clinically as 'high pigmentation' (i.e. 'pigmented') or 'low pigmentation' (i.e. 'non-pigmented/mixed'), based on the patient medical file and available

clinical photographs.[10] Mixed lesions were categorised together with non-pigmented lesions as apparently parts of the lesion lost the ability to produce pigment. Tumour pigmentation of all known recurrences per patient (also determined clinically) was combined to one value of 'always high pigmentation' (i.e. if all recurrences were pigmented), 'always low pigmentation' (i.e. if all recurrences were non-pigmented/mixed), or 'variable' (i.e. if a combination of pigmented and non-pigmented recurrences occurred within the same patient). Iris colour was classified as 'light' (i.e. blue, green or grey) or 'dark' (i.e. hazel or brown), which reflects a division between low or high melanin content of iridal melanocytes.[12] Statistical analyses were performed using SPSS software (v.23). Categorical data was analysed with the chi-square test or Fisher exact test. Numerical data was analysed with the Kruskal-Wallis test. Analyses of the development of metastasis or survival were performed with logistic regression and log rank (Kaplan-Meier) tests. P-values < 0.05 were considered statistically significant.

RESULTS

Of the 177 patients with a CoM recurrence, the pigmentation of the recurrent tumours was known in 117 (66%) cases: 46 patients (39%) had lesions in which the pigmentation was always high during follow-up, and 71 patients (61%) had recurrences in which the pigmentation was always low (or variable) during follow-up. Of these 117 patients, mean age at diagnosis of the primary CoM was 64.5 years (SD 14.0). Mean age at the moment of the first recurrence was 67.9 years (SD 14.5). Between the patients with recurrences with consistently high, consistently low, or variable pigmentation, no statistically significant differences existed in age at diagnosis (p=0.70) or age at first recurrence (p=0.80) (Table 1). There was no significant correlation between iris colour and tumour pigmentation of the recurrences (p=0.66) (Table 1).

In 105 of the 117 patients with data on recurrent tumour pigmentation, pigmentation of the primary lesion was known: there were 64 cases (61%) with high pigmentation and 41 cases (39%) with low pigmentation. Compared to this percentage of primary lesions, recurrences were significantly more often lightly pigmented (61% vs 39%, p=0.001). Low tumour pigmentation of the primary lesion was significantly related to low tumour pigmentation of the recurrences (p<0.001).

Table 1. Tumour pigmentation of conjunctival melanoma recurrences in 117 cases, relationship to clinical factors and outcomes

	Pigmentation of CoM recurrences			
	Always High Cases (%)	**Always Low Cases (%)**	**Variable Cases (%)**	
Total	**46 (39)**	**51 (44)**	**20 (17)**	**p value**
Pigmentation of the primary CoM*				
Low pigmentation	7 (17)	25 (61)	9 (22)	<0.001
High pigmentation	37 (58)	17 (27)	10 (16)	
Iris colour				
Light	28 (41)	31 (45)	10 (15)	0.66
Dark	18 (38)	20 (42)	10 (21)	
Age at primary CoM (mean, SD)	64.4 (15.5)	63.8 (13.6)	66.6 (11.9)	0.70
Age at first recurrence (mean, SD)	68.1 (15.9)	67.5 (14.7)	68.5 (10.7)	0.80
Number of recurrences per patient (mean, SD)	2.2 (2.8)	1.9 (1.0)	5.4 (5.5)	<0.001
Metastasis				
Yes	10 (22)	18 (35)	7 (35)	0.31
No	36 (78)	33 (65)	13 (65)	
Melanoma-related death				
Yes	6 (13)	10 (20)	5 (25)	0.45
No	40 (87)	41 (80)	15 (75)	

**Of the 117 recurrences included in this study, in 12 cases the pigmentation of the primary lesion was not known.*

Primary CoM with low pigmentation was related to a greater risk for metastasis (HR 2.82; 95%CI 1.21-6.56, p=0.016), and melanoma-related death (HR 2.90; 95%CI 1.07-7.88, p=0.037). There was no statistically significant relation between recurrences with low pigmentation and an increased risk for metastasis (HR 1.96; 95%CI 0.83-4.59, p=0.12) and melanoma-related death (HR 1.79; 95%CI 0.64-5.00, p=0.27).

Using Kaplan-Meier analysis, patients with primary lesions with low pigmentation had a worse metastasis-free survival compared to patients with lesions with high pigmentation (p=0.028). However, patients with recurrences with low or variable pigmentation had no different metastasis-free survival compared to those with recurrences with consistently high pigmentation (p=0.151) (Figure 2).

In addition, we controlled for the pigmentation of the primary lesion by analysing the data separately for patients with either high or low pigmented primary CoM. This demonstrated that, also within sub groups, pigmentation of recurrences was not associated with metastasis or death (Figure 3).

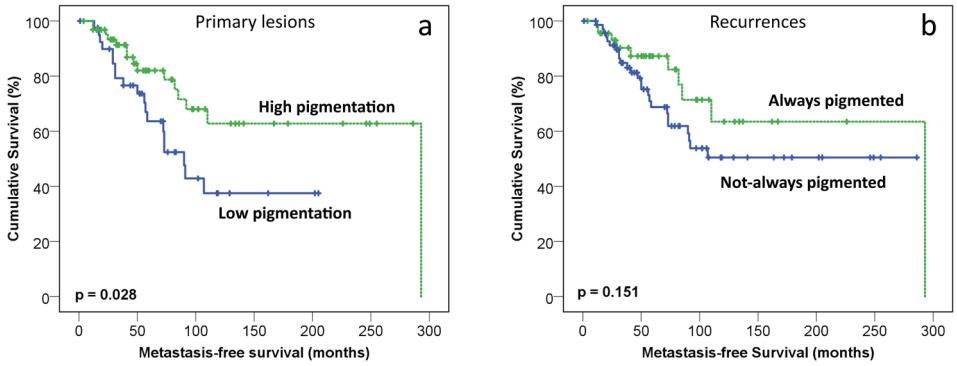

Figure 2. Kaplan-Meier analysis of metastasis-free survival. **a** Patients are categorised by pigmentation of the primary lesion. A significant worse outcome is shown for patients with low tumour pigmentation (n=41) compared to high pigmentation (n=64, p=0.028). **b** The same group of patients is depicted, but is now categorized by the pigmentation of their recurrences. Outcome is not significantly different for those with recurrences with always high pigmentation (n=46) compared to those with always low (or variable) pigmentation (n=71, p=0.151)

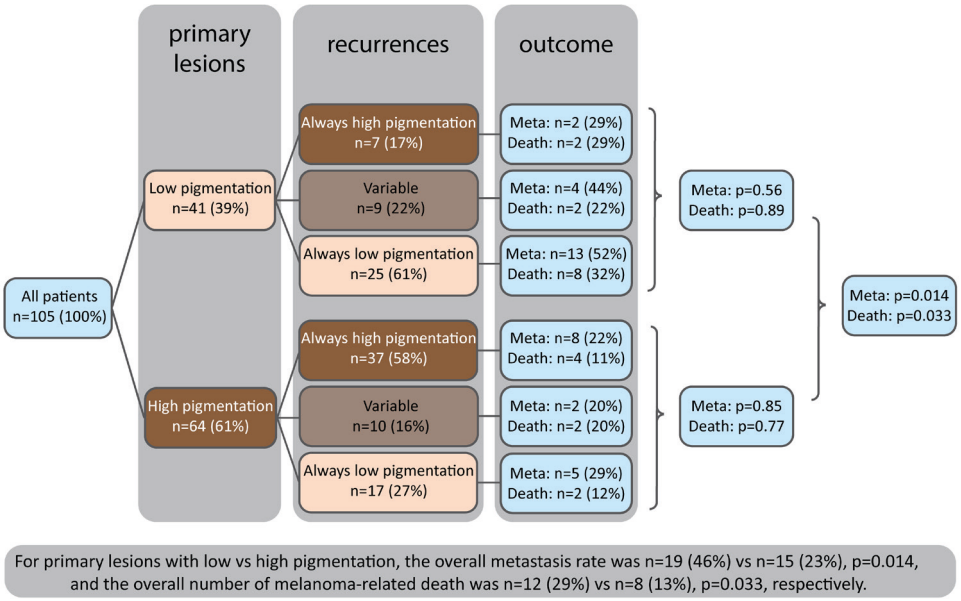

Figure 3. Flow chart of patients with a CoM recurrence and known pigmentation of both the primary and recurring lesions. Patients are first divided by the pigmentation of the primary lesion and second by the pigmentation of the recurrences. Outcome is reported for each subgroup. While metastasis and death are significantly associated with pigmentation of the primary lesion (worse for lesions with low pigmentation), pigmentation of recurrences is not further associated with outcome

DISCUSSION

In this study, we investigated the relationship between tumour pigmentation of CoM recurrences, tumour pigmentation of the corresponding primary lesions, and clinical outcome. We found that the pigmentation of recurrent tumours was correlated with pigmentation of the primary lesion, and overall, recurrences were more frequently lightly-pigmented. We found that pigmentation of recurrences did not relate to metastasis or death, while pigmentation of primary lesions did.

Clinical pigmentation depends on the amount and ratio of (dark-coloured) eumelanin and (lightly coloured) pheomelanin. These are two products of melanocytes with different biochemical characteristics: e.g. while eumelanin is protective against UV-radiation damage, pheomelanin is associated with the induction of genotoxic stress.[13,14] Cutaneous melanocytes of dark-coloured skin contain more total melanin and relatively less pheomelanin compared to melanocytes of light-coloured skin,[15] as do uveal melanocytes in dark versus light-coloured irises.[12] It is not known how the ratio of eumelanin and pheomelanin relates to tumour pigmentation in CoM, but it can be similarly expected that lesions with low pigmentation contain fewer total melanin and relatively more pheomelanin compared to lesions with high pigmentation.

As reported in our earlier study of a predominantly Caucasian population with CoM, 60% of all primary lesions were of high pigmentation and 40% were of low pigmentation.[10] This is significantly different from the percentages found in recurrent lesions of the same study population: 46 patients (39%) had exclusively pigmented lesions during follow-up, and 71 patients (61%) had non-pigmented or mixed lesions at some moment during follow-up. Therefore, as recurrences are more often lightly pigmented compared to primary lesions, the clinical observation that recurrences are frequently amelanotic is confirmed. This finding can be postulated through two different mechanisms: first, and most importantly, melanocytes of recurrent lesions may more often have lost the ability to produce pigment compared to primary lesions. One could hypothesise that this relates to an unfavourable melanocyte differentiation or unfavourable genetic status, which can be expected with melanoma that recurs. Second, and to a much lesser extent, the higher percentage of amelanotic recurrences compared to primary lesions may imply that amelanotic primary lesions are overlooked. Once a melanoma is demonstrated, clinicians will be more cautious in the follow-up of that patient, detecting possible amelanotic recurrences.

We hypothesised that tumour pigmentation in primary CoM may relate to genetic aberrations, and this could similarly determine pigmentation of recurrences.[10] Our clinical results show that recurrences often resemble their original lesion, not surprisingly as they share a genetic background and similar micro-environment, but they can also look different. In the 41 patients with a primary lesion with low pigmentation, 16 (39%) developed recurrences with variable or high pigmentation. In the 64 patients with a primary lesion with high pigmentation, 27 (42%) developed recurrences

with variable or low pigmentation. It would be interesting to see how this relates to the genetic profile. It was demonstrated by Larsen et al. that *BRAF* mutations are found more frequently in non-pigmented compared to pigmented tumours.[16] Also, it was demonstrated by Larsen et al. that *BRAF* mutations can differ between precursor lesions and outgrowth of CoM;[16] this may be similar for the situation between primary CoM and recurrences. The *BRAF* mutation status could be relevant for adjuvant treatment, as certain therapies target this specific mutation. Other mutations that have been reported in CoM - besides *BRAF* - include mutations in *NRAS*, *KIT*, *TERT* and *NF-1*.[17-19] The relationship between these mutations and clinical tumour pigmentation has not been described. Griewank et al. reported an absent relation between histologically determined tumour pigmentation and the occurrence of *TERT* mutations in 38 cases of CoM,[19] but this number may be too small for a final conclusion. Unfortunately, we could not determine the *BRAF* or other mutation status in our data set.

While the amount of pigmentation of primary CoM is related to metastasis and survival, this was not the case for pigmentation of recurrences. We hypothesise that metastases often have an early origin in patients with CoM, being more related to the primary lesion than to subsequent local recurrences. This would be in line with tumour dormancy as thought to exist in metastases of uveal and cutaneous melanoma[20] and is in line with some observations of CoM recurrence or metastasis years after margin-free excision, implying that cells have spread already prior to primary treatment.[21,22] In addition, the finding that pigmentation of recurrences is not related to clinical outcome may indicate that while primary amelanotic tumours may occasionally be excised with too small margins, recurrences are treated more heavily and adequately as clinicians will be more aware. Based on our results, we do not advise to treat CoM recurrences differently based on their pigmentation. It is emphasised to look for any aberrant lesion in an eye with previous CoM, and to inform patients that recurrences may appear differently.

A strength of this study is the large number of CoM recurrences that were included. While primary CoM has been described to a larger extent, data on recurrences is much more uncommon. As our analysis was performed on a data set with previously recorded clinical parameters, some limitations apply due to the availability of data. Unfortunately, data on tumour pigmentation was not available for all patients. We do not believe that this has biased the results, as the recording seems to be an administrative matter, with gaps in data being random, and is not related to the pigmentation status. Apart from this, it may be that amelanotic recurrences were overlooked in patients, and that the actual percentage of low pigmentation recurrences is even higher than currently reported.

A potential bias was introduced by categorising the pigmentation of all known recurrences per patient into one value. By definition, the group of patients with 'variable' pigmentation has multiple recurrences, in contrast to the groups of 'always high pigmentation' or 'always low pigmentation'

that also include patients with only one recurrence. We do not believe that this has influenced our conclusion, as the expected bias would overestimate an effect for low pigmentation / variable lesions on metastasis and death – and we detected no significant effect at all.

One might wonder whether the initial treatment of CoM relates to the pigmentation of recurrences. The majority of patients who were included in this study received excision with cryotherapy as initial treatment for the primary CoM. Other treatments included excision alone, topical chemotherapy, brachytherapy (using various devices) and external radiation. We do not feel that our data allows for a thorough analysis of all the various treatment combinations to adequately answer this question.

CONCLUSION

In short, we demonstrated that CoM recurrences are more frequently lightly pigmented compared to primary lesions. Pigmentation of the original lesion corresponds to the pigmentation of a recurrence, but deviations occur, and clinicians should be wary of any aberrant lesion in an eye with previously diagnosed CoM. In contrast to primary CoM, no association was observed between tumour pigmentation of recurrences and clinical outcome. Future research should explore the genetic profile of primary lesions versus recurrences, as they may differ and this may be relevant for treatment.

Compliance with ethical standards

Funding: NJB received an MD/PhD programme grant from the LUMC. The sponsor or funding organisation had no role in the design or conduct of this research.
Conflict of interest: The authors declare that they have no conflict of interest.
Ethical approval: All procedures performed were in accordance with the ethical standards of the institutional and/or national research committee and with the 1964 Helsinki declaration and its later amendments or comparable ethical standards.
Informed consent: For this type of study, formal consent is not required.
Open Access: This article is distributed under the terms of the Creative Commons At tribution 4.0 International License (http:/ / creativecommons.org/licenses/by/4.0/), which permits unrestricted use, distribution, and reproduction in any medium, provided you give appropriate credit to the original author(s) and the source, provide a link to the Creative Commons license, and indicate if changes were made.

REFERENCES

1. Isager P, Engholm G, Overgaard J, Storm H. Uveal and conjunctival malignant melanoma in denmark 1943-97: observed and relative survival of patients followed through 2002. *Ophthalmic Epidemiol.* 2006;13(2):85-96.
2. Triay E, Bergman L, Nilsson B, All-Ericsson C, Seregard S. Time trends in the incidence of conjunctival melanoma in Sweden. *Br J Ophthalmol.* 2009;93(11):1524-1528.
3. Tuomaala S, Eskelin S, Tarkkanen A, Kivela T. Population-based assessment of clinical characteristics predicting outcome of conjunctival melanoma in whites. *Invest Ophthalmol Vis Sci.* 2002;43(11):3399-3408.
4. Brouwer NJ, Marinkovic M, van Duinen SG, et al. Treatment of conjunctival melanoma in a Dutch referral centre. *Br J Ophthalmol.* 2018;102(9):1277-1282.
5. Shields CL. Conjunctival melanoma: risk factors for recurrence, exenteration, metastasis, and death in 150 consecutive patients. *Trans Am Ophthalmol Soc.* 2000;98:471-492.
6. Shields CL, Markowitz JS, Belinsky I, et al. Conjunctival melanoma: outcomes based on tumor origin in 382 consecutive cases. *Ophthalmology.* 2011;118(2):389-395 e381-382.
7. Missotten GS, Keijser S, De Keizer RJ, De Wolff-Rouendaal D. Conjunctival melanoma in the Netherlands: a nationwide study. *Invest Ophthalmol Vis Sci.* 2005;46(1):75-82.
8. Wong JR, Nanji AA, Galor A, Karp CL. Management of conjunctival malignant melanoma: a review and update. *Expert Rev Ophthalmol.* 2014;9(3):185-204.
9. Werschnik C, Lommatzsch PK. Long-term follow-up of patients with conjunctival melanoma. *Am J Clin Oncol.* 2002;25(3):248-255.
10. Brouwer NJ, Marinkovic M, Luyten GPM, Shields CL, Jager MJ. Lack of tumour pigmentation in conjunctival melanoma is associated with light iris colour and worse prognosis. *Br J Ophthalmol.* 2019;103(3):332-337.
11. Shields CL, Chien JL, Surakiatchanukul T, et al. Conjunctival Tumors: Review of Clinical Features, Risks, Biomarkers, and Outcomes--The 2017 J. Donald M. Gass Lecture. *Asia Pac J Ophthalmol (Phila).* 2017;6(2):109-120.
12. Wakamatsu K, Hu DN, McCormick SA, Ito S. Characterization of melanin in human iridal and choroidal melanocytes from eyes with various colored irides. *Pigment Cell Melanoma Res.* 2008;21(1):97-105.
13. Ito S, Wakamatsu K. Quantitative analysis of eumelanin and pheomelanin in humans, mice, and other animals: a comparative review. *Pigment Cell Res.* 2003;16(5):523-531.
14. Mitra D, Luo X, Morgan A, et al. An ultraviolet-radiation-independent pathway to melanoma carcinogenesis in the red hair/fair skin background. *Nature.* 2012;491(7424):449-453.
15. De Leeuw SM, Smit NP, Van Veldhoven M, et al. Melanin content of cultured human melanocytes and UV-induced cytotoxicity. *J Photochem Photobiol B.* 2001;61(3):106-113.
16. Larsen AC, Dahl C, Dahmcke CM, et al. BRAF mutations in conjunctival melanoma: investigation of incidence, clinicopathological features, prognosis and paired premalignant lesions. *Acta Ophthalmol.* 2016;94(5):463-470.
17. Scholz SL, Cosgarea I, Susskind D, et al. NF1 mutations in conjunctival melanoma. *Br J Cancer.* 2018;118(9):1243-1247.
18. Beadling C, Jacobson-Dunlop E, Hodi FS, et al. KIT gene mutations and copy number in melanoma subtypes. *Clin Cancer Res.* 2008;14(21):6821-6828.
19. Griewank KG, Murali R, Schilling B, et al. TERT promoter mutations in ocular melanoma distinguish between conjunctival and uveal tumours. *Br J Cancer.* 2013;109(2):497-501.
20. Ossowski L, Aguirre-Ghiso JA. Dormancy of metastatic melanoma. *Pigment Cell Melanoma Res.* 2010;23(1):41-56.
21. Paridaens AD, McCartney AC, Lavelle RJ, Hungerford JL. Nasal and orbital recurrence of conjunctival melanoma 21 years after exenteration. *Br J Ophthalmol.* 1992;76(6):369-371.

22. Brouwer NJ, Genders SW, Marinkovic M, et al. Two late recurrences of conjunctival melanoma. *Ocular Oncology and Pathology.* 2018:[epub ahead of print].

3.1

Conjunctival Melanoma: New Insights in Tumour Genetics and Immunology, Leading to New Therapeutic Options

Niels J. Brouwer[1], Robert M. Verdijk[1,2 3], Steffen Heegaard[4 5], Marina Marinkovic[1], Bita Esmaeli[6], Martine J. Jager[1*]

Progress in Ret Eye Res 2022; 86:100971

1 Department of Ophthalmology, Leiden University Medical Center, Leiden, The Netherlands
2 Department of Pathology, Leiden University Medica Center, Leiden, The Netherlands
3 Department of Pathology, Erasmus University Medical Center, Rotterdam, The Netherlands
4 Department of Ophthalmology, Rigshospitalet, University of Copenhagen, Copenhagen, Denmark
5 Department of Pathology, Eye pathology section, Rigshospitalet, University of Copenhagen, Copenhagen, Denmark
6 Department of Plastic Surgery, Orbital Oncology and Ophthalmic Plastic Surgery, M.D. Anderson Cancer Center, Houston, Texas, USA

ABSTRACT

Recent developments in oncology have led to a better molecular and cellular understanding of cancer, and the introduction of novel therapies. Conjunctival melanoma (CoM) is a rare but potentially devastating disease. A better understanding of CoM, leading to the development of novel therapies, is urgently needed.

CoM is characterized by mutations that have also been identified in cutaneous melanoma, e.g. in *BRAF*, *NRAS* and *TERT*. These mutations are distinct from the mutations found in uveal melanoma (UM), affecting genes such as *GNAQ, GNA11,* and *BAP1*. Targeted therapies that are successful in cutaneous melanoma may therefore be useful in CoM.

A recent breakthrough in the treatment of patients with metastatic cutaneous melanoma was the development of immunotherapy. While immunotherapy is currently sparsely effective in intraocular tumours such as UM, the similarities between CoM and cutaneous melanoma (including in their immunological tumour micro environment) provide hope for the application of immunotherapy in CoM, and preliminary clinical data are indeed emerging to support this use.

This review aims to provide a comprehensive overview of the current knowledge regarding CoM, with a focus on the genetic and immunologic understanding. We elaborate on the distinct position of CoM in contrast to other types of melanoma, and explain how new insights in the pathophysiology of this disease guide the development of new, personalized, treatments.

Article Highlights

- CoM is a rare but potentially deadly extraocular tumour, with a rising incidence.
- Genetic mutations in CoM resemble those in cutaneous melanoma, but not UM.
- The presence of immune cells is important for the development and control of CoM.
- Targeted therapy and checkpoint inhibitors can be applied to treat CoM patients.

1. INTRODUCTION

Conjunctival melanoma (CoM) is a rare but potentially devastating disease. With an incidence of 0.3 – 0.8/million in Caucasian adults,[1-4] it accounts for about 5% of ocular melanoma cases.[4,5] The estimated number of new cases per year is 130 in the USA, and 320 in Europe. CoM originates from melanocytes in the basal layers of the conjunctiva, and can develop in an area of primary acquired melanosis (PAM), in a nevus, or de novo.[6] The role of ultraviolet (UV) radiation in CoM development is under discussion, following long-standing epidemiological and more recent genetic work.

Originating from the conjunctiva, CoM is a mucosal melanoma with much resemblance to melanoma of the skin.[7,8] This may be no surprise when looking at the histological and functional similarities of these epithelial tissues. CoM is a very different entity compared to uveal melanoma (UM), which affects the choroid, ciliary body or iris,[9] and CoM and UM have distinct aetiologies and genetic backgrounds.[10]

In clinical practice, CoM most typically presents as a pigmented lesion near the limbus of the eye. Any part of the conjunctiva can be affected, however, and lesions may range from amelanotic to deeply pigmented or even black (Figure 1). Localised disease is commonly treated by surgical excision and adjuvant therapy (such as cryotherapy, radiotherapy or topical chemotherapy), while widespread disease on the ocular surface or palpebral conjunctiva may need more extensive therapy such as orbital exenteration.[11] Despite treatment, up to 66% of CoM patients may develop local recurrences,[12] and up to 38% will die due to the disease within 10 years of primary treatment (Figure 2).[1,13] Risk factors for metastases formation include a greater tumour thickness, non-bulbar location, low tumour pigmentation, histologic ulceration, and local invasion.[6,14-16] A better understanding of CoM, leading to novel therapies, is therefore urgently needed.

Recent developments in the field of oncology have led to a better understanding of cancer and the introduction of novel therapies. These therapies include 'targeted therapy', aiming at specific cellular pathways and genetic mutations of cancer cells, and 'immunotherapy', that activates the patient's own immune system to block tumour growth. Knowledge of the genetic and immunologic environment of CoM may expedite the introduction of these therapies in CoM.

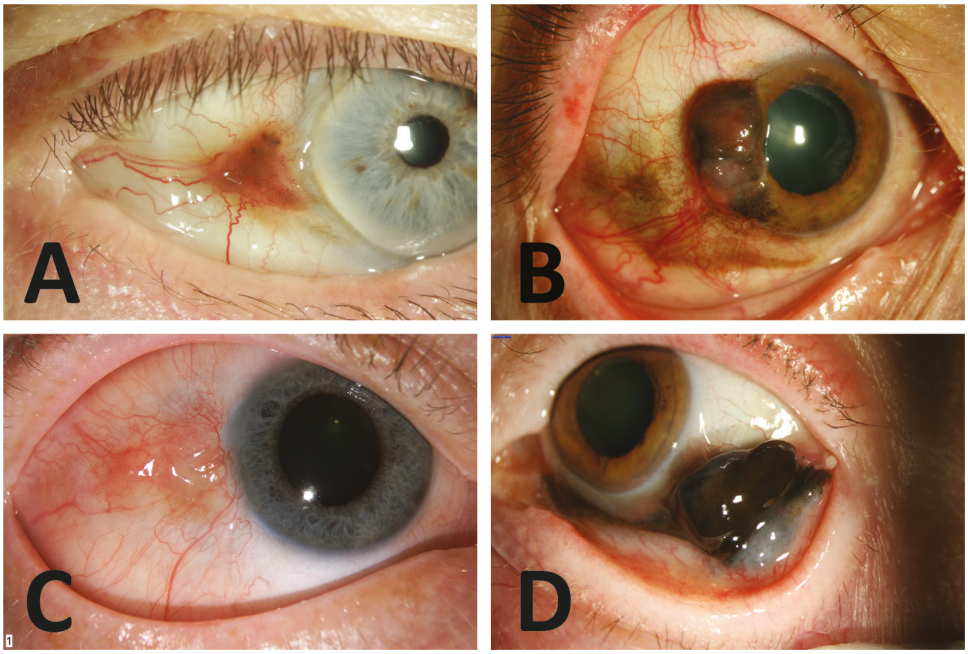

Figure 1. Conjunctival melanoma (CoM). The clinical presentation of CoM varies, as the disease can present at any part of the conjunctiva, and the colour can range from amelanotic to deeply pigmented. Treatment options are largely based on tumour size and location. (A) Localized lesion of the bulbar and limbal conjunctiva, with light-to-medium pigmentation. (B) Large pigmented lesion of the limbal conjunctiva, with an extensive area of primary acquired melanosis (PAM) on the inferior bulbar and forniceal conjunctiva. Note the marked conjunctival vessels approaching the nodular lesion. (C) Amelanotic bulbar lesion, three years after excision of an earlier CoM. (D) Large pigmented lesion, hidden in the inferior fornix of the eye. The obscured location of this lesion caused delayed presentation, which limited therapeutic options.

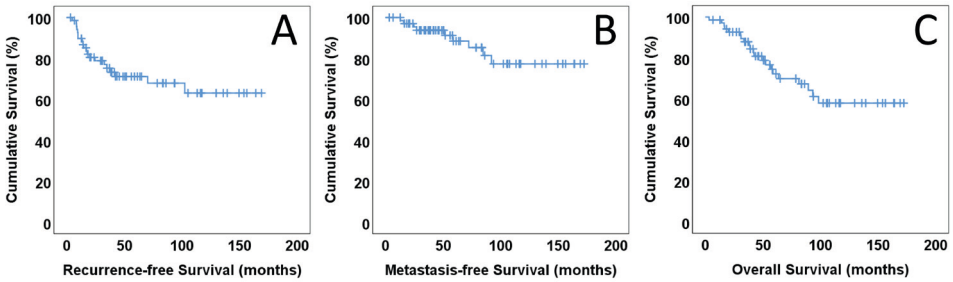

Figure 2. Clinical outcome of CoM patients. Kaplan-Meier analysis of 70 CoM patients, treated between 2001 and 2014 in The Netherlands. Included were 54 (77%) T1 tumours and 16 (23%) T2 tumours, mean tumour thickness was 2.3mm. Mean follow-up time was 70.2 months. (A) recurrence-free survival, (B) metastasis-free survival, (C) overall survival. [The cohort was reported earlier by Brouwer et al, 2018.[13]]

The genetic background of CoM is characterized by mutations in genes such as *BRAF, NRAS,* and *TERT*.[17,18] These mutations are common in cutaneous melanoma as well, and distinct from the mutations that occur in UM, affecting e.g. *GNAQ, GNA11*, and *BAP1*. Targeted therapies have recently been introduced successfully in the treatment of cutaneous melanoma: the use of vemurafenib (targeting the *BRAF* mutation) resulted in a better overall survival of cutaneous melanoma patients.[19] New insights regarding the development of treatment resistance led to the combined therapy of *BRAF* and MEK (i.e. *Mitogen-activated ERK kinase*) inhibitors, with even better results.[20] Because of the molecular resemblance of CoM and cutaneous melanoma, these drug developments may be introduced to treat CoM. Some promising case studies of targeted therapy in CoM have been published recently,[21] and further (pre-clinical) studies are being performed.

The tumour micro-environment of different types of melanoma has been studied for many decades, but is under increasing interest following the discovery of immunotherapy that enhances the body's own immune system to attack tumour cells. Examples of this breakthrough in the treatment of metastatic melanoma are checkpoint-inhibitor therapies with ipilimumab (targeting CTLA-4) and nivolumab (targeting PD-1), which via different routes activate a CD8+ T cell response. Early studies showed improved survival in patients with unresectable metastatic cutaneous melanoma who were treated with ipilimumab, compared to gp100 vaccination.[22] Later studies found improved survival for nivolumab treatment compared to dacarbazine chemotherapy.[23] While the success of immunotherapy is as yet limited in intraocular UM[24] (possibly because of the immune privilege of the eye where tumour escape mechanisms hamper immune surveillance),[25] the similarities in tumour micro environment between extra-ocular CoM and cutaneous melanoma led to the belief that immunotherapy should also be applied to CoM. Promising data on small scale use of immunotherapy in CoM have been reported,[26,27] and the evaluation of the newest therapies is awaited.

This review aims to provide an overview of the current knowledge regarding the genetic and immunologic understanding of CoM, and the implications for treatment. We touch upon similarities and differences between CoM and other types of melanoma, and explain how new insights in the pathophysiology of this disease guide the development of new therapies.

2. EPIDEMIOLOGY AND ETIOLOGY

General incidence

The incidence of CoM ranges between 0.3 and 0.8/million in Caucasian adults.[1,3,5,12,28] It is the second most prevalent malignancy of the conjunctiva, after squamous cell carcinoma (also known as '*ocular surface squamous neoplasia*, OSSN').[29] CoM accounts for approximately 5% of all primary ocular melanoma, being overshadowed by the far more prevalent UM.[4,5] The incidence of CoM

increases with age: CoM mainly affects patients from the fifth/sixth decade of life onwards,[1-4,30] and is rare in children and adolescents.[31] The incidence can be considered equal between men and women, although some studies report a slightly higher incidence amongst males (with a male-to-female ratio of 1.26:1 and 1.29:1).[5,32] For the USA and Europe, with a current population of 335 million and 740 million,[33,34] the overall incidence results into an estimated 130 and 320 new cases of CoM per year, respectively.[5,28]

The number of reports on the incidence of CoM is limited. In national registries, CoM is often classified together with other types of ocular melanoma, limiting the ability to obtain tumour-specific data.[2,28] Current data mainly originate from North America or Europe, limiting data on population groups other than Caucasians.

Geographical and racial differences

The incidence of CoM varies between geographical areas as well as between population groups with a different racial background. This may point towards a genetic (or population-related) predisposition, as well as a role for environmental factors (such as UV-radiation) in development of CoM.

CoM is typically considered a disease of people with (northern) European ancestry, occurring most frequently in the Nordic countries and parts of North America (Figure 3); however, it can impact people of any descent. A significantly higher incidence has been observed among Non-Hispanic Whites (0.49/million) compared to Hispanics (0.33/million), Blacks (0.18/million), American Indians (0.17/million), and Asians (0.15/million) in a large American study on CoM and race.[35] Recent work from Canada identified a higher incidence of CoM in the eastern Canadian provinces, with presumably many inhabitants of European descent,[32] corresponding with elevated incidences of cutaneous melanoma. In this study, the incidence of CoM was somewhat lower in Canada compared to the USA. This was attributed to the South-to-North gradient, with a lower occurrence of CoM in Canada due to less UV-radiation at the higher latitude.[36] This Canadian study demonstrated that effects from both latitude (comparing Canada and the USA) as well as ethnic background (within Canada itself) are important factors in CoM development. A recent population-based study from Europe found a CoM incidence of 0.28/million in Southern Europe, and up to 0.90/million in Northern Europe.[28] The highest incidences were found in Norway, The Netherlands and Switzerland, which were also the countries with the highest incidence of cutaneous melanoma. This study did not identify a significant association between the incidence of CoM and the latitude of the reported countries, which may be due to an analysis that did not stratify for racial background, levelling out an effect of latitude.

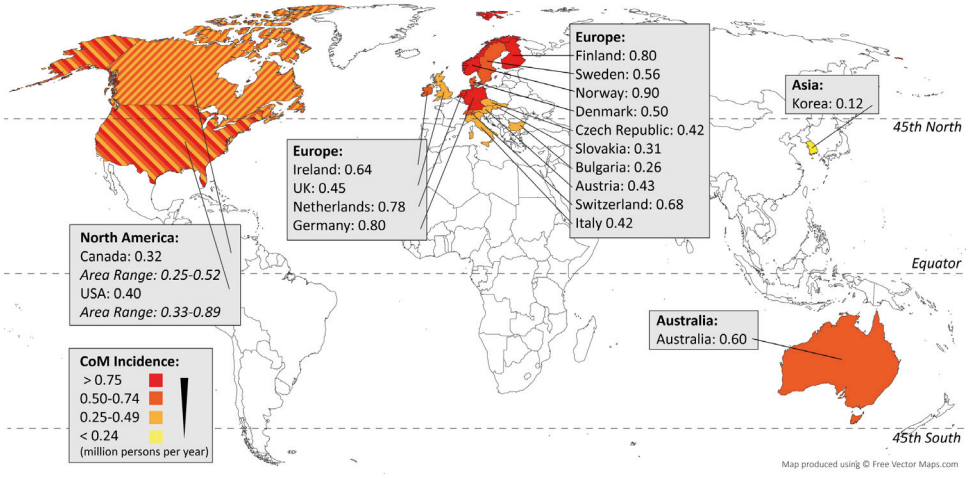

Figure 3. World map of the incidence of conjunctival melanoma. Data are depicted for countries with known incidence data based on more than 15 cases. For the USA and Canada, data are presented with a range since there is significant spread within these large countries. Incidence data source: (North America) Canada,[32] USA;[5,36] (Europe) Finland,[1] Sweden,[3] Denmark,[30] Germany,[37] Ireland, UK, Netherlands, Norway, Czech Republic, Slovakia, Bulgaria, Austria, Switzerland, and Italy;[28] (Asia) Korea;[38] (Australia).[39]

Epidemiologic observations from CoM in the US partially parallel those of UM, a disease that is most prevalent in non-Hispanic Whites (6.02/million), and less frequently seen in Hispanics (1.67/million), Asians (0.38/million) and Blacks (0.31/million).[40] Illustrating different aetiologies between CoM and UM, a significant *higher* UM incidence was observed for northern latitudes compared to other latitudes in an American[36] as well as a European[41] study.

In non-Caucasian populations, despite the rarity in absolute numbers, CoM is relatively prevalent compared to other ocular melanomas. A registry from South Korea found that 19% of all ocular melanoma were CoM,[38] which is much higher than the 5% in an American data set.[5] In the American *National Cancer Institute's Surveillance, Epidemiology and End Results* (SEER) registry, for non-Hispanic whites, an incidence ratio of 12.7 UM to every CoM was established, while this was 2.2 UM per CoM in Blacks, and 1.7 UM per CoM in Asians.[35] As will be further described in the chapter on genetics [chapter 3], mutations in CoM may differ between different populations, warranting studies into specific behaviour.[42] It is promising that awareness of CoM is increasing globally: in recent years, this resulted in (a non-exhaustive list of) reports from China,[42,43] Taiwan,[44] Japan,[45] South Korea,[38,46] Nigeria,[47] and Mexico.[48]

Time trends

The incidence of CoM has been rising during the last few decades (Table 1).[1-3,30] Some studies report stable incidences, but this may be due to limitations in study size or a short studied time span.[4,32,38,49,50] Between 1960 and 2005, the age-standardized incidence in Sweden has risen from 0.08 per million to 0.56 per million, with a more frequent occurrence on the bulbar parts of the conjunctiva.[3] A similar pattern was observed in Denmark, with a peak incidence of 0.87 per million in 2000-2009, and an increase in bulbar lesions between 1960 to 2012.[30] As will be discussed later on, there may be an etiologic and genetic difference between bulbar and non-bulbar CoM. In the USA, data from the SEER database showed an overall increase in the incidence of CoM between 1973 and 1999, age-adjusted from 0.22 to 0.46 per million.[2] Stratified for gender, however, a clear increase was seen in the incidence amongst men, but not amongst women. The authors hypothesized that this gender difference may be caused by differences in sunlight protection and outdoor activities. A recent large European study showed no significant overall change in incidence for 1995-1998 to 2003-2007 (incidence of 0.40 to 0.43 per million) but stratified by gender, there was a significant increase for men (0.41 to 0.53 per million) and a stable incidence for women (0.39 to 0.34 per million).[28]

The increasing incidence of CoM follows observations from cutaneous melanoma, with increasing numbers in the last decades in the USA[5] and Europe[1,4,51]. Similar to CoM, the increased cutaneous melanoma incidence is believed to be due to increased UV radiation exposure (specifically intermittent exposure),[52] and is most pronounced amongst males.[53]

Time trends that are observed in CoM are in contrast to observations from UM. Large population-based studies from the USA and Europe demonstrate no significant alterations in UM incidence for the last three decades, with overall values of 2-8/million in different regions.[41,54] Specific analyses show minor increases in UM, however, e.g. in the white population of the US,[54] and in Canadians over the last two decades.[55]

A complicating factor in the comparison of incidence rates of CoM (as well as other melanomas) between geographical areas and time periods are changing populations due to migration. As mentioned, genetic background is related to the risk for melanoma development. This may partially explain the differences between overall time-dependent rates of melanoma and numbers per subgroup in the literature. Data on race or ethnic background are not always available, calling for cautious interpretation of crude results.

Table 1. Epidemiologic studies on the incidence of CoM.

Study	Origin	Cases	Years	Overall incidence (Cases/million)	Current incidence (Cases/million)	Change over time		Race (Cases/million)
Tuomaala, 2002.[1]	Finland	85	1967-2000	All: 0.54	All: 0.80	1967 to 2000 0.40 to 0.80/million	Increase	Not reported
Yu, 2003.[2]	USA	206	1973-1999		All: 0.46 M: 0.63, F: 0.32	1973/1979 to 1990/1999 0.22 to 0.46/million	Increase	Whites: 0.48, Blacks: 0.19, Others: 0.26.
Vajdic, 2003.[39]	Australia	37	1996-1998	All: 0.6 M: 0.8, F: 0.4	Not reported	Not reported		Not reported
Isager, 2005.[4]	Denmark	120	1943-1997	M: 0.4, F: 0.3; NS	M: 0.3, F: 0.7; NS	1943 to 1997	Stable	Not reported
McLaughlin, 2005.[5]	USA	324	1996-2000	All: 0.4 M: 0.4, F: 0.4	Not reported	Not reported		Not reported
Hu, 2008.[35]	USA	168	1992-2003	All: 0.41**		Not reported		Non-Hispanic Whites: 0.49 Blacks: 0.18 American Indians:0.17 Asians: 0.15 Hispanics: 0.33
Triay, 2009.[3]	Sweden	170	1960-2005		All: 0.56 M: 0.74, F: 0.45	1960 to 2005 0.08 to 0.56/million	Increase	Not reported
Park, 2015.[38]	South Korea	90	1999-2011	All: 0.12	All: 0.12	1999/2005 to 2006/2011 0.11 to 0.12/million	Stable	(Asian population)
Larsen, 2016.[30]	Denmark	138	1960-2012	All: 0.50 M: 0.53, F: 0.48; NS	All: 0.48	1960/1969 to 2010/2012 0.36 to 0.48/million *Peak: 2000/2009: 0.87*	Increase	Not reported
Ghazawi, 2019.[32]	Canada	190	1992-2010	All: 0.32 M: 0.35, F: 0.29	All: 0.32 M: 0.35, F: 0.29	1992 to 2010 0.32/million	Stable	Differences based on population background*
Virgili, 2020.[28]	Europe	714	1995-2007	All: 0.46 (crude) M: 0.48, F: 0.46 All: 0.42 (age adj.)	All: 0.43 M: 0.53, F: 0.34	1995/1998 to 2003/2007 0.37 to 0.43/million	Stable	Not reported

Abbreviations: NA, not applicable; NS, not significant. M, Male; F, Female.

**Higher rates of CoM were seen in the eastern Canadian provinces (with many people of Caucasian/European descent), lower rates were seen in the provinces Ontario and Quebec (with higher numbers of self-identified minorities).*

***Overall calculation is based on the presented data per race, weighted for number of cases.*

Incidence adjusted to tissue size

The absolute rarity of CoM suggests that the conjunctiva as a tissue is unlikely to develop melanoma. An interesting figure emerges, however, when the incidence of CoM is related to the small surface of the conjunctiva, as compared to cutaneous melanoma and the much larger surface size of the skin. In a large study from the USA, the incidence of CoM was estimated at 0.4/million persons per year, and that of cutaneous melanoma at 153.5/million persons per year.[5] With an approximate skin area of 1.7 m^2 for a human adult,[56] and a conjunctival surface area per eye of 17.6 cm^2,[57] the incidence of cutaneous melanoma can be estimated at 90 per million m^2 skin per year, and the CoM incidence at 113 per million m^2 conjunctiva per year. These figures are now well within a comparable range, which is not surprising due to the similarities between skin and conjunctiva, and their respective melanomas.[7] To illustrate the difference with melanoma of the choroid, with a choroidal area approximating the retinal area of 1100 mm^2,[58] and a choroidal melanoma incidence of 4.3/million persons per year,[5] the incidence of choroidal melanoma can be estimated at 1955 per million m^2 choroid per year; this is a remarkable 20-fold higher per area unit compared to melanoma of the conjunctiva or skin. We conclude that CoM is rare in absolute numbers, but we put the rarity of CoM in perspective considering the conjunctival size. This calculation stresses the differences between intraocular and extraocular melanoma, with supposedly a different role for genetic and environmental factors (Figure 4).

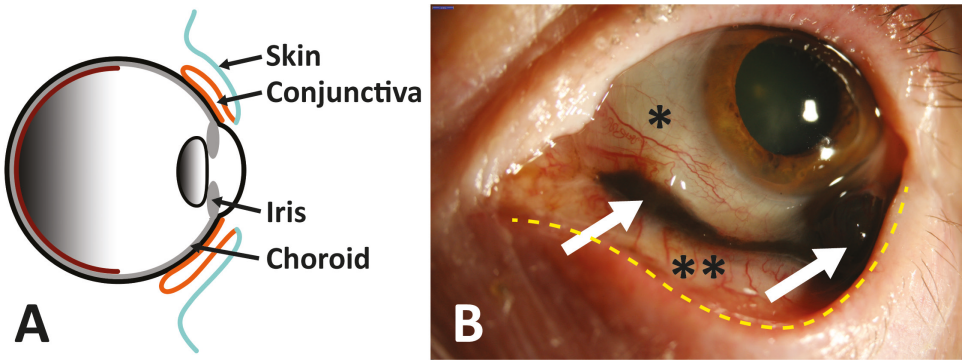

Figure 4. Ocular structures. Melanoma can affect several tissues of the ocular region. (A) There is a functional continuity between the conjunctiva and skin, opposed to the intraocular tissue of the uveal tract. (B) Note that conjunctiva can be divided into 'sun-exposed' conjunctiva (i.e. epibulbar and limbal; *) and 'covered' conjunctiva (i.e. tarsal and forniceal; **). In this patient, the melanoma extends through the fornix inferior (white arrows). The dotted yellow line indicates the eyelid margin.

Precursor lesions of CoM

Melanocytic diseases of the conjunctiva comprise a wide range of entities, based on the number and characteristics of melanocytes, and aberrations in the production of melanin. An illustrative overview of melanocytic disease was recently provided by Jakobiec.[59] Examples of conjunctival melanocytic disease include conjunctival nevi, primary acquired melanosis (PAM), complexion-associated melanosis (previously known as 'racial pigmentation') and CoM. By definition, CoM has invaded beyond the basement membrane into deeper tissues, but it may develop from other (non-invasive) disease. Many of the precursor lesions are far more prevalent than CoM, as was reported in an American study with population-based incidences of conjunctival nevi (50 cases per million), PAM (44 cases per million) and CoM (1.5 cases per million).[60] As with CoM, the prevalence of the precursor lesions differs between various races.

Most CoM (42-74% of cases) are believed to develop from PAM (Table 2).[6,16,61] PAM is clinically described as a unilateral, flat, light pigmentation of the conjunctiva (resembling 'cinnamon dust'), with a variable presence (i.e. 'waxing and waning'). The likelihood of PAM to develop into melanoma depends on histological characteristics: while PAM 'with atypia' develops into CoM in 13% of cases, PAM 'without atypia' is considered an indolent condition that rarely ever leads to malignancy.[62]

The histological classification of PAM is under continuous debate.[59] Grading PAM into 'with' or 'without' atypia was proposed[63] following systems that may have led to overacting by clinicians (using the term 'precancerous melanosis', by Reese) or to underestimation (using the term 'benign acquired melanosis', by Zimmerman). Issues remained for grouping PAM without atypia, however, and the lack of 'melanoma-in-situ' terminology. It can be advocated that PAM is the conjunctival equivalent of lentigo maligna of the skin, and that PAM with atypia is melanoma-in-situ, but the terminology from dermatopathology is not directly translatable. A newer system introduced 'conjunctival melanocytic intraepithelial neoplasia' (CMIN) on a 1-10 point score.[64] This score is increasingly being implemented. A consensus meeting for the most recent 4th ed WHO classification of tumours of the eye proposed a simplified scheme of the aforementioned PAM and CMIN terminology, using 'low-grade conjunctival melanocytic intraepithelial lesions (CMIL)', 'high-grade CMIL', and 'melanoma-in-situ'.[65] All three scoring systems were deemed suitable and comparable in sensitivity, specificity, and accuracy; however, grading of low-risk lesions may remain difficult.[66] While the debate on histological grading may continue, it should be noted that 'PAM' remains a suitable term for the clinical description of lesions, however, without information on atypia.

About 7% of CoM is believed to develop from a nevus (Table 2).[6] A range between 2 and 39% has been reported, which may be due to difficulties in histologic examination.[12,16,61,67] Conjunctival nevi are quite common,[60,68] and only rarely develop into melanoma: a large study from the USA

found that 3 out of 149 conjunctival nevi (2%) underwent malignant transformation.[69] Compared to CoM, nevi are seen more often in patients with a younger age (first/second decade) and often present with cysts; nevertheless, clinical differentiation can be challenging.[70]

In about 11-26% of CoM cases, no precursor lesion can be identified; these CoM are considered to have developed 'de novo' (Table 2).[6,12,16,61,67]

In spite of these reports, determination of the origin of CoM is controversial and imposes some difficulties. Clinical and histological findings may seem contradictory, and potential precursors may be overlooked or be impossible to determine.[71] In her 1990 thesis, De Wolff-Rouendaal noted that 16 of 33 CoM that were clinically graded as 'de novo', showed acquired melanosis on histopathological examination, questioning the origin.[72] As such, a co-occurring component of intra-epithelial melanocytes may be either pre-existing PAM or lateral spread of melanoma. Similarly difficult is the coexistence of potential precursors (such as PAM and nevi) making it difficult, if not impossible, to attribute melanoma outgrowth. While 'de novo' lesions were found to have a more unfavourable outcome compared to lesions from PAM or nevi,[6] we hypothesize that this observation is biased, and that this (in part) can be due to rapid melanoma growth, clinically lacking an obvious precursor lesion. We advocate a thorough clinicopathological correlation, combining data from clinical and histopathological observations, ideally with mapping biopsies. In the absence of these data, we suggest cautious use of the 'de novo' terminology and think that a 'de novo origin' should be regarded as 'uncertain origin'.

Table 2. Studies on the precursor lesions of CoM.

Study	Study size (cases)	PAM (%)	Nevus (%)	PAM and Nevus* (%)	De Novo (%)	Unknown* (%)
Shields, 2011.[6]	382	74	7		19	
Paridaens, 1994.[61]	256	57	18		22	2
Missotten, 2005.[12]	194	57	2	4	26	11
Larsen, 2015.[16]	139	62	33	2	11	
Tuomaala, 2002.[1]	85	61	30	8		
Anastassiou, 2002.[67]	69	42	39		16	3
De Potter, 1993.[73]	68	56	26		18	
Norregaard, 1996.[50]	42	19	21		60	

**These categories were not reported in all studies*
Abbreviations: PAM, primary acquired melanosis.

UV radiation and CoM

UV radiation is a well-established risk factor for the development of cutaneous melanoma, but has been debated in the development of CoM.[74] Several epidemiological and genetic studies indicate that UV-mediated mechanisms are involved, but the number of studies is small. Since CoM may develop at sites that are not exposed to sunlight, direct UV exposure may not be a necessity, but may be a risk factor.

Mechanisms of UV-mediated damage

Sunlight includes three classes of UV radiation: UVA (320-400nm), UVB (290-320nm), and UVC (100-280nm). UVA (95%) is more abundant than UVB (5%), while UVC is filtered by the atmosphere and hardly reaches the earth's surface. UVA and UVB have a different capacity to enter tissues, and differentially effect melanoma formation.

UVB has a direct damaging effect on DNA: photochemical reactions cause the production of cyclobutane pyrimidine dimers (CPD's) and pyrimidine pyrimidone photoproducts (PP's)[75] at locations where the pyrimidine bases (i.e. cytosine (C) or thymine (T)) are adjacent on the DNA (in sequences of CC, CT, TT, or TC). The presence of a dimer interferes with base pairing during DNA replication, leading to mutations. Both CPD's and PP's can be repaired by the nucleotide excision repair (NER) pathway, and dysregulation of NER therefore increases the risk for (cutaneous) melanoma development.[76]

UVA causes production of reactive oxygen species (ROS), and to a lesser extent of CPD's.[77] Recently it was found that melanin can be involved in UVA-mediated damage: reactive oxygen and nitrogen species excite electrons in melanin, their energy is transferred to DNA and induces CPD's, hours after the initial UV exposure.[78]

In the skin, UVB is predominantly absorbed in the epidermis, while UVA can reach the dermal stroma. The uvea is relatively protected from UV radiation by filtering in the cornea, lens, and other structures: only up to 1% of UV reaches the retina, most of which is UVA.[79] While the bulbar conjunctiva is sun-exposed, the tarsal and forniceal conjunctiva are not (Figure 4).

Based on the mechanism of action, an abundance of C>T and CC>TT mutations is typical for UV-mediated damage; this is called the UV 'signature' or 'footprint' in cancer development.[80] Additional effects of UV radiation on melanoma formation act via the immune system, as UV causes recruitment of macrophages and neutrophils in skin lesions.[81,82] The role of these immune cells in melanoma are discussed further in the sections on tumour immunology [chapter 4].

Epidemiological studies

An association between UV radiation and CoM can be derived from epidemiological studies, as was mentioned in section 2.2 (on geographical incidence) and 2.3 (on time trends). In short, areas with a lower latitude (i.e. more towards the equator) are related to higher incidences of CoM,[36] and increased numbers of CoM in recent years are particularly due to lesions of the bulbar (sun-exposed) conjunctiva.[3,30] Though vitamin D synthesis (following sun exposure) has been proposed as a protecting factor for cancer,[83] in CoM this may be overshadowed by DNA-damaging effects of UV. An Australian study on sun exposure was inconclusive regarding CoM due to low numbers (with only 19 cases reported), but CoM was related to a self-reported history of cutaneous melanoma, which could suggest either a role for sun exposure or a shared genetic susceptibility.[84]

In cutaneous melanoma, intermittent exposure and sunburn are of particular importance for tumorigenesis, but cumulative exposure infers a risk as well;[85] the relation between patterns of sunlight exposure and CoM development is not known.

Genetic studies

Early work regarding the role of UV on genetic changes in CoM was limited by the techniques to detect mutations. One of these early studies (targeting mutations in the *NRAS* gene), found no aberrations in six cases of CoM and concluded on a minor role for UV.[86] The authors recognized, however, that UV may affect the immune system to create an environment that is more prone to melanoma development. A decade later, identification of a UV signature in DNA damage[80] showed direct evidence for UV-mediated mechanisms in CoM. Griewank found *TERT* promotor mutations in 12/38 (32%) CoM samples, all with the typical UV-related C>T and CC>TT changes.[18] Later work confirmed the presence of this typical UV signature in a genome-wide sequencing study of two CoM[87] and five CoM[88] which were all from bulbar, (i.e. sun exposed) sites analysed by whole-exome sequencing. A recent extension to the work by Rivolta et al found that in 12/14 (86%) CoM more than 70% of the mutational load consisted of C>T changes, and the three studied CoM with the least C>T changes were tarsal and not bulbar;[89] these tarsal lesions had significantly lower amounts of single nucleotide variants than bulbar lesions. Other work, however, noticed no differences in gene expression of 161 oncology-related genes between 6 sun-exposed and 6 non-exposed CoM, suggesting less influence of UV on genetic profile.[90] Interestingly, a recent study found a UV signature in (sun-exposed) iris melanoma but not in posterior UM,[91] suggesting a spectre of influence of UV rather than a strict distinction between CoM and UM; this warrants further studies in genetic similarities between CoM and iris melanoma.

The position of *BRAF* mutations in UV-mediated damage is not well understood, particularly because the most-common *BRAF* mutation lacks a UV signature.[92] However, intermittent sun exposure of the skin (compared to either chronically or non-exposed sites) has been related to *BRAF* mutations.[93] Similarly, CoM at sun-exposed bulbar sites more often have *BRAF* mutations

than CoM at non-bulbar sites.[30] The increased frequency of *BRAF* mutations in cutaneous and conjunctival lesions may therefore be due to UV, with bulbar sites being intermittently sun-exposed; it was suggested that skin melanoma at chronically-exposed sites develops (partially) by other pathways.[93] A link between UV, *BRAF* mutations and melanoma is further observed since a greater exposure to UV radiation during childhood is related to the presence of more acquired nevi of the skin, carrying *BRAF* mutations, which then constitutes a risk for development of melanoma of the skin.[92] Similarly, *BRAF* mutations are more frequently found in CoM lesions that originate from conjunctival nevi,[30] which harbour *BRAF* mutations as well [section 3.2.1].

In cutaneous melanoma, patients with a higher mutational burden (as seen following UV damage) may be better candidates for immunotherapy;[92] this should be studied in CoM as well, as the use of immunotherapy is increasing [chapter 5].

Sun protection and CoM

A question that is relevant population-wide, is whether the eye needs to be protected from sunlight to diminish the risk for melanoma. Sunglasses have been suggested to prevent CoM,[87] but it will be hard to study the effects on CoM on a large scale by the rarity of the disease. Even more, as much of the UV that reaches the eye is through reflection, this may hamper good blockade.[79] Eye protection (e.g. with sunglasses) should certainly not be discouraged as it serves several purposes, but the protective effects regarding CoM should not be exaggerated in the absence of evidence.

Melanocytes and melanin

Melanin pigments have a role in the development and behaviour of different types of melanoma. This follows epidemiological data on skin and iris colour in cutaneous melanoma and UM, and is supported by the understanding of UV-mediated and UV-independent mechanisms of melanoma formation. While reports on melanin in the conjunctiva are rare, recent work suggests that tumour pigmentation is related to the behaviour of CoM,[15,94] warranting further investigation.

Two main types of melanin pigment are reported in the eye: dark-coloured *eumelanin*, and light-coloured *pheomelanin*. The amount and ratio of these pigments determine visible traits, as a low total melanin and relative abundance of pheomelanin cause light skin colour[95] and blue iris colour[96], while a high total melanin and abundance of eumelanin causes dark skin colour and brown iris colour. Eumelanin has protective effects on melanoma formation, by shielding against UV radiation[95] and scavenging reactive oxygen species (ROS) and free radicals;[97] pheomelanin can be involved in DNA damage via UVA[78] and by itself via independent ROS formation.[98] It has been suggested that melanin also is linked to the efficacy of the immune system, partially via aspects of ROS production, as ROS inhibits CD8+ T cell function[99] and stimulates differentiation of macrophages into an M2 type,[100] the implications of which are discussed in the chapter on immunology [chapter 4].

Conjunctival, uveal (including iridal), and cutaneous melanocytes are derived from the same embryonic (neural crest) cells,[101] though they migrate in different waves. Conjunctival and cutaneous melanocytes migrate to the surface ectoderm-derived epithelium and have functional similarities such as being able to transfer melanin to other cells;[101,102] this is in contrast with uveal melanocytes that migrate into deeper mesoderm-derived tissues and do not transfer melanin. Cutaneous melanoma[103] and UM[104-107] are known to occur more frequently in patients with fair skin and blue irises. No such population-based assessments exist for CoM, but as conjunctival melanocytes of light-iris eyes contain less total melanin and relatively more pheomelanin,[101] it can be hypothesized that melanocytes in the conjunctiva of patients with light-coloured eyes are more prone to CoM development.[15] Indeed, as CoM typically occur in countries with an abundance of people with light-coloured eyes, the role of melanin warrants further research.

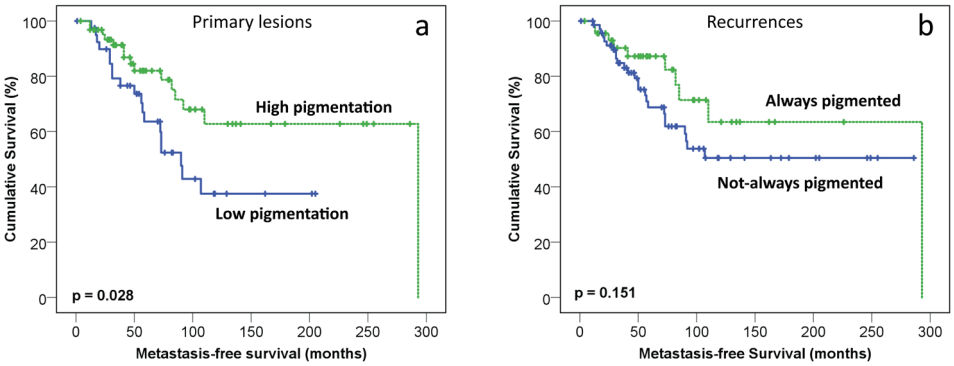

Figure 5. Kaplan-Meier analysis of metastasis-free survival based on tumour pigmentation. A combined set of Dutch and American CoM patients, of whom data on tumour pigmentation was known, was studied. (a) Patients were categorised by pigmentation of the primary lesion. A significantly worse outcome is shown for patients with low tumour pigmentation (n = 41) compared to high pigmentation (n = 64, p = 0.028). (b) The same group of patients is depicted, but is now categorised by the pigmentation of their recurrences. Outcome is not significantly different for those with recurrences with always high pigmentation (n = 46) compared to those with always low (or variable) pigmentation (n = 71, p = 0.151). [Figure re-used with permission from Brouwer et al., 2019.[94]]

CoM themselves can present as amelanotic to darkly-pigmented (Figure 1). Light tumour pigmentation in CoM is related to a worse clinical outcome compared to darker lesions, with a hazard ratio for melanoma-related death of 2.42 (p=0.020, studied in 444 CoM patients),[15] corresponding to observations from cutaneous melanoma. This could be due to direct melanocyte-related factors (such as the genotoxic/phototoxic effects of pheomelanin, and the absence of UV protection), or due to indirect effects such as late identification, insufficient treatment due to hard-to-detect tumour margins and late observation of recurrences (Figure 5).[15] CoM recurrences are more often lightly pigmented compared to their primary lesion, which could be due to more

aggressive melanocytes (lacking pigment production) or treatment-related factors as clinicians may be more meticulous in assessment of melanoma-proven patients.[94] In contrast to what was seen with primary lesions, de degree of pigmentation of recurrences is not related to outcome, however (Figure 5).

As yet, no relation has been observed for iris colour and clinical outcome in CoM,[15] nor for skin type and prognosis.[108]

Conclusions (Epidemiology and Etiology)

CoM is a rare disease that accounts for 5% of all ocular melanoma. It is most prevalent in Caucasians, and is showing a rising incidence in recent decades. Adding to epidemiological studies, recent genetic work identified UV signatures in CoM, supporting the role of UV in CoM development, and suggesting different aetiologies for tarsal versus bulbar lesions. This is similar to what is seen in cutaneous melanoma. We calculated that, adjusted for tissue size, the incidence of CoM is very similar to that of cutaneous melanoma, and very different from that of UM.

It is promising that awareness of CoM increases worldwide, as improved recognition may cause earlier detection. More extensive knowledge about CoM may help clinicians to apply the appropriate treatment. Further studies are needed to determine whether CoM behaves similarly in all populations, as most current studies originate from North-America and Europe, and the genetic profile of CoM may differ between populations.

Melanin pigments (as a visible trait of melanocytes) have been related to melanoma development in the skin and uvea. A lower metastasis-free survival in CoM lacking visible pigment was observed, suggesting that the presence of pheomelanin, and absence of eumelanin, are unfavourable. Further molecular studies with quantification of melanin are warranted to understand its exact role in CoM biology.

The traditional theory of precursor lesions for CoM (i.e. being derived from PAM, nevi, or de novo) may need revision, as it is often impossible to determine a precursor, and both internal factors (such as genetics, pre-existing lesions, and melanin pigments) and external factors (such as UV radiation) are involved in melanoma development. We advocate to thoroughly study clinical data, histological data, and perform mapping biopsies to determine the origin of a lesion. It may be necessary to be cautious with 'de novo' terminology and we urge the use of 'tumour of unknown origin' in the appropriate cases.

3. GENETICS

Tumour genetics

The development of cancer is a multistep process that has been portrayed by Hanahan and Weinberg in the 'hallmarks of cancer'.[109] Many of these hallmarks relate to genetics, such as sustained proliferative signalling, evasion of growth suppressors, and resistance to cell death. Simplified, cancer develops from the accumulation of genetic mutations, in addition to several epigenetic processes and interactions with the tumour micro-environment (TME). The TME is discussed in the chapter on tumour immunology [chapter 4]; here we elaborate on the genetic background of CoM, the comparison with other types of melanoma, and the implications for newly-developed targeted therapies.

An important concept in tumour genetics is that of *proto-oncogenes* and *tumour suppressor genes*. Proto-oncogenes are essentially normal genes, that, when overactive due to a mutation, contribute to malignancy. Tumour suppressor genes have an opposite role: they suppress malignancy in the normal situation, but contribute to it in case of decreased expression or mutational loss. Examples of proto-oncogenes in melanoma biology are *BRAF*, *NRAS*, and *GNAQ/11*; examples of tumour suppressor genes are *NF1* and *PTEN*.

Tumour genetics - as well as normal cellular processes - act via pathways: multistep cascades of proteins, enzymes (kinases), and other cellular components that result in a certain function or effect. Two important pathways in (conjunctival) melanoma biology are the 'MAPK' (mitogen-activated protein kinase, also known as 'RAS-RAF-MEK-ERK') pathway and the 'PI3K-AKT' (also known as 'PI3K-AKT-mTOR') pathway. Overactivity of these pathways causes cell survival and proliferation. The pathways are highly complex and intertwined, but can be simplified to explain the aetiology of CoM, and the mechanisms of targeted therapy (Figure 6). Via these pathways, we will discuss how the genetic signature of CoM has several similarities to cutaneous and mucosal melanoma, while there are many differences with UM. In chapter 5.2, we will elaborate on newly-developed targeted therapies and discuss the first clinical observations of their application in CoM.

The MAPK pathway

The MAPK pathway consists of the cascade of RAS, RAF, MEK, and ERK.[110] RAS is a small G protein, that can be activated by receptor tyrosine kinases (RTKs, a transmembrane protein) following binding by a ligand. RAS activates the cascade of protein kinases RAF, MEK, and ERK. Activated ERK (also known as MAPK) then enters the nucleus to cause expression of several proliferative genes. Mutations can occur throughout the MAPK pathway. Three different RAS genes (*NRAS, KRAS,* and *HRAS*) can harbour a mutation, resulting in an activated state. Among the RAF genes, a mutation in *BRAF* is the most common, resulting in increased kinase activity.[111] In

the most common *BRAF* mutation, a glutamic acid (presented by 'E') substitutes valine (presented by 'V') at the 600th amino acid, explaining the mutation terminology *V600E*.[111] Valine can be substituted by lysine (presented by 'K') as well, resulting in *V600K*; even more rare substitutions like *V600M* have been described.

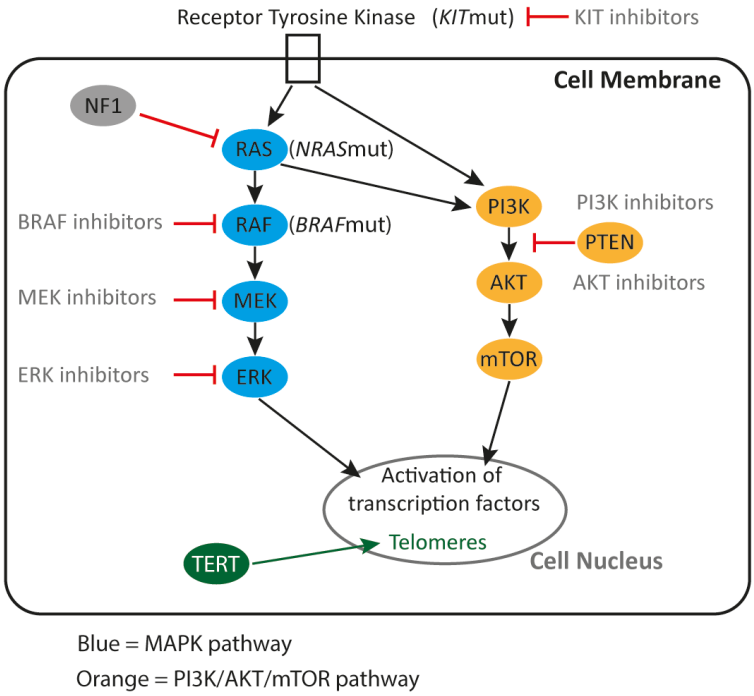

Figure 6. Cancer pathways in CoM and targets for therapy. This figure provides a simplified overview of important pathways that cause cell growth and proliferation in CoM. The MAPK pathway (in blue) consists of RAS (with possible mutations in *NRAS*), RAF (with possible mutations in *BRAF*), MEK, and ERK, which leads to activation of several proliferative factors in the nucleus. The PI3K-AKT-mTOR pathway (in orange) consists of PI3K, AKT and mTOR. NF1 (in grey) is a natural inhibitor of RAS (i.e. a tumour suppressor), by loss of this function, *NF1* mutations cause upregulation of MAPK. The receptor tyrosine kinases (with possible mutations in *KIT*) activate both MAPK and PI3K components. Another common link is RAS, that activates MAPK as well as PI3K. PTEN is a suppressor of AKT activity, acting as a tumour suppressor. TERT (in green) is involved in telomere length, causing cellular immortality.

The PI3K-AKT and other pathways

The PI3K-AKT pathway consists of phosphatidylinositol 3-kinase (PI3K), AKT, and mTOR.[112] PI3K can become activated by RTKs or RAS, providing a link between the MAPK and PI3K-AKT pathways. PI3K activates the protein kinase AKT, which then activates the kinase mTOR

(mammalian target of rapamycin). This is a regulator of cell proliferation and survival. *PTEN* is a natural inhibitor of PI3K, as it antagonizes its activity. Mutations or loss of *PTEN* can therefore upregulate PI3K activity.

Two actors that are proximal to the MAPK and PI3K-AKT pathway are NF1 and the RTKs. *NF1* is a gene that encodes the neurofibromin 1 protein, an inhibitor of RAS that works through GTPase activity.[113] Most mutations that occur in *NF1* are loss-of-function, causing upregulation of RAS. One of the transmembrane RTKs is KIT (also known as c-KIT). Binding of the KIT ligand stem cell factor causes activation of several downstream pathways including MAPK and PI3K-AKT signalling. KIT has an important role in the function of melanocytes.[114] Activating *KIT* mutations cause increased downstream signalling.

Apart from the MAPK and PI3K-AKT pathway, important actors in melanoma proliferation are the telomeres. Telomeres are end caps at chromosomes, that shorten with cell division to cause a limit in replication.[115] The telomerase reverse transcriptase (*TERT*) gene encodes a catalytic subunit of the telomerase complex that is involved in preservation of these telomeres. *TERT* promoter mutations increase TERT expression, allowing for survival ('immortality') of malignant cells.[116]

Mutations in CoM

Most work on genetic mutations in melanoma has been performed on cutaneous melanoma, which is not surprising due to their abundance over other melanoma types. Cutaneous melanoma are often classified according to their mutational status, resulting in groups of *BRAF*-mutated, *NRAS*-mutated, *NF1*-mutated and triple-WT (wild type) melanoma.[117] Several studies analysed the presence of mutations in CoM (Table 3), resulting in the idea that the same categorization may apply.[118] Recent work suggests that the *NF1*-mutated group is most frequent in CoM, while the *BRAF*-mutated group is the largest in cutaneous melanoma, pointing out that differences may exist between the two tumour types.[89]

BRAF mutations

BRAF mutations were first detected in cutaneous melanoma, where they occur in more than half of the cases.[119] The most common *BRAF* mutation in cutaneous melanoma is V600E (73%), followed by V600K (19%) and some sporadical types (<5%), such as V600R, V600M or V600G.[120] The frequency of *BRAF* mutations differs between types of cutaneous melanoma, as they are seen more often in lesions without chronic sun damage (i.e. no or intermittent sun exposure) compared to chronic sun exposure.[93]

Mutations in *BRAF* are observed in about a third of CoM,[17,30] and similar to cutaneous lesions, the most common *BRAF* mutation is V600E (in approximately 80%), followed by V600K (in

approximately 20%).[17,30,121] There may be racial differences in the occurrence of *BRAF* mutations, as these were less frequently observed in Asians (8%) compared to Caucasians,[42] similar to what is observed for cutaneous melanoma.[122]

While several authors looked for possible associations between *BRAF* mutations and clinical parameters in CoM, only a few significant relations were found, possibly due to small sample sizes. The largest series of CoM (111 cases with a known *BRAF* mutation status) showed that *BRAF* mutations (univariately) are more common in younger patients, males, lesions with an epibulbar location (compared to non-epibulbar), with absent or mixed pigmentation (compared to dark pigmentation), and lesions with a lower tumour-node-metastasis (TNM) stage.[30] Additionally, *BRAF* mutations are more often seen in CoM that originate from a nevus than those that originate from PAM.[17,30]

As no relation has been observed with recurrences, metastasis or survival, the presence of a *BRAF* mutation is of limited use for prognosis in CoM.[17,30]

During the time period 1960 to 2012, the percentage of CoM with a *BRAF* mutation has not increased, while this had been expected due to an increase in the number of bulbar CoM;[30] however, it may be that both demographic changes as well as an increased exposure to sunlight influenced the number of CoM, resulting in more CoM, but with an unaltered *BRAF* frequency. The relation between UV exposure and *BRAF* mutations is not fully understood however, as is presented in more detail in section 2.6.3. Importantly, the *BRAF* mutation status was not the sole predictor of MEK, ERK and AKT signalling in CoM tissue,[121,123] implying that the MAPK and PI3K-AKT pathway are activated by other parameters as well.

BRAF mutations are very common in conjunctival nevi, where they occur in 19-56% (Table 4).[121,123-125] While this percentage may be higher than the percentage in CoM, activation of the MAPK pathway was higher in malignant CoM than in benign nevi, again suggesting that other factors are involved in pathway activation (e.g. mutations in *NF1*).[123] The abundance of *BRAF* mutations in conjunctival nevi parallels that of nevi of the skin, where a study reported these in 82%.[126]

BRAF mutations are rare in PAM, either with or without atypia, and most studies observed no *BRAF* mutations in PAM at all (Table 4).[121,124] One report noted a *BRAF* mutation in 2/8 PAM lesions (with atypia), but these PAM were selected for later outgrowth of CoM, which may indicate that these have represented melanoma in situ.[30]

Most often a pre-malignant lesion has the same *BRAF* status as its CoM outgrowth: in 19 out of 20 pairs (12 nevi, 8 PAM) the *BRAF* status concurred.[30] However, heterogenous lesions can

occur, as one nevus (*BRAF* mutated) later recurred into a melanoma without *BRAF* mutation, possibly indicating outgrowth of a specific strain of cells. These sequential differences have also been reported for CoM lesions and their recurrences, occurring years later.[127]

BRAF mutations are less common in mucosal melanoma (other than CoM), with a likely frequency of 4-8%.[128,129] *BRAF* mutations are not seen in UM of the choroid and ciliary body,[119,130,131] although they have been described recently in iris melanoma in 1/30 cases (3%).[132]

NRAS mutations

In cutaneous melanoma, mutations in *BRAF* and *NRAS* are generally mutually exclusive, with fewer than 1% carrying both.[133] *NRAS* mutations occur less frequently than those in *BRAF*, with a frequency in cutaneous melanoma of 12-27%.[133-136]

In CoM, *NRAS* mutations are also mutually exclusive with *BRAF*,[17] and occur with a frequency of 0-18%.[17,134] *NRAS* makes up almost all mutations in *RAS* genes in CoM; activating mutations in *KRAS* are rare, those in *HRAS* (with unknown consequences) are reported hardly at all.[118] Though *NRAS* mutations are common in conjunctival nevi, with 39%,[125] their occurrence in PAM is unknown. There is no clear association between tumour origin and CoM *NRAS* status.[118]

NRAS mutations are seen in 11-24% of mucosal melanoma other than CoM.[128,129,134] *NRAS* mutations have not been reported in posterior UM,[131,137] although (similar to what is seen for *BRAF*) they may be encountered in iris melanoma (reported by one study in 3/10 cases[132]).

NF1 mutations

In cutaneous melanoma, *NF1* mutations are common (occurring in 12-14%) being the third most frequent mutation after *BRAF* and *NRAS;* often *NF1* co-occurs with either of these.[117,133] *NF1* mutations in the skin are associated with UV exposure[133] and *NF1*-mutated cutaneous melanoma have a high mutational load (compared to BRAF/RAS/triple-WT),[138] which may imply that they are more sensitive to immunotherapy (as was shown for anti-PD-1 therapy in cutaneous melanoma patients[139]). In cutaneous melanoma, patients with *NF1*-mutated lesions have a worse survival than those with *BRAF/RAS* mutations.[138] All of this makes NF1 an interesting gene.

NF1 mutations are indeed frequently observed in CoM and occur in 33%,[118] however (possibly due the smaller numbers studied) they are not associated with clinical characteristics or prognosis.[118] To our knowledge, *NF1* status is unreported in precursors of CoM.

In mucosal melanoma, *NF1* mutations are readily observed with a frequency of 18-37%.[129,140] *NF1* mutations are commonly absent in UM, but deletion of the NF1 locus was reported in one tumour in a study on 38 cases of UM (3%).[141]

KIT mutations

KIT mutations are rare in cutaneous melanoma: the incidence varies for anatomic location however, as total absence is reported in non-*chronic sun-damaged* (CSD) melanoma, and up to 28% in CSD melanoma.[142] Commonly, *KIT* mutations are mutually-exclusive with *BRAF* and *NRAS*.

In a composite of four studies on CoM, only 1 in 68 cases (1%) demonstrated a *KIT* mutation,[17,134,143,144] demonstrating similar rarity. Immunohistochemical staining of KIT occurs in about 50% of CoM, but this showed no correlation to mutational status.[143] *KIT* mutations are seen more often in CoM in Asians (11%) compared to Caucasians,[42] which concurs with the finding of a lower *BRAF* frequency. *KIT* mutations are absent in conjunctival nevi, and rarely seen in PAM with atypia,[143] however little data are available.

KIT mutations are more common in acral and mucosal melanoma (23 and 16%, resp.,[134] and some studies even report up to 40%. While they were initially unreported in UM,[134] later reports found up to 9% in choroidal lesions,[144] and 7% in iris melanoma.[132]

PTEN mutations (PI3K/AKT)

An important mediator of the PI3K/AKT/mTOR pathway is *PTEN*, that acts as an inhibitor. PTEN's function is partially determined by its location in the cell: nuclear (instead of cytoplasmatic) PTEN has a tumour suppressive role; loss of *PTEN* therefore stimulates tumour formation. *PTEN* loss is often mutually exclusive with *NRAS* mutations (and thus concurrent with *BRAF* mutations).

PTEN loss is commonly observed in cutaneous melanoma (65%),[145] and recent work showed that it was associated with worse survival, possibly by helping immune evasion.[146] *PTEN* loss has been described in CoM as well, but apart from a relation with more pigmentation, it was not related to other characteristics or prognosis in 70 lesions.[147] Several other mTOR-related proteins in CoM were associated with a high mitotic rate and thicker lesions, however.[148] Nuclear *PTEN* loss was observed more frequently in CoM than in conjunctival nevi,[147] suggesting an important role in melanoma development. This was similarly seen in cutaneous melanoma versus nevi.[145]

A comparative study between CoM and UM showed that mTOR effectors were higher in CoM, and that UM showed a higher PTEN expression.[148] PTEN loss in UM (of unreported anatomical location) was reported in 12/75 cases (16%),[149] and *PTEN* mutations were observed in 3 out of 30 (10%) iris melanoma.[132]

TERT promotor mutations

TERT promotor mutations (further referred to as '*TERT* mutations') are found in approximately 30% of primary cutaneous melanoma lesions.[150,151] *TERT* mutations are reported more often in older patients, and their frequency may vary based on tumour location, resulting in studies

reporting up to 68% in primary cutaneous melanoma.[152] Increased TERT activity relates to worse prognosis in cutaneous melanoma, but the role of either *TERT* mutations or TERT expression (not necessarily coinciding) is unclear.[152]

Very similar to the observed rates in the skin, *TERT* mutations are present in 32-43% of primary CoM.[18,116,153] In two studies, analysing 38 and 39 CoM lesions, no relation was found between *TERT* mutation status and clinical parameters or outcome (including patient age, tumour size, location, recurrences, survival).[18,153] The absence of a relation between *TERT* mutations and tumour location is remarkable, as *TERT* mutations in CoM show C>T or CC>TT nucleotide changes,[153] demonstrating a UV signature,[80] and one would expect these to occur mainly in bulbar conjunctiva. A recent, and larger, study with data of 47 CoM showed that presence of a *TERT* mutation correlated with metastatic disease, emphasizing an importance for therapeutic decision making.[116]

TERT mutations are not found in conjunctival nevi or PAM without atypia.[153] A small number, 2/25 (8%), of PAM *with* atypia carried the mutation, however.[153] This may indicate an important distinction between benign and malignant lesions, equally to what is observed in cutaneous lesions where melanoma and melanoma in situ have *TERT* mutations, but benign precursors not. A change in *TERT* may be an important early step in melanoma transformation, occurring, however later than the *BRAF* mutation.[154]

TERT mutations are rare in mucosal melanoma, with a range of 6-8%.[129,155] Presumably, this relates to the tumour locations, often lacking exposure to UV. Similarly it may be no surprise that *TERT* mutations are very rare in UM: several studies report on a total absence,[18,151] but they are found sporadically (in 1/102 cases,[153] and 1/50 cases[156]).

Other mutations: GNAQ/11 and BAP1

An analysis of genetics of CoM shows its distinction from the most common ocular melanoma: UM. Important genes in UM biology are *GNAQ/11*, *BAP1*, *SF3B1* and *EIF1AX* (extensively reviewed by Smit et al.[10]). Knowledge of these genes is relevant for CoM to understand a link with possible melanoma predisposition syndromes, and to identify the origin of unknown (secondary) conjunctival lesions based on tumour genetics, e.g. differentiating CoM from intraocular melanoma that has perforated the sclera.

GNAQ/11 signalling activates several pathways in cancer including MAPK,[131] and YAP1.[157,158] The *GNAQ/11* gene is mutated in nearly all UM,[131,159] and mutations are seen already in uveal nevi.[160] *GNAQ/11* mutations are absent in CoM,[17] other mucosal melanoma,[90] conjunctival nevi and PAM.[125,161] A *GNAQ* mutation was reported in two cases of conjunctival blue nevi, however,

indicating a different cellular origin than the common epithelial nevus.[125] *GNAQ/11* mutations are absent in cutaneous melanoma, but individual cases have been reported in chronically sun-damaged skin.[159]

Other mutations in UM that are important for tumour progression occur mainly in three genes: *BAP1*, *SF3B1,* and *EIF1AX,* which were reported in 43%, 26%, and 21% of primary UM, respectively.[10] Mutations in *BAP1* are related to the worst prognosis and these tumours often metastasize within a few years.[162] BAP1 immunohistochemistry (IHC) is nowadays commonly applied to assess *BAP1*, as a prognostic factor in UM.[163]

BAP1 (located on chromosome 3) was discovered a decade ago,[164] with the BAP1 protein as a deubiquitinating hydrolase with several functions such as protein deubiquitination, cell cycle regulation, DNA damage repair, and regulation of gene expression;[165] loss of BAP1 expression has been linked to increased inflammation[166] and angiogenesis in UM,[167] but much about its function remains to be unveiled.

Different from what is seen in posterior UM, *BAP1* mutations sporadically occur in iris melanoma (3%)[132] and are uncommon in melanomas other than UM. They are practically absent in acral, mucosal, and cutaneous melanoma, though they may occur in cutaneous melanoma lacking chronic solar damage.[168] Remarkably however, only few studies exist on sporadic *BAP1* mutations in cutaneous melanoma. Recent work on TCGA data showed that the prognostic effect of BAP1 mRNA expression was opposite for UM and cutaneous melanoma, suggesting differential roles.[169] Even so, BAP1 loss is not observed in conjunctival lesions, and its status is not commonly assessed.[88]

Chromosomal aberrations

Chromosomal copy number alterations (CNAs) are relevant to tumourigenesis as they influence the function of locally encoded genes.

Though few reports exist on the topic, a plethora of CNAs has been reported for CoM, indicating complex karyotypes. Gains have been reported in chromosomes 1q, 3p, 6p, 7, 8q, 10q, 11p, 11q, 12p, 13q, 14p, and 17q, and losses in chromosomes 1p, 3q, 4q, 6p, 6q, 8p, 9, 10, 11q, 12q, 13, 15p, 16, 17p, 19, and 22.[17,88,89,171-173] The most frequently reported CNA is 6p amplification, which has been reported in up to 61% of CoM.[171]

Table 3. Prevalence of genetic mutations in various melanoma types.

	Conjunctival Melanoma	Cutaneous Melanoma	UM (posterior, unless otherwise noted)	Mucosal melanoma (other than CoM)
BRAF	4/15 (27%) [134] 3/21 (14%) [130] 23/78 (29%) [17] 2/5 (40%) [124] 5/22 (23%) [127] 11/31 (35%) [123] 10/39 (26%) [121] 39/111 (35%) [30] 4/53 (8%) [42] *1	16/44 (36%) [137] 398/774 (51%) [119] 115/253 (46%) [120] 166/318 (52%) [117] 87/217 (40%) [136] 82/213 (38%) [133] 3/10 (10%) without CSD [93] 22/40 (59%) with CSD [93]	0/88 (0%) [130] 0/62 (0%) [137] 0/48 (0%) [131] 0/23 (0%) [119] 1/30 (3%) iris [132]	0/26 (0%) [119] 1/6 (17%) [120] 2/56 (4%) [128] 0/45 (0%) [134] 6/71 (8%) [129]
NRAS	0/11 (0%) [134] 14/78 (18%) [17]	7/60 (12%) [134] 1/27 (4%) [137] 20/114 (18%) [135] 53/217 (24%) [136] 58/213 (27%) [133]	0/47 (0%) [137] 0/48 (0%) [131] 3/30 (10%) iris [132]	8/56 (14%) [128] 9/37 (24%) [134] 8/71 (11%) [129] *2
KIT	1/13 (8%) [134] 0/5 (0%) [144] 0/42 (0%) [17] 0/8 (0%) [143] 6/53 (11%) [42] *1	1/58 (2%) [134] 0/18 (0%) without CSD [142] *3 5/18 (28%) with CSD [142] *3	0/60 (0%) [134] 6/64 (9%) chor+CB [144] 2/6 (33%) iris [144] 2/30 (7%) iris [132]	15/38 (39%) [142] 2/56 (4%) [128] 7/45 (16%) [134] 9/19 (47%) [140] 5/71 (7%) [129]
TERT	12/38 (32%) [18] 16/39 (41%) [153] 20/47 (43%) [116]	16/56 (29%) [151] 27/77 (33%) [150] 131/194 (68%) [152]	0/47 (0%) [18] 0/25 (0%) [151] 1/50 (2%) [156] 1/102 (1%) [153]	4/71 (6%) [129] 4/49 (8%) [155]
NF1	21/63 (33%) [118]	26/213 (12%) [133] 45/318 (14%) [117]	1/38 (3%) [141] 0/24 (0%) [170]	13/71 (18%) [129] 7/19 (37%) [140]
GNAQ	0/39 (0%) [17] 0/4 (0%) [161] 0/11 (0%) [131] 0/9 (0%) [159] 0/12 (0%) [90]	0/15 (0%) without CSD [131] 1/27 (4%) with CSD [131] 1/74 (0%) with CSD [159] 0/90 (0%) without CSD [159]	12/27 (44%) [161] 22/48 (46%) [131] 48% [159] *4	0/14 (0%) [131] 0/28 (%) [90]
GNA11	0/39 (0%) [17] 0/9 (0%) [159] 0/12 (%) [90]	0/74 (0%) with CSD [159] 0/90 (0%) without CSD [159]	34% [159] *5	0/28 (0%) [90]
BAP1	0/5 (0%) [88]	0/15 (0%) with CSD [168] 2/15 (13%) without CSD [168]	13/33 (39%) [168] 35/74 (47%) [163] 1/30 (3%) iris [132] *6	0/15 (0%) [168]

Abbreviations: CSD, chronic solar damage; Chor, choroidal; CB, ciliary body.

**1 In contrast to many other studies, this work includes an Asian population.[42]*

**2 Any mutation in RAS genes was observed in 12/71 (17%) of cases: NRAS mutations comprised 8/71 (11%), KRAS mutations 4/71 (6%).[129]*

**3 Note the marked difference in KIT frequency between CSD and non-CSD lesions.[142]*

**4 Any GNAQ mutation in 48%, consisting of Q209 in 73/163 (44.8%), and R183 in 4/145 (2.8%).[159]*

**5 Any GNA11 mutation in 34%, consisting of Q209 in 52/163 (31.9%), and R183 in 3/145 (2.1%).[159]*

**6 BAP1 immunohistochemistry loss in 9/30 (30%) cases.[132]*

Table 4. Prevalence of genetic mutations in precursor lesions of CoM.

	Conjunctival Nevi *Cases (%)*	**PAM without atypia** *Cases (%)*	**PAM with atypia** *Cases (%)*
BRAF	14/28 (50%) [124] 13/23 (56%) [125] 15/35 (43%) [123] 7/37 (19%) [121] 9/12 (75%) [30] *1	0/11 (0%) [124] 0/17 (0%) [121]	0/4 (0%) [124] 0/13 (0%) [121] 2/8 (25%) [30] *1
NRAS	9/23 (39%) [125]	N.A.	N.A.
KIT	0/5 (0%) [143]	N.A.	1/3 (33%) [143]
TERT	0/56 (0%) [153]	0/14 (0%) [153]	2/25 (8%) [153]
NF1	N.A.	N.A.	N.A.
GNAQ	0/29 (0%) [161] 0/23 (0%) [125] *3	0/7 (0%) [161] *2	0/7 (0%) [161] *2
GNA11	N.A.	N.A.	N.A.
BAP1	N.A.	N.A.	N.A.

Abbreviation: N.A., not applicable.
**1 Lesions were selected on later development of CoM (paired lesions), possibly introducing bias to malignancy.*
**2 Unknown status of atypia.*
**3 A GNAQ mutation was reported in 2/2 (100%) of blue nevi of the conjunctiva.[125]*

The observed CNAs in CoM resemble those in cutaneous melanoma.[93] And similar to what is seen in cutaneous melanoma,[174] CNAs in CoM were observed more frequently in *BRAF/NRAS*-wildtype tumours.[17] CNAs in CoM are distinct from observations in UM[17] where loss of chromosome 3 (which includes the *BAP1* gene) occurs frequently and is related to the development of metastases.[164] Other alterations that are frequently observed occur in chromosomes 8q and 6 (reviewed by Jager et al., 2020.[9]).

Most of the reported CNAs in CoM have no relation with clinical parameters or prognosis. A recent study identified that deletion of chromosome 10q was related to the presence of *BRAF* mutations, increased tumour thickness, metastasis development, and lymph invasion.[171] Genes encoded by the 10q region are *SUFU*, *NEURL1*, *PDCD4*, and *C10orf90* (all of which are tumour suppressor genes). The work by Kenawy et al, studying 59 lesions, shows the relevance of CNAs in CoM when assessing a relatively large cohort;[171] multicentre projects such as these are therefore essential to obtain sufficient numbers.

Predisposition syndromes

Several genetic disorders or syndromes exist that predispose to the development of cancer and melanoma, e.g. the *Familial atypical multiple mole melanoma* (FAMMM) syndrome and the *BAP1*-tumour predisposition syndrome. To our knowledge, no such syndromes have been identified for CoM, possibly due to the rarity of this disease. It is likely however, from melanocyte biology, that

certain syndromes that are associated with cutaneous melanoma, relate to development of CoM as well. Further studies are warranted, to identify patients at risk of CoM, and to optimize guidelines for screening.

A well-known melanoma syndrome is the FAMMM syndrome, also known as 'dysplastic nevus syndrome', which is associated with an increased risk for dysplastic nevi and cutaneous melanoma.[175] Despite suggestions from earlier reports,[176] more recent insights show that individuals with FAMMM do not have an increased risk for developing conjunctival pigmented disease (including melanoma) compared to others in the population.[177] Small numbers limit the strength of conclusions however.

Neurofibromatosis type I (Von Recklinghausen disease) is a genetic disorder, caused by a loss-of-function mutation in the (tumour suppressor) *NF1* gene.[178] Abnormal function of the neurofibromin protein increases RAS activity, resulting in development of several benign and malignant tumours. From this biology, it is no surprise that an increased risk for cutaneous melanoma has been reported,[178] although others state that the risk is not above chance,[179] and that sampling bias is a major concern. Several reports exist of CoM in patients with NF1-disease, but rarity of both conditions limits a conclusion on chance.[180-183] It remains controversial whether NF1-disease predisposes to UM.[184]

The nevus of Ota (oculodermal melanocytosis) is a congenital pigmented condition of the periocular area, which includes the skin, sclera, uvea and orbit. It was estimated that the lifetime risk for UM development in this condition was 1:400,[185] which is clearly above chance alone, and once UM develops, these patients have an increased risk for metastases.[186] Several cases of cutaneous melanoma have been reported in relation to a nevus of Ota,[187] including detrimental melanoma with orbital invasion,[188] but it has not been concluded that there is a true increased risk. Despite an apparent involvement of the ocular surface, we are not aware of reports on CoM associated with an ocular nevus of Ota. Pigmentation in nevi of Ota is not conjunctival however, and mutations in *GNAQ* can be found,[131] explaining a relation to blue nevi and UM rather than to cutaneous melanoma or CoM.

The *BAP1* tumour predisposition syndrome leads to increased risks for several malignancies, including UM[189] an to a lesser extent cutaneous melanoma.[168] There has been a report on a patient with the *BAP1* tumour predisposition syndrome and a conjunctival melanoma, who later developed a cutaneous melanoma; unfortunately no molecular testing or BAP1 staining was performed on the conjunctival lesion, questioning its true origin as primary conjunctival or metastatic lesion.[190]

miRNA

Micro-RNA (miRNA) is a class of small non-coding RNA that can regulate gene expression post-transcriptionally.[191] Conceptually, they can affect the expression of proto-oncogenes and tumour suppressor genes, and can serve as potentially diagnostic and prognostic markers, and as targets

for therapy. Often, miRNA have multiple targets, making it difficult to study individual effects. A plethora of miRNA have been identified in cutaneous melanoma, emerging as a new field in oncology.[191]

The first analysis of miRNA in CoM was presented by Larsen et al.[192] Studying 37 lesions, they found 25 miRNA that were differentially expressed between CoM and normal conjunctiva; several were concordant with miRNA known from cutaneous melanoma, while none were observed that had previously been associated with UM. Clustering based on seven miRNA showed that low, intermediate and high expression related in ascending order to increased CoM tumour thickness, but a true prognostic value was limited as only two miRNA related to recurrences, and none to development of metastasis.

Later work from the same group by Mikkelsen et al. analysed 13 CoM with paired metastatic lesions, and 25 CoM lesions that did not develop metastasis during a follow up of at least 5 years.[193] MiRNA were identified that showed a differential expression between non-metastatic and metastatic CoM, between CoM and its coupled metastasis, and between CoM and normal conjunctiva. Interestingly, pathway analysis of the involved miRNA showed that the hippo pathway and p53 were involved in the differentiation of normal conjunctiva to CoM. Unfortunately, there was a poor correlation between the array data and qPCR validation, implying that results need to be confirmed.

Ipenburg et al. studied 20 CoM and 6 conjunctival nevi, and validated the results in 19 CoM and 13 conjunctival nevi from another institution.[194] They identified five miRNA's (out of the 377 studied) that showed increased levels in CoM versus conjunctival nevi, and found that the homeobox gene clusters constituted a possibly shared pathway. No differences were found between lesions with or without metastases and no relation with clinical characteristics was reported. As an advantage of miRNA analysis, Ipenburg noted that miRNA testing may be used in cases with only very little available tissue, making it into a potential classifier to differentiate between a nevus and a melanoma.

Conclusions (Genetics)

Genetic mutations in CoM follow the same pattern as cutaneous and other mucosal melanoma. Frequently-observed mutations are those in *BRAF*, *NRAS, NF1,* and *TERT*. *KIT* mutations are rare but may relate to subgroups in non-Caucasians. Mutations in CoM combine the patterns from skin lesion with chronic sun damage (CSD) as well as non-CSD, being most like intermittently sun-exposed cutaneous melanoma. Although both are ocular tumours, CoM are genetically very different from UM, with mutations usually occurring in *GNAQ/11* or *BAP1.*

Little is known about tumour predisposition syndromes and CoM development. It may be expected that the FAMMM syndrome and Neurofibromatosis type 1 are related to CoM development, but the rarity of both limits the chance of finding a CoM in a patient with NF.

The diagnostic value of tumour genetics is currently confined to specific cases. The mutational profile may differentiate primary CoM or cutaneous melanoma from UM (and its metastases); differentiating a primary CoM from a lesion with a cutaneous origin is genetically difficult. Recent studies on miRNA show that expression profiles may help to differentiate benign from malignant conjunctival lesions, but this requires further validation.

The value of genetics for prognostic purposes in CoM is currently limited. Recently, *TERT* mutation presence was identified as an important factor,[116] as was loss of chromosome 10q,[171] both being related to metastasis development. Together with miRNA expression profiles, this shows that there may be prognostic use in the future. Genetic characterization of CoM may additionally be used to identify the most appropriate targeted therapy e.g. with *BRAF* inhibitor therapy, for selected patients. Although *BRAF* status is currently not predictive of outcome in CoM, it may become a prognostic factor in the future now that patients with *BRAF* mutations can receive targeted treatment.

4. IMMUNOLOGY

Tumour immunology

The human immune system is of paramount importance for tumour growth and control. Inflammation is therefore considered one of the hallmarks of cancer.[109,195] The immune system may inhibit tumour growth by killing tumour cells, but may also provide cytokines and chemokines that stimulate growth and tumour spreading. Tumours, on their turn, may use mechanisms to prevent attack by the immune system.

An important part of the specific immune response against tumour cells is played by Cytotoxic T cells (CTLs, also referred to as 'effector T cells'). These cells kill tumour cells when they recognize a specific antigen, presented via HLA Class I on the tumour cell membrane.[196] Tumours may learn to escape the killing effects of these T cells by loss of expression of HLA molecules, causing decreased recognition. Another escape mechanism acts via immune checkpoints, i.e. molecules that naturally help to diminish the activity of CTLs, preventing auto-immunity. It was recently discovered that these checkpoints can be blocked, leading to a new class of drugs (i.e. immune checkpoint-inhibitors (ICI's)) with promising results in many malignancies, including metastatic cutaneous melanoma. The first checkpoint inhibitor that was approved for metastatic melanoma by the *United States Food and Drug Administration* (FDA) in 2011 was ipilimumab, an IgG monoclonal antibody that

blocks *cytotoxic T-lymphocyte-associated protein 4* (CTLA4).[22] Later, in 2014, monoclonal antibodies against *Programmed cell death protein 1* (PD-1) followed, when nivolumab and pembrolizumab were approved by the FDA.[23,197] The 2018 Nobel Prize in Physiology or Medicine was awarded to Dr James P. Allison and Dr Tasuku Honjo for their discovery of CTLA4 and PD-1, respectively.

In this section, we discuss the current knowledge on infiltrating immune cells and expression of immunologic markers in conjunctival melanoma (CoM), and relate it to relevant observations from cutaneous and uveal melanoma (UM). In chapter 5.3, we elaborate on newly developed checkpoint inhibitor therapies and discuss the first clinical observations of their application in CoM.

Infiltrating lymphocytes and macrophages

Cell types of tumour infiltrate

The tumour micro-environment may contain a wide range of immune cells which play a role in the innate (non-specific) and the adaptive (specific) immune responses. Two main types of cells can be identified: histiocytes (i.e. macrophages and dendritic cells) and lymphocytes (i.e. B cells, T cells, and NK cells).

Macrophages are monocytes that originate in the bone marrow and circulate in the blood, until they are recruited to specific sites by chemokines. They have a role in protection against infections and in wound healing, through the production of various growth factors and cytokines.[198] Macrophages can be of an M1 or M2 subtype (though this should be considered as a spectrum), with different receptors, effector functions and chemokines.[199] M1-type macrophages target infectious diseases and can kill bacteria; they express high levels of pro-inflammatory cytokines, such as IL-12 and tumour necrosis factor (TNF). M2-type macrophages have an anti-inflammatory, pro-angiogenic, tissue remodelling role (and produce IL-10). Differentiation follows in response to microbial agents or exposure to cytokines such as interferon (IFN)-gamma.[199] While the total number of macrophages can be determined through marker CD68, the M2 type macrophages are commonly identified by double staining with monoclonal antibodies against CD68 as well as CD163. Tumour-associated macrophages (TAM's) are mainly of the M2 type,[199] which was demonstrated in cutaneous melanoma, CoM,[200] as well as in UM.[201] M2 type macrophages are notably linked to increased tumour angiogenesis in several melanomas,[201-203] where vessels serve to supply nutrients as well as provide a dissemination route for metastases.

Similar to macrophages, *dendritic cells* (DCs) are part of the antigen-presenting cell family; they play a major role in the initiation and regulation of immunological processes. They induce an antitumour response by cross-presenting antigens to both CD8+ and CD4+ cells, and can activate NK cells. DCs go through a maturation process,[196] but this will not be further discussed in this chapter.

Lymphocytes comprise a group of cells with various functions. *B cells* are known to produce antibodies, which help protect against infections.[204] Antibodies have a great target specificity, and B cells may support immune responses of other cells, such as T cells. Several different *T cell* types can be identified, such as the already mentioned CTLs, which express marker CD8. These *CD8+ T cells* can kill tumour cells and inhibit tumour growth by releasing IFN-gamma and TNF-alfa. Another important group of T cells is made up of *T helper cells* (Th) that express CD4. This group consists of several subtypes: *Th1* and *Th2* help the anti-tumour response by stimulating CD8+ T cells via the production of IFN-gamma, Transforming Growth Factor (TGF)-beta and IL-2.[205] Th1 cells can activate macrophages and help with the maturation of dendritic cells.[196] *T regulatory cells* (Tregs) are a specific subclass of Th cells that suppress immune responses. They express the protein *forkhead box P3* (FoxP3). Normally they have a role in maintaining immunologic self-tolerance and preventing autoimmune disease. In cancer, they may inhibit the anti-tumour action of other T cells.[206] A cell type with a broader reactivity is the *Natural Killer* (NK) cell. NK cells are able to kill cells that lack HLA Class I expression, or that express NK-activating ligands.[207] They are the effector cells of the innate immune system, but also interact with adaptive responses of the T and B cells.[196]

Tumour infiltrate in CoM

The first reports on inflammation in CoM date back to the second half of the 20th century.[208,209] Using regular histopathological examination, the presence of inflammatory cells was studied. Inflammatory cells could be divided into lymphocytes (small cells with a large nucleus) and macrophages, which have a large nucleus and ample cytoplasm, and often contain pigment (i.e. melanophages). It was soon recognized that infiltrate could be analysed for its prognostic value, analogous to findings from cutaneous melanoma,[210] and some studies likewise identified a significant association between the presence of infiltrate and better survival in CoM (Table 5).[209,211]

The amount of infiltrate demonstrated quite some variability. In early studies, absence of infiltrate was reported in 0 to 51%, and several subjective grading scales were used to describe the presence of infiltrating cells. Jay reported on a considerable set of 73 cases of CoM, noting *no infiltrate* in 13 cases (18%), *few cells* in 17 cases (23%), *moderate numbers* in 26 cases (36%) and *numerous cells* in 17 cases (23%).[208]

Several studies found no relation between the presence of infiltrate in CoM and prognosis.[208,212,213] Others did find such an association,[209] including Folberg, who studied the *thickest* known lesion of each patient (which could include later biopsies or recurrences as well) in a large set of 98 CoM associated with PAM; he found that lack of inflammation was associated with worse survival.[211] Another study found that inflammation was not related to survival in a univariate regression model, but that it did relate to better survival in a multivariate model which included other histological parameters.[214]

In the 1980s, monoclonal antibodies were created that helped to identify subtypes of the lymphocyte family. This allowed the identification of specific cell types, each with a specific cell surface marker and function: CD3 is a general T cell marker, CD8 is associated with cellular toxicity (CTLs) and CD4 is associated with the T-helper (Th) function. Anastassiou et al. observed variable amounts of infiltrating CD3+ cells in 26/32 (81%) of evaluable CoM.[215] CD68+ cells (macrophages) were present in almost all cases (in 33/34 (97%) of samples). There was no relation between the number of CD3+ or CD68+ cells and tumour-related mortality. A similar study in the same era used immunohistochemical staining to study the presence of lymphocytes and CD68+ macrophages in 60 specimens of CoM.[216] Lymphocytes were seen more frequently in limbal lesions, and numbers were inversely related to tumour thickness; they were not associated with the development of recurrences or survival. The number of macrophages was not associated with tumour location, thickness, or prognosis.

A decade later, Cao et al. continued on this work and studied the infiltrate of T cells and macrophages in 27 CoM using immunofluorescence (Figure 7).[200] All samples demonstrated infiltrate, again in varying amounts. Epibulbar (or cT1) lesions showed higher numbers of CD3+CD8- (i.e. Th) cells compared to non-bulbar (or cT2) CoM. The number of infiltrating cells was not related to gender, age, recurrences, metastasis or survival. There was an inverse relation between lesion thickness and numbers of CTLs (CD3+CD8+) and M2 macrophages (CD68+CD163+), which corresponded to the findings of Tuomaala. Cao additionally observed an inverse relation between largest basal diameter (LBD) and all types of lymphocytes. It was hypothesized that in the absence of infiltrate, including CTL's, CoM can grow unrestrained.

Cao noted that, using the same antibodies and techniques as in prior studies on UM, CoM contains higher densities of CD4+ overall, CD4+ Th, and CD4+ Treg cells than UM, but densities of CD8+ T cells and macrophages were lower; the cause of this is unknown. Just as in UM and cutaneous melanoma, the majority of macrophages in CoM were of the M2 type.[200]

Some studies report on the importance of ratios between infiltrating cells: a high CTL/Treg and M1/M2 ratio was related to improved survival in cervical cancer and cutaneous melanoma.[217,218] In Cao's work on CoM, however, these ratios did not relate significantly to survival or recurrences.

Major historical work on infiltrate in cutaneous melanoma was performed by Clark et al.,[210] who introduced the term tumour-infiltrating lymphocytes (TILs) and proposed the traditional classification system of TILs as being 'absent' (absent or not infiltrating), 'non-brisk' (i.e. focal presence) or 'brisk' (i.e. present at the base of lesions, or diffuse intratumourally).[220] [An illustrative review on the history of TIL research was presented by Mihm et al.[221]].

Clark noted that the absence of TILs was related to a worse survival in cutaneous melanoma.[220] Later studies were contradictory: immune infiltrate was often related to unfavourable tumour characteristics, but not uniformly to worse survival.[222,223]

Possibly, these discrepancies can be explained by characteristics of study groups. It has long been reported that TILs have impact in the vertical growth phase, but not in the (earlier) radial growth phase,[220] limiting conclusions in studies that include smaller, radial growth phase, lesions. Even so, the impact of TILs may be most clear in thicker lesions, despite thicker lesions having lower TIL numbers in general.[223]

When looking at Tregs specifically, it was observed that a high FoxP3 expression was associated with worse survival in 185 primary cutaneous melanoma patients, independent of lesion thickness. This points towards a suppressive action of Tregs in this malignancy.[224]

The role of macrophages in cutaneous melanoma is less well understood. In 202 samples, high counts of CD68+ cells were related to unfavourable features such as a greater Breslow thickness, ulceration, a higher mitotic rate and a high microvascular density (of both blood vessels and lymphatic vessels).[203] However, in this study no relation with relapse-free or overall survival was noticed. The finding that both blood vessels and lymphatic vessels were increased in lesions with many macrophages is interesting, as cutaneous melanoma (as well as CoM!) is known to disseminate via both routes, with an especially important role for the lymphatic route.

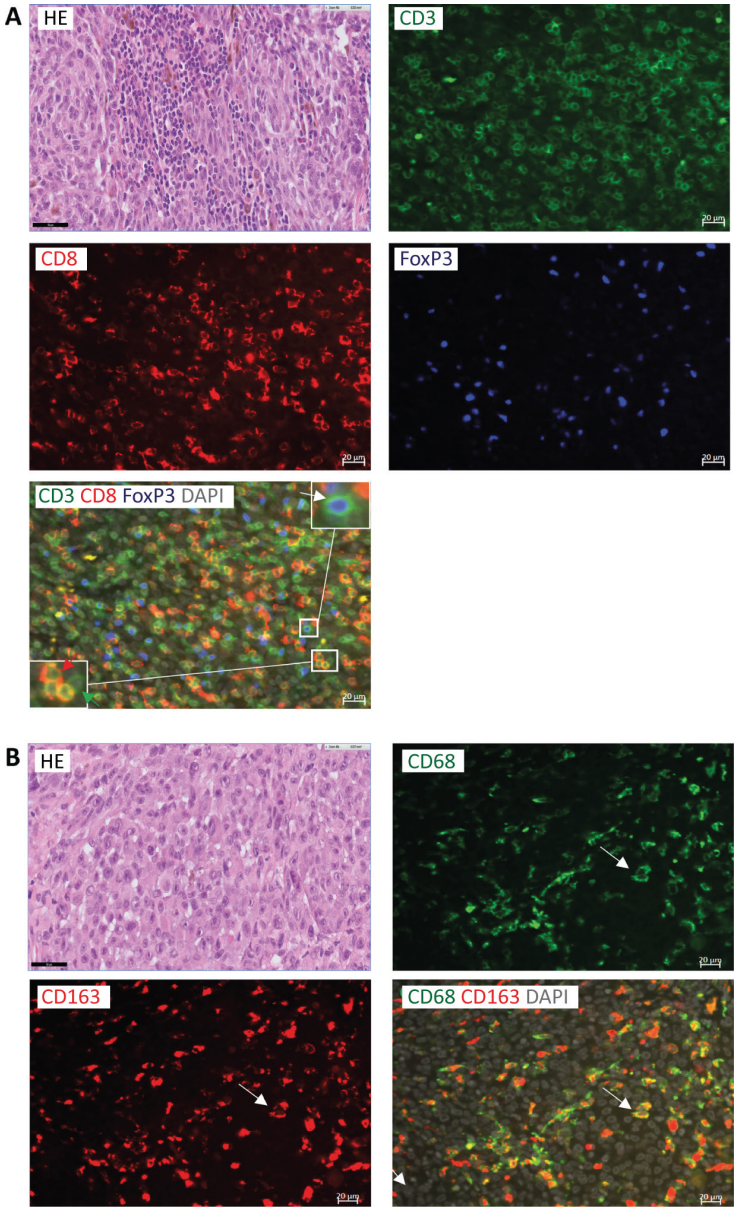

Figure 7. Tumour infiltrate in CoM. (A) CoM tissue was stained using H&E, CD3 (green, membrane), CD8 (red, membrane) and FoxP3 (blue, nucleus). The merged imaged allows for identification of individual cell types: the combination of nuclear blue Foxp3 and surface green CD3 staining (white arrow) indicates the presence of CD3+CD8-Foxp3+ T cells. The green arrow indicates a CD3+CD8-Foxp3- T cell, and the red arrow points at CD3+CD8+ T cells. (B) Staining with H&E, CD68 (green, cytoplasm/membrane), and CD163 (red, cytoplasm/membrane). The merged image shows double-positive M2 type macrophages cells. The scale bar of immunofluorescence images is 20 µm, and of H&E images is 50 µm. [Figure re-used from Cao et al. 2017 with permission.[200]]

Table 5. Studies reporting on immune infiltrate in CoM. The separation between early and later work is based on the development of immunohistochemical staining techniques.

Study	n=	Infiltrate (cell type and technique)	Presence of infiltrate	Relation with Characteristics	Relation with Survival
"early work"					
Jay, 1965.[208]	73	(no methods or cell types specified)	none n=13 (18%) few n=17 (23%) moderate n=26 (36%) numerous n=17 (23%)	No data reported	No sign. relation with survival
Crawford, 1980.[209]	19	(H&E) "most were lymphocytes"	no cells at base: 0 (0%) few at base: 6 (32%) moderate at part of base: 4 (21%) moderate at whole base: 6 (32%) intense at whole base: 3 (16%)	No data reported	Presence has better survival.
McGhee, 1982.[212]	28	(no methods or cell types specified)	mild: 19 (68%) moderate: 7 (25%) severe: 2 (7%)	No data reported	No relation with survival
Folberg, 1985.[211]	98	(no methods or cell types specified)	[**First lesion**] lack=47%, present=53%	No data reported	No sign. relation with survival
		(no methods or cell types specified)	[**Thickest lesion**] lack=51%, present=49%	No data reported	Presence has better survival.
Jeffrey, 1986.[213]	37	(H&E)	Not reported	No data reported	No relation with survival
Bobic-Radovanovic, 1998.[214]	61	(no methods or cell types specified)	Not reported	No data reported	Univariate: no relation with survival. Multivariate: presence has better survival
"later work"					
Anastassiou, 2004.[215]	32	(IHC) CD3+	No: 6 (19%), few: 14 (44%) mod: 10 (31%), strong: 2 (6%)	No data reported	No relation with survival

Table 5. Continued

Study	n=	Infiltrate (cell type and technique)	Presence of infiltrate	Relation with Characteristics	Relation with Survival
	34	(IHC) CD68+	No: 1 (3%), few: 12 (35%) mod: 15 (44%), strong: 6 (18%)	No data reported	No relation with survival
Tuomaala, 2007.[216]	60	(H&E) Lymphocytes	Few: 27 (45%) Moderate: 17 (28%) Many: 16 (27%).	More in limbal, thinner lesions.	No relation with rec/survival.
	58	CD68+ macrophages	Few: 7 (12%) Moderate: 24 (41%) Many: 27 (47%)	No relation with location/thickness	No relation with rec/survival.
Cao, 2017.[200]	27	Immuno-fluorescence, (median [range])	CD3: 151 [71–637] CD3+CD8+: 68 [26–335] CD3+CD8-: 70 [26–314] CD3+CD8-Foxp3-: 44 [13–202] CD3+CD8-Foxp3+: 30 [10–124]	CD8+: more in thinner and smaller LBD CD8- (mainly Foxp3-) more in epibulbar lesions	No relation with rec/survival.
		Immuno-fluorescence, (median [range])	CD68: 59 [19–248] CD68CD163: 39 [8–220]	M2: more in thinner lesions	No relation with rec/survival.
Lasalle, 2020.[219]	60	IHC CD8+	No: 6 (10%) <5%: 20 (33%), 5-50%: 26 (43%) >50%: 8 (13%)	More in non-epithelioid cell types, non-bulbar location	No relation with rec/survival.

Abbreviations: Rec, recurrences; M2, M2-type macrophages; H&E, haemotoxylin and eosin; IHC, immunohistochemistry.

UV radiation was found to influence the immune infiltrate in cutaneous melanoma lesions, by recruiting macrophages and neutrophils.[81,82] This is relevant for CoM as parts of the conjunctiva are sun-exposed. Macrophages have pro-angiogenic effects that are relevant for tumour dissemination. These effects include an increased IFN-gamma signalling, with upregulation of CCL8.[82] Even so, neutrophils stimulate angiogenesis and promote migration of melanoma cells towards blood vessels.[81]

Many concepts from tumour immunology have been contrasted between extraocular melanoma and intraocular UM. In the latter, the presence of inflammatory cells is known to be unfavourable for many decades.[225,226] By this remarkable position, UM provides an example of immunologic *failure* to destroy tumour cells, elucidating mechanisms of tumour escape that are relevant to other tumours as well. As such, alterations in HLA and PD-L1 expression are very relevant to CoM and are discussed in sections 4.3 and 4.4.

Similarities between extra-ocular melanoma and UM are seen in the role of (pro-inflammatory) macrophages and (immune suppressing) Tregs. The presence of both CD68+ and CD163+ cells is related to unfavourable features in UM as monosomy 3, ciliary body involvement, greater LBD, and worse survival.[227-229] Even so TAMs are related to a higher vascular density.[167,201,228] FoxP3+ cells (Tregs) were identified relatively recently in UM,[227] and while the prognostic significance needs further study, the presence of intratumoural Tregs has been related to a poorer clinical outcome[230] similar to what is seen in cutaneous melanoma.

Recent work shows that UM with increased numbers of CD8+ cells, increasingly express immune checkpoint inhibitors 'Indolamine 2,3-Dioxygenase 1' (IDO1) and 'T cell immunoreceptor with Ig and ITIM domains' (TIGIT) (which limit the efficacy of CTLs to kill tumour cells).[231] This may explain the opposite effects of TIL presence on survival in UM and other melanomas. The expression of these checkpoints in CoM is unknown, but may be relevant in cases that fail to respond against immunotherapy. Even so, Fas Ligand is a suppressor of immune activity and being expressed in conjunctival epithelium,[232] may contribute to CoM resistance against new therapies.

Discussing the infiltrate in CoM

Despite a limited number of studies on CoM, several conclusions can be drawn regarding the role of the immune infiltrate (Table 6). As such, immune cells appear to be favourable: in early reports on CoM an association was established between the presence of immune cells and a favourable prognosis.[209,211,214] The specific roles for subtypes of the infiltrate need to be elucidated however, as later studies, examining the specific presence of T cells or macrophages, failed to confirm an association with survival.[200,215,216] Two recent works (by Tuomaala and Cao) identified an inverse relation between lymphocytes and tumour thickness (a known unfavourable factor), but did not see the same relation with macrophages. These findings in CoM largely mirror those of cutaneous

melanoma where infiltrating lymphocytes correspond with a favourable prognosis (and thin lesions). Interestingly, an immune infiltrate in cutaneous melanoma has especially prognostic significance in vertical growth phase and thick lesions. CoM apparently behaves more as a vertical-growth phase cutaneous melanoma than as a radial growth phase tumour. Though little data is available for other mucosal melanoma, findings are similar to those in CoM, as in oral mucosal melanoma the absence of TILs was related to more metastases (but not to worse survival).[233]

The role of TILs in CoM, and cutaneous melanoma, is clearly different from the role in intraocular UM, where their presence is associated with a worse prognosis. Interestingly, the presence of TILs is often positively correlated with the presence of TAMs: this has been reported for CoM,[200] cutaneous melanoma,[203] and UM.[227] In UM, the presence of both cell types is prognostically unfavourable, while in cutaneous melanoma they appear to have opposing effects. The mild or absent relations between infiltrate and prognosis in cutaneous melanoma and CoM may therefore be explained, as the different cell types counteract each other. Another important issue may be that inhibitory forces (from Tregs or immune checkpoints) are more pronounced in intra-ocular than extra-ocular melanoma, explaining why the prognostic role of infiltrate is less in cutaneous melanoma and CoM.

Future projects could analyse the infiltrate in CoM with larger sample sizes, to compare findings from cutaneous melanoma with more statistical power. The role of macrophages should be unveiled, together with its influence on angiogenesis and development of lymphatic vessels (which is of major importance for metastases). Translating important lessons from UM research, the inhibitory aspects of checkpoint inhibition, expression of mechanisms as IDO and TIGIT, and the role of Tregs deserve attention. The presence of immune cells cannot be considered a binary event, with varying and even opposing roles for various cell types, and understanding this is a requirement before clinical steps may be undertaken, as to select patients for T cell-based immunotherapies.

Table 6. Overview of the effects of infiltrate in different types of melanoma.

	Conjunctival Melanoma		**Cutaneous Melanoma**		**Uveal Melanoma**	
Presence of:	**Clinical characteristics**	**Prognosis**	**Clinical characteristics**	**Prognosis**	**Clinical characteristics**	**Prognosis**
TILs	Good	Good/NS	Good	Good	Bad	Bad/NS
TAMs	NS	NS	Bad	Bad	Bad	Bad

Abbreviations: TIL, tumour infiltrating lymphocyte; TAM, tumour associated macrophage; NS, not significant.

HLA expression

The HLA system

The *human leukocyte antigen* system (HLA, the human counterpart of the *major histocompatibility complex* (MHC)) comprises a class of molecules with a major role in immunology. Two main types of HLA are identified: HLA Class I and HLA Class II. The *HLA Class I molecule* consists of two polypeptide chains: the non-polymorphic light b2-microglobulin (B2M) chain (encoded on chromosome 15), and the highly polymorphic heavy alpha chain (encoded by the *HLA* gene on chromosome 6p21).[234] Different types of the HLA Class I molecules are HLA-A, HLA-B and HLA-C. HLA Class I proteins are expressed on (almost) all nucleated cells. Their function is to present peptides from intracellular proteins and invasive viruses to the T cell receptor of CD8+ killer T cells. Also, HLA Class I inhibits NK cell activity.[235] *HLA Class II molecules* have a different structure with an alpha and beta chain (both encoded on chromosome 6). Major variants are HLA-DM/DO/DP/DQ/DR. HLA Class II is mainly present on immune cells, such as B cells, some T cells, and antigen-presenting cells (APCs). It can be upregulated on other cells during inflammation. Its function is to present peptides from outside the cell, and to interact with CD4+ T helper cells.[235] Some HLA alleles, as HLA-B27, are strongly related to the development of specific diseases.[236]

In cancer research, HLA Class I has received much attention for its role in mediating interactions between tumour cells and T cells. Loss of HLA Class I (which can either be reversible ("soft") or irreversible ("hard"))[237] is a mechanism to escape immune surveillance, and has been associated with worse survival in many malignancies, including cutaneous melanoma.[238] IFN-gamma can upregulate HLA Class I expression and therefore may restore the susceptibility of tumour cells to be lysed by T cells. However, counterbalancing mechanisms exist as NK cells on their turn are being activated by the absence of HLA Class I.[207]

Expression of HLA Class I on CoM

HLA Class I expression in CoM was studied by Cao et al. in 23 samples using immunofluorescence.[239] A marked positive expression was observed for HLA-A, HLA-B/C or B2M in a third of lesions, which is less than seen in cutaneous melanoma.[240]

The level of expression of HLA Class I in CoM was not related to the tumour's basal diameter, development of recurrences or metastases, or survival. There was a correlation with prognostic factors however, as epibulbar/T1 CoM had a higher HLA Class I expression, and thicker CoM had a lower expression of HLA Class I. An increased expression of HLA Class I was associated with a higher number of CD68+CD163+ macrophages, and tended to be so with CD8+ lymphocytes, even in this small series; this suggests that macrophages and T cells play a role in stimulating HLA Class I expression in CoM, similar to the situation in UM.[241] In vitro work on three CoM cell

lines demonstrated that addition of IFN gamma indeed caused upregulation of HLA Class I and of its transcriptional regulators CIITA, IRF1, NLRC5, and the *Transporters associated with Antigen Processing* TAP1 and TAP2.[239]

It is not yet known whether the low expression of HLA Class I in CoM is due to mutations, loss of heterozygosity (LOH) in chromosomes 6 or 15, epigenetic downregulation, or prior immune selection that led to outgrowth of HLA Class I negative tumour cells.[242] A study of CoM-derived cell lines showed that at least two of three cells lines contained a hard loss of HLA antigens: cell line CRMM1 had lost its HLA-A2 cell surface expression and cell line CRMM2 its HLA-B44 expression.[239]

The relatively recent findings on HLA expression in CoM are in line with earlier studies from cutaneous melanoma. Expression of HLA Class I and TAP1 and 2 is associated with decreased lesion thickness,[238,243,244] and a longer time to disease progression and longer survival.[238] Even so, metastases have a lower HLA Class I expression compared to primary lesions,[238,244,245] and HLA expression is favorably associated with tumour regression.[246]

HLA expression may be of a different phenotype in metastases compared to primary lesions due to selective outgrowth, and the expression on metastases may become resistant to upregulation due to mutations in the IFN pathway.[247]

Recent work shows that HLA I expression relates to survival after checkpoint inhibition in advanced melanoma patients: homozygosity of at least one allele and LOH are related to worse survival (with less variation to present tumour antigens), and while the presence of an HLA-B44 allele was related to significantly better survival after checkpoint inhibition, presence of an HLA-B62 allele was related to reduced survival. This can have implications for the design of future trials,[248] including for potential studies on CoM.

The role of tumour infiltrate on HLA expression can be demonstrated by a comparison between CoM and UM. In UM, a high HLA Class I expression is similarly associated with the presence of both leukocytes and macrophages (CD3, CD4, CD8, CD11B, CD68),[231,241,249] but it is associated with *unfavourable* tumour characteristics, such as monosomy 3 and *decreased* prognosis.[229,249] This led to the hypothesis that NK cells are specifically important for tumour surveillance in UM,[250,251] while CTLs are more important in cutaneous and conjunctival melanoma. This is supported by findings that NK cells are more effective in killing HLA-negative cells in the blood compared to in lymphoid vessels,[247] which fits the metastasis pattern of both UM and CoM.

Discussing HLA expression in CoM

Few projects focused on HLA expression in CoM, but the available data suggest that HLA expression is associated with favourable tumour traits, and that expression is increased in the presence of an immune infiltrate. These concepts are in line with work from cutaneous melanoma, and to some extent with UM. Understanding HLA expression in CoM is important as it underlies the efficacy of T cell-mediated therapy. Downregulation of HLA Class I can limit this efficacy, and HLA expression may therefore be a selection criterion for therapy in patients, as advised by Cao.[239] Even so, upregulation of HLA may be a part of future therapies to enhance the efficacy of immunotherapy. It should be studied whether subtypes of HLA respond differently to T cell-mediated therapy in CoM, as can be expected from work on cutaneous melanoma.

PD-1/PD-L1 expression

Immune checkpoints

The interaction between CTLs and tumour cells is influenced by various stimuli, including the checkpoint pathways. One of the major checkpoint pathways acts via PD-1/PD-L1. PD-1 is a glycoprotein that is expressed on activated T cells and that can bind to its ligand PD-L1 on the surface of tumour cells and macrophages. The PD1/PD-L1 interaction results in several inhibitory events within T cells, including inhibition of cytokine and enzyme production, and inducing stagnation of cell cycle or even apoptosis. This prevents T cells from targeting the tumour cell (Figure 8).[252] Other ligands for PD-1 exist, such as PD-L2, but these are beyond the scope of this manuscript.

Blockade of the PD-1/PD-L1 interaction is the underlying mechanism of anti-PD-1/PD-L1 therapies. In advanced cutaneous melanoma, anti PD-1 therapy has proven successful, with nivolumab treatment showing a better overall survival (OS) and progression-free survival (PFS) than chemotherapy (dacarbazine).[23] Both nivolumab[253] and pembrolizumab[197] monotherapy (both against PD-1) provide a better response (with a higher overall survival and progression-free survival) compared to the original checkpoint inhibitor ipilimumab (anti-CTLA4).

The CTLA-4 protein is another negative regulator of T cells (Figure 8).[254] Its function is based on the fact that T cells require more than one stimulatory signal to be activated. CTLA4 is expressed on T cells, and competes with CD28 molecules to bind B7, which is their shared ligand. CTLA4 has a greater affinity for the ligand however, and while a CD28-to-B7 binding would lead to *increased* T cell activity, a CTLA4-to-B7 binding does not cause activation and may even cause *inhibition* of the cell. The full mechanism is not fully understood however, and is likely more complex, involving for instance CTLA4-mediated activation of Tregs. To explain checkpoint inhibition in CoM, we will focus on the PD-1/PD-L1 interaction.

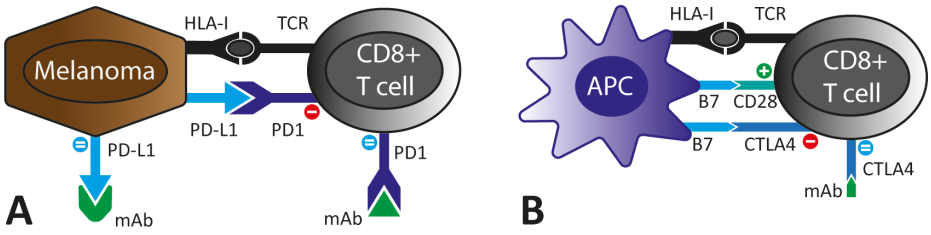

Figure 8. Checkpoints in tumour immunology. (A) CTLs interact with melanoma cells via HLA Class I molecules. Downregulation of HLA Class I causes CTL failure to recognize melanoma cells. Binding of PD-1 to its ligand PD-L1 causes inactivation of T cells, reducing the tumour killing capacity. Monoclonal antibodies against PD-1 or PD-L1 prevents the inactivating signal, resulting in undisturbed T cell activation. (B) T cells require co-stimulation apart from signalling via the TCR. Binding of B7 to CD28 causes activation, while binding of B7 to CTLA4 causes reduced signalling or even inactivation of T cells. Monoclonal antibodies against CTLA4 prevent the inactivating signal, resulting in undisturbed T cell activation. Abbreviations: TCR, T cell receptor; HLA-I, HLA Class I molecule; mAb, monoclonal antibody; APC, antigen presenting cell.

Predictive value of PD-L1 expression for treatment response

Tumour cells can express variable levels of PD-L1. One would expect that the level of PD-L1 expression on tumour cells is a marker to predict response against specific (invasive) checkpoint inhibitors, since it is the blocking of this exact PD-1/PD-L1 axis that underlies the mechanism of action. Various studies on advanced cutaneous melanoma indeed observed better response rates to checkpoint inhibitors and longer survival in patients with PD-L1 positive tumour cells compared to PD-L1 negative lesions: this was reported for pembrolizumab (anti-PD1),[255] nivolumab (anti-PD1),[23] ipilimumab (anti-CTLA4) and nivolumab + ipilimumab combination therapy.[256] Even so, a melanoma type with little PD-L1 expression (UM)[257,258] shows little response to checkpoint inhibitor therapy.[24] However, in cutaneous melanoma many patients with PD-L1 negative lesions also responded favourably to these treatments: while 53% of patients with PD-L1 positive lesions had an objective response to nivolumab treatment, also 33% of patients with PD-L1 negative lesions had a response, providing survival benefit compared to chemotherapy for PD-L1 negative lesions as well.[23] It has been suggested that not only PD-L1 expression on tumour cells is relevant to therapy, but also the expression on cells in the tumour microenvironment.[259]

Adding to the debate on the usefulness of PD-L1 assessment, there is concern about the sensitivity of specific immunohistochemistry staining tests for PD-L1, with different scoring systems and cut-off levels being used between studies.[260] In addition, PD-L1 expression may vary over time.[261]

PD-L1 expression in CoM

Only a few studies analysed expression of checkpoint inhibitors in CoM. An early study on PD-L1 expression in mucosal melanoma of the head and neck, observed positive PD-L1 in 3/23 cases; the three cases of CoM that were included in this set were all negative.[262] All nine samples of cutaneous melanoma that were used as control were PD-L1 positive.

Cao et al. studied PD-L1 expression in 27 cases of CoM (Figure 9).[200] Using a cut-off of 5% of cells, PD-L1 was expressed on tumour cells in 5 (19%) cases, and on stromal cells in 16 (59%) cases (Fig 4.3). Stromal expression mainly involved M2 macrophages. PD-L1 expression on tumour cells was associated with more metastasis and disease-specific death, studied in a cohort with a median follow up time of 46 months.

Recent work on 65 CoM confirmed that PD-L1 is expressed more often on immune cells (58%) than on tumour cells (10%), and that PD-L1 expression on CoM is associated with worse survival at a median follow-up time of 29 months; however, expression results varied between two applied IHC antibodies.[219]

The reported PD-L1 expression on CoM tumour cells (up to 19%)[200,219] is somewhat less than reported in cutaneous melanoma (30-35%)[23,263]. A large study on cutaneous melanoma reported a somewhat lower level of PD-L1 positive expression (24% of cases), but in a fairly large number of cases (11%), no status could be determined so the actual expression may be different.[253] PD-L1 expression on CoM is higher than on other mucosal melanoma (sino-nasal, vaginal, rectal).[90] Importantly, the cut-off for deeming a sample positive has a major influence on the reported numbers: one study reported PD-L1 expression in 76% of cutaneous melanoma samples, but used a cut-off of only 1% of cells expressing PD-L1.[255]

PD-1 expression has not been identified on CoM tumour cells, but is expressed on T cells in 17 (63%)[200] and 15 (23%)[219] of cases. In both studies, no significant relation with patient outcome was established, but Cao reported a trend between PD-1 expression and a higher number of recurrences.

IFN-gamma is known to enhance PD-L1/PD-1 expression in cutaneous melanoma.[263] In vitro analysis by flow cytometry of three CoM cell lines (CRMM1, CRMM2, CM2005.1) demonstrated no background expression of PD-L1, while one cell line (CRMM2) showed expression of PD-1. Addition of IFN-gamma induced upregulation of HLA Class I (used as control) in all three cell lines, with two lines showing an increase in the expression of PD-L1 (CRMM2 and CM2005.1), and one of PD-1 (CRMM2). These findings show that IFN-gamma, produced by tumour-infiltrating lymphocytes (TILs), may be responsible for enhancing PD-L1 expression in CoM.[200] This is similar to findings in cutaneous melanoma.[263]

A limitation to studies regarding PD-L1 in CoM is the small size of tissue samples. PD-L1 expression can be quite heterogenous within samples[264] and it is not known how a small sample represents the PD-L1 status of the tumour as a whole.[200] Since cutaneous melanoma patients with PD-L1 positive as well as negative tumours may respond favourably to anti-PD-1 treatment, this may not so much be a selection criteria for treatment per se (and negative staining should not prohibit CoM patients from entering trials).[255] Even so, combining checkpoint inhibition with other interventions such as radiotherapy may be beneficial, as is currently attempted in UM.[9]

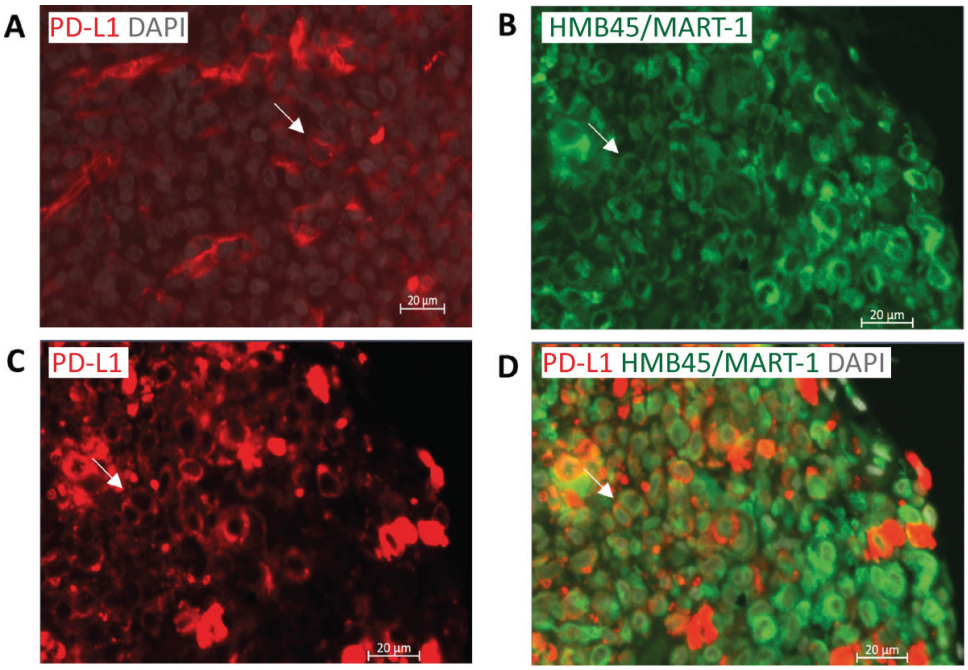

Figure 9. PD-L1 expression in CoM. (A) Membranous PD-L1 staining (red) is demonstrated in a positive control (human tonsil tissue). (B) Staining with HMB45/MART-1 (green, cytoplasmic/membranous) allows for identification of tumour cells. (C) PD-L1 (red, membranous) is expressed in the studied tissue. (D) Double staining shows that PD-L1 is expressed on CoM tumour cells. [Figure re-used from Cao et al., 2017 with permission.[200]]

Discussing PD-L1 expression in CoM

The expression of PD-L1 in CoM seems to mirror the findings of cutaneous melanoma, though somewhat lower percentages of expression have been reported. Whether PD-L1 expression has prognostic value or is a therapeutic indicator in CoM has not yet been established, but it can be expected that larger studies would identify this, as is seen in cutaneous melanoma. The relevance of this predictive effect may be similarly limited however, as PD-L1 negative CoM may still respond

to immunotherapy. Prior to initiation of larger translational studies in CoM, it may be needed to overcome technical issues such as the difficulty of obtaining representative PD-L1 expression results from small tissue samples.

Novel approaches regarding checkpoint inhibition in cutaneous melanoma include the combination with radiotherapy[265] or photodynamic therapy in preclinical models.[266] As radiotherapy has been well-established in CoM, this may be readily-transferable to CoM as well.

Conclusions (Immunology)

Similar to the situation in cutaneous melanoma, the presence of an immune infiltrate is favourable in CoM. Questions remain on the exact role of all cell types of the immune infiltrate, and regarding the role of inhibitory forces such as those of T-regs. It is as yet unknown how infiltrating macrophages relate to (lymph and blood) vessel development in CoM, which may provide a possible dissemination route for metastases. Even more, expression of IDO and TIGIT (relevant in *intra* ocular melanoma as an escape from the immune system) may have relevance in the conjunctiva, but this is currently unknown.

HLA expression is common in CoM, and as expected by its role in interaction with immune cells, has a relation with favourable traits. Downregulation may limit the efficacy of T cell-based therapies, while upregulation may enhance the susceptibility to immunological clearance. Screening for HLA expression, or the presence of specific alleles, may become part of patient workup prior to immunotherapy in CoM.

Like cutaneous melanoma, CoM is known to frequently express PD-L1. The prognostic and predictive value is limited however, as in cutaneous melanoma even negative lesions could respond to anti-PD-L1 therapy. It is a promising target for therapy, possibly in combination with other treatments such as photodynamic therapy or radiotherapy.

5. TARGETED THERAPY AND CHECKPOING INHIBITOR THERAPY IN COM

Current therapy of localised and metastatic CoM

Tumour location and extent are currently the main determinants for therapy in CoM. Localised disease is commonly treated by surgical excision using a 'no touch technique' and adjuvant therapy.[11] Adjuvant therapy includes cryotherapy (with a "double freeze-thaw" technique[267]), topical chemotherapy (such as mitomycin-c drops[268] or interferon-alfa[269]), and / or radiotherapy. For radiotherapy several techniques exist of external radiotherapy or brachytherapy using plaque or handheld applicators).[270,271] Treatment of palpebral lesions may be more complex, as this site is

more difficult to approach, and adjuvant brachytherapy can only be delivered via adapted 'outward' applicators.[272] Widespread lesions require a more extensive approach, with extensive surgery, radiotherapy,[273] and ultimately even orbital exenteration.[11]

The approach to adjuvant therapy varies between institutions, as no data supports superiority of either, and availability differs.[11,274,275] Most authors include cryotherapy to conjunctival margins by default, as part of the surgical procedure presented by Shields et al.;[267] for corneal involvement, alcohol epitheliectomy is performed. Additional adjuvant therapy may be reserved for cases with incomplete resection, with concurrent PAM, or for recurrences, but others advise to use it for all.[276] Radiotherapy is well-accepted for incomplete margins, topical chemotherapy can be applied for concurrent (and widespread) PAM.[13,275]

Importantly, patients have a better prognosis if initial treatment is delivered in a centre with expertise in ocular oncology (preventing delay and possible inappropriate or incomplete resection), calling for general ophthalmologists to swiftly refer patients with a suspicious conjunctival lesion.[13,71]

CoM may disseminate to lymph nodes (regional) as well as systemic sites (distant). Most often dissemination involves the parotid (pre-auricular), cervical and submandibular lymph nodes, and the lungs, liver, brain and skin, respectively.[12,277] In CoM, the lymph nodes are often believed to be the first site of metastasis; systemic metastases may develop independently as well.[13,277] While lymph metastases are important in CoM and cutaneous melanoma, this differs from UM since the uvea lacks lymphatic drainage. The sentinel lymph node biopsy (SLNB) is a technique to detect micro-metastases in the first node(s) that are theoretically reached by disseminating tumour cells. If detected, adjuvant therapy can be administered, and a lymphadenectomy can be performed, preventing further spread.[278] There is debate on the position of SLNB in CoM management,[279] however with new therapeutic options for metastatic disease, the clinical relevance is rising and the SLNB is performed more frequently.

There is currently no standard therapy for metastatic CoM.[280] Most often, guidelines from cutaneous melanoma are followed, e.g. as presented in the European guideline for melanoma.[281] In patients with few metastases, or those at specific accessible locations, selective surgical metastatectomy or radiotherapy can be applied. In widely disseminated disease, systemic agents are required. Up till a few years ago, cytotoxic chemotherapy was the only available option, which was associated with poor response rates and survival benefit. In the management of cutaneous melanoma, newly-developed immunotherapy and targeted therapy (as will be discussed later on) have substituted these agents as first line therapy, leaving conventional chemotherapy as a last-resort option after failure, or in those cases where (more expensive) other treatments are not available.

Targeted therapy in CoM

'Targeted therapy' or 'small molecule inhibitors' involves drugs that target genetic mutations and (upregulated) pathways that are related to malignancies, and that are absent in healthy tissues. It has been suggested to use cutaneous melanoma therapies for CoM.

Since 2013, the use of targeted therapies has been reported for a small number of CoM. We are not aware of clinical trials or large cohorts that are formally studying these drugs in CoM, and therefore resort to small series, single case reports and preliminary in vitro work. The aim for systemic targeted therapy in CoM is mainly 1) to treat widespread local disease, that is too large for excision, or as an alternative for orbital exenteration, or 2) to treat regional and distant metastases.

In this section, we will discuss patient-related outcomes of several MAPK-pathway-inhibitors in CoM, and present several new drugs with a suggested potential based on preclinical work or similarities to cutaneous melanoma.

BRAF and MEK inhibitors

The MAPK pathway can be inhibited by drugs targeting *BRAF* and MEK. Inhibitors of *BRAF* are the most well-established targeted therapy drug type in cutaneous melanoma (Table 7). First reports on single-agent therapy demonstrated survival benefit for vemurafenib (trade name: Zelboraf, Hoffmann-La Roche[283]) versus dacarbazine chemotherapy in metastatic disease in previously untreated cutaneous melanoma patients with a *BRAF* V600E mutation.[19] Later, other inhibitors were introduced as well (i.e. dabrafenib (trade name: Tafinlar, Novartis[282]), and recently encorafenib (trade name: Braftovi, Array Biopharma[284]).

Table 7. BRAF and MEK inhibitors.

	Generic name	Brand name	Dosing and route*	FDA reference
BRAF inhibitors	dabrafenib	Tafinlar	150 mg, twice daily oral	FDA, 2013.[282]
	vemurafenib	Zelboraf	960 mg, twice daily oral	FDA, 2011.[283]
	encorafenib	Braftovi	450 mg, once daily oral**	FDA, 2018.[284]
MEK inhibitors	trametinib	Mekinist	2 mg, once daily oral	FDA, 2013.[285]
	cobimetinib	Cotellic	60 mg, once daily oral	FDA, 2020.[286]
	binimetinib	Mektovi	45 mg, twice daily oral**	FDA, 2018.[287]

Abbreviations: FDA, Food and Drug Administration.
** Dosing as indicated for (metastatic) melanoma, for other indications please read product information.*
*** Encorafenib and binimetinib are indicated for combined use.*

A common issue with *BRAF* inhibition is the development of treatment resistance, that often occurs within a year. This can be due to several mechanisms such as upregulation of *NRAS,*[288] NF1,[289] or ERK,[290] and downregulation of PTEN;[291] it has recently been linked to upregulation of other pathways such as YAP1[292,293] and even PD-L1,[294] providing escape from immune cells. Combining *BRAF* and MEK inhibition is a solution to overcome this resistance, and combination therapy demonstrated prolonged survival over *BRAF* monotherapy in cutaneous melanoma: vemurafenib (*BRAF* inhibitor) and cobimetinib (MEK inhibitor; trade name: Cotellic, Genentech[286]) were superior versus vemurafenib alone.[295] A similar result was reported when dabrafenib (BRAF inhibitor) and trametinib (MEK inhibitor; trade name: Mekinist, Novartis[285]) were combined versus dabrafenib alone[296] or versus vemurafenib alone[297]. Recently, binimetinib (trade name: Mektovi, Array Biopharma[287]) has been introduced as well.

While clinical outcomes regarding *BRAF* and MEK inhibition in CoM have been reported [section 5.2.2.], preclinical work continues to optimize treatment by e.g. analysing combined pathway inhibition. In vitro work on three CoM cell lines by Cao et al tested the mutation-specific effect of two *BRAF* inhibitors and a MEK inhibitor.[121] The two *BRAF* inhibitors (vemurafenib and dabrafenib) inhibited growth of cell lines CRMM1 and CM2005 (both harbouring a *BRAF* mutation) although not with the same sensitivity. This could not be explained by *PTEN* loss (which was not found in any of the cell lines). Both drugs caused paradoxical activation of the MAPK pathway in a third cell line, CRMM2 (with an *NRAS* mutation, no *BRAF* mutation); an effect that was later confirmed by El Zaoui et al.[123] Cao et al showed that MEK inhibition had an inhibitory effect on all three cell lines, and that combined inhibition of MEK and AKT even showed synergistic effects.[121]

Reported cases of targeted therapy in CoM.

BRAF and MEK inhibitors are (similar to the situation in cutaneous melanoma) the most well-studied small molecule inhibitors in CoM. We have been able to find the reports on seven CoM patients who received treatment with a *BRAF* inhibitor (Table 8). It is likely that more patients have been treated, however, but not reported. In one case, treatment of the conjunctival lesion was the sole aim, in a patient who was free of lymph- or distant metastases.[298] This patient had a recurrence of CoM that would otherwise have been treated with orbital exenteration. There was a good response to vemurafenib, with tumour decrease and a stable situation for 3 years. The six other reported patients with targeted therapy had metastatic disease. As a response to the landmark paper by Griewank et al on the prevalence of *BRAF* mutations in CoM,[17] Weber et al. noticed that a patient with a *BRAF* V600E mutation and several distant metastases, developed only a mild response to vemurafenib monotherapy (with progression after 2 months).[299] They suggested that *BRAF* inhibitors may not be successful in CoM as in cutaneous melanoma, possibly due to frequent *PTEN* loss in CoM, which may have contributed to treatment resistance. Griewank replied by reporting a patient who was treated with dabrafenib for metastases and who had a partial response with a significant 62% tumour reduction; this patient, however, developed new lesions after 6

months.[300] A similar case was reported by Maleka et al.: a patient with metastatic CoM was treated with vemurafenib, and initially had a good response with metastases reduction; however, after 4 months, re-appearance of lesions occurred, with death shortly thereafter.[301] Notably, this patient had been treated with several other therapies, including a gene trial with AdCD40L, cyclophosphamide and radiotherapy for brain metastases, questioning the role of each individual therapy to the overall response. A promising report was delivered by Pinto Torres et al. on a CoM patient with metastatic lesions who received vemurafenib and had a complete response during the 3 years of follow up.[302]

Similar to what is seen in cutaneous melanoma, *BRAF* inhibitors have been combined with MEK inhibitors to overcome the issue of resistance in CoM. Two cases of treatment for lymph node metastases have been reported; however, there are limitations to the interpretation. One patient received dabrafenib and trametinib with a good response, being alive 1 year later.[303] Though promising, a longer follow up time would be preferred to assess the effect of the combination therapy. The other patient received dabrafenib and trametinib, with good response, but needed a switch to vemurafenib monotherapy after 1.5 months due to the development of adverse events (i.e. nausea and vomiting).[304] Progressive disease then caused a further switch to pembrolizumab (an immune checkpoint inhibitor), and vemurafenib again. Addition of cobimetinib to the vemurafenib was required to obtain a good response. Though this case resulted eventually in disease control, therapy was complex and adverse events were a major issue.

Table 8. Overview of reported cases on targeted therapy in CoM.

Study	Patient	Type of CoM	Type and Dosage Immunotherapy	Other Treatments	Clinical Outcome	Adverse Events
Indicated for primary CoM						
Pahlitzsch, 2014.[298]	F, 80y	Recurrence. No metastases. *BRAF* muta (exon 15).	Indic: pt preferred non-exenteration R: vemurafenib [no dose]	Prior: exc (incomplete), Plaque brachytherapy Later: resection	Good response, tumour decrease, stable for 3yr. Then deterioration general health. [death not mentioned]	Weight loss, nausea, vomiting, headache
Indicated for metastatic disease						
Weber, 2013.[299]	M, 45y	Metastatic CoM (subcutaneous, lung, bone) *BRAF* muta (v600e).	Indic: unresectable metastases R: vemurafenib 960mg 2dd	Prior CoM: resection Prior Mets: none	Initially good response, but after 2months progression. [death not mentioned]	Not reported
Griewank, 2013.[300]	M, 43y	Metastatic CoM (intramuscular, lung, brain) *BRAF* not reported.	Indic/ unresectable metastases R: dabrafenib [no dose]	Prior CoM: resection, Ruth, PBI. Prior Mets: dacarbazine chemo	PR. 62% tumour reduction. After 6months new lesions. [death not mentioned]	Not reported
Maleka, 2016.[301]	F, 53y	Metastatic CoM (orbit, parotid gland, lung, brain) *BRAF* muta (v600e)	Indic: unresectable metastases R: vemurafenib 960mg 2dd; later 720mg 2dd due to AE.	Prior CoM: resection, cryo, mmc, enucleation. Prior Mets: Temozolomide, AdCD40L with cyclophosphamide, Brain radiotherapy.	Initially good response, reduction of metastases. After 4 months, re-appearance of metastases and death.	Skin rash
Pinto Torres, 2017.[302]	F, 59y	Metastatic CoM (Oropharyngeal wall) *BRAF* muta (v600e)	Indic: unresectable metastases R: vemurafenib 960mg 2dd; later 480mg 2dd due to AE.	Prior CoM: exc, Prior Mets: radiotherapy 20Gy/5fractions	CR. No recur in 3yr later. Developed breast cancer.	Arthralgia, diarrhea, skin rash

Table 8. Continued.

Study	Patient	Type of CoM	Type and Dosage Immunotherapy	Other Treatments	Clinical Outcome	Adverse Events
Combined therapy						
Dagi Glass, 2017.[304]	F, 61y	Recurrent CoM Lymph metastases. *BRAF* muta (v600e)	Indic: alternative to extensive surgery R: 1) dabrafenib + trametinib; 2) vemurafenib (due to AE); 3) pembrolizumab (due to progression); 4) vemurafenib + cobimetinib (due to progression)	Prior CoM: excision, cryo Prior Lymph mets: parotidectomy and neck dissection	1: good for 1.5 months, then AE. 2-3: mixed, not complete. 4: eventually good response. [death not mentioned]	1: nausea, vomiting 2-4: not reported.
Rossi, 2019.[303]	M, 70y	Metastatic CoM (lymph) *BRAF* muta (v600e)	Indic: unresectable metastases R: dabrafenib 150mg 2dd + trametinib 2mg 1dd	Prior CoM: excision Prior lymph mets: parotidectomy and neck dissection	Good response, 1yr later. Alive.	Fever, Hyper-transaminasemia

Abbreviations: CoM,conjunctival melanoma; pembro, pembrolizumab; ipi,ipilimumab; nivo,nivolumab; PR, partial response; CR, complete response; exent, orbital exenteration; exc,excision; cryo,cryotherapy; mmc,mytomicin-c; SLNB,sentinel lymph node biopsy; M,male; F, female; AE, adverse event; met, metastasis; muta, mutation; Indic:, indication; R:,drug prescription.

Adverse events following BRAF/MEK inhibitors

Adverse events (AE) following targeted therapy proved common in cutaneous melanoma patients, with the occurrence of any AE in over 90% of all patients following *BRAF* inhibitors or combined *BRAF*/MEK inhibitor treatment (Table 9).[296]

AEs of *BRAF* inhibition in cutaneous melanoma patients were most commonly arthralgia, rash, photosensitivity, alopecia, fatigue, or diarrhoea.[19,20,296] AEs are comparable between vemurafenib and dabrafenib monotherapy, but some differences are observed, as photosensitivity is seen more often with vemurafenib but pyrexia and chills are more common with dabrafenib. Addition of a MEK inhibitor to a *BRAF* inhibitor slightly alters the AE profile. Most AEs occur more frequently following combination therapy.

A noticeable AE that raised concern following introduction of vemurafenib was the development of cutaneous squamous cell carcinoma (SCC).[19] The proposed mechanism is that *BRAF* inhibitors accelerate the progression of subclinical cancerous lesions; addition of a MEK inhibitor reduces this effect, resulting in the observation that patients with combined BRAF/MEK inhibitor treatment less often develop SCC than those on *BRAF* inhibitor alone.

The management of most adverse events requires dose reduction or switch to another drug type, however, in advanced grades additional topical or systemic therapy is needed.[305]

An ocular complication that may occur following *BRAF*/MEK inhibition is serous retinopathy (including edema and retinal detachment). This has been reported in 4% of vemurafenib, and 27% of vemurafenib + cobimetinib combination patients.[20]

The observed AEs in the sparse reports of targeted therapy in CoM are in line with the earlier reports on cutaneous melanoma. Development of rash urged a vemurafenib dose reduction in one patient,[301] and development of arthralgia, diarrhoea, and rash caused vemurafenib dose reduction in another.[302] One patient who was on dabrafenib plus trametinib developed nausea and vomiting that urged a switch to another drug.[304] Of note, since similar dosing schemes of targeted therapy are used for CoM as well for cutaneous melanoma, similar adverse events would be expected.

Table 9. Occurrence of most common adverse events (AE) following targeted therapy in cutaneous melanoma patients. (Note: less-frequently occurring AEs were omitted in this table, see the original reports for full details)

	Vemurafenib*		**Vemurafenib + Cobimetinib***		**Dabrafenib****		**Dabrafenib + Trametinib****	
	Any grade (%)	**≥ 3 (%)**	**Any grade (%)**	**≥ 3 (%)**	**Any grade (%)**	**≥ 3 (%)**	**Any grade (%)**	**≥ 3 (%)**
Any AE					96	34	95	32
Diarrhea	33	1	61	7	14	1	24	1
Fatigue	33	3	37	5	35	1	35	2
Rash	68	16	73	17	22	1	23	0
Nausea	26	1	43	1	26	1	30	0
Vomiting					14	1	20	1
Arthralgia	42	5	38	3	27	0	24	1
Pyrexia	24	0	29	1	28	2	51	6
Alopecia	33	1	17	1	26	0	7	0
Headache					29	1	30	1
Cutaneous SCC	13	13	4	4	9	4 #	2	2 #
Keratoacanthoma	9	9	2	1				

Abbreviations: AE, Adverse event. SCC, squamous cell carcinoma.
**Phase III trial, study group vemurafenib n=246, cobimetinib+vemurafenib n=247.*[20]
***Phase III trial, study group dabrafenib n=211, dabrafenib+trametinib n=209.*[296]
#SCC and keratoacanthoma combined.

Preclinical targets

Apart from the relatively well-established *BRAF* and MEK inhibitors that have been implemented already on a small scale in the treatment of CoM, several newer drugs can be suggested for CoM, based on small scale patient-related studies from cutaneous melanoma, and preclinical assessment using CoM models. Development of these drugs is important to overcome the issue of treatment resistance, and to properly target all tumours regardless of their mutational background.

Preclinical assessment of drugs is often performed using cell lines. To our knowledge, only a few CoM cell lines exist, harbouring either a *BRAF* or *NRAS* mutation (Table 10). To examine the potential efficacy of drugs in the full range of CoM, it would be interesting to develop cell lines with various combinations of *BRAF/NRAS* and other mutations such as *PTEN*, *NF1,* and *TERT*.

Table 10. Conjunctival melanoma cell lines.

Cell line	BRAF mutation	NRAS mutation	Other mutations	Reference
CRMM1	V600E	WT		Nareyeck, 2005.[306]
CRMM2	WT	Q61L		Nareyeck, 2005.[306]
CM2005.1	V600E	WT		Keijser, 2007.[307]
T1527A	G466E	WT	HRAS Q61R	El Zaoui, 2019.[123]

Abbreviations: WT, wildtype.

c-KIT inhibition

KIT inhibition is currently best known for the treatment of gastrointestinal stromal tumours (GIST) using imatinib. In GIST, about 75% of lesions harbour a *KIT* mutation, explaining the sensitivity to this drug.[308] The c-KIT inhibitor imatinib showed a response rate of 16 to 29% in phase II studies of metastatic (cutaneous) melanoma harbouring *KIT* alterations.[309-311] The alteration type is very relevant, as metastatic patients with a *KIT* mutation showed a response rate of 54%, while those with *KIT* amplification showed a response rate of 0%.[311] Since *KIT* mutations are rare in CoM, imatinib (or other drugs with *KIT* inhibitory effects, such as sunitinib, dasatinib and nilotinib that are currently all in phase 2 studies in melanoma)[114] will likely not be suitable for large scale use in CoM. With proper screening for mutation status, however, they can be part of a successful personalized treatment.

ERK1/2 inhibition

ERK (consisting of the kinases ERK1 and ERK2) is a distal actor in the MAPK pathway (Figure 6). Reactivation can be seen with resistance of upstream MAPK inhibition, and as such it is an important target to overcome *BRAF*-inhibitor resistance.[290] ERK1/2 can be inhibited by ulixertinib (BVD-523), a drug that showed potential in preclinical melanoma models,[312] and that showed an acceptable safety profile and evidence of activity in solid tumours including melanoma in a phase I study.[313] In that work, 9/19 patients with *BRAF*-mutated melanoma had a partial response (PR) or stable disease following failed *BRAF* inhibition; 9/17 patients with *NRAS*-mutated melanoma had PR or stable disease as well. To our knowledge, ulixertinib has not yet been evaluated in CoM. It is promising however that both *BRAF* and *NRAS* mutated lesions seem to be responding, suggesting a role as rescue medication.

PI3K/AKT/mTOR

The PI3K/AKT/mTOR pathway has an important role in melanoma, acting alongside MAPK (Figure 6). Targeting can be of specific use in *BRAF*-WT or *BRAF*-inhibitor-resistant melanoma. The therapeutic potential follows increased activity in CoM compared to conjunctival nevi,[123] and also in CoM compared to UM.[148]

Cell proliferation of three CoM cell lines (harbouring either a *BRAF* or *NRAS* mutation) could be inhibited by AKT inhibition using MK2206.[121] Using cell lines, the most promising effect was obtained by combining MK2206 (AKT inhibitor) with MEK162 (MEK inhibitor), that caused a stronger cell cycle arrest compared to single-agent treatment.

Another study using the same cell lines found that the PI3K inhibitor pictilisib was more effective than the dual PI3K/mTOR inhibitor dactolisib.[123] The genetic background of the cell lines was important however: both pictilisib and dactolisib were active against CRMM1 (*BRAF* mutation), pictilisib alone was effective against CRMM2 (*NRAS* mutation), and none were effective against T1527A, a cell line lacking *BRAF* V600E and *NRAS* mutations (Table 10).

The results from CoM are in line with earlier reports on cutaneous melanoma cell lines: in *NRAS*-mutated cell lines, cells were more sensitive to MEK inhibition than to PI3K/mTOR inhibition alone, but combined inhibition was superior.[314] However, there are some troublesome reports of PI3K/AKT inhibition in melanoma patients: trametinib (MEK inhibitor) and GSK2141795 (AKT inhibitor) combined had no response in 10 *NRAS*-mutated and 10 *BRAF*-WT + *NRAS*-WT melanoma (including 3 UM) and therapy was not well tolerated.[315]

TERT

The abundance of *TERT* mutations in CoM poses an opportunity for treatment. Reverse transcriptase inhibitors, e.g. azidothymidine, can target *TERT* mutated tumours by targeting reverse transcriptase activity.[316] Other approaches include a telomerase inhibitor, such as Imetelstat (GRN163L).[115] These drugs have not been studied in CoM however, but show promising results in vitro and in early stage patient studies of several cancers.

EZH2

Epigenetics concern processes that alter gene expression and regulation, without involving changes in the DNA sequence itself. The polycomb repressive complex 2 (PRC2) is involved in many of these epigenetic processes, with the 'enhancer of zeste homolog 2' (EZH2) as a core subunit of PRC2, that is overexpressed in several cancers.[317] EZH2 causes silencing of (tumour suppressor) genes, and is frequently overexpressed in cutaneous melanoma, but not in cutaneous nevi, indicating a role in tumour progression with potential as a therapeutic target.[318]

Cao et al. found that EZH2 is not expressed on melanocytes of normal conjunctiva or PAM, but was expressed in 13/26 CoM lesions and 7/8 lymph node metastases.[319] Just as in skin lesions, this implies a role for EZH2 in malignant transformation. EZH2 expression in CoM was significantly related to older age, larger tumour thickness and worse overall survival. Using two EZH2 inhibitors,

GSK503 and UNC1999, cell growth of three CoM cell lines (CRMM1, CRMM2 and CM2005.1) as well as tumour growth in a zebrafish model could be repressed. While, as far as we know, EZH2 inhibition has not been studied in CoM patients, there may be a potential therapeutic benefit.

Checkpoint inhibitor therapy in CoM

Checkpoint inhibitors

The first approved checkpoint inhibitor for advanced cutaneous melanoma was ipilimumab, a monoclonal antibody against CTLA4 (Yervoy, Bristol-Myers Squibb) (Table 11). Ipilimumab showed improved survival compared to treatment with gp100 in unresectable stage III or IV cutaneous melanoma patients (overall survival 10.1 months versus 6.4 months).[22] Ipilimumab, combined with dacarbazine chemotherapy, also provided a significantly longer overall survival compared to dacarbazine with placebo (overall survival 11.2 months versus 9.1 months).[320] In 2014, two new drugs targeting PD1 were introduced: nivolumab (Opdivo, Bristol-Myers Squibb) and pembrolizumab (Keytruda, Merck Sharp & Dohme).

Pembrolizumab (administered at both two or three week intervals) gave a better survival compared to ipilimumab, with a 6-month PFS of approximately 47% for pembrolizumab, and 27% for ipilimumab.[197] In advanced cutaneous melanoma patients, who had progressed after ipilimumab or ipilimumab plus a *BRAF*-inhibitor, nivolumab demonstrated a better response than chemotherapy (32% versus 11%).[321] Nivolumab had also a better overall survival and progression-free survival than dacarbazine in untreated advanced melanoma patients lacking a *BRAF* mutation; with nivolumab, the 1-year overall survival went from 42.1 to 72.9%, the median progression-free survival from 2.2 months to 5.1 months.[23]

Since CTLA4 and PD-1 act on T cells via different mechanisms (Figure 8), there is a rationale to combine blockade therapy. Indeed, combining nivolumab and ipilimumab led to better survival (progression-free survival of 11.5 months) than either of the therapies alone (6.9 months for nivolumab, 2.9 months for ipilimumab) in advanced cutaneous melanoma patients.[253]

Checkpoint inhibitors have been used to treat a limited number of patients with locally advanced or metastatic CoM. In the absence of formal trials, the current literature consists of single-case reports and small case-series (Table 12). First treatments were administered around 2013,[26,322] but the first reports on checkpoint inhibitors in CoM appeared in the literature from 2017 onwards.[302,323,324] The use of checkpoint inhibitors in CoM follows the same basic principles and similar dosing schemes as in locally-advanced or metastatic cutaneous melanoma, as described in the FDA reports on ipilimumab (trade name: Yervoy),[325] pembrolizumab (trade name: Keytruda),[326] and nivolumab (trade name: Opdivo).[327] Drugs targeting PD-1 (pembrolizumab, nivolumab) as well as

drugs targeting CTLA4 (ipilimumab) have been used in CoM, as single-agent as well as in various combinations. Due to different aims of therapy, the findings for patients who were treated for a primary CoM or for metastatic disease, will be discussed separately.

Table 11. Checkpoint inhibitors.

	Generic name	Brand name	Dosing and route*	FDA reference
Anti-CTLA4	ipilimumab	Yervoy	3 mg/kg iv, every 3 weeks	FDA, 2020.[325]
Anti-PD-1	nivolumab	Opdivo	240 mg iv, every 2 weeks (or 480 mg every 4 weeks)	FDA, 2020.[327]
	pembrolizumab	Keytruda	200 mg iv, every 3 weeks	FDA, 2020.[326]

Abbreviation: FDA, Food and Drug Administration; iv, intravenously.
**dosing as indicated for (metastatic) melanoma, for other indications please read product information.*

Primary CoM

In several cases, immune checkpoint inhibitors have been used as treatment for primary CoM (Table 12, cases 1-5). In four cases, immunotherapy was offered as alternative to orbital exenteration for patients who refused eye-removing therapy; in one case, treatment was for an extensive lesion with an insufficient response to prior local therapy.

The first reported patient (M, 60) received pembrolizumab single-agent therapy and had an immediate good response, with flattening of a nodular recurrence at 6 months.[323] A similar favourable response to pembrolizumab single therapy was seen for an extensive in-situ lesion (F, 53).[27]

The third patient (F, 94), reported initial progression with pembrolizumab single-agent therapy, but had a partial response with pembrolizumab + ipilimumab combination therapy. This patient died 5 months later from an unrelated cause.[322]

In two patients, a successful response was reported for the third attempted scheme of therapy, which included addition of topical IFN-alfa. One of these patients (M, 76) had no response to ipilimumab single-agent therapy, a minimal response to pembrolizumab single-agent therapy, but a complete response following pembrolizumab + topical IFN-alfa drops.[322] The second patient (F, 84) had minimal success after pembrolizumab single-agent therapy, showed progression with pembrolizumab + ipilimumab, but stable disease with pembrolizumab + ipilimumab + IFN-alfa topical treatment.[322]

Finger noted that local IFN-alfa seemed to synergize the effect of PD-L1 inhibition.[322] IFN-alfa on itself has been used longer to treat malignancies (with a small survival benefit in cutaneous

melanoma patients),[328] and also ocular malignancies, including ocular surface squamous neoplasia (OSSN)[329,330] and CoM[331,332]. IFN-alfa is known to stimulate immune reactions, with upregulation of HLA molecules, promotion of NK cell activity and activation of CD8+ T cells, making it a candidate for co-treatment with anti-PD-1 and anti-CTLA4 in cancer.[333-335] In a one-armed phase 1b/2 study on pegylated-IFN-alfa and pembrolizumab in 43 mucosal and cutaneous melanoma, an improved response rate compared to the expected rate was found for pembrolizumab alone;[336] however, this study needs further evaluation. As Cao showed, PD-L1 and PD1 could be upregulated on CoM cell lines through IFN-gamma.[200] It may well be that the same happens under the influence of IFN-alfa, providing a good target for checkpoint inhibition.

Metastatic CoM

In twelve reported cases, immunotherapy has been administered to CoM patients with metastatic disease (Table 12, cases 6-17). Eight patients had systemic metastases, one patient had regional (lymph node) metastases, and three patients had both. In three patients, treatment of metastases as well as local tumour control was attempted at the same time.

Five CoM patients received nivolumab single-agent treatment.[26,337] All had a good response, although in one case (M, 71; systemic metastases; *BRAF* V600E mutated) this treatment was supplemented with dabrafenib, trametinib and radiotherapy, hampering the conclusions on the individual effect of nivolumab.[337] One patient, with systemic and lymph node metastases, received pembrolizumab single-agent therapy, with a near to complete resolution.[302] Another patient, with multifocal CoM and lymph node metastases, received ipilimumab as a single therapy [after tumour debulking and brachytherapy, and lymph node dissection] and had excellent local control and no new lymphatic or systemic metastases.[338]

Four patients received more than one type of checkpoint inhibitor.[26,27,322,339] One patient, with systemic and lymph node metastases, received both ipilimumab and nivolumab. There was a reduction of the systemic tumour burden, and the patient survived at least 3 years.[322]

In three patients, there was a switch to other drugs due to treatment failure, or development of adverse events. In the first patient with systemic metastases, ipilimumab + nivolumab combination therapy induced hepatitis, causing a switch to nivolumab alone. This treatment with nivolumab, however, induced an infusion reaction, necessitating a switch to pembrolizumab, which was followed by a favourable response with stable disease for 2 years.[339] Interestingly, the response to this anti-PD-1 drug was favourable, while PD-L1 expression of the primary CoM was negative.

The second patient, who initially had stable disease for 6 months with pembrolizumab, eventually showed progression. Ipilimumab (with dacarbazine) caused a partial response, but had to be discontinued due to the development of hepatotoxicity.[26]

In the third patient, who was initially treated with ipilimumab single-agent therapy, a new lymph node metastasis developed. After another round of ipilimumab, the patient later developed skin metastases. A third treatment with pembrolizumab was started, and no new developments were reported in the 2 years thereafter.[322]

Discussing the cases on checkpoint inhibitor therapy in CoM

All of the 17 currently-reported cases (both with primary as well as metastatic CoM) eventually developed a favourable response to checkpoint inhibition. Unfortunately, little is known about the reasons for initial treatment failure in some of the cases. In only one patient, the PD-L1 status of the tumour was known, which was negative, and this patient experienced a good response to PD-1 blockade.[339] More studies into the patient characteristics are needed to learn about these mechanisms and the predictive value of checkpoint expression. With the small numbers, and various different treatment regimens, it is impossible to conclude on the superiority of any of the checkpoint inhibitors in CoM. It may be expected however, as in cutaneous melanoma, that PD-1 blockade is more effective than blockade of CTLA4, and that a combined blockade of PD-1 and CTLA4 may yield even better results.[253,256]

While the current reports are promising, it may be that other (unsuccessful) cases did not end up in the literature, skewing the results for CoM to a favourable outcome. We concur with the statement of Sagiv et al. of the group of Dr. Esmaeli that "our observations are so far cautiously optimistic".[26] Immunotherapy can be considered promising for CoM patients who need additional treatment to local therapy, or who develop metastatic disease, and is well-justified in those needy cases.

Adverse events following checkpoint inhibitor therapy

Checkpoint inhibitors allow T cells to respond against tumour cells, but can equally cause an increased T cell-response against normal tissues. These unwanted events are known as immune-related adverse effects (irAEs) and can be severe. Part of the pathophysiology can be an increased number of activated CD4+ and CD8+ T cells, as was detected in peripheral blood of cutaneous melanoma patients following ipilimumab treatment.[340]

Table 12. Overview of reported cases on checkpoint inhibitor therapy in CoM.

Study	Patient	Type of CoM	Type and Dosage of Immunotherapy *1	Other Treatments	Clinical Outcome	Adverse Events
Indicated for primary CoM						
Kini, 2017.[323]	M, 60s	Recurrence. Fornix, anterior orbit, limbus.	Indic: Preferred non-exenteration (other eye low vision). R: pembro 150mg iv every 3wks, 1y.	Prior: exc and cryo Later: exc and cryo	Good response. At 6m, nodule was flat. [survival not reported]	No AE.
Finger, 2019.[322]	F, 94	First. Bulbar to eyelid. No metastasis.	Indic: Age, comorbidity, refused exent. R: First: pembro. Second: pembro+ipi *2.	None	Pembro: progression Pembro+ipi: PR. Died after 5m, unrelated. *3	No related AE.
Finger, 2019.[322]	M, 76	Recurrence. Cornea to eyelid. No metastasis. *BRAF*, *KIT*, *NRAS* wt.	Indic: Progression despite chemo R: First: ipi. Second: pembro. Third: pembro+IFN-alfa drops *4	Prior: multiple local treatments incl IFN-alfa drops.	Ipi: no response Pembro: minimal response, but complete with IFN-alfa. After 36m still CR.	Ipi: adrenal insuff > ipi stop + steroids. Pembro: dermatitis > steroids, antihist
Finger, 2019.[322]	F, 84	Recurrence. Cornea to eyelids. No metastasis.	Indic: Preferred non-exenteration R: First: pembro. Second: pembro+ipi *2. Third: pembro+ipi+IFN-alfa *5	Prior: multiple local therapies incl exc, cryo, mmc, brachytherapy	Pembro: minimal success Pembro+ipi: progression Alive 1,5yr after first pembro	No AE reported
Hong, 2020.[27]	F, 53	First.*6 Bulbar to tarsal. No metastasis.	Indic: Preferred non-exenteration R: pembro	Prior: none Later: mmc	CR, after 12m near complete reduction of pigment. Disease free 12m of follow up.	Cutaneous pruritus

Table 12. Continued.

Study	Patient	Type of CoM	Type and Dosage of Immunotherapy *1	Other Treatments	Clinical Outcome	Adverse Events
Indicated for metastatic disease						
Sagiv, 2018.[26]	F, 68	Recurrent CoM. 2yr after last: syst mets to lung. *BRAFneg.*	Indic: systemic metastases R: First: pembro. Second: ipi+dacarb *7	Prior CoMs: exc, mmc, exent, 30Gy orbit radiotherapy, SLNB, parotidectomy.	Pembro: Stable at 6m, then progression. Ipi+dacarb: PR Alive at time of writing.	Pembro: No reported. Ipi+dacarb: hepatotox > stop.
Pinto Torres, 2017.[302]	M, 51	Recurrent CoM. *BRAFwt.* mets to lymph+skin	Indic: systemic and lymph node mets R: pembro	Prior CoMs: exc. Lymphadenectomy *Antiviral therapy for HIV.*	Near to CR after 3rd cycle. Survival at least 2yr after diagnosis of mets.	No AE: "good tolerance"
Sagiv, 2018.[26]	F, 58	CoM recurrence to orbit Mets to lung, liver	Indic: orbital and systemic metastases R: nivo	Prior CoMs: excisions, parotidectomy, exent	CR of orbital and meta lesions. Alive at time of writing	Elevated liver enzymes at 3m > nivo stopped.
Sagiv, 2018.[26]*11	F, 28	CoM recurrence After 5yr: mets in breast, lung, bone	Indic: systemic metastases R:nivo	Prior CoM: Exc+cryo+mmc	PR of systemic mets, later CR. Disease free 3yrs after nivo.	No AE reported.
Sagiv, 2018.[26]	F, 47	Recurrent CoM 6.5yr after last CoM: mets to lung	Indic: systemic metastases R: nivo	Prior CoMs: exc, cryo, plaque, parotidectomy, lymphadenectomy, adjuv topical IFN, mmc	Resolution of lung lesions. 7m after nivo stop free from disease	Diarrhea (AI colitis) > nivo stopped, prednison, infliximab

Table 12. Continued.

Study	Patient	Type of CoM	Type and Dosage of Immunotherapy *1	Other Treatments	Clinical Outcome	Adverse Events
Sagiv, 2018.[26]	M, 74	Recurrent CoM 2m after last: lung mets.	Indic: systemic metastases R: nivo	Prior CoMs: excisions. (declined exent)	Decrease in tumour size Disease free 1m after nivo stop	After 11m: ir colitis > nivo stopped, prednisone
Kiyohara, 2020.[337]	M, 71	Recurrent CoM *BRAF* v600e pos mets bone + liver	Indic: systemic metastases R: nivo	Prior CoMs: exc, cryo, enucl, vemurafenib Currently: dabrafenib, trametinib, radiotherapy	Died 24m after combi therapy	No AE reported
Chaves, 2018.[338]	M, 72	First CoM. bulbar to tarsal Lymph nodes pos.	Indic: multifocal CoM + lymph mets R: ipi	This CoM: debulking, brachytherapy, (refused exent). SLNB > dissection	Response, excellent local tumour control. Okay 16m post radioth.	Mild fatigue, ceased after last cycle ipi. *8
Finger, 2019.[322]	F, 72	CoM: Epibulbar *BRAF* v600k mut 9y later: metastases in lung, liver, bone, skin, lymph nodes	Indic: Systemic and lymph metastases R: ipi + nivo *9	CoM: exc + topical chemo. Metas: no other tx	Resolution of the subcutaneous nodules. Reduction of systemic tumour burden. 3yrs survival at least.	Hepatoxicity > treatment delay Colitis > fluids, steroids, infliximab Pneumonitis > steroids, inhalers
Chang, 2019.[339]	F, 60	CoM recurrence *NRAS*mut, BRAFwt, KITwt, PDL1-. Liver metastases	Indic: primary CoM+ syst metastasis. R: First: ipi + nivo *9. Second: nivo *10. Third: pembro	Prior CoMs: Excisions, cryo, SLNBneg (declined orbital radiotherapy)	Ipi/nivo: unknown Pembro: CoM and mets response, stable at 2yr.	ipi/nivo: hepatitis. > switched to nivo. Nivo: infusion reaction > pembro

Table 12. Continued.

Study	Patient	Type of CoM	Type and Dosage of Immunotherapy *1	Other Treatments	Clinical Outcome	Adverse Events
Finger, 2019.[322]	F, 76	First CoM. *NRAS*mut Mult. Lymph mets Skin metastasis	Indic: Lymph and systemic metastasis R: First: ipi. Second: ipi. Third: pembro	CoM: exc, cryo, mmc LN: Parotidectomy, surgery, radiotherapy. Skin Mets: exc, radiation	Ipi: (1.5yr) New lymph mets Ipi: (3yr) skin meta Pembro: alive after 2yr	Ipi: no AE No other AE reported
Hong, 2020.[27]	M, 66	First CoM. Fornix and orbit. Syst mets in lung and liver.	Indic: primary CoM+ syst metastasis. R:ipi+nivo	None reported	Resolution of the conj lesion, nice response of syst mets.	Pituitary failure > replacement hydroxycortisone and thyroxine.

Abbreviations: CoM, conjunctival melanoma; pembro, pembrolizumab; ipi, ipilimumab; nivo, nivolumab; PR, partial response; CR, complete response; exent, orbital exenteration; exc, excision; cryo, cryotherapy; mmc, mytomicin-c; SLNB, sentinel lymph node biopsy; M, male; F, female; AE, adverse event; met, metastasis; Indic, indication; R, drug prescription.

Footnotes:

**1 Unless otherwise reported, standard regimens for immunotherapy were:*
Pembrolizumab: 2mg/kg every 3wks, up to 200mg.
Ipilimumab: 3mg/kg every 3wks (for unresectable/metastatic melanoma)
Nivolumab: 240mg every 2wks (which equals 3mg/kg)
**2 Added dose of ipilimumab: 1mg/kg.*
**3 The patient died due to congestive heart failure.*
**4 Dose of IFN-alfa drops: 1million units/cc, 4 times daily.*
**5 Intralesional IFN-alfa, 3 million units per eyelid, monthly interval.*
**6 The reported diagnosis was 'conjunctival melanoma in situ'.*
**7 Dose of dacarbazine: 800-1000mg/m2, every 3wks*
**8 Other (likely unrelated) AE were: partial lash loss, dry eye, peripheral corneal vascularization, secondary glaucoma and radiation-induced posterior cataract.*
**9 Dose of nivolumab: 1mg/kg every 3wks*
**10 Dose of nivolumab: 240 mg every 2 weeks for 2 cycles and 480 mg every 4 weeks for 1 cycle*
**11 This case was presented earlier as well in a report by Ford et al., 2017.*[324]

Adverse events due to checkpoint inhibitors can affect any organ, but commonly are directed against the skin (pruritus, rash) or gastrointestinal system (diarrhea, colitis), and less frequently the liver or endocrine system (including general fatigue).[22,197,256,321,341] The profile and frequency of irAEs is similar for nivolumab and pembrolizumab (both being anti-PD-1 drugs), while somewhat more common in ipilimumab (as an anti-CTLA4 drug), particularly when combined with nivolumab.[341] Grade 1-2 adverse events of diarrhea, fatigue, pruritus and rash have each been reported in about 20-40% of patients receiving checkpoint inhibition, demonstrating their relatively common occurrence (Table 13). Adverse events of grade 3 or higher were reported in 10% of pembrolizumab-treated patients, 22% of nivolumab, 28% of ipilimumab, and 59% of nivolumab + ipilimumab treated cases with cutaneous melanoma.[197,256]

Some of the adverse events resemble manifestations of auto-immune disease. Checkpoint inhibitors were reported to cause a decrease in pigmentation of the skin (i.e. vitiligo)[342] and even of choroidal nevi in the fundus.[343]

Table 13. Occurrence of most common adverse events (AE) following immunotherapy in (cutaneous) melanoma.

	Nivolumab*	**Ipilimumab***	**Nivo+Ipi***	**Pembrolizumab****
Any 1-2 grade AE	64 %	58 %	37 %	63 %
Any 3-4 grade AE	22 %	28 %	59 %	10 %***
	Grade 1-2 / 3-4	**Grade 1-2 / 3-4**	**Grade 1-2 / 3-4**	**Any grade / 3-5**
Diarrhea	19 % / 3 %	28 % / 6 %	36 % / 9 %	14 % / 1.1 %
Fatigue	36 %/ 1 %	28 % / 1 %	34 % / 4 %	19 % / 0.4 %
Pruritus	22 %/ <1 %	36 % / <1 %	34 % / 2 %	14 % / 0 %
Rash	23 %/ <1 %	21 % / 2 %	27 % / 3 %	13 % / 0 %
Nausea	13 %/ 0 %	16 % / 1 %	26 % / 2 %	11 % / 0.4 %

Abbreviations: AE, adverse event.
**Phase III trial, CheckMate 067 report. Study group nivolumab n=316, ipilimumab n=315, nivo+ipi n=314; Hodi et al.,2018.[256]*
***Phase III trial, KEYNOTE 006 report (with an every 3-week dosing scheme). Study group pembrolizumab n=277;Robert et al., 2015.[197]*
****Any grade 3-5 adverse event.*

As there is only a limited number of reports on checkpoint inhibition in CoM, there are very few reports on AE's in these patients (Table 12). In 6 out of 17 reports, no AE's were reported at all. In the CoM patients who did develop AE's, similar events were noted as in patients receiving immunotherapy for cutaneous melanoma.[197,256] For ipilimumab single-agent therapy, adrenal insufficiency,[322] hepatotoxicity,[26] and fatigue[338] have been reported. With nivolumab single-agent therapy, elevated liver enzymes,[26] diarrhoea,[26] colitis,[26] and an infusion reaction[339] have been

reported. Pembrolizumab single agent therapy may have been the best-tolerated drug, with only one out of 8 patients reporting dermatitis.[322] The combination of ipilimumab + nivolumab led to hepatotoxicity, colitis and pneumonitis,[322] and pituitary failure.[27] The development of reported AE's in CoM patients required discontinuation of therapy, switch to another type of immunotherapy, or additional specific treatments, e.g. with corticosteroids or antihistamines.

Of specific note are the 'ocular irAEs', i.e. adverse events in the ocular region after checkpoint inhibitor treatment for melanoma at any site. Such ocular irAEs have been reported after anti-CTLA4 treatment in 1.3% of patients[344] and after anti-PD1 treatment in 1.6% of patients[345]. Ocular irAEs mostly include uveitis, orbital inflammation, dry eyes, and blurred vision,[344-346] as recently reviewed by Dalvin et al., 2018.[347] Rare events include Vogt-Koyanagi-Harada (VKH) syndrome with serous retinal detachment,[348] or ocular rosacea.[349] Most ocular irAEs can be treated with topical corticosteroids, and only rarely systemic therapy is required.[350] Notably, immune checkpoint inhibition may be associated with site-specific metastases, as remarkable cases of vitreous metastases of cutaneous melanoma were reported.[351,352] Not only ocular oncologists, but also general ophthalmologists should be aware of these events as immunotherapy is increasingly being applied, and it becomes more common for these irAEs to present in an ophthalmological practice.

Conclusions (Targeted therapy and checkpoint inhibitor therapy in CoM)

Conventional therapy of localised CoM relies on surgical excision with adjuvant therapy including cryotherapy, topical chemotherapy and / or radiotherapy. Treatment of extensive disease can be more complex, depending on individual cases. Treatment options for disseminated disease are very limited, and no consensus exists on the optimal approach. It is mainly in extensive and disseminated disease that new therapies are urgently needed. Targeted therapy and immunotherapy have been recently introduced successfully for the treatment of (advanced) cutaneous melanoma, and these therapies can be beneficial to CoM patients as well. Inhibitors of BRAF and MEK act in CoM due to the presence of *BRAF* mutations and activation of the MAPK pathway; a notable benefit is seen in the combination of these two drugs.

Several new targets for therapy are under investigation in CoM, e.g. c-KIT, ERK1/2, PI3K/AKT/mTOR, TERT and EZH2. While the value of such targeted therapies has yet to be determined, these may perhaps not be a cure for all, but should be seen as part of a personalized approach after genetic screening. This can e.g. be beneficial for patients with no *BRAF* mutation (limiting response to current BRAF inhibitors) or when a (rare) *KIT* mutation is present.

Checkpoint inhibitors emphasize similarities in the tumour micro-environment of CoM and that of cutaneous melanoma, while differing greatly from UM. Promising results from anti-CTLA4 and anti-PD-1/PD-L1 antibodies in small series of CoM show that these have a first-line position in

metastatic disease. While testing for expression of checkpoint molecules such as PD-1/PD-L1 could theoretically add to a personalized approach, current predictive values for treatment response are limited and we urge that negative-expressing patients are not excluded.

A secondary effect of the introduction of aforementioned therapies is the renewed interest in the SLNB in CoM. Findings of SLNB can now be followed by a curative intent, and early detection of metastases may improve the benefit of new treatments.

While results of both targeted and checkpoint inhibitor therapy are promising, clinicians should be aware of the specific adverse events and not forget that these can include all organ tracts and can be severe. As in any clinical approach, this should be weighted in the decision for certain treatment.

6. FUTURE DIRECTIONS AND CONCLUSIONS

Future directions

Recent developments in cancer research show that tumour genetics and immunology are promising fields that not only lead to a better understanding of CoM, but also provide new targets for therapy. Future projects are numerous, and illustrate that genetics and immunology are intertwined. A recurrent theme for CoM is to translate knowledge from studies on more abundant cutaneous melanoma. While this may be beneficial to the treatment of CoM (as a rare disease), it should be stressed however that the eye has several unique features and that conjunctiva-specific characteristics must not be overlooked.

Important new work is to further investigate the genetic background of CoM, and to evaluate the impact of genetics on tumour behaviour. This is facilitated by rapidly-developing sequencing techniques. Important questions that need answering are how to differentiate benign from malignant lesions, how to identify the most ominous lesions (with a risk for recurrence or metastasis, warranting extensive treatment and intensive follow-up) and how to select the most suitable therapy for individual patients. The mutational status (of genes such as *BRAF*, *NRAS*, and *TERT*) has proved to be important, and warrants studies into less common genes such as *KIT*. Chromosome status and expression of miRNA showed promising results to differentiate and prognosticate lesions, but require confirmation for further use. Genetics suggest that subgroups of CoM exist with distinct driver mutations and pathway activation.[89] While this parallels the principles learned from cutaneous melanoma it is important to look for CoM-specific groups. Following up on the questions on the development of CoM, differences between e.g. sun-exposed and non-exposed lesions need further evaluation, as well as the role of precursor lesions, melanin pigments and the immune system in melanocyte transformation.

The clinical revolution of recent years was the introduction of targeted therapies (BRAF/MEK inhibitors) and checkpoint inhibitors (anti CTLA4/PD-L1) as treatment of locally-advanced or disseminated CoM. This parallels guidelines from cutaneous melanoma and is likely to be implemented even more as drugs become more available and clinicians learn about their use. A first question is to identify patients who may benefit most from these therapies, or reversely, to match a patient to the optimal therapy. Apart from earlier mentioned tumour genetics, immune parameters as expression of HLA and PD-L1, or presence of immune cells, should be evaluated as biomarkers for a therapeutic response. Current studies show that expression of theoretically-important markers (such as PD-L1) is not a prerequisite for a therapeutic response, however, and that much is to be learned. A second question is how to overcome treatment resistance, which is unfortunately a common event in patients who respond well initially. We advocate to study combinations of *BRAF* inhibitors with not only MEK inhibitors, but also drugs targeting the AKT pathway, and possibly even YAP1.[353] Furthermore, the combination of PD-1/PDL-1 and CTLA4 inhibition should be studied. The addition of immune-stimulating agents such as IFN-alfa may be interesting as promising reports have emerged in the CoM literature; topical IFN-alfa drops are already used for topical treatment of malignant ocular surface disease, and are readily available. Even so, radiotherapy or photodynamic therapy may be added to immunotherapy as an enhancer of the immune system. This may facilitate use of aforementioned drugs in not only metastasized CoM patients, but also local disease.

In addition to earlier mentioned developments, several new drugs and druggable targets are under investigation in preclinical studies for CoM or in cutaneous melanoma. New drugs target cKIT, ERK1/2, PI3K-AKT, TERT, and EZH2. Some rely on specific (rare) mutations, suggesting that these are suitable for individualized therapy, or as last-resort, but with unknown value for the majority of patients. By the rarity of CoM it is not feasible to evaluate all of these targets in CoM itself, so data may need extrapolation from other tumour types. Screening in CoM models is warranted prior to introduction in clinical studies, however, to prevent the pursuit of inappropriate targets. The plethora of new drugs poses an additional question, however, to determine which combination of (targeted and immuno-) therapy is optimal, and whether simultaneous or sequential treatment should be applied.

For targeted therapy and checkpoint inhibitor therapy, evidence on their potential benefit is solid enough to advise inclusion of (metastatic) CoM patients in trials. The earlier-mentioned lack of proper biomarkers would argue for liberal inclusion criteria. The rarity of CoM calls for international collaboration to obtain sufficient numbers, and to include CoM patients in trials of cutaneous (and when applicable, mucosal) melanoma. A separate registry should be advised however, to prevent loss of CoM specific data.

A concurrent development with the introduction of therapies for metastatic CoM, is the increased use of screening methods for (lymph node) metastases such as with the SLNB. There is debate on its position in CoM,[279] but the SLNB is being implemented more frequently, and has been suggested as an addition to the current AJCC staging system for its prognostic value.[14] It is likely that advanced staging becomes routine practice for CoM, in which not only tumours are better characterized, but (lymph node) metastases as well.

Conclusions

From an ophthalmological perspective, CoM is a remarkable melanoma: it is very different from the far more prevalent UM (often referred to as 'ocular melanoma'), and much more resembles cutaneous and mucosal melanoma in its biology. The genetic background of CoM is characterized by mutations in *BRAF, NRAS, NF1, and TERT* and it has a complex karyotype with various aberrations. Genetic studies confirm that UV radiation contributes to CoM development, suggesting differences between sun-exposed and non-exposed conjunctiva, but little is yet known about the relation between clinical (tumour) characteristics and genetic profile. The relation between CoM and the tumour micro-environment is being unravelled, with a favourable role for the presence of immune cells and expression of HLA molecules, and an unfavourable role for expression of checkpoint molecules such as PD-L1.

New therapies that became available for cutaneous melanoma in recent years, show promising results in CoM. Targeted therapy (such as BRAF and MEK inhibitors) and checkpoint inhibitors (such as anti-CTLA4 and anti-PDL1 drugs) are an extension to the toolbox of clinicians who currently rely on excision and topical adjuvant therapy for localized disease, while options for treatment of disseminated disease are limited. While the major advancement of new therapies may be in the treatment of metastatic CoM, new therapies can be used to prevent mutilating extensive surgery for advanced primary CoM as well. As a side effect, better staging and screening methods (such as with a SLNB) are gaining popularity, now that they can be followed by therapeutic measures. Treatment resistance remains a major issue of the new drugs, however, so the search continues for combinations of drugs targeting separate (parts of) pathways. It is to be determined what the optimal sequence or combination of targeted and checkpoint inhibition should be.

It is expected that genetic and immunologic typing becomes regular practice in the management of CoM, for prognostication, and identification of patients for specific therapies. We strongly advocate international collaborations to study this rare disease, and the inclusion of CoM patients in cutaneous melanoma trials, with proper registries to allow for a separate evaluation of data.

Competing interests: No conflicting relationship exists for any author.
Funding: This work was supported by the following foundations: Leiden University Medical Center (MD/PhD program grant, NJB), and European Commission (Horizon 2020 grant number 667787, NJB, MJJ). The funding organizations had no role in the design or conduct of the study; collection, management, analysis, and interpretation of the data; preparation, review, or approval of the manuscript; and decision to submit the manuscript for publication.
Financial disclosures: No financial disclosure exists for any author.
Acknowledgements: The authors like to thank Dr. Demetrios G. Vavvas (Massachusetts Eye and Ear Infirmary, Boston, USA) for his contribution to the section on melanoma incidence and tissue size (section 2.4).

REFERENCES

1. Tuomaala S, Eskelin S, Tarkkanen A, Kivela T. Population-based assessment of clinical characteristics predicting outcome of conjunctival melanoma in whites. *Invest Ophthalmol Vis Sci.* 2002;43(11):3399-3408.
2. Yu GP, Hu DN, McCormick S, Finger PT. Conjunctival melanoma: is it increasing in the United States? *Am J Ophthalmol.* 2003;135(6):800-806.
3. Triay E, Bergman L, Nilsson B, All-Ericsson C, Seregard S. Time trends in the incidence of conjunctival melanoma in Sweden. *Br J Ophthalmol.* 2009;93(11):1524-1528.
4. Isager P, Osterlind A, Engholm G, et al. Uveal and conjunctival malignant melanoma in Denmark, 1943-97: incidence and validation study. *Ophthalmic Epidemiol.* 2005;12(4):223-232.
5. McLaughlin CC, Wu XC, Jemal A, et al. Incidence of noncutaneous melanomas in the U.S. *Cancer.* 2005;103(5):1000-1007.
6. Shields CL, Markowitz JS, Belinsky I, et al. Conjunctival melanoma: outcomes based on tumor origin in 382 consecutive cases. *Ophthalmology.* 2011;118(2):389-395 e381-382.
7. Rodrigues M, Koning L, Coupland SE, et al. So Close, yet so Far: Discrepancies between Uveal and Other Melanomas. A Position Paper from UM Cure 2020. *Cancers (Basel).* 2019;11(7).
8. Mikkelsen LH, Larsen AC, von Buchwald C, et al. Mucosal malignant melanoma - a clinical, oncological, pathological and genetic survey. *Apmis.* 2016;124(6):475-486.
9. Jager MJ, Shields CL, Cebulla CM, et al. Uveal melanoma. *Nat Rev Dis Primers.* 2020;6(1):24.
10. Smit KN, Jager MJ, de Klein A, Kili E. Uveal melanoma: Towards a molecular understanding. *Prog Retin Eye Res.* 2019:100800.
11. Wong JR, Nanji AA, Galor A, Karp CL. Management of conjunctival malignant melanoma: a review and update. *Expert Rev Ophthalmol.* 2014;9(3):185-204.
12. Missotten GS, Keijser S, De Keizer RJ, De Wolff-Rouendaal D. Conjunctival melanoma in the Netherlands: a nationwide study. *Invest Ophthalmol Vis Sci.* 2005;46(1):75-82.
13. Brouwer NJ, Marinkovic M, van Duinen SG, et al. Treatment of conjunctival melanoma in a Dutch referral centre. *Br J Ophthalmol.* 2018;102(9):1277-1282.
14. Esmaeli B, Rubin ML, Xu S, et al. Greater Tumor Thickness, Ulceration, and Positive Sentinel Lymph Node Are Associated With Worse Prognosis in Patients With Conjunctival Melanoma: Implications for Future AJCC Classifications. *Am J Surg Pathol.* 2019;43(12):1701-1710.
15. Brouwer NJ, Marinkovic M, Luyten GPM, Shields CL, Jager MJ. Lack of tumour pigmentation in conjunctival melanoma is associated with light iris colour and worse prognosis. *Br J Ophthalmol.* 2019;103(3):332-337.
16. Larsen AC, Dahmcke CM, Dahl C, et al. A Retrospective Review of Conjunctival Melanoma Presentation, Treatment, and Outcome and an Investigation of Features Associated With BRAF Mutations. *JAMA Ophthalmol.* 2015;133(11):1295-1303.
17. Griewank KG, Westekemper H, Murali R, et al. Conjunctival melanomas harbor BRAF and NRAS mutations and copy number changes similar to cutaneous and mucosal melanomas. *Clin Cancer Res.* 2013;19(12):3143-3152.
18. Griewank KG, Murali R, Schilling B, et al. TERT promoter mutations in ocular melanoma distinguish between conjunctival and uveal tumours. *Br J Cancer.* 2013;109(2):497-501.
19. Chapman PB, Hauschild A, Robert C, et al. Improved survival with vemurafenib in melanoma with BRAF V600E mutation. *N Engl J Med.* 2011;364(26):2507-2516.
20. Ascierto PA, McArthur GA, Dréno B, et al. Cobimetinib combined with vemurafenib in advanced BRAF(V600)-mutant melanoma (coBRIM): updated efficacy results from a randomised, double-blind, phase 3 trial. *Lancet Oncol.* 2016;17(9):1248-1260.

21. Esmaeli B, Sagiv O. Targeted Biological Drugs and Immune Check Point Inhibitors for Locally Advanced or Metastatic Cancers of the Conjunctiva, Eyelid, and Orbit. *International Ophthalmology Clinics.* 2019;59(2):13-26.
22. Hodi FS, O'Day SJ, McDermott DF, et al. Improved survival with ipilimumab in patients with metastatic melanoma. *N Engl J Med.* 2010;363(8):711-723.
23. Robert C, Long GV, Brady B, et al. Nivolumab in previously untreated melanoma without BRAF mutation. *N Engl J Med.* 2015;372(4):320-330.
24. Heppt MV, Steeb T, Schlager JG, et al. Immune checkpoint blockade for unresectable or metastatic uveal melanoma: A systematic review. *Cancer Treat Rev.* 2017;60:44-52.
25. Niederkorn JY. Immune escape mechanisms of intraocular tumors. *Prog Retin Eye Res.* 2009;28(5):329-347.
26. Sagiv O, Thakar SD, Kandl TJ, et al. Immunotherapy With Programmed Cell Death 1 Inhibitors for 5 Patients With Conjunctival Melanoma. *JAMA Ophthalmol.* 2018;136(11):1236-1241.
27. Hong BY-B, Ford JR, Glitza IC, et al. Immune Checkpoint Inhibitor Therapy as an Eye-Preserving Treatment for Locally Advanced Conjunctival Melanoma. *Ophthalmic Plastic & Reconstructive Surgery.* 2020;Publish Ahead of Print.
28. Virgili G, Parravano M, Gatta G, et al. Incidence and Survival of Patients With Conjunctival Melanoma in Europe. *JAMA Ophthalmol.* 2020.
29. Shields CL, Chien JL, Surakiatchanukul T, et al. Conjunctival Tumors: Review of Clinical Features, Risks, Biomarkers, and Outcomes--The 2017 J. Donald M. Gass Lecture. *Asia Pac J Ophthalmol (Phila).* 2017;6(2):109-120.
30. Larsen AC, Dahl C, Dahmcke CM, et al. BRAF mutations in conjunctival melanoma: investigation of incidence, clinicopathological features, prognosis and paired premalignant lesions. *Acta Ophthalmol.* 2016;94(5):463-470.
31. Balzer BWR, Cherepanoff S, Joshua AM, et al. Conjunctival Melanoma in Childhood and Adolescence: A Systematic Review. *Ocul Oncol Pathol.* 2019;5(6):387-395.
32. Ghazawi FM, Darwich R, Le M, et al. Incidence trends of conjunctival malignant melanoma in Canada. *Br J Ophthalmol.* 2019.
33. Statista. European Union: total population from 2010 to 2020. 2020; Available at: https://www.statista.com/statistics/253372/total-population-of-the-european-union-eu. Accessed 09-02-2021.
34. World-Factbook C. CIA World Factbook USA. 2021; Available at: https://www.cia.gov/the-world-factbook/countries/united-states/. Accessed 09-02-2021.
35. Hu DN, Yu G, McCormick SA, Finger PT. Population-based incidence of conjunctival melanoma in various races and ethnic groups and comparison with other melanomas. *Am J Ophthalmol.* 2008;145(3):418-423.
36. Yu GP, Hu DN, McCormick SA. Latitude and incidence of ocular melanoma. *Photochem Photobiol.* 2006;82(6):1621-1626.
37. Lommatzsch PK, Lommatzsch RE, Kirsch I, Fuhrmann P. Therapeutic outcome of patients suffering from malignant melanomas of the conjunctiva. *Br J Ophthalmol.* 1990;74(10):615-619.
38. Park SJ, Oh CM, Kim BW, et al. Nationwide Incidence of Ocular Melanoma in South Korea by Using the National Cancer Registry Database (1999-2011). *Invest Ophthalmol Vis Sci.* 2015;56(8):4719-4724.
39. Vajdic CM, Kricker A, Giblin M, et al. Incidence of ocular melanoma in Australia from 1990 to 1998. *Int J Cancer.* 2003;105(1):117-122.
40. Hu DN, Yu GP, McCormick SA, Schneider S, Finger PT. Population-based incidence of uveal melanoma in various races and ethnic groups. *Am J Ophthalmol.* 2005;140(4):612-617.
41. Virgili G, Gatta G, Ciccolallo L, et al. Incidence of uveal melanoma in Europe. *Ophthalmology.* 2007;114(12):2309-2315.

42. Sheng X, Li S, Chi Z, et al. Prognostic factors for conjunctival melanoma: a study in ethnic Chinese patients. *Br J Ophthalmol.* 2015;99(7):990-996.
43. Zhou C, Wang Y, Jia R, Fan X. Conjunctival Melanoma in Chinese Patients: Local Recurrence, Metastasis, Mortality, and Comparisons With Caucasian Patients. *Invest Ophthalmol Vis Sci.* 2017;58(12):5452-5459.
44. Chen PY, Liao YL, Chu YC, Tsai YJ. Conjunctival melanoma: A 20-year survey in a comprehensive medical center. *J Formos Med Assoc.* 2020.
45. Kikuchi I, Kase S, Ishijima K, Ishida S. Long-term follow-up of conjunctival melanoma treated with topical interferon alpha-2b eye drops as adjunctive therapy following surgical resection. *Graefes Arch Clin Exp Ophthalmol.* 2017;255(11):2271-2276.
46. Lee YJ, Lee C, Kim MK, Khwarg SI, Oh JY. Conjunctival pigmented lesion: Clinicopathological analysis of 85 cases in Korean population. *Sci Rep.* 2019;9(1):18204.
47. Fasina O, Oluwasola OA. Conjunctival melanoma in Southwestern Nigeria: a case series and review of literature. *Int Ophthalmol.* 2018;38(4):1747-1752.
48. Salcedo-Hernandez RA, Luna-Ortiz K, Lino-Silva LS, et al. Conjunctival melanoma: survival analysis in twenty-two Mexican patients. *Arq Bras Oftalmol.* 2014;77(3):155-158.
49. Seregard S, Kock E. Conjunctival malignant melanoma in Sweden 1969-91. *Acta Ophthalmol (Copenh).* 1992;70(3):289-296.
50. Norregaard JC, Gerner N, Jensen OA, Prause JU. Malignant melanoma of the conjunctiva: occurrence and survival following surgery and radiotherapy in a Danish population. *Graefes Arch Clin Exp Ophthalmol.* 1996;234(9):569-572.
51. Mansson-Brahme E, Johansson H, Larsson O, Rutqvist LE, Ringborg U. Trends in incidence of cutaneous malignant melanoma in a Swedish population 1976-1994. *Acta Oncol.* 2002;41(2):138-146.
52. de Vries E, Bray FI, Coebergh JW, Parkin DM. Changing epidemiology of malignant cutaneous melanoma in Europe 1953-1997: rising trends in incidence and mortality but recent stabilizations in western Europe and decreases in Scandinavia. *Int J Cancer.* 2003;107(1):119-126.
53. Bianconi F, Crocetti E, Grisci C, Primieri C, Stracci F. What has changed in the epidemiology of skin melanoma in central Italy during the past 20 years? *Melanoma Res.* 2020;30(4):396-401.
54. Aronow ME, Topham AK, Singh AD. Uveal Melanoma: 5-Year Update on Incidence, Treatment, and Survival (SEER 1973-2013). *Ocul Oncol Pathol.* 2018;4(3):145-151.
55. Ghazawi FM, Darwich R, Le M, et al. Uveal melanoma incidence trends in Canada: a national comprehensive population-based study. *Br J Ophthalmol.* 2019;103(12):1872-1876.
56. Marks R, Motley R. *Common Skin Diseases 18th edition.* CRC Press; 2019.
57. Watsky MA, Jablonski MM, Edelhauser HF. Comparison of conjunctival and corneal surface areas in rabbit and human. *Curr Eye Res.* 1988;7(5):483-486.
58. Algaeed AH, Kozak I. *Clinical Atlas of Ophthalmic Ultrasound.* Springer International Publishing; 2018.
59. Jakobiec FA. Conjunctival Primary Acquired Melanosis: Is It Time for a New Terminology? *Am J Ophthalmol.* 2016;162:3-19 e11.
60. Dalvin LA, Salomão DR, Patel SV. Population-based incidence of conjunctival tumours in Olmsted County, Minnesota. *British Journal of Ophthalmology.* 2018;102(12):1728-1734.
61. Paridaens AD, Minassian DC, McCartney AC, Hungerford JL. Prognostic factors in primary malignant melanoma of the conjunctiva: a clinicopathological study of 256 cases. *Br J Ophthalmol.* 1994;78(4):252-259.
62. Shields JA, Shields CL, Mashayekhi A, et al. Primary acquired melanosis of the conjunctiva: risks for progression to melanoma in 311 eyes. The 2006 Lorenz E. Zimmerman lecture. *Ophthalmology.* 2008;115(3):511-519 e512.

63. Folberg R, McLean IW, Zimmerman LE. Primary acquired melanosis of the conjunctiva. *Hum Pathol.* 1985;16(2):129-135.
64. Damato B, Coupland SE. Conjunctival melanoma and melanosis: a reappraisal of terminology, classification and staging. *Clin Exp Ophthalmol.* 2008;36(8):786-795.
65. Grossniklaus HEe, Eberhart CGe, KivelaM€ TTe, World Health Organization ib, International Agency for Research on Cancer p. *WHO classification of tumours of the eye.* 4th edition. ed: Lyon : International Agency for Research on Cancer; 2018.
66. Milman T, Eiger-Moscovich M, Henry RK, et al. Validation of the Newly Proposed World Health Organization Classification System for Conjunctival Melanocytic Intraepithelial Lesions: A Comparison with the C-MIN and PAM Classification Schemes. *Am J Ophthalmol.* 2020;223:60-74.
67. Anastassiou G, Heiligenhaus A, Bechrakis N, et al. Prognostic value of clinical and histopathological parameters in conjunctival melanomas: a retrospective study. *Br J Ophthalmol.* 2002;86(2):163-167.
68. Shields CL, Alset AE, Boal NS, et al. Conjunctival Tumors in 5002 Cases. Comparative Analysis of Benign versus Malignant Counterparts. The 2016 James D. Allen Lecture. *Am J Ophthalmol.* 2016.
69. Shields CL, Fasiuddin AF, Mashayekhi A, Shields JA. Conjunctival nevi: clinical features and natural course in 410 consecutive patients. *Arch Ophthalmol.* 2004;122(2):167-175.
70. Shields CL, Shields JA. Tumors of the conjunctiva and cornea. *Indian J Ophthalmol.* 2019;67(12):1930-1948.
71. Damato B, Coupland SE. An audit of conjunctival melanoma treatment in Liverpool. *Eye (Lond).* 2009;23(4):801-809.
72. De Wolff-Rouendaal D. Conjunctival melanoma in the Netherlands: a clinico-pathological and follow-up study. *(Thesis).* 1990.
73. De Potter P, Shields CL, Shields JA, Menduke H. Clinical predictive factors for development of recurrence and metastasis in conjunctival melanoma: a review of 68 cases. *Br J Ophthalmol.* 1993;77(10):624-630.
74. Kastelan S, Gverovic Antunica A, Beketic Oreskovic L, et al. Conjunctival Melanoma - Epidemiological Trends and Features. *Pathol Oncol Res.* 2018;24(4):787-796.
75. Shah P, He YY. Molecular regulation of UV-induced DNA repair. *Photochem Photobiol.* 2015;91(2):254-264.
76. Budden T, Bowden NA. The role of altered nucleotide excision repair and UVB-induced DNA damage in melanomagenesis. *Int J Mol Sci.* 2013;14(1):1132-1151.
77. de Gruijl FR. Photocarcinogenesis: UVA vs. UVB radiation. *Skin Pharmacol Appl Skin Physiol.* 2002;15(5):316-320.
78. Premi S, Wallisch S, Mano CM, et al. Photochemistry. Chemiexcitation of melanin derivatives induces DNA photoproducts long after UV exposure. *Science.* 2015;347(6224):842-847.
79. Sliney DH. How light reaches the eye and its components. *Int J Toxicol.* 2002;21(6):501-509.
80. Pleasance ED, Cheetham RK, Stephens PJ, et al. A comprehensive catalogue of somatic mutations from a human cancer genome. *Nature.* 2010;463(7278):191-196.
81. Bald T, Quast T, Landsberg J, et al. Ultraviolet-radiation-induced inflammation promotes angiotropism and metastasis in melanoma. *Nature.* 2014;507(7490):109-113.
82. Zaidi MR, Davis S, Noonan FP, et al. Interferon-γ links ultraviolet radiation to melanomagenesis in mice. *Nature.* 2011;469(7331):548-553.
83. Feldman D, Krishnan AV, Swami S, Giovannucci E, Feldman BJ. The role of vitamin D in reducing cancer risk and progression. *Nat Rev Cancer.* 2014;14(5):342-357.
84. Vajdic CM, Kricker A, Giblin M, et al. Sun exposure predicts risk of ocular melanoma in Australia. *Int J Cancer.* 2002;101(2):175-182.
85. Tucker MA, Goldstein AM. Melanoma etiology: where are we? *Oncogene.* 2003;22(20):3042-3052.

86. El-Shabrawi Y, Radner H, Muellner K, Langmann G, Hoefler G. The role of UV-radiation in the development of conjunctival malignant melanoma. *Acta Ophthalmol Scand.* 1999;77(1):31-32.
87. Rivolta C, Royer-Bertrand B, Rimoldi D, et al. UV light signature in conjunctival melanoma; not only skin should be protected from solar radiation. *J Hum Genet.* 2016;61(4):361-362.
88. Swaminathan SS, Field MG, Sant D, et al. Molecular Characteristics of Conjunctival Melanoma Using Whole-Exome Sequencing. *JAMA Ophthalmol.* 2017;135(12):1434-1437.
89. Cisarova K, Folcher M, El Zaoui I, et al. Genomic and transcriptomic landscape of conjunctival melanoma. *PLoS Genet.* 2020;16(12):e1009201.
90. Mikkelsen LH, Maag E, Andersen MK, et al. The molecular profile of mucosal melanoma. *Melanoma Res.* 2020;30(6):533-542.
91. Johansson PA, Brooks K, Newell F, et al. Whole genome landscapes of uveal melanoma show an ultraviolet radiation signature in iris tumours. *Nat Commun.* 2020;11(1):2408.
92. Craig S, Earnshaw CH, Virós A. Ultraviolet light and melanoma. *The Journal of Pathology.* 2018;244(5):578-585.
93. Curtin JA, Fridlyand J, Kageshita T, et al. Distinct sets of genetic alterations in melanoma. *N Engl J Med.* 2005;353(20):2135-2147.
94. Brouwer NJ, Marinkovic M, Luyten GPM, Shields CL, Jager MJ. Pigmentation of conjunctival melanoma recurrences and outcome. *Graefes Arch Clin Exp Ophthalmol.* 2019;257(8):1783-1788.
95. De Leeuw SM, Smit NP, Van Veldhoven M, et al. Melanin content of cultured human melanocytes and UV-induced cytotoxicity. *J Photochem Photobiol B.* 2001;61(3):106-113.
96. Wakamatsu K, Hu DN, McCormick SA, Ito S. Characterization of melanin in human iridal and choroidal melanocytes from eyes with various colored irides. *Pigment Cell Melanoma Res.* 2008;21(1):97-105.
97. Brenner M, Hearing VJ. The protective role of melanin against UV damage in human skin. *Photochem Photobiol.* 2008;84(3):539-549.
98. Mitra D, Luo X, Morgan A, et al. An ultraviolet-radiation-independent pathway to melanoma carcinogenesis in the red hair/fair skin background. *Nature.* 2012;491(7424):449-453.
99. Kusmartsev S, Nefedova Y, Yoder D, Gabrilovich DI. Antigen-specific inhibition of CD8+ T cell response by immature myeloid cells in cancer is mediated by reactive oxygen species. *J Immunol.* 2004;172(2):989-999.
100. Zhang Y, Choksi S, Chen K, et al. ROS play a critical role in the differentiation of alternatively activated macrophages and the occurrence of tumor-associated macrophages. *Cell Res.* 2013;23(7):898-914.
101. Hu DN, McCormick SA, Seedor JA, Ritterband DC, Shah MK. Isolation, purification and cultivation of conjunctival melanocytes. *Exp Eye Res.* 2007;84(4):655-662.
102. Iwamoto S, Burrows RC, Grossniklaus HE, et al. Immunophenotype of conjunctival melanomas: comparisons with uveal and cutaneous melanomas. *Arch Ophthalmol.* 2002;120(12):1625-1629.
103. Olsen CM, Carroll HJ, Whiteman DC. Estimating the attributable fraction for melanoma: a meta-analysis of pigmentary characteristics and freckling. *Int J Cancer.* 2010;127(10):2430-2445.
104. Vajdic CM, Kricker A, Giblin M, et al. Eye color and cutaneous nevi predict risk of ocular melanoma in Australia. *Int J Cancer.* 2001;92(6):906-912.
105. Weis E, Shah CP, Lajous M, Shields JA, Shields CL. The association between host susceptibility factors and uveal melanoma: a meta-analysis. *Arch Ophthalmol.* 2006;124(1):54-60.
106. Schmidt-Pokrzywniak A, Jockel KH, Bornfeld N, Sauerwein W, Stang A. Positive interaction between light iris color and ultraviolet radiation in relation to the risk of uveal melanoma: a case-control study. *Ophthalmology.* 2009;116(2):340-348.
107. Houtzagers LE, Wierenga APA, Ruys AAM, Luyten GPM, Jager MJ. Iris Colour and the Risk of Developing Uveal Melanoma. *Int J Mol Sci.* 2020;21(19).

108. Shields CL, Yaghy A, Dalvin LA, et al. Conjunctival Melanoma: Features and Outcomes Based on the Fitzpatrick Skin Type in 540 Patients at a Single Ocular Oncology Center. *Ophthalmic Plast Reconstr Surg.* 2020.
109. Hanahan D, Weinberg RA. Hallmarks of cancer: the next generation. *Cell.* 2011;144(5):646-674.
110. McCain J. The MAPK (ERK) Pathway: Investigational Combinations for the Treatment Of BRAF-Mutated Metastatic Melanoma. *P t.* 2013;38(2):96-108.
111. Garnett MJ, Marais R. Guilty as charged: B-RAF is a human oncogene. *Cancer Cell.* 2004;6(4):313-319.
112. Davies MA. The role of the PI3K-AKT pathway in melanoma. *Cancer J.* 2012;18(2):142-147.
113. Kiuru M, Busam KJ. The NF1 gene in tumor syndromes and melanoma. *Lab Invest.* 2017;97(2):146-157.
114. Meng D, Carvajal RD. KIT as an Oncogenic Driver in Melanoma: An Update on Clinical Development. *Am J Clin Dermatol.* 2019;20(3):315-323.
115. Sugarman ET, Zhang G, Shay JW. In perspective: An update on telomere targeting in cancer. *Mol Carcinog.* 2019;58(9):1581-1588.
116. van Ipenburg JA, Naus NC, Dubbink HJ, et al. Prognostic value of TERT promoter mutations in conjunctival melanomas in addition to clinicopathological features. *Br J Ophthalmol.* 2020:[Online ahead of print].
117. Cancer-Genome-Atlas-Network. Genomic Classification of Cutaneous Melanoma. *Cell.* 2015;161(7):1681-1696.
118. Scholz SL, Cosgarea I, Susskind D, et al. NF1 mutations in conjunctival melanoma. *Br J Cancer.* 2018;118(9):1243-1247.
119. Greaves WO, Verma S, Patel KP, et al. Frequency and spectrum of BRAF mutations in a retrospective, single-institution study of 1112 cases of melanoma. *J Mol Diagn.* 2013;15(2):220-226.
120. Menzies AM, Haydu LE, Visintin L, et al. Distinguishing clinicopathologic features of patients with V600E and V600K BRAF-mutant metastatic melanoma. *Clin Cancer Res.* 2012;18(12):3242-3249.
121. Cao J, Heijkants RC, Jochemsen AG, et al. Targeting of the MAPK and AKT pathways in conjunctival melanoma shows potential synergy. *Oncotarget.* 2016.
122. Kim SY, Kim SN, Hahn HJ, et al. Metaanalysis of BRAF mutations and clinicopathologic characteristics in primary melanoma. *J Am Acad Dermatol.* 2015;72(6):1036-1046 e1032.
123. El Zaoui I, Bucher M, Rimoldi D, et al. Conjunctival Melanoma Targeted Therapy: MAPK and PI3K/mTOR Pathways Inhibition. *Invest Ophthalmol Vis Sci.* 2019;60(7):2764-2772.
124. Goldenberg-Cohen N, Cohen Y, Rosenbaum E, et al. T1799A BRAF mutations in conjunctival melanocytic lesions. *Invest Ophthalmol Vis Sci.* 2005;46(9):3027-3030.
125. Francis JH, Grossniklaus HE, Habib LA, et al. BRAF, NRAS, and GNAQ Mutations in Conjunctival Melanocytic Nevi. *Invest Ophthalmol Vis Sci.* 2018;59(1):117-121.
126. Pollock PM, Harper UL, Hansen KS, et al. High frequency of BRAF mutations in nevi. *Nat Genet.* 2003;33(1):19-20.
127. Gear H, Williams H, Kemp EG, Roberts F. BRAF mutations in conjunctival melanoma. *Invest Ophthalmol Vis Sci.* 2004;45(8):2484-2488.
128. Zebary A, Jangard M, Omholt K, Ragnarsson-Olding B, Hansson J. KIT, NRAS and BRAF mutations in sinonasal mucosal melanoma: a study of 56 cases. *Br J Cancer.* 2013;109(3):559-564.
129. Cosgarea I, Ugurel S, Sucker A, et al. Targeted next generation sequencing of mucosal melanomas identifies frequent NF1 and RAS mutations. *Oncotarget.* 2017;8(25):40683-40692.
130. Spendlove HE, Damato BE, Humphreys J, et al. BRAF mutations are detectable in conjunctival but not uveal melanomas. *Melanoma Res.* 2004;14(6):449-452.
131. Van Raamsdonk CD, Bezrookove V, Green G, et al. Frequent somatic mutations of GNAQ in uveal melanoma and blue naevi. *Nature.* 2009;457(7229):599-602.

132. van Poppelen NM, Vaarwater J, Mudhar HS, et al. Genetic Background of Iris Melanomas and Iris Melanocytic Tumors of Uncertain Malignant Potential. *Ophthalmology.* 2018;125(6):904-912.
133. Krauthammer M, Kong Y, Bacchiocchi A, et al. Exome sequencing identifies recurrent mutations in NF1 and RASopathy genes in sun-exposed melanomas. *Nat Genet.* 2015;47(9):996-1002.
134. Beadling C, Jacobson-Dunlop E, Hodi FS, et al. KIT gene mutations and copy number in melanoma subtypes. *Clin Cancer Res.* 2008;14(21):6821-6828.
135. Houben R, Becker JC, Kappel A, et al. Constitutive activation of the Ras-Raf signaling pathway in metastatic melanoma is associated with poor prognosis. *J Carcinog.* 2004;3:6.
136. Heppt MV, Siepmann T, Engel J, et al. Prognostic significance of BRAF and NRAS mutations in melanoma: a German study from routine care. *BMC Cancer.* 2017;17(1):536.
137. Cruz F, 3rd, Rubin BP, Wilson D, et al. Absence of BRAF and NRAS mutations in uveal melanoma. *Cancer Res.* 2003;63(18):5761-5766.
138. Cirenajwis H, Lauss M, Ekedahl H, et al. NF1-mutated melanoma tumors harbor distinct clinical and biological characteristics. *Mol Oncol.* 2017;11(4):438-451.
139. Johnson DB, Frampton GM, Rioth MJ, et al. Targeted Next Generation Sequencing Identifies Markers of Response to PD-1 Blockade. *Cancer Immunol Res.* 2016;4(11):959-967.
140. Hintzsche JD, Gorden NT, Amato CM, et al. Whole-exome sequencing identifies recurrent SF3B1 R625 mutation and comutation of NF1 and KIT in mucosal melanoma. *Melanoma Res.* 2017;27(3):189-199.
141. Foster WJ, Fuller CE, Perry A, Harbour JW. Status of the NF1 Tumor Suppressor Locus in Uveal Melanoma. *Archives of Ophthalmology.* 2003;121(9):1311-1315.
142. Curtin JA, Busam K, Pinkel D, Bastian BC. Somatic Activation of KIT in Distinct Subtypes of Melanoma. *Journal of Clinical Oncology.* 2006;24(26):4340-4346.
143. Alessandrini L, Parrozzani R, Bertorelle R, et al. C-Kit SCF receptor (CD117) expression and KIT gene mutation in conjunctival pigmented lesions. *Acta Ophthalmol.* 2013;91(8):e641-645.
144. Wallander ML, Layfield LJ, Emerson LL, et al. KIT mutations in ocular melanoma: frequency and anatomic distribution. *Mod Pathol.* 2011;24(8):1031-1035.
145. Tsao H, Mihm MC, Sheehan C. PTEN expression in normal skin, acquired melanocytic nevi, and cutaneous melanoma. *Journal of the American Academy of Dermatology.* 2003;49(5):865-872.
146. Cabrita R, Mitra S, Sanna A, et al. The Role of PTEN Loss in Immune Escape, Melanoma Prognosis and Therapy Response. *Cancers (Basel).* 2020;12(3).
147. Westekemper H, Karimi S, Susskind D, et al. Expression of HSP 90, PTEN and Bcl-2 in conjunctival melanoma. *Br J Ophthalmol.* 2011;95(6):853-858.
148. Populo H, Soares P, Rocha AS, Silva P, Lopes JM. Evaluation of the mTOR pathway in ocular (uvea and conjunctiva) melanoma. *Melanoma Res.* 2010;20(2):107-117.
149. Abdel-Rahman MH, Yang Y, Zhou XP, et al. High frequency of submicroscopic hemizygous deletion is a major mechanism of loss of expression of PTEN in uveal melanoma. *J Clin Oncol.* 2006;24(2):288-295.
150. Horn S, Figl A, Rachakonda PS, et al. TERT promoter mutations in familial and sporadic melanoma. *Science.* 2013;339(6122):959-961.
151. Vinagre J, Almeida A, Pópulo H, et al. Frequency of TERT promoter mutations in human cancers. *Nat Commun.* 2013;4:2185.
152. Hugdahl E, Kalvenes MB, Mannelqvist M, Ladstein RG, Akslen LA. Prognostic impact and concordance of TERT promoter mutation and protein expression in matched primary and metastatic cutaneous melanoma. *Br J Cancer.* 2018;118(1):98-105.

153. Koopmans AE, Ober K, Dubbink HJ, et al. Prevalence and implications of TERT promoter mutation in uveal and conjunctival melanoma and in benign and premalignant conjunctival melanocytic lesions. *Invest Ophthalmol Vis Sci.* 2014;55(9):6024-6030.
154. Shain AH, Yeh I, Kovalyshyn I, et al. The Genetic Evolution of Melanoma from Precursor Lesions. *New England Journal of Medicine.* 2015;373(20):1926-1936.
155. Jangard M, Zebary A, Ragnarsson-Olding B, Hansson J. TERT promoter mutations in sinonasal malignant melanoma: a study of 49 cases. *Melanoma Res.* 2015;25(3):185-188.
156. Dono M, Angelini G, Cecconi M, et al. Mutation frequencies of GNAQ, GNA11, BAP1, SF3B1, EIF1AX and TERT in uveal melanoma: detection of an activating mutation in the TERT gene promoter in a single case of uveal melanoma. *Br J Cancer.* 2014;110(4):1058-1065.
157. Feng X, Degese MS, Iglesias-Bartolome R, et al. Hippo-independent activation of YAP by the GNAQ uveal melanoma oncogene through a trio-regulated rho GTPase signaling circuitry. *Cancer Cell.* 2014;25(6):831-845.
158. Yu FX, Luo J, Mo JS, et al. Mutant Gq/11 promote uveal melanoma tumorigenesis by activating YAP. *Cancer Cell.* 2014;25(6):822-830.
159. Van Raamsdonk CD, Griewank KG, Crosby MB, et al. Mutations in GNA11 in uveal melanoma. *N Engl J Med.* 2010;363(23):2191-2199.
160. Vader MJC, Madigan MC, Versluis M, et al. GNAQ and GNA11 mutations and downstream YAP activation in choroidal nevi. *Br J Cancer.* 2017;117(6):884-887.
161. Dratviman-Storobinsky O, Cohen Y, Frenkel S, Pe'er J, Goldenberg-Cohen N. Lack of oncogenic GNAQ mutations in melanocytic lesions of the conjunctiva as compared to uveal melanoma. *Invest Ophthalmol Vis Sci.* 2010;51(12):6180-6182.
162. Yavuzyigitoglu S, Koopmans AE, Verdijk RM, et al. Uveal Melanomas with SF3B1 Mutations: A Distinct Subclass Associated with Late-Onset Metastases. *Ophthalmology.* 2016;123(5):1118-1128.
163. Koopmans AE, Verdijk RM, Brouwer RW, et al. Clinical significance of immunohistochemistry for detection of BAP1 mutations in uveal melanoma. *Mod Pathol.* 2014;27(10):1321-1330.
164. Harbour JW, Onken MD, Roberson ED, et al. Frequent mutation of BAP1 in metastasizing uveal melanomas. *Science.* 2010;330(6009):1410-1413.
165. Carbone M, Yang H, Pass HI, et al. BAP1 and cancer. *Nat Rev Cancer.* 2013;13(3):153-159.
166. Gezgin G, Dogrusöz M, van Essen TH, et al. Genetic evolution of uveal melanoma guides the development of an inflammatory microenvironment. *Cancer Immunol Immunother.* 2017;66(7):903-912.
167. Brouwer NJ, Gezgin G, Wierenga APA, et al. Tumour Angiogenesis in Uveal Melanoma Is Related to Genetic Evolution. *Cancers (Basel).* 2019;11(7).
168. Wiesner T, Obenauf AC, Murali R, et al. Germline mutations in BAP1 predispose to melanocytic tumors. *Nature Genetics.* 2011;43(10):1018-1021.
169. Liu-Smith F, Lu Y. Opposite Roles of BAP1 in Overall Survival of Uveal Melanoma and Cutaneous Melanoma. *J Clin Med.* 2020;9(2).
170. Royer-Bertrand B, Torsello M, Rimoldi D, et al. Comprehensive Genetic Landscape of Uveal Melanoma by Whole-Genome Sequencing. *Am J Hum Genet.* 2016;99(5):1190-1198.
171. Kenawy N, Kalirai H, Sacco JJ, et al. Conjunctival melanoma copy number alterations and correlation with mutation status, tumor features, and clinical outcome. *Pigment Cell Melanoma Res.* 2019;32(4):564-575.
172. Vajdic CM, Hutchins AM, Kricker A, et al. Chromosomal gains and losses in ocular melanoma detected by comparative genomic hybridization in an Australian population-based study. *Cancer Genet Cytogenet.* 2003;144(1):12-17.

173. Lake SL, Jmor F, Dopierala J, et al. Multiplex ligation-dependent probe amplification of conjunctival melanoma reveals common BRAF V600E gene mutation and gene copy number changes. *Invest Ophthalmol Vis Sci.* 2011;52(8):5598-5604.
174. Gast A, Scherer D, Chen B, et al. Somatic alterations in the melanoma genome: a high-resolution array-based comparative genomic hybridization study. *Genes Chromosomes Cancer.* 2010;49(8):733-745.
175. Soura E, Eliades PJ, Shannon K, Stratigos AJ, Tsao H. Hereditary melanoma: Update on syndromes and management: Genetics of familial atypical multiple mole melanoma syndrome. *J Am Acad Dermatol.* 2016;74(3):395-407; quiz 408-310.
176. Bataille V, Boyle J, Hungerford JL, Newton JA. Three cases of primary acquired melanosis of the conjunctiva as a manifestation of the atypical mole syndrome. *Br J Dermatol.* 1993;128(1):86-90.
177. Seregard S, af Trampe E, Månsson-Brahme E, et al. Prevalence of primary acquired melanosis and nevi of the conjunctiva and uvea in the dysplastic nevus syndrome. A case-control study. *Ophthalmology.* 1995;102(10):1524-1529.
178. Seminog OO, Goldacre MJ. Risk of benign tumours of nervous system, and of malignant neoplasms, in people with neurofibromatosis: population-based record-linkage study. *British Journal of Cancer.* 2013;108(1):193-198.
179. Guillot B, Dalac S, Delaunay M, et al. Cutaneous malignant melanoma and neurofibromatosis type 1. *Melanoma Research.* 2004;14(2):159-163.
180. Medina Mendez CA, Singh AD. Multifocal melanoma of the conjunctiva in an African American patient with neurofibromatosis type 1. *Cornea.* 2014;33(7):750-751.
181. Rubinstein TJ, Plesec TP, Singh AD. Desmoplastic melanoma of the eyelid and conjunctival melanoma in neurofibromatosis type 1: a clinical pathological correlation. *Surv Ophthalmol.* 2015;60(1):72-77.
182. Stacy RC, Kenyon KR, Jakobiec FA, Colby KA. Conjunctival melanoma arising from primary acquired melanosis in a patient with neurofibromatosis type I. *Cornea.* 2010;29(2):232-234.
183. To KW, Rabinowitz SM, Friedman AH, Merker C, Cavanaugh CP. Neurofibromatosis and neural crest neoplasms: primary acquired melanosis and malignant melanoma of the conjunctiva. *Surv Ophthalmol.* 1989;33(5):373-379.
184. Honavar SG, Singh AD, Shields CL, Shields JA, Eagle RC, Jr. Iris melanoma in a patient with neurofibromatosis. *Surv Ophthalmol.* 2000;45(3):231-236.
185. Singh AD, De Potter P, Fijal BA, et al. Lifetime prevalence of uveal melanoma in white patients with oculo(dermal) melanocytosis. *Ophthalmology.* 1998;105(1):195-198.
186. Shields CL, Kaliki S, Livesey M, et al. Association of Ocular and Oculodermal Melanocytosis With the Rate of Uveal Melanoma Metastasis: Analysis of 7872 Consecutive Eyes. *JAMA Ophthalmology.* 2013;131(8):993-1003.
187. Patel BC, Egan CA, Lucius RW, et al. Cutaneous malignant melanoma and oculodermal melanocytosis (nevus of Ota): report of a case and review of the literature. *J Am Acad Dermatol.* 1998;38(5 Pt 2):862-865.
188. Radhadevi CV, Charles KS, Lathika VK. Orbital malignant melanoma associated with nevus of Ota. *Indian J Ophthalmol.* 2013;61(6):306-309.
189. Abdel-Rahman MH, Pilarski R, Cebulla CM, et al. Germline BAP1 mutation predisposes to uveal melanoma, lung adenocarcinoma, meningioma, and other cancers. *J Med Genet.* 2011;48(12):856-859.
190. Chau C, van Doorn R, van Poppelen NM, et al. Families with BAP1-Tumor Predisposition Syndrome in The Netherlands: Path to Identification and a Proposal for Genetic Screening Guidelines. *Cancers (Basel).* 2019;11(8).
191. Gajos-Michniewicz A, Czyz M. Role of miRNAs in Melanoma Metastasis. *Cancers (Basel).* 2019;11(3).

192. Larsen AC, Mikkelsen LH, Borup R, et al. MicroRNA Expression Profile in Conjunctival Melanoma. *Invest Ophthalmol Vis Sci.* 2016;57(10):4205-4212.
193. Mikkelsen LH, Andersen MK, Andreasen S, et al. Global microRNA profiling of metastatic conjunctival melanoma. *Melanoma Res.* 2019;29(5):465-473.
194. van Ipenburg JA, Gillis Ing AJM, Dorssers LCJ, et al. MicroRNA Profiling in Benign and Malignant Conjunctival Melanocytic Lesions. *Ophthalmology.* 2020;127(3):432-434.
195. Colotta F, Allavena P, Sica A, Garlanda C, Mantovani A. Cancer-related inflammation, the seventh hallmark of cancer: links to genetic instability. *Carcinogenesis.* 2009;30(7):1073-1081.
196. Antohe M, Nedelcu RI, Nichita L, et al. Tumor infiltrating lymphocytes: The regulator of melanoma evolution. *Oncol Lett.* 2019;17(5):4155-4161.
197. Robert C, Schachter J, Long GV, et al. Pembrolizumab versus Ipilimumab in Advanced Melanoma. *N Engl J Med.* 2015;372(26):2521-2532.
198. Coussens LM, Werb Z. Inflammation and cancer. *Nature.* 2002;420(6917):860-867.
199. Mantovani A, Sozzani S, Locati M, Allavena P, Sica A. Macrophage polarization: tumor-associated macrophages as a paradigm for polarized M2 mononuclear phagocytes. *Trends Immunol.* 2002;23(11):549-555.
200. Cao J, Brouwer NJ, Richards KE, et al. PD-L1/PD-1 expression and tumor-infiltrating lymphocytes in conjunctival melanoma. *Oncotarget.* 2017;8(33):54722-54734.
201. Bronkhorst IH, Ly LV, Jordanova ES, et al. Detection of M2-macrophages in uveal melanoma and relation with survival. *Invest Ophthalmol Vis Sci.* 2011;52(2):643-650.
202. Makitie T, Summanen P, Tarkkanen A, Kivela T. Microvascular density in predicting survival of patients with choroidal and ciliary body melanoma. *Invest Ophthalmol Vis Sci.* 1999;40(11):2471-2480.
203. Storr SJ, Safuan S, Mitra A, et al. Objective assessment of blood and lymphatic vessel invasion and association with macrophage infiltration in cutaneous melanoma. *Mod Pathol.* 2012;25(4):493-504.
204. LeBien TW, Tedder TF. B lymphocytes: how they develop and function. *Blood.* 2008;112(5):1570-1580.
205. Zhu J, Paul WE. CD4 T cells: fates, functions, and faults. *Blood.* 2008;112(5):1557-1569.
206. Corthay A. How do regulatory T cells work? *Scand J Immunol.* 2009;70(4):326-336.
207. Ljunggren HG, Karre K. In search of the 'missing self': MHC molecules and NK cell recognition. *Immunol Today.* 1990;11(7):237-244.
208. Jay B. Naevi and Melanomata of the Conjunctiva. *Br J Ophthalmol.* 1965;49:169-204.
209. Crawford JB. Conjunctival melanomas: prognostic factors a review and an analysis of a series. *Trans Am Ophthalmol Soc.* 1980;78:467-502.
210. Clark WH, Jr., From L, Bernardino EA, Mihm MC. The histogenesis and biologic behavior of primary human malignant melanomas of the skin. *Cancer Res.* 1969;29(3):705-727.
211. Folberg R, McLean IW, Zimmerman LE. Malignant melanoma of the conjunctiva. *Hum Pathol.* 1985;16(2):136-143.
212. McGhee CN, Ni C, Albert DM, Chu FR. Conjunctival melanoma. *Int Ophthalmol Clin.* 1982;22(3):35-56.
213. Jeffrey IJ, Lucas DR, McEwan C, Lee WR. Malignant melanoma of the conjunctiva. *Histopathology.* 1986;10(4):363-378.
214. Bobic-Radovanovic A, Latkovic Z, Marinkovic J, Radovanovic Z. Predictors of survival in malignant melanoma of the conjunctiva: a clinico-pathological and follow-up study. *Eur J Ophthalmol.* 1998;8(1):4-7.
215. Anastassiou G, Esser M, Bader E, Steuhl KP, Bornfeld N. Expression of cell adhesion molecules and tumour infiltrating leucocytes in conjunctival melanoma. *Melanoma Res.* 2004;14(5):381-385.
216. Tuomaala S, Toivonen P, Al-Jamal R, Kivela T. Prognostic significance of histopathology of primary conjunctival melanoma in Caucasians. *Curr Eye Res.* 2007;32(11):939-952.

217. Jordanova ES, Gorter A, Ayachi O, et al. Human leukocyte antigen class I, MHC class I chain-related molecule A, and CD8+/regulatory T-cell ratio: which variable determines survival of cervical cancer patients? *Clin Cancer Res.* 2008;14(7):2028-2035.
218. Melief SM, Visconti VV, Visser M, et al. Long-term Survival and Clinical Benefit from Adoptive T-cell Transfer in Stage IV Melanoma Patients Is Determined by a Four-Parameter Tumor Immune Signature. *Cancer Immunol Res.* 2017;5(2):170-179.
219. Lassalle S, Nahon-Esteve S, Frouin E, et al. PD-L1 Expression in 65 Conjunctival Melanomas and Its Association with Clinical Outcome. *Int J Mol Sci.* 2020;21(23).
220. Clark WH, Jr., Elder DE, Guerry Dt, et al. Model predicting survival in stage I melanoma based on tumor progression. *J Natl Cancer Inst.* 1989;81(24):1893-1904.
221. Mihm MC, Jr., Mule JJ. Reflections on the Histopathology of Tumor-Infiltrating Lymphocytes in Melanoma and the Host Immune Response. *Cancer Immunol Res.* 2015;3(8):827-835.
222. Azimi F, Scolyer RA, Rumcheva P, et al. Tumor-infiltrating lymphocyte grade is an independent predictor of sentinel lymph node status and survival in patients with cutaneous melanoma. *J Clin Oncol.* 2012;30(21):2678-2683.
223. Taylor RC, Patel A, Panageas KS, Busam KJ, Brady MS. Tumor-infiltrating lymphocytes predict sentinel lymph node positivity in patients with cutaneous melanoma. *J Clin Oncol.* 2007;25(7):869-875.
224. Gerber AL, Munst A, Schlapbach C, et al. High expression of FOXP3 in primary melanoma is associated with tumour progression. *Br J Dermatol.* 2014;170(1):103-109.
225. Davidorf FH, Lang JR. Lymphocytic infiltration in choroidal melanoma and its prognostic significance. *Trans Ophthalmol Soc U K.* 1977;97(3):394-401.
226. de la Cruz PO, Jr., Specht CS, McLean IW. Lymphocytic infiltration in uveal malignant melanoma. *Cancer.* 1990;65(1):112-115.
227. Bronkhorst IH, Vu TH, Jordanova ES, et al. Different subsets of tumor-infiltrating lymphocytes correlate with macrophage influx and monosomy 3 in uveal melanoma. *Invest Ophthalmol Vis Sci.* 2012;53(9):5370-5378.
228. Makitie T, Summanen P, Tarkkanen A, Kivela T. Tumor-infiltrating macrophages (CD68(+) cells) and prognosis in malignant uveal melanoma. *Invest Ophthalmol Vis Sci.* 2001;42(7):1414-1421.
229. Maat W, Ly LV, Jordanova ES, et al. Monosomy of chromosome 3 and an inflammatory phenotype occur together in uveal melanoma. *Invest Ophthalmol Vis Sci.* 2008;49(2):505-510.
230. Mougiakakos D, Johansson CC, Trocme E, et al. Intratumoral forkhead box P3-positive regulatory T cells predict poor survival in cyclooxygenase-2-positive uveal melanoma. *Cancer.* 2010;116(9):2224-2233.
231. Robertson AG, Shih J, Yau C, et al. Integrative Analysis Identifies Four Molecular and Clinical Subsets in Uveal Melanoma. *Cancer Cell.* 2017;32(2):204-220 e215.
232. Brignole F, De Saint-Jean M, Goldschild M, et al. Expression of Fas-Fas ligand antigens and apoptotic marker APO2.7 by the human conjunctival epithelium. Positive correlation with class II HLA DR expression in inflammatory ocular surface disorders. *Exp Eye Res.* 1998;67(6):687-697.
233. Song H, Wu Y, Ren G, Guo W, Wang L. Prognostic factors of oral mucosal melanoma: histopathological analysis in a retrospective cohort of 82 cases. *Histopathology.* 2015;67(4):548-556.
234. Natarajan K, Li H, Mariuzza RA, Margulies DH. MHC class I molecules, structure and function. *Rev Immunogenet.* 1999;1(1):32-46.
235. Mosaad YM. Clinical Role of Human Leukocyte Antigen in Health and Disease. *Scand J Immunol.* 2015;82(4):283-306.
236. Howell WM. HLA and disease: guilt by association. *Int J Immunogenet.* 2014;41(1):1-12.
237. Garrido F, Cabrera T, Aptsiauri N. "Hard" and "soft" lesions underlying the HLA class I alterations in cancer cells: implications for immunotherapy. *Int J Cancer.* 2010;127(2):249-256.

238. Kageshita T, Hirai S, Ono T, Hicklin DJ, Ferrone S. Down-regulation of HLA class I antigen-processing molecules in malignant melanoma: association with disease progression. *Am J Pathol.* 1999;154(3):745-754.
239. Cao J, Brouwer NJ, Jordanova ES, et al. HLA Class I Antigen Expression in Conjunctival Melanoma Is Not Associated With PD-L1/PD-1 Status. *Invest Ophthalmol Vis Sci.* 2018;59(2):1005-1015.
240. Campoli M, Ferrone S. HLA antigen changes in malignant cells: epigenetic mechanisms and biologic significance. *Oncogene.* 2008;27(45):5869-5885.
241. de Waard-Siebinga I, Hilders CG, Hansen BE, van Delft JL, Jager MJ. HLA expression and tumor-infiltrating immune cells in uveal melanoma. *Graefes Arch Clin Exp Ophthalmol.* 1996;234(1):34-42.
242. Garrido F, Perea F, Bernal M, et al. The Escape of Cancer from T Cell-Mediated Immune Surveillance: HLA Class I Loss and Tumor Tissue Architecture. *Vaccines (Basel).* 2017;5(1).
243. Brocker EB, Suter L, Bruggen J, et al. Phenotypic dynamics of tumor progression in human malignant melanoma. *Int J Cancer.* 1985;36(1):29-35.
244. D'Alessandro G, Zardawi I, Grace J, McCarthy WH, Hersey P. Immunohistological evaluation of MHC class I and II antigen expression on nevi and melanoma: relation to biology of melanoma. *Pathology.* 1987;19(4):339-346.
245. Ferrone S, Marincola FM. Loss of HLA class I antigens by melanoma cells: molecular mechanisms, functional significance and clinical relevance. *Immunol Today.* 1995;16(10):487-494.
246. Carretero R, Romero JM, Ruiz-Cabello F, et al. Analysis of HLA class I expression in progressing and regressing metastatic melanoma lesions after immunotherapy. *Immunogenetics.* 2008;60(8):439-447.
247. Garrido F, Aptsiauri N. Cancer immune escape: MHC expression in primary tumours versus metastases. *Immunology.* 2019;158(4):255-266.
248. Chowell D, Morris LGT, Grigg CM, et al. Patient HLA class I genotype influences cancer response to checkpoint blockade immunotherapy. *Science.* 2018;359(6375):582-587.
249. van Essen TH, van Pelt SI, Bronkhorst IH, et al. Upregulation of HLA Expression in Primary Uveal Melanoma by Infiltrating Leukocytes. *PLoS One.* 2016;11(10):e0164292.
250. Blom DJ, Luyten GP, Mooy C, et al. Human leukocyte antigen class I expression. Marker of poor prognosis in uveal melanoma. *Invest Ophthalmol Vis Sci.* 1997;38(9):1865-1872.
251. Ericsson C, Seregard S, Bartolazzi A, et al. Association of HLA class I and class II antigen expression and mortality in uveal melanoma. *Invest Ophthalmol Vis Sci.* 2001;42(10):2153-2156.
252. Okazaki T, Honjo T. PD-1 and PD-1 ligands: from discovery to clinical application. *Int Immunol.* 2007;19(7):813-824.
253. Larkin J, Chiarion-Sileni V, Gonzalez R, et al. Combined Nivolumab and Ipilimumab or Monotherapy in Untreated Melanoma. *N Engl J Med.* 2015;373(1):23-34.
254. Egen JG, Kuhns MS, Allison JP. CTLA-4: new insights into its biological function and use in tumor immunotherapy. *Nat Immunol.* 2002;3(7):611-618.
255. Daud AI, Wolchok JD, Robert C, et al. Programmed Death-Ligand 1 Expression and Response to the Anti-Programmed Death 1 Antibody Pembrolizumab in Melanoma. *J Clin Oncol.* 2016;34(34):4102-4109.
256. Hodi FS, Chiarion-Sileni V, Gonzalez R, et al. Nivolumab plus ipilimumab or nivolumab alone versus ipilimumab alone in advanced melanoma (CheckMate 067): 4-year outcomes of a multicentre, randomised, phase 3 trial. *Lancet Oncol.* 2018;19(11):1480-1492.
257. Qin Y, Petaccia de Macedo M, Reuben A, et al. Parallel profiling of immune infiltrate subsets in uveal melanoma versus cutaneous melanoma unveils similarities and differences: A pilot study. *Oncoimmunology.* 2017;6(6):e1321187.
258. Javed A, Arguello D, Johnston C, et al. PD-L1 expression in tumor metastasis is different between uveal melanoma and cutaneous melanoma. *Immunotherapy.* 2017;9(16):1323-1330.

259. Kleinovink JW, Marijt KA, Schoonderwoerd MJA, et al. PD-L1 expression on malignant cells is no prerequisite for checkpoint therapy. *Oncoimmunology.* 2017;6(4):e1294299.
260. Patel SP, Kurzrock R. PD-L1 Expression as a Predictive Biomarker in Cancer Immunotherapy. *Mol Cancer Ther.* 2015;14(4):847-856.
261. Mahoney KM, Freeman GJ, McDermott DF. The Next Immune-Checkpoint Inhibitors: PD-1/PD-L1 Blockade in Melanoma. *Clin Ther.* 2015;37(4):764-782.
262. Thierauf J, Veit JA, Affolter A, et al. Identification and clinical relevance of PD-L1 expression in primary mucosal malignant melanoma of the head and neck. *Melanoma Res.* 2015;25(6):503-509.
263. Taube JM, Anders RA, Young GD, et al. Colocalization of inflammatory response with B7-h1 expression in human melanocytic lesions supports an adaptive resistance mechanism of immune escape. *Sci Transl Med.* 2012;4(127):127ra137.
264. McLaughlin J, Han G, Schalper KA, et al. Quantitative Assessment of the Heterogeneity of PD-L1 Expression in Non-Small-Cell Lung Cancer. *JAMA Oncol.* 2016;2(1):46-54.
265. Sato H, Okonogi N, Nakano T. Rationale of combination of anti-PD-1/PD-L1 antibody therapy and radiotherapy for cancer treatment. *Int J Clin Oncol.* 2020.
266. Kleinovink JW, Fransen MF, Löwik CW, Ossendorp F. Photodynamic-Immune Checkpoint Therapy Eradicates Local and Distant Tumors by CD8⁺ T Cells. *Cancer Immunology Research.* 2017;5(10):832-838.
267. Shields JA, Shields CL, De Potter P. Surgical management of conjunctival tumors. The 1994 Lynn B. McMahan Lecture. *Arch Ophthalmol.* 1997;115(6):808-815.
268. Finger PT, Czechonska G, Liarikos S. Topical mitomycin C chemotherapy for conjunctival melanoma and PAM with atypia. *Br J Ophthalmol.* 1998;82(5):476-479.
269. Herold TR, Hintschich C. Interferon alpha for the treatment of melanocytic conjunctival lesions. *Graefes Arch Clin Exp Ophthalmol.* 2010;248(1):111-115.
270. Brouwer NJ, Marinkovic M, Peters FP, et al. Management of conjunctival melanoma with local excision and adjuvant brachytherapy. *Eye (Lond).* 2021;35(2):490-498.
271. Westekemper H, Anastassiou G, Sauerwein W, et al. [Analysis of ocular surface alterations following proton beam radiation in eyes with conjunctival malignant melanoma]. *Ophthalmologe.* 2006;103(7):588-595.
272. Shields JA, Shields CL, Freire JE, Brady LW, Komarnicky L. Plaque radiotherapy for selected orbital malignancies: preliminary observations: the 2002 Montgomery Lecture, part 2. *Ophthal Plast Reconstr Surg.* 2003;19(2):91-95.
273. Wuestemeyer H, Sauerwein W, Meller D, et al. Proton radiotherapy as an alternative to exenteration in the management of extended conjunctival melanoma. *Graefes Arch Clin Exp Ophthalmol.* 2006;244(4):438-446.
274. Glossmann JP, Skoetz N, Starbatty B, et al. [Conjunctival melanoma : Standard operating procedures in diagnosis, treatment and follow-up care]. *Ophthalmologe.* 2018;115(6):489-498.
275. Cohen VML, O'Day RF. Management Issues in Conjunctival Tumours: Conjunctival Melanoma and Primary Acquired Melanosis. *Ophthalmol Ther.* 2019;8(4):501-510.
276. Lim LA, Madigan MC, Conway RM. Conjunctival melanoma: a review of conceptual and treatment advances. *Clin Ophthalmol.* 2013;6:521-531.
277. Esmaeli B, Wang X, Youssef A, Gershenwald JE. Patterns of regional and distant metastasis in patients with conjunctival melanoma: experience at a cancer center over four decades. *Ophthalmology.* 2001;108(11):2101-2105.
278. Pfeiffer ML, Ozgur OK, Myers JN, et al. Sentinel lymph node biopsy for ocular adnexal melanoma. *Acta Ophthalmol.* 2017;95(4):e323-e328.
279. Mor JM, Rokohl AC, Koch KR, Heindl LM. Sentinel lymph node biopsy in the management of conjunctival melanoma: current insights. *Clin Ophthalmol.* 2019;13:1297-1302.

280. Grimes JM, Shah NV, Samie FH, Carvajal RD, Marr BP. Conjunctival Melanoma: Current Treatments and Future Options. *Am J Clin Dermatol.* 2020;21(3):371-381.
281. Garbe C, Amaral T, Peris K, et al. European consensus-based interdisciplinary guideline for melanoma. Part 2: Treatment - Update 2019. *Eur J Cancer.* 2020;126:159-177.
282. FDA. TAFINLAR (dabrafenib). 2013. Accessed August 18th, 2020.
283. FDA. ZELBORAF (vemurafenib). 2011. Accessed August 18th, 2020.
284. FDA. BRAFTOVI (encorafenib). 2018. Accessed August 18th, 2020.
285. FDA. MEKINIST (trametinib). 2013. Accessed August 18th, 2020.
286. FDA. COTELLIC (cobimetinib). 2020. Accessed August 18th, 2020.
287. FDA. MEKTOVI (binimetinib). 2018. Accessed August 18th, 2020.
288. Nazarian R, Shi H, Wang Q, et al. Melanomas acquire resistance to B-RAF(V600E) inhibition by RTK or N-RAS upregulation. *Nature.* 2010;468(7326):973-977.
289. Whittaker SR, Theurillat J-P, Van Allen E, et al. A Genome-Scale RNA Interference Screen Implicates NF1 Loss in Resistance to RAF Inhibition. *Cancer Discovery.* 2013;3(3):350-362.
290. Wagle N, Van Allen EM, Treacy DJ, et al. MAP kinase pathway alterations in BRAF-mutant melanoma patients with acquired resistance to combined RAF/MEK inhibition. *Cancer Discov.* 2014;4(1):61-68.
291. Catalanotti F, Cheng DT, Shoushtari AN, et al. PTEN Loss-of-Function Alterations Are Associated With Intrinsic Resistance to BRAF Inhibitors in Metastatic Melanoma. *JCO Precis Oncol.* 2017;1.
292. Lin L, Sabnis AJ, Chan E, et al. The Hippo effector YAP promotes resistance to RAF- and MEK-targeted cancer therapies. *Nat Genet.* 2015;47(3):250-256.
293. Kim MH, Kim J, Hong H, et al. Actin remodeling confers BRAF inhibitor resistance to melanoma cells through YAP/TAZ activation. *Embo j.* 2016;35(5):462-478.
294. Kim MH, Kim CG, Kim SK, et al. YAP-Induced PD-L1 Expression Drives Immune Evasion in BRAFi-Resistant Melanoma. *Cancer Immunol Res.* 2018;6(3):255-266.
295. Larkin J, Ascierto PA, Dréno B, et al. Combined vemurafenib and cobimetinib in BRAF-mutated melanoma. *N Engl J Med.* 2014;371(20):1867-1876.
296. Long GV, Stroyakovskiy D, Gogas H, et al. Combined BRAF and MEK inhibition versus BRAF inhibition alone in melanoma. *N Engl J Med.* 2014;371(20):1877-1888.
297. Robert C, Karaszewska B, Schachter J, et al. Improved overall survival in melanoma with combined dabrafenib and trametinib. *N Engl J Med.* 2015;372(1):30-39.
298. Pahlitzsch M, Bertelmann E, Mai C. Conjunctival Melanoma and BRAF Inhibitor Therapy. *J Clin Exp Ophthalmol.* 2014;5(1).
299. Weber JL, Smalley KS, Sondak VK, Gibney GT. Conjunctival melanomas harbor BRAF and NRAS mutations--Letter. *Clin Cancer Res.* 2013;19(22):6329-6330.
300. Griewank KG, Westekemper H, Schilling B, et al. Conjunctival melanomas harbor BRAF and NRAS mutations--response. *Clin Cancer Res.* 2013;19(22):6331-6332.
301. Maleka A, Astrom G, Bystrom P, Ullenhag GJ. A case report of a patient with metastatic ocular melanoma who experienced a response to treatment with the BRAF inhibitor vemurafenib. *BMC Cancer.* 2016;16:634.
302. Pinto Torres S, Andre T, Gouveia E, Costa L, Passos MJ. Systemic Treatment of Metastatic Conjunctival Melanoma. *Case Rep Oncol Med.* 2017;2017:4623964.
303. Rossi E, Maiorano BA, Pagliara MM, et al. Dabrafenib and Trametinib in BRAF Mutant Metastatic Conjunctival Melanoma. *Front Oncol.* 2019;9:232.
304. Dagi Glass LR, Lawrence DP, Jakobiec FA, Freitag SK. Conjunctival Melanoma Responsive to Combined Systemic BRAF/MEK Inhibitors. *Ophthalmic Plast Reconstr Surg.* 2017;33(5):e114-e116.

305. Welsh SJ, Corrie PG. Management of BRAF and MEK inhibitor toxicities in patients with metastatic melanoma. *Ther Adv Med Oncol.* 2015;7(2):122-136.
306. Nareyeck G, Wuestemeyer H, von der Haar D, Anastassiou G. Establishment of two cell lines derived from conjunctival melanomas. *Exp Eye Res.* 2005;81(3):361-362.
307. Keijser S, Maat W, Missotten GS, de Keizer RJ. A new cell line from a recurrent conjunctival melanoma. *Br J Ophthalmol.* 2007;91(11):1566-1567.
308. Joensuu H, DeMatteo RP. The management of gastrointestinal stromal tumors: a model for targeted and multidisciplinary therapy of malignancy. *Annu Rev Med.* 2012;63:247-258.
309. Carvajal RD, Antonescu CR, Wolchok JD, et al. KIT as a therapeutic target in metastatic melanoma. *Jama.* 2011;305(22):2327-2334.
310. Guo J, Si L, Kong Y, et al. Phase II, open-label, single-arm trial of imatinib mesylate in patients with metastatic melanoma harboring c-Kit mutation or amplification. *J Clin Oncol.* 2011;29(21):2904-2909.
311. Hodi FS, Corless CL, Giobbie-Hurder A, et al. Imatinib for melanomas harboring mutationally activated or amplified KIT arising on mucosal, acral, and chronically sun-damaged skin. *J Clin Oncol.* 2013;31(26):3182-3190.
312. Germann UA, Furey BF, Markland W, et al. Targeting the MAPK Signaling Pathway in Cancer: Promising Preclinical Activity with the Novel Selective ERK1/2 Inhibitor BVD-523 (Ulixertinib). *Mol Cancer Ther.* 2017;16(11):2351-2363.
313. Sullivan RJ, Infante JR, Janku F, et al. First-in-Class ERK1/2 Inhibitor Ulixertinib (BVD-523) in Patients with MAPK Mutant Advanced Solid Tumors: Results of a Phase I Dose-Escalation and Expansion Study. *Cancer Discov.* 2018;8(2):184-195.
314. Posch C, Moslehi H, Feeney L, et al. Combined targeting of MEK and PI3K/mTOR effector pathways is necessary to effectively inhibit NRAS mutant melanoma in vitro and in vivo. *Proceedings of the National Academy of Sciences.* 2013:201216013.
315. Algazi AP, Esteve-Puig R, Nosrati A, et al. Dual MEK/AKT inhibition with trametinib and GSK2141795 does not yield clinical benefit in metastatic NRAS-mutant and wild-type melanoma. *Pigment Cell & Melanoma Research.* 2018;31(1):110-114.
316. Humer J, Ferko B, Waltenberger A, et al. Azidothymidine inhibits melanoma cell growth in vitro and in vivo. *Melanoma Research.* 2008;18(5):314-321.
317. Bachmann IM, Halvorsen OJ, Collett K, et al. EZH2 expression is associated with high proliferation rate and aggressive tumor subgroups in cutaneous melanoma and cancers of the endometrium, prostate, and breast. *J Clin Oncol.* 2006;24(2):268-273.
318. Zingg D, Debbache J, Schaefer SM, et al. The epigenetic modifier EZH2 controls melanoma growth and metastasis through silencing of distinct tumour suppressors. *Nature Communications.* 2015;6(1):6051.
319. Cao J, Pontes KC, Heijkants RC, et al. Overexpression of EZH2 in conjunctival melanoma offers a new therapeutic target. *J Pathol.* 2018;245(4):433-444.
320. Robert C, Thomas L, Bondarenko I, et al. Ipilimumab plus dacarbazine for previously untreated metastatic melanoma. *N Engl J Med.* 2011;364(26):2517-2526.
321. Weber JS, D'Angelo SP, Minor D, et al. Nivolumab versus chemotherapy in patients with advanced melanoma who progressed after anti-CTLA-4 treatment (CheckMate 037): a randomised, controlled, open-label, phase 3 trial. *Lancet Oncol.* 2015;16(4):375-384.
322. Finger PT, Pavlick AC. Checkpoint inhibition immunotherapy for advanced local and systemic conjunctival melanoma: a clinical case series. *J Immunother Cancer.* 2019;7(1):83.
323. Kini A, Fu R, Compton C, Miller DM, Ramasubramanian A. Pembrolizumab for Recurrent Conjunctival Melanoma. *JAMA Ophthalmol.* 2017;135(8):891-892.

324. Ford J, Thuro BA, Thakar S, et al. Immune Checkpoint Inhibitors for Treatment of Metastatic Melanoma of the Orbit and Ocular Adnexa. *Ophthalmic Plast Reconstr Surg.* 2017;33(4):e82-e85.
325. FDA. YERVOY (ipilimumab). 2020. Accessed April 8th, 2020.
326. FDA. KEYTRUDA (pembrolizumab). 2020. Accessed April 28th, 2020.
327. FDA. OPDIVO (nivolumab). 2020. Accessed April 28th, 2020.
328. Mocellin S, Lens MB, Pasquali S, Pilati P, Chiarion Sileni V. Interferon alpha for the adjuvant treatment of cutaneous melanoma. *Cochrane Database Syst Rev.* 2013(6):Cd008955.
329. Vann RR, Karp CL. Perilesional and topical interferon alfa-2b for conjunctival and corneal neoplasia. *Ophthalmology.* 1999;106(1):91-97.
330. Karp CL, Galor A, Chhabra S, Barnes SD, Alfonso EC. Subconjunctival/perilesional recombinant interferon alpha2b for ocular surface squamous neoplasia: a 10-year review. *Ophthalmology.* 2010;117(12):2241-2246.
331. Finger PT, Sedeek RW, Chin KJ. Topical interferon alfa in the treatment of conjunctival melanoma and primary acquired melanosis complex. *Am J Ophthalmol.* 2008;145(1):124-129.
332. Benage MJ, Morrow NC, Janson BJ, Greiner MA. Evaluation of interferon alpha 2b as adjunctive therapy for conjunctival melanoma. *Am J Ophthalmol Case Rep.* 2019;15:100467.
333. Rafique I, Kirkwood JM, Tarhini AA. Immune checkpoint blockade and interferon-alpha in melanoma. *Semin Oncol.* 2015;42(3):436-447.
334. Baron S, Tyring SK, Fleischmann WR, Jr., et al. The interferons. Mechanisms of action and clinical applications. *Jama.* 1991;266(10):1375-1383.
335. Curtsinger JM, Valenzuela JO, Agarwal P, Lins D, Mescher MF. Type I IFNs provide a third signal to CD8 T cells to stimulate clonal expansion and differentiation. *J Immunol.* 2005;174(8):4465-4469.
336. Davar D, Wang H, Chauvin JM, et al. Phase Ib/II Study of Pembrolizumab and Pegylated-Interferon Alfa-2b in Advanced Melanoma. *J Clin Oncol.* 2018:Jco1800632.
337. Kiyohara T, Tanimura H, Miyamoto M, et al. Two cases of BRAF-mutated, bulbar conjunctival melanoma, and review of the published literature. *Clin Exp Dermatol.* 2020;45(2):207-211.
338. Chaves LJ, Huth B, Augsburger JJ, Correa ZM. Eye-Sparing Treatment for Diffuse Invasive Conjunctival Melanoma. *Ocul Oncol Pathol.* 2018;4(4):261-266.
339. Chang M, Lally SE, Dalvin LA, Orloff MM, Shields CL. Conjunctival melanoma with orbital invasion and liver metastasis managed with systemic immune checkpoint inhibitor therapy. *Indian J Ophthalmol.* 2019;67(12):2071-2073.
340. Weber JS, Hamid O, Chasalow SD, et al. Ipilimumab increases activated T cells and enhances humoral immunity in patients with advanced melanoma. *J Immunother.* 2012;35(1):89-97.
341. Weber JS, Postow M, Lao CD, Schadendorf D. Management of Adverse Events Following Treatment With Anti-Programmed Death-1 Agents. *Oncologist.* 2016;21(10):1230-1240.
342. Byrne EH, Fisher DE. Immune and molecular correlates in melanoma treated with immune checkpoint blockade. *Cancer.* 2017;123(S11):2143-2153.
343. Sophie R, Moses GM, Hwang ES, Kim JE. Fundus Hypopigmentation and Loss of Choroidal Nevi Pigmentation Associated With Nivolumab. *JAMA Ophthalmol.* 2019;137(7):851-853.
344. Tarhini A. Immune-mediated adverse events associated with ipilimumab ctla-4 blockade therapy: the underlying mechanisms and clinical management. *Scientifica (Cairo).* 2013;2013:857519.
345. Zimmer L, Goldinger SM, Hofmann L, et al. Neurological, respiratory, musculoskeletal, cardiac and ocular side-effects of anti-PD-1 therapy. *Eur J Cancer.* 2016;60:210-225.
346. Papavasileiou E, Prasad S, Freitag SK, Sobrin L, Lobo AM. Ipilimumab-induced Ocular and Orbital Inflammation--A Case Series and Review of the Literature. *Ocul Immunol Inflamm.* 2016;24(2):140-146.

347. Dalvin LA, Shields CL, Orloff M, Sato T, Shields JA. CHECKPOINT INHIBITOR IMMUNE THERAPY: Systemic Indications and Ophthalmic Side Effects. *Retina.* 2018;38(6):1063-1078.
348. Wong RK, Lee JK, Huang JJ. Bilateral drug (ipilimumab)-induced vitritis, choroiditis, and serous retinal detachments suggestive of vogt-koyanagi-harada syndrome. *Retin Cases Brief Rep.* 2012;6(4):423-426.
349. Brouwer NJ, Haanen J, Jager MJ. Development of Ocular Rosacea following Combined Ipilimumab and Nivolumab Treatment for Metastatic Malignant Skin Melanoma. *Ocul Oncol Pathol.* 2017;3(3):188-192.
350. Fierz FC, Meier F, Chaloupka K, Boni C. Intraocular Inflammation Associated with New Therapies for Cutaneous Melanoma - Case Series and Review. *Klin Monbl Augenheilkd.* 2016;233(4):540-544.
351. Kellermann N, Maier M, Feucht N. [Vitreous metastasis of malignant cutaneous melanoma during treatment with ipilimumab]. *Ophthalmologe.* 2017;114(2):163-166.
352. Francis JH, Berry D, Abramson DH, et al. Intravitreous Cutaneous Metastatic Melanoma in the Era of Checkpoint Inhibition: Unmasking and Masquerading. *Ophthalmology.* 2020;127(2):240-248.
353. Brouwer NJ, Konstantinou EK, Gragoudas ES, et al. Targeting the YAP/TAZ Pathway in Uveal and Conjunctival Melanoma With Verteporfin. *Invest Ophthalmol Vis Sci.* 2021;62(4):3.

3.2

PD-L1/PD-1 Expression and Tumor-Infiltrating Lymphocytes in Conjunctival Melanoma

Jinfeng Cao[1,2*], Niels J. Brouwer[1*], Kate E. Richards[1], Marina Marinkovic[1], Sjoerd G. van Duinen[3], Daan Hurkmans[1], Els M. E. Verdegaal[5], Ekaterina S. Jordanova[3,4#], Martine J. Jager[1#]

*These authors contributed equally to this work

#These authors shared senior authorship

Oncotarget 2017; 8(33):54722–54734.

1. Department of Ophthalmology, Leiden University Medical Center, Leiden, The Netherlands
2. Department of Ophthalmology, The Second Hospital of Jilin University, Changchun, China
3. Center for Gynaecological Oncology Amsterdam (CGOA), Department of Obstetrics and Gynaecology, VU University Medical Center, Amsterdam, The Netherlands
4. Department of Pathology, Leiden University Medical Center, Leiden, The Netherlands
5. Department of Medical Oncology, Leiden University Medical Center, Leiden, The Netherlands

ABSTRACT

Conjunctival melanoma (CM) is an infrequent but potentially lethal malignancy, with limited therapeutic options for metastases. Recent inhibitors of the interaction of programmed cell death protein 1 (PD-1) and its ligand PD-L1 are associated with good clinical responses in many malignancies. To investigate the therapeutic potential of targeting the PD-1/PD-L1 axis in CM, we analyzed the expression of PD-1 and PD-L1 and the density of various types of tumor-infiltrating lymphocytes (TILs) in primary CM (n = 27), using immunofluorescence staining. Results were compared with clinical parameters and outcome. Flow cytometry was exploited to determine the PD-L1 and PD-1 protein expression in conjunctival and cutaneous melanoma cell lines. PD-L1 expression was identified on tumor cells in five (19%) primary CM and on stromal cells (mainly CD68+CD163+ M2 macrophages) in 16 (59%) cases. PD-L1 expression on tumor cells was associated with the presence of distant metastases and a worse melanoma-related survival. PD-1 expression was seen in 17 (63%) cases, all of which were T2 stage tumors. Small tumors had a higher density of TILs than large tumors. The density of TILs was not correlated with survival, tumoral/stromal PD-L1 or PD-1 expression. In vitro results showed that most CM and cutaneous melanoma cell lines do not constitutively express PD-L1. However, expression could be upregulated after interferon gamma stimulation. Our findings suggest that blocking the PD-1/PD-L1 axis should be evaluated as a treatment for CM.

INTRODUCTION

Conjunctival melanoma (CM) is a rare ocular malignancy, accounting for 5% of all ocular melanoma.[1] CM is a subtype of mucosal melanoma, which is possibly associated with ultraviolet light exposure.[2] The incidence in Caucasians has risen in the last few decades to 0.8/million.[3] CM arises from melanocytes in the conjunctiva, often presenting as a brownish lesion on the eye. Most frequently, CM develops in primary acquired melanosis (PAM) (up to 74%), and less frequently in a nevus (7%) or de novo (19%).[4] Treatment of primary CM generally consists of wide local excision followed by adjuvant treatment with either cryotherapy, brachytherapy, or topical chemotherapy.[5] Radical surgical procedures like exenteration are reserved for the most advanced stages.[5] The local recurrence rate is high, and may reach 60% in patients after 5 years, with a 5-year melanoma-related death rate of 14%.[6] Treatment options for metastasis of conjunctival melanoma are currently limited.

Recently, immunotherapies aiming at immune checkpoint pathways, such as cytotoxic T lymphocyte antigen 4 (CTLA-4) and programmed death 1 (PD-1), have been successfully exploited in the treatment of metastases of different malignancies and have led to long-lasting clinical responses.[7] Both CTLA-4 and PD-1 are upregulated on the surface of activated T cells and can bind to their respective ligands: CTLA-4 binds to B7 on antigen-presenting cells (APCs), and subsequently prevents the delivery of co-stimulatory signals and therefore the activation of T cells. PD-1 on T cells binds to the programmed death ligand 1 (PD-L1), a major PD-1 ligand which is present on the cell surface of tumor cells and macrophages, and functionally impairs the activated T cell, thereby preventing it from mounting an effective immune response against tumor antigens. Monoclonal antibodies that inhibit the interaction between PD-1 and PD-L1 block this inhibitory function and have led to improved survival in patients with metastases of cutaneous melanoma, colorectal cancer and non-small cell lung cancer.[8-10]

CM in many ways resembles cutaneous melanoma, suggesting that patients with CM metastases might also benefit from treatment with anti-PD-1/PD-L1 agents. PD-L1 expression determined by immunohistochemistry (IHC) on tumor cells is thought to be a potential biomarker predicting the sensitivity of anti-PD-1/PD-L1 treatment.[11-13] Whether blocking the PD-1/PD-L1 axis will be an effective therapy for CM may therefore depend on the PD-1/PD-L1 expression status of CM. To further elucidate the role of the PD-1/PD-L1 axis in CM, and its potential interrelationship with the tumor microenvironment, we studied PD-1/PD-L1 expression and the presence of tumor-infiltrating lymphocytes (TILs) in a cohort of primary CM, and compared expression and (co) localization of these factors to clinical and histological characteristics.

RESULTS

Patient characteristics

We studied primary CM from 27 patients who had been treated at the LUMC between 1996 and 2014 (Table 1). Fifteen (56%) patients were female, and 14 (52%) were over 60 years old. The epibulbar localization (n = 20) is comprised of limbal (n = 16) and bulbar conjunctiva (n = 4). The non-epibulbar localization (n = 7) includes tarsal, forniceal and caruncular conjunctiva. The clinical TNM stage was T1 in 20 (74%) and T2 in 7 (26%) cases. Two (7%) of the patients underwent surgical excision alone as primary treatment, three (11%) excision with cryotherapy, one (4%) excision and mitomycin C, 16 (59%) excision and subsequent brachytherapy, one (4%) external beam radiation, and four (15%) were treated by exenteration. The median follow-up time was 46 months (range 3–247 months). Eleven (41%) cases developed local recurrences. At the end of the follow-up period, four patients had died from CM metastases, two from unknown diseases without any signs of metastases, and 21 patients were alive.

Expression of PD-L1/PD-1 and TILs in CM

We determined PD-L1 expression on sections of 27 CM that were co-stained with HMB45/MART-1 antibody. The combination allowed us to distinguish between PD-L1 expressing tumor cells versus non-tumor cells. The PD-L1 positive non-tumor cells were mainly comprised of macrophages, similar to what has been described previously.[14]

Using a cut-off value of 5%, tumoral and stromal PD-L1 membranous expression was identified in five (19%) and 16 (59%) CM sections, respectively, as illustrated in Figure 1 and Table 1. One tumor showed 30% tumoral PD-L1 expression, while the other four cases had between 5–10% of the tumor cells expressing PD-L1. Published cut-off points used to define PD-L1 positivity vary from 1% to 50%.[13] As only one sample had sporadic PD-L1 positive tumor cells (1% to 5%) in our cohort, we decided to use 5% as cut-off point for comparisons. PD-L1 expression in stroma was seen more often in patients over 60 ($p = 0.03$), while positive PD-L1 staining in tumor areas was associated with the development of distant metastases ($p = 0.01$). Kaplan-Meier analysis and log rank testing similarly showed that PD-L1 positive staining in the tumor was associated with a worse melanoma-related survival ($p = 0.045$; Figure 4). Furthermore, to better understand the nature of PD-L1 positive cells in stroma, we stained sections from seven CM that contained PD-L1 positive stromal cells with anti-PD-L1, CD68 and CD163 antibodies. We observed that PD-L1 positive stromal cells were mainly CD68+CD163+ cells (Figure 2).

Table 1: Clinicopathological characteristics and correlation with PD-L1 and PD1 expression

		Tumoral PDL1			Stromal PDL1			Stromal PD1		
	All cases	Negative	Positive		Negative	Positive		Negative	Positive	
Characteristic	**Cases (%)**	**Cases (%)**	**Cases (%)**	**p value**	**Cases (%)**	**Cases (%)**	**p value**	**Cases (%)**	**Cases (%)**	**p value**
Overall	**27 (100)**	**22 (81)**	**5 (19)**		**11 (41)**	**16 (59)**		**10 (37)**	**17 (63)**	
Sex										
Male	12 (44)	10 (45)	2 (40)	1.00*	4 (36)	8 (50)	0.70*	4 (40)	8 (47)	1.00*
Female	15 (56)	12 (55)	3 (60)		7 (64)	8 (50)		6 (60)	9 (53)	
Age at diagnosis										
Age ≤60 year	13 (48)	12 (55)	1 (20)	0.33*	8 (73)	5 (31)	0.03**	5 (50)	8 (47)	1.00*
Age >60 year	14 (52)	10 (45)	4 (80)		3 (27)	11 (69)		5 (50)	9 (53)	
Tumor size, thickness	N=23	N=20	N=3		N=10	N=13		N=9	N=14	
Median [range], mm	1.0 [0.1-16.0]	0.9 [0.2-5.0]	6.0 [0.1-16.0]	0.40&	0.8 [0.2-5.0]	1.4 [0.1-16.0]	0.65&	0.6 [0.2-5.0]	1.2 [0.1-16.0]	0.56&
Tumor size, LBD	*N=24*	*N=19*	*N=5*		N=10	N=14		N=9	N=15	
Median [range], mm	9.5 [2.0-30.0]	10.0 [2.0-30.0]	6.0 [5.0-20.0]	0.89&	9.5 [2.0-12.0]	10.0 [2.0-30.0]	0.44&	7.0 [2.0-15.0]	10.0 [2.0-30.0]	0.48&
Location										
Epibulbar	20 (74)	17 (77)	3 (60)	0.58*	9 (82)	11 (69)	0.66*	10 (100)	10 (59)	*0.03**
Non-epibulbar	7 (26)	5 (23)	2 (40)		2 (18)	5 (31)		0 (0)	7 (41)	
cTNM**										
T1	20 (74)	17 (77)	3 (60)	0.58*	10 (82)	11 (69)	0.66*	10 (100)	10 (59)	*0.03**
T2	7 (26)	5 (23)	2 (40)		2 (18)	5 (31)		0 (0)	7 (41)	

Table 1. Continued

		Tumoral PDL1			Stromal PDL1			Stromal PD1		
	All cases	Negative	Positive		Negative	Positive		Negative	Positive	
Characteristic	**Cases (%)**	**Cases (%)**	**Cases (%)**	**p value**	**Cases (%)**	**Cases (%)**	**p value**	**Cases (%)**	**Cases (%)**	**p value**
Local recurrence										
No	16 (59)	13 (59)	3 (60)	1.00*	6 (55)	10 (63)	0.71*	8 (80)	8 (47)	0.12*
Yes	11 (41)	9 (41)	2 (40)		5 (45)	6 (38)		2 (20)	9 (53)	
Distant metastasis										
No	23 (85)	21 (95)	2 (40)	*0.01**	11 (100)	12 (75)	0.12*	10 (100)	13 (76)	0.27*
Yes	4 (15)	1 (5)	3 (60)		0 (0)	4 (25)		0 (0)	4 (24)	

*LBD = largest basal diameter. cTNM = clinical TNM stage, based on the first occurring conjunctival melanoma. P value calculation: * = Fischer exact test; ** = Pearson's chi-square; ♂ = Mann Whitney U test. Italic P values are ≤ 0.05.*

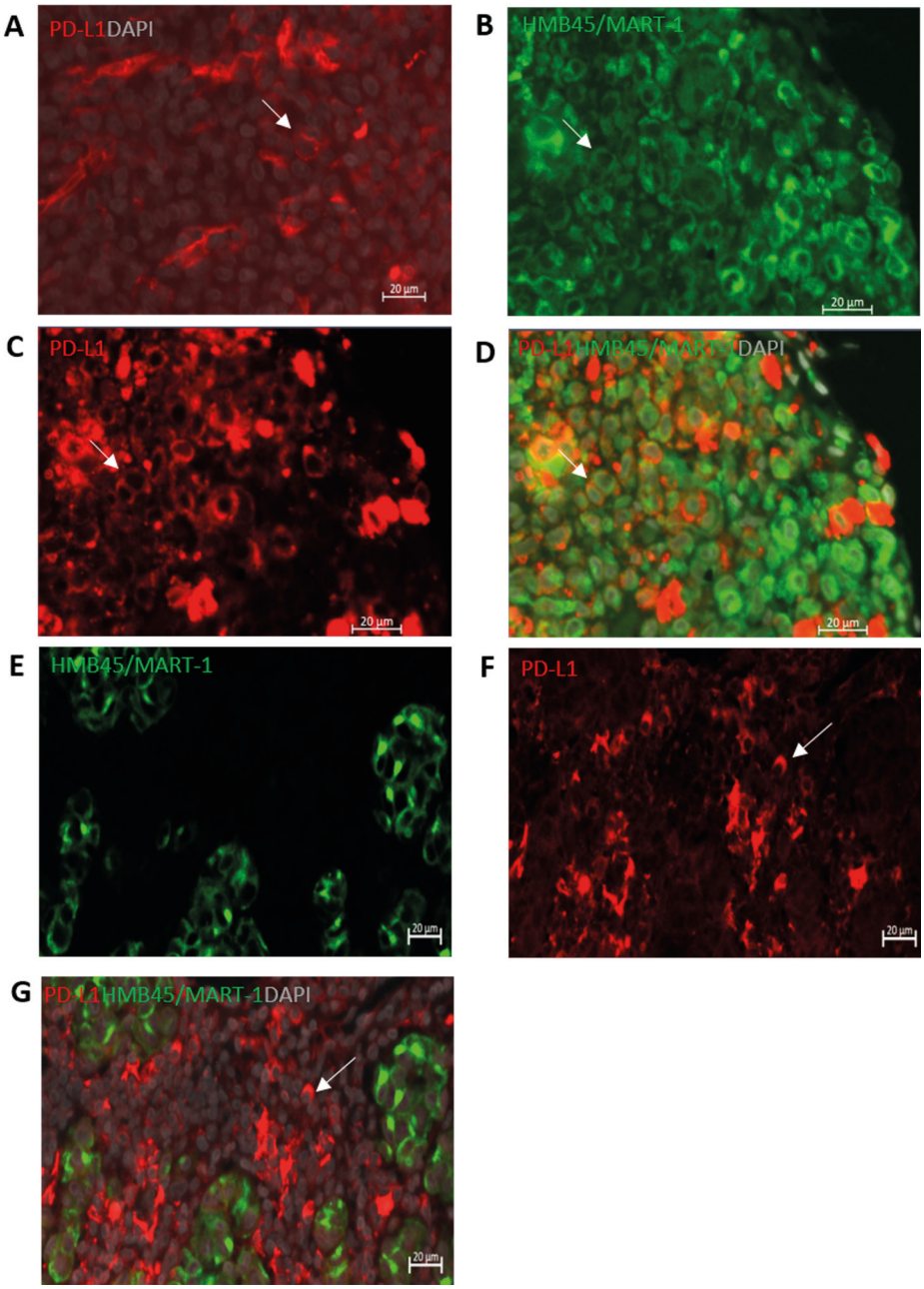

Figure 1: PD-L1 expression in primary CM as determined by IF analysis. (A) Positive membranous PD-L1 (red) staining in the positive control, human tonsil tissue. (B–D) Representative images of HMB45/MART-1 (B, green, cytoplasmic/membranous), PD-L1 (C, red, membranous) and double staining (D) with DAPI (grey), show that PD-L1 is expressed on CM cells. (E–G) PD-L1 is expressed on HMB45/Mart-1 negative stromal cells. Scale bar is 20µm. White arrows indicate the positive cells.

PD-1 expression was localized on the membrane of T cells (Figure 3), and was seen in 17 (63%) CM samples. All tumors at T2 stage were PD-1 positive ($p = 0.03$). Absence of PD-1 tended to correlate with less local recurrence ($p = 0.12$). A prior study on cutaneous melanoma showed that those melanomas often harbor intrinsically PD-1-positive tumor cell subpopulations;[15] however, we did not find positive PD-1 staining on the tumor cells themselves.

In order to see whether specific types of infiltrating leukocytes contributed to PD-L1 and PD-1 expression on tumor cells, we determined the presence of different subsets of T cells and myeloid cells in the same CM, by performing immunofluorescence (IF) staining according to previously described techniques:[16] we measured the numbers of CD3, CD3+CD8+, CD3+CD8-, CD3+CD8-Foxp3+ and CD3+CD8-Foxp3- T cells, and CD68 (macrophages) and CD68+CD163+ (M2 macrophages) within tumor areas of 26 primary CM sections. Figure 5 shows an example of a tumor with a high number of infiltrating lymphocytes. In general, all tumors presented a wide variety of different types of TILs (Table 2). T2 tumors showed less infiltration with CD3+CD8- and CD3+CD8-Foxp3- positive cells than non-T2 tumors ($p = 0.048$ and 0.02, respectively, Table 2). Although the CD3+CD8-Foxp3+ regulatory T cells may function as suppressors of effector T cells, Spearman rank analysis showed significantly positive associations between the density of CD3+CD8-Foxp3+ and of CD3, CD3+CD8+, CD3+CD8- as well as of CD3+CD8-Foxp3- T cells (Supplementary table 1). The different subsets of T cells frequently co-infiltrate CM. As tumor thickness is a known prognostic risk factor for CM,[17] we correlated the density of TILs with tumor thickness, and observed that thicker tumors had less CD3+CD8+ T cells ($p = 0.03$) and tumor-infiltrating M2 macrophages ($p = 0.02$; Table 3). Tumors with larger basal diameters contained fewer infiltrating CD3 ($p = 0.01$), CD3+CD8+ ($p = 0.02$), CD3+CD8- ($p = 0.01$), CD3+CD8-Foxp3- ($p = 0.02$) and CD3+CD8-Foxp3+ ($p = 0.03$) T cells within their tumor areas than tumors with smaller basal diameters (Table 3). The density of all types of TILs mentioned above was not correlated with tumoral/stromal PD-L1 expression ($p > 0.05$) or with melanoma-related survival. IF staining of CD68 and CD68+CD163+ showed that the majority of macrophages belong to the M2 phenotype, suggesting a potential tumor-favorable environment created by macrophages in CM. As high cytotoxic T lymphocyte (CTL)/regulatory T cell (Treg) and high M1 (CD68+CD163-)/M2 macrophage ratios have been found to be associated with improved survival in breast cancer and cutaneous melanoma, respectively,[14,18] we evaluated these ratios in our study. No significant difference in survival or association with clinical parameters was observed ($p > 0.05$). However, higher CTL/Treg ratio tended to correlate with local recurrence ($p = 0.13$). Correlation coefficients are shown in Table 3 and Supplementary Table 1.

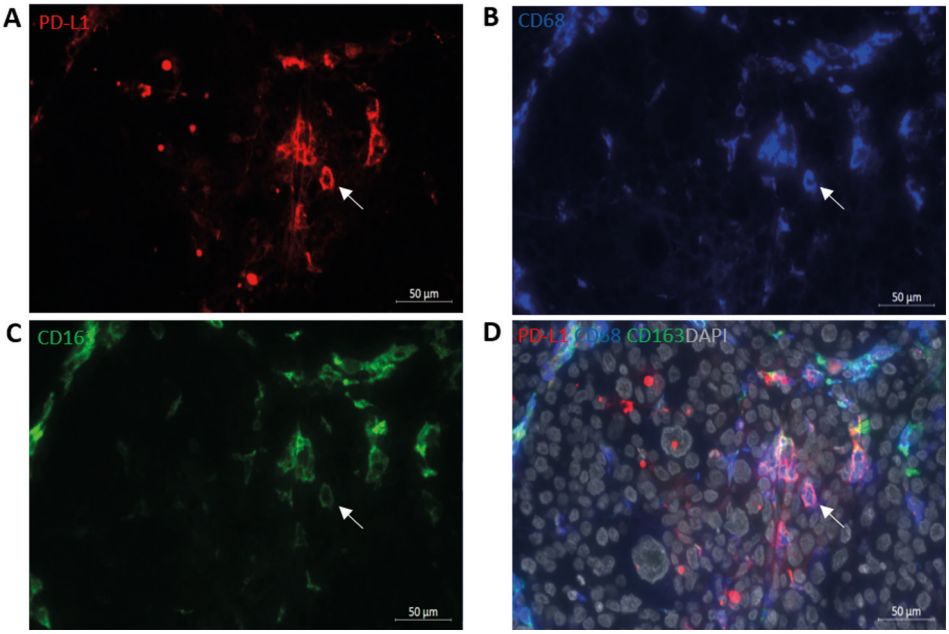

Figure 2. PD-L1 positive stromal cells are primarily CD68+CD163+ macrophages. (A) PD-L1 (red, membranous), (B) CD68 (blue, cytoplasmic/membranous), (C) CD163 (green, cytoplasm/membrane) and merged image (D) with DAPI (grey) show that PD-L1 positive stromal cells are also CD68+CD163+ positive cells. White arrow indicates the positive staining. Scale bar is 50 µm.

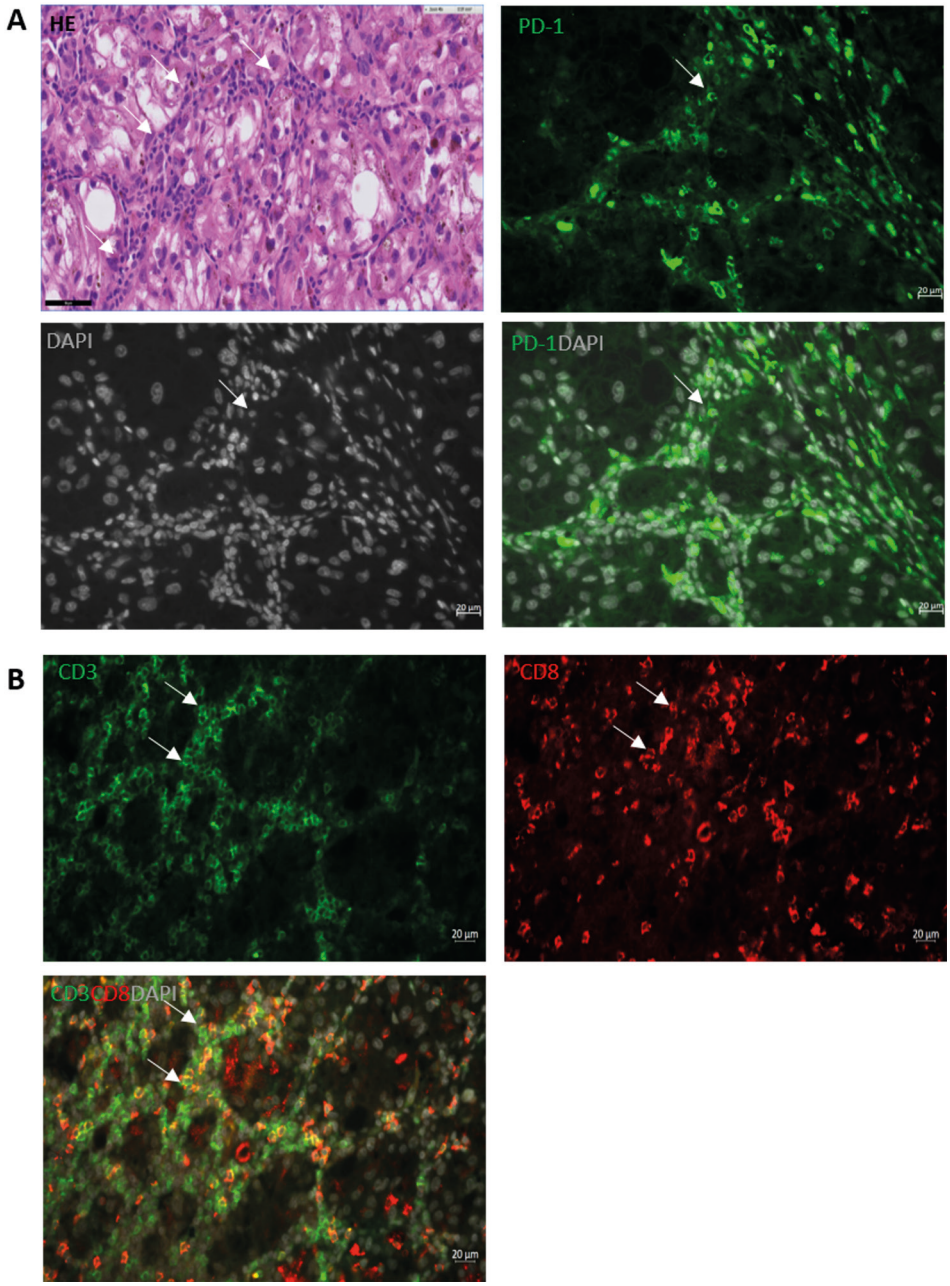

Figure 3. PD-1 expression in CM. Representative immunohistological staining shows that: (A) PD-1 (green, membrane) is expressed on stromal cells surrounding the primary tumor areas (white arrows); (B) staining of CD3 (green) and CD8 (red) demonstrates these stromal cells are T cells (white arrows). Scale bar of IF is 20 µm, and of HE is 50 µm.

Table 2. Baseline clinicopathological characteristics and correlation with tumor-infiltrating lymphocytes.

		CD3		CD3+CD8+		CD3+CD8-		CD3+CD8-Foxp3-		CD3+CD8-Foxp3+		CD68+		CD68+CD163+	
Categorical variables	**Cases (%)**	**Median [range]**	**p**	**Median [range]**	**p**	**Median [range]**	**p**	**Median [range]**	**p**	**Median [range]**	**p**	**Median [range]**	**p**	**Median [range]**	**p**
Overall	26 (100)	151 [71-637]		68 [26-335]		70 [26-314]		44 [13-202]		30 [10-124]		59 [19-248]		39 [8-220]	
Sex															
Male	11 (42)	130 [71-637]	0.33	65 [26-335]	0.51	65[26-302]	0.33	39 [13-202]	0.22	32 [11-100]	0.72	39 [19-248]	0.10	30 [8-220]	0.54
Female	15 (58)	159 [85-617]		80 [43-303]		83 [30-314]		53 [13-190]		26[10-124]		63 [22-189]		41 [11-161]	
Age at diagnosis, yr															
≤60	12 (46)	137 [85-299]	0.86	66 [28-170]	0.86	73 [26-173]	0.98	48 [15-100]	1.00	30 [11-80]	0.86	40 [19-76]	0.08	29 [8-59]	0.09
>60	14 (54)	158 [71-637]		74 [26-335]		69 [30-314]		42 [13-202]		30 [10-124]		63 [19-248]		43 [18-220]	
Location															
Epibulbar	19 (73)	171 [71-637]	0.08	82 [26-335]	0.15	83 [26-314]	*0.048*	53 [15-202]	*0.02*	34 [10-124]	0.53	63 [19-248]	0.12	41 [8-220]	0.23
Non-epibulbar	7 (27)	121 [110-144]		58 [50-80]		63 [30-76]		35 [13-51]		25 [17-48]		47 [19-63]		22 [11-59]	
cTNM															
T1	19 (73)	171 [71-637]	0.08	82 [26-335]	0.15	83 [26-314]	*0.048*	53 [15-202]	*0.02*	34 [10-124]	0.53	63 [19-248]	0.12	41 [8-220]	0.23
T2	7 (27)	121 [110-144]		58 [50-80]		63 [30-76]		35 [13-51]		25 [17-48]		47 [19-63]		22 [11-59]	
Local recurrence															
No	15 (58)	125 [71-617]	0.61	58 [26-303]	0.28	68 [30-314]	0.88	42 [13-189]	0.88	27 [10-124]	0.84	57 [19-189]	1.00	41 [8-161]	1.00
Yes	11 (42)	161 [85-637]		74 [43-335]		79 [26-302]		45 [13-202]		32 [11-100]		63 [22-248]		38 [11-220]	
Distant metastasis															
No	22 (85)	151 [71-637]	0.86	66 [26-335]	0.76	70 [26-314]	0.52	46 [15-202]	0.20	27 [10-124]	0.76	63 [19-248]	0.17	43 [8-220]	0.28
Yes	4 (15)	142 [110-207]		77 [62-82]		70 [30-133]		27 [13-92]		39 [17-48]		40 [27-47]		26 [19-39]	

cTNM = clinical TNM stage, based on the first occurring conjunctival melanoma. P values were calculated by Mann-Whitney U test. P ≤ 0.05 are in italics.

Table 3. Correlation between different types of infiltrating immune cells and tumor size

	Tumor thickness		Tumor LBD	
	r	p	r	p
CD3	–0.40	0.06	–0.56	*0.01*
$CD3^+CD8^+$	–0.45	*0.03*	–0.50	*0.02*
$CD3^+CD8^-$	–0.36	0.09	–0.54	*0.01*
$CD3^+CD8^-Foxp3^-$	–0.39	0.07	–0.50	*0.02*
$CD3^+CD8^-Foxp3^+$	–0.32	0.19	–0.46	*0.03*
CD68	–0.38	0.07	–0.26	0.24
$CD68^+CD163^+$	–0.49	*0.02*	–0.23	0.30
Tumor thickness	–	–	0.65	*0.001*

r = two-tailed Spearman correlation coefficient, with 26 observations. LBD = largest basal diameter. P ≤ 0.05 are in italics.

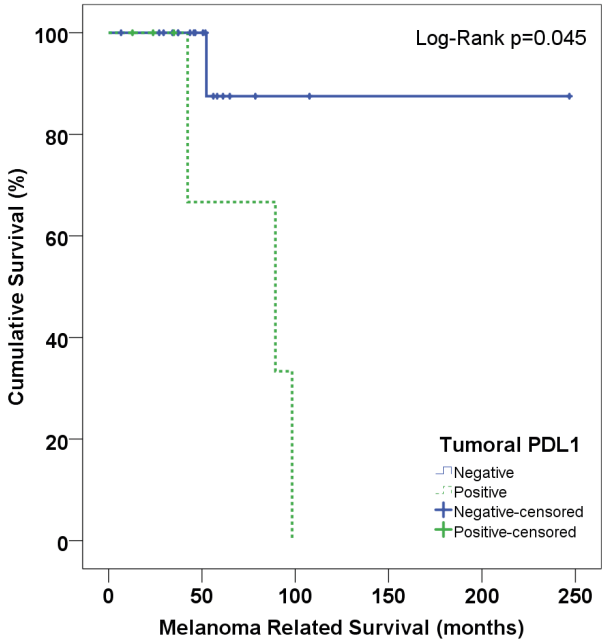

Figure 4: Survival analysis according to PD-L1 status in CM. Kaplan-Meier plot shows disease-specific survival of patients with PD-L1-positive tumors (green, dotted) and negative tumors (blue, continuous) (cut-off at 5%). P-value has been calculated using the log-rank test.

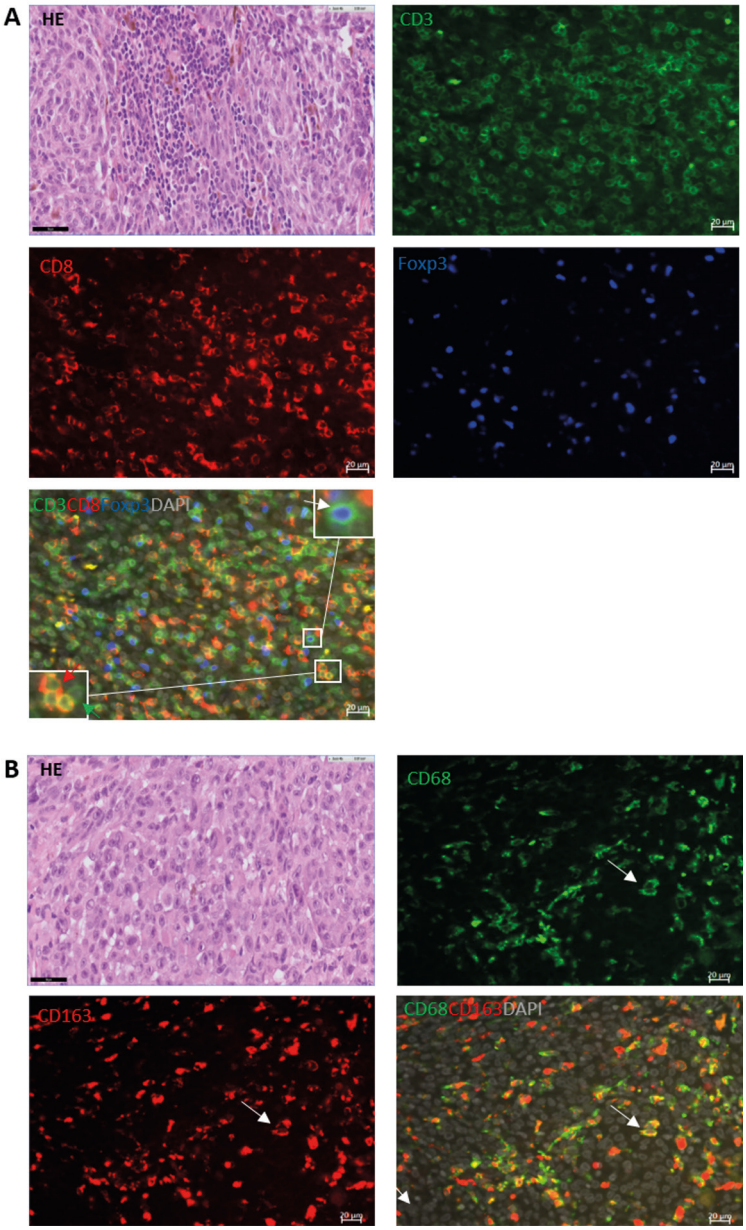

Figure 5: T cell and macrophage subset analysis in the tumor area of CM. (A) HE, CD3 (green, membrane), CD8 (red, membrane), Foxp3 (blue, nucleus) and the merged image; the combination of nuclear blue Foxp3 and surface green CD3 staining (white arrow) indicates the presence of CD3+CD8-Foxp3+ T cells. The green arrow indicates a CD3+CD8-Foxp3- T cell, and the red arrow points at CD3+CD8+ T cells. (B) HE, CD68 (green, cytoplasm/membrane), CD163 (red, cytoplasm/membrane) and merged image shows double-positive M2 macrophages cells. Scale bar of IF is 20 µm, and of HE is 50 µm.

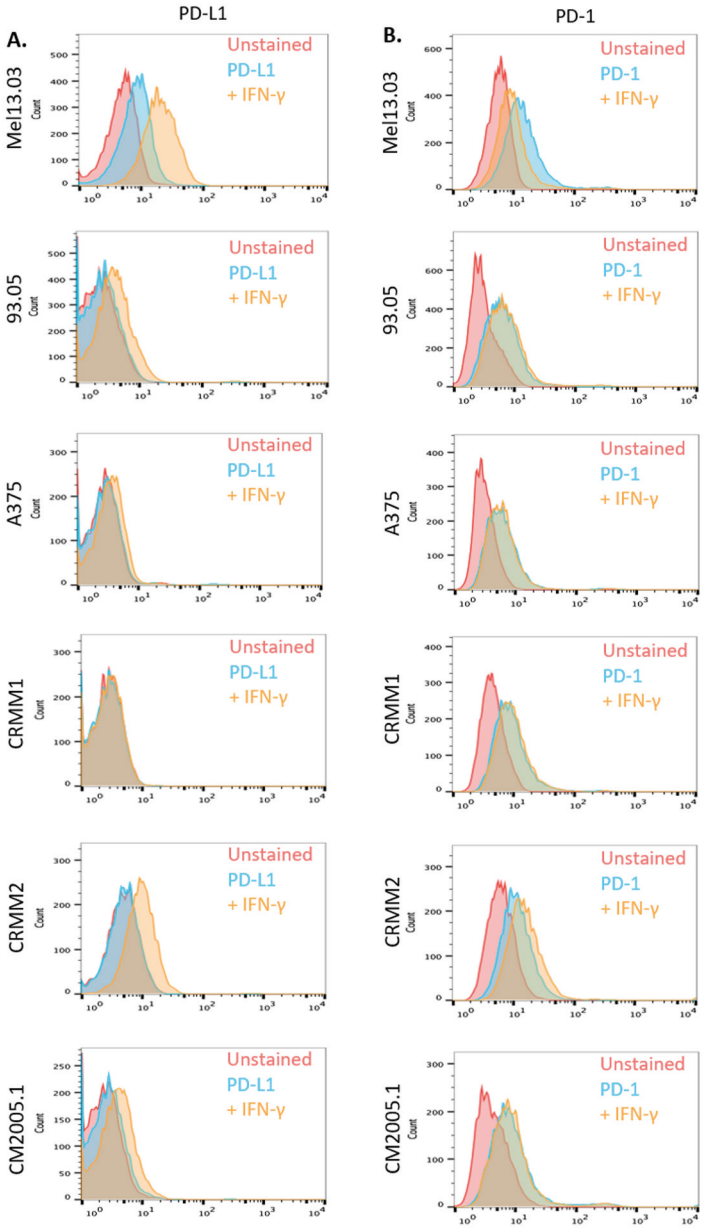

Figure 6. Cutaneous (MEL13.03, MEL93.05 and A375) and conjunctival melanoma (CRMM1, CRMM2 and CM2005.1) cell lines express various levels of PD-L1 and PD-1. MEL13.03 is the positive control cell line for both PD-L1 and PD-1. Representative histograms show (A) PD-L1 and PD-1 (B) expression in cell lines with or without IFN-γ (100 IU/ml) exposure for 48 h. Pink, blue and brown shaded histograms represent unstained, PD-L1 (PD-1) staining, and the effect of IFN-γ stimulation on PD-L1 and PD-1, respectively.

Human CM cell lines express various levels of PD-L1

Infiltration lymphocytes may be a source of interferon gamma (IFN-γ), which has been reported to enhance PD-L1 and PD-1 expression.[19,20] To examine how PD-L1 and PD-1 are expressed on the cell surface of CM cell lines, and to determine whether expression is sensitive to environmental cytokines, we performed flow cytometry on three human cutaneous melanoma and three CM cell lines. The cutaneous melanoma cell line MEL13.03 served as PD-L1 and PD-1 positive control. Figure 6 shows that compared to MEL13.03, the other five cell lines were PD-L1 negative, while only one other cell line, CRMM2, expressed PD-1. Next, to mimic the immune environment in vivo, we stimulated these cells with IFN-γ. As a control, we determined the upregulation of IFN-γ pathway by analyzing HLA Class I expression, using an anti-HLA class I antibody (Supplementary Figure 1). HLA Class I expression of all cell lines was upregulated upon IFN-γ stimulation. After 48 h incubation with IFN-γ, PD-L1 expression was upregulated at different levels on two of the three cutaneous melanoma cell lines (MEL13.03, MEL93.05) and on two of the three CM cell lines tested (CRMM2 and CM2005.1), while PD-1 was only slightly increased on one cell line (CRMM2) (Figure 6).

DISCUSSION

Immunotherapies that work through inhibiting the PD-L1/PD-1 axis have been successful in inducing clinical responses in patients with different malignancies, including cutaneous melanoma, non-small cell lung cancer, and bladder cancer.[21-23] However, there are no data yet on the expression of immune checkpoint molecules in CM, a rare malignancy. As far as we know, one ongoing clinical trial testing the efficacy and safety of Ipilimumab in metastatic melanoma patients is currently recruiting CM patients (NCT01355120). Very recently, a CM patient with a breast metastasis was successfully treated with Nivolumab, a monoclonal antibody directly against PD-1.[24] However, the PD-L1 expression of the primary or metastatic tumor of the patient was not described. Although the accuracy and reproducibility of PD-L1 staining is disputable, and the clinical responses may occur in PD-L1 negative tumors and not all PD-L1 positive tumors respond,[23] immunostaining is the best attempt to spredict the potential of immune-based therapies.[25] Since most CM are small and heterogenous, and some are pigmented, we decided to use the anti-PD-L1 SP142 clone as it has been shown to work in IF staining on paraffin-embedded sections.[14,23] In addition, it has recently been approved by the FDA as a complementary diagnostic to help make treatment decisions for the use of Atezolizumab in patients with non-small cell lung cancer. We determined whether PD-L1 expression was located on tumor cells or cells of the tumor microenvironment by simultaneous staining with a melanoma marker.

PD-L1 expression is a potential biomarker for prognosis in different types of cancer.[26-29] Expression of PD-L1 has been investigated in varies malignancies with most researchers using either a 1% or

5% cut-off for positivity.[30] Cytoplasmic staining of PD-L1 has often been neglected because the significance of intracellular expression of PD-L1 remains unclear and does not seem functional.[31] In the present study of a human CM cohort, we found that 19% of the tumors expressed PD-L1 (cut-off 5%), and that this expression was correlated with the presence of distant metastases and a worse melanoma-related survival. The incidence of tumor PD-L1 expression is lower than cutaneous melanoma, as reported previously.[32] However, our finding should be interpreted with caution as our cohort has a limited size. More patients are needed for further analysis of the prognostic value of PD-L1 expression in CM in order to confirm our findings. Although one study shows positive PD-L1 expression in 13% (3/23) of mucosal malignant melanoma of head and neck,[33] another study[34] did not find any clinical response by application of PD-1 inhibitors in a group of patients with advanced recurrent mucosal melanoma of head and neck. However, the cohort is rather small (n = 5).

Not only expression of PD-L1 on tumor cells may be important, also PD-L1 expressed by myeloid cells in the tumor microenvironment may play an essential role in suppression of the host's immune response, even when the malignant cells lack PD-L1.[14,35] Stromal PD-L1 expression can predict poor prognosis in adult T-cell leukemia or lymphoma and gastric carcinoma.[9,29] Here, we observe that 59% of CM contained PD-L1 positive stromal cells, but expression did not correlate with survival. The PD-L1 positive stromal cells were mainly comprised of CD68+CD163+ M2 macrophages, similar to what has been described previously.[14] In vitro experiment showed that all CM cell lines expressed low levels of membranous PD-L1, and a variable but clear increase of PD-L1 expression was seen in two out of three CM cell lines following IFN-γ stimulation. These findings suggest that in CM, initially PD-L1 negative or weakly positive tumors may display enhanced PD-L1 expression after exposure to IFN-γ produced by TILs.

Cancer exploits multiple mechanisms to avoid antitumor immune responses. Based on the "cancer immunogram" depicted by Blank, et al.,[36] the general immune status and immune cell infiltration needs to be addressed to facilitate the understanding of immune-based treatments. Unlike another type of ocular melanoma, uveal melanoma (UM), the immunology of CM has hardly been studied. Although the unique conjunctiva-associated lymphoid tissue (CALT) system in conjunctiva especially contains B lymphocytes,[37] we mainly focus on T lymphocytes because the PD-L1/PD-1 axis inactivates T-cell function. When we compare expression with the cell counts of TILs in UM, using the same antibodies and techniques as in our prior study on UM, we notice that CM contain higher densities of CD4 (CD3+CD8-), CD4 helper (CD3+CD8-Foxp3-) and Foxp3 (CD3+CD8-Foxp3+) cells than UM. However, the densities of CD8 (CD3+CD8+), CD68 and CD68CD163 cells were lower than those in UM. Compared to one study of cutaneous melanoma metastasis,[38] the density of CD3 and CD68CD163 was similar, with a higher density of CD4 and Foxp3, and lower density of CD8 cells. Some studies have shown that PD-L1 expression inversely correlates with TILs.[32,39] We find no association between tumoral or stromal PD-L1 positivity and the density

of TILs. However, the density of TILs was inversely correlated with tumor size, with larger tumors containing fewer immune cells, suggesting that in the absence of infiltrating immune cells, including cytotoxic T cells, the tumor could grow unrestrained.

A major limitation of the present study is the small size of the cohort, coming from a single institute, due to the rarity of CM. We need more patients and tumor material, especially metastases, to carry out further studies and draw solid conclusions. In addition, we should be aware that CM samples are generally quite small, and that a representative section accounts for a small volume of tumor, and may not represent the PD-L1 expression of the whole tumor, as it is known that PD-L1 expression may be quite heterogeneous.[35]

In general, we provide a comprehensive view of PD-L1 and PD-1 protein expression, and immune infiltration status in CM. These findings deepen our understanding of the immunology of CM. We believe that these results support the rationale of PD-L1/PD-1 checkpoint immunotherapy for patients with metastatic CM and recommend to include these patients in future immunotherapy clinical trials inhibiting the PD-L1/PD-L1 pathway.

MATERIALS AND METHODS

Patient data

Twenty-seven patients with histologically-proven primary CM were included in this study. All patients were seen at the Leiden University Medical Center, The Netherlands, and diagnosed with CM between 1996 and 2014. The medical files were reviewed for clinical and histopathological data. Information regarding the localisation and size of the primary tumors was obtained from the patient files, histology reports, and pre-excision color photographs. All tumors were evaluated by an experienced ophthalmic pathologist. Tumor stage was determined according to the 7th edition of the AJCC TNM cancer staging manual.[40] Treatment was defined as the initial treatment applied immediately or directly after histologic confirmation of CM. Local recurrence was defined as recurrence of histologically-proven CM. Metastasis was proven by histology or imaging. Total follow up time was defined as the time from diagnosis to the last known moment of survival or death. The study adhered to the tenets of the declaration of Helsinki, and the institutional Medical Ethical Committee of LUMC did not object to this retrospective analysis.

Immunofluorescence staining

Formalin-fixed, paraffin-embedded blocks containing tumor material were cut in 4 µm sections, and mounted on slides. After deparaffinization with Xylene, rehydration with alcohol (100%, 90%, 80%, 70%), and Tris-EDTA (pH 9.0) heat-based antigen retrieval, the tissues were incubated with primary antibodies at 4°C overnight. On the second day, after washing with phosphate-buffered

saline (PBS), the samples were incubated with AlexaFluor (Invitrogen, Breda, The Netherlands) secondary antibodies for 1 hour at room temperature, followed by washing steps. The slides were counterstained and mounted with VECTASHIELD mounting medium with DAPI (4',6-diamidino-2-phenylindole; H-1200; Vector Laboratories, USA). Tonsil tissues were used as positive control. Incubation with 1% bovine serum albumin (BSA)/PBS instead of primary antibodies served as negative control. One tumor contained only enough material for PD-L1 and PD-1 staining, and not for additional staining. The primary antibodies are listed below: HMB45/Mart-1 (mouse, clone HMB45 + DT101 + BC199, ab732, 1:200; Abcam, UK), anti-PD-L1 (rabbit, clone SP142, 1:100; Spring Bioscience, CA, USA), anti-PD1 (goat, AF1086, 1:100; R&D Systems, UK), CD3 (rabbit, ab828, 1:100; Abcam), anti-CD8 (mouse IgG2b, 4B11, 1:75; Novocastra, Valkenswaard, The Netherlands), anti-FoxP3 (mouse IgG1, clone 236A/E7, 1:100; Abcam), anti-CD68 (mouse IgG2a, ab49777, 1:75; Abcam) and anti-CD163 (mouse IgG1, clone 10D6, 1:100; Novocastra). The secondary antibodies are in Supplementary Table 2.

Imaging, scoring and analysis

The images of hematoxylin and eosin (HE) stained tumor sections were captured using Philips Image Management System 2.2. Images of IF staining were captured using either a Leica TCS SP8 X or Zeiss LSM 700 confocal laser scanning microscope. Depending on the tumor size, one to seven representative images at high power (250X) in different areas were randomly selected. Tumor areas were morphologically recognized by DAPI nuclear staining. Two investigators, without prior knowledge of clinicopathological data, scored membranous PD-L1 and PD1 expression. Expression of PD-L1 and PD-1 was designated as positive, when ≥ 5% of the tumor/stromal cells were positive.[32,41] For evaluation of the number of tumor-infiltrating lymphocytes within the tumor sites, tumor regions (mm2) were evaluated using Leica Application Suite X or Zeiss Zen 2.1 software. Positive cells were counted manually by two observers, as previously described.[16] Results were presented as cell numbers/mm2.

Cell lines

Three conjunctival melanoma cell lines (CRMM1, CRMM2 and CM2005.1)[42,43] and three cutaneous melanoma cell lines (A375 (ATCC), and MEL93.05 and MEL13.03, established in the Department of Medical Oncology, LUMC, Leiden) were used in our experiments. To determine the expression of PD-L1 and PD-1 on the cell lines, cells were first seeded in 6-well plates. On the second day, media were refreshed or replaced with culture media containing 100 international units (IU)/ml of IFN-γ (ImmunoTools, Germany) and incubated for 48 h. Cells were subsequently prepared for fluorescence-activated cell sorting (FACS).

Flow cytometry

Cells were incubated with the previously determined optimal dilution of mouse monoclonal PD-L1 (17-5983, APC; Bioscience), PD-1 (329935, FITC; BioLegend) or HLA class I antibodies (W6/32, 311414, Alexa Fluor 647; BioLegend). Cells were collected (10000-20000 per live gate) using the FACSCalibur cytometer (Becton Dickinson), and results were analysed using FlowJo software (V10.0.7, Flowjo LLC).

Statistical analysis

Data were analysed with SPSS software version 23.0 (SPSS, Inc., Chigaco, IL, USA). Data were considered statistically significant if $p \leq 0.05$. Pearson's chi square and Fisher's exact test were applied for categorical data; Mann Whitney U test was used for numerical data. Spearman's rank correlation analysis (two-tailed) was performed to compare correlations between different TILs and tumor size. Survival analysis was performed using Kaplan-Meier with log rank tests.

Abbreviations

programmed cell death protein 1 (PD-1), programmed death-ligand 1 (PD-L1), conjunctival melanoma (CM), tumor-infiltrating lymphocytes (TIL), cytotoxic T lymphocyte antigen 4 (CTLA-4), antigen-presenting cells (APCs), immunohistochemistry (IHC), immunofluorescence (IF), cytotoxic T lymphocyte (CTL), regulatory T cell (Treg), Interferon-gamma (IFN-γ), conjunctiva-associated lymphoid tissue (CALT).

Authors' contributions

MJJ initiated the idea, supervised the study, obtained funding and critically revised the article. EJ was involved in setting up, conducting and analysing the experiments, and improving the manuscript. JC performed the experiments, analysed the data and wrote the manuscript. NB collected materials and clinical information, interpreted data, and wrote the manuscript. KER and DH collected material and clinical data, and KER performed the experiments and interpreted the data. EMV was involved in the experiment and critically reviewed the manuscript. MM and SD gave technical and material support.

ACKNOWLEDGEMENTS

We thank Nick Landman for performing flow cytometry, Mieke Versluis for cutting sections, and Brendy EWM van den Akker and Joop Wiegant for assistance using the confocal microscope. We thank Sjoerd van der Burg for critical comments.

Conflicts of interest

The authors declare no conflicts of interest.

Grant support

This work was supported partly by grants from the China Scholarship Council (JC), the Dutch Cancer Society funding (UL 2013-5757), Horizon 2020 CURE UM grant, The Leiden Ophthalmological Support Fund, The Uveal Melanoma Bontius Fund, and a LUMC MD/PhD programme grant (NJB).

REFERENCES

1. Isager P, Engholm G, Overgaard J, Storm H. Uveal and conjunctival malignant melanoma in denmark 1943-97: observed and relative survival of patients followed through 2002. *Ophthalmic Epidemiol.* 2006;13(2):85-96.
2. Triay E, Bergman L, Nilsson B, All-Ericsson C, Seregard S. Time trends in the incidence of conjunctival melanoma in Sweden. *Br J Ophthalmol.* 2009;93(11):1524-1528.
3. Tuomaala S, Eskelin S, Tarkkanen A, Kivela T. Population-based assessment of clinical characteristics predicting outcome of conjunctival melanoma in whites. *Invest Ophthalmol Vis Sci.* 2002;43(11):3399-3408.
4. Shields CL, Markowitz JS, Belinsky I, et al. Conjunctival melanoma: outcomes based on tumor origin in 382 consecutive cases. *Ophthalmology.* 2011;118(2):389-395 e381-382.
5. Wong JR, Nanji AA, Galor A, Karp CL. Management of conjunctival malignant melanoma: a review and update. *Expert Rev Ophthalmol.* 2014;9(3):185-204.
6. Missotten GS, Keijser S, De Keizer RJ, De Wolff-Rouendaal D. Conjunctival melanoma in the Netherlands: a nationwide study. *Invest Ophthalmol Vis Sci.* 2005;46(1):75-82.
7. Sharma P, Allison JP. The future of immune checkpoint therapy. *Science.* 2015;348(6230):56-61.
8. Weber JS, D'Angelo SP, Minor D, et al. Nivolumab versus chemotherapy in patients with advanced melanoma who progressed after anti-CTLA-4 treatment (CheckMate 037): a randomised, controlled, open-label, phase 3 trial. *Lancet Oncol.* 2015;16(4):375-384.
9. Miyoshi H, Kiyasu J, Kato T, et al. PD-L1 expression on neoplastic or stromal cells is respectively a poor or good prognostic factor for adult T-cell leukemia/lymphoma. *Blood.* 2016;128(10):1374-1381.
10. Li Y, Liang L, Dai W, et al. Prognostic impact of programed cell death-1 (PD-1) and PD-ligand 1 (PD-L1) expression in cancer cells and tumor infiltrating lymphocytes in colorectal cancer. *Mol Cancer.* 2016;15(1):55.
11. Taube JM, Anders RA, Young GD, et al. Colocalization of inflammatory response with B7-h1 expression in human melanocytic lesions supports an adaptive resistance mechanism of immune escape. *Sci Transl Med.* 2012;4(127):127ra137.
12. Mahoney KM, Freeman GJ, McDermott DF. The Next Immune-Checkpoint Inhibitors: PD-1/PD-L1 Blockade in Melanoma. *Clin Ther.* 2015;37(4):764-782.
13. Patel SP, Kurzrock R. PD-L1 Expression as a Predictive Biomarker in Cancer Immunotherapy. *Mol Cancer Ther.* 2015;14(4):847-856.
14. Heeren AM, Punt S, Bleeker MC, et al. Prognostic effect of different PD-L1 expression patterns in squamous cell carcinoma and adenocarcinoma of the cervix. *Mod Pathol.* 2016;29(7):753-763.
15. Kleffel S, Posch C, Barthel SR, et al. Melanoma Cell-Intrinsic PD-1 Receptor Functions Promote Tumor Growth. *Cell.* 2015;162(6):1242-1256.
16. Bronkhorst IH, Vu TH, Jordanova ES, et al. Different subsets of tumor-infiltrating lymphocytes correlate with macrophage influx and monosomy 3 in uveal melanoma. *Invest Ophthalmol Vis Sci.* 2012;53(9):5370-5378.
17. Tuomaala S, Toivonen P, Al-Jamal R, Kivela T. Prognostic significance of histopathology of primary conjunctival melanoma in Caucasians. *Curr Eye Res.* 2007;32(11):939-952.
18. Melief SM, Visconti VV, Visser M, et al. Long-term Survival and Clinical Benefit from Adoptive T-cell Transfer in Stage IV Melanoma Patients Is Determined by a Four-Parameter Tumor Immune Signature. *Cancer Immunol Res.* 2017;5(2):170-179.
19. Terawaki S, Chikuma S, Shibayama S, et al. IFN-α directly promotes programmed cell death-1 transcription and limits the duration of T cell-mediated immunity. *J Immunol.* 2011;186(5):2772-2779.
20. Abiko K, Matsumura N, Hamanishi J, et al. IFN-γ from lymphocytes induces PD-L1 expression and promotes progression of ovarian cancer. *Br J Cancer.* 2015;112(9):1501-1509.

21. Topalian SL, Hodi FS, Brahmer JR, et al. Safety, activity, and immune correlates of anti-PD-1 antibody in cancer. *N Engl J Med.* 2012;366(26):2443-2454.
22. Powles T, Eder JP, Fine GD, et al. MPDL3280A (anti-PD-L1) treatment leads to clinical activity in metastatic bladder cancer. *Nature.* 2014;515(7528):558-562.
23. Herbst RS, Soria JC, Kowanetz M, et al. Predictive correlates of response to the anti-PD-L1 antibody MPDL3280A in cancer patients. *Nature.* 2014;515(7528):563-567.
24. Ford J, Thuro BA, Thakar S, et al. Immune Checkpoint Inhibitors for Treatment of Metastatic Melanoma of the Orbit and Ocular Adnexa. *Ophthal Plast Reconstr Surg.* 2016.
25. Bhaijee F, Anders RA. PD-L1 Expression as a Predictive Biomarker: Is Absence of Proof the Same as Proof of Absence? *JAMA Oncol.* 2016;2(1):54-55.
26. Sabatier R, Finetti P, Mamessier E, et al. Prognostic and predictive value of PDL1 expression in breast cancer. *Oncotarget.* 2015;6(7):5449-5464.
27. Böger C, Behrens HM, Mathiak M, et al. PD-L1 is an independent prognostic predictor in gastric cancer of Western patients. *Oncotarget.* 2016;7(17):24269-24283.
28. Ottenhof SR, Djajadiningrat RS, de Jong J, et al. Expression of Programmed Death Ligand 1 in Penile Cancer is of Prognostic Value and Associated with HPV Status. *J Urol.* 2017;197(3 Pt 1):690-697.
29. Cho J, Lee J, Bang H, et al. Programmed cell death-ligand 1 expression predicts survival in patients with gastric carcinoma with microsatellite instability. *Oncotarget.* 2017;8(8):13320-13328.
30. Ilie M, Hofman V, Dietel M, Soria JC, Hofman P. Assessment of the PD-L1 status by immunohistochemistry: challenges and perspectives for therapeutic strategies in lung cancer patients. *Virchows Arch.* 2016;468(5):511-525.
31. Mahoney KM, Sun H, Liao X, et al. PD-L1 Antibodies to Its Cytoplasmic Domain Most Clearly Delineate Cell Membranes in Immunohistochemical Staining of Tumor Cells. *Cancer Immunol Res.* 2015;3(12):1308-1315.
32. Taube JM, Klein A, Brahmer JR, et al. Association of PD-1, PD-1 ligands, and other features of the tumor immune microenvironment with response to anti-PD-1 therapy. *Clin Cancer Res.* 2014;20(19):5064-5074.
33. Thierauf J, Veit JA, Affolter A, et al. Identification and clinical relevance of PD-L1 expression in primary mucosal malignant melanoma of the head and neck. *Melanoma Res.* 2015;25(6):503-509.
34. Thierauf J, Veit JA, Hess J, et al. Checkpoint inhibition for advanced mucosal melanoma. *Eur J Dermatol.* 2017;27(2):160-165.
35. McLaughlin J, Han G, Schalper KA, et al. Quantitative Assessment of the Heterogeneity of PD-L1 Expression in Non-Small-Cell Lung Cancer. *JAMA Oncol.* 2016;2(1):46-54.
36. Blank CU, Haanen JB, Ribas A, Schumacher TN. CANCER IMMUNOLOGY. The "cancer immunogram". *Science.* 2016;352(6286):658-660.
37. Knop N, Knop E. Conjunctiva-associated lymphoid tissue in the human eye. *Invest Ophthalmol Vis Sci.* 2000;41(6):1270-1279.
38. Erdag G, Schaefer JT, Smolkin ME, et al. Immunotype and immunohistologic characteristics of tumor-infiltrating immune cells are associated with clinical outcome in metastatic melanoma. *Cancer Res.* 2012;72(5):1070-1080.
39. Inman BA, Sebo TJ, Frigola X, et al. PD-L1 (B7-H1) expression by urothelial carcinoma of the bladder and BCG-induced granulomata: associations with localized stage progression. *Cancer.* 2007;109(8):1499-1505.
40. Edge SB BD, Compton CC. Malignant melanoma of the conjunctiva. In: Edge SB BD, Compton CC, ed. *AJCC Cancer Staging Manual*. 7 ed. New York: Springer; 2010:539-546.
41. D'Incecco A, Andreozzi M, Ludovini V, et al. PD-1 and PD-L1 expression in molecularly selected non-small-cell lung cancer patients. *Br J Cancer.* 2015;112(1):95-102.
42. Nareyeck G, Wuestemeyer H, von der Haar D, Anastassiou G. Establishment of two cell lines derived from conjunctival melanomas. *Exp Eye Res.* 2005;81(3):361-362.

43. Keijser S, Maat W, Missotten GS, de Keizer RJ. A new cell line from a recurrent conjunctival melanoma. *Br J Ophthalmol.* 2007;91(11):1566-1567.

SUPPLEMENTARY MATERIAL

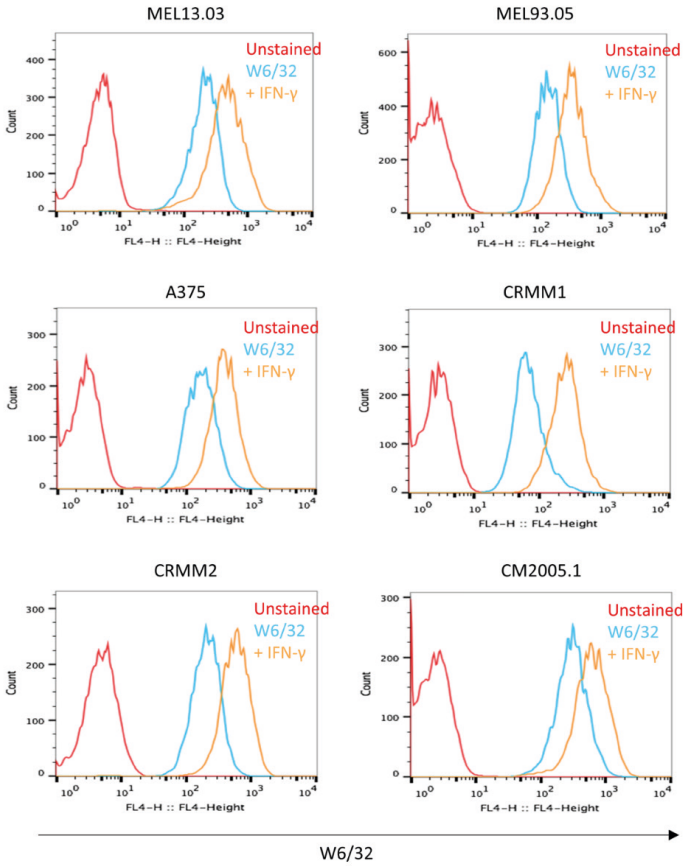

Supplementary Figure 1. The confirmation of IFN-γ effect on cutaneous (MEL13.03, MEL93.05 and A375) and conjunctival melanoma (CRMM1, CRMM2 and CM2005.1) cell lines using the anti-human HLA-A, B, C antibody (W6/32). The cells were treated with IFN-γ(100 IU/ml) for 48 h. Histograms with red, blue and brown line represent unstained, W6/32 expression, and the effect of IFN-γ stimulation on W6/32, respectively.

Supplementary Table 1. Correlation between different infiltrating immune cells (T cells and macrophages)

		CD3+CD8+	CD3+CD8-	CD3+CD8-Foxp3-	CD3+CD8-Foxp3+	CD68	CD68+CD163+
CD3	*r*	0.84	0.95	0.88	0.84	0.63	0.48
	P	*<0.001*	*<0.001*	*<0.001*	*<0.001*	*0.001*	*0.01*
CD3+CD8+	*r*		0.69	0.63	0.57	0.59	0.46
	P		*<0.001*	*0.001*	*0.002*	*0.001*	*0.02*
CD3+CD8-	*r*			0.93	0.84	0.53	0.38
	P			*<0.001*	*<0.001*	*0.005*	0.053
CD3+CD8-Foxp3-	*r*				0.65	0.51	0.34
	P				*<0.001*	*0.01*	0.09
CD3+CD8-Foxp3+	r					0.49	0.46
	P					*0.01*	*0.02*
CD68	*r*						0.87
	P						<0.001

r = two-tailed Spearman correlation coefficient, with 26 observations. P ≤ 0.05 are in italics.

Supplementary Table 2. Secondary antibodies used in IF

Antibody	Specificity	Isotype	Company	Catalogue number	Dilutions
AlexaFluor 488	mouse	IgG	Life Technologies	A-11001	1:300
AlexaFluor 546	rabbit	IgG	Life Technologies	A-11010	1:300
AlexaFluor 488	goat	IgG	Life Technologies	A-11055	1:300
AlexaFluor 488	rabbit	IgG	Life Technologies	A-11034	1:300
AlexaFluor 546	mouse	IgG2b	Life Technologies	A-21143	1:300
AlexaFluor 647	mouse	IgG1	Life Technologies	A-21240	1:300
AlexaFluor 488	mouse	IgG2a	Life Technologies	A-21131	1:300
AlexaFluor 546	mouse	IgG1	Life Technologies	A-21123	1:300
AlexaFluor 647	mouse	IgG2a	Life Technologies	A-21241	1:300
AlexaFluor 488	mouse	IgG1	Life Technologies	A-21121	1:300

PART II – UVEAL MELANOMA

Chapter 4: Treatment Targets

4.1 Targeting the YAP/TAZ Pathway in Uveal and Conjunctival Melanoma with verteporfin
4.2 Tumour Angiogenesis in Uveal Melanoma Is Related to Genetic Evolution

Chapter 5: Imaging Techniques

5.1 Retinal Oximetry is Altered in Eyes with Choroidal Melanoma but not in Eyes with Choroidal Nevi
5.2 Anterior Segment OCTA of Melanocytic Lesions of the Conjunctiva and Iris

4.1

Targeting the YAP/TAZ Pathway in Uveal and Conjunctival Melanoma with Verteporfin

Niels J. Brouwer[1,2], Eleni K. Konstantinou[1], Evangelos S. Gragoudas[1], Marina Marinkovic[2], Gregorius P.M. Luyten[2], Ivana K. Kim[1], Martine J. Jager[2], Demetrios G. Vavvas[1]

Invest Ophthalmol Vis Sci 2021; 62(4):3

1 Department of Ophthalmology, Retina Service, Angiogenesis Laboratory, Massachusetts Eye and Ear Infirmary, Harvard Medical School, Boston, USA

2 Department of Ophthalmology, Leiden University Medical Center, Leiden, The Netherlands

ABSTRACT

Purpose: The purpose of this study was to determine whether YAP/TAZ activation in uveal melanoma (UM) and the susceptibility of melanoma cell lines to YAP/TAZ inhibition by verteporfin (VP) is related to the tumor's genetic background.

Methods: Characteristics of 144 patients with enucleated UM were analyzed together with mRNA expression levels of YAP/TAZ-related genes (80 patients from the The Cancer Genome Atlas [TCGA] project and 64 patients from Leiden, The Netherlands). VP was administered to cell lines 92.1, OMM1, Mel270, XMP46, and MM28 (UM), CRMM1 and CRMM2 (conjunctival melanoma), and OCM3 (cutaneous melanoma). Viability, growth speed, and expression of YAP1-related proteins were assessed.

Results: In TCGA data, high expression of *YAP1* and *WWTR1* correlated with the presence of monosomy 3 (p=0.009 and p<0.001, respectively) and BAP1-loss (p=0.003 and p=0.001, respectively) in the primary UM; metastasis development correlated with higher expression of *YAP1* (p=0.05) and *WWTR1* (p=0.003). In Leiden data, downstream transcription factor *TEAD4* was increased in cases with M3/BAP1-loss (p=0.002 and p=0.006) and related to metastasis (p=0.004).

UM cell lines 92.1, OMM1, and Mel270 (*GNAQ/11*-mutation, BAP1-positive) and the fast-growing cell line OCM3 (*BRAF*-mutation) showed decreased proliferation after exposure to VP. Two slow-growing UM cell lines XMP46 and MM28 (*GNAQ/11*-mutation, BAP1-negative) were not sensitive to VP, and neither were the two conjunctival melanoma cell lines (*BRAF/NRAS*-mutation).

Conclusion: High risk UM showed an increased expression of YAP/TAZ-related genes. Although most UM cell lines responded in vitro to VP, BAP1-negative and conjunctival melanoma cell lines did not. Not only the mutational background, but also cell growth rate is an important predictor of response to YAP/TAZ inhibition by VP.

INTRODUCTION

Uveal melanoma (UM) is the most common primary intraocular malignant tumor in adults, with an incidence of approximately 5 to 6 per million in the US.[1, 2] Treatment includes various forms of radiotherapy, removal of the eye is a last resort option.[3-5] Up to 50% of patients develop metastasis,[6] and no proper treatment for metastatic disease is as yet available.[7]

Conjunctival melanoma (CoM) is rarer than UM, with an incidence of approximately 0.7 per million in Caucasians.[8-10] Treatment consists generally of excision and adjuvant therapy (e.g. radiotherapy or topical chemotherapy);[11] even so, 7% to 32% of patients die from metastases.[12-14]

Although both lesions are related to the eye, the genetic background of UM and CoM differs. UM is known to have driver mutations in *GNAQ/11,*[15, 16] *CYSLTR2,*[17] and *PLCB4,*[18] with subsequent mutations in *BAP1* (associated with adverse prognosis), *SF3B1* (associated with late metastasis) or *EIF1AX* (associated with good prognosis).[19] CoM on the other hand resembles cutaneous melanoma and has driver mutations in *BRAF, NRAS, Kit, TERT,* or *NF1.*[20-25] Despite their different backgrounds, UM and CoM share the need for the development of new and effective therapies.[26]

Recent studies identified the importance of the YAP/TAZ pathway in oncology, for tumor growth and possible targeting.[27] The YAP/TAZ pathway is involved in normal cell proliferation and apoptosis, regulating organ size. Key components of this pathway are Yes-Associated Protein 1 (YAP1) and its co-activator TAZ (a.k.a. WWTR1, not to be confused with the unrelated *Tafazzin* gene). YAP1 and TAZ can bind to TEAD proteins in the cell nucleus, allowing them to read DNA, and activate several genes that promote cell growth and proliferation (e.g. *CTGF, CYR61,* and *Survivin*).[28] In various cancers, including cutaneous melanoma, increased activity of the YAP/TAZ pathway has been related to worse survival,[29, 30] and inhibition of YAP/TAZ has been suggested as a potential new therapy.[27] Interestingly, the YAP/TAZ pathway can be blocked pharmacologically, using the benzoporphyrin verteporfin (VP, trade name: Visudyne). VP is being used clinically as a photosensitizer in photodynamic therapy (PDT) for various retinal disorders.[31] In PDT, upon irradiation with a nonthermal laser, reactive oxygen species are formed causing damage to the endothelium and regression of vessels. VP blocks YAP/TAZ through a different mechanism, however, as it can disrupt the YAP-TEAD complexes even without light activation.[32] Via this mechanism, VP inhibited in vitro cell growth in several cancers such as retinoblastoma[33] and glioma[34].

Approximately 90% of UM harbor a *GNAQ/11* mutation,[15, 16, 19] which was found to activate the YAP/TAZ cascade.[35, 36] Inhibition of this pathway by shRNA or drugs led to decreased cell growth in vitro as well as tumor regression in mouse models carrying a *GNAQ/11* mutation.[35, 36] This leads to the question whether the YAP/TAZ pathway can be used as a therapeutic target in UM. The *GNAQ/11* mutation is absent in CoM,[16, 37] but other stimuli (such as mechanical stress

and receptor signaling) can activate the YAP/TAZ cascade as well.[38] YAP1 expression was detected in cutaneous melanoma cell lines lacking a *GNAQ/11* mutation (but harboring *BRAF* or *NRAS* mutations instead),[35, 39, 40] and in human cutaneous melanoma tissue where a high expression was related to worse survival.[29, 30] Results of YAP/TAZ inhibition in cutaneous melanoma are mixed: one study identified diminished cell growth in cutaneous melanoma cell lines after administration of VP but found no effect on tumor development or tumor growth in a mouse model,[39] whereas another study found no effect of YAP/TAZ inhibition using shRNA on in vitro proliferation, but identified decreased in vitro invasiveness and less metastases formation after injection of melanoma cells in mice.[40] To our knowledge, no studies exist on YAP/TAZ inhibition in CoM.

Recently, it was reported that the YAP/TAZ pathway has little prognostic value for patient survival in UM.[41] This mechanism is poorly understood, however, and it is unknown if the YAP/TAZ pathway (activated by the early *GNAQ/11* mutation) is altered by chromosome changes or other mutations, such as in *BAP1*, which is known to be related to adverse prognosis.[42, 43] Interestingly, the genes coding for *BAP1* as well as *TAZ* are located on chromosome 3. Hypothesizing a link between the genetic make-up of UM and YAP/TAZ activity, we wondered if UM cells lacking BAP1 expression are more susceptible to treatment with VP, and whether CoM cells are sensitive at all.

We set out to investigate whether mRNA expression of YAP1-related genes was related to clinical, histological and genetic tumor characteristics in UM. Next, we studied the effect of YAP1-inhibition using VP without light activation on multiple UM cell lines with different genetic profiles (including cell lines with and without BAP1 expression), and included CoM cell lines with either a *BRAF* or *NRAS* mutation as a control. We show that the YAP/TAZ pathway has a higher activity in UM tissue with unfavorable genetic characteristics such as monosomy 3 (M3) / BAP1 loss. We confirm that VP inhibits growth of BAP1-positive UM cells in vitro, whereas it has limited effect on BAP1-negative cells and CoM, and observed that not only the genetic background, but other traits such as cell growth rate, were major determinants of VP response.

METHODS

Patient and tumor data

Data from two independent sets of patients with UM were analyzed. The first set was comprised of 80 patients with UM from The Cancer Genome Atlas (TCGA) project (http://cancergenome.nih.gov/). The second set was comprised of 64 patients with UM who underwent primary enucleation at the Leiden University Medical Center (The Netherlands).

From the TCGA project, data on mRNA expression were retrieved for 80 cases.[44] In this set, the median follow-up time was 26.0 months. BAP1 expression was provided as mRNA expression levels, and dichotomized at the median into BAP1-positive and BAP1-negative cases.[45]

All Leiden patients had been treated by primary enucleation between 1999 and 2008. Clinical and survival data were retrieved from patient medical files, and complemented with data from the Dutch national cancer registry (*Registratie Applicatie Nederlandse Kankerregistratie* (RANK)).

Messenger RNA was isolated from frozen tumor material for gene expression analysis using the RNeasy Mini Kit (Qiagen, Venlo, The Netherlands). The Illumina HT-12 version 4 chip was used to determine gene expression levels (Illumina, San Diego, CA, USA).

DNA was isolated for single-nucleotide polymorphism (SNP) analysis using the QIAmp DNA Mini kit (Qiagen, Venlo, The Netherlands). With the Affymetrix 250K_NSP microarray and Affymetrix Cytoscan HD chip (Affymetrix, Santa Clara, CA, USA), status of chromosome 3 was determined.[46] Status of chromosome 8q was additionally identified with digital polymerase chain reaction (dPCR).[46] BAP1 expression status was assessed by an experienced ocular pathologist with immunohistochemistry (IHC) as previously described[47] and categorized as BAP1-positive or BAP1-negative. Further details on the determination of chromosome 3 / 8q status, and IHC of BAP1 were described before.[48, 49]

The study was approved by the Biobank Committee of the Leiden University Medical Center (LUMC; 19.062.CBO/uveamelanoomlab-2019-3; B20.023). The tenets of the Declaration of Helsinki were followed.

Cell lines and culturing

Human uveal melanoma cell lines 92.1 (BAP1-pos, *GNAQ*-mut)[50], OMM1 (BAP1-pos, *GNA11*-mut)[51], Mel270 (BAP1-pos, *GNAQ*-mut)[52], XMP46 (BAP1-neg, *GNAQ*-mut)[53], MM28 (BAP1-neg, *GNA11*-mut)[53], human conjunctival melanoma cell lines CRMM1 (*BRAF*-mut)[54], CRMM2 (*NRAS*-mut)[54], and human melanoma cell line OCM3 (BAP1-pos, *BRAF*-mut)[55] were studied. An overview of studied cell lines and their genetic mutations is provided in Supplementary Table 1.[56]

Cell lines 92.1, OCM3, OMM1 and Mel270 were grown in RPMI 1640 medium (Gibco, Life Technologies Co.) supplemented with 10% fetal bovine serum (FBS; Gibco, Life Technologies Co.) and 1% antibiotics (10.000 units/ml Penicillin, 10.000 ug/ml Streptomycin; Gibco, Life Technologies Co.). Cell lines XMP46 and MM28 were grown in IMDM medium (Sigma-Aldrich, UK) supplemented with 20% FBS and 2% antibiotics. Cell lines CRMM1 and CRMM2 were grown in F-12K medium (Gibco, Life Technologies Co.) supplemented with 10% FBS and 1%

antibiotics. Cells were incubated in a humidified atmosphere of 5% CO2 at 37°C. Cells were protected from light using aluminum foil, and the experiments were performed under dimmed lights.

Investigated drugs

The investigated drug was liposomal verteporfin in phosphate buffered saline (PBS; original VP dilution 2mg/ml; Novartis AG, distributed by Valeant Ophthalmics, Bridgewater NJ, USA). As a control, PBS (Gibco, Life Technologies Co., Grand Island NY, USA) was used. Drugs or controls were added to regular cell culture medium of the respective cell lines, in concentrations as described with the experimental designs.

Viability assays

Cell viability was assessed using the Cell Counting Kit-8 (Dojindo Molecular Technologies, Rockville, MD, USA). In this assay, a tetrazolium salt (WST-8) is reduced by dehydrogenase activity into a yellow/orange formazan dye. Light absorbance thereby reflects the activity of living cells. Cells were seeded in a 96-well plate at a density of 10.000 cells per well. The following day, various concentrations of VP were added. After 3 days, all wells were gently washed with fresh medium (to remove staining from VP) and the WST-8 salt was added according to the manufacturer's guideline. Light absorbance at 450nm was measured using a microplate reader and normalized to control values. Experiments were performed in triplicate.

Growth curves

Cells were seeded in 6-well plates at a density of 300.000 cells per well. The following day, culture medium was replaced by new medium with the addition of 1.25ug/ml VP, 7.5ug/ml VP or PBS. At days 2, 4, and 6, cell numbers were determined using the trypan blue (0.4%) dye exclusion method in an automated cell counter (Invitrogen, Countess II FL). Culture medium (with drugs or control as mentioned previously) was refreshed on days 2 and 4 for the remaining wells. Experiments were performed in triplicate.

Protein expression

Cells were seeded in 6-well plates at a density of 800.000 cells per well. The following day, culture medium was replaced by new medium with the addition of 1.25ug/ml VP, 7.5ug/ml VP or PBS. After 24-hour incubation, cells were washed with ice-cold PBS and lysed with MPER with a protease and phosphatase inhibitor. Samples were sonicated for 15 seconds, and centrifugated for 20 minutes at 14.000g in a pre-cooled 4°C centrifuge. The supernatant was used for further analyses.

Per lane, 20ug of protein were loaded on a 4% to 12% Bis-Tris gel (NuPage, Invitrogen). After electrophoresis, the assay was transferred to a polyvinylidene difluoride (PVDF) membrane

(Millipore, Billerica, MA, USA). Coomassie blue staining was used to ensure equal loading. The membrane was blocked for 1 hour at room temperature in 5% milk and incubated for 3 hours with the respective primary antibodies at a 1:1000 dilution. After washing, the membrane was incubated for 1.5 hours with the respective secondary antibodies at a 1:2000 dilution. Protein expression was visualized with the ECL technique (Amersham ECL Select). Antibodies were purchased from Cell Signaling Technology (Danvers, MA, USA): YAP (4912S), TEAD1 (12292S), and c-Myc (9402S).

Statistics

Data were analyzed using SPSS version 23. The applied statistical tests were the Mann-Whitney U test (numerical parameters, 2 groups) or the Jonckheere test for trends (numerical parameters, more than 2 groups). The Spearman's rho was applied for analysis of correlations. Survival was analyzed with the Kaplan-Meier method and log-rank tests. When applicable, "high" and "low" expression of mRNA values was categorized based on the median expression values. Two-sided tests were reported, and *P* values <0.05 were considered statistically significant.

RESULTS

The YAP/TAZ pathway is related to tumor characteristics in UM

To study the activation of the YAP/TAZ pathway in human UM, we first analyzed the mRNA expression of YAP1-related genes in UM samples in two independent datasets. One set was comprised of material from 80 UM from the TCGA project, the other set of 64 UM from patients who underwent an enucleation in the LUMC (The Netherlands). In the TCGA dataset, probes were available for *YAP1*, *WWTR1* (=*TAZ*), and *TEAD1*. In the Leiden dataset, probes were available for *YAP1* and *TEAD4*, but not for the other YAP1-related genes.

Both in the TCGA and Leiden datasets, expression of YAP1-related genes did not vary based on patient age, American Joint Commission on Cancer (AJCC) stage, or tumor prominence (Table 1 and 2). In the TCGA dataset, increased *WWTR1* was associated with a greater largest basal diameter (LBD; Spearman correlation 0.323, p=0.004) and a mixed/epithelioid cell type (p=0.002). Interestingly, a higher expression of YAP1 was noticed for lightly-pigmented tumors in both data sets compared to highly-pigmented cases (TCGA: p=0.006 and Leiden: p=0.007).

YAP1-related genes are associated with unfavorable tumor genetics

As the YAP/TAZ pathway is activated by mutations in *GNAQ/11*, we examined the expression of mRNA in tumors with and without these mutations. In the TCGA dataset, tumors with either a *GNAQ* or *GNA11* mutation (n=72) did not differ in their expression of YAP1-related genes compared with tumors without these mutations (n=6; Table 1). In the Leiden dataset, the four

tumors that lacked a GNAQ/11 mutation had a higher YAP1 expression, but a similar TEAD4 expression, than the tumors with a *GNAQ/11* mutation (n=60; p=0.033 and p=0.84, respectively; see Table 2); the interpretation of this finding is hampered, however, due to low numbers of cases lacking a *GNAQ/11*-mutation.

We then tested whether YAP1 activity relates to the genetic status of UM, such as monosomy 3 (M3)/BAP1-loss, or gain of chromosome 8q, two adverse prognostic factors. In the TCGA dataset, both M3 and BAP1-loss were associated with a higher expression of *YAP1* (p=0.009 and p=0.003, respectively) and *WWTR1* (p<0.001 and p=0.001, respectively; Table 3). Although *YAP1* did not differ between M3/BAP1-loss and D3/BAP1-positive UM in the Leiden data, *TEAD4* was expressed higher in M3/BAP1-loss cases (p=0.002 and p=0.006, respectively). Gain of chromosome 8q related to a higher expression of *WWTR1* in the TCGA data (p<0.001) but a lower expression of *TEAD1* (p=0.025), whereas no association with 8q status were observed in the Leiden data. From these data, we conclude that the chromosome 3 / BAP1 status of UM is related to the expression of YAP1-related genes, with a higher activity in the prognostically-unfavorable cases.

YAP1-related genes are modestly associated with worse clinical outcome in UM

In the TCGA dataset, patients who developed metastasis had a higher expression of *WWTR1* (p=0.003) and a borderline insignificant higher expression of *YAP1* (p=0.050) compared to patients without metastases (median follow-up time 26 months) (Table 1). In the Leiden data, *YAP1* was not related to the development of metastases (p=0.31) but a higher expression of *TEAD4* was (p=0.004) (median follow-up time 62 months) (Table 2). These findings indicate that high activity of (components of) the YAP/TAZ pathway is modestly associated with a worse clinical outcome in UM.

Table 1. Clinical characteristics of the TCGA study group and mRNA expression levels of YAP1, WWTR1, and TEAD1.

CATEGORICAL	Total N=80 Cases (%)	YAP1		WWTR1		TEAD1	
		Median	p	Median	p	Median	p
Gender							
Male	45	11.0	0.659	6.8	0.652	10.6	0.476
Female	35	11.0		6.8		10.7	
TNM cat (8th)							
T1	0	NA	0.407	NA	0.092	NA	0.115
T2	14	10.9		5.8		10.8	
T3	32	10.9		6.8		10.7	
T4	34	11.1		7.0		10.6	
Pigmentation							
Light	39	11.1	0.006	6.6	0.099	10.9	<0.001
Dark	41	10.7		7.1		10.4	
Cell Type							
Spindle	43	10.9	0.092	6.1	0.002	10.7	0.904
Mixed + Epithelioid	37	11.1		7.2		10.7	
Ciliary body involvement							
No	64	10.9	0.234	6.6	0.243	10.6	0.012
Yes	16	11.0		7.1		10.9	
Metastasis							
No	53	10.8	0.050	6.5	0.006	10.7	0.552
Yes	27	11.2		7.4		10.7	
Mel.-Related Death							
No	60	10.9	0.117	6.5	0.003	10.7	0.437
Yes	20	11.2		7.4		10.6	
Necrosis							
No	63	11.0	0.568	6.6	0.256	10.7	0.381
Yes	17	10.9		7.0		10.5	
GNAQ/11 or WT							
No mutation (both WT)	6	10.9	0.574	6.95	0.285	10.78	0.139
Any GNAQ/11 mutation	72	11.0		6.65		10.65	

Table 1. Continued.

CATEGORICAL	Total N=80 Cases (%)	YAP1 Median	YAP1 p	WWTR1 Median	WWTR1 p	TEAD1 Median	TEAD1 p
GNAQ or GNA11 status*							
GNAQ-mutation	38	11.0	0.752	10.6	0.030	10.6	0.701
GNA11-mutation	34	11.0		10.7		10.7	
NUMERICAL	**Total N=80**	**Correlation Spearman**	**p**	**Correlation Spearman**	**p**	**Correlation Spearman**	**p**
Age – Median	61.5	0.007	0.953	0.032	0.778	-0.138	0.221
LBD – Median	16.0	0.085	0.461	0.323	0.004	-0.079	0.491
Prominence - Median	11.0	0.154	0.185	0.078	0.501	-0.002	0.985

The mRNA expression concerns the individual intensity of each gene.
Mel., melanoma; LBD, largest basal diameter; NA, not applicable; WT, wild type.
**Includes mutually exclusive cases only. In 6 cases, no GNAQ or GNA11 mutation was found; in 2 cases, both GNAQ and GNA11 were mutated.*

Table 2. Clinical characteristics of the Leiden study group and mRNA expression levels of YAP1 and TEAD4.

CATEGORICAL	Total N=64 Cases (%)	YAP1 Median	p	TEAD4 Median	p
Gender					
Male	33	8.3	0.234	8.0	0.043
Female	31	8.4		8.3	
TNM cat (8th)					
T1	6	8.3	0.173	8.1	0.100
T2	25	8.4		8.0	
T3	31	8.3		8.1	
T4	2	8.1		8.1	
Pigmentation					
Light	43	8.4	0.007	8.2	0.469
Dark	20	8.2		8.0	
Cell Type					
Spindle	22	8.3	0.932	8.1	0.745
Mixed + Epithelioid	42	8.3		8.1	
Ciliary body involvement					
No	40	8.4	0.031	8.0	0.230
Yes	23	8.3		8.2	
Metastasis					
No	27	8.4	0.305	8.0	0.004
Yes	37	8.3		8.2	
Mel.-Related Death					
No	27	8.4	0.305	8.0	0.004
Yes	37	8.3		8.2	
Necrosis					
No	38	8.2	0.008	8.0	0.318
Yes	26	8.5		8.2	
GNAQ/11 or WT					
No mutation (both WT)	4	8.6	0.033	8.0	0.841
Any GNAQ/11 mutation	60	8.3		8.1	
GNAQ or GNA11 status*					
GNAQ-mutation	28	8.3	0.468	8.1	0.424
GNA11-mutation	32	8.3		8.1	

Table 2. Continued.

NUMERICAL	Total N=64	Correlate		Correlate	
		Spearman	p	Spearman	p
Age – Median	61.6	0.040	0.751	0.052	0.684
LBD – Median	13.0	-0.148	0.244	0.203	0.107
Prominence - Median	8.0	-0.171	0.176	0.178	0.160

The mRNA expression concerns the individual intensity of each gene.

Mel., melanoma; LBD, largest basal diameter; NA, not applicable; WT, wild type.

** Includes mutually exclusive cases only. In 4 cases, no GNAQ or GNA11 mutation was found.*

Table 3. mRNA expression of YAP1-related genes related to status of chromosome 3 and 8q, and BAP1 protein.

	TCGA data							Leiden data				
	n=80	YAP1		WWTR1		TEAD1		n=54	YAP1		TEAD4	
	Cases (%)	Median	*p*	Median	*p*	Median	*p*	Cases (%)	Median	*p*	Median	*p*
Chromosome 3												
Disomy	37 (46)	10.7	0.009	5.7	<0.001	10.8	0.020	20	8.4	0.986	7.9	0.002
Monosomy	37 (46)	11.1		7.4		10.5		34	8.4		8.2	
Chromosome 8q												
Normal	21 (26)	11.1	0.403	5.2	<0.001	10.9	0.025	13	8.4	0.326	8.0	0.213
Gain	59 (74)	10.9		7.2		10.6		41	8.3		8.1	
BAP1 expression												
Negative	40 (50)	11.1	0.003	7.3	0.001	10.6	0.191	30	8.4	0.169	8.2	0.006
Positive	40 (50)	10.7		6.0		10.8		24	8.3		7.9	

The mRNA expression concerns the individual intensity of each gene.

VP inhibits cell growth in a dose-dependent manner in cell lines with a GNAQ/11 mutation, but not in cell lines with a BRAF/NRAS mutation.

Next, we studied the effect of YAP/TAZ inhibition in UM and CoM cell lines using VP without light activation. First, we analyzed the inhibitory effect of VP treatment on BAP1-positive UM cell lines with a mutation in *GNAQ* or *GNA11*. Following 3 days of incubation with VP, UM cell lines 92.1 (*GNAQ-mut*), OMM1 (*GNA11-mut*) and Mel270 (*GNAQ-mut*) demonstrated more cell death with increased dosages of VP (Fig. 1A, 1C, 1E). When cultured for a total of 6 days, a low dose of VP was noticed to have only a minor effect on cell growth, whereas a high dose caused complete inhibition (Fig. 1B, 1D, 1F).

We compared the results in the UM cell lines with the effect on cell lines with a *BRAF* or *NRAS* mutation (i.e. melanoma cell line OCM3 [*BRAF-mut*] and the CoM cell lines CRMM1 [*BRAF-mut*] and CRMM2 [*NRAS-mut*]. Cell line OCM3 was sensitive to VP treatment at higher doses, with a remarkable drop in cell viability after treatment for 3 days with >2ug/ml (Fig. 2A). This could point at nonspecific toxicity of VP rather than a specific effect due to YAP1 inhibition. Both CoM cell lines were not sensitive to VP even at high doses, showing unaltered cell viability (Fig. 2C, 2E). Although the growth curves of CRMM1 and CRMM2 demonstrate a reduced growth speed with high dose VP administration, cell counts were not reduced to zero (Fig. 2D, 2F).

UM cell lines lacking BAP1 expression are not sensitive to treatment with VP

As we had noticed that UM tissues with M3/BAP1-loss show a higher mRNA expression of actors in the YAP1 pathway, we now compared the susceptibility of BAP1-expressing and BAP1-negative UM cell lines to VP.

We included two recently developed UM cell lines with a *GNAQ/11* mutation, which lack expression of BAP1 (i.e. cell line MM28 [*GNA11-mut*, BAP1-neg] and cell line XMP46 [*GNAQ-mut*, BAP1-neg]. Viability assays demonstrated a relative tolerance for VP at low dosages, whereas a dose-dependent decrease of viability tended to occur in both cell lines at dosages >4ug/ml VP (Fig. 3A, 3C), however with a smaller effect than in the BAP1-positive UM cell lines.

Remarkably, cell growth experiments demonstrated that the cell numbers of the BAP1-negative cell lines were little affected by either low or high VP concentrations. It should be noticed, however, that these cell lines grew at a much slower rate than the other lines (Fig. 3B, 3D). As the YAP1 pathway is involved in growth, an absence of robust growth may cause insensitivity to YAP1 inhibition. To our knowledge, no fast-growing BAP1-negative UM cell lines exist.

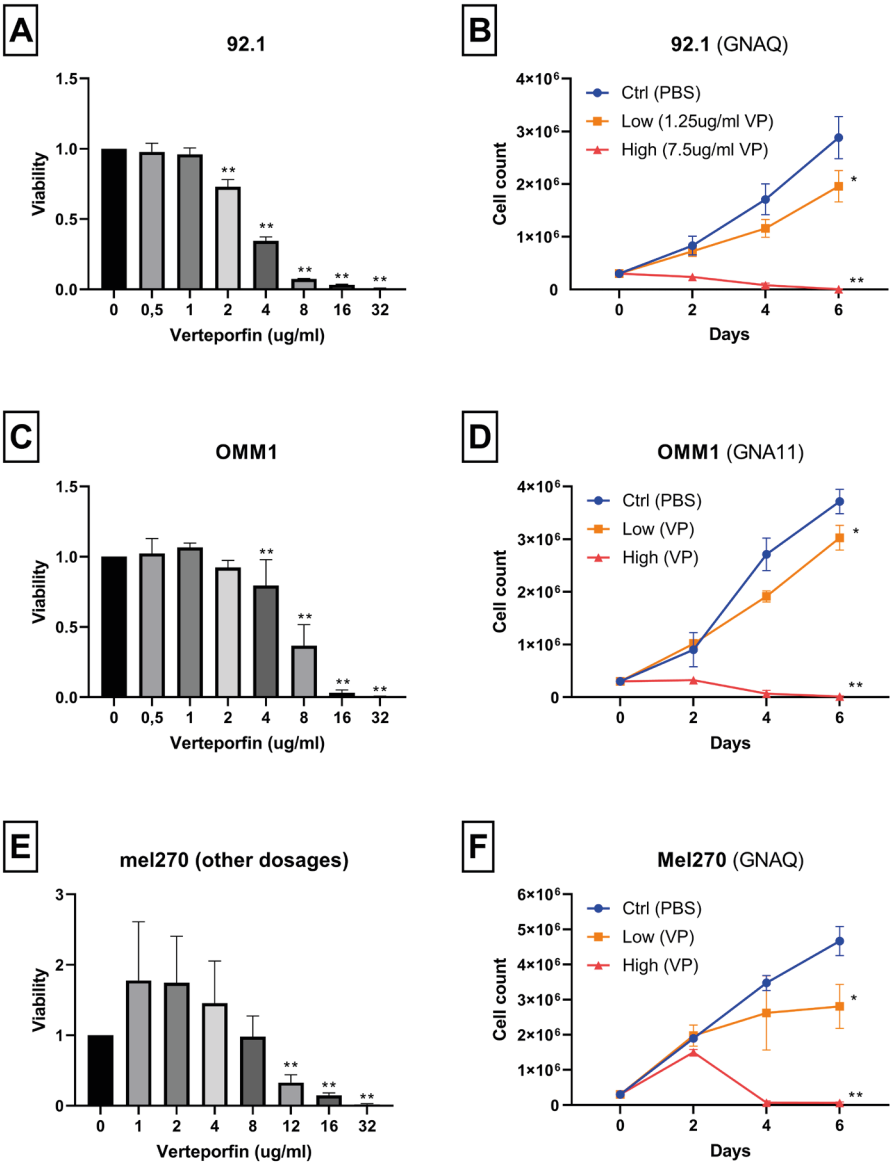

Figure 1. Viability and cell growth after verteporfin treatment. (**A, B**) UM cell line 92.1: *GNAQ*-mutation, BAP1-positive. (**C, D**) UM cell line OMM1: *GNA11*-mutation, BAP1-positive. (**E, F**) UM cell line Mel270: *GNAQ*-mutation, BAP1-positive. Values show mean ± SD of three experiments. In A, C, and E, measurements at each concentration of VP were compared to 0ug/ml; in B, D, and E, cell counts at the final day were compared between control and low, and between control and high concentrations. The *P* values are indicated by * ($p<0.05$) or ** ($p<0.01$).

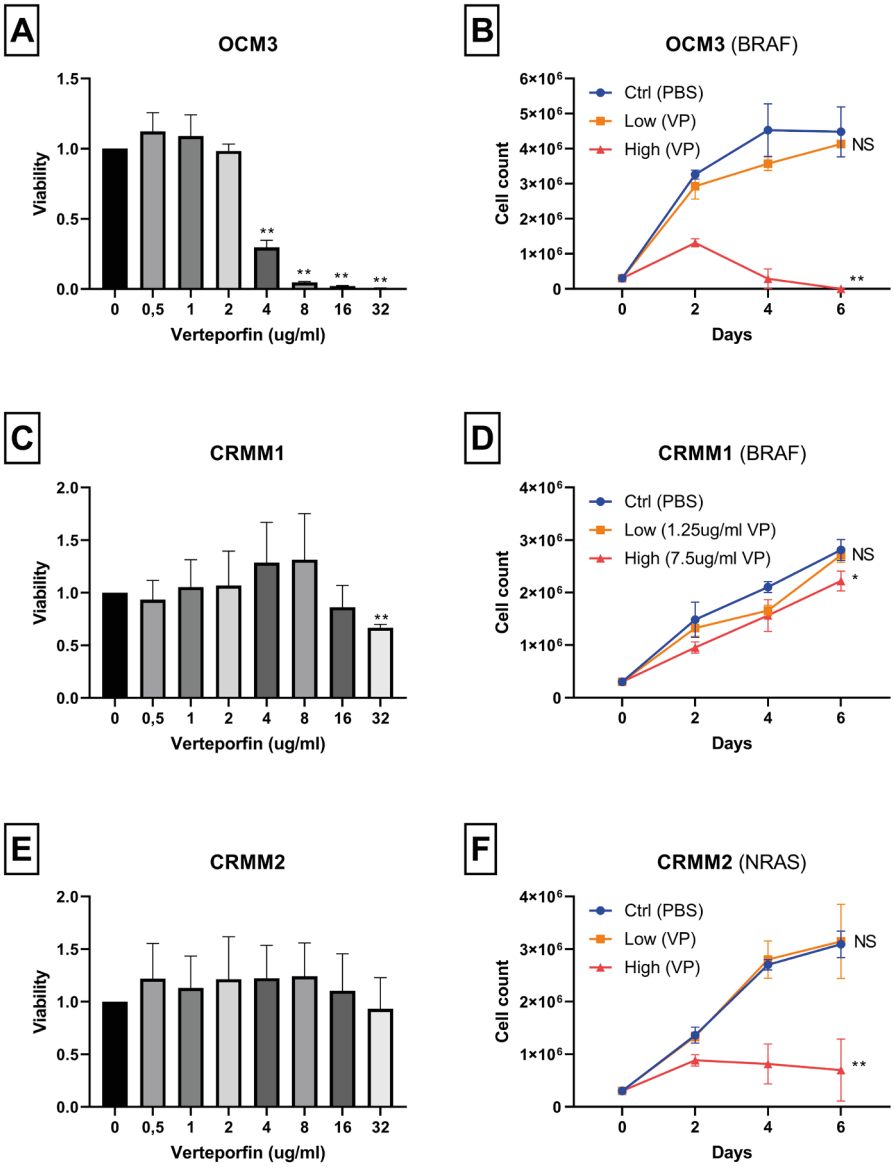

Figure 2. Viability and cell growth after verteporfin treatment. (**A, B**) melanoma cell line OCM3: *BRAF*-mutation. (**C, D**) CoM cell line CRMM1: *BRAF*-mutation. (**E, F**) CoM cell line CRMM2: *NRAS*-mutation. Values show mean ± SD of three experiments. In A, C, and E, measurements at each concentration of VP were compared to 0ug/ml; in B, D, and E, cell counts at the final day were compared between control and low, and between control and high concentrations. The *P* values are indicated by * ($p<0.05$), ** ($p<0.01$) or not significant (NS) ($p>0.05$).

Not only the genetic background, but also cell growth rate predicts susceptibility for VP of the various cell lines

To examine the effect of growth rate on the susceptibility of cell lines to VP, we plotted the LD50 (as determined with the viability tests) against the doubling time (as determined with the cell growth experiments) of all cell lines. Three clusters of cells could be identified: (1) high doubling time and high LD50 (i.e. slow growing, insensitive to VP); (2) low doubling time and high LD50 (i.e. fast growing, insensitive to VP); and (3) low doubling time and low LD50 (i.e. fast growing, sensitive to VP). Cluster 1 comprises the BAP1-negative UM cell lines (XMP46 and MM28). Cluster 2 comprises the CoM cell lines (CRMM1 and CRMM2). Cluster 3 comprises the other, BAP1-positive, UM cell lines (92.1, MEL270, and OMM1) and melanoma cell line (OCM3; Fig. 4).

It can be deduced that, in order to be susceptible to VP, cell lines need a certain amount of cell growth, and a *GNAQ/11* mutation may lower the threshold for VP sensitivity.

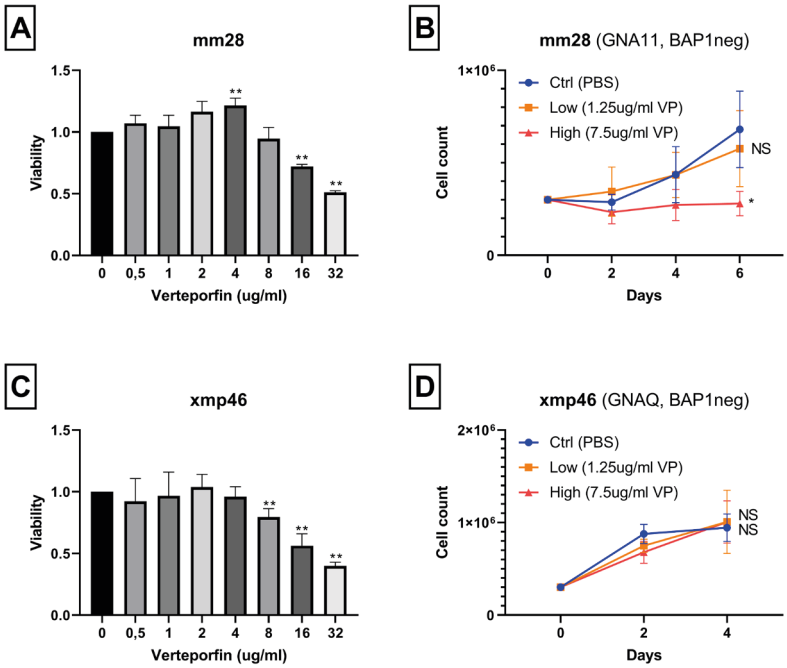

Figure 3. Viability and cell growth after verteporfin treatment. (**A, B**) UM cell line mm28: *GNA11*-mutation, BAP1-negative. (**C, D**) UM Cell line xmp46: *GNAQ*-mutation, BAP1-negative. Values show mean ± SD of three experiments. In A and C, measurements at each concentration of VP were compared to 0ug/ml; in B and D, cell counts at the final day were compared between control and low, and between control and high concentrations. The *P* values are indicated by * ($p<0.05$), ** ($p<0.01$) or not significant (NS) ($p>0.05$).

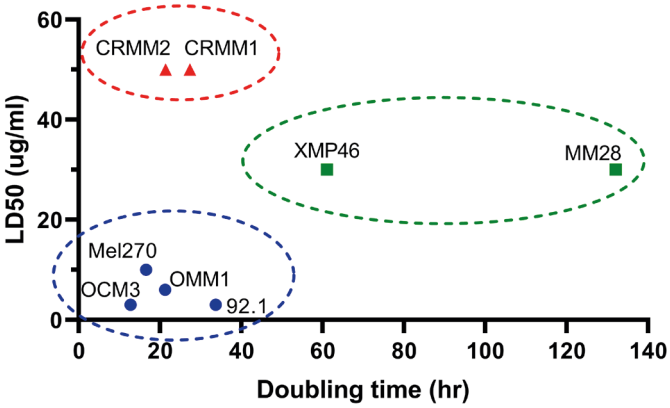

Figure 4. Doubling Time and LD50 for each studied cell line. Cell growth doubling time was based on non-VP-treated cells in our specific experimental conditions. LD50 for VP was based on VP treatment at various dosages for each cell line. Values for CRMM1 and CRMM2 were arbitrarily cut off at a maximum of 50 ug/ml. Three clusters can be identified: A (Red), CoM cell lines (*BRAF*/*NRAS*-mut). B (Green), UM cell lines (BAP1-neg, *GNAQ*/*11*-mut). C (Blue), UM cell lines (BAP1-pos, *GNAQ*/*11*-mut) and cutaneous melanoma cell line (*BRAF*-mut).

Protein expression of YAP/TEAD and downstream actors CMYC/CYR61 follows cell viability

To further understand the effects of VP on melanoma cells and the YAP/TAZ pathway in various cell lines, we performed Western Blot analyses of YAP, TEAD, and downstream target CMYC. Cell lines were cultured for 24 hours with a low dose liposomal VP in PBS (1.25ug/ml), high dose liposomal VP in PBS (7.5ug/ml), or control (PBS).

All BAP1-positive, *GNAQ*/*11*-mutant UM cell lines demonstrated a reduction of YAP, TEAD and CMYC upon VP administration. This was similarly seen in cell line OCM3 (*BRAF*-mut) and to some extent in the *NRAS*-mutated cell line CRMM2. The rest of the cell lines (*BRAF*-mutated cell line CRMM1, and slow-growing BAP1-negative cell lines MM28 and XMP46) demonstrated little or no reduction of YAP, TEAD, or CMYC upon VP administration (Supplementary Figure 1).

DISCUSSION

We observed that expression of several YAP/TAZ-related genes correlated with tumor genetics in UM, with a higher activity in M3/BAP1-negative lesions, although the prognostic value of the YAP/TAZ pathway was limited. Although most UM cell lines were sensitive to VP, two BAP1-negative

UM cell lines, as well as two *BRAF/NRAS*-mutated CoM cell lines, were not. We found that not only the mutational background of the studied genes, but also cell growth rate was an important predictor of YAP/TAZ inhibition by VP, with a slow growth rate relating to VP insensitivity.

To our knowledge, we are the first to extensively relate the YAP1 pathway to genetic characteristics of UM, using a large set of patients with UM. When comparing mRNA expression of YAP1-related genes with clinical and genetic determinants, we found a higher expression level in UM with M3/BAP1-loss. The prognostic value of YAP1-related mRNA expression was limited, however, with only a high expression of *WWTR1* being significantly related to metastasis development. A recent study on mRNA data of the TCGA project on UM similarly identified no relation between *YAP1* gene expression and survival, but did not report on *WWTR1* or the relation with the genetic makeup of the tumors.[41]

Our experiments showed that exposure to VP decreased cell viability in BAP1-positive UM cell lines harboring mutations in *GNAQ/11*, as has been reported before.[35, 57] A mutation in *GNAQ/11* was no exclusive predictor of a response to VP, however, as we report on cell lines with a *GNAQ/11* mutation without a clear response (MM28 and MP46), and a cell line lacking *GNAQ/11* mutations that did demonstrate decreased survival (OCM3). We noticed that the non-responding cell lines had a slower growth rate compared to the responding ones, and we hypothesize that this may have been limiting the susceptibility for YAP1-inhibition.

We expected that BAP1-negative UM cell lines would be more susceptible to YAP1-inhibition, because the YAP1 pathway was upregulated in BAP1-loss UM. Unexpectedly, these cell lines demonstrated very little response to VP; however, we noticed a remarkable slower growth rate compared to the BAP1-positive UM cell lines. An alternative explanation is that BAP1-loss results in YAP/TAZ pathway insensitivity, or that BAP1-loss causes a YAP1-independent growth disadvantage.

We also studied cell lines lacking a mutation in *GNAQ/11*. We identified no convincing effect of VP in the two CoM cell lines with either a *BRAF* or *NRAS* mutation (CRMM1 and CRMM2), whereas the cutaneous melanoma cell line OCM3 did show a response to VP. Notably, the growth rate of OCM3 was higher than that of CRMM1 and CRMM2. In line with our findings, previous work by Yu et al. showed a limited, yet present, response to VP for cell line OCM3, with about a halving of cell count compared to control after 3 days of treatment with high-dose VP.[35] Our results may be more pronounced due to a longer, 6 day, treatment and addition of FBS to the cell culture medium (that is known to activate the Hippo pathway),[58] but both studies confirm that cell lines lacking a *GNAQ/11*-mutation may be affected by VP.

As a treatment for UM, we concur with others reporting on the potential benefit of VP in preclinical models. Clinical experience shows that BAP1-mutated UM show more aggressive characteristics than BAP1-wildtype UM, however, which is opposite to the in vitro behavior of our cell line model with BAP1-loss. Unfortunately, no fast-growing UM cell line models lacking BAP1 are available. It would therefore still be interesting to test the susceptibility of BAP1-negative cells in vivo to VP treatment. It has been suggested that targeting the YAP1-pathway alone may not be the most effective route to attack UM, and that combined treatment aimed at the *GNAQ/11* pathway and other pathways such as *BAP1,*[59] or at others[19] would be more effective. Indeed, as VP only targets one arm of the G-coupled receptor network, it may be necessary to target multiple upstream nodal points to fully block the YAP1-pathway and it is likely that combinations of drugs are needed.[19]

Being the first to study VP in CoM, our results are not supportive for VP as a single-agent therapy in this disease. This may resemble earlier work on cutaneous melanoma cell lines that demonstrated mixed responses to YAP/TAZ inhibition: whereas reduced cell growth and reduced YAP/TAZ protein levels were reported after VP,[35, 39] inhibiting YAP/TAZ in cutaneous melanoma cell lines via shRNA, demonstrated no effect on proliferation in vitro.[40] Similarly, whereas cutaneous melanoma xenograft mouse models demonstrated no tumor response to VP in one study,[39] another study using shRNA inhibition of YAP/TAZ did identify a decreased in vitro invasiveness and less metastases formation in mice.[40]

A strength of our study is the availability of data on mRNA expression and genetic status of a large number of UM cases. We were also able to test a broad panel of cell lines, representing various mutational backgrounds of UM and CoM. Some conflicting findings were observed between mRNA expression of YAP-related genes in the TCGA data and Leiden data. This may be due to differences in the study group, as UM in the Leiden cohort were somewhat smaller than those analyzed in the TCGA project, which may have influenced YAP1 activity.

An interesting matter in cell line studies is whether cell lines mimic the traits of their original tumor type,[56] and whether in vitro findings correspond to the in vivo situation. In our study, we find that YAP1-related genes are differentially expressed in UM tissue based on genetic traits (such as BAP1 loss). Because protein expression in our cell culture work was assessed using separate experiments, we cannot formally conclude on a differential baseline YAP1 expression between individual BAP1-positive and BAP1-negative cell lines. Importantly, all studied cell lines expressed YAP1 protein, allowing assessment of inhibition following VP treatment (Supplementary Figure 1), which was the aim of this study. The relevance of different baseline YAP1 expression levels between cell lines are difficult to assess, because external stimuli influence hippo-pathway activity,[38] which is not modelled fully in vitro.

Interestingly, the YAP/TAZ pathway has recently been linked to mechanisms of resistance against targeted therapy and escape against immunotherapy in cancer.[60, 61] Upregulation of the YAP/TAZ pathway was found in cutaneous melanoma tissue of patients who developed resistance to BRAF-inhibitor or RAF+MEK-inhibitor therapy.[62, 63] Similar to these findings in cutaneous melanoma, upregulation of the YAP1 pathway was found in UM models after MEK-inhibition.[64]

Upregulation of the YAP/TAZ pathway has also been linked to several immune-suppressing effects, relevant for immunotherapy. YAP1 expression was positively associated with PD-L1 expression in samples of cutaneous melanoma, creating an escape for destruction by CD8+ T cells.[65] Increased YAP1 was associated with lower expression of CD8, HLA class I molecules and TAP1 in cutaneous melanoma tissue, similarly pointing towards decreased immune recognition. [62]

Blocking the YAP/TAZ pathway may be beneficial to overcome MAPK-inhibitor resistance, as YAP/TAZ knockdown restored sensitivity to BRAF-inhibitors in previously-resistant cutaneous melanoma cell lines,[66] and VP caused reduced tumor formation in a mouse model with BRAF-inhibitor-resistant skin melanoma cells.[67] Even so, knockdown of YAP and TAZ caused reduced expression of PD-L1 in cutaneous melanoma cell lines,[65] which would theoretically make these cells more vulnerable to CD8+ T cell attack.

The true future application of YAP/TAZ inhibition (as with VP) may therefore possibly not be as a single-agent therapy to any type of melanoma, but as an additive to other (targeted or immuno-) therapies. This would be beneficial in the treatment of UM as well as CoM, mirroring the findings from cutaneous melanoma.

Concluding, expression of YAP/TAZ-related genes correlated with tumor genetics in UM, with a higher activity in M3/BAP1-negative lesions. The prognostic value of YAP1-related gene expression on metastasis development was limited. Although most UM cell lines responded in vitro to VP, BAP1-negative UM cell lines and CoM cell lines did not. We find that not only the mutational background of the studied genes, but also cell growth rate is an important predictor of YAP/TAZ inhibition by VP. Our study implies a potential role for the YAP1 pathway as therapeutic target in UM, but finds a limited role for single-agent therapy in CoM. YAP1 inhibition may be used as a cotreatment with both targeted and immunotherapy, to overcome mechanisms of resistance and escape.

Funding: Supported by: Stichting LOOF, Stichting Nelly Reef Fund, Foundation "De Drie Lichten", Stichting Blindenhulp, Stichting tot Verbetering van het Lot der Blinden, Rotterdamse Stichting Blindenbelangen, Landelijke Stichting voor Blinden en Slechtzienden, Stichting PG Binkhorst, Leids Universiteits Fonds / P.A. Jager-van Gelder Fonds.

Disclosures: **N. Brouwer**, None; **E. Konstantinou**, None; **E.S. Gragoudas**, None; **M. Marinkovic**, None, **G.P.M. Luyten**, None; **I.K. Kim**, Castle Biosciences (C), Kodiak Sciences (C), Novartis (C), Biophytis (C), **M.J. Jager**, None; **D.G. Vavvas**, None.

REFERENCES

1. Singh AD, Turell ME, Topham AK. Uveal melanoma: trends in incidence, treatment, and survival. *Ophthalmology* 2011;118:1881-1885.
2. Egan KM, Seddon JM, Glynn RJ, Gragoudas ES, Albert DM. Epidemiologic aspects of uveal melanoma. *Surv Ophthalmol* 1988;32:239-251.
3. Kaliki S, Shields CL. Uveal melanoma: relatively rare but deadly cancer. *Eye (Lond)* 2017;31:241-257.
4. Gragoudas ES. Proton beam irradiation of uveal melanomas: the first 30 years. The Weisenfeld Lecture. *Invest Ophthalmol Vis Sci* 2006;47:4666-4673.
5. Hawkins BS. The Collaborative Ocular Melanoma Study (COMS) randomized trial of pre-enucleation radiation of large choroidal melanoma: IV. Ten-year mortality findings and prognostic factors. COMS report number 24. *Am J Ophthalmol* 2004;138:936-951.
6. Damato B. Progress in the management of patients with uveal melanoma. The 2012 Ashton Lecture. *Eye (Lond)* 2012;26:1157-1172.
7. Lane AM, Kim IK, Gragoudas ES. Survival Rates in Patients After Treatment for Metastasis From Uveal Melanoma. *JAMA Ophthalmol* 2018;136:981-986.
8. Tuomaala S, Eskelin S, Tarkkanen A, Kivela T. Population-based assessment of clinical characteristics predicting outcome of conjunctival melanoma in whites. *Invest Ophthalmol Vis Sci* 2002;43:3399-3408.
9. Yu GP, Hu DN, McCormick S, Finger PT. Conjunctival melanoma: is it increasing in the United States? *Am J Ophthalmol* 2003;135:800-806.
10. Triay E, Bergman L, Nilsson B, All-Ericsson C, Seregard S. Time trends in the incidence of conjunctival melanoma in Sweden. *Br J Ophthalmol* 2009;93:1524-1528.
11. Wong JR, Nanji AA, Galor A, Karp CL. Management of conjunctival malignant melanoma: a review and update. *Expert Rev Ophthalmol* 2014;9:185-204.
12. Shields CL. Conjunctival melanoma: risk factors for recurrence, exenteration, metastasis, and death in 150 consecutive patients. *Trans Am Ophthalmol Soc* 2000;98:471-492.
13. Brouwer NJ, Marinkovic M, van Duinen SG, Bleeker JC, Jager MJ, Luyten GPM. Treatment of conjunctival melanoma in a Dutch referral centre. *Br J Ophthalmol* 2018;102:1277-1282.
14. Anastassiou G, Heiligenhaus A, Bechrakis N, Bader E, Bornfeld N, Steuhl KP. Prognostic value of clinical and histopathological parameters in conjunctival melanomas: a retrospective study. *Br J Ophthalmol* 2002;86:163-167.
15. Van Raamsdonk CD, Bezrookove V, Green G, et al. Frequent somatic mutations of GNAQ in uveal melanoma and blue naevi. *Nature* 2009;457:599-602.
16. Van Raamsdonk CD, Griewank KG, Crosby MB, et al. Mutations in GNA11 in uveal melanoma. *N Engl J Med* 2010;363:2191-2199.
17. Moore AR, Ceraudo E, Sher JJ, et al. Recurrent activating mutations of G-protein-coupled receptor CYSLTR2 in uveal melanoma. *Nat Genet* 2016;48:675-680.
18. Johansson P, Aoude LG, Wadt K, et al. Deep sequencing of uveal melanoma identifies a recurrent mutation in PLCB4. *Oncotarget* 2016;7:4624-4631.
19. Smit KN, Jager MJ, de Klein A, Kili E. Uveal melanoma: Towards a molecular understanding. *Prog Retin Eye Res* 2019;100800.
20. Spendlove HE, Damato BE, Humphreys J, Barker KT, Hiscott PS, Houlston RS. BRAF mutations are detectable in conjunctival but not uveal melanomas. *Melanoma Res* 2004;14:449-452.
21. Griewank KG, Murali R, Schilling B, et al. TERT promoter mutations in ocular melanoma distinguish between conjunctival and uveal tumours. *Br J Cancer* 2013;109:497-501.

22. Beadling C, Jacobson-Dunlop E, Hodi FS, et al. KIT gene mutations and copy number in melanoma subtypes. *Clin Cancer Res* 2008;14:6821-6828.
23. Scholz SL, Cosgarea I, Susskind D, et al. NF1 mutations in conjunctival melanoma. *Br J Cancer* 2018;118:1243-1247.
24. Griewank KG, Westekemper H, Murali R, et al. Conjunctival melanomas harbor BRAF and NRAS mutations and copy number changes similar to cutaneous and mucosal melanomas. *Clin Cancer Res* 2013;19:3143-3152.
25. Swaminathan SS, Field MG, Sant D, et al. Molecular Characteristics of Conjunctival Melanoma Using Whole-Exome Sequencing. *JAMA Ophthalmol* 2017;135:1434-1437.
26. Rodrigues M, Koning L, Coupland SE, et al. So Close, yet so Far: Discrepancies between Uveal and Other Melanomas. A Position Paper from UM Cure 2020. *Cancers (Basel)* 2019;11.
27. Moroishi T, Hansen CG, Guan KL. The emerging roles of YAP and TAZ in cancer. *Nat Rev Cancer* 2015;15:73-79.
28. Meng Z, Moroishi T, Guan KL. Mechanisms of Hippo pathway regulation. *Genes Dev* 2016;30:1-17.
29. Menzel M, Meckbach D, Weide B, et al. In melanoma, Hippo signaling is affected by copy number alterations and YAP1 overexpression impairs patient survival. *Pigment Cell Melanoma Res* 2014;27:671-673.
30. Feng Q, Guo P, Kang S, Zhao F. High expression of TAZ/YAP promotes the progression of malignant melanoma and affects the postoperative survival of patients. *Pharmazie* 2018;73:662-665.
31. Miller JW. Higher irradiance and photodynamic therapy for age-related macular degeneration (an AOS thesis). *Trans Am Ophthalmol Soc* 2008;106:357-382.
32. Liu-Chittenden Y, Huang B, Shim JS, et al. Genetic and pharmacological disruption of the TEAD-YAP complex suppresses the oncogenic activity of YAP. *Genes Dev* 2012;26:1300-1305.
33. Brodowska K, Al-Moujahed A, Marmalidou A, et al. The clinically used photosensitizer Verteporfin (VP) inhibits YAP-TEAD and human retinoblastoma cell growth in vitro without light activation. *Exp Eye Res* 2014;124:67-73.
34. Al-Moujahed A, Brodowska K, Stryjewski TP, et al. Verteporfin inhibits growth of human glioma in vitro without light activation. *Sci Rep* 2017;7:7602.
35. Yu FX, Luo J, Mo JS, et al. Mutant Gq/11 promote uveal melanoma tumorigenesis by activating YAP. *Cancer Cell* 2014;25:822-830.
36. Feng X, Degese MS, Iglesias-Bartolome R, et al. Hippo-independent activation of YAP by the GNAQ uveal melanoma oncogene through a trio-regulated rho GTPase signaling circuitry. *Cancer Cell* 2014;25:831-845.
37. Dratviman-Storobinsky O, Cohen Y, Frenkel S, Pe'er J, Goldenberg-Cohen N. Lack of oncogenic GNAQ mutations in melanocytic lesions of the conjunctiva as compared to uveal melanoma. *Invest Ophthalmol Vis Sci* 2010;51:6180-6182.
38. Liu H, Du S, Lei T, et al. Multifaceted regulation and functions of YAP/TAZ in tumors (Review). *Oncol Rep* 2018;40:16-28.
39. Lui JW, Xiao S, Ogomori K, Hammarstedt JE, Little EC, Lang D. The Efficiency of Verteporfin as a Therapeutic Option in Pre-Clinical Models of Melanoma. *J Cancer* 2019;10:1-10.
40. Nallet-Staub F, Marsaud V, Li L, et al. Pro-invasive activity of the Hippo pathway effectors YAP and TAZ in cutaneous melanoma. *J Invest Dermatol* 2014;134:123-132.
41. Kim YJ, Lee SC, Kim SE, Kim SH, Kim SK, Lee CS. YAP Activity is Not Associated with Survival of Uveal Melanoma Patients and Cell Lines. *Sci Rep* 2020;10:6209.
42. van Essen TH, van Pelt SI, Versluis M, et al. Prognostic parameters in uveal melanoma and their association with BAP1 expression. *Br J Ophthalmol* 2014;98:1738-1743.
43. Harbour JW, Onken MD, Roberson ED, et al. Frequent mutation of BAP1 in metastasizing uveal melanomas. *Science* 2010;330:1410-1413.

44. Robertson AG, Shih J, Yau C, et al. Integrative Analysis Identifies Four Molecular and Clinical Subsets in Uveal Melanoma. *Cancer Cell* 2017;32:204-220 e215.
45. Gezgin G, Dogrusöz M, van Essen TH, et al. Genetic evolution of uveal melanoma guides the development of an inflammatory microenvironment. *Cancer Immunol Immunother* 2017;66:903-912.
46. Versluis M, de Lange MJ, van Pelt SI, et al. Digital PCR validates 8q dosage as prognostic tool in uveal melanoma. *PLoS One* 2015;10:e0116371.
47. Koopmans AE, Verdijk RM, Brouwer RW, et al. Clinical significance of immunohistochemistry for detection of BAP1 mutations in uveal melanoma. *Mod Pathol* 2014;27:1321-1330.
48. Brouwer NJ, Wierenga APA, Gezgin G, et al. Ischemia Is Related to Tumour Genetics in Uveal Melanoma. *Cancers (Basel)* 2019;11.
49. Brouwer NJ, Gezgin G, Wierenga APA, et al. Tumour Angiogenesis in Uveal Melanoma Is Related to Genetic Evolution. *Cancers (Basel)* 2019;11.
50. De Waard-Siebinga I, Blom DJ, Griffioen M, et al. Establishment and characterization of an uveal-melanoma cell line. *Int J Cancer* 1995;62:155-161.
51. Luyten GP, Naus NC, Mooy CM, et al. Establishment and characterization of primary and metastatic uveal melanoma cell lines. *Int J Cancer* 1996;66:380-387.
52. Verbik DJ, Murray TG, Tran JM, Ksander BR. Melanomas that develop within the eye inhibit lymphocyte proliferation. *Int J Cancer* 1997;73:470-478.
53. Amirouchene-Angelozzi N, Nemati F, Gentien D, et al. Establishment of novel cell lines recapitulating the genetic landscape of uveal melanoma and preclinical validation of mTOR as a therapeutic target. *Mol Oncol* 2014;8:1508-1520.
54. Nareyeck G, Wuestemeyer H, von der Haar D, Anastassiou G. Establishment of two cell lines derived from conjunctival melanomas. *Exp Eye Res* 2005;81:361-362.
55. Huang XQ, Mitchell MS, Liggett PE, Murphree AL, Kan-Mitchell J. Non-fastidious, melanoma-specific CD8+ cytotoxic T lymphocytes from choroidal melanoma patients. *Cancer Immunol Immunother* 1994;38:399-405.
56. Jager MJ, Magner JA, Ksander BR, Dubovy SR. Uveal Melanoma Cell Lines: Where do they come from? (An American Ophthalmological Society Thesis). *Trans Am Ophthalmol Soc* 2016;114:T5.
57. Ma YW, Liu YZ, Pan JX. Verteporfin induces apoptosis and eliminates cancer stem-like cells in uveal melanoma in the absence of light activation. *Am J Cancer Res* 2016;6:2816-2830.
58. Miller E, Yang J, DeRan M, et al. Identification of serum-derived sphingosine-1-phosphate as a small molecule regulator of YAP. *Chem Biol* 2012;19:955-962.
59. Field MG, Harbour JW. GNAQ/11 mutations in uveal melanoma: is YAP the key to targeted therapy? *Cancer Cell* 2014;25:714-715.
60. Lin L, Bivona TG. The Hippo effector YAP regulates the response of cancer cells to MAPK pathway inhibitors. *Mol Cell Oncol* 2016;3:e1021441.
61. Shibata M, Ham K, Hoque MO. A time for YAP1: Tumorigenesis, immunosuppression and targeted therapy. *Int J Cancer* 2018;143:2133-2144.
62. Hugo W, Shi H, Sun L, et al. Non-genomic and Immune Evolution of Melanoma Acquiring MAPKi Resistance. *Cell* 2015;162:1271-1285.
63. Lin L, Sabnis AJ, Chan E, et al. The Hippo effector YAP promotes resistance to RAF- and MEK-targeted cancer therapies. *Nat Genet* 2015;47:250-256.
64. Faiao-Flores F, Emmons MF, Durante MA, et al. HDAC Inhibition Enhances the In Vivo Efficacy of MEK Inhibitor Therapy in Uveal Melanoma. *Clin Cancer Res* 2019;25:5686-5701.
65. Kim MH, Kim CG, Kim SK, et al. YAP-Induced PD-L1 Expression Drives Immune Evasion in BRAFi-Resistant Melanoma. *Cancer Immunol Res* 2018;6:255-266.

66. Kim MH, Kim J, Hong H, et al. Actin remodeling confers BRAF inhibitor resistance to melanoma cells through YAP/TAZ activation. *Embo j* 2016;35:462-478.
67. Fisher ML, Grun D, Adhikary G, Xu W, Eckert RL. Inhibition of YAP function overcomes BRAF inhibitor resistance in melanoma cancer stem cells. *Oncotarget* 2017;8:110257-110272.
68. Folberg R, Kadkol SS, Frenkel S, et al. Authenticating cell lines in ophthalmic research laboratories. *Invest Ophthalmol Vis Sci* 2008;49:4697-4701.
69. Griewank KG, Yu X, Khalili J, et al. Genetic and molecular characterization of uveal melanoma cell lines. *Pigment Cell Melanoma Res* 2012;25:182-187.
70. de Waard NE, Cao J, McGuire SP, et al. A Murine Model for Metastatic Conjunctival Melanoma. *Invest Ophthalmol Vis Sci* 2015;56:2325-2333.
71. Bailey FP, Clarke K, Kalirai H, et al. Kinome-wide transcriptional profiling of uveal melanoma reveals new vulnerabilities to targeted therapeutics. *Pigment Cell Melanoma Res* 2018;31:253-266.
72. White JS, Becker RL, McLean IW, Director-Myska AE, Nath J. Molecular cytogenetic evaluation of 10 uveal melanoma cell lines. *Cancer Genet Cytogenet* 2006;168:11-21.
73. Nareyeck G, Zeschnigk M, Prescher G, Lohmann DR, Anastassiou G. Establishment and characterization of two uveal melanoma cell lines derived from tumors with loss of one chromosome 3. *Exp Eye Res* 2006;83:858-864.
74. Mosbeh A, Halfawy K, Abdel-Mageed WS, Sweed D, Rahman MHA. Nuclear BAP1 loss is common in intrahepatic cholangiocarcinoma and a subtype of hepatocellular carcinoma but rare in pancreatic ductal adenocarcinoma. *Cancer Genet* 2018;224-225:21-28.

SUPPLEMENTARY MATERIAL

Supplementary Table 1. Characteristics of studied cell lines.

Cell line	92.1	Mel270	OMM1	XMP46	MM28	OCM3	CRMM1	CRMM2
Origin	UM	UM	UM	UM	UM	Skin Mel, [1]	Conj. Mel	Conj. Mel
Tissue	Primary	Primary	Metastasis	PDX, prim., [4]	PDX, met., [4]	Primary	Prim., [5]	Prim., [5]
Passage number	P23	P21	P6	P50	P40	P22	P75	P77
GNAQ	Q209L, [2]	Q209P, [2]	WT, [2]	c.626A>T, [4]	WT, [4]	WT, [2]	WT, [7]	WT, [7]
GNA11	WT, [2]	WT, [2]	Q209L, [2]	WT, [4]	c.626A>T, [4]	WT, [2]	WT, [7]	WT, [7]
BRAF	WT, [2]	WT, [2]	WT, [2]	ND	ND	V600E, [2]	V600E, [6]	WT, [6]
NRAS	WT, [2]	WT, [2]	WT, [2]	ND	ND	WT, [2]	WT, [6]	Q61L, [6]
BAP1 mutation	WT, [3]	WT, [3]		WT, [4]	c.1881C>A, [4]			
BAP1 IHC	Pos, [3]	Pos, [3]	Pos, [8]	Neg, [4]	Neg, [4]	Pos, [11]	ND, [7]	ND, [7]
Chr 3	Disomy, [3]	Disomy, [3]	ND, [7]	Monosomy, [4]	Monosomy, [4]	Disomy, [9] [10]	ND, [7]	ND, [7]
Chr 8	Gain 8q, [3]	Disomy 8q, [3]	ND, [7]	Gain 8q, [4]	Gain 8q, [4]		ND, [7]	ND, [7]
EIF1AX	C17G/A, [3]	WT, [3]	WT, [8]	WT, [4]	WT, [4]		ND, [7]	ND, [7]
SF3B1	WT, [3]	WT, [3]	WT, [8]	WT, [4]	WT, [4]		ND, [7]	ND, [7]
Original Reference	De Waard-Siebinga et al 1995 [50]	Verbik et al 1997 [52]	Luyten et al 1996 [51]	Amirouchene-Angelozzi et al 2014 [53]	Amirouchene-Angelozzi et al 2014 [53]	Huang et al 1994 [55]	Nareyeck et al 2005 [54]	Nareyeck et al 2005 [54]

Abbreviations: WT, Wild Type; ND, Not determined; Met, metastasis; Prim, primary; IHC, immunohistochemistry; Pos, positive; Neg, negative.
1. Cell line OCM3 was originally believed to be a UM cell line, but its origin was questioned[68] and it was found that it demonstrated many similarities with skin melanoma cell line SK-Mel28 [69]. 2. Griewank et al [69]. 3. Jager et al [56]. 4. Amirouchene et al [53]. 5. Nareyeck et al [54]. 6. De Waard et al [70]. 7. Bailey et al [71]. 8. Bailey et al [71]. 9. White et al [72]. 10. Nareyeck et al [73]. 11. Mosbeh et al [74].12. Yu et al [35]



Supplementary Figure 1. Protein expression of YAP1-related genes in studied cell lines following 24 hr incubation with verteporfin (low dose: 1.25 ug/ml, high dose: 7.5 ug/ml) or control (PBS). Coomassie blue staining was used to ensure equal loading.

4.2

Tumour Angiogenesis in Uveal Melanoma Is Related to Genetic Evolution

Niels J. Brouwer[1], Gülçin Gezgin[1], Annemijn P.A. Wierenga[1], Inge H.G. Bronkhorst[2], Marina Marinkovic[1], Gregorius P.M. Luyten[1], Mieke Versluis[1], Wilma G.M. Kroes[3], Pieter A. van der Velden[1], Robert M. Verdijk[4,5] and Martine J. Jager[1]

Cancers (Basel) 2019; 11(7):979.

1 Department of Ophthalmology, Leiden University Medical Center, Albinusdreef 2, 2333 ZA Leiden, The Netherlands
2 Department of Ophthalmology, Jeroen Bosch Hospital, 5223 GZ 's-Hertogenbosch, The Netherlands
3 Department of Clinical Genetics, Leiden University Medical Center, 2333 ZA Leiden, The Netherlands
4 Department of Pathology, Leiden University Medical Center, 2333 ZA Leiden, The Netherlands
5 Department of Pathology, Erasmus University Medical Center, 3015 GD Rotterdam, The Netherlands

ABSTRACT

Increased angiogenesis is associated with a higher metastasis- and mortality rate in uveal melanoma (UM). Recently, it was demonstrated that genetic events, such as 8q-gain and BAP1-loss, influence the level of immune infiltrate. We aimed to determine whether genetic events, and specific cytokines, relate to angiogenesis in UM. Data from UM patients who underwent enucleation between 1999 and 2008 were analysed. Microvascular density (MVD) and the presence of infiltrating immune cells were determined with immunohistochemistry (IHC) and immunofluorescence in 43 cases. Chromosome status, BAP1 IHC and mRNA expression of angiogenesis-related genes were known in 54 cases. Tumours with monosomy 3/BAP1-loss showed a higher MVD compared to tumours with disomy 3/normal BAP1 expression ($p = 0.008$ and $p = 0.004$, respectively). Within BAP1-positive lesions ($n = 20$), 8q-gain did not relate to MVD ($p = 0.51$). A high MVD was associated with an increased expression of angiopoietin 2 (ANGPT2) ($p = 0.041$), VonWillebrand Factor (VWF) ($p = 0.010$), a decreased expression of vascular endothelial growth factor B (VEGF-B) ($p = 0.024$), and increased numbers of tumour-infiltrating macrophages (CD68+, $p = 0.017$; CD68+CD163+, $p = 0.031$) and lymphocytes (CD4+, $p = 0.027$). Concluding, vascular density of UM relates to its genetic profile: Monosomy 3 and BAP1-loss are associated with an increased MVD, while an early event (gain of 8q) is not independently related to MVD, but may initiate a preparation phase towards development of vessels. Interestingly, VEGF-B expression is decreased in UM with a high MVD.

INTRODUCTION

Uveal melanoma (UM) is the most common ocular malignancy in Caucasian adults. The disease is often lethal with up to 50% of patients developing metastases.[1] In recent years, research has focussed on targeted and immunotherapeutic therapies, as promising results were obtained in the treatment of, for example, cutaneous melanoma. Results in UM are disappointing; however, and questions remain regarding the mechanisms leading to metastases and the tumour's resistance to treatment. We sought to learn more about the relation between the tumour's immunological microenvironment and the development of angiogenesis, which is an important parameter in growth and behaviour of UM, and a potential target for therapy.

Restricted by the limits of diffusion (1–2 mm), an expanding UM requires new vessels to grow. The concept of the "angiogenic switch" describes the turning point between an initial phase of slow, avascular growth into a phase with more rapid growth and angiogenesis. Angiogenesis can be studied using micro-vascular density (MVD). An increased MVD has been associated with a higher metastasis rate[2] and mortality rate in UM.[3,4] Since UM metastasizes solely via the haematogenous route, it is logical to assume a relation between growth of intra-tumoural vessels and systemic spread. This concept led to the hypothesis that anti-angiogenic therapy could be used to treat UM or its metastases. One recent study reports a potential benefit of treatment with anti- vascular endothelial growth factor (VEGF) therapy in metastatic UM,[5] but others stress that anti-angiogenic therapy has been unsuccessful in UM.[6] This illustrates that there are still questions to be answered to fully understand angiogenesis in UM. Scientific interest in tumour vascularization has recently increased as new targets, including hypoxia signalling,[7] have proven to be promising in the therapeutic approach of UM.[8]

While angiogenesis describes the formation of endothelial-lined new vessels, it is important to note that other mechanisms resulting in intra-tumoural vascular channels have been recognized in UM.[9,10] This phenomenon is called "vascular mimicry", and can be depicted by periodic acid–Schiff (PAS) staining of extravascular matrix patterns. The presence of so-called loops and networks in UM was related to the MVD[11] and worse prognosis.[11] However, the exact function and development of these channels remains debated.

The MVD of UM is known to be associated with the tumour's immune infiltrate. Studies on this topic have focussed mainly on the relation with an increased presence of macrophages, describing their pro-angiogenic properties. An association between a higher MVD and increased numbers of all macrophages (CD68+ cells)[12] and M2 type macrophages (CD68+CD163+ cells)[2] has been established. Recently, it was found that genetic changes that reflect the evolution of UM relate to the type of immune infiltrate in tumour samples.[13] Gain of chromosome 8q (an early event in UM development)[14,15] is related to an increased presence of macrophages, while the loss of BAP1

expression (a later event) is related to an increased presence of T cells. Currently, the roles of 8q gain or BAP1 loss in angiogenesis are unknown. As monosomy 3 and BAP1 loss are very important for prognosis in this disease,[16,17] and they play a role in developing an inflammatory phenotype,[18] we wondered if angiogenesis as demonstrated by MVD is similarly regulated by these genetic events.

We hypothesize that genetic changes not only influence the immunological microenvironment, but also drive angiogenesis in UM, and that MVD is a consequence of a highly-malignant genetic profile. We set out to test this, and also analysed if several angiogenesis-related cytokines are expressed in relation to the development of tumour vascularity of primary UM.

RESULTS

A High MVD Relates to a Mixed/Epithelioid Cell Type and a Worse Clinical Outcome

As a high MVD is known to be associated with a bad prognosis in UM, we first determined whether our population confirmed the existing assumptions. The MVD had been determined by counting CD34-expressing vessels in sections of 43 UM, using a well-established technique as presented by Makitie et al.[3] The mean age at enucleation of these patients was 60.6 years. The median largest basal diameter (LBD) of the tumours was 13.0 mm. Following the American Joint Committee on Cancer (AJCC) tumour-node-metastasis (TNM) staging criteria, three (7%) tumours were Stage T1, 22 (51%) Stage T2 and 18 (42%) Stage T3. Further details on the patient and tumour characteristics are provided in Table 1.

The median MVD count was 89.0 CD34+ vessels/mm^2 (Range: 28.0–202.0). A high MVD was related to a mixed/epithelioid cell type (p = 0.004), but not to gender (p = 0.89), age (p = 0.25), tumour stage (p = 0.23) or tumour pigmentation (p = 0.45). When looking at a comparison with vascular mimicry, the median MVD count increased from cases without loops or networks (71.0 vessels/mm^2), to those with loops only (83.0 vessels/mm^2) and those with both loops and networks (102.0 vessels/mm^2) (p = 0.052). The median follow-up time was 120 months (range: 14–205 months). In total, 18 patients (42%) developed metastasis and died of melanoma-related causes. A high MVD was related to the development of metastasis (p = 0.009) and the occurrence of metastasis-related death (p = 0.009) (Table 1), similarly presented in Figure 1a.

Table 1. Patient and tumour characteristics of 43 uveal melanoma patients for whom data on micro-vascular density (MVD) were available.

Categorical	Total Cases (%)	MVD Median	p-Value
Gender			
Male	23 (53)	89.0	0.85 #
Female	20 (47)	88.5	
Side			
OD	23 (53)	86.0	0.95 #
OS	20 (47)	93.5	
TNM stage (8th)			
T1	4 (9)	79.0	0.23 *
T2	14 (33)	82.0	
T3	25 (58)	91.0	
Pigmentation			
Light	29 (67)	89.0	0.97 #
Dark	14 (33)	96.5	
Cell Type			
Spindle	11 (26)	69.0	0.009 #
Mixed + Epithelioid	32 (74)	100.0	
Ciliary Body Involvement			
No	24 (56)	89.0	0.58 #
Yes	19 (44)	103.0	
Loops and Networks			
None	7 (16)	71.0	0.052 *
Loops+, networks–	8 (19)	83.0	
Loops+, networks+	27 (63)	102.0	
Metastasis			
No	25 (58)	76.0	0.010 #
Yes	18 (42)	110.0	
Melanoma-Related Death			
No	25 (58)	76.0	0.010 #
Yes	18 (42)	110.0	
NUMERICAL	**Total**	**Correlation Spearman**	**p-Value**
Age—Median	63.6	0.135	0.390
LBD—Median	13.0	0.299	0.051
Prominence—Median	8.0	–0.278	0.072

*p values were calculated with: # Mann–Whitney U test, * Jonckheere test for trend. (Abbreviations: TNM, tumour-node-metastasis; LBD, largest basal diameter).*

MVD Relates to the Expression of Several Angiogenesis-Related Genes

To identify the relevance of angiogenesis-related pathways in UM, we related the MVD to the mRNA expression levels of several selected angiogenesis-related genes. Data on MVD as well as mRNA expression was available for 28 UM patients. Potentially-relevant genes were selected from the literature because of their theoretical role in angiogenesis, such as those coding for VEGF-A/B/C, HIF1a, ANGPT1/2, and PDGF-A. We also analysed vessel markers such as CD34 and PECAM1 (CD31). Patient and tumour characteristics of the 28 patients are provided in Table S1.

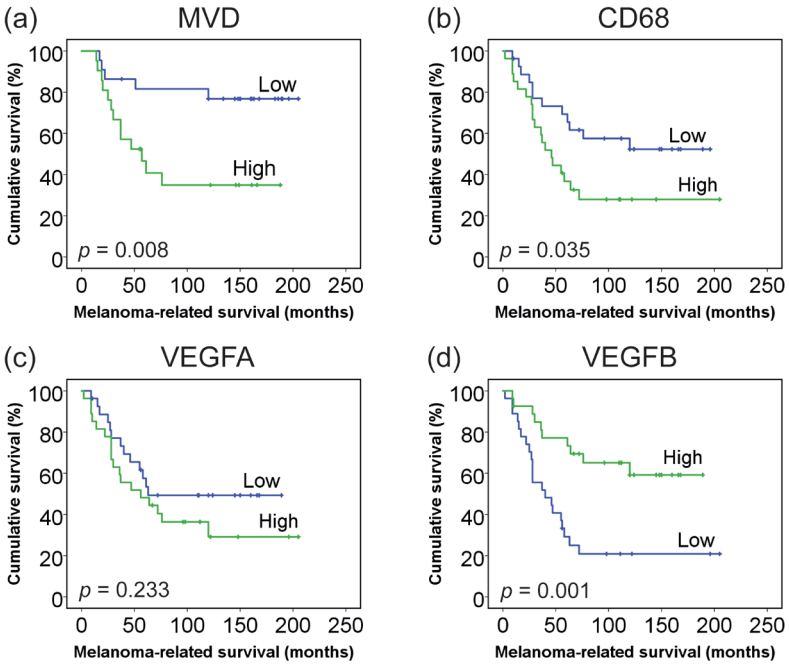

Figure 1. Patient survival in relation to MVD and mRNA gene expression. Groups (high vs. low) were based on the median vessel counts and mRNA gene expression values. (**a**) Immunohistochemistry (IHC) counts of MVD (n = 43), (**b**) mRNA gene expression of CD68 macrophages (n = 54), (**c**) mRNA gene expression of VEGF-A (n = 54), and (**d**) mRNA gene expression of VEGF-B (n = 54).

A high MVD (defined as number of CD34+ vessels/mm^2) was correlated with an increased mRNA expression of the vessel markers CD34 (p = 0.007) and PECAM1 (p = 0.055), the pro-angiogenic factors ANGPT2 (p = 0.041) and VWF (p = 0.010), and a decreased expression of VEGF-B (p = 0.024). The expression of VEGF-A was not related to MVD (p = 0.98), while the expression of

HIF1a (p = 0.089) and CDH1 (p = 0.079) demonstrated a trend towards an increase with a higher MVD, but this did not reach statistical significance (Table 2). A low expression of VEGF-B (but not VEGF-A) was related to worse survival in a Kaplan–Meier analysis (Figure 1c,d).

Table 2. mRNA expression of angiogenesis-related genes in relation to MVD (n = 28).

mRNA	Median (Range)	Spearman Correlation	*p*-Value
VEGF-A	6.76 (6.51–7.34)	0.005	0.989
VEGF-B	8.54 (7.6–9.41)	−0.425	0.024 *
VEGF-C	6.73 (6.37–7.73)	0.209	0.286
HIF1A	7.21 (6.89–7.91)	0.327	0.089
VHL	7.96 (7.35–8.54)	−0.226	0.248
ANGPT1	6.57 (6.31–7.04)	0.155	0.431
ANGPT2	6.54 (6.23–8.19)	0.389	0.041 *
PDGFA	6.96 (6.46–7.82)	0.060	0.761
CD34	7.37 (6.73–7.9)	0.497	0.007 *
CDH1	10.74 (5.8–12.94)	0.337	0.079
PECAM1	7.23 (6.68–9.57)	0.367	0.055
VWF	9.86 (8.62–11.14)	0.479	0.010 *

* *p-value < 0.05.*

MVD Relates to Increased Numbers of Macrophages (CD68+) as Well as T Cells (CD4+)

Previously, MVD was found to correlate with the number of tumour-infiltrating macrophages.[2] This was confirmed in the current set of 43 tumours, by determining the numbers of lymphocytes (CD3+, CD4+, CD8+, FoxP3+; using immunofluorescence (IF))[19] and macrophages (CD68+, CD163+, CD68+CD163+; using IF)[2]. A higher MVD was significantly associated with an increased number of CD68+ (r 0.361, p = 0.017), and CD68+CD163+ (r 0.329, p = 0.031) macrophages, and also with the number of CD4+ (r 0.336, p = 0.027) T cells. A trend was observed between a high MVD and increased counts of CD3+ (r 0.287, p = 0.062), CD8+ (r 0.271, p = 0.062) and FoxP3+ (r 0.283, p = 0.078) cells.

MVD Relates to Monosomy 3 and BAP1 Loss, but Not to Gain of Chromosome 8q

To investigate the association between tumour genetics and angiogenesis, the status of chromosome 3, chromosome 8q and the expression of the BAP1 protein were determined in 43 patients. Tumours with monosomy 3 (n = 21) had a higher MVD compared to tumours with disomy 3 (n = 22, p =

0.008). Similarly, BAP1-negative tumours (n = 23) had a higher MVD compared to BAP1-positive tumours (n = 20, p = 0.004) (Figures 2a and 3a). To investigate the role of BAP1 independently of chromosome 3 status, we analysed the association between BAP1 and MVD within groups of disomy 3 and monosomy 3 tumours separately. Within the group of disomy 3 tumours (n = 22), BAP1 loss (n = 6) was still related to a higher MVD compared to tumours that expressed BAP1 (n = 16, p = 0.008). Within the group of monosomy 3 tumours (n = 21), this association could not be established, but that may be due to a small sample size as only four out of 21 tumours with monosomy 3 had not lost their BAP1 expression (Figure 3b). For further comparisons, we focussed on BAP1 expression.

While monosomy 3 (or loss of BAP1) is considered a late event in the development of UM, gain of 8q is an early event.[14,15] When analysing all cases, gain of chromosome 8q was related to an increased MVD (p = 0.029) (Figure 3a), but most tumours with gain of 8q also demonstrated BAP1 loss. When we analysed the relationship of 8q gain within tumours that still expressed BAP1 (n = 20), 8q gain was not related to MVD (p = 0.59) (Figure 2). As only two of the BAP1-negative tumours demonstrated normal 8q, we cannot conclude on the effect of 8q gain within BAP1-negative lesions.

Expression of Angiogenesis-Related Genes is Related to Genetic Progression of UM

Earlier in this study, we noticed that several angiogenesis-related genes are related to the MVD in UM. We wondered whether the expression of these genes may be related to genetic progression (early 8q gain and later BAP1 loss) in the 54 cases with data on tumour genetics and mRNA gene expression (Table S2). First, we compared all BAP1-positive (n = 24) with all BAP1-negative (n = 30) lesions. Loss of BAP1 expression was associated with an increased expression of HIF1a and ANGPT2, and a decreased expression of VEGF-B, and VHL (all $p < 0.05$). When looking at vascular markers and infiltrate, BAP1 loss was associated with an increased mRNA expression of vascular markers CDH1, PECAM1, VWF and infiltrate markers CD3, CD4, CD8 and CD68 (Table S3).

We corroborated these findings using the TCGA dataset, and found similar results for the association between BAP1 loss and increased expression of HIF1a, ANGPT2, CDH1, PECAM1, CD3 and CD8, and between BAP1 loss and a decreased expression of VHL and VEGF-B. Interestingly, in the TCGA data, BAP1 loss was also related to an increase of VEGF-A and ANGPT1 (while this was not observed in the Leiden data) (Table S4).

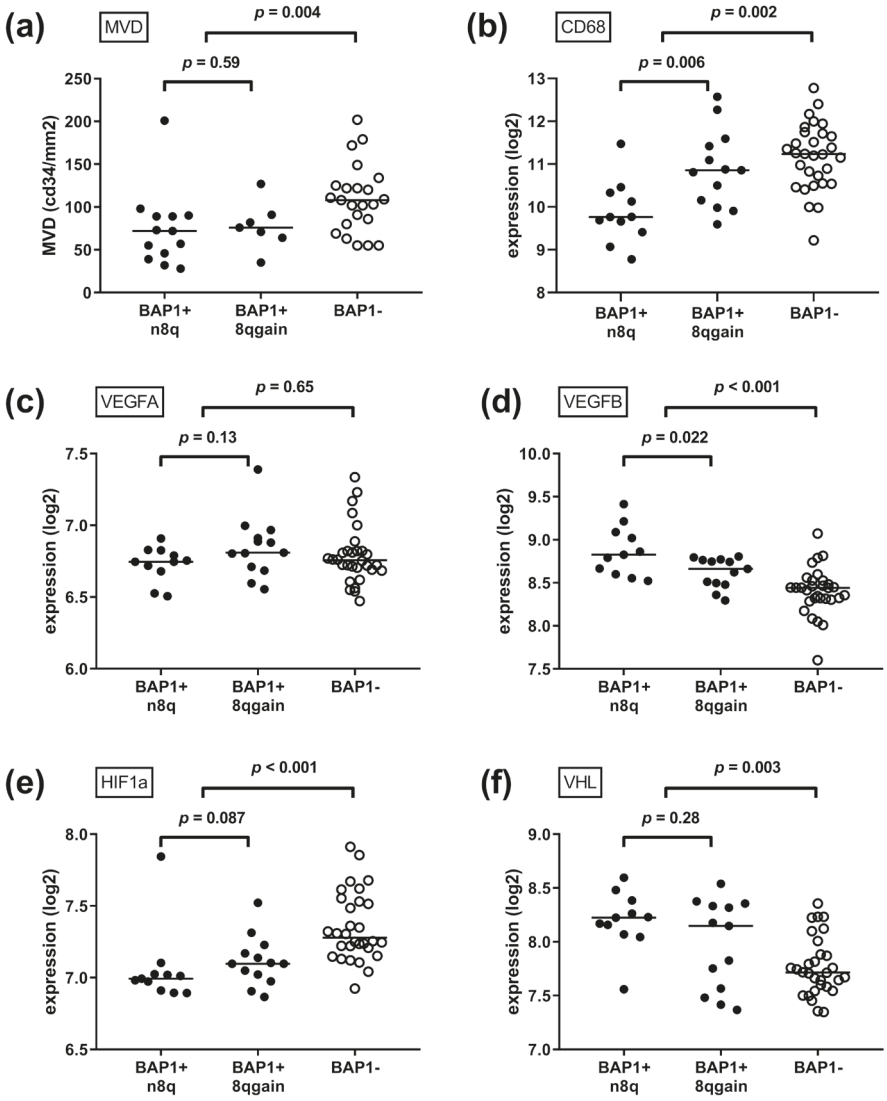

Figure 2. Tumour genetics in relation to MVD and mRNA gene expression. Gain of chromosome 8q is an early event in UM development, while loss of BAP1 is a later event. (**a**) IHC counts of MVD (n = 43), (**b**) mRNA gene expression of CD68 macrophages (n = 54), (**c**) mRNA gene expression of VEGF-A (n = 54), (**d**) mRNA gene expression of VEGF-B (n = 54), (**e**) mRNA gene expression of HIF1a (n = 54), and (**f**) mRNA gene expression of VHL (n = 54). (p-values were obtained using Mann–Whitney U tests, comparing BAP1+ and n8q with BAP1+ and 8qgain patients, and all BAP1+ with all BAP1– patients. Abbreviations: BAP1+, BAP1-positive; BAP1–, BAP1-negative; n8q, normal chromosome 8q; 8qgain, gain of chromosome 8q).

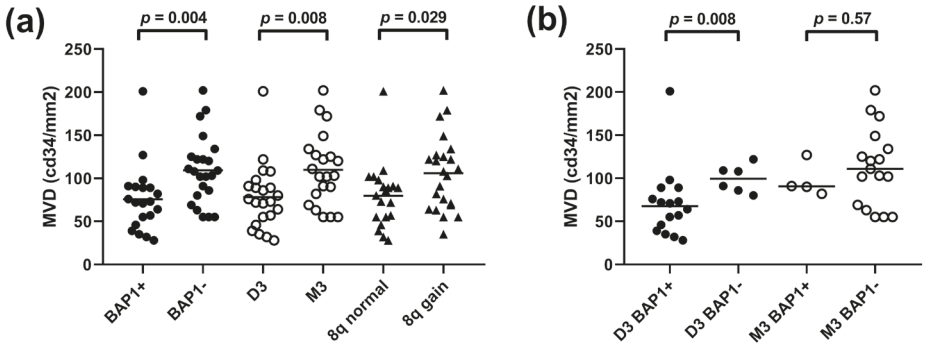

Figure 3. Tumour genetics in relation to MVD. (**a**) Within all 43 patients, patients were compared based on status of BAP1, chromosome 3 or chromosome 8q. (**b**) Within either disomy 3 (n = 22) or monosomy 3 (n = 21) patients, patients were compared based on status of BAP1. (p-values were obtained using Mann–Whitney U tests. Abbreviations: BAP1+, BAP1-positive; BAP1–, BAP1-negative; D3, Disomy 3; M3, Monosomy 3; 8q normal, normal chromosome 8q; 8q gain, gain of chromosome 8q).

Second, we evaluated the role of chromosome 8q within the BAP1 expressing tumours. Although we identified that gain of 8q is not independently related to MVD, a previous study demonstrated that gain of 8q is related to increased counts of (pro-angiogenic) macrophages.[13] We confirm that within the group of BAP1-expressing tumours from Leiden, gain of 8q was associated with a higher mRNA expression of CD3 (lymphocytes, p = 0.026) and especially of more CD68 (macrophages, p = 0.007). When examining cytokines, within the group of BAP1-expressing tumours, 8q gain was related to an increased expression of ANGPT2 (p = 0.040) and a decreased expression of VEGF-B (p = 0.022) and VEGF-C (p = 0.026) (Table S3). The relation between 8q gain, BAP1 loss and the expression of several of the investigated genes is presented in Figure 2. During tumour progression, VEGF-B and VHL decrease, while HIF1a increases.

In the TCGA data, gain of 8q was similarly related to an increased expression of CD68 (macrophages), and expression of PDGF-A, but no relation with any of the other cytokines was observed (Table S4).

DISCUSSION

As we already know that genetic events are closely associated with the immunological microenvironment in UM, including the presence of macrophages and lymphocytes, we analysed whether genetic events also play a role in the MVD and the expression of angiogenic factors in UM. We demonstrate an important association between monosomy 3/BAP1 loss and the expression

of several angiogenesis-related genes and MVD. Gain of chromosome 8q was not independently related to MVD, but it was related to a differential expression of several angiogenesis-related genes: The expression of pro-angiogenic ANGPT2 was increased, and (presumably) anti-angiogenic VEGF-B was decreased with 8q gain. This may indicate that 8q gain is involved in a preparation phase towards the development of more vessels. However, it looks as if a true increase in MVD can only be accomplished by a series of events, in which the BAP1 gene may play an important role. This idea may fit well into the concept of the angiogenic switch, describing a slow early avascular tumour growth phase, followed by a more rapid growth with vascular development.

By using mRNA expression techniques, a comprehensive analysis of angiogenesis-related genes was performed. Interestingly, VEGF-A expression was not related to MVD in our data. VEGF-A is the main type of VEGF and is considered to be of importance for the development of new blood vessels. Even more, various studies demonstrated that elevated levels of VEGF-A are present in the aqueous and vitreous of UM eyes.[20-22] An explanation for our finding could be that VEGF-A is either important for the most initial development of vasculature, or for the maintenance of previously-developed vasculature, while other factors influence a further increase in MVD.

Our results show that VEGF-B may have a much more important role in angiogenesis in UM than previously thought. An abundant expression of VEGF-B was reported earlier in UM cell lines,[23] but the role of VEGF-B has always been described as enigmatic. Interestingly, in our data the expression of VEGF-B correlated negatively with the MVD. A relation between VEGF-B and MVD is unreported in UM, but the function of VEGF-B was recently studied in a murine model, using a cutaneous melanoma cell line. Enforced expression of VEGF-B led to suppressed primary tumour growth in mice and a reduced MVD, but more metastases.[24] It was proposed that an increase in VEGF-B causes increased vascular leakiness, a high degree of hypoxia, with increased numbers of tumour-infiltrating macrophages, leading to a metastasis-promoting environment.[24] Indeed, a relation between high mRNA expression of VEGF-B and worse survival was found in patients with lung squamous cell carcinoma and non-ocular melanoma.[24] Interestingly, the relation between a low VEGF-B expression and metastasis development in our UM data did not follow the positive correlation that was reported with other cancers. In the Leiden data, the development of metastasis was not related to VEGF-A expression, but it related to a decreased expression of VEGF-B. In the TCGA data, both an increased expression of VEGF-A and a decreased expression of VEGF-B were related to more metastasis formation. These observations may indicate that the function of VEGF-B regarding tumour behaviour is different in UM compared to other tumours.

New insights in ischemic signalling pathways have drawn attention to HIF1a-regulated angiogenesis in UM, and new drugs targeting these pathways are being developed.[8] In our study, mRNA expression of HIF1a was not significantly related to an increasing MVD ($p = 0.089$). This may be due to sample size, as Mouriaux demonstrated a link between HIF1a expression and vascular marker

CD31 in a larger set of 56 UM.[25] A recent study in UM cell lines on HIF1a-related angiogenesis showed that both VEGF and ANGPTL4 are promotors for tubule formation.[26] The effectors of HIF1a may therefore include multiple pathways, stressing that not only VEGF-A related pathways may have relevance. We furthermore demonstrate that BAP1-loss is strongly related to HIF1a expression, implicating the HIF1a-mediated pathways of angiogenesis in the later steps of UM progression. However, the exact role of BAP1 in UM development, including angiogenesis, is not well understood. It can be hypothesized that BAP1 loss leads to an upregulation of HIF1a via the NF-kB cascade, as BAP1 was shown to suppress this pathway in human oesophageal carcinoma,[27] and BAP1 loss was found to be related to an increased NF-kB expression in UM,[28] but the mechanism needs to be investigated further.

Previously, associations were reported between the MVD and the presence of tumour-associated macrophages (CD68+ cells,[3] and CD68+CD163+ cells[2]). It was hypothesized that macrophages have a pro-angiogenic effect by, for example, secreting VEGF. We confirm the relationship between a high MVD and increased counts of CD68+ cells, and also find an association with CD4+ cells. The numbers of these cells are highly correlated;[19] however, and it has been observed that activated macrophages can attract a T cell infiltrate.[29] It should; therefore, be further studied if T cells have an independent relation to vasculature or whether they act downstream of the presence of macrophages.

Regarding tumour size, we identified that LBD (B = 5.15; 95%CI 0.73 to 9.58; p = 0.024), but not tumour prominence (B = −3.63; 95%CI −9.07 to 1.80; p = 0.18), was related to MVD in a univariate linear regression analysis. Adjusting for BAP1 status, there was still a trend that LBD related to MVD (B = 4.16; 95%CI −0.10 to 8.42; p = 0.055) while BAP1 status related to MVD as well (B = −29.08; 95%CI −53.01 to −5.14; p = 0.019). Makitie detected a weak correlation between MVD and increasing LBD as well as with prominence, but had a larger study group of 134 UM, and he did not know the BAP1 status.[3] Our results may imply that tumour size alone (with presumed increased hypoxia) is not the driver of angiogenesis, and that genetics are an important determinant. It would be interesting to investigate whether increased vascularity explains why some large, yet disomy 3/BAP1-positive tumours become metastatic. However, our numbers were not sufficient to examine this relation.

Opposed to the relations we identified between tumour genetics and MVD, the presence of extravascular matrix patterns demonstrated a slightly different relationship. As with MVD, the status of chromosome 8q was not related to the presence of loops (p = 0.89) or networks (p = 0.32). However, cases with monosomy 3 demonstrated more often loops (p = 0.038) and networks (p = 0.016). This finding is line with the earlier observation of Onken et al. that the presence of loops and networks relates to gene expression profile class II UM.[30] Interestingly, loops and networks

did not relate to BAP1 status ($p = 0.13$ and $p = 0.13$, respectively). This finding may underline the different aetiology of the vascular structures, though we cannot but speculate on the role of BAP1 in this finding.

A limitation of this study was that mainly larger tumours were included as all samples were obtained from enucleated eyes. This also limited the variation in tumour size. It can be expected that new vasculature is especially important for larger lesions; however, so it may be of no major concern that few small-sized tumours were studied.

While the presence of intra-tumoural vessels and infiltrate was analysed with immunohistochemistry (IHC) and IF, respectively, the expression of the various angiogenic factors was analysed using mRNA. This is a well-established technique capable of identifying pathways of interest. However, there may be differences between mRNA gene expression and protein production. Future studies could investigate how our findings, which we corroborated using the mRNA expression data of the TCGA project, relate to data on protein expression of the respective factors.

Our study implicates that angiogenesis should be studied together with the genetic background of UM. An important future project could be to study if anti-angiogenic treatment is more effective in specific (genetic) sub groups of UM. As we show that vascularity is related to genetics, it may be that mainly highly-vascularized lesions are effectively attacked with those treatments or that genetic profiling can predict responses to anti-angiogenic therapy. Another project may be to study which other genes on chromosome 3, besides BAP1, are important for MVD development. In this, it may be important to consider the role of VHL as the VHL gene is, like BAP1, located on chromosome 3. As we demonstrate a role for VEGF-B in UM angiogenesis, the exact role of this cytokine and the relevance for anti-angiogenic therapy should be investigated.

MATERIALS AND METHODS

Patient Selection

Tumour samples were obtained from eyes with UM that had been primarily enucleated at the Leiden University Medical Center (LUMC, Leiden, The Netherlands) between 1999 and 2008. Clinical data was retrieved from patient medical files. Survival data was complemented with data from the Dutch national cancer registry (RANK). The study was approved by the Biobank Committee of the LUMC (19.060.CBO/uveamelanoomlab-2019-1), and adhered to the tenets of the Declaration of Helsinki.

The current study includes a previously reported set of 43 tumours with data on MVD, tumour infiltrate and tumour genetics (Table 1),[2,19] and an additional (partially overlapping) set of 54

tumours with data on mRNA gene expression and tumour genetics (Table S2). Of all patients, 28 cases with combined data on MVD and mRNA gene expression were available (Table S1). Clinical data and survival data of all patients were updated until 1 March 2017.

Histopathology

Tumour material was snap frozen using 2-methyl butane and later used for DNA and RNA isolation. Remaining tumour material was fixed in 4% neutral-buffered formalin for 48 h and embedded in paraffin. Haematoxylin/eosin-stained 4 µm sections were reviewed by an ocular pathologist for confirmation of the diagnosis and evaluated for histologic parameters (LBD, prominence, cell type, pigmentation). The eighth edition of the AJCC staging manual was used for tumour classification.[31]

Immunohistochemistry and Immunofluorescence

MVD was assessed in 43 cases with IHC for CD34 as described previously.[3] Counts were represented as vessels/mm^2. Numbers of lymphocytes and macrophages were assessed as described previously.[2,19] T cells were detected with IF using antibodies against CD3, CD4, CD8 and FoxP3. Counts were represented as number of cells/mm^2. Macrophages were detected with IF using antibodies against CD68, CD163, and CD68CD163 double-staining. Counts were determined in pixels/mm^2. BAP1 status was assessed with IHC as described previously.[32] Nuclear BAP1 staining was scored by an experienced ocular pathologist, and categorized as BAP1-positive or BAP1-negative. Extravascular networks were identified with PAS staining; closed vascular structures were named "loops", and at least 3 adjacent loops were named "networks".

Chromosome 3/8q Status and Gene Expression

The QIAmp DNA Mini Kit was used to isolate DNA for single nucleotide polymorphism (SNP) analysis according to guidelines of the manufacturer (Qiagen, Venlo, The Netherlands). Status of chromosome 3 was determined with SNP analysis performed with the Affymetrix 250K_NSP chip and the Affymetrix Cytoscan HD chip (Affymetrix, Santa Clara, CA, USA).[14] The copy number of chromosome 8q was identified with ddPCR. A threshold of >2.1 was defined as gain of 8q.[14] The RNeasy Mini Kit was used to isolate mRNA for gene expression analysis (Qiagen, Venlo, The Netherlands). Gene expression levels were obtained using the Illumina HT-12 v4 chip (Illumina, San Diego, CA, USA). Angiogenesis-related factors were selected based on literature regarding angiogenesis. Only these predefined genes were assessed in the current analysis (Table S5).

TCGA Data

Findings were corroborated using mRNA data from 80 UM patients from the TCGA project: http://cancergenome.nih.gov/.[33] In this set, BAP1 expression was provided as mRNA expression levels, and dichotomized into BAP1-positive and BAP1-negative tumours, using the median.[13]

Statistical Analysis

Analyses were performed using SPSS version 23 (I.B.M.). Categorical data was analysed with Chi-square tests. Numerical data was analysed with the Mann–Whitney *U* test between 2 groups, and with the Jonckheere test between multiple groups with a trend. Correlations were assessed with the Spearman's test. Linear regression was performed for univariate and multivariate analyses. Survival data was analysed with the Kaplan–Meier method and log-rank tests; groups of high and low MVD and mRNA gene expression were based on the median. p-values < 0.05 were considered statistically significant.

CONCLUSIONS

In conclusion, we demonstrated that the genetic evolution of UM not only involves tumour infiltrate, but also tumour angiogenesis. Late events (such as BAP1 loss) are related to an increase in MVD, while early events (such as 8q gain) are not. Gain of 8q may be related to a preparation phase; however, as several angiogenesis-related genes are already expressed differentially in the absence of monosomy 3/BAP1 loss. We observed new associations with MVD, such as with monosomy 3/BAP1 loss, an increased count of lymphocytes, and a decreased expression of VEGF-B, indicating that more (and other) mechanisms are involved in angiogenesis of UM than previously thought.

Author Contributions: Conceptualization, N.J.B. and M.J.J.; formal analysis, N.J.B., A.P.A.W. and M.J.J.; investigation, G.G., A.P.A.W., I.H.G.B., M.M., G.P.M.L., M.V., W.G.M.K., P.A.v.d.V. and R.M.V.; methodology, N.J.B. and M.J.J.; resources, G.G., A.P.A.W., I.H.G.B., M.M., G.P.M.L., M.V., W.G.M.K., P.A.v.d.V. and R.M.V.; supervision, M.J.J.; writing—original draft, N.J.B. and M.J.J.; writing—review and editing, all.

Funding: This project was supported by Algemene Nederlandse Vereniging Ter Voorkoming van Blindheid (ANVVB), Stichting Blinden Penning, Landelijke Stichting voor Blinden en Slechtzienden (LSBS), Novartis Foundation, Stichting Nederlands Oogheelkundig Onderzoek (SNOO), Rotterdamse Stichting Blindenbelangen, MD/PhD program grant of the LUMC, and the European Commission Horizon 2020 program UM Cure (Project number: 667787).

Conflicts of Interest: The authors declare no conflicts of interest.

REFERENCES

1. Damato B. Progress in the management of patients with uveal melanoma. The 2012 Ashton Lecture. *Eye (Lond).* 2012;26(9):1157-1172.
2. Bronkhorst IH, Ly LV, Jordanova ES, et al. Detection of M2-macrophages in uveal melanoma and relation with survival. *Invest Ophthalmol Vis Sci.* 2011;52(2):643-650.
3. Makitie T, Summanen P, Tarkkanen A, Kivela T. Microvascular density in predicting survival of patients with choroidal and ciliary body melanoma. *Invest Ophthalmol Vis Sci.* 1999;40(11):2471-2480.
4. Foss AJ, Alexander RA, Jefferies LW, et al. Microvessel count predicts survival in uveal melanoma. *Cancer Res.* 1996;56(13):2900-2903.
5. Piperno-Neumann S, Diallo A, Etienne-Grimaldi MC, et al. Phase II Trial of Bevacizumab in Combination With Temozolomide as First-Line Treatment in Patients With Metastatic Uveal Melanoma. *Oncologist.* 2016;21(3):281-282.
6. El Filali M, van der Velden PA, Luyten GP, Jager MJ. Anti-Angiogenic Therapy in Uveal Melanoma. In: Jager MJ, Desjardins L, Kivela T, Damato BE, eds. *Current Concepts in Uveal Melanoma.* Vol 49. Basel: Karger; 2012:117-136.
7. Grossniklaus HE, Van Meir EG. Are Risk Factors for Growth of Choroidal Nevi Associated With Malignant Transformation? Assessment With a Validated Genomic Biomarker. *Am J Ophthalmol.* 2019.
8. Dong L, You S, Zhang Q, et al. Arylsulfonamide 64B Inhibits Hypoxia/HIF-Induced Expression of c-Met and CXCR4 and Reduces Primary Tumor Growth and Metastasis of Uveal Melanoma. *Clin Cancer Res.* 2019;25(7):2206-2218.
9. Folberg R, Hendrix MJ, Maniotis AJ. Vasculogenic mimicry and tumor angiogenesis. *Am J Pathol.* 2000;156(2):361-381.
10. Bhat P, Jakobiec FA, Folberg R. Comparison of tumor-associated vasculatures in uveal and cutaneous melanomas. *Semin Ophthalmol.* 2009;24(3):166-171.
11. Makitie T, Summanen P, Tarkkanen A, Kivela T. Microvascular loops and networks as prognostic indicators in choroidal and ciliary body melanomas. *J Natl Cancer Inst.* 1999;91(4):359-367.
12. Makitie T, Summanen P, Tarkkanen A, Kivela T. Tumor-infiltrating macrophages (CD68(+) cells) and prognosis in malignant uveal melanoma. *Invest Ophthalmol Vis Sci.* 2001;42(7):1414-1421.
13. Gezgin G, Dogrusöz M, van Essen TH, et al. Genetic evolution of uveal melanoma guides the development of an inflammatory microenvironment. *Cancer Immunol Immunother.* 2017;66(7):903-912.
14. Versluis M, de Lange MJ, van Pelt SI, et al. Digital PCR validates 8q dosage as prognostic tool in uveal melanoma. *PLoS One.* 2015;10(3):e0116371.
15. Singh N, Singh AD, Hide W. Inferring an Evolutionary Tree of Uveal Melanoma From Genomic Copy Number Aberrations. *Invest Ophthalmol Vis Sci.* 2015;56(11):6801-6809.
16. Harbour JW, Onken MD, Roberson ED, et al. Frequent mutation of BAP1 in metastasizing uveal melanomas. *Science.* 2010;330(6009):1410-1413.
17. Damato B, Eleuteri A, Taktak AF, Coupland SE. Estimating prognosis for survival after treatment of choroidal melanoma. *Prog Retin Eye Res.* 2011;30(5):285-295.
18. van Essen TH, van Pelt SI, Versluis M, et al. Prognostic parameters in uveal melanoma and their association with BAP1 expression. *Br J Ophthalmol.* 2014;98(12):1738-1743.
19. Bronkhorst IH, Vu TH, Jordanova ES, et al. Different subsets of tumor-infiltrating lymphocytes correlate with macrophage influx and monosomy 3 in uveal melanoma. *Invest Ophthalmol Vis Sci.* 2012;53(9):5370-5378.
20. Boyd SR, Tan D, Bunce C, et al. Vascular endothelial growth factor is elevated in ocular fluids of eyes harbouring uveal melanoma: identification of a potential therapeutic window. *Br J Ophthalmol.* 2002;86(4):448-452.

21. Missotten GS, Notting IC, Schlingemann RO, et al. Vascular endothelial growth factor a in eyes with uveal melanoma. *Arch Ophthalmol.* 2006;124(10):1428-1434.
22. Cheng Y, Feng J, Zhu X, Liang J. Cytokines concentrations in aqueous humor of eyes with uveal melanoma. *Medicine (Baltimore).* 2019;98(5):e14030.
23. Notting IC, Missotten GS, Sijmons B, et al. Angiogenic profile of uveal melanoma. *Curr Eye Res.* 2006;31(9):775-785.
24. Yang X, Zhang Y, Hosaka K, et al. VEGF-B promotes cancer metastasis through a VEGF-A-independent mechanism and serves as a marker of poor prognosis for cancer patients. *Proc Natl Acad Sci U S A.* 2015;112(22):E2900-2909.
25. Mouriaux F, Sanschagrin F, Diorio C, et al. Increased HIF-1alpha expression correlates with cell proliferation and vascular markers CD31 and VEGF-A in uveal melanoma. *Invest Ophthalmol Vis Sci.* 2014;55(3):1277-1283.
26. Hu K, Babapoor-Farrokhran S, Rodrigues M, et al. Hypoxia-inducible factor 1 upregulation of both VEGF and ANGPTL4 is required to promote the angiogenic phenotype in uveal melanoma. *Oncotarget.* 2016;7(7):7816-7828.
27. Mori T, Sumii M, Fujishima F, et al. Somatic alteration and depleted nuclear expression of BAP1 in human esophageal squamous cell carcinoma. *Cancer Sci.* 2015;106(9):1118-1129.
28. Souri Z, Wierenga APA, van Weeghel C, et al. Loss of BAP1 Is Associated with Upregulation of the NFkB Pathway and Increased HLA Class I Expression in Uveal Melanoma. *Cancers (Basel).* 2019;11(8).
29. de Lange MJ, Nell RJ, Lalai RN, et al. Digital PCR-Based T-cell Quantification-Assisted Deconvolution of the Microenvironment Reveals that Activated Macrophages Drive Tumor Inflammation in Uveal Melanoma. *Mol Cancer Res.* 2018;16(12):1902-1911.
30. Onken MD, Lin AY, Worley LA, Folberg R, Harbour JW. Association between microarray gene expression signature and extravascular matrix patterns in primary uveal melanomas. *American Journal of Ophthalmology.* 2005;140(4):748-749.
31. Kivela T, Simpson ER, Grossniklaus HE, et al. Uveal Melanoma. In: Amin MB ES, Green F, ed. *AJCC Cancer Staging Manual, 8th ed*. New York: Springer; 2017:805-817.
32. Koopmans AE, Verdijk RM, Brouwer RW, et al. Clinical significance of immunohistochemistry for detection of BAP1 mutations in uveal melanoma. *Mod Pathol.* 2014;27(10):1321-1330.
33. Robertson AG, Shih J, Yau C, et al. Integrative Analysis Identifies Four Molecular and Clinical Subsets in Uveal Melanoma. *Cancer Cell.* 2017;32(2):204-220 e215.

SUPPLEMENTARY MATERIALS

Supplemental Table S1. Patient and tumour characteristics of UM patients with data on MVD and mRNA expression (n = 28).

CATEGORICAL	Total Cases (%)
Gender	
Male	15 (54)
Female	13 (46)
Side	
OD	14 (50)
OS	14 (50)
TNM stage (8th)	
T1	4 (14)
T2	9 (32)
T3	15 (54)
Pigmentation	
Light	22 (79)
Dark	6 (21)
Cell Type	
Spindle	10 (36)
Mixed + Epithelioid	18 (64)
Ciliary body involvement	
No	16 (57)
Yes	12 (43)
Loops and Networks	
None	7 (25)
Loops+, networks-	5 (18)
Loops+, networks+	16 (57)
Metastasis	
No	14 (50)
Yes	14 (50)
Melanoma-Related Death	
No	14 (50)
Yes	14 (50)
NUMERICAL	
Age – Median	68.9
LBD – Median	14.5
Prominence - Median	7.0

Supplemental Table S2. Patient and tumour characteristics of UM patients with data on tumour genetics and mRNA expression (*n* = 54).

CATEGORICAL	Total Cases (%)
Gender	
Male	28 (52)
Female	26 (48)
Side	
OD	26 (48)
OS	28 (52)
TNM stage (8th)	
T1	2 (4)
T2	23 (43)
T3	27 (50)
T4	2 (4)
Pigmentation*	
Light	36 (67)
Dark	17 (32)
Cell Type	
Spindle	19 (35)
Mixed + Epithelioid	35 (65)
Ciliary body involvement*	
No	32 (59)
Yes	21 (39)
Loops and Networks*	
None	16 (30)
Loops+, networks-	10 (19)
Loops+, networks+	27 (50)
Metastasis	
No	23 (43)
Yes	31 (57)
Melanoma-Related Death	
No	23 (43)
Yes	31 (57)
NUMERICAL	**Total**
Age – Median	64.0
LBD – Median	14.0
Prominence - Median	8.0

**Rows do not add up to 100% due to one missing value.*

Supplemental Table S3. mRNA expression of angiogenesis-related genes in relation to 8q gain and BAP1 loss in 24 and 54 cases, respectively (Leiden data).

mRNA	BAP1+ 8q normal *n* = 11 Median	BAP1+ 8q gain *n* = 13 Median	*p*		BAP1+ *n* = 24 Median	BAP1- *n* = 30 Median	*p*	
VEGF-A	6.75	6.81	0.125		6.80	6.76	0.651	
VEGF-B	8.83	8.66	0.022*	↓	8.74	8.44	<0.001*	↓
VEGF-C	6.86	6.62	0.026*	↓	6.76	6.68	0.651	
HIF1A	6.99	7.10	0.087		7.02	7.28	<0.001*	↑
VHL	8.22	8.15	0.284		8.17	7.71	0.003*	↓
ANGPT1	6.58	6.63	0.931		6.59	6.55	0.508	
ANGPT2	6.42	6.52	0.040*	↑	6.45	6.58	0.015*	↑
PDGFA	6.94	6.97	0.839		6.96	6.91	0.384	
CD34	6.94	7.24	0.401		7.22	7.37	0.126	
CDH1	9.57	9.82	0.235		9.73	11.58	<0.001*	↑
PECAM1	6.80	6.99	0.140		6.95	7.28	0.004*	↑
VWF	9.47	9.83	0.839		9.57	9.97	0.013*	↑
CD3D	6.46	6.67	0.026*	↑	6.59	7.18	0.015*	↑
CD4	6.41	6.58	0.077		6.53	6.66	0.042*	↑
CD8A	6.55	6.72	0.125		6.63	7.50	0.016*	↑
CD68	9.76	10.86	0.007*	↑	10.24	11.23	0.002*	↑
CD163	6.82	7.31	0.125		7.01	7.19	0.394	
BAP1	7.96	7.95	0.977		7.96	7.26	<0.001*	↓

**p-value <0.05. (Abbreviations: BAP1+, BAP1-positive; BAP1-, BAP1-negative; 8q normal, normal chromosome 8q; 8q gain, gain of chromosome 8q)*

Supplemental Table S4. mRNA expression of angiogenesis-related genes in relation to 8q gain or BAP1 loss in 40 and 40 patients, respectively (TCGA data).

mRNA	BAP1+ 8q normal *n* = 17 Median	BAP1+ 8q gain *n* = 23 Median	*p*		BAP1+ *n* = 40 Median	BAP1- *n* = 40 Median	*p*	
VEGF-A	7.67	8.23	0.151		8.12	8.64	0.001*	↑
VEGF-B	12.90	13.07	0.503		12.96	12.17	<0.001*	↓
VEGF-C	6.49	5.27	0.069		5.36	6.24	0.059	
HIF1A	10.05	9.21	0.061		9.69	10.27	0.002*	↑
VHL	8.49	7.95	0.176		8.27	7.91	0.023*	↓
ANGPT1	1.89	1.76	0.519		1.76	2.69	0.022*	↑
ANGPT2	4.33	4.75	0.159		4.62	5.62	<0.001*	↑
PDGFA	9.97	9.08	0.002*	↓	9.43	9.83	0.006*	↑
CD34	8.09	8.09	0.753		8.09	8.10	0.665	
CDH1	12.43	12.41	0.880		12.42	14.06	<0.001*	↑
PECAM1	7.27	7.44	0.712		7.35	7.95	<0.001*	↑
VWF	11.10	11.23	0.753		11.16	10.95	0.651	
CD3D	1.37	2.33	0.924		1.88	4.18	<0.001*	↑
CD4	8.76	9.24	0.082		9.02	9.19	0.810	
CD8A	3.87	3.02	0.359		3.37	6.23	<0.001*	↑
CD68	10.95	12.07	<0.001*	↑	11.68	11.98	0.149	
CD163	7.50	7.02	0.159		7.14	7.69	0.149	
BAP1	11.97	12.28	0.136		12.09	9.71	<0.001*	↓

**p-value <0.05. (Abbreviations: BAP1+, BAP1-positive; BAP1-, BAP1-negative; 8q normal, normal chromosome 8q; 8q gain, gain of chromosome 8q)*

Supplemental Table S5. Overview of angiogenesis-related genes.

mRNA	Name	Locus	EntrezID	Probe name	Probe number	Remarks
VEGF-A	VEGF-A	6p21.1	7422	VEGFA_p1	ILMN_2375879	
VEGF-B	VEGF-B	11q13.1	7423	VEGFB_p3	ILMN_1722855	
VEGF-C	VEGF-C	4q34.3	7424	VEGFC_p1	ILMN_1701204	
HIF1A	Hypoxia Inducible Factor-1alfa	14q23.2	3091	HIF1A_p1	ILMN_2379788	
VHL	Von Hippel Lindau	3p25.3	7428	VHL_p2	ILMN_1738579	
ANGPT1	Angiopoietin 1	8q23.1	284	ANGPT1_p1	ILMN_1677723	
ANGPT2	Angiopoietin 2	8q23.1	285	ANGPT2_p2	ILMN_1774207	
PDGFA	Platelet-derived Growth Factor-A	7p22.3	5154	PDGFA_p1	ILMN_2342695	
CD34	CD34	1q32.2	947	CD34_p1	ILMN_2341229	
CDH1	Cadherin-1	16q22.1	999	CDH1_p1	ILMN_1770940	Also known as: epithelial cadherin (e-cadherin)
PECAM1	Platelet Endothelial Cell Adhesion Molecule 1	17q23.3	5175	PECAM1_p1	ILMN_1689518	Also known as: CD31
VWF	Von Willebrand Factor	12p13.31	7450	VWF_p1	ILMN_1752755	
CD3D	CD3	11q23.3	915	CD3D_p1	ILMN_2261416	Lymphocyte marker
CD4	CD4	12p13.31	920	CD4_p1	ILMN_1727284	Lymphocyte marker
CD8A	CD8	2p11.2	925	CD8A_p3	ILMN_2353732	Lymphocyte marker
CD68	CD68	17p13.1	968	CD68_p1	ILMN_1714861	Macrophage marker
CD163	CD163	12p13.31	9332	CD163_p2	ILMN_2379599	Macrophage marker
BAP1	BRCA1 Associated Protein1	3p21.1	8314	BAP1_p1	ILMN_1768363	

5.1

Retinal Oximetry is Altered in Eyes with Choroidal Melanoma, but not in Eyes with Choroidal Nevi

Niels J. Brouwer[1], Marina Marinkovic[1], Jaco C. Bleeker[1], Mariam el Filali[2], Einar Stefansson[3], Gregorius P.M. Luyten[1], Martine J. Jager[1]

Retina 2020; 40(11):2207-2215

1 Department of Ophthalmology, Leiden University Medical Center, Leiden, The Netherlands
2 Department of Ophthalmology, Reinier de Graaf Gasthuis, Delft, The Netherlands
3 Department of Ophthalmology, Landspitali University Hospital, University of Iceland, Reykjavik, Iceland.

ABSTRACT

Purpose: To compare retinal vessel oxygenation in eyes with an untreated choroidal nevus or choroidal melanoma.

Methods: The affected and fellow eye of patients with an untreated choroidal nevus (n=42) or choroidal melanoma (n=45) were investigated using noninvasive retinal oximetry (Oxymap T1). Oxygen saturation of arterioles (ArtSat) and venules (VenSat) was determined, together with the arteriovenous difference (AV-difference).

Results: In choroidal nevus patients, retinal oximetry did not differ between the affected and fellow eye: the mean ArtSat was 94.5% and 94.2% (p=0.56), the VenSat was 60.5% and 61.3% (p=0.35) and the AV-difference was 34.0% and 32.9% (p=0.18), respectively. In choroidal melanoma patients, alterations were detected: the mean ArtSat was 94.8% and 93.2% (p=0.006), the VenSat was 58.0% and 60.0% (p=0.014) and the AV-difference was 36.8% and 33.2% (p<0.001), respectively. The largest increase in AV-difference was observed between the retinal halves without the lesion in melanoma eyes compared with the corresponding half in the fellow eye (37.5% vs. 32.1%, p<0.001).

Conclusion: Although retinal oximetry was not significantly altered in eyes with a choroidal nevus, eyes with choroidal melanoma showed an increased ArtSat and decreased VenSat, leading to an increased AV-difference. These changes may be caused by inflammation and a higher metabolism, with larger oxygen consumption, leading to altered blood flow and intraocular oxygen relocation.

INTRODUCTION

Although both arise from ocular melanocytes, a choroidal nevus (CN) is a benign ocular tumor, whereas a choroidal melanoma (CM) is a malignancy. A choroidal nevus is rather common, with a prevalence of 4.7 per 100 in the United States[1] and up to 6.5 per 100 in Australia.[2] Chroidal melanoma is more rare, with an incidence of 4.3 per million,[3] but forms the majority (>70%) of all ocular melanoma.[3] Both lesions occur more often in Caucasians and are associated with a phenotype of light skin and light eye color. Choroidal nevi are generally without symptoms and can remain untreated, although occasionally (in about 1%) treatments, including laser treatment or anti-vascular endothelial growth factor (VEGF) injections, are necessary to treat subretinal fluid or choroidal neovascular membranes.[4] Typical symptoms of CM are flashes, floaters, and a decrease in visual acuity (VA) or visual field defects. Despite treatment, including proton beam irradiation, brachytherapy, or enucleation, up to 50% of CM patients will die from metastases.[5]

In the development of CM, angiogenesis is an important parameter because growing tumors require new vessels to satisfy their demand to obtain oxygen and nutrients. An increased (histological) microvascular density of the tumor was found to relate to a worse prognosis in choroidal and ciliary body melanoma,[6,7] and has been associated with the presence of monosomy 3, which is a major risk factor for metastasis formation.[8]

Vascular changes are not restricted to the tumor tissue in CM. Using modern optical coherence tomography angiography (OCTA) technology, retinal changes were identified in eyes with untreated CM. These changes include enlargement of the deep foveal avascular zone and a decrease of the capillary vascular density, suggesting tumor-related parafoveal microvascular ischemia.[9] These retinal changes were not observed in a study on eyes containing a CN.[10]

A new technique to study retinal disease is through analysis of retinal vessel oxygenation by noninvasive retinal oximetry.[11] Vessel oximetry provides information on the oxygen levels in arteries and veins and the difference between them. A recent review describes findings in various (retinal) disorders, including diabetic retinopathy and central retinal vein occlusion.[12] After treatment for CM, altered levels of retinal arterial and venous oxygenation were detected in patients with radiation retinopathy.[13] No pretreatment values were determined however, although such information might help to understand why some eyes develop radiation retinopathy and others do not. To the best of our knowledge, no studies on retinal oximetry in untreated melanoma or nevus eyes have as yet been reported.

In this study, retinal oxygenation was investigated in eyes with untreated choroidal melanoma or choroidal nevi. The aim was to identify whether the presence of a benign or malignant choroidal

tumor affects the retinal vessels, and if so, to elucidate the mechanisms responsible. We hypothesized that eyes with choroidal melanoma show increased oxygen consumption compared with nondiseased eyes due to the tumor's metabolism, with a lesser effect in eyes with choroidal nevi.

METHODS

Study Population

Patients with an untreated CM or CN were included in this study at the Leiden University Medical Center (Leiden, The Netherlands), between September 2017 and May 2018. Patients were examined by an experienced oncologic ophthalmologist, using clinical examination, ultrasound investigation, and commonly fluorescein angiography.

Patients had to be 18 years or older at the moment of inclusion. Exclusion criteria were as follows: a melanoma or nevus in the fellow eye, previous removal (enucleation or exenteration) of the fellow eye, retinal disease in any eye (including age-related macular degeneration, central retinal vein occlusion, branch retinal vein occlusion, and diabetic retinopathy), previous ocular treatment with anti-VEGF medication in either eye, severe cataract, other opacities, or patient-related factors limiting the investigation. The study was approved by the Institutional Medical Ethics Committee of the LUMC (approval P17.134) and adhered to the tenets of the Declaration of Helsinki. Written informed consent was obtained from all participants.

Clinical Examination

Lesion size was evaluated using ultrasound and color fundus photography. Thickness measurements included the sclera. Flat lesions with no measurable thickness on ultrasound were assigned a default thickness of 1.50 mm for the purpose of analysis. The location of lesions was scored as 'central' if the lesion was fully between the arcades (or extended to the area between the arcades), as 'arcades' if it was not central but touching the arcades or optic disc, or as 'peripheral' if it was fully outside of the arcades and not touching the optic disc. Visual acuity was measured with Snellen charts. All ocular symptoms were recorded, including (but not limited to) decrease of visual acuity, flashes, floaters, pain, redness of the eye, or metamorphopsia. Both the affected (melanoma or nevus containing) and fellow eye were investigated. Pupils were dilated for clinical examination with eye drops of Tropicamide 0.5% and Phenylephrine 5%. Melanomas were staged according to the eighth edition of the AJCC TNM classification.[14]

The presence of risk factors for growth of choroidal nevi was determined. These are a thickness of >2 mm, subretinal fluid, clinical symptoms, orange pigment, a margin within 3 mm of the optic disc, absence of halo, absence of drusen, and ultrasound hollowness.[15]

Retinal Oximetry

Retinal oximetry was performed with the Oxymap T1 device (Oxymap, ehf., Reykjavik, Iceland). This noninvasive retinal oximeter is composed of two digital cameras, mounted on a fundus camera. The device simultaneously takes two fundus images with different wavelengths of light, at 570 nm and 600 nm. Specialized software automatically selects measurement points on the images and calculates the so-called 'optical density'. The optical density of hemoglobin is sensitive to oxygenation at 600 nm, but not at 570 nm; the ratio of the optical densities has a relationship to oxygen saturation. A pseudo color fundus map is automatically generated. The reliability and reproducibility of the Oxymap technique have been demonstrated before.[11]

Images were analyzed with the Oxymap Analyzer software version 2.5.2. An adapted version of the protocol by Geirsdottir et al was used to select vessel segments.[16] In short, a retinal image centered on the optic disc was used for analysis (Figure 1). Oxygen saturation was determined by the software in all retinal vessels in the area between two concentric circles of 1.5 and 3 optic disc diameters around the optic disc. Vessel segments were manually selected with a width of at least 8 pixels (approx. 74 µm), and a length of at least 50 pixels. Vessel crossings or areas with extremes in background brightness (due to e.g., undetected nearby vessels, scars, or hemorrhages) were excluded from the analysis.

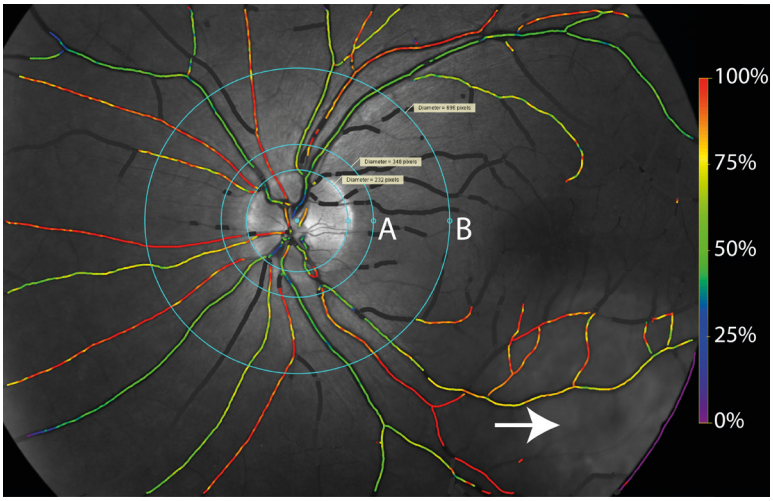

Figure 1. Pseudo color fundus map of a choroidal melanoma eye. The image is centered on the optic disc. In this specific case the choroidal melanoma is visible at the lower right (arrow). The Oxymap software automatically calculates vessel saturation and produces a color map (values correspond to the scale bar on the right side, ranging from 0% (purple) to 100% (red)). Vessel segments between the concentric circles at 1.5 (A) and 3 (B) disc diameters are manually selected for analysis. Vessels that are dark gray on the color map were too thin to acquire reliable measurements, and are not included in the analysis.

The mean width of selected arterial and venous vessel segments was reported (1 pixel corresponds to approx. 9 µm). The Oxymap Analyzer software provided an overall image quality score (0 low, 10 high) based on focus and contrast.

The overall retinal saturation of arteries (ArtSat), venules (VenSat), and the difference between these (AV-difference) was calculated. The affected eye was compared with the fellow eye of the same individual; the difference between two AV-differences was termed 'relative AV-difference' (Rel-AVdiff). A secondary analysis was performed on the saturation of the vessels in the retinal half overlying or not overlying the lesion (Figure 2).

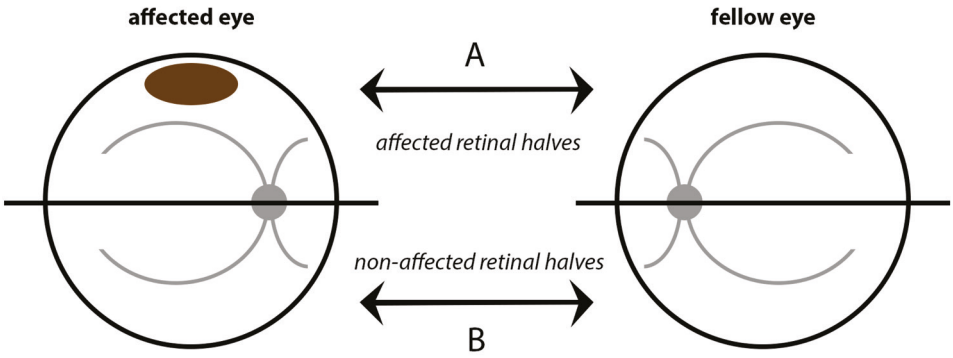

Figure 2. Comparison of retinal halves. In eyes with a choroidal melanoma or nevus, one retinal half can be defined containing the lesion ("affected halves") and one retinal half without the lesion ("nonaffected halves"). These halves were compared with the corresponding halves in the fellow eye (visualized by "A" and "B"). Retinal halves were divided by a horizontal or vertical line, seen from the optic disc, fitting the most appropriate division according to the location of the melanoma or nevus.

Statistics

Nominal data were analyzed with the chi-square test or Fisher exact test. Continuous data were analyzed with the independent t-test, paired t-test, or Kruskal-Wallis test, as appropriate. Linear univariate regression analysis was performed, and hazard rations with 95% confidence intervals were provided. Study data were analyzed with SPSS software version 23. P-values < 0.05 were considered statistically significant.

RESULTS

Patient Characteristics

A total of 45 patients with CM and 42 patients with CN were included. The mean age of the CM patients was 65.5 years, and this was 66.0 years for the patients with CN (p=0.85). The melanomas had a mean thickness of 4.0 mm and a mean largest basal diameter (LBD) of 11.9 mm; the nevi had a mean thickness of 1.8 mm (p<0.001) and a mean LBD of 6.4 mm (p<0.001). Choroidal melanoma lesions were staged T1 (14 cases, 31%), T2 (21 cases, 47%), T3 (7 cases, 16%) or T4 (3 cases, 7%). The general medical history showed that 18 (40%) of the CM patients had a cardiovascular disease (including diabetes, hypertension, hypercholesterolemia and atrial fibrillation) as did 18 (43%) of the CN patients (p=0.79). Of the CM patients, 9 (20%) had mild cataract in both eyes, versus 11 (26%) of CN patients (p=0.49). None of the studied patients had marked exudative retinal detachment. The mean visual acuity of CM patients was 0.89 (20/22) for the affected eye, and 1.09 (20/18) for the fellow eye (p=0.001). For CN patients this was 1.06 (20/19) and 1.08 (20/19), respectively (p=0.58). Table 1 shows the characteristics of the CM and CN patients.

Retinal Oximetry

We compared oximetry values between melanoma- or nevus-containing eyes with their fellow eyes. In CM patients, a difference was noticed between the affected and fellow eye: the overall ArtSat of the affected versus fellow eye was 94.8% versus 93.2% (p=0.006), the overall VenSat was 58.0% versus 60.0% (p=0.014), and the AV-difference was 36.8% versus 33.2% (p<0.001). In CN patients, the affected and fellow eye did not differ significantly: the overall ArtSat of the affected versus fellow eye was 94.5% versus 94.2% (p=0.57), the overall VenSat was 60.5% versus 61.3% (p=0.35), and the AV-difference was 34.0% versus 32.9% (p=0.18) (Table 2).

When we compared affected CM eyes to affected CN eyes, the AV-difference was found to be significantly higher in melanoma-containing eyes (36.8% for CM and 34.0% for CN, p=0.04), although the separate ArtSat (p=0.77) or VenSat (p=0.14) did not differ significantly.

Venous vessel segments of affected CM eyes were thicker compared with their fellow eyes (15.5 pixels vs. 14.9 pixels, p=0.019), whereas venous segments of the affected CN eyes were equally thick compared with their fellow eyes (15.3 pixels vs. 15.3 pixels, p=0.83). There were no significant differences in image quality between affected and fellow eyes for both CM and CN patients (p=0.19 and p=0.87, respectively) (Table 2).

Table 1. Baseline Characteristics of Patients with Choroidal Melanoma or Nevus.

	Melanoma patients Cases (%)	Nevus patients Cases (%)	p-value
Total	45 (100)	42 (100)	
Sex			
Male	27 (60)	14 (33)	0.013*
Female	18 (40)	28 (67)	
Age			
Mean ± SD	65.5 ± 14.2	66.0 ± 10.6	0.85†
Side			
OD	19 (42)	23 (55)	0.24*
OS	26 (58)	19 (45)	
Location			
Central	9 (20)	8 (19)	0.26‡
Arcade	12 (27)	18 (43)	
Peripheral	24 (53)	16 (38)	
Thickness			
Mean ± SD	4.0 ± 1.6	1.8 ± 0.5	<0.001†
Largest Basal Diameter			
Mean ± SD	11.9 ± 3.1	6.4 ± 2.7	<0.001†
TNM, T group (8th)			
T1	14 (31)	N.A.	N.A.
T2	21 (47)		
T3	7 (16)		
T4	3 (7)		
COMS size			
Small	14 (31)	N.A.	N.A.
Medium	27 (60)		
Large	4 (9)		
Tumor pigmentation			
Pigmented	36 (80)	34 (81)	1.00*
Amelanotic/Mixed	9 (20)	8 (19)	

** Pearson Chi Square test.*
† independent samples t-test.
‡ Fisher Exact test.
TNM, AJCC TNM classification; N.A., not applicable.

Table 2. Outcome of Retinal Oximetry in Eyes With a Choroidal Melanoma or Nevus Versus the Contralateral Eyes.

	Melanoma patients (n=45)			Nevus patients (n=42)		
	Affected eye	**Fellow eye**	**p-value**	**Affected eye**	**Fellow eye**	**p-value**
ArtSat (%)	94.8 ± 4.8	93.2 ± 4.9	0.006	94.5 ± 4.2	94.2 ± 3.6	0.56
VenSat (%)	58.0 ± 8.4	60.0 ± 9.3	0.014	60.5 ± 7.2	61.3 ± 6.7	0.35
AV-diff (%)	36.8 ± 6.3	33.2 ± 7.0	<0.001	34.0 ± 6.0	32.9 ± 5.5	0.18
Art. Diam. (pixels)*	12.0 ± 1.2	12.0 ± 1.0	0.98	12.1 ± 1.2	12.1 ± 1.1	0.80
Ven. Diam. (pixels)*	15.5 ± 1.6	14.9 ± 1.5	0.019	15.3 ± 1.5	15.3 ± 1.4	0.83
Image Quality (score)†	7.6 ± 0.8	7.8 ± 0.8	0.19	7.9 ± 0.6	7.9 ± 0.6	0.87

Values are reported as mean ± SD. All p-values were obtained using the paired samples t-test
**One pixel width corresponds to approx. 9 μ.*
†Overall image quality as provided by the Oxymap Analyzer software (scale: 0 = low, 10 = high).
ArtSat, Arterial Saturation; VenSat, Venous Saturation; AV-diff, Arteriovenous difference; Art. Diam., Arterial Diameter; Ven. Diam., Venous Diameter.

To determine whether the presence of a tumor affected the whole eye, we compared the affected and nonaffected retinal halves with their corresponding half in the fellow eye. A visual representation of these comparisons is provided in Figure 2. When we compared the affected retinal halves in CM patients with the corresponding halves in their fellow eye, a significant increase in ArtSat (94.9% vs 93.1%, p=0.027) was observed in the CM eye. There were no differences in VenSat or AV-difference (p=0.92 and p=0.096, respectively). A comparison of the nonaffected retinal halves in CM patients demonstrated a significant increase in ArtSat in the affected eye (94.5% vs. 93.0%, p=0.02), with additionally a significant decrease in VenSat (57.0% vs. 60.8%, p=0.001) and a significant increase in AV-difference (37.5% vs. 32.1%, p<0.001) In CN patients, no significant differences in ArtSat, VenSat or AV-difference were detected between the affected and nonaffected retinal halves of affected and fellow eyes (Table 3).

We wondered whether patient- or tumor-related factors contributed to the observed oximetry values in CM and CN patients. We noticed that a correlation existed between the AV-differences of the affected and the fellow eye in both groups: the Pearson correlation for CM patients was 0.77 (p<0.001), and for CN patients was 0.57 (p<0.001). This implies that further analyses should be performed using the relative AV-difference, as this parameter indicates the difference between the two eyes in one individual and, therefore, yields the overall effect of the presence of either a CM or CN.

In CM patients, a significant relation was found between older age and a higher Rel-AVdiff (linear regression, B=0.19, 95%CI 0.11-0.27, p<0.001). None of the other parameters (including tumor

thickness and location of the lesion in relation to the macula, arcades or periphery) was found to correlate significantly with the Rel-AVdiff (see Table, Supplemental Digital Content 1, http://links.lww.com/IAE/B156).

In CN patients, right eyes were related to a higher Rel-AVdiff (p=0.002), as was absence of ultrasound hollowness (p=0.015). None of the other parameters, including the presence of multiple risk factors for melanoma progression, was found to correlate significantly with the Rel-AVdiff (see Table, Supplemental Digital Content 2, http://links.lww.com/IAE/B157).

Table 3. Outcomes of Retinal Oximetry per Retinal half.

	Melanoma patients (n=45)			Nevus patients (n=42)		
	Affected eye	**Fellow eye**	**p-value**	**Affected eye**	**Fellow eye**	**p-value**
(A) Comparison of affected retinal halves						
ArtSat (%)	94.9 ± 5.8	93.1 ± 5.1	0.027	95.4 ± 6.0	93.9 ± 4.4	0.079
VenSat (%)	58.3 ± 9.7	58.4 ± 11.7	0.92	60.9 ± 8.4	60.4 ± 8.1	0.65
AV-diff (%)	36.6 ± 8.4	34.7 ± 9.2	0.096	34.5 ± 7.6	33.5 ± 6.6	0.41
(B) Comparison of nonaffected retinal halves						
ArtSat (%)	94.5 ± 5.3	93.0 ± 6.3	0.020	93.5 ± 4.1	94.3 ± 3.9	0.093
VenSat (%)	57.0 ± 9.6	60.8 ± 9.1	0.001	59.5 ± 8.2	61.4 ± 7.2	0.10
AV-diff (%)	37.5 ± 7.3	32.1 ± 7.7	<0.001	34.0 ± 6.8	32.9 ± 6.6	0.33

Values are reported as mean ± SD. All p-values were obtained using the paired samples t-test.
ArtSat, Arterial Saturation; VenSat, Venous Saturation; AV-diff, Arteriovenous difference.
Reported is the saturation of the affected versus similar retinal half in the fellow eye (A), and the saturation of the non-affected versus similar half in the fellow eye (B). A schematic explanation of the comparisons is provided in Figure 2.

DISCUSSION

In this study, we compared retinal oximetry of eyes with untreated choroidal melanoma or choroidal nevi with their fellow eye. We identified alterations in ArtSat and VenSat with a higher AV-difference in eyes with CM, whereas this was not observed in eyes with CN. In CM patients, older age was related to a higher Rel-AVdiff comparing affected and fellow eyes. As far as we know, these are new observations in CM, implicating that the presence of a melanoma is related to widespread retinal changes.

We hypothesize that multiple events contribute to the increased AV-difference in CM eyes. The increased oxygen demand of active tumor cells is the first step. Because CM is considered to be

mainly fed by vessels from the choroid, this would imply a role in tumor nourishment for the retinal vasculature that was investigated in this study. Because there is interaction between the choroidal and retinal circulation,[17] and oxygen can diffuse within these layers,[18] this can be plausible although it should be noted that we are unaware of studies that examined the retinal contribution to nourishment of choroidal lesions. There must be a second step, however, as regional differences in oxygenation also occurred in the nonmelanoma-containing part of the retina in CM eyes. This means that the presence of a tumor affects a large part of the eye. We did not observe a relation between oximetry values, obtained from vessels around the optic disc, and the location of the tumor as being central, near the arcades, or periphery. This contributes to the idea of a generalized involvement of the eye.

Central to overall retinal changes in CM eyes may be the presence of inflammation. Melanoma eyes contain higher concentrations of VEGF-A in both the aqueous and vitreous fluid,[19,20] and several other inflammatory cytokines and chemokines (including IL-6, IL-10, TNF-alfa) were found to be elevated in the vitreous as well.[21] Supporting the relation between inflammation and retinal oximetry, aberrant retinal oximetry values were correlated with the presence of various inflammatory markers of the aqueous humor in patients with diabetic retinopathy.[22] In diabetic retinopathy, as well as other ischemic retinopathies, inflammation and angiogenesis are known to be linked.[23,24] The production of VEGF-A in eyes with UM, as measured in aqueous humor, was positively related to UM tumor diameter and originated from both the tumor and overlying retinal tissue.[19] Because these cytokines reach other parts of the retina besides the tumor-overlying tissue, metabolic changes (which can be measured with the retinal oximetry) can be expected there as well.

An increased AV-difference of the nonaffected retinal halves in melanoma eyes may additionally be explained by oxygen relocation. Because the melanoma needs an increased amount of blood, a relative decrease in flow can be expected in the nonaffected retinal parts. A larger AV-difference would thereby reflect the increased extraction of oxygen from the reduced amount of available blood. This mechanism would be comparable to eyes with ischemic disease as central retinal vein occlusion, similarly detecting an increased overall AV-difference in the area with diminished flow.[25]

Another factor that may be of importance to the amount of oxygen in retinal vessels of melanoma eyes is the Warburg effect. This effect describes the phenomenon that cancer cells use anaerobic glycolysis for nourishment rather than aerobic pathways, despite the presence of oxygen.[26] This effect underlies modern-day positron emission tomography (PET) scans, using the enhanced glucose uptake to demonstrate the presence of malignancies. As mentioned before, there is interaction between the choroidal and retinal circulation,[17,18] although the magnitude of this interaction is not known for CM eyes. Implying a role for the Warburg effect in ocular melanoma, the relation between tumor presence and oxygen uptake may be complicated (as both an increased oxygen uptake due to tumor activity or a decreased oxygen uptake due to altered metabolism can be

expected). This effect may explain the absence of a relation between tumor size and AV-difference in our study, as larger tumors would not necessarily require more oxygen (Figure 3). Even more, it may add to the mechanism of increased oxygen uptake in the nonaffected retinal half, as the affected retinal half demonstrates an aberrant metabolism relying more on glucose than on oxygen.

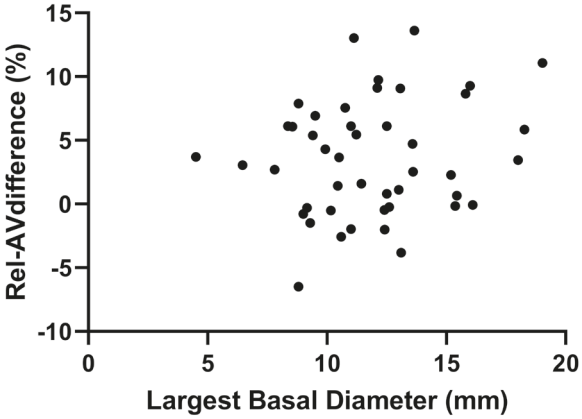

Figure 3. Relative AV-difference versus largest basal tumour diameter in choroidal melanoma patients. The relative AV-difference (i.e. the AV-difference of the affected eye minus the AV-difference of the fellow eye) is plotted against the largest basal diameter of the tumour in choroidal melanoma patients. The correlation is not statistically significant, with a correlation coefficient of 0.180 (p=0.24). This implies that in our study, no relation exists between tumour size and the relative AV-difference.

Older age was related to a larger Rel-AVdiff in CM patients. This means that the effect of melanoma presence on retinal oximetry is larger in older patients than in younger patients. We hypothesize that increased vessel wall stiffness in older patients limits flow alterations to account for increased oxygen demand, resulting in a larger extraction of oxygen from the available blood. In addition, tumor infiltrate may be involved because murine experiments demonstrated a relationship between older age and an increase of macrophages;[27,28] which have been suggested to be relevant for differences in tumor angiogenesis.[8,29]

In this study, we detected retinal oxygen imaging changes in CM eyes but not in CN eyes. This is in line with findings using OCTA, demonstrating foveal changes in melanoma eyes but not in nevi.[10] Differences may be due to a lower metabolic activity in nevi and to less local inflammation. Also, because of slow growth and a longer presence, recovery mechanisms may be more pronounced in nevus eyes, limiting differences in oximetry. Lesion size may be relevant as well, as it may act as

a barrier between the choroidal and retinal vasculature, and choroidal nevi are often smaller than melanoma. However, becuase lesion size did not relate to retinal oximetry within both the groups of melanoma or nevi in this study (Figure 3), this effect may be of limited concern.

Retinal oximetry has been described in many (ischemic) retinal diseases,[12,30] but, as far as we know, not in untreated CM or nevi. In a small study of eight patients with radiation retinopathy after treatment for CM, a reduced blood flow with increased ArtSat and VenSat was identified in affected eyes.[13] No pretreatment values were reported however. An interesting comparison can be made with studies on retinal vasculature in treatment-naïve melanoma and nevi using OCTA. It was found that the deep foveal avascular zone was larger in macular melanoma compared with healthy eyes. This was not the case for extramacular melanoma or nevi. Capillary vessel density was reduced in melanoma eyes but not in nevus eyes.[10] The authors hypothesized that parafoveal ischemia occurred due to tumor-related ischemia and intraocular leakage of cytokines. Our results on whole-eye involvement of saturation changes are in line with this finding, although we did not detect a difference between tumors located close to the macula and extramacular lesions. Another study detected higher ocular (choroidal) blood flow in eyes with uveal melanoma compared with the fellow eye, in line with the theory of increased demand due to the presence of a tumor.[31]

Our study is the first study to report on retinal oximetry in treatment-naïve melanoma and nevi. This provides baseline values for CM and CN, without the influence of earlier treatments. Because both eyes of each patient were examined in our study, a good comparison could be made, adjusting for patient-related parameters as systemic disease and age. Also, we could compare similar areas between the affected and fellow eyes, as it is known that oxygen levels are different for various areas of the retina, hampering comparisons within one eye.[11]

Because image quality and presence of comorbidity were similar between affected and fellow eyes, we feel that is unlikely that our results are due to measurement artifacts. Even more, low image quality or presence of cataract would lead to lower values of saturation in both arteries and venules,[32,33] although we detected a higher ArtSat in melanoma eyes; an additional mechanism is therefore needed to explain our findings.

It could be hypothesized that co-occurring retinal detachment, a condition that might cause retinal nonperfusion, may influence the AV-difference in our study. None of the studied patients had marked exudative retinal detachment, however, so it is not expected that this has biased the conclusions. Even so, the presence of subretinal fluid (which was more prevalent in melanoma eyes) could be hypothesized to have influenced the results. To test this, we compared melanoma eyes without subretinal fluid (n=19) to nevus eyes with subretinal fluid (n=3), as this should force effects into opposite directions. We found that the AV-difference in melanoma eyes remained higher compared with nevus eyes (mean 37.3%, SD 4.9 vs. 35.8%, SD 6.8; p=0.66) although this was not

statistically significant. However, the small number of nevus eyes hampers a statistical comparison. Although we observed that right eyes in CN patients were related to a higher Rel-AVdiff, we believe that this was by chance only and not reflecting a relevant pathophysiologic mechanism.

Currently, fluorescein angiography is a commonly used imaging technique to help differentiate CM from other lesions as hemangioma or nevi. This is an invasive technique, requiring the intravenous injection of a contrast agent. Although no pathognomonic pattern exists for CM, the characteristics include intrinsic circulation (due to abnormal vessels), hot spots (due to pinpoint leaks from the retinal pigment epithelium) and late leakage.[34] Our study identifies a new parameter that differs between CM and CN (i.e. increased oxygen use). Because the observed differences between eyes with CM and CN are small, this will currently not be of use as a diagnostic criterion, but it demonstrates that melanoma-related vascular alterations are present. An interesting future project would be to investigate whether retinal oximetry identifies patients with a higher risk of developing radiation retinopathy after radiation therapy, which could then have clinical implications to detect or follow selected patients, allowing for early treatment. Also, knowledge obtained by retinal oximetry may aid in the understanding of other imaging techniques, such as OCTA.

Concluding, our current study demonstrates that the presence of a CM influences the vessel oxygenation of the whole eye, which is probably due to an increased oxygen metabolism; this was not observed in eyes with CN. Future projects may test the value of oximetry in the identification and follow-up of patients with radiation retinopathy, and may guide future studies into antiangiogenic therapies.

ACKNOWLEDGEMENTS

The authors thank Katinka Emmanouilidis-van der Spek and Wouter B.H.J. Vehmeijer (Leiden University Medical Center, The Netherlands) for their support with data acquisition and software analysis.

Footnotes: N.J. Brouwer is the recipient of a MD/PhD programme grant of the Leiden University Medical Center. Financial support for acquisition of the Oxymap T1 Device was provided by Mr. O. Roell and the Stichting Nederlands Oogheelkundig Onderzoek (SNOO). The sponsors had no role in the design or conduct of the study.

E. Stefansson is patentholder and shareholder in Oxymap ehf (Reykjavic, Iceland), which produces retinal oximeters.

REFERENCES

1. Qiu M, Shields CL. Choroidal Nevus in the United States Adult Population: Racial Disparities and Associated Factors in the National Health and Nutrition Examination Survey. *Ophthalmology.* 2015;122(10):2071-2083.
2. Sumich P, Mitchell P, Wang JJ. Choroidal nevi in a white population: the Blue Mountains Eye Study. *Arch Ophthalmol.* 1998;116(5):645-650.
3. McLaughlin CC, Wu XC, Jemal A, et al. Incidence of noncutaneous melanomas in the U.S. *Cancer.* 2005;103(5):1000-1007.
4. Shields CL, Furuta M, Mashayekhi A, et al. Clinical spectrum of choroidal nevi based on age at presentation in 3422 consecutive eyes. *Ophthalmology.* 2008;115(3):546-552 e542.
5. Damato B. Progress in the management of patients with uveal melanoma. The 2012 Ashton Lecture. *Eye (Lond).* 2012;26(9):1157-1172.
6. Makitie T, Summanen P, Tarkkanen A, Kivela T. Microvascular density in predicting survival of patients with choroidal and ciliary body melanoma. *Invest Ophthalmol Vis Sci.* 1999;40(11):2471-2480.
7. Foss AJ, Alexander RA, Jefferies LW, et al. Microvessel count predicts survival in uveal melanoma. *Cancer Res.* 1996;56(13):2900-2903.
8. Bronkhorst IH, Ly LV, Jordanova ES, et al. Detection of M2-macrophages in uveal melanoma and relation with survival. *Invest Ophthalmol Vis Sci.* 2011;52(2):643-650.
9. Li Y, Say EA, Ferenczy S, Agni M, Shields CL. Altered Parafoveal Microvasculature in Treatment-Naive Choroidal Melanoma Eyes Detected by Optical Coherence Tomography Angiography. *Retina.* 2017;37(1):32-40.
10. Valverde-Megias A, Say EA, Ferenczy SR, Shields CL. Differential Macular Features on Optical Coherence Tomography Angiography in Eyes with Choroidal Nevus and Melanoma. *Retina.* 2017;37(4):731-740.
11. Palsson O, Geirsdottir A, Hardarson SH, et al. Retinal oximetry images must be standardized: a methodological analysis. *Invest Ophthalmol Vis Sci.* 2012;53(4):1729-1733.
12. Stefansson E, Olafsdottir OB, Einarsdottir AB, et al. Retinal Oximetry Discovers Novel Biomarkers in Retinal and Brain Diseases. *Invest Ophthalmol Vis Sci.* 2017;58(6):BIO227-BIO233.
13. Rose K, Krema H, Durairaj P, et al. Retinal perfusion changes in radiation retinopathy. *Acta Ophthalmol.* 2018.
14. Kivela T, Simpson ER, Grossniklaus HE, et al. Uveal Melanoma. In: Amin MB ES, Green F, ed. *AJCC Cancer Staging Manual, 8th ed*. New York: Springer; 2017:805-817.
15. Shields CL, Furuta M, Berman EL, et al. Choroidal nevus transformation into melanoma: analysis of 2514 consecutive cases. *Arch Ophthalmol.* 2009;127(8):981-987.
16. Geirsdottir A, Palsson O, Hardarson SH, et al. Retinal vessel oxygen saturation in healthy individuals. *Invest Ophthalmol Vis Sci.* 2012;53(9):5433-5442.
17. Yu PK, McAllister IL, Morgan WH, Cringle SJ, Yu DY. Inter-Relationship of Arterial Supply to Human Retina, Choroid, and Optic Nerve Head Using Micro Perfusion and Labeling. *Invest Ophthalmol Vis Sci.* 2017;58(9):3565-3574.
18. Nickla DL, Wallman J. The multifunctional choroid. *Prog Retin Eye Res.* 2010;29(2):144-168.
19. Missotten GS, Notting IC, Schlingemann RO, et al. Vascular endothelial growth factor a in eyes with uveal melanoma. *Arch Ophthalmol.* 2006;124(10):1428-1434.
20. Boyd SR, Tan D, Bunce C, et al. Vascular endothelial growth factor is elevated in ocular fluids of eyes harbouring uveal melanoma: identification of a potential therapeutic window. *Br J Ophthalmol.* 2002;86(4):448-452.
21. Nagarkatti-Gude N, Bronkhorst IH, van Duinen SG, Luyten GP, Jager MJ. Cytokines and chemokines in the vitreous fluid of eyes with uveal melanoma. *Invest Ophthalmol Vis Sci.* 2012;53(11):6748-6755.

22. Tayyari F, Khuu LA, Sivak JM, et al. Retinal blood oxygen saturation and aqueous humour biomarkers in early diabetic retinopathy. *Acta Ophthalmol.* 2019;97(5):e673-e679.
23. Semeraro F, Cancarini A, dell'Omo R, et al. Diabetic Retinopathy: Vascular and Inflammatory Disease. *J Diabetes Res.* 2015;2015:582060.
24. Rivera JC, Dabouz R, Noueihed B, et al. Ischemic Retinopathies: Oxidative Stress and Inflammation. *Oxid Med Cell Longev.* 2017;2017:3940241.
25. Traustason S, la Cour M, Larsen M. Retinal vascular oximetry during ranibizumab treatment of central retinal vein occlusion. *Br J Ophthalmol.* 2014;98(9):1208-1211.
26. Dell' Antone P. Energy metabolism in cancer cells: how to explain the Warburg and Crabtree effects? *Med Hypotheses.* 2012;79(3):388-392.
27. Ashcroft GS, Horan MA, Ferguson MW. Aging is associated with reduced deposition of specific extracellular matrix components, an upregulation of angiogenesis, and an altered inflammatory response in a murine incisional wound healing model. *J Invest Dermatol.* 1997;108(4):430-437.
28. Ly LV, Baghat A, Versluis M, et al. In aged mice, outgrowth of intraocular melanoma depends on proangiogenic M2-type macrophages. *J Immunol.* 2010;185(6):3481-3488.
29. Jager MJ, Klaver CCW. Macrophages feel their age in macular degeneration. *Journal of Clinical Investigation.* 2007;117(11):3182-3184.
30. Rilven S, Torp TL, Grauslund J. Retinal oximetry in patients with ischaemic retinal diseases. *Acta Ophthalmol.* 2017;95(2):119-127.
31. Yang YC, Kent D, Fenerty CH, Kosmin AS, Damato BE. Pulsatile ocular blood flow in eyes with untreated choroidal melanoma. *Eye (Lond).* 1997;11 (Pt 3):331-334.
32. Chen H, Lin H, Chen W, et al. Preoperative and postoperative measurements of retinal vessel oxygen saturation in patients with different grades of cataracts. *Acta Ophthalmol.* 2017;95(6):e436-e442.
33. Hardarson SH, Jonsson BA, Karlsson RA, et al. Image Quality Affects Measurements of Retinal Vessel Oxygen Saturation. *Investigative Ophthalmology & Visual Science.* 2015;56(7).
34. Bakri SJ, Sculley L, Singh AD. Diagnostic techniques. In: Singh AD, Damato BE, Pe'er J, Murphree AL, Perry JD, eds. *Clinical Ophthalmic Oncology*. Edinburgh, UK: Elsevier-Saunders; 2007:175-180.

SUPPLEMENTARY MATERIAL

Supplemental Digital Content 1, Table. Clinical parameters related to Rel-AVdiff in choroidal melanoma patients.

Total	Low Rel-AVdiff* Cases (%) 23 (100)	High Rel-AVdiff* Cases (%) 22 (100)	p-value
Sex			
Male	15 (65)	12 (55)	0.47‡
Female	8 (35)	10 (45)	
Age			
Mean ± SD	60.3 ± 15.6	70.9 ± 10.4	0.011††
Side			
OD	10 (43)	9 (41)	0.86‡
OS	13 (57)	13 (59)	
Location			
Central	6 (26)	3 (14)	0.41**
Arcade	7 (30)	5 (23)	
Peripheral	10 (44)	14 (64)	
Thickness			
Mean ± SD	4.00 ± 1.4	4.02 ± 1.8	0.97††
Largest Bas Diameter			
Mean ± SD	11.9 ± 2.9	11.8 ± 3.4	0.92††
TNM, T group (8th)			
T1	6 (26)	8 (36)	0.67**
T2	11 (48)	10 (46)	
T3	5 (22)	2 (9)	
T4	1 (4)	2 (9)	
COMS			
Small	6 (26)	8 (36)	0.81**
Medium	15 (65)	12 (55)	
Large	2 (9)	2 (9)	
Pigmentation			
Pigmented	19 (83)	17 (77)	0.87**
Amelanotic	3 (13)	3 (14)	
Mixed	1 (4)	2 (9)	
Subretinal fluid			

Supplemental Digital Content 1, Table. Continued

Total	Low Rel-AVdiff* Cases (%) 23 (100)	High Rel-AVdiff* Cases (%) 22 (100)	p-value
No	11 (48)	8 (36)	0.44‡
Yes	12 (52)	14 (64)	
Symptoms			
No	10 (43)	9 (41)	0.86‡
Yes	13 (57)	13 (59)	
Orange pigment†			
No	13 (59)	15 (68)	0.53‡
Yes	9 (41)	7 (32)	
Margin < 3mm of optic disc			
No	17 (74)	20 (91)	0.24‡
Yes	6 (26)	2 (9)	

SD = Standard Deviation; TNM = AJCC TNM classification.

** Low and High groups are separated based on the median Rel-AVdiff.*

† One lesion could not be scored on these items due to its location.

‡ Pearson Chi Square test.

*** Fisher Exact test.*

†† Independent samples t-test.

Supplemental Digital Content 2, Table. Clinical parameters related to Rel-AVdiff in choroidal nevus patients.

Total	Low Rel-AVdiff* Cases (%) 21 (100)	High Rel-AVdiff* Cases (%) 21 (100)	p-value
Sex			
Male	5 (24)	9 (43)	0.19**
Female	16 (77)	12 (57)	
Age			
Mean ± SD	65.4 ± 12.3	66.5 ± 8.8	0.74‡‡
Side			
OD	6 (29)	17 (81)	0.002**
OS	15 (71)	4 (19)	
Location			
Central	4 (19)	4 (19)	0.92††
Arcade	10 (48)	8 (38)	
Peripheral	7 (33)	9 (43)	
Thickness			
Mean ± SD	1.76 ± 0.35	1.84 ± 0.54	0.61‡‡
Largest Bas Diameter			
Mean ± SD	6.96 ± 2.8	5.89 ± 2.7	0.22‡‡
Nevus Thickness Cat			
Small (<1.5mm)	10 (48)	12 (57)	0.54**
Large (≥1.5mm)	11 (52)	9 (43)	
Pigmentation			
Pigmented	18 (86)	16 (76)	0.83††
Amelanotic	2 (10)	4 (19)	
Mixed	1 (5)	1 (5)	
Risk Factors†,‡			
0-4	18 (90)	16 (89)	1.00**
5-8	2 (10)	2 (11)	
Thickness >2 mm			
No	15 (71)	15 (71)	1.00**
Yes	6 (29)	6 (29)	
Subretinal fluid			
No	20 (95)	19 (90)	1.00**
Yes	1 (5)	2 (10)	

Supplemental Digital Content 2, Table. Continued.

Total	Low Rel-AVdiff* Cases (%) 21 (100)	High Rel-AVdiff* Cases (%) 21 (100)	p-value
Symptoms			
No	18 (86)	18 (86)	1.00**
Yes	3 (14)	3 (14)	
Orange pigment			
No	18 (86)	15 (71)	0.45**
Yes	3 (14)	6 (29)	
Margin < 3mm of optic disc			
No	14 (67)	14 (67)	1.00**
Yes	7 (33)	7 (33)	
Ultrasound Hollow‡			
No	10 (50)	16 (89)	0.015**
Yes	10 (50)	2 (11)	
Halo Absent‡			
No	1 (5)	2 (10)	0.61**
Yes	20 (95)	18 (90)	
Drusen Absent			
No	11 (52)	7 (33)	0.21**
Yes	10 (48)	14 (67)	

SD = Standard Deviation; TNM = AJCC TNM classification.

** Low and High groups are separated based on the median Rel-AVdiff.*

† Risk factors are: thickness of >2mm, subretinal fluid, clinical symptoms, orange pigment, a margin within 3mm of the optic disc, absence of halo, absence of drusen, and ultrasound hollowness.[15]

‡ Four lesions in total could not be scored due to missing data.

*** Pearson Chi Square test.*

†† Fisher Exact test.

‡‡ Independent samples t-test.

5.2

Anterior Segment OCTA of Melanocytic Lesions of the Conjunctiva and Iris

Niels J. Brouwer[1], Marina Marinkovic[1], Jaco C. Bleeker[1], Gregorius P.M. Luyten[1] , Martine J. Jager[1]

Am J Ophthalmol 2021; 222:137-147

1 Department of Ophthalmology, Leiden University Medical Center, Leiden, The Netherlands

ABSTRACT

PURPOSE: To study the feasibility and diagnostic value of vascular imaging using optical coherence tomography (OCT)-angiography (OCTA) of melanocytic lesions of the conjunctiva and iris.

DESIGN: Cross-sectional study.

METHODS: Twenty-five patients with an untreated conjunctival lesion (5 melanoma, 13 nevus, 7 primary acquired melanosis [PAM]) and 52 patients with an untreated iris lesion (10 melanoma, 42 nevus) were included. Patients were imaged using a commercially available OCTA device, with the addition of an anterior segment lens and manual focussing. Tumor vessel presence, vascular patterns and vascular density were assessed.

RESULTS: Good OCTA images were obtained in 18 of 25 conjunctival lesions and 42 of 52 iris lesions. Failure was caused by lack of patient cooperation, an unfavorable location, or mydriasis. In all imaged conjunctival lesions and 77% of iris lesions, vascular structures were detected. Conjunctival melanoma and nevi demonstrated the same intralesional tortuous patterns, whereas vasculature in eyes with PAM was similar to normal conjunctiva. Both iris melanoma and nevi demonstrated tortuous patterns, distinct from the radially oriented normal iris vasculature.

CONCLUSIONS: Optical coherence tomography angiography (OCTA) allows for noninvasive imaging of the vasculature in melanocytic lesions of the conjunctiva and iris. Good image quality depends highly on patient cooperation and lesion characteristics. Differentiation of benign and malignant lesions was not possible. New software is called for to improve image acquisition and analysis.

INTRODUCTION

Nevi of the conjunctiva or iris are relatively common conditions, requiring no further treatment apart from close observation or excision for cosmetic reasons.[1,2] Malignant melanoma of the conjunctiva or iris, however, have the potential to metastasize and treatment is generally indicated.[3,4] Clinical differentiation of these entities can be challenging,[1,2] despite imaging techniques such as ultrasonography and optical coherence tomography (OCT) of the anterior segment.

A factor to differentiate melanocytic lesions of the eye, is tumor vascularity. Fluorescein angiography (FA) has long been used to differentiate between benign and malignant choroidal lesions.[5,6] Since the early 1970s, FA was used to study iris lesions as well.[7,8] Benign iris lesions demonstrated less chaotic patterns than malignant lesions and even showed silencing (masking) of the FA signal,[9-12] but there has been no full agreement on all FA findings, such as orderly patterns or leakage of dye.[11,13-15] The usefulness of dye-based angiography of the conjunctiva has long been limited since low-molecular-weight fluorescein easily leaks from vessels,[16] and to these authors' knowledge, no studies of dye-based angiography of the intrinsic vasculature of conjunctival melanoma, nevi or primary acquired melanosis (PAM) exist. As a drawback for FA, the technique is relatively time consuming and requires injection of dye, with potential adverse events.[17,18]

A new and non-invasive technique to study ocular vasculature is OCT-Angiography (OCTA). This technique has been developed to depict the retinal vasculature.[19] By measuring changes in sequential cross-sectional images (B-scans), flow can be visualized without the need for intravenous dye injection. OCTA has several additional advantages, such as high image quality, visualization of vessels at different depths, and easy operating instructions. Recently it was demonstrated that, apart from imaging retinal vessels, OCTA can image tumor vessels in choroidal melanoma and nevi as well.[20-22]

With some adjustments to the conventional posterior segment technique (using an anterior segment lens, and (manual) focussing on the ocular surface), OCTA can detect vascular flow in the anterior segment as well.[23] Small series have demonstrated proof-of-principle in iridal, corneal and conjunctival tissue.[24-26] Most commercially available OCTA devices do not support the full range of image acquisition and analysis modes for the anterior segment that were developed for retinal images; however, and obtaining good image quality can therefore be challenging.[27] Using OCTA of the anterior segment, Skalet and associates demonstrated vascular patterns in pigmented lesions of the iris and found a difference in vascular density between three iris nevi and three iris melanomas.[28] To the present authors' knowledge, no studies of OCTA of melanocytic lesions of the conjunctiva exist.

The feasibility of OCTA of melanocytic lesions of the conjunctiva and iris were studied, with a second aim of identifying differentiating features between benign and malignant lesions.

METHODS

Patient selection

Patients were recruited at the Leiden University Medical Center (LUMC), a tertiary hospital for ocular oncology in The Netherlands. Included were patients with a treatment-naïve conjunctival melanoma (n=5), conjunctival nevus (n=13), primary acquired melanosis (PAM, n=7), iris melanoma (n=10), or iris nevus (n=42). Patients were seen and diagnosed in the ophthalmo-oncology clinic of the Department of Ophthalmology. Standard clinical examinations were performed including slit lamp examination and anterior segment photography.

Approval for this cross-sectional study was obtained from the Institutional Ethics Review Board of the LUMC (approval number P17.134). The tenets of the declaration of Helsinki were followed. All patients signed an informed consent.

Conjunctival lesions

All 5 conjunctival melanoma cases were confirmed by histology. In 9 of 13 cases, the diagnosis of conjunctival nevus was confirmed by histology; 4 cases were diagnosed clinically (with circumscribed lesions and cysts; in 3 of those cases the lesion had not changed in more than 30 years, and in 1 case in more than 9 years).[2,29] Six cases were diagnosed with PAM, which was confirmed by biopsy (showing 4 cases with atypia, and 2 without), whereas 1 case was diagnosed clinically (with a unilateral diffuse lesion and variable presence [i.e. "waxing and waning"]).[2] Where possible, the thickness of conjunctival lesions was determined by histology, the largest basal diameter was assessed by clinical measurements.

Iris lesions

Ultrasonography was performed on all iris lesions to determine lesion size and extent. Iris lesions were diagnosed by clinical and ultrasonographic characteristics. Diagnosis of melanoma was based on tumor size, evidence of growth, ultrasonographic structure, visibility of vessels, and secondary symptoms such as elevated intraocular pressure or cataract.[30-33] Biopsies were only performed in 2 patients, confirming the clinical diagnosis of 1 iris nevus and 1 iris melanoma.

OCTA acquisition and analysis

Images were taken prior to any surgical procedure. OCTA scans were performed using an "RS 3000 Advance" OCTA device (Nidek, Ltd, Gamagori, JA). A device-specific anterior segment lens was inserted. Patients were positioned in front of the device and instructed to focus on either the external fixator light or gaze in a specific direction. Conjunctival lesions were assessed under dimmed light conditions, and iris lesions were assessed under ambient room lighting to create miosis. First, the anterior segment lens was positioned close to the ocular surface to retrieve a signal from the tissue of

interest. Second, the focus was manually adjusted to obtain the clearest view. Images were acquired in retinal mode (while focussing on the conjunctiva or iris), with an image size setting of 3x3 mm for all patients (for detailed vessel density calculation), and additional scans of up to 9x9 mm were taken for larger lesions (for an overview). Image resolution of all scans (regardless of the size of the depicted area) was 256x256 pixels. Images were acquired in 'skip mode', as the trace function (developed for retinal imaging) proved not suitable to trace the surface of the conjunctiva or iris.

Images were assessed using the device-specific software Navis-Ex version 1.8 (Nidek). As the automated image segmentation (developed to delineate retinal layers) misinterpreted the conjunctival and iridal structures, 2 segmentation lines were drawn manually to include the lesion of interest.

First, it was recorded if an acceptable image was obtained, that is, if a full scan was completed, including the lesion of interest, without major surface-trace issues resulting in total artefacts. Second, the presence of vessel-like segments was noted, in healthy conjunctiva or iris tissue (to assess successful imaging) and at the site of the lesion. When vessels were visible in the lesion, image quality of those vessels was graded subjectively as (grade 1) clear visibility, (grade 2) medium visibility, or (grade 3) nonclear visibility.

Vessel density (VD) was quantified in the en-face images of a subset of patients using ImageJ software (National Institutes of Health, Besthesda, Maryland, USA). The lesion of interest was selected manually, binarization was performed with an Otsu threshold.[34] In the area of interest, pixels attributed to vessels (those above the threshold) were counted and expressed as a percentage of the total selected area size.

In conjunctival lesions, VD was first calculated in all bulbar lesions (excluding lesions of the caruncle or plica), and a second analysis was performed excluding heavily pigmented and grade 3 quality lesions (to limit the influence of signal masking by heavy pigmentation and noise). In iris lesions, the VD was similarly calculated in those cases with a light or modest tumor pigmentation and grades 1-2 image quality. The en-face area of ectropion uveae was excluded from analysis.

Anterior Segment-OCT imaging

Each lesion was assessed with high-resolution anterior segment (AS)-OCT using the same imaging device that was applied for AS-OCTA. The anterior segment lens was inserted, capturing images in regular anterior segment mode. Images with a width of 6.0 mm were acquired in a radial pattern at 'ultra fine' resolution.

Statistical analysis

Statistical analyses were performed using SPSS version 23 software (IBM, Armonk, New York, USA). For all analyses, p values < 0.05 were considered significant. Differences between continuous data were tested using the Mann-Whitney U or Kruskal-Wallis test. Differences between discrete data were tested with the Fisher exact or linear-by-linear test.

FOV when examining the anterior segment

Due to different optics when examining the anterior segment, the automated scales to measure retinal or choroidal structures were not fully applicable to this study. To determine the field of view (FOV) of the anterior segment, a calliper was placed with a fixed width of 9.0 mm in front of the anterior segment lens and a scan was acquired with a setting of 9 x 9 mm (Supplemental Figure; available at AJO.com). By comparing the ratio between the calliper size and the scanned image size, the true FOV in the settings proved to be 12.3 x 12.3 mm. A similar technique to determine the FOV of anterior segment OCTA was reported by Liu and associates, resulting in comparable (yet device-specific) values.[35]

RESULTS

Patients

Twenty-five patients with conjunctival lesions were included. Five of the lesions (20%) were diagnosed as conjunctival melanoma, 13 (52%) as conjunctival nevus, and 7 (28%) as PAM. The mean age of patients with a conjunctival lesion was 48.2 year. All lesions were epibulbar or involved the plica or caruncle; all 5 conjunctival melanoma were stage pT1a (TNM staging system, 8th edition).[36]

Fifty-two patients with an iris lesion were included. Ten of them (19%) received diagnoses of iris melanoma and 42 (81%) of iris nevus. The mean age of patients with an iris lesion was 61.4 years. The TNM stage of the iris melanoma was T1a (n=6), T1b (n=1), T1c (n=1), T2a (n=1); 1 case of predominantly ciliary body melanoma with significant iris involvement was T2b (TNM staging system, 8th edition).[37] Further patient and tumor characteristics are provided in Table 1.

Table 1. Characteristics of the included patients.

	Conjunctival Melanoma n=5 *Cases (%)*	**Conjunctival Nevus n=13** *Cases (%)*	**PAM n=7** *Cases (%)*	**Iris Melanoma n=10** *Cases (%)*	**Iris Nevus n=42** *Cases (%)*
Sex					
Male	2 (40)	4 (31)	2 (29)	5 (50)	23 (55)
Female	3 (60)	9 (69)	5 (71)	5 (50)	19 (45)
Mean age, y	61.0	38.2	57.7	60.4	61.6
Mean thickness, mm[a]	0.77	N.A.	N.A.	2.0	1.1
Mean LBD, mm	6.6	3.3	N.A.	6.4	3.9
Lesion Pigmentation					
Amelanotic/light	3 (60)	5 (38)	3 (43)	2 (20)	15 (36)
Medium	1 (20)	4 (31)	4 (57)	5 (50)	13 (31)
Dark	1 (20)	4 (31)	0 (0)	3 (30)	14 (33)
Location in the conjunctiva					
Bulbar	5 (100)	7 (54)	7 (100)	N.A.	N.A.
Plica/caruncle	0 (0)	6 (46)	0 (0)	N.A.	N.A.
Location in an iris quadrant					
Superior	N.A.	N.A.	N.A.	1 (10)	6 (14)
Inferior	N.A.	N.A.	N.A.	6 (60)	20 (48)
Temporal/Nasal	N.A.	N.A.	N.A.	3 (30)	16 (38)
Mean clock h, size	N.A.	N.A.	N.A.	2.4	1.7
Secondary cataract	N.A.	N.A.	N.A.	0 (0)	1 (2)
IOP > 20 or IOP treatment	N.A.	N.A.	N.A.	3 (30)	7 (17)
Ectropion uveae	N.A.	N.A.	N.A.	6 (60)	20 (48)
Iris Color					
Blue	N.A.	N.A.	N.A.	10 (100)	37 (88)
Green	N.A.	N.A.	N.A.	0 (0)	4 (10)
Brown	N.A.	N.A.	N.A.	0 (0)	1 (2)

IOP = intraocular pressure; LBD = largest basal diameter; N.A. = not applicable; PAM = primary acquired melanosis. Values are n (%).

[a] *Data for lesion thickness (assessed by histology) were available for all conjunctival melanoma but none of the conjunctival nevi or PAM.*

Conjunctival lesions

OCTA scans were acquired successfully in 4 of 5 (80%) conjunctival melanoma patients, and 8 of 13 (62%) conjunctival nevus patients. Causes for failure were patient noncooperation (n=3), lack of focus (n=2 caruncular lesions), or a bulbar location behind the upper eyelid (n=1). Manual lifting of the upper eye lid proved not feasible as this resulted in minor movements that hampered the investigation (Supplemental Table; available at AJO.com).

In all 4 successfully imaged conjunctival melanoma, and all 8 successfully imaged conjunctival nevi, tortuous vascular structures were detected, distinct from the adjacent conjunctiva (Figure 1). Image quality was better in lightly pigmented lesions compared to dark lesions (Table 2). The plica/caruncle proved difficult to image due to its irregular shape (Table 2). In many nevi, cysts were observed that lacked vascularity**.** No clear differences were seen between vascular patterns of conjunctival nevi and melanoma.

Table 2. Comparison between the Visibility of Vessels (Image Quality) and Lesion Characteristics.

Image quality	**Clear n=13 Cases (%)**	**Medium n=18 Cases (%)**	**Nonclear n=21 Cases (%)**	**p-value**
Lesion Pigmentation *(all)*				
Amelanotic/light	9 (69)	7 (39)	5 (24)	0.006 [a]
Medium	3 (23)	9 (50)	9 (43)	
Dark	1 (8)	2 (11)	7 (33)	
Mean patient age, y	44.2	60.5	61.2	0.019 [b c]
Location *(Conjunctival lesions)*	*n=4*	n=10	n=4	
Bulbar	4 (100)	9 (90)	2 (50)	0.065 [a]
Plica/caruncle	0 (0)	1 (10)	2 (50)	
Location *(Iris lesions)*	*n=9*	*n=8*	*n=17*	
Superior	0 (0)	0 (0)	2 (12)	0.45 [a]
Inferior	5 (56)	7 (88)	9 (53)	
Temp/Nasal	4 (44)	1 (12)	6 (35)	

Values are n (%).

[a] *Linear-by-linear test;*

[b] *Kruskal-Wallis test;*

[c] *P value comparing age in groups 'clear' vs 'medium' quality is p=0.022 (Mann-Whitney U test)*

In 6 of 7 patients (86%) with PAM, OCTA scans were acquired successfully. In 1 case, the lesion proved small and was misidentified during scanning. Vascular structures were detected in all images, both when the full conjunctiva and sclera were selected, and when only a superficial layer of tissue (approximating the epithelium) was selected for analysis (Figure 2). The vasculature at the area of PAM appeared similar to the normal conjunctival vessels of the contralateral eye, although in PAM the vasculature appeared to be somewhat finer (Figure 2).

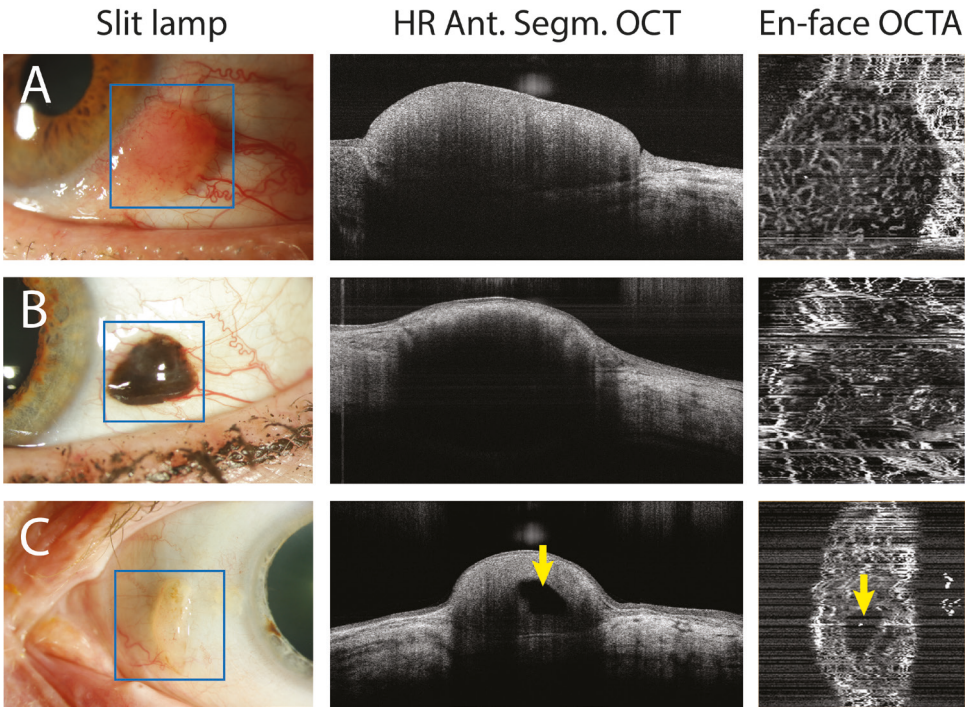

Figure 1. Conjunctival melanoma and nevi. Vascular structures were seen in all conjunctival lesions. Image quality was higher in lightly pigmented lesions (Patient A, conjunctival melanoma) compared to those with dark lesions (Patient B, conjunctival melanoma), and had better signal penetrance. In conjunctival nevi (Patient C), cysts were often seen as areas with no apparent vasculature. (All OCTA scans were acquired in a 3x3mm setting.)

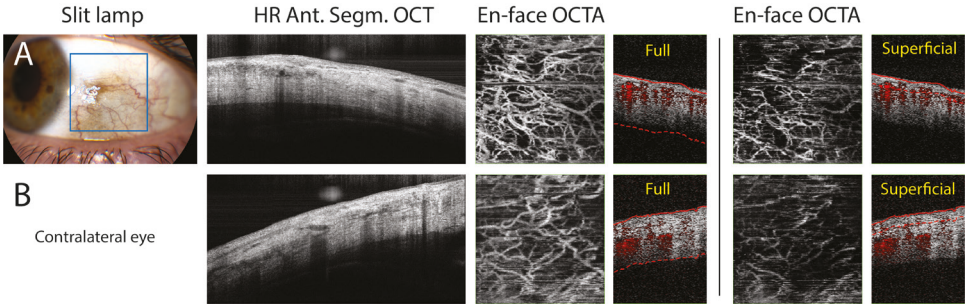

Figure 2. PAM and healthy conjunctiva. The vascular pattern in eyes with PAM (A, top row) was similar to the pattern in the contralateral eye with unaffected conjunctiva (B, bottom row), although the meshwork might have been somewhat finer. Both a full-thickness selection of tissue (including sclera and conjunctiva) and a superficial layer selection (approximating the conjunctival epithelium) are presented. (All OCTA scans were acquired in a 3x3mm setting.) PAM = primary acquired melanosis.

The median vascular density (VD) of quantified bulbar lesions was 35.5% in conjunctival melanoma (n=4), and 32.5% in conjunctival nevi (n=5) (p=0.62). In a further selection of light and medium pigmented cases only, this was 38.3% (melanoma, n=3) and 37.0% (nevi, n=3) (p=0.51) (Table 3). The median VD of PAM was 40.3% (n=5), whereas that of paired conjunctiva tissue of contralateral eyes was 41.1% (p=0.14). The VD was decreased in heavily pigmented conjunctival lesions compared to lightly pigmented lesions (median VD 29.1% n=3, and 38.4% n=12, p=0.014) (Figure 3). The presence of cysts was noticed: cysts were seen on scans in 0 of 6 melanoma, 4 of 8 nevi and 0 of 6 PAM, p=0.046.

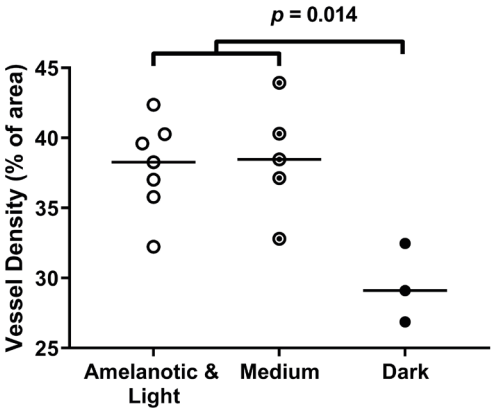

Figure 3. Vascular density and pigmentation of conjunctival lesions. The VD was higher in lightly pigmented lesions compared to dark lesions (p=0.014), suggesting a masking effect due to pigment. VD = vessel density.

Iris lesions

OCTA scans were acquired successfully in 9 of 10 patients (90%) with iris melanoma and 35 of 42 patients (83%) with iris nevi. Unsuccessful acquisition was due to patient noncooperation (n=4), pharmacological mydriasis (n=2), a lesion located too far in the ciliary body (n=1), or a location behind the upper eyelid (n=1). Similar to the investigation of conjunctival lesions, manual lifting of the eyelid proved not feasible as this induced movement (Supplemental Table; available at AJO.com).

Vascular structures were seen in the area of the lesion in all 9 (100%) successfully imaged iris melanoma, and 25 of 35 iris nevi (71%) (p=0.09) (Table 3). Of the 10 cases with no visible lesion vessels, 8 cases (80%) did demonstrate vessels outside the lesion, indicating that the OCTA technique was feasible, but lesion characteristics (such as significant masking, or absence of vessels) caused a reduced vascular signal.

Table 3. Comparing OCTA Features among Various Lesions.[f]

	Conjunctival Melanoma n=4 *Cases (%)*	**Conjunctival Nevi n=8** *Cases (%)*	**PAM n=6** *Cases (%)*	*P value*	**Iris Melanoma n=9** *Cases (%)*	**Iris Nevi n=35** *Cases (%)*	*P value*
Vessels in lesion							
Present	4 (100)	8 (100)	6 (100)	N.A.	9 (100)	25 (71)	0.09 [a]
Absent	0	0	0		0 (0)	10 (29)	
Vessel visibility							
1 (clear)	1 (25)	2 (25)	1 (17)	1.00 [b]	2 (22)	7 (20)	0.071 [b]
2 (medium)	2 (50)	4 (50)	4 (67)		2 (22)	6 (17)	
3 (nonclear)	1 (25)	2 (25)	1 (17)		5 (56)	12 (34)	
Vessels absent					0 (0)	10 (29)	
VD *(overall)*	*n=4*	*n=5*	*n=6*		n=4	n=13	
Median (%)	35.5	32.5	39.4	0.14 [c]	31.8	30.5	0.82 [d]
VD *(selection [e])*	*n=3*	*n=3*	*n=5*		n=4	n=12	
Median (%)	38.3	37.0	40.3	0.26 [c]	31.8	29.8	1.00 [d]

NA = not applicable; PAM = primary acquired melanosis; VD = vessel density.
[a] Fisher Exact test. [b] Linear-by-linear test. [c] Kruskal-Wallis test. [d] Mann-Whitney U test. [e] in the selection of lesions with a light/medium pigmentation and grades 1-2 image quality. [f] Reported are patients whose imaging scans were 'acceptable'. P-values refer to the comparison of all conjunctival lesions, and all iris lesions, respectively.

In healthy iris tissue, radially oriented vessels were seen (Figure 4). The vasculature was remarkably more pronounced in the posterior layers of iris stroma than in the anterior layers (Figure 4). This is consistent with findings from FA studies, describing that iris veins (which are larger and more tortuous than arteries) are located in the posterior stroma.[38]

Tortuous patterns were visible in iris melanoma as well as nevi (Figure 5). Image quality was graded as good or medium in 4 cases (44%) of melanoma, and 13 cases (37%) of nevi. Image quality was better in amelanotic or lightly pigmented lesions than in those with dark pigmentation, and in those with a younger age than those who were older (Figure 5, Table 2). In cases with ectropion uveae, it was seen that the OCTA signal was blocked, causing a shadow on the cross-sectional B-scan, and an apparent avascular area on the en-face OCTA (Figure 5). We did not see clear differences in vascular patterns between iris nevi and melanoma. The signal tended to be more often absent or of low quality in nevi; however, that could have been due either to masking or because of a truly reduced vascular density (p=0.07).

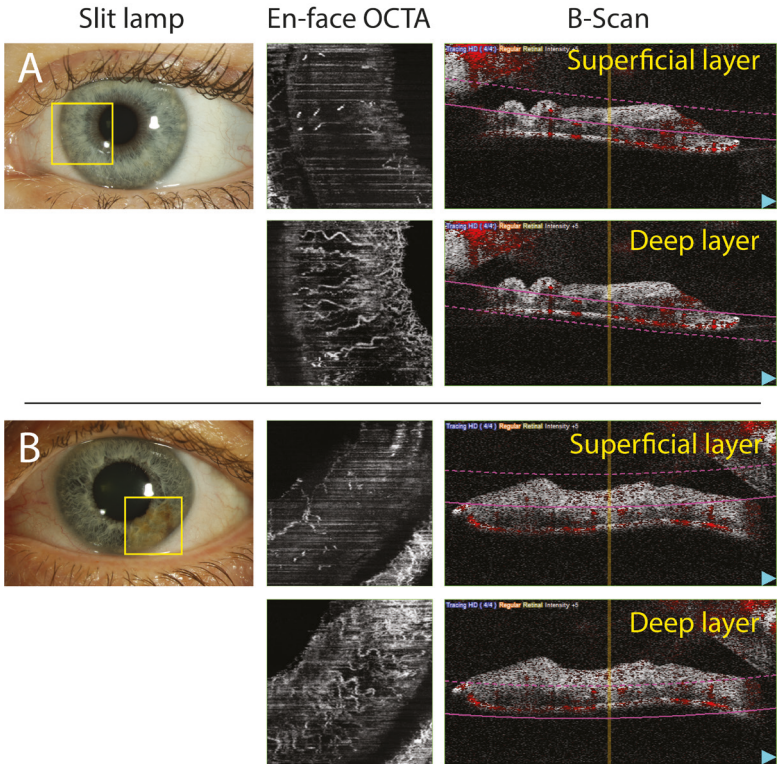

Figure 4. Iris vessels at different depths of tissue. (A) In a healthy iris, the radial pattern of iris vessels was clearly visible with OCTA. The vasculature was often more pronounced in the deep (posterior) layers of the iris than in the superficial (anterior) layers. (B) The vessels (iris nevus) may be intrinsic to the tumor or derived from normal vessels. (All OCTA Scans were acquired in a 3x3mm setting.) OCTA = optical coherence tomography angiography.

The median VD of light or medium pigmented iris melanoma was 31.8% (n=4); for iris nevi this was 29.8% (n=12) (p=0.99). The median VD of all iris lesions combined was 30.5%, this was significantly less than the median VD of paired healthy iris tissue of contralateral eyes (n=15) (35.6%, p=0.012).

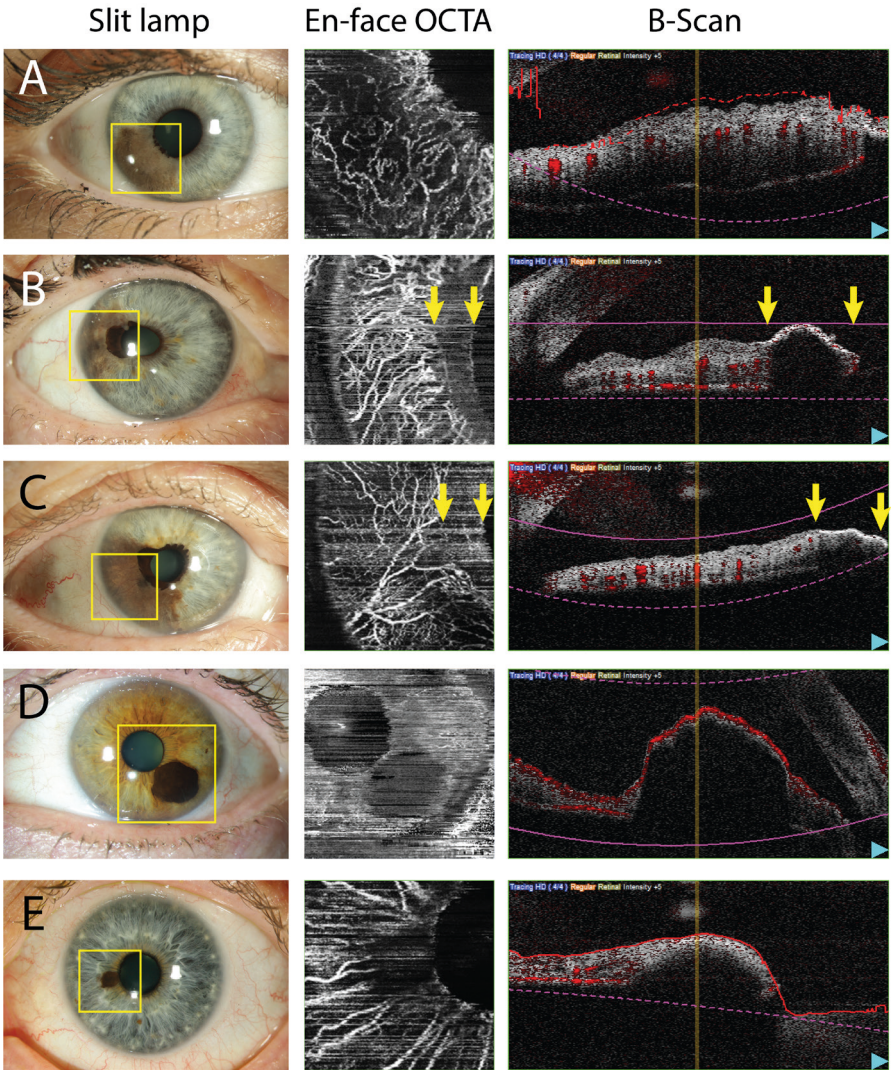

Figure 5. Iris melanoma and nevi. Three examples of iris lesions with visible tortuous vascular patterns are shown. (A) melanoma, (B) melanoma and (C) nevus. The dark pigmented lesion of Patient D (nevus) and E (nevus) blocked the OCT signal, resulting in an apparent avascular area on OCTA. Similarly, in Patient B and C, the blocking effect of an ectropion uveae was seen. (Scans A, B, C, and E were acquired in a 3x3mm setting; scan D was acquired in a 6x6mm setting.)

DISCUSSION

Various melanocytic lesions of the anterior segment were studied using OCTA. To the authors' knowledge, this is the first report of OCTA in melanocytic lesions of the conjunctiva, and the largest study of OCTA in melanocytic lesions of the iris. Vessels were depicted in all conjunctival and most iris lesions. Obtaining good quality images depended largely on patient cooperation, lesion location, and tumor pigmentation. Significantly better imaging was seen in lightly pigmented lesions and younger patients. Although vascular patterns of the melanocytic lesions were distinct from healthy tissue, no differentiating OCTA features were found between nevi and melanoma of either the conjunctiva or iris.

Tortuous vascular patterns were detected in both conjunctival nevi and melanoma, which was different from PAM, which apparently lacked an intrinsic vasculature. No vascular patterns or VD measurements were observed that discriminated between conjunctival nevi and melanoma, apart from avascular areas in nevi due to cysts. The absence of distinct vessels in PAM might have been due to confinement to epithelium, not requiring internal vessels as with thicker nodular lesions; the apparent finer meshwork compared to normal conjunctiva may be due to masking by pigment.

Few studies of OCTA of the conjunctiva exist. Healthy conjunctiva has been studied using OCTA resulting in a better visibility of vessels compared to biomicroscopy.[25,35] In a single conjunctival haemangioma, OCTA depicted vasculature better than conventional FA.[39] Recently, OCTA of the conjunctiva and cornea was reported to be better at detecting ischemia compared to clinical examination in patients with chemical injury,[40] and OCTA proved feasible in pinguecula and pterygia,[41] and ocular surface squamous neoplasia.[42]

Some authors have studied vasculature in conjunctival melanoma using immunohistochemistry. Tuomaala and associates quantified vessels in 56 samples by using endothelial marker CD34 and noted no relationship with tumor thickness or survival.[43] Subjectively, in that work, the microvascular density was comparable to uveal melanoma. A later report found less CD34 expression in conjunctival melanoma than in surrounding noncancerous stroma, suggesting it to be a hypovascular tumor, despite VEGF production.[44] Heindl and associates studied lymphatic vessels using immunohistochemistry in 109 samples and found a relationship between the presence of vessels and larger lesions and a worse recurrence and survival rate.[45] In the present study, however, the authors could not differentiate between blood vessels and lymphatic vessels.

OCTA was used to detect vessels in healthy iris tissue of all but 2 cases. Interestingly, those 2 irises were brown or green, unlike most of the patients, who had blue irises. This was consistent with earlier studies that found that darker iris pigmentation related to worse detection of vessels using OCTA.[46] Iris lesions displayed tortuous patterns, which were clearly distinct from healthy radial

vessels (Figure 4 and 5). Different patterns between iris nevi and melanoma were not observed, but vessels tended to be absent more frequently in iris nevi. This is consistent with earlier reports of FA in iris tumors. Masking has been related to benign lesions, whereas melanoma demonstrated more chaotic patterns.[9-12] The value of these patterns is debated, as geometric patterns were observed in benign lesions as well, and pigment is a known masking factor when using FA.[10,12,13]

The VD in this study did not differ between lightly pigmented iris melanoma (n=4) and nevi (n=12). This may not be surprising, considering the small sample size, but is remarkably different from earlier observations that described a higher VD in 3 iris melanoma compared to 3 iris nevi.[28] In that work, the presence of darkly pigmented, or cyst-containing lesions was not reported, however, while that may have influenced measurements. Alternatively, the present technique might have been less sensitive to changes.

The OCTA device applied in this study (Nidek) uses a spectral domain (SD) technique with an 880 nm wavelength. Present commercially available OCTA devices usually apply either a SD or swept source (SS) technique, with some differences in the underlying technique. SS systems use light of a higher wavelength, allowing visualization of deeper layers, but at a lower resolution.[27] Skalet and associates reported that pigmented lesions of the iris were better imaged with a 1050 nm technique than with 840 nm,[28] mainly due to tissue penetrance. The present study, in line with others,[35,39] demonstrated that images can be acquired using the SD technique as well but that tissue penetrance is an important limitation, possibly favouring techniques with longer wavelengths.

Our data set was large considering the rarity of the studied diseases, but small for statistical analysis. Motion artefacts influenced imaging significantly, resulting in some uninterpretable images and possible underestimation of effects. Motion caused increased 'flow', whereas masking or nonpenetrance of the OCT signal caused decreased 'flow' (which may explain the decreased VD in iris lesions compared to healthy tissue). The authors, therefore, call for the development of new software to help in image acquisition and analysis (eg, for stabilizing images as in assessment of the retina).

We regard it as a strength that almost all conjunctival lesions in this project were diagnosed by histology. In 3 cases of conjunctival nevus and 1 case of PAM, no tissue was obtained as the clinical diagnosis was clear and not suspicious for malignancy. This is common in clinical management of conjunctival lesions,[2,29,47] and these authors do not believe that obtaining tissue would have influenced results. Even so, a limitation of this study was that iris lesions were usually diagnosed by clinical investigation and ultrasonography only.[30-32] Although there is debate about the exact clinical features of benign and malignant iris lesions,[48] it is common to treat malignant lesions without obtaining histology, and to manage unsuspicious iris lesions by observation.[30,31,33]

Our study shows that OCTA can be used in anterior segment ocular oncology, but better software and enhanced imaging techniques are needed before conclusions about its clinical utility can be drawn. Imaging techniques that are not dependent on light (such as ultrasound biomicroscopy, using sound waves) may be more suitable to depict tumor size,[49] but AS-OCT [50] and AS-OCTA may provide an additional parameter for differentiating disease (eg, providing reassurance when no abnormal vessels are seen). With better techniques, a prognostic value of angiography may be established. For now, these authors propose that OCTA is most suitable for superficial and nonpigmented disease (eg, lymphoma, ocular surface squamous neoplasia, or basal cell carcinoma) or lightly pigmented melanoma or nevi. As OCTA requires no intravenous dye, with its potential adverse events,[17,18] the use of OCTA may become more widespread than fluorescein angiography or indocyanine green angiography has been up to now.

We conclude that it is feasible to obtain OCTA images of melanocytic lesions of the anterior segment. Good image quality, however, depends highly on patient cooperation and lesion characteristics such as location and pigmentation. New software is called for to improve image acquisition and analysis, and to further develop OCTA analysis of anterior segment lesions. While promising by the noninvasive nature and clinical ease, the role of OCTA in clinical and investigational anterior segment ocular oncology is yet to be established.

ACKNOWLEDGEMENTS/DISCLOSURES

All authors have completed and submitted the ICMJE form for disclosure of potential conflicts of interest and none were reported. This study was supported by the European Commission Horizon 2020 program UMCure (667787). The sponsors had no role in the design or conduct of this study. N.B. received an MD/PhD programme grant from Leiden University Medical Center, Leiden, The Netherlands. All other authors have reported that they have no relationships relevant to the contents of this paper to disclose.

The authors thank Laméris Ootech BV, Ede, The Netherlands, for providing the imaging device used in this study.

REFERENCES

1. Shields CL, Kaliki S, Hutchinson A, et al. Iris nevus growth into melanoma: analysis of 1611 consecutive eyes: the ABCDEF guide. *Ophthalmology.* 2013;120(4):766-772.
2. Shields CL, Shields JA. Tumors of the conjunctiva and cornea. *Indian J Ophthalmol.* 2019;67(12):1930-1948.
3. Wong JR, Nanji AA, Galor A, Karp CL. Management of conjunctival malignant melanoma: a review and update. *Expert Rev Ophthalmol.* 2014;9(3):185-204.
4. Popovic M, Ahmed IIK, DiGiovanni J, Shields CL. Radiotherapeutic and surgical management of iris melanoma: A review. *Surv Ophthalmol.* 2017;62(3):302-311.
5. Bakri SJ, Sculley L, Singh AD. Diagnostic techniques. In: Singh AD, Damato BE, Pe'er J, Murphree AL, Perry JD, eds. *Clinical Ophthalmic Oncology*. Edinburgh, UK: Elsevier-Saunders; 2007:175-180.
6. Oosterhuis JA, van Waveren CW. Fluorescein photography in malignant melanoma. *Ophthalmologica.* 1968;156(2):101-116.
7. Cheng H, Bron AJ, Easty D. A study of iris masses by fluorescein angiography. *Trans Ophthalmol Soc U K.* 1971;91:199-205.
8. Greite JH. [Fluorescence angiography in iris tumors]. *Ber Zusammenkunft Dtsch Ophthalmol Ges.* 1974;72:343-347.
9. Kottow M. Fluorescein angiographic behaviour of iris masses. *Ophthalmologica.* 1977;174(4):217-223.
10. Brovkina AF, Chichua AG. Value of fluorescein iridography in diagnosis of tumours of the iridociliary zone. *Br J Ophthalmol.* 1979;63(3):157-160.
11. Jakobiec FA, Depot MJ, Henkind P, Spencer WH. Fluorescein angiographic patterns of iris melanocytic tumors. *Arch Ophthalmol.* 1982;100(8):1288-1299.
12. Dart JK, Marsh RJ, Garner A, Cooling RJ. Fluorescein angiography of anterior uveal melanocytic tumours. *Br J Ophthalmol.* 1988;72(5):326-337.
13. Demeler U. [Control of the course of iris tumors with the aid of fluorescence angiography]. *Adv Ophthalmol.* 1978;35:167-178.
14. Christiansen JM, Wetzig PC, Thatcher DB, Green WR. Diagnosis and management of anterior uveal tumors. *Ophthalmic Surg.* 1979;10(1):81-88.
15. Bandello F, Brancato R, Lattanzio R, et al. Biomicroscopy and fluorescein angiography of pigmented iris tumors. A retrospective study on 44 cases. *Int Ophthalmol.* 1994;18(2):61-70.
16. Meyer PA, Watson PG. Low dose fluorescein angiography of the conjunctiva and episclera. *Br J Ophthalmol.* 1987;71(1):2-10.
17. Kwan AS, Barry C, McAllister IL, Constable I. Fluorescein angiography and adverse drug reactions revisited: the Lions Eye experience. *Clin Exp Ophthalmol.* 2006;34(1):33-38.
18. Hope-Ross M, Yannuzzi LA, Gragoudas ES, et al. Adverse reactions due to indocyanine green. *Ophthalmology.* 1994;101(3):529-533.
19. Spaide RF, Klancnik JM, Jr., Cooney MJ. Retinal vascular layers imaged by fluorescein angiography and optical coherence tomography angiography. *JAMA Ophthalmol.* 2015;133(1):45-50.
20. Cennamo G, Romano MR, Breve MA, et al. Evaluation of choroidal tumors with optical coherence tomography: enhanced depth imaging and OCT-angiography features. *Eye (Lond).* 2017;31(6):906-915.
21. Toledo JJ, Asencio-Duran M, Garcia-Martinez JR, Lopez-Gaona A. Use of OCT Angiography in Choroidal Melanocytic Tumors. *J Ophthalmol.* 2017;2017:1573154.
22. Pellegrini M, Corvi F, Invernizzi A, et al. SWEPT-SOURCE OPTICAL COHERENCE TOMOGRAPHY ANGIOGRAPHY IN CHOROIDAL MELANOMA: An Analysis of 22 Consecutive Cases. *Retina.* 2019;39(8):1510-1519.

23. Ang M, Baskaran M, Werkmeister RM, et al. Anterior segment optical coherence tomography. *Prog Retin Eye Res.* 2018;66:132-156.
24. Allegrini D, Montesano G, Pece A. Optical Coherence Tomography Angiography in a Normal Iris. *Ophthalmic Surg Lasers Imaging Retina.* 2016;47(12):1138-1139.
25. Akagi T, Uji A, Huang AS, et al. Conjunctival and Intrascleral Vasculatures Assessed Using Anterior Segment Optical Coherence Tomography Angiography in Normal Eyes. *Am J Ophthalmol.* 2018;196:1-9.
26. Ang M, Sim DA, Keane PA, et al. Optical Coherence Tomography Angiography for Anterior Segment Vasculature Imaging. *Ophthalmology.* 2015;122(9):1740-1747.
27. Lee WD, Devarajan K, Chua J, et al. Optical coherence tomography angiography for the anterior segment. *Eye Vis (Lond).* 2019;6:4.
28. Skalet AH, Li Y, Lu CD, et al. Optical Coherence Tomography Angiography Characteristics of Iris Melanocytic Tumors. *Ophthalmology.* 2017;124(2):197-204.
29. Shields CL, Fasiuddin AF, Mashayekhi A, Shields JA. Conjunctival nevi: clinical features and natural course in 410 consecutive patients. *Arch Ophthalmol.* 2004;122(2):167-175.
30. Harbour JW, Augsburger JJ, Eagle RC, Jr. Initial management and follow-up of melanocytic iris tumors. *Ophthalmology.* 1995;102(12):1987-1993.
31. Conway RM, Chua WC, Qureshi C, Billson FA. Primary iris melanoma: diagnostic features and outcome of conservative surgical treatment. *Br J Ophthalmol.* 2001;85(7):848-854.
32. Giuliari GP, Krema H, McGowan HD, Pavlin CJ, Simpson ER. Clinical and ultrasound biomicroscopy features associated with growth in iris melanocytic lesions. *Am J Ophthalmol.* 2012;153(6):1043-1049.
33. Oxenreiter MM, Lane AM, Jain P, Kim IK, Gragoudas ES. Conservative management of suspicious melanocytic lesions of the iris. *Graefes Arch Clin Exp Ophthalmol.* 2019;257(6):1319-1324.
34. Mehta N, Liu K, Alibhai AY, et al. Impact of Binarization Thresholding and Brightness/Contrast Adjustment Methodology on Optical Coherence Tomography Angiography Image Quantification. *Am J Ophthalmol.* 2019.
35. Liu Z, Wang H, Jiang H, Gameiro GR, Wang J. Quantitative analysis of conjunctival microvasculature imaged using optical coherence tomography angiography. *Eye Vis (Lond).* 2019;6:5.
36. Coupland SE, Barnhill RL, Conway M, et al. Conjunctival Melanoma. In: Amin MB ES, Green F, ed. *AJCC Canger Staging Manual, 8th ed*. New York: Springer; 2017:795-803.
37. Kivela T, Simpson ER, Grossniklaus HE, et al. Uveal Melanoma. In: Amin MB ES, Green F, ed. *AJCC Cancer Staging Manual, 8th ed*. New York: Springer; 2017:805-817.
38. Brancato R, Bandello F, Lattanzio R. Iris fluorescein angiography in clinical practice. *Surv Ophthalmol.* 1997;42(1):41-70.
39. Chien JL, Sioufi K, Shields CL. Optical Coherence Tomography Angiography of Conjunctival Racemose Hemangioma. *Ophthalmology.* 2017;124(4):449.
40. Fung SSM, Stewart RMK, Dhallu SK, et al. Anterior Segment Optical Coherence Tomographic Angiography Assessment of Acute Chemical Injury. *Am J Ophthalmol.* 2019;205:165-174.
41. Zhao F, Cai S, Huang Z, Ding P, Du C. Optical Coherence Tomography Angiography in Pinguecula and Pterygium. *Cornea.* 2020;39(1):99-103.
42. Liu Z, Karp CL, Galor A, et al. Role of optical coherence tomography angiography in the characterization of vascular network patterns of ocular surface squamous neoplasia. *Ocul Surf.* 2020.
43. Tuomaala S, Toivonen P, Al-Jamal R, Kivela T. Prognostic significance of histopathology of primary conjunctival melanoma in Caucasians. *Curr Eye Res.* 2007;32(11):939-952.
44. Kase S, Kikuchi I, Ishida S. Expression of VEGF in human conjunctival melanoma analyzed with immunohistochemistry. *Clin Ophthalmol.* 2018;12:2363-2367.

45. Heindl LM, Hofmann-Rummelt C, Adler W, et al. Prognostic significance of tumor-associated lymphangiogenesis in malignant melanomas of the conjunctiva. *Ophthalmology.* 2011;118(12):2351-2360.
46. Zett C, Stina DMR, Kato RT, Novais EA, Allemann N. Comparison of anterior segment optical coherence tomography angiography and fluorescein angiography for iris vasculature analysis. *Graefes Arch Clin Exp Ophthalmol.* 2018;256(4):683-691.
47. Gloor P, Alexandrakis G. Clinical characterization of primary acquired melanosis. *Gaz Med Fr.* 1995;36(8):1721-1729.
48. Jakobiec FA, Silbert G. Are most iris "melanomas' really nevi? A clinicopathologic study of 189 lesions. *Arch Ophthalmol.* 1981;99(12):2117-2132.
49. Bianciotto C, Shields CL, Guzman JM, et al. Assessment of anterior segment tumors with ultrasound biomicroscopy versus anterior segment optical coherence tomography in 200 cases. *Ophthalmology.* 2011;118(7):1297-1302.
50. Nanji AA, Sayyad FE, Galor A, Dubovy S, Karp CL. High-Resolution Optical Coherence Tomography as an Adjunctive Tool in the Diagnosis of Corneal and Conjunctival Pathology. *Ocul Surf.* 2015;13(3):226-235.

SUPPLEMENTARY MATERIAL

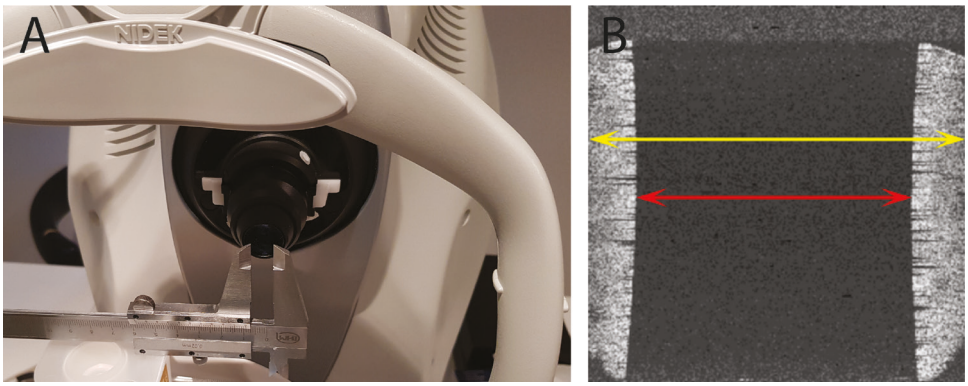

Supplemental Figure. Imaging of calliper with an anterior segment lens. (A) a calliper was positioned in front of the OCTA device at some distance from the anterior-segment lens, similar to the situation of true ocular imaging. (B) The image was acquired in a 9.0 mm setting (yellow arrow), but due to different optics when using the anterior segment lens, the calliper distance with a width of 9.0 mm (red arrow), appears smaller. Using the ratio of these arrows, the true imaging size was determined.

Supplemental Table. Flow Chart of Patient Numbers, Explaining the Numbers of Analysed Cases.

	Conjunctival Melanoma (n, %)	**Conjunctival Nevus (n, %)**	**PAM (n, %)**	**Iris Melanoma (n, %)**	**Iris Nevus (n, %)**
Included patients:	5 (100)	13 (100)	7 (100)	10 (100)	42 (100)
Loss due to:	*Behind eye lid 1*	*Non-coop 3* *No focus 2*	*Wrong area 1*	*Hidden in ciliary body 1*	*Non-coop 4* *Behind eye lid 1* *Mydriasis 2*
Acceptable OCTA:	4 (80)	8 (62)	6 (86)	9 (90)	35 (83)
Vessels outside lesion					
Present	4 (100)	8 (100)	5 (100)[a]	9 (100)	33 (94)
Absent	0	0	0	0 (0)	2 (6)

Non-coop = non-cooperation; OCTA = optical coherence tomography angiography; PAM = primary acquired melanosis.
[a] in 1 case of PAM, no nonaffected tissue could be analyzed.

CLINICAL CASES

Chapter 6: Clinical Cases

6.1 Conjunctival Metastasis of a Cutaneous Melanoma
6.2 Development of Ocular Rosacea following Combined Ipilimumab and Nivolumab Treatment for Metastatic Malignant Skin Melanoma
6.3 Two Late Recurrences of Conjunctival Melanoma
6.4 Multiple Pigmented Conjunctival Lesions following Intravitreal Injections in a Patient with Uveal Melanoma

6.1

Conjunctival Metastasis of a Cutaneous Melanoma

Niels J. Brouwer[1], Marina Marinkovic[1], Anouk Jochems[2], Ellen W. Kapiteijn[2], Sjoerd G. van Duinen[3], Barbara I. Haeseker[4], Martine J. Jager[1], Gregorius P.M. Luyten[1]

Ocul Oncol Pathol 2018; 4(2):107-111

1 Department of Ophthalmology, Leiden University Medical Centre, Leiden, The Netherlands
2 Department of Medical Oncology, Leiden University Medical Centre, Leiden, The Netherlands
3 Department of Pathology, Leiden University Medical Centre, Leiden, The Netherlands
4 Department of Ophthalmology, Alrijne Hospital, Leiden, The Netherlands

ABSTRACT

Purpose: To report a patient who presented with a conjunctival tumour as a first sign of distant metastasis of cutaneous melanoma. The patient was treated successfully with BRAF/MEK-inhibitors and anti-PD-1 antibodies.

Methods: Clinical and histopathological examination of the conjunctival lesion.

Results: A 74-year-old man was referred to our hospital with a pigmented conjunctival tumour, 5 months after having been diagnosed with cutaneous melanoma on his right scapula with loco-regional axillary lymph node metastases. The conjunctival lesion was excised and showed a BRAF V600E mutation. Histopathology showed a melanoma with characteristics suspicious for metastasis, as the lesion did not have a relation with the overlying epithelium. Systemic screening showed multiple distant metastases of the cutaneous melanoma in spleen, liver and bone. Systemic treatment with the combination of a BRAF-inhibitor (dabrafenib) and MEK-inhibitor (trametinib) was started and followed by a switch to an anti-PD-1 antibody (pembrolizumab). Twenty-two months later, the patient is alive and in good clinical health.

Conclusion: Conjunctival metastases of cutaneous melanoma may mimic primary conjunctival melanoma. A good medical history and systemic work-up are required to differentiate these diseases. Identification of the proper diagnosis including mutation analysis is crucial, allowing patients to benefit from newly introduced treatment strategies for metastatic cutaneous melanoma.

Established Facts:

- Cutaneous melanoma may metastasize to various locations, including the conjunctiva.
- New treatments for metastasized cutaneous melanoma are currently available.

Novel Insights:

- Ophthalmologists should be aware that systemic work-up and a proper medical history are required to differentiate metastases of cutaneous melanoma from primary conjunctival melanoma, thus allowing patients to benefit from the newly introduced treatments.

INTRODUCTION

Since melanocytes are naturally widespread in the human body, melanoma can develop as a primary malignancy at various locations. Most commonly, it develops as a primary melanoma of the skin. In ophthalmology, melanoma can arise from the uvea and conjunctiva. Cutaneous melanoma can spread via the lymph system or by haematogenous dissemination. Metastases are often located in subcutaneous tissue, visceral organs, the brain and bone, but other – more rare – locations such as the conjunctiva have been reported.[1,2]

In recent years, new therapies have been developed for advanced stages of cutaneous melanoma, acting on specific molecular pathways ("targeted therapy") or stimulating the immune system ("immune checkpoint inhibitors").[3] BRAF-inhibitors (e.g. dabrafenib, vemurafenib) and MEK-inhibitors (e.g. trametinib, cobimetinib) are examples of targeted therapy. The BRAF-mutation is frequently present in melanoma, mostly of the non-chronic sun exposed skin parts,[4] and leads to cell proliferation via activation of the MAPK pathway, in which MEK proteins are involved. Inhibition of BRAF and MEK counteracts the proliferative effect of this pathway. Anti-PD-1 antibodies (e.g. nivolumab, pembrolizumab) are examples of immune checkpoint inhibitors, blocking the inhibitory signal of Programmed Death 1 receptors on T cells. This results in upregulation of the immune system to attack tumour cells. Recent clinical trials showed an improved survival in selected patients with advanced cutaneous melanoma treated with targeted or immune checkpoint inhibitor therapy.[5]

Clinically, it can be difficult to differentiate primary from secondary malignant melanocytic lesions. This discrimination is very relevant for further treatment, as patients with metastatic cutaneous melanoma might benefit from the aforementioned treatments, which would not be applied to a localized conjunctival melanoma. We describe a patient with a pigmented conjunctival tumour, which turned out to be the first presentation of distant metastasis of a cutaneous melanoma, and who was successfully treated with systemic therapy.

CASE REPORT

A 74-year-old white male was diagnosed in 2015 with a cutaneous melanoma on the right scapular region of the back. The lesion (Breslow thickness 8 mm) was completely excised and demonstrated a BRAF V600E mutation. PET-CT screening for metastases revealed suspicious nodes in the ipsilateral axilla, but no other systemic lesions. A lymph node dissection was performed, with 3 out of 13 positive lymph nodes. Postoperative radiation therapy (20 fractions of 2.4 Gy) was administered to the axillar region. According to the 7th edition of the AJCC staging manual, the melanoma was classified as a T4aN2bM0 tumour, stage III B.

Five months after the diagnosis, a pigmented tumour was observed in the inferior fornix of the right eye (Figure 1). The lesion had a distinct border and no other conjunctival pigmentation was seen. The lesion was excised and histopathology showed a melanoma, positive for the BRAF V600E mutation. The tumour was located in the subepithelial stroma without a component of primary acquired melanosis (PAM) in the overlying epithelium and therefore a metastasis was suspected of the previously diagnosed cutaneous melanoma (Figure 2). The primary melanoma showed an epithelioid cell type with similarities to the suspected metastasis in cell size, nuclear size and cellular configuration (Figure 3).

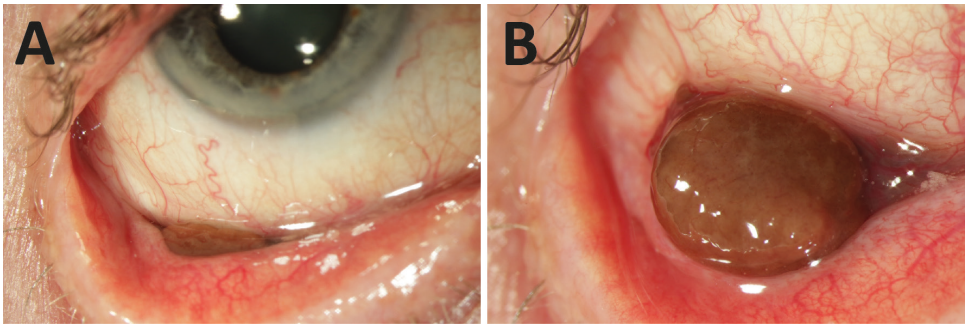

Figure 1. Slit-lamp photography at presentation. (A) A pigmented lesion is located in the inferior fornix of the right eye. (B) On closer examination, a well-circumscribed nodular lesion is seen with a diameter of 5.0 mm.

A PET-CT scan was repeated and other metastases were subsequently identified in the liver, spleen and various bones. Treatment with a BRAF-inhibitor was started (dabrafenib 100 mg, twice daily) for 4 months, followed by a combined treatment with a MEK-inhibitor (trametinib 2 mg, once daily) for another 2 months. Due to a mixed response, the treatment regimen was switched to intravenous injections with the anti PD-1 antibody pembrolizumab (200 mg) with 3-week intervals.

Currently, 22 months after the diagnosis of metastatic cutaneous melanoma, the patient is still alive and in good health. No local recurrences or new conjunctival lesions have been observed, and the distant metastases regressed. During treatment with pembrolizumab, a mild skin rash developed for which topical corticosteroids were prescribed, but no other adverse events of the immunotherapy have been noticed. Treatment with pembrolizumab will be continued till disease progression or unacceptable toxicity, for at most another 8 months to a total of 24 months.

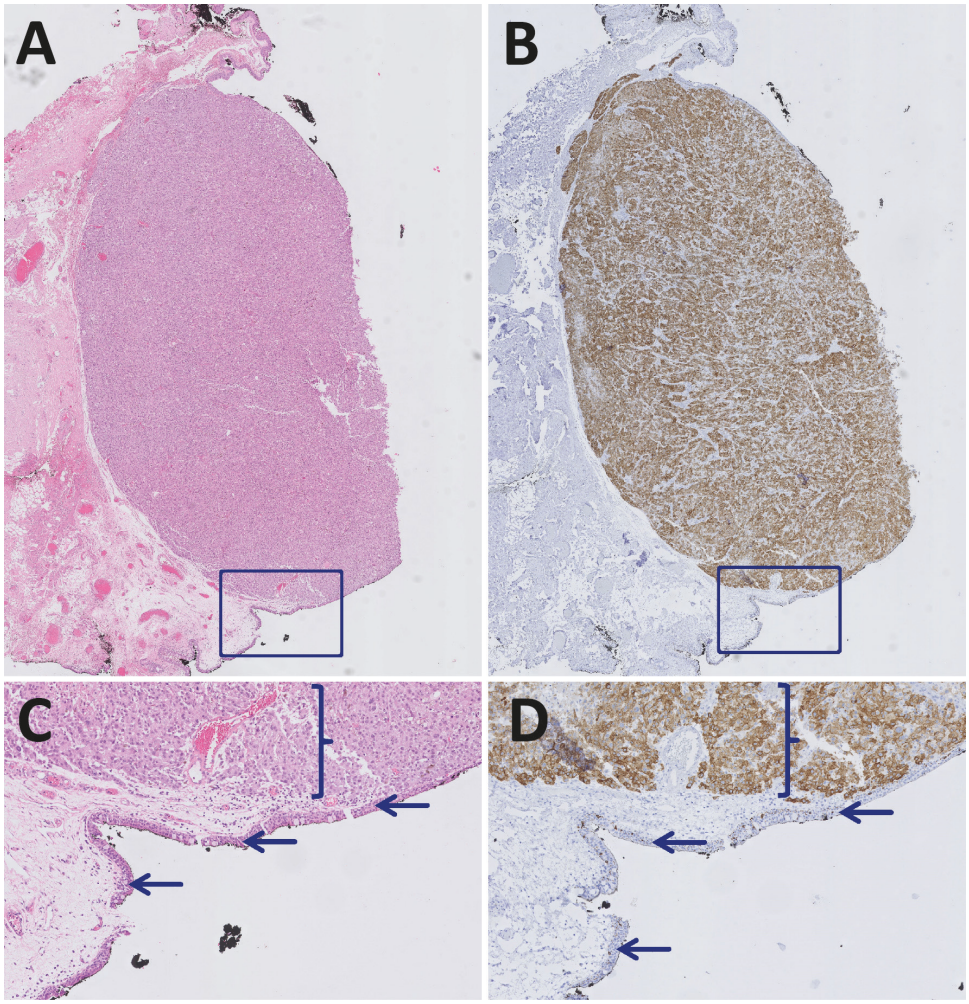

Figure 2. Histopathology. (A) Overview of the pigmented lesion, revealing a nodular tumour in the forniceal conjunctiva. The area within the box is presented at a higher magnification in c (HE staining, original magnification 5x). (B) The nodule stains positive for Melan-A, indicating a melanocytic origin of the cells, suggestive for melanoma. The area within the box is presented at a higher magnification in d (Melan-A staining, original magnification 5x). (C) The tumour cells (bracket) are located in the stroma without relation to the conjunctival epithelium (arrows). (HE staining, original magnification 40x). (D) The positively staining melanocytes of the tumour (bracket) are clearly separated from the epithelium (arrows) and no intra-epithelial growth of primary acquired melanosis is present. Together, this suggests a non-primary (metastatic) origin of the lesion (Melan-A staining, original magnification 40x).

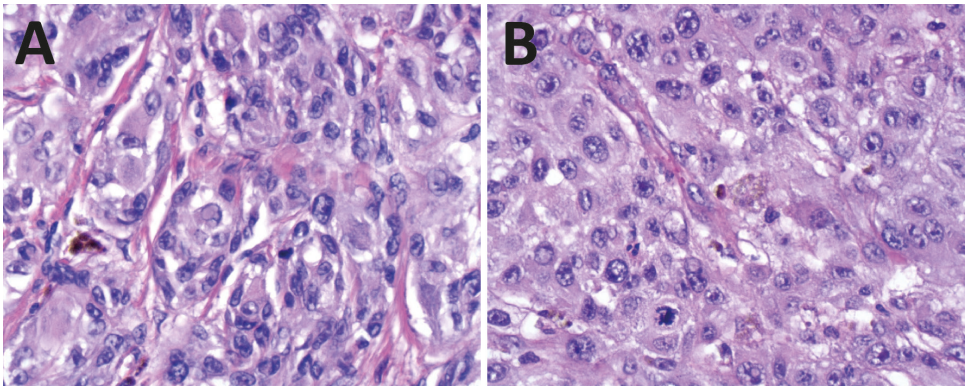

Figure 3. Cell type of the primary and metastatic lesion. The primary cutaneous melanoma (A) shows an epithelioid cell type, with similarities in cell size, nuclear size and cellular configuration to the conjunctival metastasis (B). (HE staining, original magnification 40x).

DISCUSSION

Melanomas can develop in the conjunctiva both as a primary or secondary lesion. As a primary tumour, conjunctival melanomas originates from the melanocytes in the basal layer of the conjunctiva. With an incidence of up to 0.8/million in Caucasians, it is rare.[6] Conjunctival melanomas can develop de novo, from a nevus, but most frequently they develop from PAM.[7] The treatment of primary conjunctival melanomas consists generally of local excision with adjuvant treatment of topical chemotherapy, cryotherapy or brachytherapy.[8]

Secondary conjunctival melanomas may result from direct extension or distant metastasis of cutaneous or uveal melanomas.[9,10] An overview of 19 conjunctival metastases of cutaneous melanomas showed a poor survival, ranging from <1 to 16 months.[11] However, it has to be noted that survival data in 5 out of 19 reported cases were absent.[2,10,12-20]

Based on clinical appearance, the pigmented conjunctival lesion of our patient could not be classified as a primary or secondary lesion. Histologic examination showed that no PAM was present in the conjunctiva and the tumour was located entirely in the subepithelial stroma, which suggested a diagnosis of cutaneous melanoma metastasis. When systemic metastasis screening was repeated, it revealed metastases to other organs. Together with the history of cutaneous melanoma, we suspected the conjunctival lesion to be a distant metastasis as well.

Both the primary cutaneous melanoma and the conjunctival metastasis showed the same BRAF V600E mutation. This similarity, however, should not be seen as a prove of shared origin, since the

BRAF mutation may occur in primary conjunctival melanoma as well.[21] This is illustrated by the fact that conjunctival melanomas shares a genetic similarity with cutaneous melanoma, rather than with uveal melanomas: BRAF and NRAS mutations that are common in cutaneous melanomas are also seen in conjunctival melanomas, but are extremely rare in uveal melanomas.[22,23] GNAQ en GNA11 mutations are seen in uveal melanomas, but have not been identified in conjunctival melanomas.[24] Following these genetic characteristics, some patients with localized and metastatic conjunctival melanomas were treated with BRAF inhibitors,[25,26] while other treatments are required for metastatic melanomas of the uvea. Since both melanomas of the skin and of the uvea can metastasize to the conjunctiva, determination of the origin of a metastasis can be very relevant for treatment selection.

In conclusion, a conjunctival metastasis of cutaneous melanoma may mimic primary conjunctival melanoma. In our case, following the discovery of disseminated disease, the patient was treated successfully with new systemic therapy. Clinicians should always be aware of the possibility of metastasis of cutaneous melanoma to the eye, indicating the importance of a proper medical history and systemic work-up. Newly introduced treatments for metastasized cutaneous melanoma might benefit these patients.

Statement of Ethics: The patient gave informed consent for the publication of this paper.

Disclosure Statement: None of the authors have a conflict of interest to disclose.

REFERENCES

1. Leiter U, Meier F, Schittek B, Garbe C. The natural course of cutaneous melanoma. *J Surg Oncol.* 2004;86(4):172-178.
2. Kiratli H, Shields CL, Shields JA, DePotter P. Metastatic tumours to the conjunctiva: report of 10 cases. *Br J Ophthalmol.* 1996;80(1):5-8.
3. Michielin O, Hoeller C. Gaining momentum: New options and opportunities for the treatment of advanced melanoma. *Cancer Treat Rev.* 2015;41(8):660-670.
4. Kim SY, Kim SN, Hahn HJ, et al. Metaanalysis of BRAF mutations and clinicopathologic characteristics in primary melanoma. *J Am Acad Dermatol.* 2015;72(6):1036-1046 e1032.
5. Kee D, McArthur G. Immunotherapy of melanoma. *Eur J Surg Oncol.* 2016.
6. Tuomaala S, Eskelin S, Tarkkanen A, Kivela T. Population-based assessment of clinical characteristics predicting outcome of conjunctival melanoma in whites. *Invest Ophthalmol Vis Sci.* 2002;43(11):3399-3408.
7. Shields CL, Markowitz JS, Belinsky I, et al. Conjunctival melanoma: outcomes based on tumor origin in 382 consecutive cases. *Ophthalmology.* 2011;118(2):389-395 e381-382.
8. Wong JR, Nanji AA, Galor A, Karp CL. Management of conjunctival malignant melanoma: a review and update. *Expert Rev Ophthalmol.* 2014;9(3):185-204.
9. Blumenthal EZ, Garzozi H, Bahir J, Pe'er J. Multiple conjunctival metastases as the initial sign of metastatic uveal melanoma. *Am J Ophthalmol.* 1997;124(4):549-550.
10. Dhar-Munshi S, Ameen M, Wilson RS. Simultaneous metastases of cutaneous malignant melanoma to conjunctiva and choroid. *Br J Ophthalmol.* 2000;84(8):930-931.
11. Carey AR, Espana EM, Margo CE. Conjunctival metastasis from a regional cutaneous melanoma. *Can J Ophthalmol.* 2014;49(4):e97-99.
12. Jakobiec FA, Buckman G, Zimmerman LE, et al. Metastatic melanoma within and to the conjunctiva. *Ophthalmology.* 1989;96(7):999-1005.
13. Kwapiszeski BR, Savitt ML. Conjunctival metastasis from a cutaneous melanoma as the initial sign of dissemination. *Am J Ophthalmol.* 1997;123(2):266-268.
14. Shields JA, Shields CL, Eagle RC, Jr., Raber IM. Conjunctival metastasis as initial sign of disseminated cutaneous melanoma. *Ophthalmology.* 2004;111(10):1933-1934.
15. Shields JA, Eagle RC, Jr., Gausas RE, Bundy WE, 3rd, Shields CL. Retrograde metastasis of cutaneous melanoma to conjunctival lymphatics. *Arch Ophthalmol.* 2009;127(9):1222-1224.
16. Strempel I. [Metastatic conjunctival tumor originating in a primary cutaneous malignant melanoma (author's transl)]. *Ophthalmologica.* 1982;185(1):52-57.
17. Ziakas NG, Eke T, Kendall CH, Goulstine DB. Metastatic cutaneous melanoma to the conjunctiva in an Afro-Caribbean patient. *Eye (Lond).* 2000;14 (Pt 4):667-668.
18. Font RL, Naumann G, Zimmerman LE. Primary malignant melanoma of the skin metastatic to the eye and orbit. Report of ten cases and review of the literature. *Am J Ophthalmol.* 1967;63(4):738-754.
19. Gunther I. [Ocular metastases in malignant melanoma of the skin (author's transl)]. *Klin Monbl Augenheilkd.* 1973;162(6):821-823.
20. Filik L, Oskay T, Ozyilkan O. Conjunctival involvement in a patient with cutaneous malignant melanoma. *Onkologie.* 2002;25(1):64-65.
21. Larsen AC, Dahl C, Dahmcke CM, et al. BRAF mutations in conjunctival melanoma: investigation of incidence, clinicopathological features, prognosis and paired premalignant lesions. *Acta Ophthalmol.* 2016;94(5):463-470.
22. Spendlove HE, Damato BE, Humphreys J, et al. BRAF mutations are detectable in conjunctival but not uveal melanomas. *Melanoma Res.* 2004;14(6):449-452.

23. Griewank KG, Westekemper H, Murali R, et al. Conjunctival melanomas harbor BRAF and NRAS mutations and copy number changes similar to cutaneous and mucosal melanomas. *Clin Cancer Res.* 2013;19(12):3143-3152.
24. Van Raamsdonk CD, Griewank KG, Crosby MB, et al. Mutations in GNA11 in uveal melanoma. *N Engl J Med.* 2010;363(23):2191-2199.
25. Maleka A, Astrom G, Bystrom P, Ullenhag GJ. A case report of a patient with metastatic ocular melanoma who experienced a response to treatment with the BRAF inhibitor vemurafenib. *BMC Cancer.* 2016;16:634.
26. Pahlitzsch M, Bertelmann E, Mai C. Conjunctival Melanoma and BRAF Inhibitor Therapy. *J Clin Exp Ophthalmol.* 2014;5(1).

6.2

Development of Ocular Rosacea following Combined Ipilimumab and Nivolumab Treatment for Metastatic Malignant Skin Melanoma

Niels J. Brouwer[1], John B.A.G. Haanen[2], Martine J. Jager[1]

Ocul Oncol Pathol 2017; 3(3):188-192

1 Department of Ophthalmology, Leiden University Medical Center, Leiden, The Netherlands.
2 Department of Medical Oncology, Netherlands Cancer Institute, Amsterdam, The Netherlands

ABSTRACT

Purpose: To report a case of severe ocular rosacea following ipilimumab plus nivolumab treatment in a patient with metastatic malignant skin melanoma.

Methods: Case report and review of the literature.

Results: A 68-year-old male with newly diagnosed metastatic malignant cutaneous melanoma was treated with first-line ipilimumab plus nivolumab, which resulted in a partial response. Four months after initiation of treatment, the patient developed red eyelids and conjunctivae, with painful gritty eyes, limiting his capacity to read. Following a diagnosis of severe ocular rosacea and dry eyes, treatment including corticosteroids, antimicrobial agents and eyelid hygiene was started, and in 3 months, the ocular complaints resolved.

Conclusion: Treatment with checkpoint inhibitor immunotherapy for metastatic melanoma may trigger several ocular immune-related adverse events. This case describes severe ocular rosacea as an adverse event following ipilimumab plus nivolumab treatment.

Established facts:

- Immunotherapy for metastatic melanoma may result in ocular adverse events such as uveitis and orbital inflammation.

Novel Insights:

- Ocular rosacea is a rare but potential adverse event of anti-CTLA-4 and anti-PD-1 treatment.

INTRODUCTION

The monoclonal antibodies ipilimumab and nivolumab have recently been introduced as therapy for metastatic cutaneous melanoma. Ipilimumab is an antibody directed against inhibitory CTLA-4 proteins on the surface of activated T cells, while nivolumab blocks signalling of the inhibitory PD-1 receptor of tumour-resident T cells, thus enhancing the immune system to attack tumour cells. Treatment with so-called 'checkpoint inhibitor immunotherapy' results in a higher survival for patients with metastatic cutaneous melanoma, however, at the cost of sometimes severe immune-related adverse effects (irAEs).[1,2] The most-common irAEs include dermatologic and gastro-intestinal complaints, such as skin rashes and diarrhoea as a result of dermatitis and colitis respectively, and general fatigue,[1,2] which may be caused by endocrinopathies, including thyroid gland disorders or hypophysitis. Ocular irAEs are rare but have been reported in 1.3% of patients receiving anti-CTLA-4 treatment,[3] and 1.6% of patients receiving anti-PD-1 treatment.[4] Typical ocular irAEs are uveitis and orbital inflammation. This report presents a case of severe ocular rosacea following combination treatment with ipilimumab and nivolumab, and reviews the literature regarding ocular surface irAEs.

CASE DESCRIPTION

A 68-year-old male was diagnosed in 2015 with metastatic malignant cutaneous melanoma and treated with immunotherapy. He had had a pigmented lesion removed from his back in 2006. The patient was treated in a clinical trial (NCT01621490) and received, starting June 2015, 4 doses of ipilimumab in combination with nivolumab, followed by 5 doses of nivolumab monotherapy. Subsequently, a partial response (RECIST 1.1 criteria)[5] was seen, with regression of cerebral and extracerebral metastases on magnetic resonance imaging and computed tomography (figure 1). Adverse effects (AE) included diarrhoea, skin rash, and renal insufficiency, for which the immunotherapy was interrupted for 1 month and for which the patient received prednisone in August 2015.

Prior to the immunotherapy, the patient had had some minor complaints of dry eyes, without the need to visit an ophthalmologist. In late October 2015, 4 months after the start of immunotherapy, when prednisone for other adverse events had been tapered, the patient developed new complaints of dry eyes, aggravating in December 2015 to complaints of severe dry eyes, redness of peri-orbital skin, swelling of his face, and nasal congestion. At that time he also developed asymptomatic grade 4 lipase and grade 3 amylase elevations, without clinical signs of pancreatitis, and symptomatic adrenal insufficiency for which hydrocortisone substitution therapy was started. His immunotherapy treatment was discontinued permanently. The patient received artificial tears and in February 2016 prednisone was restarted at 30 mg per day for facial swelling and nasal congestion, which

reduced the facial swelling and nasal congestion, but not the ocular problems (figure 2a); this led to referral of the patient to the Department of Ophthalmology of the Leiden University Medical Center in March 2016. On examination, the patient had typical facial rosacea, bilateral severe redness of the eyelids with many telangiectasia, congested Meibomian glands with surrounding inflammation, severe nasal and temporal conjunctival injection, diffuse severe punctate keratitis with adherent mucus, and no signs of uveitis or any other intraocular problems. Schirmer's test for tear secretion was less than 5 mm for each eye. Upon a diagnosis of severe ocular rosacea, topical treatment was started with corticosteroids (fluorometholone), a steroidal/antimicrobial ointment (hydrocortisone/oxytetracycline/polymyxine B) for the eyelids and eyelid scrubbing twice daily. Lubricants were continued. Within 3 months, the ocular complaints had resolved and the corneal epithelium had recovered, showing a smooth and shiny surface without any punctate staining. There were telangiectasia on the lower eyelids, but no Meibomian congestion or inflammation, with excellent oil production. The patient experienced a great relieve and had discontinued the use of corticosteroids (figure 2b). Treatment was continued with eyelid hygiene and lubricants.

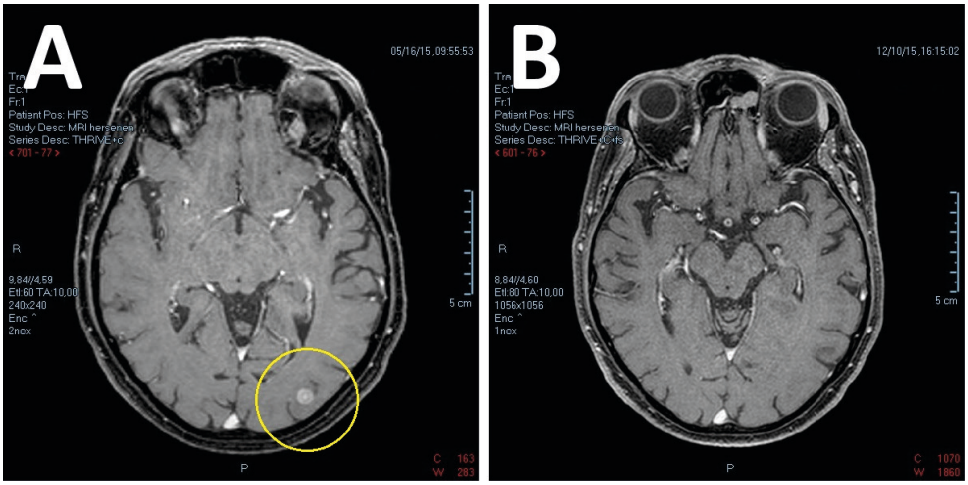

Figure 1. Magnetic resonance imaging scans of cerebral metastasis. **a** Cerebral metastasis of the cutaneous melanoma at baseline. **b** Seven months later the lesions have regressed following ipilimumab plus nivolumab treatment.

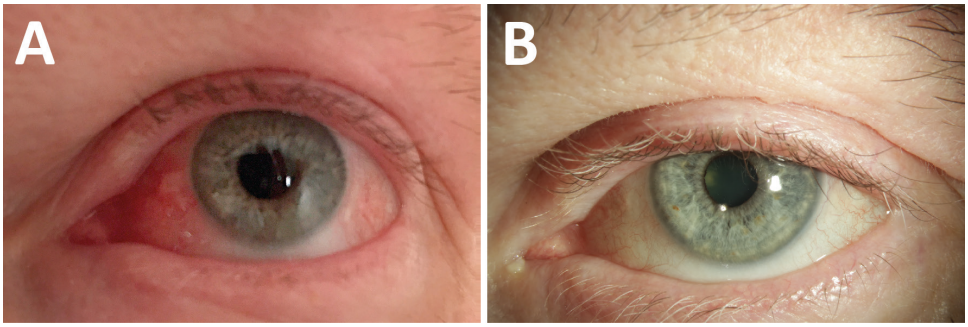

Figure. 2. Slit lamp photography. **a** Ocular rosacea after ipilimumab and nivolumab treatment. The redness of the eyelids and injection of the conjunctiva are clearly visible. The left eye is shown; both eyes had a similar appearance. **b** After adequate treatment for the ocular rosacea, the redness and inflammation have disappeared.

DISCUSSION

Several ocular irAEs have been described with ipilimumab treatment, such as uveitis, vitritis, peripheral ulcerative keratitis, choroiditis and serous retinal detachment and orbitopathy.[6] Only a few ocular irAEs have been described during nivolumab treatment, which include dry eyes, conjunctivitis, blurred vision and iritis.[4,7,8] Our case presents ocular rosacea following treatment with ipilimumab plus nivolumab. A summary of the literature regarding irAEs of the ocular surface is provided (Table 1).

As checkpoint inhibitors stimulate immune responses rather aspecifically, adverse immunological evens can be expected. Immune responses involve the adaptive immune response, and can be due to T-cell responses. Our case suggests that adaptive immune responses play an important role in rosacea, as has also been suggested by Nguyen et al. in the occurrence of complaints of dry eyes following nivolumab.[7] The importance of T-cell-mediated autoimmunity in the lacrimal glands, which leads to lack of tear production, has previously been indicated.[9] Although the pathophysiology of ocular rosacea is still not fully understood, a local immune response is considered important.[10] Analysis of the skin in rosacea patients has shown an elevated presence of T-cells, with mainly CD4+ expression and CD8+ expression to a lesser extent.[11] Treatment with either ipilimumab or nivolumab has been shown to increase the level of CD4+ and CD8+ cells in tumour tissue, thus supporting the suggestion of T-cell mediation in the pathophysiology of our case.[12,13] Parallel to the situation in dry eyes, treatment with ipilimumab and nivolumab may probably have triggered a T-cell-mediated autoimmune response in the eyelids, leading to Meibomian gland disease, in combination with tear gland disease, which is responsible for the lack of tear production.

Table 1. Overview of ocular surface immune-related adverse events for ipilimumab and nivolumab in the literature

First author	Age/ sex	Current Immunotherapy	Previous Immunotherapies	Ocular surface immune-related adverse events	Treatment for immune-related adverse events	Outcome of ocular complaints
Papavasileiou[6]	55/F	Ipilimumab, Bevacizumab	Not reported	Peripheral ulcerative keratitis	Topical corticosteroids, topical antibiotics, acyclovir	Resolved
Voskens,[14] 2013	57/M	Ipilimumab	DTIC, Sorafenib	Conjunctivitis	Lubrication	Resolved
Voskens,[15] 2012	53/F	Ipilimumab	Dacarbacine, Sorafenib	Iridocyclitis, marginal keratitis	Systemic corticosteroids	Resolved
Henderson[16]	55/M	Ipilimumab	Not reported	Episcleritis, orbital inflammation	Topical steroids	Improved
Zimmer[4]	78/M	Nivolumab	Interferon-alfa	Conjunctivitis	Topical corticosteroids	Not resolved
	49/F	Nivolumab	Vemurafenib, Dabrafenib, Ipilimumab	Dry eyes	Topical therapy	Not resolved
Nguyen[7]	58/M	Nivolumab	Not reported	Dry eyes; corneal perforation	Lubrication, topical cyclosporine, punctal occlusion	Improved
	46/F	Nivolumab	Not reported	Dry eyes	Lubrication, topical cyclosporine	Improved
Montaudie[17]	56/M	Nivolumab	Not reported	Dry eyes, sarcoidosis	Systemic corticosteroids	Resolved

The patient in our case responded initially to systemic corticosteroids, and had complete resolution of ocular irAEs after topical treatment with corticosteroids and antimicrobial agents, together with eyelid hygiene. Most ocular irAEs following immunotherapy have been successfully treated with topical corticosteroids, and only rarely systemic therapy has been required.[18] Systemic steroids were required for ocular irAEs after immunotherapy in a patient developing iridocyclitis and marginal keratitis[15] and a patient developing dry eyes and sarcoidosis.[17] In one case, punctal occlusion was used for dry eye treatment,[7] but the authors noted the ambiguity of this procedure, which could worsen the complaints of dry eyes when clearance of inflammatory mediators from the ocular surface is delayed.

This report shows ocular rosacea as a rare but potential irAE of the ocular surface after treatment with immunotherapy for metastatic melanoma. As in most ocular irAEs, our patient responded well

to corticosteroids. With immunotherapy being approved for an increasing number of indications, clinicians should be aware of the potential adverse events this treatment may elicit, including rare events, such as ocular rosacea.

Statement of Ethics: Written informed consent was obtained from the patients for this report. The institute's medical ethics committee of the Leiden University Medical Center declared that there was no objection to this study.

Disclosure Statement: N.J.B. and M.J.J. declare no conflicts of interest. J.B.A.G.H. reports having received institutional research grants from BMS, MSD, GSK and having advisory roles for MSD, BMS, Pfizer, Roche, Ibsen, Novartis, NEON Therapeutics.

REFERENCES

1. Hodi FS, O'Day SJ, McDermott DF, et al. Improved survival with ipilimumab in patients with metastatic melanoma. *N Engl J Med.* 2010;363(8):711-723.
2. Weber JS, D'Angelo SP, Minor D, et al. Nivolumab versus chemotherapy in patients with advanced melanoma who progressed after anti-CTLA-4 treatment (CheckMate 037): a randomised, controlled, open-label, phase 3 trial. *Lancet Oncol.* 2015;16(4):375-384.
3. Tarhini A. Immune-mediated adverse events associated with ipilimumab ctla-4 blockade therapy: the underlying mechanisms and clinical management. *Scientifica (Cairo).* 2013;2013:857519.
4. Zimmer L, Goldinger SM, Hofmann L, et al. Neurological, respiratory, musculoskeletal, cardiac and ocular side-effects of anti-PD-1 therapy. *Eur J Cancer.* 2016;60:210-225.
5. Eisenhauer EA, Therasse P, Bogaerts J, et al. New response evaluation criteria in solid tumours: revised RECIST guideline (version 1.1). *Eur J Cancer.* 2009;45(2):228-247.
6. Papavasileiou E, Prasad S, Freitag SK, Sobrin L, Lobo AM. Ipilimumab-induced Ocular and Orbital Inflammation--A Case Series and Review of the Literature. *Ocul Immunol Inflamm.* 2016;24(2):140-146.
7. Nguyen AT, Elia M, Materin MA, Sznol M, Chow J. Cyclosporine for Dry Eye Associated With Nivolumab: A Case Progressing to Corneal Perforation. *Cornea.* 2016;35(3):399-401.
8. Brahmer JR, Tykodi SS, Chow LQ, et al. Safety and activity of anti-PD-L1 antibody in patients with advanced cancer. *N Engl J Med.* 2012;366(26):2455-2465.
9. McClellan AJ, Volpe EA, Zhang X, et al. Ocular surface disease and dacryoadenitis in aging C57BL/6 mice. *Am J Pathol.* 2014;184(3):631-643.
10. Holmes AD, Steinhoff M. Integrative concepts of rosacea pathophysiology, clinical presentation and new therapeutics. *Exp Dermatol.* 2016.
11. Buhl T, Sulk M, Nowak P, et al. Molecular and Morphological Characterization of Inflammatory Infiltrate in Rosacea Reveals Activation of Th1/Th17 Pathways. *J Invest Dermatol.* 2015;135(9):2198-2208.
12. Weber JS, Hamid O, Chasalow SD, et al. Ipilimumab increases activated T cells and enhances humoral immunity in patients with advanced melanoma. *J Immunother.* 2012;35(1):89-97.
13. Choueiri TK, Fishman MN, Escudier B, et al. Immunomodulatory Activity of Nivolumab in Metastatic Renal Cell Carcinoma. *Clin Cancer Res.* 2016.
14. Voskens CJ, Goldinger SM, Loquai C, et al. The price of tumor control: an analysis of rare side effects of anti-CTLA-4 therapy in metastatic melanoma from the ipilimumab network. *PLoS One.* 2013;8(1):e53745.
15. Voskens C, Cavallaro A, Erdmann M, et al. Anti-cytotoxic T-cell lymphocyte antigen-4-induced regression of spinal cord metastases in association with renal failure, atypical pneumonia, vision loss, and hearing loss. *J Clin Oncol.* 2012;30(33):e356-357.
16. Henderson AD, Thomas DA. A case report of orbital inflammatory syndrome secondary to ipilimumab. *Ophthal Plast Reconstr Surg.* 2015;31(3):e68-70.
17. Montaudie H, Pradelli J, Passeron T, Lacour JP, Leroy S. Pulmonary sarcoid-like granulomatosis induced by nivolumab. *Br J Dermatol.* 2016.
18. Fierz FC, Meier F, Chaloupka K, Boni C. Intraocular Inflammation Associated with New Therapies for Cutaneous Melanoma - Case Series and Review. *Klin Monbl Augenheilkd.* 2016;233(4):540-544.

6.3

Two Late Recurrences of Conjunctival Melanoma

Niels J. Brouwer[1], Stijn W. Genders[1], Marina Marinkovic[1], Sjoerd G. van Duinen[2], Martine J. Jager[1], Gré P.M. Luyten[1]

Ocul Oncol Pathol 2019; 5(4):262-266

1 Department of Ophthalmology, Leiden University Medical Center, Leiden, The Netherlands
2 Department of Pathology, Leiden University Medical Center, Leiden, The Netherlands

ABSTRACT

Purpose: To report a patient who developed two late recurrences of conjunctival melanoma (CoM), of which one occurred after orbital exenteration.

Methods: We describe the case of a patient based on clinical and histopathological examination.

Results: A 52-year-old patient was treated with local excision and cryotherapy for a CoM with primary acquired melanosis (PAM) near the limbus of the right eye. Twenty-one years later, a recurrence developed in the superior fornix of the same eye in an area with widespread PAM; an orbital exenteration was performed. After another 4 years, a painful nodule developed subcutaneously at the inferior margin of the right orbital socket. Pathology showed a recurrence of CoM with a *BRAF* V600K mutation, similar to both of the previous lesions (of 25 and 4 years earlier). The nodule was excised without additional therapy. No recurrences or metastases have been observed in the next 2.5 years. The proposed mechanism for the recurrence after surgery could be via dormant tumor cells that have spread prior to the procedure or via residual intraepithelial malignant melanocytes.

Conclusion: Very late recurrences of CoM are rare but may occur. Our case illustrates the need for long-term awareness of doctors and patients, even after extensive surgical procedures such as orbital exenteration.

Established Facts:

- Conjunctival melanoma (CoM) is a rare ocular tumor, with a high recurrence rate. It is often treated with local excision and adjuvant therapy.
- Orbital exenteration is a last-resort therapy, with either the intention to be curative or symptomatic.

Novel Insights:

- CoM may give rise to very late recurrences (after 20 years), as well as recurrences after orbital exenteration.
- Long-term awareness - for both patients and doctors – is needed, even after extensive surgical treatment.

INTRODUCTION

Conjunctival melanoma (CoM) is an aggressive ocular disease with an incidence of up to 0.8 per million in adult Caucasians.[1] Treatment of limited disease involves most often local excision with adjuvant therapy, but more extensive procedures may be required in advanced cases. As a last resort, orbital exenteration can be performed. The aim of an orbital exenteration can be either curative, by removing all potentially affected tissues in the orbit, or symptomatic, if the patient experiences discomfort that cannot be resolved otherwise. The risk for local recurrence or metastasis of CoM is high, commonly developing within the first 5-10 years after presentation of the primary lesion.[2] We present a rare case of a patient who developed a very late recurrence of CoM, and another late recurrence after orbital exenteration, stressing the need for adequate long-term follow-up.

CASE REPORT

A 52-year-old female was diagnosed in 1990 with a CoM on the temporal limbus of the right eye, approximately 4 clock hours in size, with a component of primary acquired melanosis (PAM) (no photograph available). This constituted a cT1, N0, M0 tumor,[3] which was treated with local excision and cryotherapy. The melanoma was removed with tumor-free margins (Figure 1). During the first 10 years of follow-up at our oncology center, no local recurrence or metastasis was detected. In 2001, the patient returned to her local ophthalmologist.

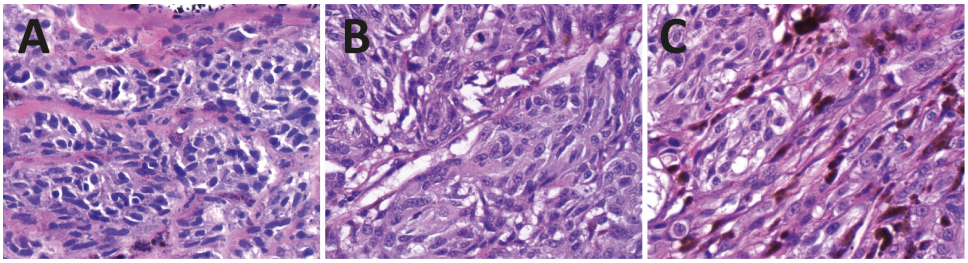

Figure 1. Histopathology. (a) Histology of the primary CoM in 1990 demonstrated a mixed cell type with both spindle cells and epithelioid cells. (H&E stain, original magnification 40x). (b) Histology of the recurrence in 2011 demonstrated a similar mixed cell type, with mitoses, no ulceration and no vessel invasion. (H&E stain, original magnification 40x). (c) The subcutaneous nodule in 2015 demonstrated similarities to the lesion from 2011 in cell type, cell size and cellular configuration. (H&E stain, original magnification 40x).

In 2011, 21 years after treatment for the primary lesion, the patient returned to our center with a nodular lesion in the superior fornix of the right eye, suspicious for recurrence of the CoM (Figure 2). Earlier, no abnormalities had been noticed by the patient. A CT scan showed a preseptal

lesion and biopsy proved it to be a CoM. A total orbital exenteration (with removal of the globe, conjunctiva, and eyelids) was performed and histology of the specimen showed radical excision of the melanoma with widespread PAM (Figure 1).

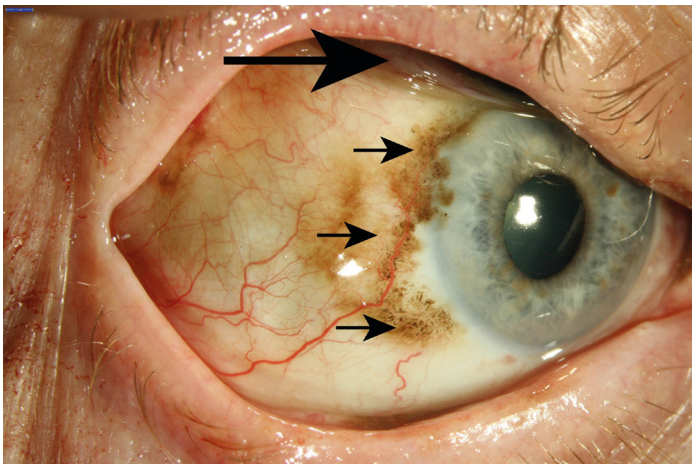

Figure 2. Slit-lamp photography of the right eye (2011). Widespread melanosis is located on the ocular surface (small arrows) and a large nodule is located in the superior fornix (large arrow).

Four years later, the now 78-year-old woman presented with a painful subcutaneous nodule on the inferior margin of the right orbit (Figure 3). MRI showed a hypointense lesion measuring 6 by 4 mm, anterior to the maxillary sinus (Figure 4). The nodule was excised and proved to be a CoM, with histological similarities to the lesion of 2011 in cell type and configuration (Figure 1). A mutation in the *BRAF* gene (p.Val600Lys; V600K) but not in *NRAS* or *KIT* was identified in the newest lesion. Additional tests on the tissue of the orbital exenteration and the first lesion from 1990 demonstrated the same *BRAF* V600K mutation, and a similar absence of mutations in *NRAS* or *KIT* in both samples. Presurgery screening for metastatic disease by CT of the chest and abdomen revealed multiple lesions in both lungs: a biopsy showed these to be metastases of a newly detected colon carcinoma. For this malignancy, the patient was treated with capecitabine chemotherapy and surgical resection of the sigmoid. The patient did not receive further treatment for the recurrent melanoma, as at that time, excision was regarded appropriate treatment. A total of 2.5 years after removal of the orbital nodule, the 80-year-old patient is doing fine regarding her ophthalmic situation, with no other recurrences or metastases. An ultrasound of the neck is performed every six months and this showed no abnormalities in the cervical lymph nodes so far. The lung lesions from the colon carcinoma have shown only minor progression without need for further treatment.

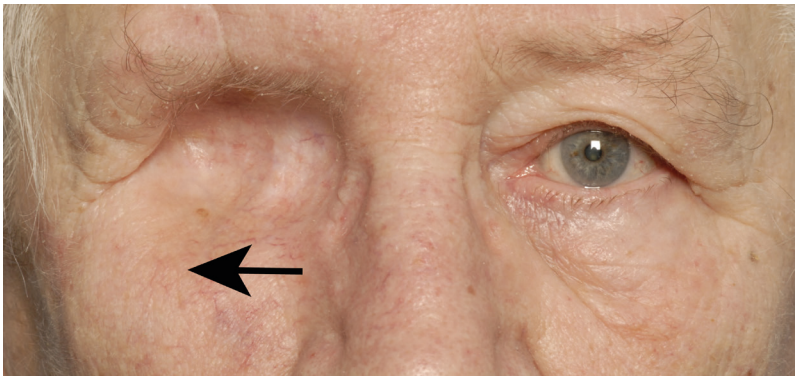

Figure 3. En face photography of the orbital socket, 1 year before development of the lesion (2014). The lesion was located at the inferior border of the orbital rim (arrow).

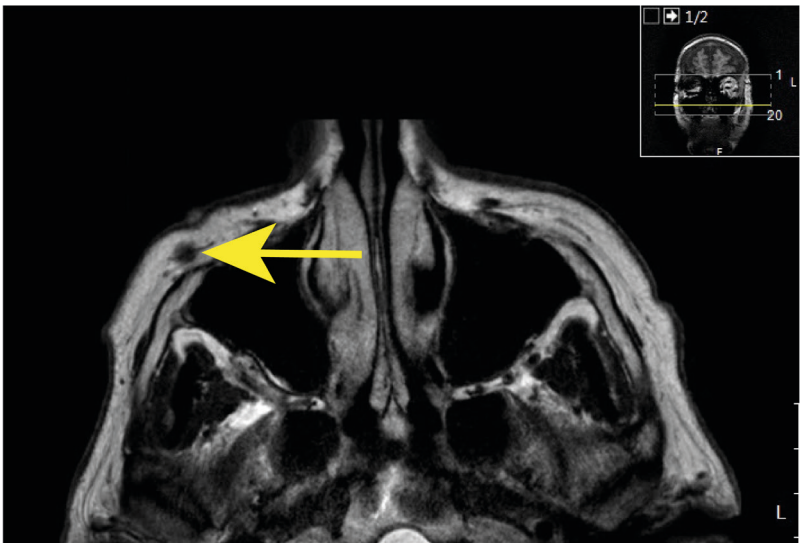

Figure 4. Magnetic Resonance Imaging (2015) reveals a hypointense nodule at the inferior border of the orbital rim on a T2-weighed scan (arrow).

DISCUSSION

Local recurrence of CoM is rather common, with an overall 5-year recurrence rate of 36-61%.[2,4] Very late recurrences (after 20 years) are rare, being reported once in a long-term follow-up study of 85 patients,[4] once in 194 patients,[2] and once in 256 patients.[5] The mean follow-up time of these

studies was 13.8 years (with 12 patients followed for longer than 20 years), 9.2 years (with 7 patients followed for longer than 20 years) and 9.0 years (with no reported numbers for 20 year follow-up), respectively. The development of a late recurrence after orbital exenteration is also most unusual. In our case, the patient developed a recurrence four years after this procedure. To our knowledge, this kind of recurrence has only been reported once before, in a patient who had undergone orbital exenteration 21 years before.[6]

The primary conjunctival tumor, the first recurrence, and the subcutaneous nodule in our patient all contained the same mutation in the *BRAF* gene (V600K). While a *BRAF* mutation has been reported in 29-50% of all CoM, the V600K mutation is a rare type found in approximately 20% of *BRAF*-mutated CoM, in contrast to the *BRAF* V600E mutation that makes up nearly all other 80%.[7] This finding adds to the likelihood that the lesions are related and that both the first lesion and the subcutaneous nodule should be considered a recurrence of CoM. This is no proof, however, since a small study by Larsen et al. (including 8 cases) showed that *BRAF* mutations can be both present and absent in paired lesions of PAM and melanoma, implying that it may be impossible to distinguish whether the recurrence developed from dormant melanoma cells or from residual PAM.[8] Clinically, this is not relevant as it does not alter the treatment strategy.

Late development of CoM recurrences may be in line with the theory of metastatic dormancy. This has been described in uveal melanoma, and to some extent in cutaneous melanoma.[9] It has been hypothesized that environmental factors may induce a senescent state of melanoma cells, allowing for long periods of disease-free survival. It is thought that the immune system plays an important role in the detection of tumor cells. Genetic factors may contribute as well, although the effect of BRAF is unclear. Relevance of metastatic dormancy for CoM is unknown, but an observation as ours implies that it might play a role in some cases.

There are two possible mechanisms for the development of the recurrence after orbital exenteration in our patient. Melanoma cells may have spread in advance of, or during, the orbital exenteration, and subsequently remained dormant for several years. Alternatively, a component of intraepithelial (premalignant) melanocytes might have been left in the orbital socket, later developing into a second primary CoM. Though PAM was widespread in the exenteration specimen, all surgical margins were free, suggesting that the first mechanism is the most likely in our case.

A third explanation for the development of melanoma that we considered is that the lesion is a primary cutaneous melanoma, or a secondary lesion of another (nonconjunctival) melanoma.[10] Histologically, there was no relation between the subcutaneous nodule and the cutaneous melanocytes in our patient, indicating that a primary cutaneous origin is very unlikely. As the patient had no other cutaneous or ocular lesions that were suspect for melanoma, a second skin lesion or CoM with local metastatic spreading is unlikely as well. Detection of a (secondary) cutaneous origin could be

very relevant, as new treatments with targeted therapy (e.g. BRAF-inhibitors) have become available with potential benefit for selected patients.[11] Various cases have been reported of ocular presentation of disseminated cutaneous melanoma, which were successfully treated with these agents.[12]

We regard the orbital lesion as a local recurrence of CoM and not as metastatic disease, as no other (systemic) lesions were detected, and there are plausible mechanisms for the recurrence to occur. However, this might be a matter of terminology as one might state that a successful orbital exenteration removes all the periocular tissues required for a local recurrence. In contrast to our case of local recurrence, distant metastases of CoM after orbital exenteration have been reported more often,[13] with a 35% rate in a series with 51 months of mean follow-up.[14] However, exact numbers are scarce, possibly because many patients are lost to follow-up after the procedure, as it is not uncommon for patients to return to their local doctor once the orbital exenteration has been performed.

The orbital CoM recurrence in our patient was excised with clear, tumor-free, margins. As the patient was diagnosed shortly after this excision with a disseminated colon carcinoma (T3N0M1a, stage IVa) for which a palliative treatment was started, no adjuvant therapy for the CoM lesion was given. Nevertheless, this could be up for discussion as a CoM recurrence might occur again via the mechanisms we proposed earlier, through possibly dormant melanoma cells or residual PAM. Although the patient was treated with capecitabine chemotherapy for her colon carcinoma, this will be of limited relevance as capecitabine (or another form of 5-FU) is not indicated for the treatment of CoM.[15,16] Regarding the first episode of CoM with accompanying histologic PAM in our patient, we would currently advise to apply mitomycin C drops after excision to reduce the recurrence risk.[17]

In conclusion, our case shows that very late recurrences of CoM may occur, and that an orbital exenteration should not be regarded as the 'final solution' of CoM treatment. One should be aware of the potential occurrence of either new melanoma or recurrences. Patients with CoM or PAM should preferably be followed in a tertiary reference centre. Patients should be instructed to immediately report any changes, and whenever there is even the smallest suspicion of an abnormality, clinicians should not hesitate to perform a MRI of the orbital region.

Statement of Ethics: The patient gave written informed consent for the publication of this paper.

Disclosure statement: The authors have no financial interests or conflicts of interest to disclose.

Financial support: N.J.B. is the recipient of a MD/PhD program grant from the Leiden University Medical Center. The funder had no role in the design or execution of the study.

REFERENCES

1. Tuomaala S, Eskelin S, Tarkkanen A, Kivela T. Population-based assessment of clinical characteristics predicting outcome of conjunctival melanoma in whites. *Invest Ophthalmol Vis Sci.* 2002;43(11):3399-3408.
2. Missotten GS, Keijser S, De Keizer RJ, De Wolff-Rouendaal D. Conjunctival melanoma in the Netherlands: a nationwide study. *Invest Ophthalmol Vis Sci.* 2005;46(1):75-82.
3. Coupland SE, Barnhill RL, Conway M, et al. Conjunctival Melanoma. In: Amin MB ES, Green F, ed. *AJCC Canger Staging Manual, 8th ed*. New York: Springer; 2017:795-803.
4. Werschnik C, Lommatzsch PK. Long-term follow-up of patients with conjunctival melanoma. *Am J Clin Oncol.* 2002;25(3):248-255.
5. Paridaens AD, Minassian DC, McCartney AC, Hungerford JL. Prognostic factors in primary malignant melanoma of the conjunctiva: a clinicopathological study of 256 cases. *Br J Ophthalmol.* 1994;78(4):252-259.
6. Paridaens AD, McCartney AC, Lavelle RJ, Hungerford JL. Nasal and orbital recurrence of conjunctival melanoma 21 years after exenteration. *Br J Ophthalmol.* 1992;76(6):369-371.
7. Mor JM, Heindl LM. Systemic BRAF/MEK Inhibitors as a Potential Treatment Option in Metastatic Conjunctival Melanoma. *Ocul Oncol Pathol.* 2017;3(2):133-141.
8. Larsen AC, Dahl C, Dahmcke CM, et al. BRAF mutations in conjunctival melanoma: investigation of incidence, clinicopathological features, prognosis and paired premalignant lesions. *Acta Ophthalmol.* 2016;94(5):463-470.
9. Ossowski L, Aguirre-Ghiso JA. Dormancy of metastatic melanoma. *Pigment Cell Melanoma Res.* 2010;23(1):41-56.
10. Rose AM, Cowen S, Jayasena CN, Verity DH, Rose GE. Presentation, Treatment, and Prognosis of Secondary Melanoma within the Orbit. *Front Oncol.* 2017;7:125.
11. Michielin O, Hoeller C. Gaining momentum: New options and opportunities for the treatment of advanced melanoma. *Cancer Treat Rev.* 2015;41(8):660-670.
12. Brouwer NJ, Marinkovic M, Jochems A, et al. Conjunctival metastasis of a cutaneous melanoma. *Ocul Oncol Pathol.* 2018;4:107-111.
13. Paridaens AD, McCartney AC, Minassian DC, Hungerford JL. Orbital exenteration in 95 cases of primary conjunctival malignant melanoma. *Br J Ophthalmol.* 1994;78(7):520-528.
14. Shields JA, Shields CL, Gunduz K, Cater J. Clinical features predictive of orbital exenteration for conjunctival melanoma. *Ophthal Plast Reconstr Surg.* 2000;16(3):173-178.
15. Vora GK, Demirci H, Marr B, Mruthyunjaya P. Advances in the management of conjunctival melanoma. *Surv Ophthalmol.* 2016.
16. FDA. Capecitabine. n.d.; Available at: https://www.accessdata.fda.gov/drugsatfda_docs/label/2005/020896s016lbl.pdf. Accessed March 8, 2018.
17. Brouwer NJ, Marinkovic M, van Duinen SG, et al. Treatment of conjunctival melanoma in a Dutch referral centre. *Br J Ophthalmol.* 2018;102(9):1277-1282.

6.4

Multiple Pigmented Conjunctival Lesions following Intravitreal Injections in a Patient with Uveal Melanoma

Niels J. Brouwer, Gregorius P.M. Luyten, Sjoerd G. van Duinen, Martine J. Jager, Marina Marinkovic

Ocul Oncol Pathol 2017; 3(2):113-116

Department of Ophthalmology, Leiden University Medical Centre, Leiden, The Netherlands

ABSTRACT

Purpose: This paper reports a case of pigmented conjunctival lesions after intravitreal injections in a patient who received brachytherapy for uveal melanoma.

Methods: Clinical and histopathological examination of the pigmented conjunctival lesions was performed.

Results: A 57-year-old male who was treated with brachytherapy for uveal melanoma developed radiation retinopathy. Following intravitreal anti-vascular endothelial growth factor (VEGF) injections, 2 pigmented conjunctival spots appeared at the injection sites. After excision of the lesions, histopathology showed pigment-loaded macrophages, with no signs of active tumour cells.

Conclusion: Two conjunctival lesions that appeared following uveal melanoma brachytherapy and anti-VEGF injections were excised under suspicion of tumour seeding. Histopathology, however, showed aggregates of pigment-loaded macrophages.

INTRODUCTION

Uveal melanoma is the most common intraocular tumour in adults with an incidence rate of 5.1 per million in Caucasians.[1] Various treatment modalities are available, including brachytherapy, proton beam irradiation and enucleation.[2,3] Plaque therapy with Ruthenium 106 provides excellent tumour control but local recurrence or extraocular outgrowth may occur in rare cases.[4] Patients may develop radiation retinopathy with macular edema as a complication, requiring treatment with vascular endothelial growth factor (VEGF) inhibitors or corticosteroids.[3,5] We describe a patient who was treated with brachytherapy for uveal melanoma and who developed radiation retinopathy for which he was treated with intravitreal injections. Subsequently, he developed pigmented lesions at the injection sites.

CASE REPORT

A 57-year-old, white, Caucasian male was referred with decreased visual acuity and a lesion suspicious for malignancy. On fundus examination, there was a juxtapapillary choroidal tumour with an intravitreal haemorrhage. Ultrasonography showed a choroidal tumour measuring 9.3 by 7.7 mm in basal diameter and 5.2 mm in tumour thickness without retinal invasion or breakthrough of Bruch's membrane (Figure 1). The clinical examination was consistent with the diagnosis of choroidal melanoma. Ruthenium plaque brachytherapy was performed with a COB applicator of 20 mm in diameter, designed for administering radiation on the posterior pole adjacent to the optic nerve (BEBIG GmbH, Berlin, Germany), and the tumour flattened gradually to 4.6 mm after 3 years (Figure 2).

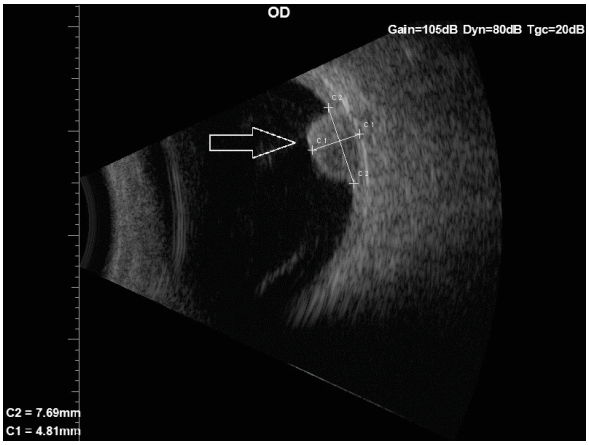

Figure 1. Ultrasound image showing the dome-shaped choroidal melanoma before brachytherapy (arrow).

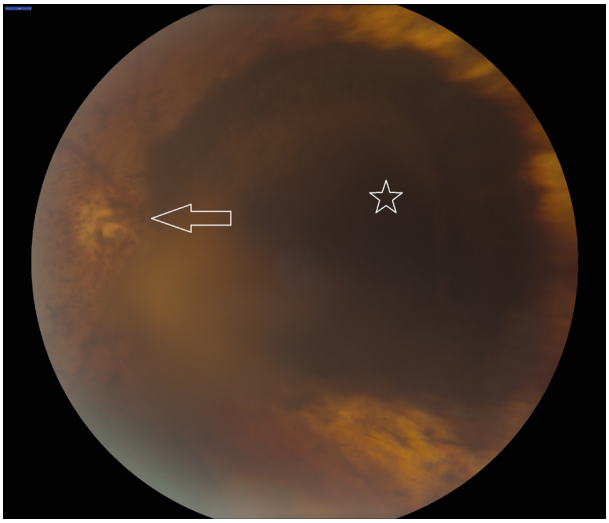

Figure 2. Fundoscopic image of the pigmented tumour (star) adjacent to the optic disc (arrow) with floating pigmented cells most readily visible in front of the optic disk after brachytherapy.

Seventeen months after brachytherapy, the visual acuity in the treated eye decreased from 0.7 (20/29) to 0.4 (20/50) due to macular edema caused by radiation retinopathy. The patient was treated with a series of 3 intravitreal anti-VEGF injections with bevacizumab (1.25mg = 0.05mL) in four-week intervals, followed by a series of 3 intravitreal injections with ranibizumab (0.5mg = 0.05mL) in four-week intervals due to lacking response. All injections were administered in the temporal-inferior quadrant at 4 mm distance from the limbus, with a regular 30G needle. Six months after the first injection, 2 pigmented lesions appeared on the bulbar conjunctiva, raising suspicion of tumour cell seeding (Figure 3). Both lesions were located at the exact sites of the anti-VEGF injections, opposing the location of the tumour, and not at perforating vessel locations. As a needle track-related outgrowth of malignancy was suspected, an excisional biopsy was performed. The lesions were excised with large margins, leaving the inner sclera intact without any macroscopically visible pigmentation. Histopathological examination demonstrated the presence of cells in the conjunctival stroma with small nuclei and cytoplasmic melanin pigment (Figure 4). Staining with anti-CD68 showed that the majority of these cells were macrophages, whereas a melanocytic origin of the cells could not be demonstrated by Melan-A staining. No additional treatment was given and no recurrences have been observed within the 3 months following excision.

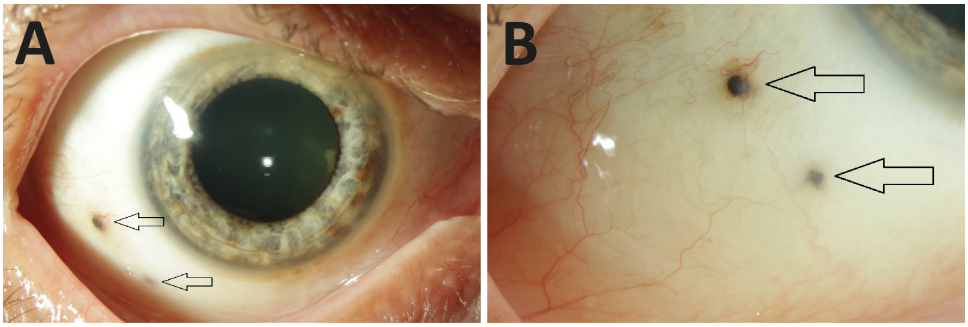

Figure 3. Conjunctival lesions. **a** Pigmented lesions on the conjunctiva, located at 7 and 8 o'clock (arrows). Some melanosis is visible at the limbus, unrelated to the pigmented lesions. **b** Magnification of the lesions (arrows). Near the upper lesion some small conjunctival vessels are visible, while near the lower lesion no vessels are seen.

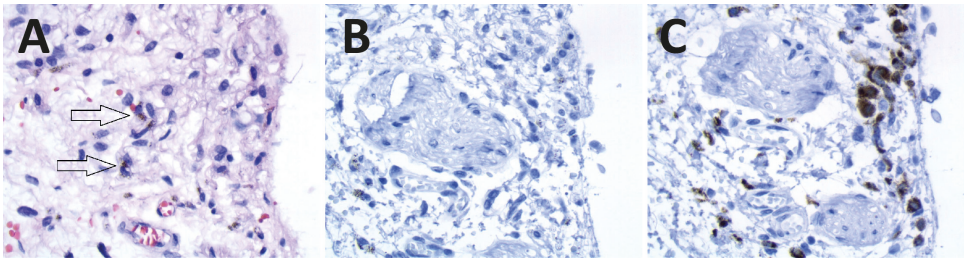

Figure 4. Histopathology. a Histology of the pigmented lesion showing conjunctival stroma with scattered cells with brown cytoplasmic pigment and small nuclei (arrows). (HE stain, original magnification 40x). **b** The cells are not reactive for Melan-A. In some cells, brown pigmentation persisted despite melanin depigmentation, but it is very distinct from the immunohistochemical reaction product. (Melan-A stain after melanin depigmentation, original magnification 40x). **c** The cells show positive staining for macrophage-specific CD68. (CD68 stain after melanin depigmentation, original magnification 40x).

DISCUSSION

The occurrence of pigmented conjunctival lesions following uveal melanoma treatment or needle insertion has been described, which includes cases of tumour seeding following fine-needle aspiration biopsy (FNAB) or open biopsy. In 2006, Caminal et al.[6] described a case of epibulbar seeding after FNAB in a patient with uveal melanoma. In 2013, Schefler et al.[7] described 4 cases of extraocular extension following FNAB, vitrectomy or open biopsy, while more recently Mashayekhi et al.[8] described a case of extraocular extension of ciliochoroidal melanoma after FNAB.

Pigmented lesions unrelated to biopsy, but following brachytherapy in uveal melanoma, have been described earlier by Toivonen and Kivela[9] and were seen within 1 year after treatment in 85% of cases. Toivonen and Kivela suggested that following irradiation, macrophages with debris migrated transsclerally.

In our case, no biopsy of the primary tumour was performed but intravitreal injections with anti-VEGF treatment were administered in a patient with uveal melanoma. To our knowledge, no other cases of pigmented lesions following this procedure have been described. Histopathology showed that the pigmentation was most probably caused by melanin-loaded macrophages. We therefore suggest that the mechanism of pigmentation in our case occurred due to migration of pigment-loaded macrophages to the injection site of the intravitreal injection, reaching the deep conjunctival layers. Alternatively, the brachytherapy-induced tumour cell necrosis must have led to the presence of numerous melanin-containing macrophages in the vitreous that may have adhered to the needle.

Summarizing our case, this is the first known report of a pigmented conjunctival lesion at the injection site of intravitreal treatment for radiation retinopathy following brachytherapy for uveal melanoma. Ophthalmologists should be aware that new conjunctival pigmented lesions in patients with uveal melanoma are not necessarily malignant.

Statement of Ethics: Written informed consent was obtained from the patient for this report.

Disclosure Statement: The authors state they have no conflicts of interest to disclose.

REFERENCES

1. Singh AD, Turell ME, Topham AK. Uveal melanoma: trends in incidence, treatment, and survival. *Ophthalmology.* 2011;118(9):1881-1885.
2. Damato BE. Treatment selection for uveal melanoma. *Dev Ophthalmol.* 2012;49:16-26.
3. Tarmann L, Wackernagel W, Avian A, et al. Ruthenium-106 plaque brachytherapy for uveal melanoma. *Br J Ophthalmol.* 2015;99(12):1644-1649.
4. Damato B, Patel I, Campbell IR, Mayles HM, Errington RD. Local tumor control after 106Ru brachytherapy of choroidal melanoma. *Int J Radiat Oncol Biol Phys.* 2005;63(2):385-391.
5. Wen JC, McCannel TA. Treatment of radiation retinopathy following plaque brachytherapy for choroidal melanoma. *Curr Opin Ophthalmol.* 2009;20(3):200-204.
6. Caminal JM, Sanz S, Carreras M, et al. Epibulbar seeding at the site of a transvitreal fine-needle aspiration biopsy. *Arch Ophthalmol.* 2006;124(4):587-589.
7. Schefler AC, Gologorsky D, Marr BP, et al. Extraocular extension of uveal melanoma after fine-needle aspiration, vitrectomy, and open biopsy. *JAMA Ophthalmol.* 2013;131(9):1220-1224.
8. Mashayekhi A, Lim RP, Shields CL, Eagle RC, Jr., Shields JA. Extraocular Extension of Ciliochoroidal Melanoma after Transscleral Fine-Needle Aspiration Biopsy. *Retin Cases Brief Rep.* 2016;10(3):289-292.
9. Toivonen P, Kivelä T. Pigmented episcleral deposits after brachytherapy of uveal melanoma. *Ophthalmology.* 2006;113(5):865-873.

GENERAL DISCUSSION AND APPENDICES

Chapter 7: Summary and General Discussion

Chapter 8: Appendices

8.1 Dutch Summary
8.2 Acknowledgements
8.3 Curriculum Vitae
8.4 List of Publications

7

Summary and General Discussion

IMAGING AND TREATMENT OF OCULAR MELANOMA

The aims of this thesis were to better diagnose ocular melanoma lesions using new imaging techniques, and to identify new targets for ocular melanoma therapy. Both conjunctival melanoma (CoM) and uveal melanoma (UM) have been studied: malignancies that share a need for better understanding and therapy, yet each with its distinct genetic background and clinical presentation. A common link in several projects of this thesis is 'angiogenesis'. This was assessed to better understand tumour growth, for diagnostic use, and as a target for therapy. We believe that the inclusion of UM as well as CoM in this thesis, and the inclusion of basic projects as well as clinical projects, resulted in a comprehensive overview with a better understanding of both malignancies.

PART I – CONJUNCTIVAL MELANOMA

Summary and discussion

CoM is a rare ocular tumour with an incidence of 0.3-0.8 per million in Caucasians.[1-4] It has a high recurrence rate (of approximately 40% in 5 years)[1,5] and high metastatic potential (of approximately 20% in 10 years)[6,7]. There is a need to diagnose patients early, and to develop better therapies, especially for advanced and metastatic disease.

This thesis starts by analyzing current CoM patients and their clinical outcome (**chapters 2.1, 2.2, 2.3**). The findings support the call for better therapies and provide recommendations regarding clinical follow up. Next, we summarize the current knowledge on the genetic and immunologic background of CoM (**chapters 3.1, 3.2**). This provides a basis for diagnostic and prognostic purposes, and indicates targets for new therapies based on genetic and immunologic principles.

CoM has high recurrence and metastasis rates

Better therapies in CoM are urgently needed because of the substantial rates of recurrences and metastases.[4,5] While several studies have reported on this topic, most study groups are small and only assess a limited follow-up time. This may be not surprising due to the rarity of CoM and fragmented healthcare systems in many countries, however it compromises conclusions on prognostic features. In the Netherlands, national referral centers for ocular oncology have been appointed and a national oncology registry exists (i.e. OncDoc / RANK), which allowed us to obtain a large cohort of 70 patients with good-quality follow-up data (**chapter 2.1**). We identified the importance of early referral to a center with expertise, as patients who had a first excision elsewhere had a significantly higher recurrence rate. This may be due to incomplete excision or suboptimal surgical approach with a risk for tumour dissemination. For localized CoM, we found that surgical excision alone is not an appropriate therapy, and that adjuvant strategies are required. There is currently no data favouring a particular strategy.[8,9] Our approach includes brachytherapy (currently with Ru-106

plaques) for bulbar lesions, and addition of mitomycin c drops when a component of primary acquired melanosis (PAM) is present. Results of this approach in development of recurrences and patient survival are favourable compared to the literature and could be advised for other centers as well.[10]

Tumour pigmentation is an important clinical feature of CoM

While assessing our cohort of CoM patients, we were struck by the variety of clinical presentations. CoM may range from amelanotic and pink to black, reflecting different types of tumour pigmentation. Melanin has a role in melanoma formation and behaviour – as is known from work on skin melanoma and UM[11]- and this posed the question whether pigment characteristics are related to CoM behaviour. We studied pigment in a combined set of 444 CoM patients from Leiden and Philadelphia (USA), notably one of the largest reported cohorts on CoM. In **chapter 2.2** we describe that lightly-pigmented CoM have a worse clinical outcome compared to darker lesions. This may result from characteristics of different types of melanin,[12] but also from treatment-related factors such as early identification and visualization of tumour margins. In **chapter 2.3** we compared the original CoM lesions with their recurrences. We show that recurrences are more often lightly-pigmented than their parent lesions, but any pigmentation status can occur. This finding may be due to a loss of pigment-producing ability in more malignant melanocytes, or because primary amelanotic lesions are more easily overlooked. As clinical outcome did not relate to pigmentation of recurrences (as it did to pigmentation of the primary lesion), this may imply that metastases have an early origin more related to the primary lesion than to the recurrence, or that recurrences have been treated more heavily.

CoM requires a thorough and lengthy follow-up

Regarding the clinical management of CoM, we emphasize the importance of proper follow-up and identification of conjunctival lesions. Recurrences of CoM may not only show a variety of pigmentation (**chapter 2.3**), but also occur even after several years, as we illustrate by a patient who developed two late recurrent lesions; one recurrence developed 21 years after excision and cryotherapy, the other developed 4 years after orbital exenteration (**chapter 6.3)**. This implies that CoM is prone to 'tumour dormancy'[13] with cells that spread prior to surgical therapy. Proper identification of conjunctival lesions during follow-up is therefore important to provide appropriate care. Importantly, when assessing conjunctival lesions, clinicians should always be wary of secondary causes of melanoma, as the conjunctiva is prone to harbour metastases of distantly-located melanoma types.[14] We present a patient with a conjunctival lesion that proved to be a metastasis of a cutaneous melanoma (**chapter 6.1**). This patients was treated successfully with new targeted/immunotherapy, stating the relevance of these new therapies. Illustrating that not every pigmented conjunctival

lesion is malignant, however, was our observation in a patient who received brachytherapy for UM and later developed two pigmented spots on the sclera, presumably consisting of pigment-loaded macrophages requiring no further treatment (**chapter 6.4**).

The genetic background of CoM is that of an extraocular melanoma

Recent work shows that CoM harbours mutations in genes such as *BRAF*, *NRAS*, *NF1* and *TERT*, and that rare mutations can occur in *KIT* and other genes.[15-19] This profile resembles cutaneous melanoma[20,21] and illustrates the position of CoM as an *extraocular* tumour different from UM (e.g. with mutations in *GNAQ/11* and *BAP1*).[22-24] Assessment of genetic mutations in CoM confirms that ultraviolet (UV) radiation is a contributing factor for tumour development, with many C>T alterations and a high mutational burden;[25-27] however, CoM can develop both at sun-exposed as well as non-exposed sites, implying that UV is not a necessity for its development.

Precursor lesions of CoM, such as conjunctival nevi and PAM,[28] harbour similar mutations as found in CoM and while frequencies in reported genes differ, no truly exclusive mutations are known.[17,29-32] This limits the use of genetics to differentiate benign from malignant lesions and illustrates that key moments in tumorigenesis of CoM are yet to be identified. Mutational status can be used to differentiate melanocytic lesions with a conjunctival origin from a uveal origin however, relevant in specific cases of UM tumour outgrowth or in cases with an unknown primary lesion. Very recent reports show that (anterior) uveal melanoma may harbour *BRAF* mutations,[33] and CoM may sporadically harbour BAP1 mutations however,[34] which though unlikely, limits this approach.

The prognostic relevance of mutations in primary CoM is currently limited since studies are not consistent regarding their clinical outcome, and hampered by small sample sizes. Recent work shows that *TERT* mutations may relate to metastasis, and that these mutations are very rare in benign disease, so this may become an important new factor in CoM staging.[35] A promising approach regarding the genetic traits of CoM is that of micro RNA (miRNA) analysis, which - although in an early phase - may be informative by analysing many genes at once to differentiate and prognosticate lesions.[36-38]

Presence of immune infiltrate in CoM suppresses tumour growth but needs further identification

In addition to tumour genetics, inflammation is one of the hallmarks of cancer and has been recognized as an important factor for tumour development and behaviour.[39] Tumour infiltrate in CoM consists of several cell types, including lymphocytes and macrophages with different effector functions. The presence of inflammatory cells is known to be favourable in CoM,[40-42] suggesting benefit from tumour surveillance. This observation shows that – also in this matter – CoM resembles cutaneous melanoma while this is in contrast with UM where inflammation is a sign of malignancy and worse clinical outcome.[43]

The role of macrophages in CoM is poorly understood, but as these cells can promote angiogenesis (especially the predominantly identified M2 subtype),[44] it is likely that they exert an unfavourable effect on CoM growth as is known from cutaneous melanoma and also from UM.[45]

One of the important immunological mechanisms (checkpoints) of host-tumour interactions is the PD-1/PD-L1 pathway.[46] In this, expression of molecules causes downregulation of the immune system and thus allows unrestricted tumour growth. We showed that PD-L1 is expressed in CoM and this expression relates to worse survival as can be hypothesized by the mechanism of action (**chapter 3.2**). This is similar to observations from cutaneous melanoma.

New therapies for CoM follow genetic and immunologic findings

A consequence of the findings on tumour genetics and immunologic behaviour of CoM are the theoretical benefit of 'targeted' and 'checkpoint inhibitor' therapies, as were recently introduced for cutaneous melanoma. New therapies like these are urgently awaited for CoM cases where conventional therapy is not sufficient. To our knowledge, no clinical trials or large series on this topic exist, but small reports on CoM patients illustrate the benefit for locally advanced as well as metastatic disease.

Targeted therapy includes *BRAF* and MEK inhibitors, and several reports have been presented on successful tumour control in CoM (reviewed in **chapter 3.1**). In addition, a plethora of drugs is being evaluated in preclinical studies (targeting eg *KIT*, *TERT*, or EZH2).

Checkpoint inhibitors act by host-tumour interaction, as by the earlier mentioned PD-1/PD-L1 axis. Looking at tumour sections and in vitro models, we showed a rationale for usage of anti PD-1/PD-L1 drugs in CoM (**chapter 3.2**). Cases of patients who were treated with these drugs have been reported with successful outcome (reviewed in **chapter 3.1**).

Drawbacks to new therapies for CoM

Two unfortunate drawbacks of the currently-available new therapies are to be mentioned: *treatment resistance* and the *development of side effects*.[47-50] To overcome the first issue, a combination of therapies may be required, targeting several pathways simultaneously. Importantly, genetic screening and typing of CoM allows for a personalized approach to best fit patients and drugs. Side effects of the new therapies should be monitored to adapt the therapy, or to allow for side effect treatment. Since immune-related side effects are a relatively new phenomenon in medicine, this calls for clinical attention. Notably, immune-related side effects can be ocular – while admission of new drugs is systemic – and ophthalmologists should therefore be wary of these in any oncology patients treated with immunologic drugs for non-ocular malignancies.[51] We show a case of development of ocular rosacea following ipilimumab and nivolumab use, that was effectively treated with topical steroids (**chapter 6.2**).

Future perspectives

Current studies on genetics and immunology in CoM demonstrate that much is still to be learned about tumour development and behaviour. Similarly though, it shows that by this knowledge new promising therapies are visible around the corner. A better characterization of CoM (based on genetics, precursor lesions, and external stimuli such as melanin and UV-radiation) will allow for better prognostication and individualized therapies. In addition to drugs targeting *BRAF* and MEK, and immunotherapy against PD-1 and CTLA4, new drugs targeting *Kit, NF1, TERT*, or *EZH2* are awaited. New drugs will mostly benefit metastatic patients, but may also be beneficial to patients with advanced local disease as an alternative to extensive surgery. A secondary effect of these new therapeutic options is the relevance of better tumour staging. Apart from staging based on tumour material, this includes the use of lymph node staging by the sentinel lymph node biopsy[52] and imaging.

A promising development in ocular oncology is the recognition of CoM as distinct disease entity within ocular melanoma, and the awareness of clinicians worldwide about this. Early referral to tertiary centers should become regular practice, as should be the use of appropriate adjuvant therapy. Besides a direct benefit for current patients to receive best treatment, this facilitates research on larger numbers of patients, benefiting future patients as well.

PART II – UVEAL MELANOMA

Summary and discussion

UM is the most common type of ocular melanoma with an incidence of 5.1-8.6 per million in Caucasians.[53,54] It comprises melanoma of the choroid, ciliary body and iris. Up to 50% of patients die from metastatic disease,[55] with unchanged numbers over the last five decades.[56] Many concepts and therapies that apply to other forms of melanoma are not effective for UM due to its distinct genetic background and immune-privileged position in the eye.[57] Differentiating benign from malignant uveal lesions can be challenging, while the first are harmless and there is an urgent need for development of better therapies for the latter.

In this part of the thesis, we first address the genetic and immunologic profile of UM, which are very different from what is seen in cutaneous melanoma and CoM (**chapter 3.1**). We focus on activation of the growth-related YAP1 pathway as potential predictor of metastases and as therapeutic target for UM (**chapter 4.1**). Next we study angiogenesis as a factor defining UM behaviour and as link between tumour genetics and clinical outcome (**chapter 4.2**). In a patient setting using new imaging devices, we study vasculature in both uveal and conjunctival lesions to differentiate benign and malignant disease (**chapters 5.1, 5.2**).

The genetic and immunologic background of UM are different from cutaneous and conjunctival melanoma

UM has a remarkable genetic profile and immunologic background, very different from what is seen in cutaneous melanoma and CoM (**chapter 3.1**). UM's are characterized by early mutations in *GNAQ/11*, and secondary mutations in *BAP1*, *EIF1AX* and *SF3B1*.[57] There is no role for UV radiation in the etiology of *posterior* UM, while new insights show that *anterior* UM occasionally demonstrate typical UV-induced genetic signatures.[58] The presence of immune infiltrate is unfavorable in UM, suggesting that immune cells fail to destroy the tumour; a possible explanation is found in the expression of immune inhibitors such as *Indoleamine 2,3-dioxygenase* (IDO1) and *T cell immunoreceptor with Ig and ITIM domains* (TIGIT), limiting immune responses.[59] Newly-introduced targeted and immunotherapy are currently not successful in UM, which is again attributed to the altered immune response compared to what is seen in extraocular CoM and cutaneous melanoma.[60]

The YAP1-pathway is involved in tumour growth and provides a new approach to UM therapy

Cell growth is regulated by several stimuli, including the YAP1 pathway.[61] Interestingly, YAP1 is activated by the *GNAQ/11* mutation that is commonly identified in UM,[62,63] and the YAP1 pathway received recent interest as player in UM behaviour and as candidate for therapy; it can be inhibited by the readily available ophthalmic drug verteporfin.[64]

In **chapter 4.1** we study the YAP1 pathway in both UM and CoM. We show that YAP1 expression is higher in UM with an unfavorable genetic profile and tends to be associated with worse clinical outcome. In vitro tests with verteporfin show a response in several UM cell lines, but only a limited response in CoM cell lines and (slow growing) BAP1-negative UM cell lines, demonstrating that not only the studied genetic background but also traits such as cell growth rate underlie drug sensitivity. While verteporfin may not be best as a single-use drug for UM, targeting the YAP1 pathway may be part of an approach for UM and beneficial to overcome drug resistance with other agents.

Angiogenesis relates to tumour genetics and worse clinical outcome in UM

Angiogenesis is important for the development and behavior of UM.[45,65] Vessels provide nutrients and oxygen to a tumour, and provide a route for metastatic cells to disseminate. Angiogenesis is influenced by the tumour micro environment as immune cells can produce pro-inflammatory and pro-angiogenic cytokines. It was recently demonstrated that genetic events in UM relate to the presence of immune cells[66] and we therefore wondered whether genetic events relate to (markers of) angiogenesis. In **chapter 4.2** we show that vascular density relates to the genetic profile, with an increased vascular density in M3/BAP1-loss UM. Status of chromosome 8q (of which gain is an early event)[67] was not related to the vascular density, indicating that true increased angiogenesis is a later event. Increased vascular density was associated with expression of ANGPT2, VWF and remarkably less VEGF-B, a cytokine that needs further elucidation (in contrast to the better-known VEGF-A).

A key regulator of angiogenesis is HIF1a.[68] Drugs targeting HIF1a are currently under investigation in UM[69] and we wondered which patients could benefit most. We showed that higher expression of HIF1a was observed in BAP1-loss UM. This provides information on the development of UM and suggests that tumours with M3/BAP1-loss may be the best candidates for HIF1a targeting.[70]

Clinical assessment of retinal oximetry differentiates between choroidal melanoma and nevi

Tumour vessels are currently assessed in clinical practice to differentiate benign from malignant ocular lesions. This can be done using fluorescein angiography, with injection of dye and assessment of vascular patterns and leakage.[71,72] Drawbacks to the technique are the invasive nature and limited use in anterior segment lesions particularly of the conjunctiva as dye easily leaks from conjunctival

vessels.[73] As proliferating tumour cells are expected to have an increased metabolism, we studied oxygenation of retinal vessels in eyes with a choroidal melanoma or nevus using a relatively new imaging device (Oxymap T1) (**chapter 5.1**). While choroidal nevus eyes had no alterations, we found different oxygen values in choroidal melanoma eyes, including in retina not-overlying tumour tissue. The observed alterations may be due to a different oxygen metabolism, inflammation, and relocation of flow in melanoma eyes. As a diagnostic technique, other techniques may currently be more specific, but retinal oximetry adds to this knowledge and also allows for future monitoring of treatment-related (radiation) effects.

OCT-Angiography is feasible for CoM and UM of the anterior segment but currently limited by imaging and software techniques

A new non-invasive imaging technique to depict the structure of vessels of the eye is OCT-Angiography (OCTA). While being developed to study retinal vessels,[74] we applied this technique to the anterior segment with the aim of visualizing tumour vessels in the iris and conjunctiva (**chapter 5.2**). We show that vessels can be depicted, but that obtaining good-quality images is highly dependent on patient and tumour characteristics such as cooperation and pigmentation status. Within nevi as well as melanoma, we found tortuous vascular patters, distinct from healthy iris and conjunctiva. We did not observe differences in vascular density or patterns between benign and malignant lesions, however, possibly hampered by a small sample size and the reported limitations of current imaging techniques.

Future Perspectives

The search for treatment of (disseminated) UM continues, and several targets are under investigation. Multi-pathway blocking may overcome issues with current drugs, and targeting the YAP1 pathway is a promising route as part of treatment for UM. Verteporfin, as a readily-available ophthalmic drug, may also demonstrate other usage such as slowing down tumour growth while waiting for (radiation) therapy. The immune privilege of the eye, and the position of UM, needs better understanding to possibly introduce drugs that revolutionized therapy of cutaneous, and conjunctival, melanoma.

New imaging techniques are promising in the non-invasive approach to diagnose ocular lesions. For the assessment of tumour vessels, developments in imaging resolution and analysis software are beneficial to overcome artefacts of tumour pigment and lesion thickness. Oximetry of retinal vessels may perhaps not be an addition for diagnostic purposes, but a candidate to monitor treatment response, in combination with structural imaging using OCTA. The latter has proven suitable to detect minor vascular aberrations in UM eyes and may be implemented more with the renewed studies into radiation retinopathy following the application of anti-VEGF therapy.

CONCLUDING REMARKS

Over the last two centuries, much has changed in the field of ocular oncology. The implementation of the ophthalmoscope (to visualize intraocular lesions in patients), and histological assessment (to visualize individual melanoma cells) were only the beginning of a path that led to advanced diagnostic procedures and therapeutic possibilities. A variety of imaging techniques is currently available to study melanocytic lesions, and cell traits can be studied on a genetic level identifying subclones within single tumours. Surgery, radiotherapy and conventional chemotherapy have been complemented by individualized (targeted/immune) therapy for specific tumour cells.

Why then, two centuries of study later, is ocular melanoma still a deadly condition and is the call for better management still urgent? As we demonstrate in this thesis, a first explanation may be that 'ocular melanoma' is not a homogenous field of study, and that in fact it comprises a variety of tumour types. Not only UM and CoM have different traits, but as knowledge continues, subgroups within UM and within CoM are being identified, all requiring a different approach. Second, the rarity of these entities does not allow for large-scale trials. Collaborations, internationally, are therefore further needed to answer the pending questions with sufficient numbers. In line with rarity is lack of exposure for many (general) ophthalmologists, calling for specialized structures of healthcare. And third, perhaps the era of digital imaging and personalized medicine has only just started. For CoM, some major advances coming from cutaneous melanoma have been introduced and it is expected that this will largely benefit patients in the coming years. For UM, a personalized approach needs further study of possible targets, but it is not unlikely that new drugs will follow shortly. Technological advances develop by the day, and as we look upon how much technology has changed in a decade, who knows what imaging techniques will be developed. This thesis, naturally, can only aim to be a piece in that large puzzle, and hopefully adds to the path of making ocular melanoma a disease of the past.

REFERENCES

1. Tuomaala S, Eskelin S, Tarkkanen A, Kivela T. Population-based assessment of clinical characteristics predicting outcome of conjunctival melanoma in whites. *Invest Ophthalmol Vis Sci.* 2002;43(11):3399-3408.
2. Yu GP, Hu DN, McCormick S, Finger PT. Conjunctival melanoma: is it increasing in the United States? *Am J Ophthalmol.* 2003;135(6):800-806.
3. Triay E, Bergman L, Nilsson B, All-Ericsson C, Seregard S. Time trends in the incidence of conjunctival melanoma in Sweden. *Br J Ophthalmol.* 2009;93(11):1524-1528.
4. Missotten GS, Keijser S, De Keizer RJ, De Wolff-Rouendaal D. Conjunctival melanoma in the Netherlands: a nationwide study. *Invest Ophthalmol Vis Sci.* 2005;46(1):75-82.
5. Shields CL, Markowitz JS, Belinsky I, et al. Conjunctival melanoma: outcomes based on tumor origin in 382 consecutive cases. *Ophthalmology.* 2011;118(2):389-395 e381-382.
6. Tuomaala S, Kivela T. Metastatic pattern and survival in disseminated conjunctival melanoma: implications for sentinel lymph node biopsy. *Ophthalmology.* 2004;111(4):816-821.
7. Shields CL. Conjunctival melanoma: risk factors for recurrence, exenteration, metastasis, and death in 150 consecutive patients. *Trans Am Ophthalmol Soc.* 2000;98:471-492.
8. Wong JR, Nanji AA, Galor A, Karp CL. Management of conjunctival malignant melanoma: a review and update. *Expert Rev Ophthalmol.* 2014;9(3):185-204.
9. Vora GK, Demirci H, Marr B, Mruthyunjaya P. Advances in the management of conjunctival melanoma. *Surv Ophthalmol.* 2016.
10. Brouwer NJ, Marinkovic M, Peters FP, et al. Management of conjunctival melanoma with local excision and adjuvant brachytherapy. *Eye (Lond).* 2021;35(2):490-498.
11. Slominski RM, Zmijewski MA, Slominski AT. The role of melanin pigment in melanoma. *Exp Dermatol.* 2015;24(4):258-259.
12. Ito S, Wakamatsu K. Quantitative analysis of eumelanin and pheomelanin in humans, mice, and other animals: a comparative review. *Pigment Cell Res.* 2003;16(5):523-531.
13. Ossowski L, Aguirre-Ghiso JA. Dormancy of metastatic melanoma. *Pigment Cell Melanoma Res.* 2010;23(1):41-56.
14. Kiratli H, Shields CL, Shields JA, DePotter P. Metastatic tumours to the conjunctiva: report of 10 cases. *Br J Ophthalmol.* 1996;80(1):5-8.
15. Griewank KG, Westekemper H, Murali R, et al. Conjunctival melanomas harbor BRAF and NRAS mutations and copy number changes similar to cutaneous and mucosal melanomas. *Clin Cancer Res.* 2013;19(12):3143-3152.
16. Griewank KG, Murali R, Schilling B, et al. TERT promoter mutations in ocular melanoma distinguish between conjunctival and uveal tumours. *Br J Cancer.* 2013;109(2):497-501.
17. Koopmans AE, Ober K, Dubbink HJ, et al. Prevalence and implications of TERT promoter mutation in uveal and conjunctival melanoma and in benign and premalignant conjunctival melanocytic lesions. *Invest Ophthalmol Vis Sci.* 2014;55(9):6024-6030.
18. Scholz SL, Cosgarea I, Susskind D, et al. NF1 mutations in conjunctival melanoma. *Br J Cancer.* 2018;118(9):1243-1247.
19. Sheng X, Li S, Chi Z, et al. Prognostic factors for conjunctival melanoma: a study in ethnic Chinese patients. *Br J Ophthalmol.* 2015;99(7):990-996.
20. Krauthammer M, Kong Y, Bacchiocchi A, et al. Exome sequencing identifies recurrent mutations in NF1 and RASopathy genes in sun-exposed melanomas. *Nat Genet.* 2015;47(9):996-1002.

21. Curtin JA, Fridlyand J, Kageshita T, et al. Distinct sets of genetic alterations in melanoma. *N Engl J Med.* 2005;353(20):2135-2147.
22. Van Raamsdonk CD, Bezrookove V, Green G, et al. Frequent somatic mutations of GNAQ in uveal melanoma and blue naevi. *Nature.* 2009;457(7229):599-602.
23. Van Raamsdonk CD, Griewank KG, Crosby MB, et al. Mutations in GNA11 in uveal melanoma. *N Engl J Med.* 2010;363(23):2191-2199.
24. Koopmans AE, Verdijk RM, Brouwer RW, et al. Clinical significance of immunohistochemistry for detection of BAP1 mutations in uveal melanoma. *Mod Pathol.* 2014;27(10):1321-1330.
25. Rivolta C, Royer-Bertrand B, Rimoldi D, et al. UV light signature in conjunctival melanoma; not only skin should be protected from solar radiation. *J Hum Genet.* 2016;61(4):361-362.
26. Swaminathan SS, Field MG, Sant D, et al. Molecular Characteristics of Conjunctival Melanoma Using Whole-Exome Sequencing. *JAMA Ophthalmol.* 2017;135(12):1434-1437.
27. Cisarova K, Folcher M, El Zaoui I, et al. Genomic and transcriptomic landscape of conjunctival melanoma. *PLoS Genet.* 2020;16(12):e1009201.
28. Jakobiec FA. Naming the Precursors of Conjunctival Melanoma. *Am J Ophthalmol.* 2016;164:152-153.
29. Goldenberg-Cohen N, Cohen Y, Rosenbaum E, et al. T1799A BRAF mutations in conjunctival melanocytic lesions. *Invest Ophthalmol Vis Sci.* 2005;46(9):3027-3030.
30. Francis JH, Grossniklaus HE, Habib LA, et al. BRAF, NRAS, and GNAQ Mutations in Conjunctival Melanocytic Nevi. *Invest Ophthalmol Vis Sci.* 2018;59(1):117-121.
31. Dratviman-Storobinsky O, Cohen Y, Frenkel S, Pe'er J, Goldenberg-Cohen N. Lack of oncogenic GNAQ mutations in melanocytic lesions of the conjunctiva as compared to uveal melanoma. *Invest Ophthalmol Vis Sci.* 2010;51(12):6180-6182.
32. Alessandrini L, Parrozzani R, Bertorelle R, et al. C-Kit SCF receptor (CD117) expression and KIT gene mutation in conjunctival pigmented lesions. *Acta Ophthalmol.* 2013;91(8):e641-645.
33. van Poppelen NM, Vaarwater J, Mudhar HS, et al. Genetic Background of Iris Melanomas and Iris Melanocytic Tumors of Uncertain Malignant Potential. *Ophthalmology.* 2018;125(6):904-912.
34. van Poppelen NM, van Ipenburg JA, van den Bosch Q, et al. Molecular Genetics of Conjunctival Melanoma and Prognostic Value of TERT Promoter Mutation Analysis. *Int J Mol Sci.* 2021;22(11).
35. van Ipenburg JA, Naus NC, Dubbink HJ, et al. Prognostic value of TERT promoter mutations in conjunctival melanomas in addition to clinicopathological features. *Br J Ophthalmol.* 2020:[Online ahead of print].
36. Larsen AC, Mikkelsen LH, Borup R, et al. MicroRNA Expression Profile in Conjunctival Melanoma. *Invest Ophthalmol Vis Sci.* 2016;57(10):4205-4212.
37. Mikkelsen LH, Andersen MK, Andreasen S, et al. Global microRNA profiling of metastatic conjunctival melanoma. *Melanoma Res.* 2019;29(5):465-473.
38. van Ipenburg JA, Gillis Ing AJM, Dorssers LCJ, et al. MicroRNA Profiling in Benign and Malignant Conjunctival Melanocytic Lesions. *Ophthalmology.* 2020;127(3):432-434.
39. Hanahan D, Weinberg RA. Hallmarks of cancer: the next generation. *Cell.* 2011;144(5):646-674.
40. Bobic-Radovanovic A, Latkovic Z, Marinkovic J, Radovanovic Z. Predictors of survival in malignant melanoma of the conjunctiva: a clinico-pathological and follow-up study. *Eur J Ophthalmol.* 1998;8(1):4-7.
41. Crawford JB. Conjunctival melanomas: prognostic factors a review and an analysis of a series. *Trans Am Ophthalmol Soc.* 1980;78:467-502.
42. Folberg R, McLean IW, Zimmerman LE. Malignant melanoma of the conjunctiva. *Hum Pathol.* 1985;16(2):136-143.
43. Bronkhorst IH, Jager MJ. Inflammation in uveal melanoma. *Eye (Lond).* 2013;27(2):217-223.

44. Mantovani A, Sozzani S, Locati M, Allavena P, Sica A. Macrophage polarization: tumor-associated macrophages as a paradigm for polarized M2 mononuclear phagocytes. *Trends Immunol.* 2002;23(11):549-555.
45. Bronkhorst IH, Ly LV, Jordanova ES, et al. Detection of M2-macrophages in uveal melanoma and relation with survival. *Invest Ophthalmol Vis Sci.* 2011;52(2):643-650.
46. Okazaki T, Honjo T. PD-1 and PD-1 ligands: from discovery to clinical application. *Int Immunol.* 2007;19(7):813-824.
47. Ascierto PA, McArthur GA, Dréno B, et al. Cobimetinib combined with vemurafenib in advanced BRAF(V600)-mutant melanoma (coBRIM): updated efficacy results from a randomised, double-blind, phase 3 trial. *Lancet Oncol.* 2016;17(9):1248-1260.
48. Long GV, Stroyakovskiy D, Gogas H, et al. Combined BRAF and MEK inhibition versus BRAF inhibition alone in melanoma. *N Engl J Med.* 2014;371(20):1877-1888.
49. Robert C, Schachter J, Long GV, et al. Pembrolizumab versus Ipilimumab in Advanced Melanoma. *N Engl J Med.* 2015;372(26):2521-2532.
50. Hodi FS, Chiarion-Sileni V, Gonzalez R, et al. Nivolumab plus ipilimumab or nivolumab alone versus ipilimumab alone in advanced melanoma (CheckMate 067): 4-year outcomes of a multicentre, randomised, phase 3 trial. *Lancet Oncol.* 2018;19(11):1480-1492.
51. Dalvin LA, Shields CL, Orloff M, Sato T, Shields JA. CHECKPOINT INHIBITOR IMMUNE THERAPY: Systemic Indications and Ophthalmic Side Effects. *Retina.* 2018;38(6):1063-1078.
52. Esmaeli B, Rubin ML, Xu S, et al. Greater Tumor Thickness, Ulceration, and Positive Sentinel Lymph Node Are Associated With Worse Prognosis in Patients With Conjunctival Melanoma: Implications for Future AJCC Classifications. *Am J Surg Pathol.* 2019;43(12):1701-1710.
53. Singh AD, Turell ME, Topham AK. Uveal melanoma: trends in incidence, treatment, and survival. *Ophthalmology.* 2011;118(9):1881-1885.
54. Virgili G, Gatta G, Ciccolallo L, et al. Incidence of uveal melanoma in Europe. *Ophthalmology.* 2007;114(12):2309-2315.
55. Damato B. Progress in the management of patients with uveal melanoma. The 2012 Ashton Lecture. *Eye (Lond).* 2012;26(9):1157-1172.
56. Roelofsen CDM, Wierenga APA, van Duinen S, et al. Five Decades of Enucleations for Uveal Melanoma in One Center: More Tumors with High Risk Factors, No Improvement in Survival over Time. *Ocul Oncol Pathol.* 2021;7(2):133-141.
57. Jager MJ, Shields CL, Cebulla CM, et al. Uveal melanoma. *Nat Rev Dis Primers.* 2020;6(1):24.
58. Johansson PA, Brooks K, Newell F, et al. Whole genome landscapes of uveal melanoma show an ultraviolet radiation signature in iris tumours. *Nat Commun.* 2020;11(1):2408.
59. Robertson AG, Shih J, Yau C, et al. Integrative Analysis Identifies Four Molecular and Clinical Subsets in Uveal Melanoma. *Cancer Cell.* 2017;32(2):204-220 e215.
60. Heppt MV, Steeb T, Schlager JG, et al. Immune checkpoint blockade for unresectable or metastatic uveal melanoma: A systematic review. *Cancer Treat Rev.* 2017;60:44-52.
61. Moroishi T, Hansen CG, Guan KL. The emerging roles of YAP and TAZ in cancer. *Nat Rev Cancer.* 2015;15(2):73-79.
62. Yu FX, Luo J, Mo JS, et al. Mutant Gq/11 promote uveal melanoma tumorigenesis by activating YAP. *Cancer Cell.* 2014;25(6):822-830.
63. Feng X, Degese MS, Iglesias-Bartolome R, et al. Hippo-independent activation of YAP by the GNAQ uveal melanoma oncogene through a trio-regulated rho GTPase signaling circuitry. *Cancer Cell.* 2014;25(6):831-845.
64. Liu-Chittenden Y, Huang B, Shim JS, et al. Genetic and pharmacological disruption of the TEAD-YAP complex suppresses the oncogenic activity of YAP. *Genes Dev.* 2012;26(12):1300-1305.

65. Makitie T, Summanen P, Tarkkanen A, Kivela T. Microvascular density in predicting survival of patients with choroidal and ciliary body melanoma. *Invest Ophthalmol Vis Sci.* 1999;40(11):2471-2480.
66. Gezgin G, Dogrusöz M, van Essen TH, et al. Genetic evolution of uveal melanoma guides the development of an inflammatory microenvironment. *Cancer Immunol Immunother.* 2017;66(7):903-912.
67. Singh N, Singh AD, Hide W. Inferring an Evolutionary Tree of Uveal Melanoma From Genomic Copy Number Aberrations. *Invest Ophthalmol Vis Sci.* 2015;56(11):6801-6809.
68. Rankin EB, Giaccia AJ. The role of hypoxia-inducible factors in tumorigenesis. *Cell Death Differ.* 2008;15(4):678-685.
69. Dong L, You S, Zhang Q, et al. Arylsulfonamide 64B Inhibits Hypoxia/HIF-Induced Expression of c-Met and CXCR4 and Reduces Primary Tumor Growth and Metastasis of Uveal Melanoma. *Clin Cancer Res.* 2019;25(7):2206-2218.
70. Brouwer NJ, Wierenga APA, Gezgin G, et al. Ischemia Is Related to Tumour Genetics in Uveal Melanoma. *Cancers (Basel).* 2019;11(7).
71. Bakri SJ, Sculley L, Singh AD. Diagnostic techniques. In: Singh AD, Damato BE, Pe'er J, Murphree AL, Perry JD, eds. *Clinical Ophthalmic Oncology*. Edinburgh, UK: Elsevier-Saunders; 2007:175-180.
72. Oosterhuis JA, van Waveren CW. Fluorescein photography in malignant melanoma. *Ophthalmologica.* 1968;156(2):101-116.
73. Meyer PA, Watson PG. Low dose fluorescein angiography of the conjunctiva and episclera. *Br J Ophthalmol.* 1987;71(1):2-10.
74. Spaide RF, Klancnik JM, Jr., Cooney MJ. Retinal vascular layers imaged by fluorescein angiography and optical coherence tomography angiography. *JAMA Ophthalmol.* 2015;133(1):45-50.

8

Appendices

8.1 Dutch Summary / Nederlandse Samenvatting
8.2 Acknowledgements
8.3 Curriculum Vitae
8.4 List of Publications

CHAPTER 8.1 - DUTCH SUMMARY / NEDERLANDSE SAMENVATTING

NIEUWE ONTWIKKELINGEN IN BEELDVORMING EN BEHANDELING VAN OOGMELANOOM

Dit proefschrift heeft als doel om de diagnostiek van oogmelanoom te verbeteren met nieuwe beeldvormingstechnieken, en om nieuwe aangrijpingspunten te vinden voor behandeling. Zowel conjunctivamelanoom (CoM) als uveamelanoom (UM) zijn bestudeerd, twee tumortypen die betere diagnostiek en behandeling behoeven, maar elk met hun eigen genetische achtergrond en klinische presentatie. Een overkoepelend thema in meerdere projecten van dit proefschrift is 'angiogenese', d.w.z. vaatgroei. Dit is onderzocht om een beter begrip te krijgen over de rol van vaatvorming bij tumorgroei, bij diagnostiek, en als aangrijpingspunt voor behandeling. Door zowel UM als CoM te onderzoeken, en door zowel basale projecten als klinische projecten uit te voeren, menen wij dat dit proefschrift heeft geleid tot een beter begrip van beide tumortypen.

DEEL I – CONJUNCTIVAMELANOOM

Samenvatting en discussie

CoM is een zeldzame oogtumor die ontstaat uit pigmentcellen van de slijmvliezen van het oog, met een incidentie van 0.3-0.8 per miljoen in een blanke bevolking.[1-4] Het heeft een hoge recidiefkans (van circa 40% in 5 jaar)[1,5] en kans om uit te zaaien (circa 20% in 10 jaar)[6,7]. Het is nodig om patiënten vroeg te diagnosticeren, en er is een grote behoefte aan betere behandelingen, met name voor uitgebreide ziekte en in het geval van uitzaaiingen.

Dit proefschrift start met een analyse van huidige patiënten met CoM (**hoofdstukken 2.1, 2.2, 2.3**). De bevindingen laten zien dat nieuwe behandelingen nodig zijn en leiden tot aanbevelingen voor het vervolgen van patiënten in de praktijk. Hierna gaan we verder met een samenvatting van de kennis over de genetische en immunologische achtergrond van CoM (**hoofdstukken 3.1, 3.2**). Dit geeft een basis voor verdere diagnostiek en prognostiek, en geeft nieuwe aangrijpingspunten voor behandeling gebaseerd op genetische en immunologische mechanismen.

CoM heeft een hoge kans op recidieven en uitzaaiingen

Betere behandeling van CoM is nodig vanwege de hoge kans op recidieven en uitzaaiingen.[4,5] Hoewel meerdere studies dit onderwerp behandelen, zijn de meeste studies klein en rapporteren ze slechts een kort beloop. Dit is niet verwonderlijk door de zeldzaamheid van CoM en de

gefragmenteerde zorgstructuur in vele landen, maar het beperkt conclusies over prognostische eigenschappen. In Nederland zijn landelijke verwijscentra voor oogoncologie aangewezen en bestaat een landelijke oncologische registratie (OncDoc / RANK) waardoor wij een relatief groot cohort van 70 patiënten met goede gegevens over het beloop konden analyseren (**hoofdstuk 2.1**). We vonden het belang van vroege verwijzing naar expertisecentra, aangezien patiënten die hun eerste excisie in een ander centrum ontvingen, een significant hogere recidiefkans hebben. Dit kan komen door incomplete resectie of suboptimale benadering met kans op verspreiding van tumorcellen. Voor lokaal beperkte CoM vonden we dat tumorresectie alléén niet afdoende is, en dat aanvullende (adjuvante) behandeling noodzakelijk is. Er is momenteel geen data die daarbij de voorkeur geeft aan een bepaalde strategie.[8,9] Onze benadering omvat brachytherapie (met Ru-106 applicatoren) voor bulbaire laesies, en toevoeging van mitomycine-c druppels indien er (ook) primair verworven melanose (PAM) aanwezig is. Bij deze benadering zijn de uitkomsten qua recidieven en overleving gunstig vergeleken met de literatuur en dit kan dus eveneens geadviseerd worden voor andere centra.[10]

Tumorpigmentatie is een belangrijke eigenschap van CoM

Bij het analyseren van ons cohort aan CoM patiënten, werden wij getroffen door de variatie in klinische presentatie. CoM kan ongepigmenteerd, roze en zwart zijn, wat een uiting is van verschillende typen tumorpigmentatie. Melanine heeft een rol in melanoomvorming en gedrag – zoals bekend is van huidmelanoom en UM[11] – en hierdoor vroegen we ons af of kenmerken van tumorpigment bij CoM gerelateerd zijn aan tumorgedrag. Wij onderzochten pigment in een gecombineerde set van 444 CoM patiënten uit Leiden en Philadelphia (Verenigde Staten), wat opmerkelijk genoeg één van de grootste cohorten CoM is die ooit beschreven zijn. In **hoofdstuk 2.2** vonden we dat licht gepigmenteerde CoM een slechtere uitkomst hebben vergeleken met donkere laesies. Dit kan voortkomen uit eigenschappen van verschillende typen melanine,[12] maar ook van factoren die gerelateerd zijn aan behandeling zoals een vroegere herkenning en zichtbaarheid van tumorranden bij gepigmenteerde tumoren.

In **hoofdstuk 2.3** vergeleken we vervolgens de pigmentatie van oorspronkelijke CoM laesies met hun recidieven. We toonden dat recidieven vaker licht gepigmenteerd zijn dan hun oorspronkelijke laesie, maar dat elke vorm van pigmentatie kan optreden. Dit kan komen door verlies van pigmentproductie bij meer maligne pigmentcellen, of omdat primair ongepigmenteerde laesies eenvoudiger gemist worden. Aangezien de klinische uitkomst niet samenhing met pigmentatie van recidieven (en wel met de primaire laesie), kan dit erop wijzen dat uitzaaiingen een vroeg ontstaan hebben, dat meer gerelateerd is aan de primaire laesie dan aan locale recidieven, of dat recidieven intensiever worden behandeld.

CoM patiënten hebben een lange en grondige follow-up nodig

Voor het klinisch vervolgen van CoM benadrukken wij het belang van goede follow-up en het herkennen van conjunctivale laesies. Recidieven van CoM kunnen niet alleen verschillende graden van pigmentatie hebben (hoofdstuk 2.3), maar kunnen ook optreden na meerdere jaren, zoals we laten zien met een patiënt die twee late recidieven ontwikkelde: één recidief ontstond 21 jaar na excisie en cryotherapie, het andere ontstond vier jaar na orbitale exenteratie (d.w.z. totale verwijdering van het oog en omliggende weefsels, **hoofdstuk 6.3**). Dit impliceert dat CoM onderhevig is aan 'tumour dormancy', d.w.z. een tijdelijke rustfase,[13] met cellen die zich al verspreid hebben voorafgaand aan chirurgische behandeling. Goede herkenning van conjunctivale laesies tijdens het vervolgen van patiënten is daarom belangrijk voor optimale zorg. Belangrijk bij het beoordelen van conjunctivale laesies is dat clinici zich bewust moeten zijn van secundaire oorzaken van melanoom, aangezien de conjunctiva uitzaaiingen kan bevatten van elders gelokaliseerd melanoom.[14] We presenteren een patiënt met een conjunctivale laesie die een metastase bleek te zijn van een huidmelanoom (**hoofdstuk 6.1**). Deze patiënt is succesvol behandeld met nieuwe doelgerichte- en immunotherapie, wat tevens het belang van deze nieuwe behandelingen toont (hoofdstuk 3.1). Illustratief bij het gegeven dat niet elke gepigmenteerde laesie van de conjunctiva kwaadaardig is, was onze observatie bij een patiënt die eerder brachytherapie ontving voor UM en later twee gepigmenteerde plekjes op de sclera ontwikkelde, dit waren geen recidieven maar plekjes die pigment-bevattende macrofagen bevatten waarbij geen verdere behandeling nodig was (**hoofdstuk 6.4**).

CoM heeft de genetische achtergrond van een niet-oogheelkundig melanoom

Recent onderzoek laat zien dat CoM mutaties heeft in genen zoals *BRAF*, *NRAS*, *NF1* en *TERT*, en dat zeldzame mutaties kunnen optreden in *KIT* en andere genen.[15-19] Dit profiel lijkt erg op dat van huidmelanoom[20,21] en illustreert dat CoM als tumor *buiten* het oog gelegen is, en erg verschilt van uveamelanoom (met o.a. mutaties in *GNAQ/11* en *BAP1*) dat *binnen* het oog voorkomt.[22-24] Genetische mutaties laten zien dat ultraviolette (UV) straling vermoedelijk bijdraagt aan het ontstaan van CoM, met veel C>T veranderingen en een hoge mutatielast.[25-27] CoM kan echter zowel ontstaan in conjunctiva die blootstaat aan zonlicht als conjunctiva die bedekt is, wat impliceert dat UV geen noodzakelijke factor is voor de ontwikkeling van CoM.

Voorlopers van CoM, zoals nevi (moedervlekken) en primair verworven melanose (PAM),[28] tonen gelijksoortige mutaties als CoM, en hoewel de percentages van optreden verschillen, zijn geen volledig onderscheidende mutaties bekend.[17,29-32] Dit beperkt het gebruik van genetica om goedaardige van kwaadaardige laesies te onderscheiden, en laat zien dat sleutelmomenten in het ontstaan van CoM nog gevonden moeten worden. Mutaties kunnen echter gebruikt worden bij gepigmenteerde laesies om een onderscheid te maken tussen een oorsprong uit de conjunctiva en de uvea, wat relevant is bij specifieke gevallen waarbij UM door het oog groeit, of in gevallen met

een onbekende primaire laesie. Zeer recente studies tonen echter ook hiervan de betrekkelijkheid, omdat UM van het voorsegment eveneens *BRAF* mutaties kunnen bevatten,[33] en omdat CoM in zeldzame gevallen ook *BAP1* mutaties toont, een kenmerk van UM.[34]

De prognostische waarde van mutaties in CoM is momenteel beperkt door verschillende bevindingen in studies, en wordt tevens beperkt door kleine studiegroottes. Recent onderzoek toont dat *TERT* mutaties mogelijk samenhangen met het optreden van uitzaaiingen, en dat deze mutaties erg zeldzaam zijn bij goedaardige aandoeningen, waarmee dit mogelijk een belangrijke nieuwe factor wordt in de stadiering van CoM.[35] Een veelbelovende aanpak van genetische kenmerken van CoM is via micro-RNA (miRNA), wat - hoewel nog in de kinderschoenen - informatief kan zijn voor differentiatie en prognosticatie door vele genen tegelijkertijd te analyseren.[36-38]

Aanwezigheid van immuuncellen bij CoM remt tumorgroei, maar de celtypen moeten verder geïdentificeerd worden

In aanvulling op *genetica*, vormt *ontsteking* één van 'hoekstenen' van kanker en is als zodanig erkend als belangrijke factor voor ontwikkeling en gedrag van tumoren.[39] Tumorinfiltraat bij CoM bestaat uit verschillende celtypen, waaronder lymfocyten en macrofagen met verschillende functies. De aanwezigheid van immuuncellen is geassocieerd met een gunstige prognose bij CoM,[40-42] wat impliceert dat het immuunsysteem de tumorcellen aanpakt. Ook in dit aspect lijkt CoM op huidmelanoom, waarbij dit verschilt van UM waar ontsteking juist een teken is van maligniteit en slechtere uitkomst.[43]

De rol van macrofagen bij CoM is nog onduidelijk, maar aangezien deze cellen angiogenese kunnen bevorderen (met name de voornamelijk aanwezige M2-type macrofagen),[44] is het waarschijnlijk dat zij een ongunstig effect hebben op groei van CoM, zoals ook bekend is van huidmelanoom en UM.[45]

Een van de belangrijke regelmechanismen tussen het immuunsysteem en tumorcellen wordt gevormd door de PD-1/PD-L1 as.[46] Een cel die PD-L1 tot expressie brengt, remt een T cel die PD-1 op het oppervlak heeft. Tumorcellen maken hiervan gebruik om het immuunsysteem af te remmen. Wij toonden dat PD-L1 tot uiting komt op CoM en dat de expressie hiervan samenhangt met slechtere overleving zoals o.b.v. het mechanisme kan worden verondersteld (**hoofdstuk 3.2**). Dit komt overeen met bevindingen bij huidmelanoom.

Nieuwe beh andelingen voor CoM volgen uit genetica en immunologie

De bevindingen in tumorgenetica en immunologisch gedrag van CoM leiden tot 'doelgerichte therapie' en 'checkpoint inhibitor therapie', zoals recent al geïntroduceerd voor huidmelanoom. Nieuwe behandelingen zoals deze zijn erg nodig voor CoM waarbij conventionele behandeling niet

volstaat. Zover wij weten bestaan er geen klinische trials of grote series over dit onderwerp, maar kleine studies met CoM patiënten tonen een voordeel voor zowel lokaal uitgebreide CoM, als voor CoM met uitzaaiingen.

Doelgerichte therapie omvat *BRAF* en MEK remmers, en verschillende beschrijvingen zijn bekend waarbij CoM succesvol is behandeld (samengevat in **hoofdstuk 3.1**). In aanvulling hierop worden meerdere medicijnen momenteel in preklinische studies onderzocht (gericht tegen bijv. *KIT*, *TERT*, of EZH2).

Checkpoint inhibitors werken door de interactie tussen het immuunsysteem en de tumor, zoals eerder genoemd bij PD-1/PD-L1. Door het bestuderen van tumorweefsel en in vitro modellen, laten we de rationale zien voor gebruik van anti PD-1/PD-L1 medicijnen bij CoM (**hoofdstuk 3.2**). Enkele casus van patiënten die hiermee - meestal succesvol - behandeld zijn, zijn gerapporteerd in de literatuur (samengevat in **hoofdstuk 3.1**).

Nadelen bij nieuwe behandelingen voor CoM

Bij de nieuwgenoemde behandelingen moeten twee nadelen belicht worden: *resistentie* en *bijwerkingen*.[47-50] Tegen het eerste punt is mogelijk een combinatie van behandelingen nodig, die verschillende pathways tegelijkertijd aanpakt. Belangrijk daarbij is een genetische screening die een gepersonaliseerde aanpak mogelijk maakt die zorgt voor de beste aansluiting tussen patiënt en therapie. Bijwerkingen van de nieuwe behandelingen moeten in de gaten worden gehouden om de therapie aan te passen, of om de bijwerkingen zélf te behandelen. Aangezien immuun-gemedieerde bijwerkingen een relatief nieuw verschijnsel zijn in de geneeskunde, vraagt dit om bewustwording onder artsen. Belangrijk hierbij is dat immuun-gemedieerde bijwerkingen het oog kunnen aandoen terwijl de middelen systemisch gegeven worden, waarbij oogartsen zich bewust moeten zijn van deze bijwerkingen bij oncologische patiënten die behandeld worden met immuuntherapie voor niet-oogheelkundige maligniteiten.[51] Wij presenteren een casus van een patiënt die rosacea van het oog ontwikkelde na gebruik van checkpoint inhibitors ipilimumab en nivolumab, hetgeen goed behandeld kon worden met lokale steroïden (**hoofdstuk 6.2**).

Toekomstperspectieven

Huidige studies naar genetica en immunologie bij CoM laten zien dat er nog veel te leren is over tumorontwikkeling en gedrag. Tegelijkertijd tonen de huidige studies dat door deze kennis nieuwe behandelingen tot stand komen. Een betere karakterisering van CoM (gebaseerd op genetica, immunologie, en externe invloeden van melanine en UV straling) zullen betere prognosticering en gepersonaliseerde therapie mogelijk maken. In aanvulling op medicijnen tegen *BRAF* en MEK, en immunotherapie tegen PD-1 en CTLA4, worden nieuwe medicijnen tegen *Kit, NF1, TERT*, of *EZH2* binnenkort verwacht. Nieuwe medicijnen zullen vooral ten gunste komen van patiënten met uitzaaiingen, maar zijn mogelijk ook gunstig voor patiënten met vergevorderde lokale ziekte, als

alternatief voor uitgebreide chirurgie. Een secundair effect van de nieuwe behandelmogelijkheden is de relevantie van betere tumorstadiering. Naast stadiering gebaseerd op tumormateriaal, omvat dit het gebruik van lymfeklierstadiering door de schildwachtklier procedure[52] en beeldvorming.

Een veelbelovende ontwikkeling in oogoncologie is het besef dat CoM een aparte ziekte-entiteit is binnen het oogmelanoom, en dat dit wereldwijd beter beseft wordt. Vroege verwijzing naar tertiaire centra dient de standaard te worden, net als het gebruik van gepaste adjuvante behandeling. Naast een direct voordeel voor huidige patiënten die de beste therapie kunnen ontvangen, maakt dit ook beter onderzoek mogelijk met grotere aantallen, wat ten goede komt aan toekomstige patiënten.

DEEL II – UVEAMELANOOM

Samenvatting en discussie

UM is de meest voorkomende soort oogmelanoom met een incidentie van 5.1-8.6 per miljoen in een blanke bevolking.[53,54] Het omvat melanoom van de choroidea (vaatvlies), corpus ciliare (straalvormig lichaam) en iris (regenboogvlies). Tot wel 50% van de patiënten overlijdt aan uitzaaiingen,[55] wat stabiel is gebleven in de afgelopen vijf decennia.[56] Vele concepten en behandelingen die van toepassing zijn op andere typen melanoom zijn niet effectief bij UM door de specifieke genetische achtergrond en immuun-geprivilegieerde positie in het oog.[57] Het maken van een onderscheid tussen goedaardige en kwaadaardige laesies van de uvea kan lastig zijn, hoewel de eerste onschuldig zijn en er een grote behoefte is aan betere behandelingen van de laatste.

In dit deel van het proefschrift beschrijven we eerst het genetische en immunologische profiel van UM, dat erg verschilt van huidmelanoom en CoM (**hoofdstuk 3.1**). We gaan dieper in op activatie van het aan groei gerelateerde YAP1-pathway als mogelijke voorspeller van uitzaaiingen en als mogelijk behandeldoel van UM (**hoofdstuk 4.1**). Hierna bestuderen we angiogenese als belangrijke factor in het gedrag van UM en als link tussen tumorgenetica en klinische uitkomst (**hoofdstuk 4.2**). Met nieuwe beeldvormingstechnieken bij patiënten bestuderen we vasculatuur in zowel conjunctivale als uveale laesies om een onderscheid te maken tussen goedaardige en kwaadaardige ziekte (**hoofdstukken 5.1, 5.2**).

De genetische en immunologische achtergrond van UM verschilt van huidmelanoom en CoM

UM heeft een opmerkelijk genetisch profiel en immunologische achtergrond, dat erg afwijkt van wat gezien wordt bij huidmelanoom en CoM (**hoofdstuk 3.1**). UM wordt getypeerd door vroege mutaties in *GNAQ/11*, en latere mutaties in *BAP1*, *EIF1AX* en *SF3B1*.[57] Er is geen rol voor UV straling bij het ontstaan van UM in het *achtersegment*, hoewel nieuwe inzichten laten zien dat UM in het *voorsegment* sporadisch een typische UV signatuur toont.[58] De aanwezigheid van immuun infiltraat is ongunstig bij UM, wat impliceert dat immuuncellen er niet in slagen tumorcellen te

vernietigen; een mogelijke verklaring volgt uit de expressie van immuunremmers zoals *Indoleamine 2,3-dioxygenase* (IDO1) en *T cell immunoreceptor with Ig and ITIM domains* (TIGIT), wat immuunresponsen beperkt.[59] Nieuw geïntroduceerde doelgerichte- en immuuntherapie zijn momenteel niet succesvol bij UM, wat wederom wordt toegeschreven aan een andere immuunrespons vergeleken met wat wordt gezien bij (buiten het oog gelegen) CoM en huidmelanoom.[60]

Het YAP1-pathway is betrokken bij tumorgroei en biedt een nieuwe benadering voor behandeling van UM

Celgroei wordt gereguleerd door verschillende stimuli, waaronder de YAP1-pathway.[61] Interessant is dat YAP1 geactiveerd wordt door de *GNAQ/11* mutatie die meestal al vroeg optreedt bij UM.[62,63] De YAP1-pathway is onlangs in de belangstelling komen te staan als mogelijk doel voor behandeling; het kan geremd worden door het reeds bestaande medicijn *verteporfine*.[64]

In **hoofdstuk 4.1** bestudeerden wij de YAP1-pathway in zowel UM als CoM. We toonden dat YAP1 expressie hoger is bij UM met een ongunstig genetisch profiel en mogelijk geassocieerd is met een ongunstige klinische uitkomst. In vitro werk met verteporfine toonde een respons in meerdere UM cellijnen, maar slechts een beperkte respons bij CoM cellijnen en (traag groeiende) BAP1-negatieve UM cellijnen, wat toont dat niet alleen de onderzochte genetische achtergrond maar ook eigenschappen zoals snelheid van celgroei bepalend zijn voor medicijngevoeligheid. Hoewel verteporfine vermoedelijk niet het meest geschikt is als losstaand medicijn bij UM, is het aanpakken van de YAP1-pathyway mogelijk wel geschikt als *onderdeel* van een behandeling tegen UM en geschikt om resistentie tegen andere middelen te overwinnen.

Angiogenese is gerelateerd aan tumorgenetica en ongunstige klinische uitkomst bij UM

Angiogenese is belangrijk voor het ontwikkelen van en het gedrag van UM.[45,65] Vaten brengen voedingsstoffen en zuurstof naar een tumor, en vormen een route voor cellen om uit te zaaien. Angiogenese wordt beïnvloed door het tumormilieu aangezien immuuncellen cytokines kunnen produceren die ontsteking en vaatgroei stimuleren. Recent werd gevonden dat genetische veranderingen bij UM samenhangen met de aanwezigheid van immuuncellen[66] en daarom vroegen wij ons af of genetische veranderingen eveneens samenhangen met (markers van) angiogenese.

In **hoofdstuk 4.2** toonden we aan dat vaatdichtheid gerelateerd is aan het genetische profiel, met een toegenomen vaatdichtheid bij UM met het prognostisch slechte monosomie 3 / verlies van BAP1 eiwit expressie. De status van chromosoom 8q (waarbij het optreden van extra kopieën een vroege gebeurtenis is)[67] was niet gerelateerd aan vaatdichtheid, wat erop wijst dat werkelijke angiogenese een latere gebeurtenis is. Toegenomen vaatdichtheid was geassocieerd met expressie van meerdere factoren zoals ANGPT2, VWF en opmerkelijk genoeg minder VEGF-B (in tegenstelling tot het beter bekende VEGF-A). Een sleutelregulator van angiogenese is *Hypoxia Inducible Factor 1a* (HIF1a).[68] Medicijnen tegen HIF1a worden momenteel onderzocht bij UM[69] en wij vroegen ons

daarom af welke patiënten hiervan de meeste baat kunnen hebben. Wij toonden dat hogere expressie van HIF1a gezien wordt bij BAP1-verlies in UM. Dit geeft informatie over de ontwikkeling van UM en doet de suggestie dat tumoren met monosomie 3 / verlies van BAP1 de beste kandidaten zijn voor HIF1a therapie.[70]

Klinische zuurstofwaarden in de retina verschillen tussen choroidea melanomen en nevi

Tumorvaten worden momenteel al geanalyseerd in de klinische praktijk om een onderscheid te maken tussen goedaardige en kwaadaardige oogheelkundige laesies. Dit kan middels fluorescentie angiografie, waarbij kleurstof in de bloedvaten wordt ingespoten en vaatpatronen en lekkage van het oog worden onderzocht.[71,72] Een nadeel van deze techniek is de invasieve aard en een beperkt gebruik bij laesies van het voorsegment, met name omdat de kleurstof erg snel lekt uit conjunctivale vaten.[73] Omdat delende tumorcellen een toegenomen metabolisme hebben, onderzochten we zuurstofwaarden van retinale vaten in ogen met een choroidea melanoom of naevus met een relatief nieuwe beeldvormende techniek (Oxymap T1) (**hoofdstuk 5.1**). Hoewel ogen met een choroidea naevus geen veranderingen lieten zien, vonden we afwijkende zuurstofwaarden in ogen met een choroidea melanoom, waaronder in de retina die niet over de tumor gelegen is. Deze veranderingen wijzen op afwijkend zuurstof metabolisme, ontsteking en herverdeling van bloedstroom in UM-ogen. Als diagnostische techniek zijn andere technieken momenteel meer specifiek, maar retinale oxymetrie voegt informatie toe aan deze gegevens en kan gebruikt worden bij het vervolgen van behandelings-gerelateerde (bestralings-) effecten.

OCT-Angiografie is mogelijk bij CoM en UM van het voorsegment, maar momenteel beperkt door de beeldvormende techniek en software

Een nieuwe niet-invasieve beeldvormende techniek om vaten van het oog af te beelden is OCT-Angiografie (OCTA). Hoewel ontwikkeld voor retinale vaten,[74] pasten we deze techniek toe op het voorsegment met als doel om tumorvaten in de iris en conjunctiva af te beelden (**hoofdstuk 5.2**). We toonden dat vaten kunnen worden afgebeeld, maar dat het verkrijgen van een goed beeld sterk afhangt van eigenschappen van de patiënt en tumor, zoals goede medewerking en tumorpigmentatie. Bij zowel nevi als melanomen vonden we kronkelige vaatpatronen, afwijkend van gezonde iris en conjunctiva. We vonden geen verschil in vaatdichtheid tussen goedaardige of kwaadaardige laesies. Dit werd echter mogelijk beperkt door lage aantallen en de genoemde beperkingen van de huidige beeldvormende technieken.

Toekomstperspectieven

De zoektocht naar behandelingen voor (uitgezaaide) UM gaat door. Het remmen van meerdere pathways tegelijkertijd kan problemen met huidige medicijnen overwinnen, en het aanpakken van de YAP1-pathway is een veelbelovend aspect als onderdeel van behandeling voor UM. Verteporfine, als reeds bestaand oogheelkundig medicijn, kan mogelijk ook op andere wijze gebruikt worden zoals

tumorgroei te vertragen in afwachting van (bestralings)therapie. Het immuun privilege van het oog, en intraoculaire en uitgezaaide UM, vragen om beter begrip zodat mogelijk ook de medicijnen geïntroduceerd kunnen worden die eerder de behandeling van huidmelanoom, en CoM, zo drastisch hebben verbeterd.

Nieuwe beeldvormingstechnieken zijn veelbelovend om ooglaesies niet-invasief te diagnosticeren. Voor het bestuderen van tumorvaten zijn een betere beeldresolutie en analyse software nodig om artefacten door tumorpigmentatie en laesie dikte te verhelpen. Oxymetrie van retinale vaten is mogelijk niet een toevoeging voor *diagnostiek*, maar wel een kandidaat om de *behandelreactie* te monitoren, in combinatie met structurele beeldvorming middels OCTA. Die laatste techniek kan minimale vaatafwijkingen in UM ogen tonen, en kan uitgebreid toegepast worden bij studies naar bestralingsretinopathie, wat tegenwoordig beter behandeld wordt met de introductie van vaatgroeiremmende (anti-VEGF) therapie.

REFERENTIES

1. Tuomaala S, Eskelin S, Tarkkanen A, Kivela T. Population-based assessment of clinical characteristics predicting outcome of conjunctival melanoma in whites. *Invest Ophthalmol Vis Sci.* 2002;43(11):3399-3408.
2. Yu GP, Hu DN, McCormick S, Finger PT. Conjunctival melanoma: is it increasing in the United States? *Am J Ophthalmol.* 2003;135(6):800-806.
3. Triay E, Bergman L, Nilsson B, All-Ericsson C, Seregard S. Time trends in the incidence of conjunctival melanoma in Sweden. *Br J Ophthalmol.* 2009;93(11):1524-1528.
4. Missotten GS, Keijser S, De Keizer RJ, De Wolff-Rouendaal D. Conjunctival melanoma in the Netherlands: a nationwide study. *Invest Ophthalmol Vis Sci.* 2005;46(1):75-82.
5. Shields CL, Markowitz JS, Belinsky I, et al. Conjunctival melanoma: outcomes based on tumor origin in 382 consecutive cases. *Ophthalmology.* 2011;118(2):389-395 e381-382.
6. Tuomaala S, Kivela T. Metastatic pattern and survival in disseminated conjunctival melanoma: implications for sentinel lymph node biopsy. *Ophthalmology.* 2004;111(4):816-821.
7. Shields CL. Conjunctival melanoma: risk factors for recurrence, exenteration, metastasis, and death in 150 consecutive patients. *Trans Am Ophthalmol Soc.* 2000;98:471-492.
8. Wong JR, Nanji AA, Galor A, Karp CL. Management of conjunctival malignant melanoma: a review and update. *Expert Rev Ophthalmol.* 2014;9(3):185-204.
9. Vora GK, Demirci H, Marr B, Mruthyunjaya P. Advances in the management of conjunctival melanoma. *Surv Ophthalmol.* 2016.
10. Brouwer NJ, Marinkovic M, Peters FP, et al. Management of conjunctival melanoma with local excision and adjuvant brachytherapy. *Eye (Lond).* 2021;35(2):490-498.
11. Slominski RM, Zmijewski MA, Slominski AT. The role of melanin pigment in melanoma. *Exp Dermatol.* 2015;24(4):258-259.
12. Ito S, Wakamatsu K. Quantitative analysis of eumelanin and pheomelanin in humans, mice, and other animals: a comparative review. *Pigment Cell Res.* 2003;16(5):523-531.
13. Ossowski L, Aguirre-Ghiso JA. Dormancy of metastatic melanoma. *Pigment Cell Melanoma Res.* 2010;23(1):41-56.
14. Kiratli H, Shields CL, Shields JA, DePotter P. Metastatic tumours to the conjunctiva: report of 10 cases. *Br J Ophthalmol.* 1996;80(1):5-8.
15. Griewank KG, Westekemper H, Murali R, et al. Conjunctival melanomas harbor BRAF and NRAS mutations and copy number changes similar to cutaneous and mucosal melanomas. *Clin Cancer Res.* 2013;19(12):3143-3152.
16. Griewank KG, Murali R, Schilling B, et al. TERT promoter mutations in ocular melanoma distinguish between conjunctival and uveal tumours. *Br J Cancer.* 2013;109(2):497-501.
17. Koopmans AE, Ober K, Dubbink HJ, et al. Prevalence and implications of TERT promoter mutation in uveal and conjunctival melanoma and in benign and premalignant conjunctival melanocytic lesions. *Invest Ophthalmol Vis Sci.* 2014;55(9):6024-6030.
18. Scholz SL, Cosgarea I, Susskind D, et al. NF1 mutations in conjunctival melanoma. *Br J Cancer.* 2018;118(9):1243-1247.
19. Sheng X, Li S, Chi Z, et al. Prognostic factors for conjunctival melanoma: a study in ethnic Chinese patients. *Br J Ophthalmol.* 2015;99(7):990-996.
20. Krauthammer M, Kong Y, Bacchiocchi A, et al. Exome sequencing identifies recurrent mutations in NF1 and RASopathy genes in sun-exposed melanomas. *Nat Genet.* 2015;47(9):996-1002.

21. Curtin JA, Fridlyand J, Kageshita T, et al. Distinct sets of genetic alterations in melanoma. *N Engl J Med.* 2005;353(20):2135-2147.
22. Van Raamsdonk CD, Bezrookove V, Green G, et al. Frequent somatic mutations of GNAQ in uveal melanoma and blue naevi. *Nature.* 2009;457(7229):599-602.
23. Van Raamsdonk CD, Griewank KG, Crosby MB, et al. Mutations in GNA11 in uveal melanoma. *N Engl J Med.* 2010;363(23):2191-2199.
24. Koopmans AE, Verdijk RM, Brouwer RW, et al. Clinical significance of immunohistochemistry for detection of BAP1 mutations in uveal melanoma. *Mod Pathol.* 2014;27(10):1321-1330.
25. Rivolta C, Royer-Bertrand B, Rimoldi D, et al. UV light signature in conjunctival melanoma; not only skin should be protected from solar radiation. *J Hum Genet.* 2016;61(4):361-362.
26. Swaminathan SS, Field MG, Sant D, et al. Molecular Characteristics of Conjunctival Melanoma Using Whole-Exome Sequencing. *JAMA Ophthalmol.* 2017;135(12):1434-1437.
27. Cisarova K, Folcher M, El Zaoui I, et al. Genomic and transcriptomic landscape of conjunctival melanoma. *PLoS Genet.* 2020;16(12):e1009201.
28. Jakobiec FA. Naming the Precursors of Conjunctival Melanoma. *Am J Ophthalmol.* 2016;164:152-153.
29. Goldenberg-Cohen N, Cohen Y, Rosenbaum E, et al. T1799A BRAF mutations in conjunctival melanocytic lesions. *Invest Ophthalmol Vis Sci.* 2005;46(9):3027-3030.
30. Francis JH, Grossniklaus HE, Habib LA, et al. BRAF, NRAS, and GNAQ Mutations in Conjunctival Melanocytic Nevi. *Invest Ophthalmol Vis Sci.* 2018;59(1):117-121.
31. Dratviman-Storobinsky O, Cohen Y, Frenkel S, Pe'er J, Goldenberg-Cohen N. Lack of oncogenic GNAQ mutations in melanocytic lesions of the conjunctiva as compared to uveal melanoma. *Invest Ophthalmol Vis Sci.* 2010;51(12):6180-6182.
32. Alessandrini L, Parrozzani R, Bertorelle R, et al. C-Kit SCF receptor (CD117) expression and KIT gene mutation in conjunctival pigmented lesions. *Acta Ophthalmol.* 2013;91(8):e641-645.
33. van Poppelen NM, Vaarwater J, Mudhar HS, et al. Genetic Background of Iris Melanomas and Iris Melanocytic Tumors of Uncertain Malignant Potential. *Ophthalmology.* 2018;125(6):904-912.
34. van Poppelen NM, van Ipenburg JA, van den Bosch Q, et al. Molecular Genetics of Conjunctival Melanoma and Prognostic Value of TERT Promoter Mutation Analysis. *Int J Mol Sci.* 2021;22(11).
35. van Ipenburg JA, Naus NC, Dubbink HJ, et al. Prognostic value of TERT promoter mutations in conjunctival melanomas in addition to clinicopathological features. *Br J Ophthalmol.* 2020:[Online ahead of print].
36. Larsen AC, Mikkelsen LH, Borup R, et al. MicroRNA Expression Profile in Conjunctival Melanoma. *Invest Ophthalmol Vis Sci.* 2016;57(10):4205-4212.
37. Mikkelsen LH, Andersen MK, Andreasen S, et al. Global microRNA profiling of metastatic conjunctival melanoma. *Melanoma Res.* 2019;29(5):465-473.
38. van Ipenburg JA, Gillis Ing AJM, Dorssers LCJ, et al. MicroRNA Profiling in Benign and Malignant Conjunctival Melanocytic Lesions. *Ophthalmology.* 2020;127(3):432-434.
39. Hanahan D, Weinberg RA. Hallmarks of cancer: the next generation. *Cell.* 2011;144(5):646-674.
40. Bobic-Radovanovic A, Latkovic Z, Marinkovic J, Radovanovic Z. Predictors of survival in malignant melanoma of the conjunctiva: a clinico-pathological and follow-up study. *Eur J Ophthalmol.* 1998;8(1):4-7.
41. Crawford JB. Conjunctival melanomas: prognostic factors a review and an analysis of a series. *Trans Am Ophthalmol Soc.* 1980;78:467-502.
42. Folberg R, McLean IW, Zimmerman LE. Malignant melanoma of the conjunctiva. *Hum Pathol.* 1985;16(2):136-143.
43. Bronkhorst IH, Jager MJ. Inflammation in uveal melanoma. *Eye (Lond).* 2013;27(2):217-223.

44. Mantovani A, Sozzani S, Locati M, Allavena P, Sica A. Macrophage polarization: tumor-associated macrophages as a paradigm for polarized M2 mononuclear phagocytes. *Trends Immunol.* 2002;23(11):549-555.
45. Bronkhorst IH, Ly LV, Jordanova ES, et al. Detection of M2-macrophages in uveal melanoma and relation with survival. *Invest Ophthalmol Vis Sci.* 2011;52(2):643-650.
46. Okazaki T, Honjo T. PD-1 and PD-1 ligands: from discovery to clinical application. *Int Immunol.* 2007;19(7):813-824.
47. Ascierto PA, McArthur GA, Dréno B, et al. Cobimetinib combined with vemurafenib in advanced BRAF(V600)-mutant melanoma (coBRIM): updated efficacy results from a randomised, double-blind, phase 3 trial. *Lancet Oncol.* 2016;17(9):1248-1260.
48. Long GV, Stroyakovskiy D, Gogas H, et al. Combined BRAF and MEK inhibition versus BRAF inhibition alone in melanoma. *N Engl J Med.* 2014;371(20):1877-1888.
49. Robert C, Schachter J, Long GV, et al. Pembrolizumab versus Ipilimumab in Advanced Melanoma. *N Engl J Med.* 2015;372(26):2521-2532.
50. Hodi FS, Chiarion-Sileni V, Gonzalez R, et al. Nivolumab plus ipilimumab or nivolumab alone versus ipilimumab alone in advanced melanoma (CheckMate 067): 4-year outcomes of a multicentre, randomised, phase 3 trial. *Lancet Oncol.* 2018;19(11):1480-1492.
51. Dalvin LA, Shields CL, Orloff M, Sato T, Shields JA. CHECKPOINT INHIBITOR IMMUNE THERAPY: Systemic Indications and Ophthalmic Side Effects. *Retina.* 2018;38(6):1063-1078.
52. Esmaeli B, Rubin ML, Xu S, et al. Greater Tumor Thickness, Ulceration, and Positive Sentinel Lymph Node Are Associated With Worse Prognosis in Patients With Conjunctival Melanoma: Implications for Future AJCC Classifications. *Am J Surg Pathol.* 2019;43(12):1701-1710.
53. Singh AD, Turell ME, Topham AK. Uveal melanoma: trends in incidence, treatment, and survival. *Ophthalmology.* 2011;118(9):1881-1885.
54. Virgili G, Gatta G, Ciccolallo L, et al. Incidence of uveal melanoma in Europe. *Ophthalmology.* 2007;114(12):2309-2315.
55. Damato B. Progress in the management of patients with uveal melanoma. The 2012 Ashton Lecture. *Eye (Lond).* 2012;26(9):1157-1172.
56. Roelofsen CDM, Wierenga APA, van Duinen S, et al. Five Decades of Enucleations for Uveal Melanoma in One Center: More Tumors with High Risk Factors, No Improvement in Survival over Time. *Ocul Oncol Pathol.* 2021;7(2):133-141.
57. Jager MJ, Shields CL, Cebulla CM, et al. Uveal melanoma. *Nat Rev Dis Primers.* 2020;6(1):24.
58. Johansson PA, Brooks K, Newell F, et al. Whole genome landscapes of uveal melanoma show an ultraviolet radiation signature in iris tumours. *Nat Commun.* 2020;11(1):2408.
59. Robertson AG, Shih J, Yau C, et al. Integrative Analysis Identifies Four Molecular and Clinical Subsets in Uveal Melanoma. *Cancer Cell.* 2017;32(2):204-220 e215.
60. Heppt MV, Steeb T, Schlager JG, et al. Immune checkpoint blockade for unresectable or metastatic uveal melanoma: A systematic review. *Cancer Treat Rev.* 2017;60:44-52.
61. Moroishi T, Hansen CG, Guan KL. The emerging roles of YAP and TAZ in cancer. *Nat Rev Cancer.* 2015;15(2):73-79.
62. Yu FX, Luo J, Mo JS, et al. Mutant Gq/11 promote uveal melanoma tumorigenesis by activating YAP. *Cancer Cell.* 2014;25(6):822-830.
63. Feng X, Degese MS, Iglesias-Bartolome R, et al. Hippo-independent activation of YAP by the GNAQ uveal melanoma oncogene through a trio-regulated rho GTPase signaling circuitry. *Cancer Cell.* 2014;25(6):831-845.
64. Liu-Chittenden Y, Huang B, Shim JS, et al. Genetic and pharmacological disruption of the TEAD-YAP complex suppresses the oncogenic activity of YAP. *Genes Dev.* 2012;26(12):1300-1305.

65. Makitie T, Summanen P, Tarkkanen A, Kivela T. Microvascular density in predicting survival of patients with choroidal and ciliary body melanoma. *Invest Ophthalmol Vis Sci.* 1999;40(11):2471-2480.
66. Gezgin G, Dogrusöz M, van Essen TH, et al. Genetic evolution of uveal melanoma guides the development of an inflammatory microenvironment. *Cancer Immunol Immunother.* 2017;66(7):903-912.
67. Singh N, Singh AD, Hide W. Inferring an Evolutionary Tree of Uveal Melanoma From Genomic Copy Number Aberrations. *Invest Ophthalmol Vis Sci.* 2015;56(11):6801-6809.
68. Rankin EB, Giaccia AJ. The role of hypoxia-inducible factors in tumorigenesis. *Cell Death Differ.* 2008;15(4):678-685.
69. Dong L, You S, Zhang Q, et al. Arylsulfonamide 64B Inhibits Hypoxia/HIF-Induced Expression of c-Met and CXCR4 and Reduces Primary Tumor Growth and Metastasis of Uveal Melanoma. *Clin Cancer Res.* 2019;25(7):2206-2218.
70. Brouwer NJ, Wierenga APA, Gezgin G, et al. Ischemia Is Related to Tumour Genetics in Uveal Melanoma. *Cancers (Basel).* 2019;11(7).
71. Bakri SJ, Sculley L, Singh AD. Diagnostic techniques. In: Singh AD, Damato BE, Pe'er J, Murphree AL, Perry JD, eds. *Clinical Ophthalmic Oncology*. Edinburgh, UK: Elsevier-Saunders; 2007:175-180.
72. Oosterhuis JA, van Waveren CW. Fluorescein photography in malignant melanoma. *Ophthalmologica.* 1968;156(2):101-116.
73. Meyer PA, Watson PG. Low dose fluorescein angiography of the conjunctiva and episclera. *Br J Ophthalmol.* 1987;71(1):2-10.
74. Spaide RF, Klancnik JM, Jr., Cooney MJ. Retinal vascular layers imaged by fluorescein angiography and optical coherence tomography angiography. *JAMA Ophthalmol.* 2015;133(1):45-50.

CHAPTER 8.2 - ACKNOWLEDGEMENTS

Met bijzonder veel plezier kijk ik op mijn promotietijd terug. Graag wil ik enkele mensen speciaal noemen in dit (beknopte) dankwoord.

Geachte professor Jager, beste Martine. Zoveel passie en enthousiasme voor wetenschap kom je zelden tegen. Vanaf de start heb je mij begeleid als student en onderzoeker. Je oneindige ideeën, het tempo waarin je teksten van feedback voorziet, en je internationale blik waarmee je mensen stimuleert om over de grens te kijken: ik zou het nooit hebben willen missen, en sluit aan in een lange rij van mensen die je hiervoor dankbaar is.

Geachte professor Luyten, beste Gré. Als afdelingshoofd en stafarts op het melanoomspreekuur was jouw schakel naar de kliniek onontbeerlijk in vele projecten. Je hebt het mogelijk gemaakt dat veel projecten konden plaatsvinden, en ik een grote vrijheid genoot. Ik dank je voor dit vertrouwen.

Geachte drs. Marinkovic, beste Marina. Wekelijks kwam ik bij je langs om de lopende projecten te bespreken. Jouw kennis van (en passie voor) de patiëntenzorg maakte dat ik ook echt begreep wat een oogmelanoom is. Je enthousiasmeerde me om ook de krenten uit de pap te vissen in een promotietijd. Ik waardeer je inzet enorm.

Vele clinici waren betrokken bij mijn projecten. De (overige) oncoloog-oogartsen: drs. Bleeker, dr. Vu, drs. Van der Meeren, drs. Koetsier, dank voor de zorg voor de patiënten op wie dit werk gebaseerd is. De pathologen: dr. Van Duinen, dr. Verdijk, dank voor het (her)beoordelen van vele coupes en de uitleg daarbij. De radiotherapie, radiologie en medische oncologie, dank voor alle samenwerking. De ondersteuners op de poli, fotografen, en in het bijzonder Katinka Emmanouillidis-van der Spek, dank voor jullie steun.

Veel plezier heb ik gehaald uit de projecten met het oogheelkundig laboratorium. Dr. Mieke Versluis, dank voor alle uitleg en de spoedcursus voordat ik zelf in het diepe mocht. Dr. Jinfeng Cao, thank you for the great collaborations. Dr. Van der Velden, dank voor de nieuwe inzichten. Rogier, Zahra, Maria, Sen, Mehmet, Gülçin, you were all great and fun colleagues.

The international collaborations were a most pleasant experience during my PhD. It was an honour to collaborate with professors Carol Shields, Einar Stefansson, Bita Esmaeli, and Steffen Heegaard. The UMCURE consortium deserves a warm notice for its great research and wonderful meetings with amazing people.

Some of the best months of my PhD were spent in Boston, where I gratefully worked at the Harvard Ophthalmology Department of professor Gragoudas. Thank you so much Dr. Kim and Dr. Lane, for having me over. Prof. Vavvas, you are an amazingly energetic person, thanks for showing me around the clinic and supervising me with proper lab work.

Huisgenoten van Marion Street, jullie hebben de tijd in Boston compleet gemaakt: Veerle, Anouk, Theun, Tom, Charles, Alexander, Karst en anderen, ik ben blij dat we elkaar ook in Nederland treffen.

Mijn directe collega's ben ik veel dank verschuldigd. Thomas, de gehele promotie-rit deelde ik met jou een werkkamer. Naast inhoudelijk overleg ging het ook uren over niks, en gaf je mij een nuchtere kijk als ik weer eens ergens veel te moeilijk over deed. Ik koester de vriendschap, kijk uit naar nog vele fietstochten, en waardeer het dat je paranimf bent. Annemijn (Wierenga), jij was mijn gids voor zoveel op het lab, en sprong bij als het mij te moeilijk werd. Dank voor alle uitleg en de gesprekken waarin dit vaak uitliep. Ik ben blij dat je paranimf bent. Cindy, naast wetenschapper ook altijd enthousiast en sociaal, jij hielp me meermaals (hardhandig) over angsten heen. Vincent, Kasia, Danial, Mays, Leo, Thanh, Joost, Luc, Melissa, Annemijn (ten Voorde), dank voor de belevenissen op de kamers als student of onderzoeker. Elon, dank voor de hulp en bekommering in de PhD-tijd en daarna. Clair, Juleke, Lisette en Robin, een dankbare bijvangst van de connecties met Rotterdam.

Vrienden van AHC Ravage, dank voor alle afleiding en discussievaardigheid. Ramzi, Lisa, Maartje, Patrick, het is mij veel waard dat we al zoveel jaren verbonden zijn.

Een bijzondere dank is voor de Honours Academy van de Universiteit Leiden. Het *Pre-University*, *Honours College* en *MD/PhD traject:* er vroeg bij zijn heeft geloond.

De afronding van dit werk mocht plaatsvinden naast mijn opleiding tot oogarts. Professor Nicoline Schalij-Delfos, als opleider, dank voor het faciliteren hiervan en het vertrouwen dat ik nu in de opleiding geniet. Dank aan mijn mede arts-assistenten voor de steun als ik (weer) aan de wetenschap ging.

Familie verdient een bijzondere plek in dit dankwoord. Mama, dank voor je oneindige zorg en interesse. Papa, ik kon graag met je over geneeskunde praten, het bedroeft me dat je dit moment moet missen. Opa en oma, die mij al jong stimuleerden voor wetenschap en creativiteit. Pake en Beppe, waarmee meerdere dokters Brouwer volgden. Margit, je hebt een bijzondere plaats in de herinneringen aan Wiebe. Mijn zus(je) Rixt, de belangrijkste steun op zware momenten tijdens dit traject. Alex en Bastiaan, jullie boffen maar.

CHAPTER 8.3 - CURRICULUM VITAE

Niels Brouwer was born on December 30th, 1990, in The Hague, The Netherlands. During high school at the Gymnasium Haganum (The Hague), he participated in the Pre-University College of Leiden University. He started to study Medicine in 2009 at Leiden University. He was selected for the Honours Program, and took part in a research project at the Department of Cardiology of the Leiden University Medical Center (LUMC). Following several committees on student activities and education, he joined the Board of the medical students association '*Medische Faculteit der Leidse Studenten*' (M.F.L.S.).

During the final year of his Medicine study (2016), Niels Brouwer started with a research project on conjunctival melanoma at the Department of Ophthalmology of the LUMC. After being awarded a MD/PhD programme grant from the Board of Directors of the LUMC, this expanded into a PhD track aiming at conjunctival as well as uveal melanoma under the supervision of prof. dr. M.J. Jager and prof. dr. G.P.M. Luyten, with daily supervision by drs. M. Marinkovic.

During his PhD time, Niels Brouwer presented at several (international) conferences and was awarded an *ARVO* travel grant in 2019, and a best oral presentation award at the *DOPS* conference 2020. During the final stage of his PhD track, he took up a research project at the Massachusetts Eye and Ear Infirmary (Harvard Medical School) in Boston, USA, under the supervision of prof. dr. D.G. Vavvas. In August 2020, he started his training as resident in Ophthalmology at the LUMC, under the supervision of prof. dr. N.E. Schalij-Delfos.

CHAPTER 8.4 - LIST OF PUBLICATIONS

1. Wierenga AP, **Brouwer NJ**, Gelmi MC, Verdijk RM, Stern MH, Bas Z, Malkani K, van Duinen SG, Ganguly A, Kroes WGM, Marinkovic M, Luyten GPM, Shields CL, Jager MJ. **Chromosome 3 and 8q aberrations in Uveal Melanoma show greater impact on survival in patients with light iris versus dark iris color.**
   Ophthalmology 2021;S0161-6420(21)00867-8 [Online ahead of print]

2. **Brouwer NJ**, Verdijk RM, Heegaard S, Marinkovic M, Esmaeli B, Jager MJ. **Conjunctival melanoma: New insights in tumour genetics and immunology, leading to new therapeutic options.**
   Prog Retin Eye Res 2022;86:100971.

3. **Brouwer NJ**, Konstantinou EK, Gragoudas ES, Marinkovic M, Luyten GPM, Kim IK, Jager MJ, Vavvas DG. **Targeting the YAP/TAZ pathway in uveal and conjunctival melanoma with verteporfin.**
   Invest Ophthalmol Vis Sci 2021;62(4):3.

4. **Brouwer NJ**, Marinkovic M, Bleeker JC, Luyten GPM, Jager MJ**. Anterior segment OCTA of melanocytic lesions of the conjunctiva and iris.**
   Am J Ophthalmol 2021;222:137-147.

5. **Brouwer NJ*,** Marinkovic M*, Peters FP, Hulshof M, Pieters BR, de Keizer RJW, Horeweg N, Laman MS, Bleeker JC, van Duinen SG, Jager MJ, Creutzberg CL, Luyten GPM. **Management of conjunctival melanoma with local excision and adjuvant brachytherapy.**
   Eye (Lond) 2021;35(2):490-498.

6. Dogrusoz M, **Brouwer NJ**, de Geus SJR, Ly LV, Bohringer S, van Duinen SG, Kroes WGM, van der Velden PA, Haasnoot GW, Marinkovic M, Luyten GPM, Kivela TT, Jager MJ. **Prognostic factors five years after enucleation for uveal melanoma.**
   Invest Ophthalmol Vis Sci 2020;61(3):31

7. Boudry C, Alvarez-Munoz P, Arencibia-Jorge R, Ayena D, **Brouwer NJ**, Chaudhuri Z, Chawner B, Epee E, Errais K, Fotouhi A, Gharaibeh AM, Hassanein DH, Herwig-Carl MC, Howard K, Kaimbo Wa Kaimbo D, Laughrea PA, Lopez FA, Machin-Mastromatteo JD, Malerbi FK, Ndiaye PA, Noor NA, Pacheco-Mendoza J, Papastefanou VP, Shah M, Shields CL, Wang YX, Yartsev V, Mouriaux F. **Worldwide inequality in access to full text scientific articles: the example of ophthalmology.**
   PeerJ. 2019;7:e7850. doi: 10.7717/peerj.7850. eCollection 2019.

8. Wierenga APA, Gezgin G, van Beelen E, Eikmans M, Spruyt-Gerritse M, **Brouwer NJ**, Versluis M, Verdijk RM, van Duinen SG, Marinkovic M, Luyten GPM, Jager MJ. **Soluble HLA in the aqueous humour of uveal melanoma is associated with unfavourable tumour characteristics.**
Cancers (Basel) 2019;11(8). pii: E1202.

9. **Brouwer NJ,** Marinkovic M, Bleeker JC, el Filali M, Stefansson E, Luyten GPM, Jager MJ. **Retinal oximetry is altered in eyes with choroidal melanoma, but not in eyes with choroidal nevi.**
Retina 2020;40(11):2207-2215.

10. **Brouwer NJ,** Gezgin G, Wierenga APA, Bronkhorst IHG, Marinkovic M, Luyten GPM, Versluis M, Kroes WGM, van der Velden PA, Verdijk RM, Jager MJ. **Tumour angiogenesis in uveal melanoma is related to genetic evolution.**
Cancers (Basel) 2019;11(7). Pii: E979

11. **Brouwer NJ,** Wierenga APA, Gezgin G, Marinkovic M, Luyten GPM, Kroes WGM, Versluis M, van der Velden PA, Verdijk RM, Jager MJ. **Ischemia is related to tumour genetics in uveal melanoma.**
Cancers (Basel) 2019;11(7). Pii: E1004

12. Jain P, Finger PT, Damato B, Coupland SE, Heimann H, Kenawy N, **Brouwer NJ**, Marinkovic M, Van Duinen SG, Caujolle JP, Maschi C, Seregard S, Pelayes D, Folgar M, Yousef YA, Krema H, Gallie B, Calle-Vasquez A, American Joint Committee on Cancer Ophthalmic Oncology Task F. **Multicenter, international assessment of the eighth edition of the American Joint Committee on Cancer Cancer Staging Manual for conjunctival melanoma.**
JAMA Ophthalmol 2019;137(8):905-911.

13. **Brouwer NJ,** Marinkovic M, Luyten GPM, Shields CL, Jager MJ. **Pigmentation of conjunctival melanoma recurrences and outcome.**
Graefes Arch Clin Exp Ophthalmol 2019;257(8):1783-1788.

14. **Brouwer NJ,** Genders SW, Marinkovic M, van Duinen SG, Jager MJ, Luyten GPM. **Two late recurrences of conjunctival melanoma.**
Ocul Oncol and Pathol 2019;5(4):262-266.

15. **Brouwer NJ,** Marinkovic M, Jochems A, Kapiteijn EW, van Duinen SG, Haeseker BI, Jager MJ, Luyten GPM. **Conjunctival metastasis of a cutaneous melanoma.**
Ocul Oncol and Pathol 2018;4(2):107-111

16. Jager MJ, **Brouwer NJ,** Esmaeli B. **The Cancer Genome Atlas Project: An integrated molecular view of uveal melanoma.**
Ophthalmology 2018;125(8)1139-1142

17. **Brouwer NJ,** Marinkovic M, Luyten GPM, Shields CL, Jager MJ. **Lack of tumour pigmentation in conjunctival melanoma is associated with light iris colour and worse prognosis.**
Br J Ophthalmol 2019;103(3):332-337.

18. Cao J, Pontes KC, Heijkants RC, **Brouwer NJ,** Groenewoud A, Jordanova ES, Marinkovic M, van Duinen SG, Teunisse AF, Verdijk RM, Snaar-Jagalska E, Jochemsen AG, Jager MJ. **Overexpression of EZH2 in conjunctival melanoma offers a new therapeutic target.**
J Pathol 2018;245(4)433-444

19. Cao J, **Brouwer NJ,** Jordanova ES, Marinkovic M, van Duinen SG, de Waard NE, Ksander BR, Mulder A, Claas FHJ, Heemskerk MHM, Jager MJ. **HLA class I antigen expression in conjunctival melanoma is not associated with PD-L1/PD-1 status.**
Invest Ophthalmol Vis Sci 2018;59(2):1005-1015

20. **Brouwer NJ**, Marinkovic M, van Duinen SG, Bleeker JC, Jager MJ, Luyten GPM. **Treatment of conjunctival melanoma in a Dutch referral centre.**
Br J Ophthalmol 2018;102(9):1277-1282

21. **Brouwer NJ,** Haanen JBAG, Jager MJ. **Development of ocular rosacea following combined ipilimumab and nivolumab treatment for metastatic malignant skin melanoma.**
Ocul Oncol and Pathol 2017;3(3):188-192

22. Cao J*, **Brouwer NJ***, Richards KE, Marinkovic M, van Duinen SG, Hurkmans D, Verdegaal EME, Jordanova ES, Jager MJ. **PD-L1/PD-1 expression and tumor-infiltrating lymphocytes in conjunctival melanoma.**
Oncotarget 2017;8(33):54722-54734

23. **Brouwer NJ,** Luyten GPM, van Duinen SG, Jager MJ, Marinkovic M. **Multiple pigmented conjunctival lesions following intravitreal injections in a patient with uveal melanoma.**
Ocul Oncol and Pathol 2017;3(2):113-166

24. Pieterse AH, Kunneman M, Engelhardt EG, **Brouwer NJ**, Kroep JR, Marijnen CAM, Stiggelbout AM, Smets EMA. **Oncologist, patient and companion questions during pre-treatment consultations about adjuvant cancer treatment: A shared decision-making perspective.**
Psycho-Oncology 2017;26(7):943-950

25. Kröner ES, Westenberg JJ, Kroft LJ, **Brouwer NJ**, van den Boogaard PJ, Scholte AJ. **Coupling between MRI-assessed regional aortic pulse wave velocity and diameters in patients with thoracic aortic aneurysm: a feasibility study.**
Neth Heart J 2015;23(10):493-501.

26. Kröner ES, Westenberg JJ, van der Geest RJ, **Brouwer NJ**, Doornbos J, Kooi ME, van der Wall EE, Lamb HJ, Siebelink HJ. **High field carotid vessel wall imaging: a study on reproducibility.**
Eur J Radiol 2013;82(4):680-5.

27. Kröner ES, van Schinkel LD, Versluis MJ, **Brouwer NJ**, van den Boogaard PJ, van der Wall EE, de Roos A, Webb AG, Siebelink HM, Lamb HJ. **Ultrahigh-field 7-T magnetic resonance carotid vessel wall imaging: initial experience in comparison with 3-T field strength.**
Invest Radiol 2012;47(12):697-704.

* shared first authorship