



Universiteit  
Leiden  
The Netherlands

## Novel imaging strategies in venous thromboembolism

Dam, L.F. van

### Citation

Dam, L. F. van. (2022, January 27). *Novel imaging strategies in venous thromboembolism*. Retrieved from <https://hdl.handle.net/1887/3254464>

Version: Publisher's Version

License: [Licence agreement concerning inclusion of doctoral thesis in the Institutional Repository of the University of Leiden](#)

Downloaded from: <https://hdl.handle.net/1887/3254464>

**Note:** To cite this publication please use the final published version (if applicable).



1

# **CHAPTER**

**Introduction and outline of  
this thesis**



Venous thromboembolism (VTE) encompasses pulmonary embolism (PE) and deep vein thrombosis (DVT). DVT most commonly occurs in the deep veins of the lower extremity but can also occur in the veins of upper extremity, abdomen and cerebrum. As symptoms of VTE are nonspecific, the diagnosis of VTE is based on diagnostic tests, including clinical decision rules (CDR), D-dimer tests and imaging. Although the diagnostic management of VTE has greatly advanced in recent years with the introduction of novel CDRs and high-sensitive D-dimer tests, the diagnosis may still be challenging in certain settings. The latter is mainly caused by the indirect way of thrombus visualisation by current imaging tests, such as by showing incompressibility with compression ultrasonography (CUS) or a filling defect on contrast-enhanced computed tomography (CT) or magnetic resonance imaging (MRI).

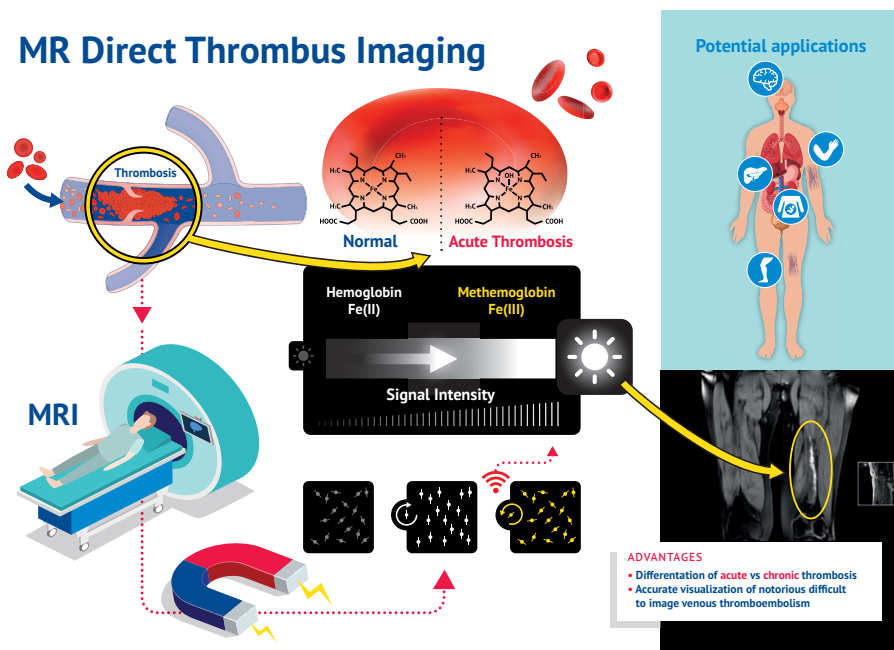
This thesis focuses on challenging settings for diagnosing VTE. One of these settings is suspected *recurrent VTE*. CUS is the current imaging test of choice in both patients with suspected first and recurrent DVT.<sup>1</sup> However, in suspected *recurrent ipsilateral DVT* the diagnosis with CUS is complicated as persistent vascular abnormalities after a previous DVT are present in up to 50% of patients after one year.<sup>2</sup> Magnetic Resonance Non-Contrast Thrombus Imaging (MR-NCTI) is a non-invasive MRI technique that can directly visualize thrombosis and may be of value in the diagnostic management of recurrent VTE. MR-NCTI is based on the formation methemoglobin when blood clots, resulting in shortening of the MR signal on a T1-weighted MRI sequence. Therefore, acute thrombi are visible as a 'white' signal, which disappears when a thrombus is formed (**Figure 1**).<sup>3,4</sup> Magnetic Resonance Direct Thrombus Imaging (MRDTI), a MR-NCTI sequence, has previously been shown to accurately distinguish acute recurrent DVT from chronic thrombotic remains.<sup>5</sup> Its safety to exclude acute recurrent ipsilateral DVT was evaluated in the Theia study. Results of this prospective multicentre diagnostic management study are described in **Chapter 2**. Since it is unknown whether the application of MRDTI in the diagnostic management of suspected recurrent ipsilateral DVT is costeffective, an analysis to compare the one-year healthcare costs between 10 diagnostic scenarios with and without MRDTI was performed. The results are described in **Chapter 3**. The combination of a CDR and D-dimer test is used to exclude a first episode of DVT without performing imaging tests. The diagnostic performance of a CDR combined with a D-dimer test has not yet been sufficiently evaluated in patients with suspected recurrent DVT.<sup>6</sup> One of the predefined secondary outcomes of the Theia study was to assess the diagnostic accuracy of the combination of the Wells rule for DVT and a D-dimer test for suspected recurrent ipsilateral DVT (**Chapter 4**).

MR-NCTI may also be useful in the diagnostic management of *upper extremity deep vein thrombosis* (UEDVT), where CUS examination is hindered by overlying anatomic structures. The alternative diagnostic imaging test is contrast venography, which has several disadvantages including radiation exposure and risk for contrast allergic reactions.<sup>7</sup> In **Chapter 5**, the results of the Selene study are provided, in which the diagnostic accuracy of MR-NCTI for the diagnosis of UEDVT was evaluated. Another setting where MR-NCTI could be a valuable diagnostic test is in *portal vein thrombosis* (PVT). Differentiation between acute and chronic thrombosis is of paramount importance in the management of PVT, since the anticoagulant strategy in patients with acute PVT differs of that in patients with chronic thrombosis.<sup>8</sup> It is however not always possible with currently available imaging tests to make this distinction. As MR imaging of the portal veins can be more challenging than of the veins in the extremities due to bowel movements and the presence of intestinal air, we performed a study to identify the most optimal MR-NCTI sequence for PVT imaging (**Chapter 6**). In **Chapter 7**, an overview of different imaging techniques including MR-NCTI and their diagnostic accuracy in suspected acute *cerebral vein thrombosis* (CVT) is provided. Based on our studies and increasing experience with MR-NCTI, this technique is now more and more used to guide treatment decisions in other settings, such as in the patients in **Chapter 8** and **Chapter 9**. The first patient (**Chapter 8**) was suspected of an acute CVT but had an inconclusive CT and MR venography. The second patient described in **Chapter 9** had an extensive *aortic thrombosis* on CT angiography of unknown age, and a strong contraindication to anticoagulant treatment.

The last chapters of this thesis focus on the application of CT in the diagnostic and prognostic management of acute PE. CT pulmonary angiography (CTPA) is the current diagnostic imaging of choice for the diagnosis of PE.<sup>9</sup> New CT techniques have been developed in recent years including techniques that can provide perfusion or iodine maps, representing the hemodynamic and functional impact of PE. This so-called CT pulmonary perfusion (CTPP) imaging may have an added value on top CTPA reading for initial risk stratification of acute PE. In **Chapter 10**, the correlation between perfusion defects on CTPP and symptoms at presentation as well as short-term adverse outcome was assessed. Furthermore, as extensive perfusion defects on CT at the time of PE diagnosis may also correlate to long-term symptoms and outcome<sup>10</sup>, we evaluated the association between perfusion defects on CTPP at initial PE-diagnosis and persistent symptoms, including dyspnea, chest pain, functional impairment and adverse outcomes after 3-months of follow-up in **Chapter 11**. CTPA is also used in the diagnostic management of

patients with coronavirus disease 19 (COVID-19) pneumonia who are suspected of concomitant acute PE. COVID-19 has been associated with high rates of VTE <sup>11</sup>, particularly PE. Based on the results of autopsy studies it was suggested that thrombosis may often be the result of an in-situ immunothrombosis rather than conventional thromboembolism.<sup>12</sup> To further evaluate whether COVID-19 associated PE differs from conventional PE, clinical and CT characteristics of PE in patients with COVID-19 pneumonia were compared to those in patients without COVID-19 pneumonia (**Chapter 12**).

**Figure 1.** Infographic of the Magnetic Resonance Direct Thrombus Imaging technique.



This was originally published in *Blood*. Van Dam, L.F., et al. *Blood*. 2020 Apr 16;135(16):1377-1385. © the American Society of Hematology.

## REFERENCES

1. Mazzolai, L., et al., *Diagnosis and management of acute deep vein thrombosis: a joint consensus document from the European Society of Cardiology working groups of aorta and peripheral vascular diseases and pulmonary circulation and right ventricular function*. Eur Heart J, 2018. **39**(47): p. 4208-4218.
2. Tan, M., et al., *High percentage of non-diagnostic compression ultrasonography results and the diagnosis of ipsilateral recurrent proximal deep vein thrombosis*. J Thromb Haemost, 2010. **8**(4): p. 848-50.
3. Moody, A.R., *Magnetic resonance direct thrombus imaging*. J Thromb Haemost, 2003. **1**(7): p. 1403-9.
4. Saha, P., et al., *Magnetic resonance T1 relaxation time of venous thrombus is determined by iron processing and predicts susceptibility to lysis*. Circulation, 2013. **128**(7): p. 729-736.
5. Tan, M., et al., *Ability of magnetic resonance direct thrombus imaging (MRDTI) to differentiate acute recurrent ipsilateral deep vein thrombosis from residual thrombosis*. Blood, 2014(124(4)): p. 623-7.
6. Huisman, M.V. and F.A. Klok, *Diagnostic management of acute deep vein thrombosis and pulmonary embolism*. J Thromb Haemost, 2013. **11**(3): p. 412-22.
7. Baarslag, H.J., et al., *Prospective study of color duplex ultrasonography compared with contrast venography in patients suspected of having deep venous thrombosis of the upper extremities*. Ann Intern Med, 2002. **136**(12): p. 865-72.
8. Simonetto, D.A., et al., *ACG Clinical Guideline: Disorders of the Hepatic and Mesenteric Circulation*. Am J Gastroenterol, 2020. **115**(1): p. 18-40.
9. Konstantinides, S.V., et al., *2019 ESC Guidelines for the diagnosis and management of acute pulmonary embolism developed in collaboration with the European Respiratory Society (ERS)*. Eur Heart J, 2020. **41**(4): p. 543-603.
10. Pesavento, R., et al., *Impact of residual pulmonary obstruction on the long-term outcome of patients with pulmonary embolism*. Eur Respir J, 2017. **49**(5).
11. Klok, F.A., et al., *Incidence of thrombotic complications in critically ill ICU patients with COVID-19*. Thromb Res, 2020.
12. Ackermann, M., et al., *Pulmonary Vascular Endothelialitis, Thrombosis, and Angiogenesis in Covid-19*. N Engl J Med, 2020. **383**(2): p. 120-128.