



Universiteit  
Leiden  
The Netherlands

## **Treating Meningioma: does the patient benefit? A paradigm shift from tumor to patient**

Zamanipoor Najafabadi, A.H.

### **Citation**

Zamanipoor Najafabadi, A. H. (2022, January 13). *Treating Meningioma: does the patient benefit?: A paradigm shift from tumor to patient*. Retrieved from <https://hdl.handle.net/1887/3249735>

Version: Publisher's Version

License: [Licence agreement concerning inclusion of doctoral thesis in the Institutional Repository of the University of Leiden](#)

Downloaded from: <https://hdl.handle.net/1887/3249735>

**Note:** To cite this publication please use the final published version (if applicable).

# Chapter 9

---

**Visual outcomes endorse surgery of patients  
with sphenoid-orbital meningioma with minimal  
visual impairment or hyperostosis**

---

*Acta Neurochirurgica, 2021;163(1): 73-82*

Amir H. Zamanipoor Najafabadi

Stijn W. Genders

Wouter R. van Furth

# ABSTRACT

## Background

Most spheno-orbital meningioma series span multiple decades and predictors of visual outcomes have not yet been systemically assessed. We describe visual outcomes in a recent cohort and assess predictors of postoperative visual outcomes.

## Methods

Consecutive case series operated by a team of a neurosurgeon and orbital surgeon between May 2015 and January 2019. Best corrected visual acuity (BCVA), visual fields (static perimetry), and relative proptosis were measured pre- and postoperatively at 3/6/12 months after which it was assessed yearly. Predictors were assessed with linear regression analysis.

## Results

Nineteen patients (all WHO grade I) were operated by the pterional approach (median follow-up: 2.4 years). Preoperative visual acuity deficits (n=10) normalized in 70% and improved in 10% (median preoperative: 0.8, postoperative: 1.2,  $p=0.021$ ). Preoperative visual field deficits (n=8) normalized in all patients (preoperative: -6.5dB, postoperative: -1.5dB,  $p=0.008$ ). Preoperative proptosis (n=16) normalized in 44% and improved in 56% (preoperative: 5mm, postoperative: 2mm,  $p<0.001$ ). BCVA and visual fields remained stable at longer follow-up in 95% of patients, while 21% showed progression of proptosis. Predictors for worse longer-term (>12 months) BCVA were worse preoperative BCVA ( $p=0.002$ ) and diagnosis of multiple meningioma ( $p=0.021$ ). Predictors for worse longer-term visual fields were higher diameter of hyperostosis ( $p=0.009$ ) and higher Simpson grade ( $p=0.032$ ). Predictor for short-term (3 months) proptosis was preoperative proptosis ( $p=0.006$ ).

## Conclusion

We recommend surgery, even of patients with minimal visual impairment or hyperostosis, as patients who present with deteriorated visual function or extensive hyperostosis are less likely to have postoperative visual outcomes restored to normal.

## Key words

Spheno-orbital, meningioma, surgery, vision, hyperostosis

## INTRODUCTION

Spheno-orbital meningioma (SOM) are tumors originating from the sphenoid ridge, primarily characterised by hyperostosis of the lesser and/or greater sphenoid wing.<sup>1,2</sup> In addition, the majority of patients have an intradural meningioma, often described as a thin “carpet-like” or “en-plaque” tumor, which can be more extensive including cavernous sinus involvement and an intraorbital component.<sup>2-4</sup> Due to its location, the majority of patients present with visual deficits, and/or proptosis.<sup>5</sup>

Due to the low incidence of SOM, current series in the literature describe smaller and larger patient series often covering multiple decades, while surgical techniques have improved over the years.<sup>1,2,12,3,4,6-11</sup> In these series, surgery has proven its value with improvement of visual function (10-73%) and proptosis (50-93%).<sup>1-3,6-9,11,12</sup> Nevertheless, many papers only describe the pre- and postoperative visual acuity and proptosis, neglecting patients’ visual fields deficits, while this is strongly associated with patients’ health-related quality of life.<sup>3,4,6,7,9,11</sup> In addition, predictors of visual outcomes have not yet been systematically assessed. Identification of these predictors may optimise the decision and timing of surgical treatment and tailor postsurgical ophthalmological follow-up.

Therefore, we aimed to describe visual outcomes, complications and recurrence in a recent cohort of surgically treated SOM patients in a high-volume referral centre with a dedicated multidisciplinary team. In addition, we systematically assessed predictors of short- and longer-term postoperative best corrected visual acuity (BCVA), visual fields, and proptosis

## METHODS

### Study setting and subject selection

Consecutive (i.e. no case selection) spheno-orbital meningioma patients operated between June 2015 and January 2019 in the Leiden University Medical Center (LUMC) in Leiden the Netherlands were described in this study. A set team of a neurosurgeon (WRvF) and orbital/oculoplastic surgeon (SWG) operated patients and followed patients at their multidisciplinary outpatient clinic. SOM was defined as an inner sphenoid-ridge meningioma with hyperostosis of at least the lesser or greater sphenoid wing with an intradural meningioma. Patients were excluded if previously operated. In our center the usual first line treatment of SOM consists of surgery, with radiotherapy reserved for recurrent tumors. This study was reviewed and approved by the LUMC-LDD medical ethics committee as part of a larger study protocol (G19.011).

## Surgical technique

The pterional approach was used in all cases. Patients were positioned in the supine position, with the head extended and rotated to the contralateral side. An interfascial temporal flap was developed to expose the skull.<sup>13</sup> Neuronavigation was used to verify extension of bony resection. Hyperostotic bone of the orbital roof and lateral orbital wall was microscopically decompressed from the maxillary strut to the optic strut using the eggshell technique, which comprises thinning of bone to softly peel the layer of bone around critical structures. If involved the optic canal was decompressed in total length. The meningo-orbital band was cut to fully expose the superior orbital fissure (Figure 1). Intradural meningioma was removed, but no attempts were made to remove intracavernous sinus meningioma. Intraorbital meningioma was resected by the orbital surgeon and periorbital was partially resected, or incised, to reduce proptosis. Common grafting techniques (cranial periosteum, donor or artificial material) was used for watertight dural reconstruction. If indicated, the lateral orbital wall was reconstructed with titanium mesh, or patient-specific 3D-printed PEEK (polyetheretherketone) implant to prevent pulsatile enophthalmos and/or adhesion of the temporal muscle to the periorbital. Abdominal fat, or gelatine-based artificial material was used to fill-up the defect. The surgical technique was somewhat modified over time based on developing experiences and new insights.

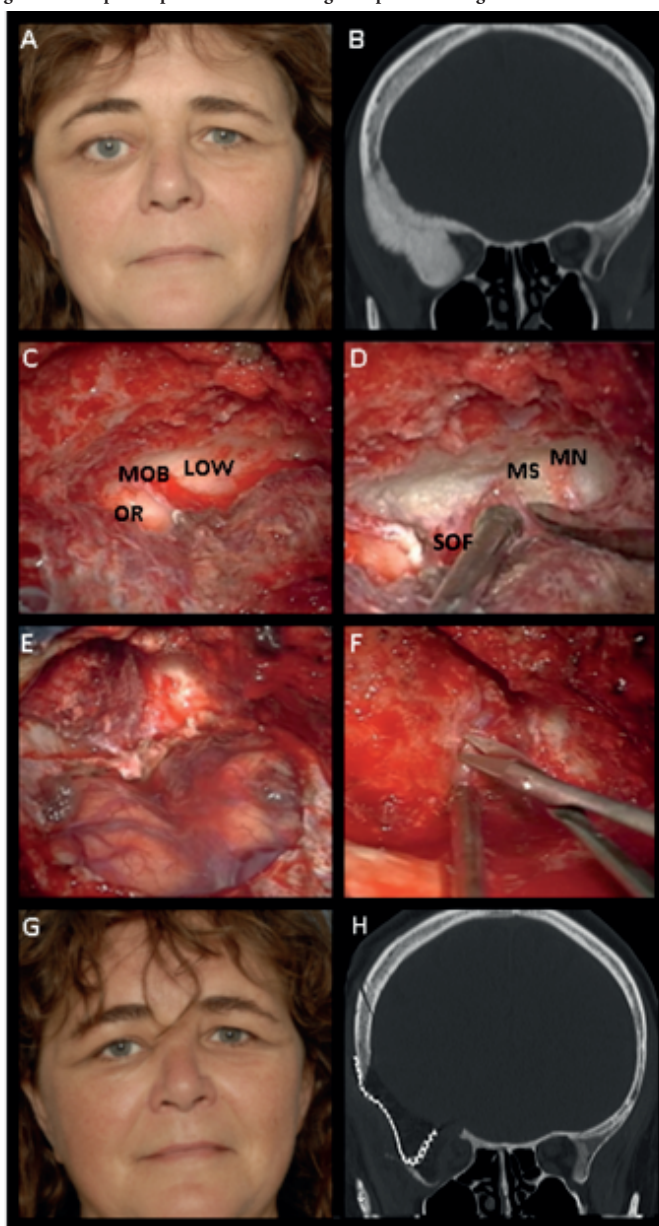
## Data collection

Demographic characteristics were collected from the electronic patient charts. Patients underwent both computed tomography (CT) and gadolinium contrast-enhanced magnetic resonance imaging (MRI) both before and after surgery (postoperative: after 6 months and then yearly.) Multiple visual outcomes were measured preoperatively, and postoperatively at 3, 6, and 12 months, after which patients were seen yearly in the multidisciplinary outpatient clinic of both surgeons. Best corrected visual acuity (BCVA) was measured with the Snellen chart. Patient's visual fields were investigated using the Zeiss Humphrey visual field analyser, described as Mean Deviation (MD) in decibel (dB). Proptosis was determined by measuring axial globe position using a double-prism exophthalmometer, comparing the affected eye with the unaffected eye.<sup>14</sup>

## Statistical Analysis

Outcomes after surgery are described as the percentage of patients with deteriorated, stable, improved or normalized BCVA, visual fields and proptosis. Preoperative outcomes were compared with direct postoperative outcomes using the Wilcoxon signed rank test. Individual patient data is graphically depicted over time for all outcomes in graphs. Furthermore, median values were calculated for all patients together and for those patients with and without preoperative visual acuity deficits (cut-off for deficit 0.8 or lower), visual field deficits (cut-off for deficit -5dB or lower)<sup>15</sup>, or proptosis (cut-off for clinically relevant proptosis 2mm or more). No cut-offs for improvement on the individual patient level were set, as clinical interpretation

Figure 1: Example of Spheno-Orbital meningioma patient management



**A:** Patient presented with a relative proptosis of 8 mm of the right eye, BCVA of 0.6 and a visual field deficit of  $-6.50\text{dB}$ . **B:** Hyperostosis of both the orbital roof and lateral orbital wall is shown on the CT scan in bone setting. **C/D:** Pictures of the microsurgical decompression. MOB = Meningo-Orbital Band. OR = Orbital Roof. LOW = Lateral Orbital Wall. MS = Maxillary Strut. MN = Maxillary Nerve. **E:** A Simpson grade I resection was achieved after intradural and intraorbital meningioma resection. **F:** After resection of intraorbital meningioma, vertical cuts were made in the periorbita to reduce proptosis. **G:** Postoperative facial picture showed clear reduction of proptosis. Her BCVA normalised (1.20) as well as the visual field deficit ( $-0.33\text{dB}$ ). **H:** CT scan in bone setting showed reduction of hyperostotic bone and reconstruction of the lateral orbital wall with titanium mesh. Figures published with permission of the patient after written informed consent.

of improvement is highly dependent on the preoperative status (e.g. visual acuity improvement of 0.0 to 0.4 vs 1.0 to 1.4). Instead, the above-mentioned cut-offs were used both preoperatively and postoperatively and distinction was made between postoperative improvement and normalization of visual outcomes. Predictors of BCVA, visual fields and proptosis were assessed by univariable linear regression analysis, separately for the direct postoperative outcomes (3 months) and outcomes at longest follow-up. No multivariable analysis was performed due to the small number of patients. IBM SPSS Statistics version 23.0 (Armonk, NY, USA) was used for all statistics and a p-value lower than 0.05 was considered statistically significant.

## RESULTS

### Subjects

During the study period, 20 patients were operated, but one patient was lost to follow-up, as the patient died due to comorbidities not related to the SOM or surgery. The remaining 19 patients were described in this study (median age: 47.0, 97% female). All patients suffered from unilateral disease. See table 1 for a description of all baseline characteristics. Median follow-up time between diagnosis and surgery was 7.2 months, as a short wait-and scan regimen was chosen as initial treatment for patients who only presented with proptosis without any visual deficits. Median follow-up time after surgery was 2.4 years (IQR: 1.3 to 3.3).

### Surgical techniques

In all cases the pterional approach was used, including decompression of the lateral orbital wall and superior orbital fissure (Table 2). The principles of the used surgical technique modified somewhat over time; the meningo-orbital band was cut in the last 10 patients (38%) to facilitate full exposure of the superior orbital fissure. Furthermore, in the first couple of operated patients the optic canal and orbital roof were only decompressed if preoperative CT showed extensive hyperostosis of these structures and/or a patient presented with visual acuity or visual field deficits. In the last 12 patients the orbital roof and optic canal were decompressed in all patients. Resection of the anterior clinoid process, decompression of the foramen rotundum, ovale and spinosum were only performed when clinically indicated. In the first patients, reconstruction of the lateral orbital wall was performed with titanium mesh, while in recent patients patient-specific 3D-printed PEEK implants were used for reconstruction. Gross total resection, i.e. resection of meningioma tissue and hyperostotic bone, was achieved in 14 patients (74%). A subtotal resection was achieved in 5 (26%) patients, due to extensive hyperostosis over the skull base.

Table 1: Baseline characteristics of Spheno-orbital meningioma patients

	LUMC cohort (n=19)
Gender, female	18 (95%)
Age at surgery, years	47.0 (45.0-50.0)
Time between diagnosis and surgery in months	7.2 (3.4-8.9)
Hyperostosis diameter (mm)	31.0 (24.0-35.0)
Soft tissue diameter (mm)	11.0 (8.0-18.0)
Simpson Grade	
Grade I	6 (32%)
Grade II	9 (47%)
Grade III	0 (0%)
Grade IV	4 (21%)
Extent of resection	
Full resection	15 (79%)
Subtotal resection	4 (21%)
WHO grade I	19 (100%)
WHO subtypes	
Meningothelial	15 (79%)
Transitional	3 (16%)
Secretory	1 (5%)
Number of tumors	
1	13 (69%)
2	3 (16%)
3	0 (0%)
4	1 (5%)
5	2 (11%)
Postoperative proton radiotherapy	2 (11%)
Postoperative photon radiotherapy	1 (5%)
Reoperation	2 (11%)
Follow-up length in years	2.4 (1.3-3.3)

Continuous outcomes are described as median value and interquartile range. Dichotomous outcomes are described as number and percentages. Percentages might not add up to 100% due to rounding.

Extent of resection was determined intraoperatively and on postoperative CT and MRI scan. A subtotal resection was defined as residual meningioma tissue or hyperostosis.

## Visual outcomes

Ten (53%) patients suffered from a decrease in BCVA, which normalized in 7 (70%) after surgery, improved in 1 (10%) and remained unchanged in 2 (20%, preoperative BCVA: 0.0 and 0.7) patients. Median BCVA before surgery was 0.8 (IQR: 0.7 to 1.5), which improved postoperatively to 1.2 (IQR: 1.0 to 1.5,  $p=0.021$ ), and remained stable in all patients at 1-year follow-up (1.2, IQR: 1.0 to 1.5) and longer follow-up (1.2, IQR: 1.0 to 1.5). Eight (42%) patients had preoperative visual field deficits, which normalized in all (100%) patients after



Table 2: Surgical techniques

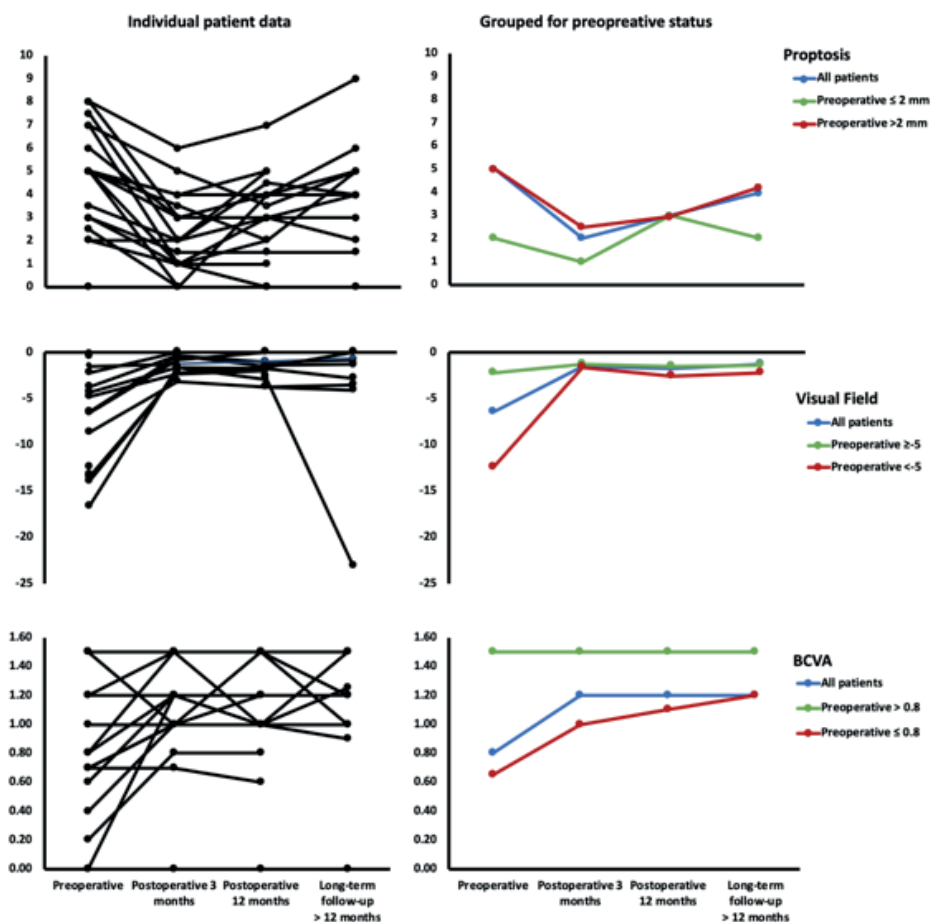
	LUMC cohort (n=19)
<b><u>Resection hyperostotic bone</u></b>	
Lateral orbital wall	19 (100%)
Orbital roof	
Complete	10 (53%)
Partial	5 (26%)
Not	4 (21%)
Anterior clinoid process	1 (5%)
<b><u>Decompression of foramina</u></b>	
Superior orbital fissure	19 (100%)
Optic canal	
Complete (full-length)	7 (37%)
Partial	5 (26%)
Not	7 (37%)
Foramen rotundum	1 (5%)
Foramen ovale	0 (0%)
Foramen spinosum	1 (5%)
<b><u>Resection of soft-tissue structures</u></b>	
Meningo-orbital band	10 (53%)
Intraorbital meningioma	10 (53%)
<b><u>Periorbita management</u></b>	
Cuts	4 (22%)
Stripping	7 (37%)
Nothing	8 (42%)
<b><u>Reconstruction</u></b>	
Patient-specific 3D PEEK implant	3 (16%)
Titanium mesh reconstruction	12 (63%)
No reconstruction performed	4 (21%)
Periumbilical fat filling	11 (58%)

PEEK: polyetheretherketone. Percentages might not add up to 100% due to rounding.

surgery. Median visual field before surgery was -6.5dB (IQR: -12.9 to -3.0), which improved postoperatively to -1.5dB (IQR: -2.2 to -0.7,  $p=0.03$ ) and remained stable in seven (88%) patients at 1-year follow-up (all patients: -1.7dB, IQR: -2.5 to -1.1) and longer follow-up (all patients: -1.3dB, IQR: -3.2 to -0.3). One patient suffered from a strong deterioration (-23.1dB) after 1-year follow-up. Sixteen (84%) patients presented with proptosis preoperatively, which normalized in seven (44%) and improved in nine (54%) patients. Median relative proptosis before surgery was 5mm (IQR: 3.0 to 6.5), which improved postoperatively to 2mm (IQR: 1.0 to 3.3,  $p<0.01$ ). However, four of these patients (25%) suffered from deterioration

at one-year follow-up (all patients: 3mm, IQR: 2 to 4) and one patient (6%) at longer follow-up (all patients: 4mm, IQR: 2 to 5). Individual patient data over time of BCVA, visual fields and proptosis are depicted in figure 2. In addition, median values are provided for all patients together and separately for patients with and without preoperative visual acuity deficits, visual field deficits and proptosis.

Figure 2: Proptosis, Visual Fields and Visual Acuity: individual patient data and grouped for patients with preoperative deficits



Pre-and postoperative measures of proptosis, visual fields and visual acuity are depicted for individual patients and grouped for all patients and patients with and without preoperative deficits. Proptosis was measured with a Hertel exophthalmometer in mm. Visual fields were measured with the Humphrey visual field analyser, described as Mean Deviation (MD) in decibel (dB). Visual acuity was measured with the Snellen chart.

## Complications and reintervention

Patients suffered from the following postoperative complications: transient (n=3) and permanent (n=3) hypesthesia of the maxillary nerve, transient deficit of the frontal branch of the facial nerve with consequently asymmetry of the eyebrows (n=3), wound abscess requiring debridement of the wound (n=1), preseptal orbital cellulitis (n=1) which was successfully treated with antibiotics, and oscillopsia during chewing (n=1) for which eventually a patient-specific 3D-printed PEEK reconstruction was performed. No complications of the other cranial nerves or surgical mortality were observed. After 1-year follow-up two patients developed MRI established growth of residual tumor, for which one patient received photon radiotherapy 1.5 years after surgery and one patient received proton beam therapy 4.0 years after surgery. As stated before, one patient suffered from strong deterioration of visual fields (-23.1dB), requiring resection and proton beam therapy, which improved and stabilized the patient's visual field deficit (-10.0dB). One patient required resection for the development of ophthalmoplegia, which improved the patient's symptoms. In these four patients the optic canal was decompressed in one and the orbital roof in three patients.

## Predictors of short- and longer-term postoperative visual acuity, visual fields and proptosis

*Short-term:* Predictor for worse short-term postoperative BCVA was worse preoperative BCVA: for each point lower preoperative BCVA, postoperative BCVA was 0.49 lower (95%CI: -0.21 to -0.77, p=0.002). No predictors were identified for short-term visual fields. Predictor of worse postoperative proptosis was worse preoperative proptosis: for each additional mm preoperative proptosis, postoperative proptosis was 0.47 mm higher (95%CI: 0.16 to 0.78, p=0.006). Detailed information about predictors of short-term outcomes is provided in Supplementary Table 1.

*Longer-term:* Predictors for worse longer-term BCVA were worse preoperative BCVA ( $\beta=-0.49$ , 95%CI: -0.21 to -0.77, p=0.002), and the number of tumors: for each extra diagnosed meningioma, postoperative BCVA was -0.14 lower (95%CI: -0.26 to -0.02, p=0.021). Predictors for worse postoperative visual fields were the maximum diameter of preoperative hyperostosis: for each additional mm preoperative hyperostosis, postoperative visual fields were 0.39dB lower (95%CI: -0.67 to -0.12, p=0.009); and Simpson grade: for each grade increase in Simpson grade, postoperative visual fields were 3.71dB lower (95%CI: -6.63 to -0.78, p=0.017). No predictors were identified for longer-term proptosis. Detailed information about predictors of longer-term outcomes is provided in Supplementary Table 2.

## DISCUSSION

In a recent cohort of sphenoidal meningioma patients operated by a dedicated team of a neurosurgeon and orbital surgeon in a high-volume referral center good visual outcomes were achieved and maintained with modest morbidity and no mortality. Postoperative visual acuity and visual fields endorsed surgery of patients with SOM, even with minimal visual impairment or hyperostosis, as we showed with our regression analysis that preoperative visual deficits and the maximum diameter of hyperostosis were predictors of poorer outcome.

Results of this mono-center study were in line with published studies of the last two decades, which reported improvement of vision in 37-87% of patients, visual fields in 17-88%, proptosis in 60-100%, and permanent complications in 22-44% of patients.<sup>2,6,8,16-19</sup> We reported improvement of visual acuity in 80% and visual fields in 100% of patients with stable outcomes in 95% of these patients during our modest follow-up period. Proptosis was also improved in all patients, however 21% reported deterioration at longer follow-up. We observed permanent complications in 32%. Despite the good visual outcomes, 21% of patients showed progression requiring resection, which was comparable to the outcomes (22-48%) of recently published studies by other groups.<sup>9,16,17,20</sup>

### Predictors of postoperative vision

Based on our results, multiple data driven recommendations can be made to optimize surgery and postsurgical follow-up for SOM patients (Table 3). Our results suggest that it might be beneficial to operate patients, even with minimal visual impairment or hyperostosis, to prevent the development of visual deficits, that might not completely resolve after surgery (i.e. strongest predictor for postoperative visual outcomes were preoperative visual function and hyperostosis), which is in line with conclusions reported in published literature<sup>3,4,6,9,11,17,18,21</sup>. Our, relatively short, follow up results suggest early surgery has a lasting change on the clinical course of the disease, with persisting good visual outcomes in the majority of patients. Patients with normal visual function, operated for their proptosis, maintained good visual outcomes after surgery. While surgery of patients with minimal visual symptoms seems intuitive and was recommended by other case series, these studies did not systematically assess predictors of postoperative visual outcomes.<sup>3,4,6,9,11,17,18,21</sup> As these tumors tend to invade the bone near the foramina of the cranial nerves, early surgery might prevent extensive hyperostosis, narrowing of foramina, and consequently cranial nerve deficits.<sup>1,6</sup> Indeed it is reported that optic canal and intraorbital involvement are predictors for postoperative visual deficits.<sup>21</sup> Nevertheless we also acknowledge that surgery itself imposes a risk of new visual and cranial nerve deficits.<sup>2,16</sup> Especially in very old patients, patients with severe comorbidities, or patients with extensive disease resulting in full blindness, the benefits of surgery might not always outweigh the risk of complications. However, in general we believe that the risk for new complications might

be smaller when patients are operated on early in their disease course, as cranial nerves are less vulnerable when compression is less severe. Our results also indicate that patients diagnosed with multiple intracranial meningioma were at higher risk for postoperative visual acuity deficits. Therefore, we advise a more intensive multidisciplinary postsurgical follow-up for these patients, to identify objective or subjective postoperative visual deterioration as early as possible, enabling early resection. The need for repeat intervention was high in this group.

## **Surgical approaches**

Although multiple surgical approaches have been described for SOM surgery, the pterional approach is the most used approach in these patients, and also used for all patients described in this study.<sup>2,6,7,11,19,22</sup> Advantages of pterional craniotomy are wide exposure and access to the anterior, middle and temporal cranial fossa, and therefore ability to resect the hyperostotic bone and soft-tissue tumor as radically as possible. Recently, multiple endoscopic approaches have been described for anterior skull base pathology, such as the supraorbital, and the combined endonasal and transorbital approach.<sup>23–29</sup> Three studies described a total of 12 SOM patients operated with the endonasal transorbital approach.<sup>27,28,30</sup> The endonasal approach was used for decompression of the medial part of the optic canal. Further decompression of the hyperostotic bone and tumor removal was accomplished with the transorbital approach.<sup>27,28,30</sup> Compared with endonasal approach only, this combined approach enabled resection of more laterally located pathology.<sup>27</sup> Overall these case series showed stabilisation of visual function with moderate to good reduction of proptosis. Proposed advantages are the less invasive approach with cosmetically pleasing results. However, gross total resection is often not possible, and therefore these approaches should be preserved for selected patients with suspected benign meningioma with minimal intradural growth and in whom relief of symptoms through decompression of the optic canal is the primary goal.<sup>30</sup> In these cases residual tumor can be controlled by radiotherapy.<sup>30</sup>

## **Hyperostotic bone resection, dealing with periorbita, and reconstruction techniques**

In the last decades a paradigm shift has occurred in skull base surgery from aiming maximum surgical resection to optimizing patient outcomes and health-related quality of life.<sup>31,32</sup> A maximum resection of hyperostotic bone is advocated to reduce proptosis, to restore visual function and minimize progression. However, there is no consensus on the degree of bony resection, the need to resect invaded periorbit and the need for reconstruction of the lateral orbital wall. We agree with earlier reports that cavernous sinus involvement is a contra-indication for gross-total resection.<sup>1,6,17,22</sup> Some of the same reports advise no decompression of superior orbital fissure tumor involvement. However, with transection of the meningo-orbital band, full decompression of the superior orbital fissure is possible.<sup>33</sup> It remains controversial whether resection of bone should be limited to clearly visible hyperostotic bone or whether decompression of the

optic canal and possible other foramina should be performed routinely for preservation of good visual function.<sup>17</sup> We recommend resection of at least the orbital roof and lateral orbital wall, and decompression of the optic canal, and superior orbital fissure to prevent further deterioration of visual outcomes and improve proptosis (Table 3). Although standard resection of the anterior clinoid process is performed by others, we only advise to resect this structure in case of hyperostosis to prevent early postoperative progression, as no cranial nerves are directly affected by hyperostosis of the anterior clinoid process.<sup>1–3,11,17,34</sup> Another debate is the need for resection of the periorbit. While this should clearly be done when the periorbit is invaded with tumor, it is advocated by some to preserve the periorbita to prevent pulsatile enophthalmos. However, we agree with others that resection of the periorbit is critical to maximally reduce proptosis. Based on our own experience and the reported literature, we advise reconstruction with titanium mesh or customized patient-specific 3D PEEK implants to prevent (pulsatile) enophthalmos, especially in case of periorbita resection.<sup>3,6–8,10,11,17,34</sup> Other groups have reported to actually not perform reconstruction to provide an even greater reduction of proptosis.<sup>1,2,19</sup>

**Table 3 – Recommendations for surgical indication, surgical technique and patient follow-up**

Current practice	Recommendations	Evidence current study	Literature supporting recommendation
<i>Indication for surgery</i>			
• Significant visual symptoms or proptosis	• Prevention of visual deficits by early surgery, even of patients with minimal visual impairment or hyperostosis	• Worse preoperative deficits were related to worse postoperative outcomes	• 3,4,6,9,11,17,18,21
<i>Surgical technique</i>			
• Resection of hyperostotic bone	• Maximum resection of hyperostotic bone: at least the lateral orbital wall, orbital roof, optic canal, and superior orbital fissure	• Need for resection or radiotherapy was observed in patient without decompression of orbital roof and optic canal	• 2,11,16,18 • 11,17,20,38–40 • 8,11,16–18,34,41
• Limited resection intraorbital meningioma and periorbita	• Maximum intraorbital meningioma resection, including periorbita	• Simpson grade was predictive for long-term visual field deficits	
• Reconstruction is some patients	• Reconstruction with titanium mesh or customized 3d-printed PEEK implant	• Reconstruction with titanium mesh or 3D-printed PEEK implant showed good postoperative proptosis results	
<i>Patient follow-up</i>			
• Routine meningioma follow-up	• More frequent follow-up of patients with multiple meningioma	• Tumor number was predictive for long-term visual acuity	• No relevant literature

## Progression and Adjuvant treatment

In this case series with limited follow-up length, 21% of patients needed reintervention. Two patients showed established tumor growth without the development of new visual deficits. These patients were treated with radiotherapy to halt the tumor growth. While radiotherapy is associated with optic neuropathy, extra-ocular muscle dysfunction and pituitary insufficiency<sup>16,20</sup>, irradiation was chosen over reoperation, as the growing tumor remnants were deemed difficult to fully resect. Especially with the introduction of proton beam therapy, irradiation might be less harmful than reoperation for cases with residual disease or tumor regrowth without symptoms of newly developed visual deficits.<sup>35</sup> However, in the two patients with newly developed visual deficits due to postoperative tumor growth, reoperation was chosen in an attempt to decompress the optic system to improve the visual function of the patient. These percentages and treatment strategies for recurrent disease are in line with other case series.<sup>2,16,34,36</sup> Although our case series did not include any patients with a WHO grade II tumor, other authors advise upfront radiotherapy for these patients.<sup>16,37</sup>

## Strengths and limitations

Strengths of this study are the use of a recent cohort of SOM patients operated by a dedicated set team of a neurosurgeon and orbitoplastic surgeon for assessment of short- and longer-term visual outcomes. Furthermore, we prospectively comprehensively assessed visual outcomes, not only reporting visual acuity, but also standardised measurement of visual fields. Only few studies have been published reporting results of visual fields, while this is a significant symptom for patients, highly correlated with their health-related quality of life.<sup>15</sup> Another strength is the assessment of predictors for postoperative visual outcomes, enabling formulation of recommendations for SOM surgery and patient follow-up. However, due to the small number of patients no multivariable analysis was performed and ideally our results should be validated in a larger (international) dataset, to ensure robustness of the results. Although we did not perform a direct comparison between patients with an early vs. late stage disease, we formulated that surgery of patients with minimal visual impairment or hyperostosis might provide better postoperative results, as predictors of worse postoperative visual outcomes were worse preoperative visual acuity and a larger diameter of proptosis. While more intuitive, a direct comparison of early vs. later surgery was not possible due to the small patient sample and might actually not be preferred as it does not take into account the extent of disease and visual status at diagnosis. Longer follow-up is needed to assess more accurate recurrence rates and the long-term outcomes after resection and radiotherapy.

## Conclusions

The aim of surgery for speno-orbital meningioma should be to optimize visual outcomes and health-related quality of life. As speno-orbital meningioma is a rare disease with significant treatment variation, sound comparison of different treatment strategies and outcomes can only

be performed through international collaboration and harmonized data collection. In lack of that, we present outcome data of our recent small series and make an argument for surgical intervention of spheno-orbital meningiomas, even in patients with limited visual impairments or hyperostosis, as worse preoperative visual acuity, and greater diameter of hyperostosis were predictors of poorer visual outcome.

**Funding:**

The Leiden University Medical Center provided financial support in the form of a personal MD/PhD grant funding for AHZN. The sponsor had no role in the design or conduct of this research.

**Acknowledgements:**

None

**Conflicts of interest:**

All authors certify that they have no affiliations with or involvement in any organization or entity with any financial interest (such as honoraria; educational grants; participation in speakers' bureaus; membership, employment, consultancies, stock ownership, or other equity interest; and expert testimony or patent-licensing arrangements), or non-financial interest (such as personal or professional relationships, affiliations, knowledge or beliefs) in the subject matter or materials discussed in this manuscript.

**Ethics approval:**

All procedures performed in studies involving human participants were in accordance with the ethical standards of the institutional and/or national research committee (name of institute/committee) and with the 1964 Helsinki declaration and its later amendments or comparable ethical standards. This cross-sectional study was approved by the medical ethical committees of the Leiden University Medical Center as part of a larger study protocol (G19.011).

**Informed consent:**

Informed consent was obtained from all individual participants included in the study. Additional informed consent was obtained from all individual participants for whom identifying information is included in this article.

**Authorship:**

AHZN, SWG, and WRvF designed the study, and collected data. AHZN performed data analysis and wrote the first and successive versions of the manuscript. All authors contributed to the interpretation of the results, intellectual content, critical revisions to the drafts of the



paper, and approved the final version. AHZN had full access to all the data in the study and had final responsibility for the decision to submit for publication.

## REFERENCES

1. Maroon JC, Kennerdell JS, Vidovich D V., Abl A, Sternau L. Recurrent sphenoid-orbital meningioma. *J Neurosurg.* 1994;80(2):202-208. doi:10.3171/jns.1994.80.2.0202
2. Ringel F, Cedzich C, Schramm J. Microsurgical technique and results of a series of 63 sphenoid-orbital meningiomas. *Neurosurgery.* 2007;60(4 SUPPL. 2):214-222. doi:10.1227/01.NEU.0000255415.47937.1A
3. Mirone G, Chibbaro S, Schiabello L, Tola S, George B. En plaque sphenoid wing meningiomas: Recurrence factors and surgical strategy in a series of 71 patients. *Neurosurgery.* 2009;65(6 SUPPL. 1):100-109. doi:10.1227/01.NEU.0000345652.19200.D5
4. Mariniello G, Bonavolontà G, Tranfa F, Maiuri F. Management of the optic canal invasion and visual outcome in sphenoid-orbital meningiomas. *Clin Neurol Neurosurg.* 2013;115(9):1615-1620. doi:10.1016/j.clineuro.2013.02.012
5. Saeed P, Van Furth WR, Tanck M, et al. Natural history of sphenoid-orbital meningiomas. *Acta Neurochir (Wien).* 2011;153(2):395-401. doi:10.1007/s00701-010-0878-0
6. Leroy HA, Leroy-Ciocanea CI, Baroncini M, et al. Internal and external sphenoid-orbital meningioma varieties: different outcomes and prognoses. *Acta Neurochir (Wien).* 2016;158(8):1587-1596. doi:10.1007/s00701-016-2850-0
7. Honig S, Trantakis C, Frerich B, et al. Sphenoid-orbital meningiomas : outcome after microsurgical treatment : a clinical review of 30 cases Sphenoid-orbital meningiomas : outcome after microsurgical treatment : a clinical review of 30 cases. *Neurol Res A.* 2013;6412(May 2017):314-325. doi:10.1179/016164109X12464612122614
8. Heufelder MJ, Sterker I, Trantakis C, et al. Reconstructive and ophthalmologic outcomes following resection of sphenoid-orbital meningiomas. *Ophthalm Plast Reconstr Surg.* 2009;25(3):223-226. doi:10.1097/IOP.0b013e3181a1f345
9. Freeman JL, Davern MS, Oushy S, et al. Sphenoid-Orbital Meningiomas: A 16-Year Surgical Experience. *World Neurosurg.* 2017;99:369-380. doi:10.1016/j.wneu.2016.12.063
10. Sandalcioğlu IE, Gasser T, Mohr C, Stolke D, Wiedemayer H. Sphenoid-orbital meningiomas: interdisciplinary surgical approach, resectability and long-term results. *J Craniomaxillofac Surg.* 2005;33(1010-5182 (Print)):260-266.
11. Marcus H, Schwindack C, Santarius T, Mannion R, Kirollos R. Image-guided resection of sphenoid-orbital skull-base meningiomas with predominant intraosseous component. *Acta Neurochir (Wien).* 2013;155(6):981-988. doi:10.1007/s00701-013-1662-8
12. Cannon PS, Rutherford SA, Richardson PL, King A, Leatherbarrow B. The surgical management and outcomes for sphenoid-orbital meningiomas: a 7-year review of multi-disciplinary practice. *Orbit.* 2009;28(6):371-376. doi:10.3109/01676830903104645
13. Yaşargil MG, Reichman M V., Kubik S. Preservation of the frontotemporal branch of the facial nerve using the interfascial temporalis flap for pterional craniotomy. *J Neurosurg.* 1987;67(3):463-466. doi:10.3171/jns.1987.67.3.0463
14. Genders SW, Mourits DL, Jasem M, Kloos RJHM, Saeed P, Mourits MP. Parallax-free Exophthalmometry: A Comprehensive Review of the Literature on Clinical Exophthalmometry and the Introduction of the First Parallax-Free Exophthalmometer. *Orbit.* 2015;34(1):23-29. doi:10.3109/01676830.2014.963877
15. Patino CM, Varma R, Azen SP, Conti D V., Nichol MB, McKean-Cowdin R. The impact of change in visual field on health-related quality of life: The Los Angeles Latino Eye Study. *Ophthalmology.* 2011;118(7):1310-1317. doi:10.1016/j.ophtha.2010.12.018

16. Dalle Ore CL, Magill ST, Rodriguez Rubio R, et al. Hyperostosing sphenoid wing meningiomas: surgical outcomes and strategy for bone resection and multidisciplinary orbital reconstruction. *J Neurosurg*. Published online 2020:1-10. doi:10.3171/2019.12.jns192543
17. Terrier LM, Bernard F, Fournier HD, et al. Spheno-Orbital Meningiomas Surgery: Multicenter Management Study for Complex Extensive Tumors. *World Neurosurg*. 2018;112:e145-e156. doi:10.1016/j.wneu.2017.12.182
18. Shrivastava RK, Sen C, Costantino PD, Della Rocca R. Sphenoorbital meningiomas: surgical limitations and lessons learned in their long-term management. *J Neurosurg*. 2005;103(3):491-497. doi:10.3171/jns.2005.103.3.0491
19. Talacchi A, De Carlo A, D'Agostino A, Nocini P. Surgical management of ocular symptoms in sphenoorbital meningiomas. Is orbital reconstruction really necessary? *Neurosurg Rev*. 2014;37(2):301-309. doi:10.1007/s10143-014-0517-y
20. Nagahama A, Goto T, Nagm A, et al. Spheno-Orbital Meningioma: Surgical Outcomes and Management of Recurrence. *World Neurosurg*. 2019;126:e679-e687. doi:10.1016/j.wneu.2019.02.123
21. Yannick N, Patrick F, Samuel M, et al. Predictive factors for visual outcome after resection of sphenoorbital meningiomas: A long-term review. *Acta Ophthalmol*. 2012;90(8):663-665. doi:10.1111/j.1755-3768.2012.02419.x
22. Mortini P, Gagliardi F, Boari N, Losa M. Surgical strategies and modern therapeutic options in the treatment of craniopharyngiomas. *Crit Rev Oncol Hematol*. 2013;88(3):514-529. doi:10.1016/j.critrevonc.2013.07.013
23. Raza SM, Garzon-Muvdi T, Boahene K, et al. The supraorbital craniotomy for access to the skull base and intraaxial lesions: A technique in evolution. *Minim Invasive Neurosurg*. 2010;53(1):1-8. doi:10.1055/s-0030-1247504
24. Locatelli D, Pozzi F, Turri-zanoni M, et al. Transorbital endoscopic approaches to the skull base: current concepts and future perspective. *J Neurosurg Sci*. 2016;60(December):514-528.
25. De JR, Vescan AD, Gullane PJ, et al. Development of a disease-specific quality-of-life questionnaire for anterior and central skull base pathology-The skull base inventory. *Laryngoscope*. 2012;122(9):1933-1942. doi:10.1002/lary.23426
26. Zoia C, Bongetta D, Gaetani P. Endoscopic transorbital surgery for sphenoorbital lesions: how I do it. *Acta Neurochir (Wien)*. 2018;160(6):1231-1233. doi:10.1007/s00701-018-3529-5
27. Dallan I, Castelnovo P, Locatelli D, et al. Multiportal combined transorbital transnasal endoscopic approach for the management of selected skull base lesions: preliminary experience. *World Neurosurg*. Published online 2015:1-11. doi:10.1016/j.wneu.2015.02.034
28. Lubbe D, Mustak H, Taylor A, Fagan J. Minimally invasive endo-orbital approach to sphenoid wing meningiomas improves visual outcomes - our experience with the first seven cases. *Clin Otolaryngol*. Published online 2016:1-5. doi:10.1111/coa.12722
29. He H, Li W, Liang C, et al. Eyebrow Incision for Combination Supraorbital Minicraniotomy with Orbital Osteotomy: Application to Cranio-Orbital Lesions. *World Neurosurg*. Published online 2018. doi:10.1016/j.wneu.2018.03.043
30. Almeida JP, Omay SB, Shetty SR, et al. Transorbital endoscopic eyelid approach for resection of sphenoorbital meningiomas with predominant hyperostosis: report of 2 cases. *J Neurosurg*. Published online 2017. doi:10.3171/2017.3.JNS163110.
31. Zamanipoor Najafabadi AH, Peeters MCM, Lobatto DJ, et al. Health-related quality of life of cranial WHO grade I meningioma patients: are current questionnaires relevant? *Acta Neurochir (Wien)*. 2017;159(11):2149-2159. doi:10.1007/s00701-017-3332-8

32. Zamanipoor Najafabadi AH, Peeters MCM, Lobatto DJ, et al. Impaired health-related quality of life of meningioma patients - a systematic review. *Neuro Oncol.* 2017;17(9):897-907. doi:10.1093/neuonc/now250
33. Fukuda H, Evins AI, Burrell JC, Iwasaki K, Stieg PE, Bernardo A. The meningo-orbital band: Microsurgical anatomy and surgical detachment of the membranous structures through a frontotemporal craniotomy with removal of the anterior clinoid process. *J Neurol Surgery, Part B Skull Base.* 2014;75(2):125-132. doi:10.1055/s-0033-1359302
34. Boari N, Gagliardi F, Spina A, Bailo M, Franzin A, Mortini P. Management of sphenoid orbital en plaque meningiomas: Clinical outcome in a consecutive series of 40 patients. *Br J Neurosurg.* 2013;27(May 2017):84-90. doi:http://dx.doi.org/10.3109/02688697.2012.709557
35. Combs SE, Ganswindt U, Foote RL, Kondziolka D, Tonn JC. State-of-the-art treatment alternatives for base of skull meningiomas: Complementing and controversial indications for neurosurgery, stereotactic and robotic based radiosurgery or modern fractionated radiation techniques. *Radiat Oncol.* 2012;7(1):1-9. doi:10.1186/1748-717X-7-226
36. Shapey J, Jung J, Barkas K, et al. A single centre's experience of managing sphenoid orbital meningiomas: lessons for recurrent tumour surgery. *Acta Neurochir (Wien).* 2019;161(8):1657-1667. doi:10.1007/s00701-019-03977-3
37. Rogers L, Barani I, Chamberlain M, et al. Meningiomas: Knowledge base, treatment outcomes, and uncertainties. A RANO review. *J Neurosurg.* 2015;122(1):4-23. doi:10.3171/2014.7.JNS131644
38. Mariniello G, Maiuri F, Strianese D, et al. Sphenoid orbital meningiomas: Surgical approaches and outcome according to the intraorbital tumor extent. *Zentralbl Neurochir.* 2008;69(4):175-181. doi:10.1055/s-2008-1077077
39. Scarone P, Leclercq D, Hérin F, Robert G. Long-term results with exophthalmos in a surgical series of 30 sphenoid orbital meningiomas: Clinical article. *J Neurosurg.* 2009;111(5):1069-1077. doi:10.3171/2009.1.JNS081263
40. Gonen L, Nov E, Shimony N, Shofty B, Margalit N. Sphenoid orbital meningioma: surgical series and design of an intraoperative management algorithm. *Neurosurg Rev.* 2018;41(1):291-301. doi:10.1007/s10143-017-0855-7
41. Essa AA, Hamdan AR. Sphenoid meningioma en plaque with proptosis: Surgical excision, reconstruction and outcome. *Clin Neurol Neurosurg.* 2018;167:147-156. doi:10.1016/j.clineuro.2018.02.028

## SUPPLEMENTS

**Supplementary Table 1: baseline predictors for short-term (3-months) postoperative best corrected visual acuity (BCVA), visual fields and proptosis**

	Beta	95%CI	p-value
<b>BCVA</b>			
Tumor diameter in mm	-0.007	-0.026 to 0.012	0.458
Diameter hyperostosis in mm	-0.005	-0.026 to 0.016	0.630
Simpson grade (I-V)	-0.067	-0.237 to 0.103	0.416
Number tumors	-0.120	-0.245 to 0.005	0.059
BCVA (Snellen chart)	0.487	0.207 to 0.766	0.002
Age at surgery in years	0.002	-0.019 to 0.023	0.874
<b>Visual Fields</b>			
Tumor diameter in mm	0.041	-0.074 to 0.156	0.441
Diameter hyperostosis in mm	-0.040	-0.123 to 0.044	0.316
Simpson grade (I-V)	-0.020	-0.885 to 0.844	0.959
Number tumors	-0.175	-0.660 to 0.309	0.439
Visual field mean deviation in dB	0.098	0.098 to 0.230	0.124
Age at surgery in years	-0.023	-0.089 to 0.044	0.466
<b>Proptosis</b>			
Tumor diameter in mm	0.049	-0.039 to 0.136	0.255
Diameter hyperostosis in mm	0.039	-0.056 to 0.133	0.399
Simpson grade (I-V)	0.343	-0.437 to 1.123	0.366
Number tumors	-0.124	-0.764 to 0.516	0.687
Proptosis in mm	0.466	0.156 to 0.775	0.006
Age at surgery in years	-0.083	-0.170 to -0.004	0.059

**Supplementary Table 2: baseline predictors for long-term (median 2.4 years) postoperative best corrected visual acuity (BCVA), visual fields and proptosis**

	Beta	95%CI	p-value
<b>Visual Acuity</b>			
Tumor diameter in mm	-0.004	-0.024 to 0.015	0.634
Diameter hyperostosis in mm	0.004	-0.017 to 0.025	0.716
Simpson grade (I-V)	-0.080	-0.248 to 0.089	0.332
Number tumors	-0.143	-0.261 to -0.024	0.021
BCVA (Snellen chart)	0.489	0.210 to 0.767	0.002
Age at surgery in years	-0.005	-0.026 to 0.015	0.596
<b>Visual Fields</b>			
Tumor diameter in mm	-0.009	-0.366 to 0.348	0.959
Diameter hyperostosis in mm	-0.393	-0.670 to -0.116	0.009
Simpson grade (I-V)	-3.705	-6.633 to -0.777	0.017
Number tumors	0.508	-2.231 to 3.247	0.695
Visual field mean deviation in dB	0.331	-0.313 to 0.975	0.284
Age at surgery in years	0.174	-0.170 to 0.519	0.294
<b>Proptosis</b>			
Tumor diameter in mm	0.066	-0.054 to 0.186	0.262
Diameter hyperostosis in mm	0.035	-0.097 to 0.166	0.557
Simpson grade (I-V)	0.514	-0.551 to 1.580	0.323
Number tumors	0.415	-0.442 to 1.272	0.321
Proptosis in mm	0.364	-0.140 to 0.867	0.146
Age at surgery in years	-0.048	-0.178 to 0.082	0.446

