



Universiteit
Leiden
The Netherlands

Descemet membrane endothelial keratoplasty: graft rejection, failure and survival

Baydoun, L.

Citation

Baydoun, L. (2021, December 1). *Descemet membrane endothelial keratoplasty: graft rejection, failure and survival*. Retrieved from <https://hdl.handle.net/1887/3247928>

Version: Publisher's Version

License: [Licence agreement concerning inclusion of doctoral thesis in the Institutional Repository of the University of Leiden](#)

Downloaded from: <https://hdl.handle.net/1887/3247928>

Note: To cite this publication please use the final published version (if applicable).

CHAPTER 8

Combined Specular Microscopy
and Scheimpflug Imaging to Improve
Detection of an Upcoming Allograft
Rejection after DMEK

Acta Ophthalmol 2020;98:261-6

Lamis Baydoun, Marieke Bruinsma, Diana Santander-García,
Lisanne Ham, Silke Oellerich, Gerrit R.J. Melles

ABSTRACT

Purpose: To assess whether combined analysis of specular microscopy and Scheimpflug imaging improves detection of an upcoming allograft rejection following Descemet membrane endothelial keratoplasty (DMEK).

Methods: Retrospective analysis of 22 eyes that had developed a clinical proven allograft rejection 28 (± 22) months (range: 4–84 months) after DMEK. Specular microscopy and Scheimpflug images routinely made after DMEK were retrospectively analysed for changes in endothelial cell morphology (e.g., nuclear activation), cell density ($>10\%$) and pachymetry ($>7\%$), and/or the presence of subclinical keratic precipitates. The same parameters were evaluated for 22 control eyes matched for age, gender, and surgery indication.

Results: A total of 20/22 eyes (91%) showed detectable changes 0.25–75 months before allograft rejection became clinically manifest: 13/22 (59%) showed both specular microscopy and Scheimpflug imaging changes; 5/22 (23%) only had changes on Scheimpflug imaging; and 2/22 (9%) only had specular microscopy changes. In 18/22 (82%) and 14/22 (64%) eyes, subclinical keratic precipitates and endothelial cell morphology changes could be detected, respectively. A total of 11/22 (50%) eyes concurrently showed a $>10\%$ drop in endothelial cell density and 4/22 (18%) a $>7\%$ pachymetry increase. Of the control eyes, 7/22 (32%) showed changes with specular microscopy but not with Scheimpflug imaging.

Conclusions: Combined analysis of specular microscopy and Scheimpflug imaging may allow recognizing an upcoming allograft rejection in over 90% of eyes and up to 6 years before rejection becomes clinically manifest. Early recognition of eyes at risk may allow for targeted intensified steroid treatment to prevent endothelial cell damage associated with rejection.

INTRODUCTION

Descemet membrane endothelial keratoplasty (DMEK), the selective replacement of the diseased endothelial cell layer, offers several advantages, including relatively quick and near complete visual recovery (Rodríguez-Calvo-de-Mora et al. 2015; Oellerich et al. 2017; Price et al. 2017; Deng et al. 2018). DMEK may also be associated with a lower risk of allograft rejection of 1–2%, compared to that in penetrating keratoplasty (10–15%) and Descemet stripping (automated) endothelial keratoplasty (DSEK/DSAEK) (5–10%) (Thompson et al. 2003; Allan et al. 2007; Claesson & Armitage 2009; Jordan et al. 2009; Lee et al. 2009; Dapena et al. 2011a; Anshu et al. 2012; Li et al. 2012; Wu et al. 2012).

Still allograft rejection is one of the more severe complications that may result in endothelial cell damage and secondary graft failure (Anshu et al. 2012; Williams et al. 2012). Hence, to be able to recognize and treat early signs of an immune reaction to possibly prevent manifestation of rejection would be desirable. We have recently shown that specific changes in endothelial cell morphology with specular microscopy may precede rejection (Monnereau et al. 2014). Likewise, Scheimpflug imaging may allow for detection of subtle immune reactions (keratic precipitates not seen on biomicroscopy) and pachymetric deviations may be expected to occur before rejection becomes clinically manifest (Baydoun et al. 2016). Therefore, to increase the power of our method to recognize upcoming allograft rejections, the various measurements and displaying techniques may be combined to work towards an improved algorithm for early allograft detection in post-DMEK eyes.

The aim of the current study was to correlate the findings of specular microscopy and Scheimpflug imaging in order to assess whether combining these diagnostic devices has added value in detecting eyes at risk of rejection after DMEK.

MATERIALS AND METHODS

From a series of 1077 consecutive DMEK eyes of 741 patients with a mean follow-up time of 64 (± 33) months (range: 3–139 months), 27 eyes (2.5%) of 26 patients developed a clinical proven allograft rejection 2–84 months (median 19 months) after surgery. Five eyes were excluded from analysis owing to poor image quality (two eyes with congenital glaucoma) or the occurrence of a rejection ≤ 3 months after DMEK (so that no baseline images were available) (Table 1). Hence, 22 eyes

Table 1. Demographics of rejection and control eyes after Descemet membrane endothelial keratoplasty

	Study group rejection eyes	Control group non-rejection eyes
Eyes / Patients (n)	22/21	22/22
Mean age (years) \pm SD (range)	66 \pm 13 (30-80)	67 \pm 11 (44-79)
Average time-point of rejection (months), (median, range)	28 \pm 22 (25, 4-84)	--
Gender (male/female)	12/9	13/9
Pseudophakic/phakic	17/5	18/4
Preoperative diagnosis		
FECD	17	18
Pseudophakic BK	--	1
BK		
(removed) phakic IOL	1	--
In the presence of a glaucoma tube	2	--
Pseudophakic eye with radial keratotomy, extra incisions, LASIK	--	1
Failed DSEK (presence of glaucoma tube and AC-IOL)	2 (1)	2 (0)
Mean donor age (years) \pm SD (range)	66 \pm 11 (48-84)	67 \pm 11 (48-85)
Excluded eyes (5 out of 27 rejection cases)		
Eyes with rejection \leq 3 months after DMEK (FED, PPBK, removed phakic IOL)	3	--
Eyes with poor image quality (congenital glaucoma)	2	0

AC-IOL: Anterior chamber intraocular lens

DSEK: Descemet stripping endothelial keratoplasty

FECD: Fuchs endothelial corneal dystrophy

PPBK: Pseudophakic bullous keratopathy

SD: Standard deviation

of 21 patients (9 female/12 male; 17 pseudophakic/5 phakic; aged 66 (\pm 13) years) were included in our retrospective study (Table 1). DMEK was performed for Fuchs endothelial corneal dystrophy ($n = 17$), bullous keratopathy owing to phakic intraocular lens removal ($n = 1$) or a glaucoma drainage device ($n = 2$), and for failed DSEK ($n = 2$) (Table 1). All included rejection eyes have been operated between January 2008 and January 2016. In addition, 22 eyes matched for age, gender, and surgery indication without a rejection episode after DMEK were included as normal controls and were evaluated until the last available follow-up point (Table 1). None of the rejection or control eyes that received DMEK after failed DSAEK had a rejection episode in the earlier DSAEK graft.

All patients had signed an IRB-approved informed consent for research participation prior to surgery. The study adhered to the Declaration of Helsinki.

Rejection episode

Graft rejection was defined as an event with objective clinical findings (rejection line, keratic precipitates with or without an increase in corneal thickness, anterior uveitis and/or ciliary injection) on slit-lamp examination, with or without subjective complaints.

Allograft rejection after DMEK was treated with topical steroids while the frequency of the steroid application (four times per day to hourly) depended on the clinical appearance of rejection (mild, only keratic precipitates/severe, corneal decompensation). Four eyes of the study group developed endothelial graft failure after allograft rejection and needed regrafting.

Donor tissue processing and DMEK surgery

Descemet membrane endothelial keratoplasty (DMEK) grafts were prepared as described previously and then stored in organ culture medium until the time of transplantation (Lie et al. 2008; Groeneveld-van Beek et al. 2013). Average donor age for the study and control group was 66 (± 11) and 67 (± 11) years, respectively (Table 1).

'No-touch' DMEK surgery was performed in all cases in a standardized manner as described in detail earlier (Dapena et al. 2011b). In eyes that underwent DMEK as a secondary procedure, the primary DSEK graft was removed from the recipient posterior stroma using a reversed Sinsky hook in an anterior chamber filled with air.

At the end of surgery, subconjunctival dexamethasone and gentamicin were injected. Postoperative treatment consisted of topical antibiotics for two weeks, and a steroid regime of dexamethasone 0.1% four times daily for four weeks, followed by fluorometholone 0.1% four times daily, tapered to once daily at 1 year postoperatively and once daily or once every other day thereafter (Dapena et al. 2011b).

Measurements and analysis

All eyes were evaluated before surgery, and postoperatively at 3, 6, 9 and 12 months and at 6-month intervals thereafter, with specular microscopy to moni-

tor endothelial cell morphology and density (Topcon SP3000, Topcon Europe Medical, The Netherlands).

Central endothelial cell morphology was graded by three masked observers (LB, MB and SO) on a scale from 1 to 5 as previously described (Figure 1, top row) (Monnereau et al. 2014): (1) ‘quiet’ endothelial cell layer with a regular cell morphology and distribution, that is a cell layer of inactivated cells with no nuclei visible and a hexagonal cell pattern without exhibiting polymorphism and polymegathism; (2)

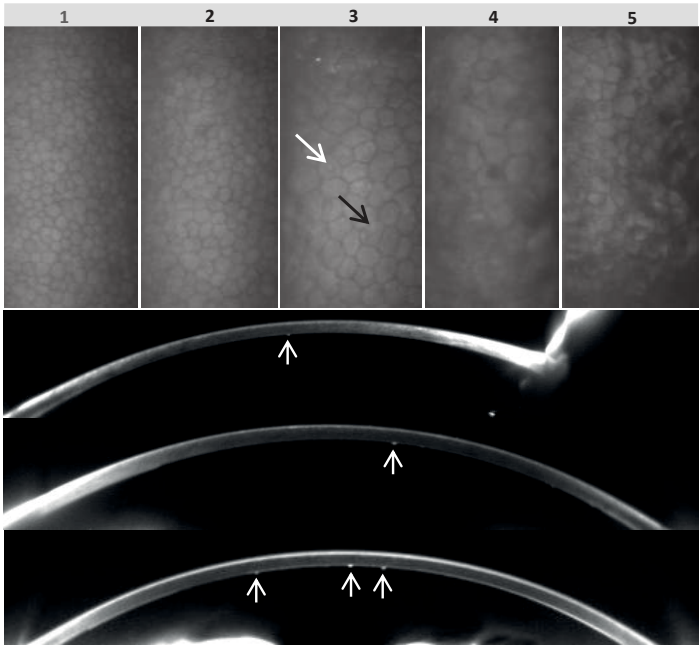


Figure 1. Examples of specular microscopy and Scheimpflug images in eyes following rejection after Descemet Membrane Endothelial Keratoplasty (DMEK). Specular microscopy images (top row) and Scheimpflug images (bottom rows) displaying the sequential stages used to subjectively score endothelial cell morphology on a scale from 1 to 5 (top row, left to right): quiet endothelial cell layer with a regular cell morphology and distribution, without any sign of cellular activation (1); slightly irregular endothelial cell morphology and/or distribution, without any sign of cellular activation (2); mild to moderate irregular endothelial cell morphology and/or distribution, with mild to moderate appearance of cellular activation. Note the increased cellular reflectivity (black arrow) with detectable cell nuclei (white arrow) (3); severe irregular endothelial cell morphology and/or distribution, and clear presence of cellular activation with enlarged cell nuclei (4); extreme irregular endothelial cell morphology and/or distribution, and presence of highly activated cells (5). (bottom rows, top to bottom) Scheimpflug images of three DMEK eyes showing different densities of keratic precipitates (arrows) from localized small keratic precipitates one month before rejection to more prominent keratic precipitates 5.5 years before rejection and to multiple keratic precipitates 12 months, respectively, before rejection was diagnosed.

slightly irregular endothelial cell morphology and/or distribution, but without any sign of cellular activation, that is visibility of cellular nuclei and/or increased cellular reflectivity; (3) mild to moderate irregular endothelial cell morphology and/or distribution, and mild to moderate appearance of cellular activation; (4) severe irregular endothelial cell morphology and/or distribution, and clear presence of cellular activation with enlarged cell nuclei; (5) extreme irregular endothelial cell morphology and/or distribution, and presence of highly activated cells (Figure 1, top row). An average score of >2.5 was considered significant at any of the follow-up points (Monnereau et al. 2014).

For endothelial cell density analysis, the automatically delineated cell borders were manually corrected. Three central images of each eye were analysed per follow-up point, and the results were averaged. A drop in endothelial cell density of $>10\%$ between follow-up points (≤ 6 months) was considered significant.

At corresponding follow-up points, Scheimpflug images (Pentacam, Oculus, Wetzlar Germany) were evaluated by the same observers for keratic precipitates, seen as hyperreflective retrocorneal deposits varying in size and density as previously described (Figure 1, bottom rows) (Baydoun et al. 2016). For each measurement, the Scheimpflug camera generates 25 images over 360° to produce the three-dimensional image; for each eye, all 25 scans taken were analysed up to the time-point before rejection. Scheimpflug-based central corneal thickness was measured and the differences between consecutive visits calculated. A pachymetry change of $>7\%$ between follow-up points (≤ 6 months) was considered a significant change (Baydoun et al. 2016).

RESULTS

From the 22 eyes in our study with an average rejection time-point of 28 (± 22) months (median: 25 months, range: 4–84 months) after DMEK, 20 eyes (91%) retrospectively showed detectable changes on specular microscopy (endothelial cell morphology change and/or endothelial cell density decrease) and/or with Scheimpflug imaging (subclinical keratic precipitates and/or pachymetry increase) up to 75 months (median: 10 months, range: 0.25–75 months) before allograft rejection became clinically manifest (Figure 2; Table 2) and only two eyes showed no alterations throughout the entire studied period (Figure 2, Table 2). In total, 13 out of the 22 eyes (59%) showed concomitant alterations with specular microscopy and Scheimpflug imaging (Figure 2, Table 2). In five eyes

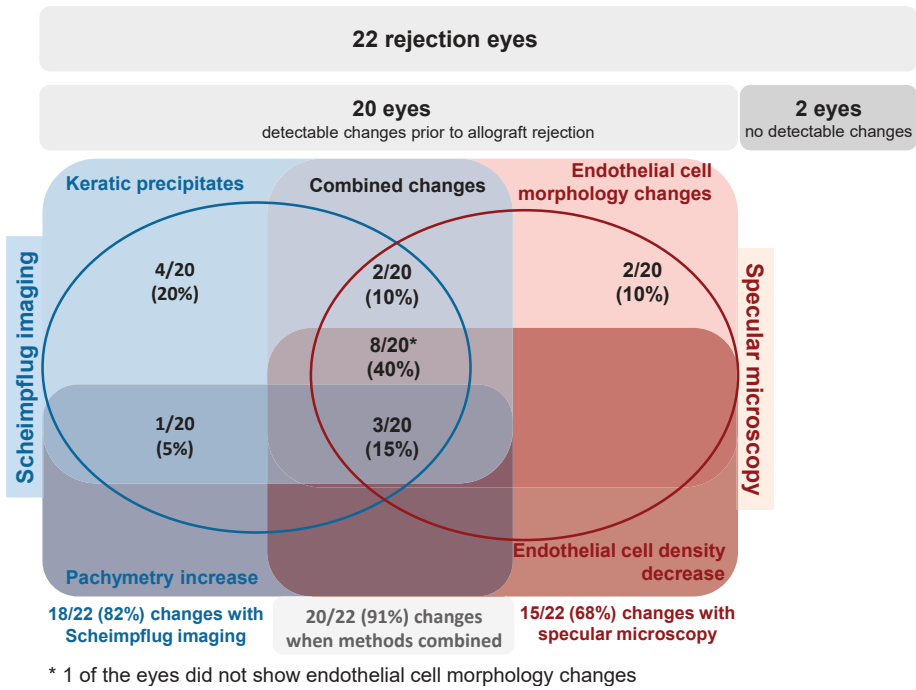


Figure 2. Diagram illustrating all study eyes and the distribution of subclinical changes recognized in those eyes prior to clinical manifestation of allograft rejection after Descemet Membrane Endothelial Keratoplasty: with Scheimpflug imaging (subclinical keratic precipitates and increase in pachymetry) and specular microscopy (changes in endothelial cell morphology and decrease in cell density). Asterisk indicates that one of those eyes did not show endothelial cell morphology changes.

(23%), changes were only seen with Scheimpflug imaging (keratic precipitates $n = 4$, pachymetry increase $n = 1$) and in two eyes (9%) only on specular microscopy (endothelial cell morphology changes $n = 2$) (Figure 2, Table 2). Changes with specular microscopy were observed in 15/22 eyes (68%) (Figure 2, Table 2): 14/22 eyes (64%) had endothelial cell morphology changes 1–50 months before rejection (on average $17 (\pm 13)$ months, median 17 months, average scores between 2.6 and 5) and 11/22 eyes (50%) had at least once a $>10\%$ (range 11–44%) endothelial cell density decrease between the follow-up points 1–26 months before rejection (on average $13 (\pm 8)$ months, median 13 months). Both parameters concurred in 10 eyes (Table 2).

Changes with Scheimpflug imaging were observed in 18/22 eyes (82%) (Figure 2, Table 2): All 18/22 eyes (82%) showed keratic precipitates 0.25–75 months before rejection (on average $18 (\pm 20)$ months, median 11 months), and four of these eyes

(4/22, 18%) also had a pachymetry increase of >7% 1–23 months before rejection (on average 13 (\pm 11) months, median 14 months).

The combination of keratic precipitates and endothelial cell morphology changes concurred in 12 eyes of which 10 eyes also showed endothelial cell decrease and three eyes a pachymetry increase (Figure 2, Table 2). Hence, in three eyes all four parameters concurred.

During the follow-up period of up to 8.5 years, 7/22 control eyes (32%) retrospectively showed detectable changes with specular microscopy but not with Scheimpflug imaging. Six eyes either had endothelial cell morphology changes ($n = 2$, average scores between 2.6 and 2.9) or a high endothelial cell density decrease ($n = 4$) while in one eye both changes concurred. In the latter eye, a continuous endothelial cell density decay was noted postoperatively from 3 years onwards which resulted in endothelial graft failure 7 years after DMEK; intraocular inflammation was absent at all follow-up time-points (Table 2).

DISCUSSION

We have recently shown that specular microscopy and Scheimpflug imaging may be useful diagnostics in the recognition of eyes that may be at risk of allograft rejection following DMEK. Our current study showed that prerejection changes in corneas that underwent DMEK could be detected in 68% of the eyes with specular microscopy and in 82% of the eyes with Scheimpflug imaging. When both these methods were combined, about 90% of the eyes could be recognized of being at risk of developing allograft rejection. If so, a proper algorithm weighing the combined assessment and adequate topical steroid regimens might potentially reduce the incidence of long-term post-DMEK rejections from 1–2.5% to $\leq 0.25\%$ (Dapena et al. 2011a; Anshu et al. 2012; Monnereau et al. 2014; Baydoun et al. 2016; Hos et al. 2017).

Interestingly, normal control eyes also showed alterations in 32% of the cases. However, these alterations were limited to specular microscopy changes which were in general less pronounced (lower average scores) than the alterations seen in the rejection eyes. In addition, the changes did not continuously deteriorate in time as could be observed in some rejection eyes. One exception was the control eye that developed secondary graft failure (absent of rejection), a condi-

Table 2. Overview of changes in rejection eyes and matched control eyes

Rejection Group					Control Group			
Rejection Case # (Gender, Age)	Surgery indication	Time-point of rejection	FU (m) with first changes	Overview of changes given in chronological order (first changes = underlined)	Matched Control Case # (Gender, Age)	Surgery indication	FU (m) with first changes	Overview of changes given in chronological order
1 (M,44)	FECD	30	12	<u>ECD decrease</u> , KPs, EC changes	1 (M,47)	FECD	48	ECD decrease, EC changes (endothelial failure)
2 (F,76)	FECD	4	3	EC changes	2 (F,77)	FECD	3	EC changes
3 (M,67)	FECD	84	9	KPs	3 (M,68)	FECD	--	--
4 (M,61)^	FECD	42	18	<u>KPs, EC changes, ECD decrease</u>	4 (M,59)	FECD	--	--
5 (M,62)^	FECD	10	3	EC changes	5 (M,63)	FECD	--	--
6 (F,30)	BK*	18	9	KPs	6 (F,48)	FECD	36	ECD decrease
7 (F,57)	FECD	80	24	<u>KPs, EC changes, ECD decrease</u>	7 (F,58)	FECD	--	--
8 (F,76)	FECD	31	24	<u>ECD decrease</u> , KPs	8 (F,79)	FECD	--	--
9 (F,77)	FECD	58	48	KPs	9 (F,77)	FECD	--	--
10 (M,62)	FECD	38	18	<u>KPs, EC changes</u>	10 (M,65)	FECD	--	--
11 (F,78)	FECD	27	3	<u>KPs, EC changes, ECD decrease, Pachy increase</u>	11 (F,79)	FECD	36	ECD decrease
12 (M,77)	Failed DSEK	7	3	<u>KPs, EC changes, ECD decrease, Pachy increase</u>	12 (M,77)	Failed DSEK	--	--
13 (M,40)	FECD	19	13	<u>KPs, EC changes, ECD decrease</u>	13 (M,44)	FECD	--	--
14 (M,71)	FECD	30	9	<u>Pachy increase</u> , KPs	14 (M,72)	FECD	6	EC changes
15 (M,72)	FECD	24	6	<u>ECD decrease</u> , KPs, EC changes	15 (M,73)	FECD	12	ECD decrease
16 (M,78)	FECD	6	5,75	KPs	16 (M,75)	FECD	24	ECD decrease
17 (M,63)	BK†	9	3	<u>EC changes, ECD decrease</u> , KPs	17 (M,62)	BK%	--	--
18 (M,61)	FECD	26	16	<u>KPs, EC changes</u>	18 (M,63)	FECD	--	--

Table 2. Overview of changes in rejection eyes and matched control eyes (continued)

Rejection Group					Control Group			
Rejection Case # (Gender, Age)	Surgery indication	Time-point of rejection	FU (m) with first changes	Overview of changes given in chronological order (first changes = underlined)	Matched Control Case # (Gender, Age)	Surgery indication	FU (m) with first changes	Overview of changes given in chronological order
19 (F,72)	Failed DSEK#	32	9	<u>EC changes</u> , Pachy increase, ECD decrease, KPs	19 (F,73)	Failed DSEK	--	--
20 (F,76)	FECD	24	--	--	20 (F,76)	FECD	--	--
21 (M,80)	BK†	7	4	<u>KPs</u> , <u>EC changes</u> , <u>ECD decrease</u>	21 (M,75)	PPBK	--	--
22 (F,66)	FECD	15	--	--	22 (F,65)	FECD	--	--

* Removed phakic IOL; † Glaucoma tube; # Combined with glaucoma tube & anterior chamber intraocular lens, % Post radial keratotomy, ^ Eyes of the same patient
ECD = Endothelial cell density; Pachy = Pachymetry; FECD = Fuchs endothelial corneal dystrophy, BK= Bullous keratopathy; KPs=Keratic precipitates; DSEK=Descemet stripping endothelial keratoplasty; M/F= Male/Female; PPBK = Pseudophakic bullous keratopathy; FU = Follow-up; m = Months

tion that may also go along with endothelial cell changes as described earlier (Zygoura et al. 2017).

Specular microscopy and Scheimpflug imaging are established methods to monitor post-keratoplasty corneas by assessing a decrease in endothelial cell density (on specular microscopy) and an increase in corneal thickness (with Scheimpflug imaging). This combination of changes may be expected to occur in secondary graft failure not associated with allograft rejection (Lass et al. 2010; Benetz et al. 2013; Baydoun et al. 2015). However, if associated with an upcoming rejection episode, our study showed that these two criteria are virtually always seen in combination with changes in endothelial cell morphology and/or the presence of subclinical keratic precipitates. Notably, the latter two parameters may be directly obtained from the taken measurement, while endothelial cell density decrease and pachymetry increase need to first be calculated.

In addition, within our study group, keratic precipitates and/or endothelial cell morphology changes (82% and 64%, respectively) were observed more often than endothelial cell density decrease or pachymetry increase (50% and 18%, respectively). And the latter two parameters always concurred with keratic precipitates and/or endothelial cell morphology changes. This may agree with the likely pathologic pathway associated with allograft rejection: the immune system may be primarily activated which results in leucocyte (keratic precipitates) and endothelial cell activation (nuclear swelling), which over time results in endothelial cell damage and/or cell death (decrease in endothelial cell density) and consequently corneal decompensation (increase in pachymetry) (Nieder Korn & Larkin 2010).

To avoid graft failure due to allograft rejection following DMEK (Claerhout et al. 2003; Baydoun et al. 2015), reversion of a (subclinical) immune reaction at its earliest stage to prevent a full-blown rejection from manifestation should be the main treatment goal. Considering the above observations, as a preliminary algorithm to make the decision to start treatment, we now use the following criteria: 1) progression of subclinical keratic precipitates either isolated or in combination with a continuous degradation in endothelial cell morphology during closer follow-up visits or any other parameter, and 2) a significant decrease in cell density and/or increase in pachymetry, in combination with subclinical keratic precipitates or a degradation in endothelial cell morphology.

Unnecessary or overtreatment with steroids may always be a risk, but if in doubt whether to start intensified steroids, the patient can be monitored more closely by reducing the time until the next follow-up visit. From experience, we learned that reducing the interval between examination often makes the decision on treatment relatively easy without putting the eye at risk.

A limiting factor is that eyes that develop an allograft rejection within the first three to six months may escape detection, because they lack baseline measurements for comparison between follow-up intervals (i.e., it is difficult to determine significant changes if no or just one prior scan is available). In addition, the low rejection rates and the retrospective study design allow only the inclusion of a limited number of eyes and require cautious interpretation of the data. Hence, to determine the benefit of early (prerejection) treatment of eyes at risk of rejection, the rejection group would ideally be compared to a group of eyes at risk that did not receive treatment, which would probably need to be investigated in a prospective multicenter setting.

To prevent 90% of post-DMEK allograft rejections, both specular microscopy and Scheimpflug imaging would need to be performed at 6-month intervals, which is seen as a normal cycle in hospitals and specialized clinics to monitor patients after keratoplasty. Although the additional evaluation of images for keratic precipitates and endothelial cell morphology changes could be seen as a burden for clinicians, in our experience, the screening described in the current study is rather quick, as is the assessment of the images by a trained eye.

REFERENCES

1. Anshu A, Price MO, Price F Jr. Risk of corneal transplant rejection significantly reduced with Descemet's membrane endothelial keratoplasty. *Ophthalmology* 2012;119:536-40
2. Baydoun L, Ham L, Borderie V, et al. Endothelial survival after Descemet membrane endothelial keratoplasty. *JAMA Ophthalmol* 2015; 133:1277-79
3. Baydoun L, Livny E, Ham L, Bruinsma M, Melles GRJ. 360-Degree Scheimpflug imaging to predict allograft rejection after Descemet membrane endothelial keratoplasty. *Cornea* 2016;35:1385-90
4. Benetz BA, Lass JH, Gal RL et al. Endothelial morphometric measures to predict endothelial graft failure after penetrating keratoplasty. *JAMA Ophthalmol* 2013;131:601-8
5. Claerhout I, Beele H, De Bacquer D, Kestelyn P. Factors influencing the decline in endothelial cell density after corneal allograft rejection. *Invest Ophthalmol Vis Sci* 2003;44:474-52
6. Claesson M & Armitage WJ. Ten-year follow-up of graft survival and visual outcome after penetrating keratoplasty in Sweden. *Cornea* 2009;28:1124-9
7. Dapena I, Ham L, Netukova M, van der Wees J, Melles GR. Incidence of early allograft rejection after Descemet membrane endothelial keratoplasty. *Cornea* 2011;30:1341-5
8. Dapena I, Moutsouris K, Droutsas K, et al. Standardized "no-touch" technique for Descemet membrane endothelial keratoplasty. *Arch Ophthalmol* 2011;129:88-94
9. Deng SX, Lee WB, Hammersmith KM, et al. Descemet membrane endothelial keratoplasty: safety and outcomes: a report by the American Academy of Ophthalmology. *Ophthalmology* 2018;125:295-310
10. Groeneveld-van Beek EA, Lie JT, Van der Wees J, Bruinsma M, Melles GR. Standardized "no-touch" donor tissue preparation for DALK and DMEK: harvesting undamaged anterior and posterior donor transplants from the same donor cornea. *Acta Ophthalmol* 2013;91:145-50
11. Hos D, Tuac O, Schaub F, Stanzel TP, et al. Incidence and clinical course of immune reactions after Descemet membrane endothelial keratoplasty: retrospective analysis of 1000 consecutive eyes. *Ophthalmology* 2017;124:512-18
12. Jordan CS, Price MO, Trespalacios R, Price FW Jr. Graft rejection episodes after Descemet stripping with endothelial keratoplasty: part one: clinical signs and symptoms. *Br J Ophthalmol* 2009;93:387-90
13. Lass JH, Sugar A, Benetz BA et al. Endothelial cell density to predict endothelial graft failure after penetrating keratoplasty. *Arch Ophthalmol* 2010;128:63-9
14. Lee WB, Jacobs DS, Musch DC, et al. Descemet's stripping endothelial keratoplasty: safety and outcomes: a report by the American Academy of Ophthalmology. *Ophthalmology* 2009;116:1818-30
15. Li JY, Terry MA, Goshe J, Shamie N, Davis Boozer D. Graft rejection after Descemet's stripping automated endothelial keratoplasty: graft survival and endothelial cell loss. *Ophthalmology* 2012;119:90-4
16. Lie JT, Birbal R, Ham L, van der Wees J, Melles GR. Donor tissue preparation for Descemet membrane endothelial keratoplasty. *J Cataract Refract Surg* 2008;34:1578-83
17. Monnereau C, Bruinsma M, Ham L, et al. Endothelial cell changes as an indicator for upcoming allograft rejection following Descemet membrane endothelial keratoplasty. *Am J Ophthalmol* 2014;158:485-95

18. Niederkorn JY, Larkin DF. Immune privilege of corneal allografts. *Ocul Immunol Inflamm* 2010;18:162-71
19. Oellerich S, Baydoun L, Peraza-Nieves J, et al. Multicenter study of 6-month clinical outcomes after Descemet membrane endothelial keratoplasty. *Cornea* 2017;36:1467-76
20. Price MO, Gupta P, Lass J, Price FW Jr. EK (DLEK, DSEK, DMEK): new Frontier in Cornea Surgery. *Annu Rev Vis Sci* 2017;15:69-90
21. Rodríguez-Calvo-de-Mora M, Quilendrino R, Ham L et al. Clinical outcome of 500 consecutive cases undergoing Descemet's membrane endothelial keratoplasty. *Ophthalmology* 2015;122:464-70
22. Thompson RW Jr, Price MO, Bowers PJ, Price FW . Jr. Long-term graft survival after penetrating keratoplasty. *Ophthalmology* 2003;110:1396-1402
23. Williams KA, Lowe MT, Keane MC et al. The Australian corneal graft registry 2012 report. Adelaide, Snap Printing, 2012 report
24. Wu EI, Ritterband DC, Yu G, Shields RA, Seedor JA Graft rejection following Descemet stripping automated endothelial keratoplasty: features, risk factors, and outcomes. *Am J Ophthalmol* 2012 153:949-57
25. Zygoura V, Baydoun L, Monnereau C, et al. Dark endothelial spots after Descemet membrane endothelial keratoplasty may appear as recurrent Fuchs dystrophy or herald graft failure or rejection. *Cornea* 2017;36:1480-85

