



Universiteit  
Leiden

The Netherlands

## **A multidisciplinary approach to improve treatment strategies for patients with hepatic or pancreatic cancer**

Leede, E.M. de

### **Citation**

Leede, E. M. de. (2021, December 1). *A multidisciplinary approach to improve treatment strategies for patients with hepatic or pancreatic cancer*. Retrieved from <https://hdl.handle.net/1887/3244234>

Version: Publisher's Version

License: [Licence agreement concerning inclusion of doctoral thesis in the Institutional Repository of the University of Leiden](#)

Downloaded from: <https://hdl.handle.net/1887/3244234>

**Note:** To cite this publication please use the final published version (if applicable).



# CHAPTER 4



## **Percutaneous Hepatic Perfusion (PHP) with melphalan as a treatment for unresectable metastases confined to the liver**

E.M. de Leede, M.C. Burgmans, C.H. Martini, A.R. van Erkel, F.G.J. Tijn,  
E. Kapiteijn, C. Verhoef, J. Vuyk, C.J.H. van de Velde and A.L. Vahrmeijer  
Journal of Visualized Experiments, July 2016

## ABSTRACT

Unresectable liver metastases of colorectal cancer can be treated with systemic chemotherapy, aiming to limit the disease, extend survival or turn unresectable metastases into resectable ones. Some patients however, suffer from side effects or progression under systemic treatment. For patients with metastasized uveal melanoma there are no standard systemic therapy options. For patients without extrahepatic disease, isolated liver perfusion (IHP) may enable local disease control with limited systemic side effects. Previously, this was performed during open surgery with satisfying results, but morbidity and mortality related to the open procedure, prohibited a widespread application. Therefore, percutaneous hepatic perfusion (PHP) with simultaneous chemofiltration was developed. Besides decreasing morbidity and mortality, this procedure can be repeated, hopefully leading to a higher response rate and improved survival (by local control of disease). During PHP, catheters are placed in the proper hepatic artery, to infuse the chemotherapeutic agent, and in the inferior caval vein to aspirate the chemosaturated blood returning through the hepatic veins. The caval vein catheter is a double balloon catheter that prohibits leakage into the systemic circulation. The blood returning from the hepatic veins is aspirated through the catheter fenestrations and then perfused through an extra-corporeal filtration system. After filtration, the blood is returned to the patient by a third catheter in the right internal jugular vein. During PHP a high dose of melphalan is infused into the liver, which is toxic and would lead to life threatening complications when administered systemically. Because of the significant hemodynamic instability resulting from the combination of caval vein occlusion and chemofiltration, hemodynamic monitoring and hemodynamic support is of paramount importance during this complex procedure.



## INTRODUCTION

Resection of malignant liver tumours is the first choice of treatment for both primary and secondary hepatic malignancies. However, a large proportion of patients are no candidates for surgery because of extended disease or location of the metastases. For patients with unresectable metastases from colorectal carcinoma, systemic therapy is often the preferred treatment. Hepatic metastases from uveal melanoma are often small and diffusely spread throughout the liver. No standard systemic therapy is available for this group of patients. Local therapy can be an alternative to systemic treatment, in case the metastases are confined to the liver.

Because of the specific vascular anatomy of the liver, this organ can be isolated from the systemic circulation. This allows perfusion of the liver with high dose chemotherapy (IHP, isolated hepatic perfusion). Besides, liver malignancies have a dominant or exclusive vascular supply from the hepatic artery, whereas 70-80% of the supply of the non-tumorous liver parenchyma is derived from the portal vein.<sup>1,2</sup> This technique was developed over twenty years ago, to treat patients with unresectable metastases from various primary origins.<sup>3,4</sup> Especially, uveal melanoma patients with metastases in the liver may be candidates for IHP because the metastases are often small and spread throughout the entire liver, and at present no standard systemic therapy is available.<sup>5, 6</sup>

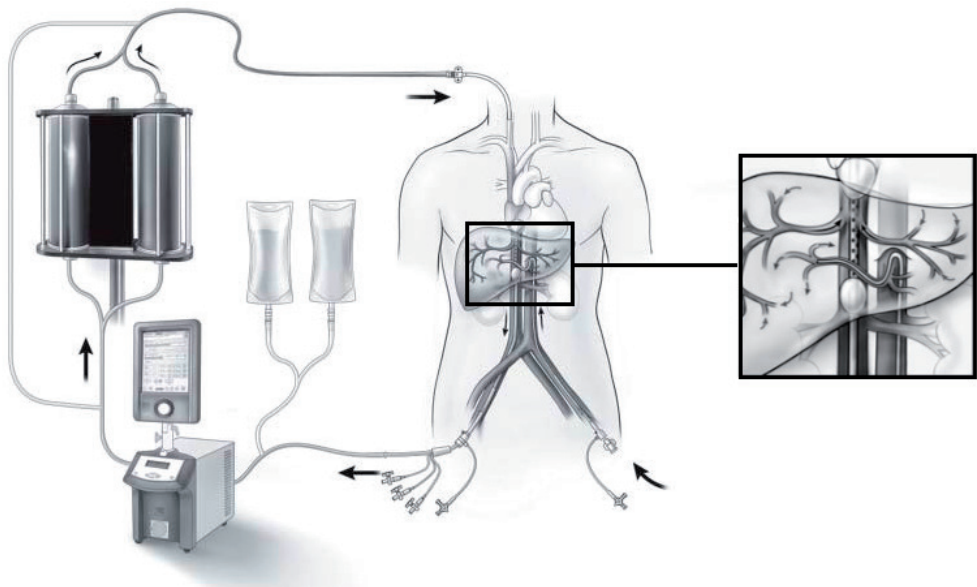
The principle of IHP is to temporarily isolate the liver from the systemic circulation and perfuse the organ with a high dose of chemotherapy, leading to high local drug exposure with limited systemic side effects.<sup>7</sup> This high dose of chemotherapy would be toxic and lead to complications when administered systemically. The majority of IHP studies were performed with melphalan, and have investigated treatment of hepatic metastasis from colorectal cancer patients, as well as patients with uveal melanoma metastases.<sup>8,9</sup> Several studies of IHP during open surgery suggest that this treatment might be effective: 50%-59 % tumour response rates (partial and complete response) for the treatment of colorectal cancer and a 68% tumour response rate for patients with metastatic uveal melanoma have been reported.<sup>8,10,11,12</sup> Despite these treatment results, this procedure never gained wide acceptance, because of the complexity of the procedure, the duration of hospital stay and the associated morbidity and mortality.

Percutaneous hepatic perfusion (PHP) offers a minimal invasive alternative to IHP and was first demonstrated in a porcine model in 1993 using doxorubicin<sup>13</sup> and the first in human trial was performed by Ravikumar *et al* in 1994.<sup>14</sup> Due to lack of evidence of efficacy, the technique was largely abandoned until the early 2000's



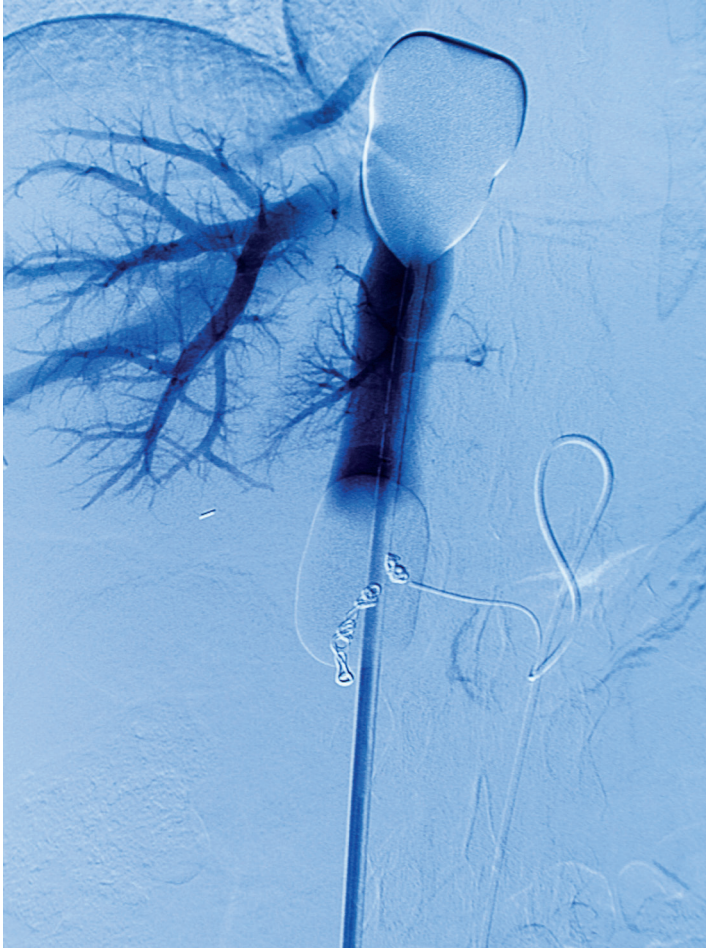
when it was re-evaluated in National Cancer Institute (NCI) in the United States.<sup>15</sup> During PHP, a catheter is placed percutaneous into the proper hepatic artery via the femoral artery to infuse the chemotherapeutic agent. A second catheter is placed in the inferior caval vein via the femoral vein to aspirate the hepatic chemosaturated outflow (see the PHP circuit in Figure 1). The isolation aspiration catheter placed in the caval vein is a double balloon catheter, prohibiting leakage into the systemic circulation. (See Figure 2) The aspirated chemosaturated blood is filtered by a double charcoal filter and returned to the patient by a third catheter placed in the internal jugular vein. The patient is admitted in the hospital with a length of stay of approximately 3 days. The PHP procedure is performed in an angiography room under general anaesthesia by a well-trained multidisciplinary team consisting of a dedicated interventional radiologist, anaesthesiologist and an extracorporeal perfusionist. A surgical oncologist and medical oncologist are also members of this multidisciplinary team, and especially focus on informing the patient, patient selection and post-operative care.

This minimal invasive procedure is associated with less operative morbidity and can be repeated several times (at least up to four times). Besides, it only takes



**FIGURE 1: Schematic image of the PHP circuit.**

This figure displays the set-up of the PHP circuit. It shows an isolated hepatic perfusion circuit with extra-corporeal bypass line.



**FIGURE 2: Per-procedural angiogram**

Venous double balloon catheter in the inferior caval vein and arterial infusion catheter in the proper hepatic artery. Retrograde contrast is injected via the venous catheter. Coils from the pre-procedural angiography and embolization are in place.

approximately 3 to 4 hours and patient recovery is fast. The advantage of PHP is the fact that all sizes of metastases can be treated, and micro metastases are being treated as well. Also the location of the metastases, close to vascular structures and bile ducts, is not a contraindication for PHP. Initial studies were performed with the 1<sup>st</sup> generation filter, with a 77% (mean) filter extraction efficiency.<sup>16</sup>

Recently, the results of a phase III trial were published by Hughes et al. showing a significant improvement of hepatic progression free survival in uveal melanoma



patients with hepatic metastases treated with PHP compared to best alternative care.<sup>17</sup>

Since April 2012 a 2<sup>nd</sup> generation filter is available. In pre-clinical studies the 2<sup>nd</sup> generation filter is extracting 98% of melphalan. Several studies and case series investigating PHP for multiple indications have been published, but apart from the recent published phase III trial, survival has not extensively been analysed.<sup>16,18,19,20</sup> In the present video paper, we focus on the interventional radiology procedure, as well as the anaesthetic management and the extra corporeal circulation that is used during this procedure in order to facilitate the use of this treatment in other medical centers.

## PROTOCOL

After a patient met all inclusion criteria and was carefully evaluated by a medical oncologist, surgeon and anaesthesiologist, a patient was included in the study. All patients provided written informed consent. Both clinical studies were approved by the Local Medical Ethics Committee of the Leiden University Medical Centre and are performed in accordance with the ethical standards of the Helsinki Declaration.

For an extensive description of the protocol, see chapter

## REPRESENTATIVE RESULTS

Knowledge about PHP is based on small phase I and II trials and case series and a recent larger phase III trial; an overview of published results is shown in Table 1. One paper discusses the anaesthesiology procedure, hemodynamic and metabolic aspects of the treatment. Three larger trials that were reported, included metastatic liver disease from different primary tumours and the results are therefore difficult to interpret<sup>16,22</sup>. The first manuscript was published in 1994 and 5-FU and doxorubicin were used.<sup>20,23</sup> Published overall response rates vary between 30 and 90% and limited data on survival data are reported.

A recent phase III trial, comparing PHP to best alternative care (BAC) for patients with hepatic metastases of uveal melanoma, reports improved hepatic progression free survival of 7 months compared to 1.6 months for the group that received BAC ( $p < 0.0001$ ).<sup>17</sup> In the PHP group 36% of patients had a partial response and another 52% had a stable disease. No significant difference in median overall survival was



TABLE I: Published results of percutaneous hepatic perfusion

Author	Year	n	Tumor	Chemotherapeutic agent	ORR	CR	PR	SD	Median hPFS	Median survival	Mortality
Hofmann	2014	1	pseudopapillary pancreatic tumor	melphalan			1			n.a.	n.a.
Vogl	2014	14	Metastatic hepatic disease (melanoma, carcinoma)	melphalan	86%	1/14 (7%)	6/14 (43%)	5/14 (36%)	240 days	n.a.	1
Fitzpatrick	2014	5	Melanoma	melphalan	n.a.		11/14 (78%)			n.a.	n.a.
Forster	2013	10	Melanoma/Sarcoma	melphalan	90%		9/10 (90%)			n.a.	0
Deneve	2012	1	Sarcoma	melphalan					16 months	n.a.	n.a.
Miao	2008	51	Metastatic hepatic disease (NET, melanoma, carcinoma)	melphalan	n.a.					n.a.	n.a.
Pingpank	2005	28	Primary and metastatic hepatic tumors (10) (Ocular melanoma-subgroup)	melphalan	30%	2	6			n.a.	n.a.
Savier	2003	4	Primary and metastatic hepatic tumors	melphalan	n.a.	2	3			n.a.	
Ravikumar	1994	21	Primary and metastatic hepatic tumors	5-FU, doxorubin	n.a.		2	2		n.a.	0
							4 (19%)				

Publications with clinical outcomes reported for patients with metastases confined to the liver treated with PHP. ORR=overall response rate; CR=complete response; PR = partial response; SD= stable disease. hPFS= hepatic progression free survival; n.a.=not available



observed (10 months), probably because patients in the BAC group could crossover to the PHP treatment.<sup>17</sup>

Reported peri-procedural events (during the procedure up to 72 hours after the procedure) included thrombocytopenia (74%) and anemia (60%), often treated with transfusion. Also procedure-related hypotension and hepatic artery spasm were observed, which could be treated with vasopressors and nitroglycerin respectively. Four deaths (4% mortality rate) were reported; two bone-marrow suppression associated (neutropenia and streptococcal sepsis), one because of progressive hepatic failure and one from gastric perforation.<sup>17</sup>

Initial studies were performed with the 1<sup>st</sup> generation filter, with a 77% (mean) filter extraction efficiency.<sup>16</sup> The filter set and the associated protocols were adjusted in response to occurring complications. Studies using the first generation filter also report grade 3 and 4 coagulopathy, possibly related to consumption of clotting factors by the filters.<sup>22 17</sup> Based on these findings, a 2<sup>nd</sup> generation filter was developed, and is available since April 2012. In pre-clinical studies the filter efficacy was improved (98%).

The chemotherapeutic agent of choice for the PHP procedure is melphalan, because it has previously shown to be effective in the treatment of different kinds of liver metastases, without being hepatotoxic, even when administered in myeloablative dosages.<sup>7,22</sup> Melphalan is an alkylating agent of the nitrogen mustard group. It adds an alkyl group to DNA, interfering normal mitosis in rapidly dividing cells by damaging the original structure.<sup>24</sup> Adding other chemotherapeutic agents such as 5-fluorouracil (5-FU) and leucovorin<sup>25</sup>, oxaliplatin<sup>26</sup> or TNF<sup>11</sup> did not improve response rate and an increase in hepatotoxicity was observed in most studies<sup>27</sup>

To investigate the efficacy and safety of this procedure with the 2<sup>nd</sup> generation filter in patients with unresectable liver metastases of uveal melanoma or colorectal cancer, two phase II trials have been initiated at the Leiden University Medical Center and Erasmus MC Cancer Institute (NTR4112 respectively NTR4050). Primary endpoint is the response rate according to RECIST 1.1 criteria on CT / MRI-scans. Secondary endpoints are safety, toxicity according to CTCAE 4.0, (overall) survival and (hepatic) progression free survival and duration of response. Up to now, 27 patients have been treated and there has been no PHP related mortality.

## DISCUSSION

Patients with unresectable liver metastases can be treated with systemic therapy. However, for patients with metastatic uveal melanoma, no standard systemic therapy is available and immunotherapy or targeted therapy have not yet been able to show improved survival. Isolated hepatic perfusion has been shown to be an effective treatment for patients with unresectable uveal melanoma metastases confined to the liver.<sup>9 28</sup>

For colorectal cancer metastases more therapeutic systemic options are available, but some patients progress under these regimens or do not tolerate this treatment because of toxicity. In 2009, Van Iersel and colleagues reported a median overall survival of 25.0 months for patients treated with one IHP procedure versus 21.7 months after treatment with systemic therapy. Although not significant, it shows a trend towards benefit from one IHP procedure versus the CAIRO-1 cycles of systemic chemotherapy.<sup>29</sup>

IHP is a complex surgical intervention and because of the complexity, duration of hospital stay and associated morbidity and mortality never gained wide acceptance. Because of the promising results, a less invasive percutaneous system was developed. Because of hemodynamic perturbations during the procedure and post-procedural haematological toxicity, patient selection is of great importance. Patients with WHO status 0 and 1, no or limited cardiopulmonary risk factors and preserved liver functions can be selected for PHP treatment.

Due to the high dose chemotherapy, there is a risk of hepatic failure and therefore no more than 60% of liver volume should be replaced by tumour.

Another crucial aspect of the PHP procedure is the anaesthetic management of the patient and especially the control of blood pressure.<sup>30</sup> During the procedure, transient hypotension occurs due to the reduction in preload due to caval vein occlusion and peripheral vasodilation from passage of blood through the chemofilters (hemofiltration) and removal of vasoactive agents (e.g. norepinephrine and phenylephrine) by the chemofilters. Ravikumar *et al.* first described percutaneous hepatic vein isolation and infusion of chemotherapy and the consequent transient hypotension after balloon inflation in 79% of the procedures and the importance to anticipate this.<sup>14</sup> A second period of hypotension occurs after the flow is diverted through the charcoal-activated filters.<sup>22 17</sup> This hypotension is of short duration and responds well to administration of fluids and sympatho-mimetics.



Although a filter extraction rate of 77% (generation 1 filter) has been observed, still small systemic leakage of melphalan occurs, leading to myelosuppression. This has been reported in the majority of cases in literature, is of transient nature and well manageable with GCSF growth factor and/or blood products, mostly on an outpatient basis.<sup>16,19 17</sup> The nadir of cytopenia is generally reached 10-14 days after PHP. Therefore, regular blood tests in the first two weeks after PHP are mandatory. The 2<sup>nd</sup> generation filter that is currently being used, hopefully reduces toxicity by an increased filter extraction.

During the procedure, teamwork and clear communication is of utmost importance. The procedure is best performed by a dedicated team with well-trained members. During the PHP procedures in our hospital, the interventional radiologist acts as team leader.

The current status of PHP in treating hepatic malignancies is not yet settled. Future trials will have to prove whether PHP can be integrated in treatment strategy for other types of malignancies. The short hospital stay after the procedure, indicating the tolerability of this procedure, and the manageable complications supports ongoing research of PHP in the treatment of cancer confined to the liver.

In summary, PHP is a well-tolerated local therapy for patients with unresectable liver metastases. Survival and duration of response are investigated in various trials.

## REFERENCES

- 1 Jovanovic, P. *et al.* Ocular melanoma: an overview of the current status. *Int J Clin Exp Pathol.* 6 (7), 1230-1244 (2013).
- 2 Taylor, I., Bennett, R. & Sherriff, S. The blood supply of colorectal liver metastases. *Br J Cancer.* 38 (6), 749-756 (1978).
- 3 van de Velde, C. J. *et al.* A successful technique of in vivo isolated liver perfusion in pigs. *J Surg Res.* 41 (6), 593-599 (1986).
- 4 Vahrmeijer, A. L., Van Der Eb, M. M., Van Dierendonck, J. H., Kuppen, P. J. & Van De Velde, C. J. Delivery of anticancer drugs via isolated hepatic perfusion: a promising strategy in the treatment of irresectable liver metastases? *Semin Surg Oncol.* 14 (3), 262-268 (1998).
- 5 Vahrmeijer, A. L., van de Velde, C. J., Hartgrink, H. H. & Tollenaar, R. A. Treatment of melanoma metastases confined to the liver and future perspectives. *Dig Surg.* 25 (6), 467-472, doi:10.1159/000184738, (2008).
- 6 Ben-Shabat, I. *et al.* Isolated hepatic perfusion as a treatment for liver metastases of uveal melanoma. *J Vis Exp.* (95), 52490, doi:10.3791/52490, (2015).
- 7 Vahrmeijer, A. L. *et al.* Increased local cytostatic drug exposure by isolated hepatic perfusion: a phase I clinical and pharmacologic evaluation of treatment with high dose melphalan in patients with colorectal cancer confined to the liver. *Br J Cancer.* 82 (9), 1539-1546, doi:10.1054/bjoc.2000.1175, (2000).
- 8 Rothbarth, J. *et al.* Isolated hepatic perfusion with high-dose melphalan for the treatment of colorectal metastasis confined to the liver. *Br J Surg.* 90 (11), 1391-1397, doi:10.1002/bjs.4308, (2003).
- 9 van Iersel, L. B. *et al.* Isolated hepatic perfusion with 200 mg melphalan for advanced noncolorectal liver metastases. *Ann Surg Oncol.* 15 (7), 1891-1898, doi:10.1245/s10434-008-9881-6, (2008).
- 10 van Iersel, L. B. *et al.* Isolated hepatic melphalan perfusion of colorectal liver metastases: outcome and prognostic factors in 154 patients. *Ann Oncol.* 19 (6), 1127-1134, doi:10.1093/annonc/mdn032, (2008).
- 11 Alexander, H. R. *et al.* A phase I-II study of isolated hepatic perfusion using melphalan with or without tumor necrosis factor for patients with ocular melanoma metastatic to liver. *Clin Cancer Res.* 6 (8), 3062-3070 (2000).
- 12 Olofsson, R. *et al.* Isolated hepatic perfusion for ocular melanoma metastasis: registry data suggests a survival benefit. *Ann Surg Oncol.* 21 (2), 466-472, doi:10.1245/s10434-013-3304-z, (2014).
- 13 Curley, S. A. *et al.* Increased doxorubicin levels in hepatic tumors with reduced systemic drug exposure achieved with complete hepatic venous isolation and extracorporeal chemofiltration. *Cancer Chemother Pharmacol.* 33 (3), 251-257 (1993).
- 14 Ravikumar, T. S. *et al.* Percutaneous hepatic vein isolation and high-dose hepatic arterial infusion chemotherapy for unresectable liver tumors. *J Clin Oncol.* 12 (12), 2723-2736 (1994).
- 15 Lillemoe, H. A. & Alexander, H. R., Jr. Current Status of Percutaneous Hepatic Perfusion as Regional Treatment for Patients with Unresectable Hepatic Metastases: A Review. *Am Oncology and Hematology Rev* 2014 (15-23), (2014).



- 16 Pingpank, J. F. *et al.* Phase I study of hepatic arterial melphalan infusion and hepatic venous hemofiltration using percutaneously placed catheters in patients with unresectable hepatic malignancies. *J Clin Oncol.* 23 (15), 3465-3474, doi:10.1200/JCO.2005.00.927, (2005).
- 17 Hughes, M. S. *et al.* Results of a Randomized Controlled Multicenter Phase III Trial of Percutaneous Hepatic Perfusion Compared with Best Available Care for Patients with Melanoma Liver Metastases. *Ann Surg Oncol.* 23 (4), 1309-1319, doi:10.1245/s10434-015-4968-3, (2016).
- 18 Fitzpatrick, M. *et al.* Use of partial venovenous cardiopulmonary bypass in percutaneous hepatic perfusion for patients with diffuse, isolated liver metastases: a case series. *J Cardiothorac Vasc Anesth.* 28 (3), 647-651, doi:10.1053/j.jvca.2013.07.022, (2014).
- 19 Forster, M. R. *et al.* Chemosaturation with percutaneous hepatic perfusion for unresectable metastatic melanoma or sarcoma to the liver: a single institution experience. *J Surg Oncol.* 109 (5), 434-439, doi:10.1002/jso.23501, (2014).
- 20 Deneve, J. L. *et al.* Chemosaturation with percutaneous hepatic perfusion for unresectable isolated hepatic metastases from sarcoma. *Cardiovasc Intervent Radiol.* 35 (6), 1480-1487, doi:10.1007/s00270-012-0425-x, (2012).
- 21 K, K. & L, M. *Handbook of Interventional Radiologic Procedures.* 4th edn, 269-270 (Lippincott Williams & Wilkins, 2011).
- 22 Vogl, T. J. *et al.* Chemosaturation with percutaneous hepatic perfusions of melphalan for hepatic metastases: experience from two European centers. *Rofo.* 186 (10), 937-944, doi:10.1055/s-0034-1366081, (2014).
- 23 Hofmann, H. *et al.* Unresectable isolated hepatic metastases from solid pseudopapillary neoplasm of the pancreas: a case report of chemosaturation with high-dose melphalan. *Pancreatology.* 14 (6), 546-549, doi:10.1016/j.pan.2014.08.006, (2014).
- 24 Rothbarth, J., Vahrmeijer, A. L. & Mulder, G. J. Modulation of cytostatic efficacy of melphalan by glutathione: mechanisms and efficacy. *Chem Biol Interact.* 140 (2), 93-107 (2002).
- 25 Bartlett, D. L., Libutti, S. K., Figg, W. D., Fraker, D. L. & Alexander, H. R. Isolated hepatic perfusion for unresectable hepatic metastases from colorectal cancer. *Surgery.* 129 (2), 176-187, doi:10.1067/msy.2001.110365, (2001).
- 26 van Iersel, L. B. *et al.* Isolated hepatic perfusion with oxaliplatin combined with 100 mg melphalan in patients with metastases confined to the liver: A phase I study. *Eur J Surg Oncol.* doi:10.1016/j.ejso.2014.06.010, (2014).
- 27 Rothbarth, J., Tollenaar, R. A. & van de Velde, C. J. Recent trends and future perspectives in isolated hepatic perfusion in the treatment of liver tumors. *Expert Rev Anticancer Ther.* 6 (4), 553-565, doi:10.1586/14737140.6.4.553, (2006).
- 28 van Etten, B., de Wilt, J. H., Brunstein, F., Eggermont, A. M. & Verhoef, C. Isolated hypoxic hepatic perfusion with melphalan in patients with irresectable ocular melanoma metastases. *Eur J Surg Oncol.* 35 (5), 539-545, doi:10.1016/j.ejso.2008.07.004, (2009).
- 29 van Iersel, L. B. *et al.* Management of isolated nonresectable liver metastases in colorectal cancer patients: a case-control study of isolated hepatic perfusion with melphalan versus systemic chemotherapy. *Ann Oncol.* 21 (8), 1662-1667, doi:10.1093/annonc/mdp589, (2010).

- 30 Miao, N. *et al.* Percutaneous hepatic perfusion in patients with metastatic liver cancer: anesthetic, hemodynamic, and metabolic considerations. *Ann Surg Oncol.* 15 (3), 815-823, doi:10.1245/s10434-007-9781-1, (2008).

