



Universiteit
Leiden

The Netherlands

A multidisciplinary approach to improve treatment strategies for patients with hepatic or pancreatic cancer

Leede, E.M. de

Citation

Leede, E. M. de. (2021, December 1). *A multidisciplinary approach to improve treatment strategies for patients with hepatic or pancreatic cancer*. Retrieved from <https://hdl.handle.net/1887/3244234>

Version: Publisher's Version

License: [Licence agreement concerning inclusion of doctoral thesis in the Institutional Repository of the University of Leiden](#)

Downloaded from: <https://hdl.handle.net/1887/3244234>

Note: To cite this publication please use the final published version (if applicable).

PART I



Hepatic perfusion for the
treatment of unresectable
liver metastases



CHAPTER 2



**Isolated hepatic perfusion with
oxaliplatin combined with
100 mg melphalan in patients with
metastases confined to the liver:
a phase I study**

L.B.J. van Iersel, E.M. de Leede, A.L.Vahrmeijer, F.G.J. Tijl, J. den
Hartigh, P.J.K. Kuppen, H.H. Hartgrink, A.J. Gelderblom, J.W.R. Nortier,
R.A.E.M. Tollenaar and C.J.H. van de Velde

European Journal of Surgical Oncology, November 2014

ABSTRACT

Aim

To improve isolated hepatic perfusion (IHP), we performed a phase I dose-escalation study to determine the optimal oxaliplatin dose in combination with a fixed melphalan dose.

Methods

Between June 2007 and July 2008, 11 patients, comprising of 8 colorectal cancer and 3 uveal melanoma patients and all with isolated liver metastases, were treated with a one hour IHP with escalating doses of oxaliplatin combined with 100mg melphalan. Samples of blood and perfusate were taken during IHP treatment for pharmacokinetic analysis of both drugs and patients were monitored for toxicity, response and survival.

Results

Dose limiting sinusoidal obstruction syndrome (SOS) occurred at 150mg oxaliplatin. The areas under the concentration-time curves (AUC) of oxaliplatin at the maximal tolerated dose (MTD) of 100mg oxaliplatin ranged from 11.9 mg/L x h to 16.5 mg/L x h. All 4 patients treated at the MTD showed progressive disease 3 months after IHP.

Conclusions

In view of similar and even higher doses of oxaliplatin applied in both systemic treatment and hepatic artery infusion (HAI), applying this dose in IHP is not expected to improve treatment results in patients with isolated hepatic metastases.



INTRODUCTION

Liver metastases are diagnosed in 10-25% of colorectal cancer patients at the time of primary tumour resection, while up to 70 % of patients with colorectal cancer will at some stage of their disease develop liver metastases [1-3]. Surgical resection is considered the golden standard for isolated hepatic metastases, with 10-year survival rates as high as 17% ⁴. Recently, the number of patients suitable for resection has increased to up to 60% with the introduction of new neoadjuvant systemic treatment regimens [5-9]. Nonetheless, a significant number of patients still remain unsuitable for resection. For patients with uveal melanoma, 70-90% will eventually develop metastases confined to the liver. Because disease is often multifocal, surgical resection is not an option in the majority of patients. Median survival in this group is less than 1 year and currently there is no standard systemic therapy. ²⁵

Isolated hepatic perfusion (IHP) is a possible therapeutic option for unresectable liver metastases, but recent developments in systemic treatment in colorectal cancer have limited the role of IHP ¹⁰. For IHP to remain a treatment option, response rates and overall survival need to increase, by improving both the procedure and drugs applied in IHP. Several drugs have been applied in IHP including 5-FU [11, 12], mitomycin C [13, 14], cisplatin ¹¹ and melphalan [11, 14-16], but in the past 10 years melphalan has been the main drug used in clinical trials [16, 17]. To improve the current standard of IHP, we considered some of the newly developed drugs for systemic treatment of colorectal cancer for application in IHP. As IHP is a regional treatment, the drug should be in the active form or easily transformed to its active agent in the liver. Preferably, this drug shows a steep dose-response curve. Moreover, IHP is a short treatment of usually 1 hour, therefore the drug should cause rapid irreversible tumor cell cytotoxicity. Finally, liver toxicity should be minimal. We evaluated all registered drugs for colorectal cancer, taking into account the considerations above. Irinotecan is not an ideal candidate for IHP, since it is a pro-drug and the bioactivation to its active metabolite SN-38 is slow¹⁸. The monoclonal antibodies bevacizumab, cetuximab and panitumumab may not be suitable either, because they are not directly cytotoxic. Therefore oxaliplatin was selected as the most promising new candidate for IHP. Phase III trials have shown the superiority of oxaliplatin combination therapy versus oxaliplatin monotherapy [19, 20], suggesting a role for the possible application of a combination of oxaliplatin and melphalan in IHP. *In vitro* results showed a synergistic schedule dependent interaction between melphalan and oxaliplatin ²¹.

In this report we present the results of a phase I trial with IHP with escalating doses of oxaliplatin combined with a fixed dose of 100mg melphalan.



PATIENTS AND METHODS

Patient Eligibility

All patients had measurable, unresectable metastases confined to the liver. Unresectability was based on the decision made by the HPB multidisciplinary team. Often this was because the tumour is multifocal, too large or positioned close to central vascular structures. Standard staging studies were performed including CT scan of the chest and abdomen. Additional MRI or PET scans were performed if clinically indicated. Eligibility criteria included a WHO performance status of 0 or 1, leukocyte count $\geq 3.0 \times 10^9/L$, platelet count $\geq 100 \times 10^9/L$, minimum creatinine clearance level of 40 ml/min and maximum bilirubin level 17 $\mu\text{mol/L}$. Exclusion criteria were age over 65 years, more than 60% hepatic replacement by tumour tissue as estimated from the preoperative abdominal CT scan, evidence of extrahepatic metastatic disease or coagulation disorders (disorders affecting APTT, PT and/or INR). The interval between resection of the primary colorectal tumour and perfusion had to be at least 6 weeks.

Study design

This study is a prospective cohort study, including 11 patients with isolated liver metastases that were treated between June 2007 and July 2008. Patients were treated with IHP with escalating doses of oxaliplatin combined with 100mg melphalan. The study protocol was approved by the medical ethical committee of the Leiden University Medical Center, was registered in the EudraCT database: number 2006-005088-25 and written informed consent was obtained from all patients.

IHP technique

All patients were treated with IHP, consisting of an extracorporeal veno-venous bypass, as described previously¹⁵.

Leakage Detection

Leakage of perfusate into the systemic circuit was monitored by adding 10 MBq ^{99m}Tc-pertechnetate to the isolated circuit with subsequent measurement of the level of radioactivity in both the systemic and isolated circuit, as described previously [22, 23]. If no leakage was detected, oxaliplatin was administered. During the one hour treatment leakage was constantly monitored, if leakage exceeded 10% during the perfusion period, the procedure was immediately aborted and the liver flushed.

Postoperative Care

All patients received a daily subcutaneous dose of 480 µg granulocyte colony-stimulating factor (G-CSF) (Filgrastim/Neupogen®; Amgen, Breda, The Netherlands) starting the day after the operation until the nadir in leukocyte count was reached and the count had risen to more than $1.0 \times 10^9/L$. Patients were monitored in the intensive care unit for at least 1 day after IHP. Liver and renal function tests and full blood counts were carried out daily in the first week and henceforth as indicated by their respective levels. Antibiotics in a combination of cefuroxim and metronidazol were given to all patients for 5 days after IHP.

Oxaliplatin and melphalan

Oxaliplatin (Sanofi-Aventis, Gouda, The Netherlands) was obtained as a ready-made solution and administered as a bolus in the isolated hepatic circuit. Melphalan 100mg (Alkeran®, GlaxoSmithKline, Zeist, The Netherlands) was dissolved in 40 mL Wellcome Diluent (a 60/40 (v/v) mixture of propylene glycol containing 5.2% (v/v) ethanol and 0.068 mol/l sodium citrate), which was subsequently diluted with 60 mL sterile saline. The melphalan was administered as a bolus in the isolated hepatic circuit 30 minutes after the oxaliplatin was administered.

Dose escalation

Dose escalation depended on toxicities at the prior dose level. At least 3 patients were treated at each dose level. If 1 of 3 patients experienced dose limiting toxicity (DLT), 3 additional patients were entered at that dose level. DLT was defined as grade 4 thrombopenia or neutropenia for more than 7 days or febrile neutropenia or irreversible grade 3/4 liver toxicity or other grade 3/4 non-hematological toxicity other than nausea and vomiting without adequate treatment. The maximal tolerated dose (MTD) was defined as the dose level below that, which induced DLT in at least one-third of the patients. (i.e., ≥ 2 of 3 or 6 patients). Melphalan was kept at a fixed dose of 100 mg, because this was considered standard treatment in several phase II trials [24-26]. Oxaliplatin was escalated with 50mg at a time. Oxaliplatin was administered 30 minutes prior to melphalan based on *in vitro* findings, suggesting a schedule dependent interaction between melphalan and oxaliplatin ²¹.

Toxicity

Systemic and regional toxicity were graded according to the National Cancer Institute Common Toxicity Criteria version 3.0. Hepatic toxicities were considered melphalan-related if elevations in liver function persisted beyond 7 days after perfusion, as previously suggested ¹⁶. Non-hepatic toxicities were defined as all toxicities that were not reversed within 24 hours after perfusion.



Melphalan and oxaliplatin pharmacokinetics

Heparinized samples of all patients were taken from the perfusion medium at hepatic inflow and outflow tracts and from the systemic circulation, at 15 different time points (t=0, 1, 5, 10, 15, 20, 25, 30, 31, 33, 35, 40, 45, 50, 60 minutes). Samples were stored at -80° C until analysis. All samples were analysed for melphalan by a HPLC assay as previously described ²⁷. Oxaliplatin concentrations were determined by ICP-MS (Inductively Coupled Plasma- Massa Spectrometry). The areas under the concentration-time curves (AUC) were calculated with the trapezoidal rule.

Response evaluation

Objective tumour response measurements were obtained by follow up CT scans of the liver and remaining abdomen at 3-month intervals after treatment and at 6-month interval after 1 year. Additional imaging was performed if clinically indicated. RECIST criteria were used to determine response rates. For the RECIST criteria lesions were only considered measurable if ≥ 10 mm. Complete response was defined as disappearance of all known disease, partial response as a reduction in the sum of maximal diameters of $\geq 30\%$, stable disease as a reduction of $< 30\%$ or an increase of $< 20\%$ and progressive disease as an increase of $\geq 20\%$ or the appearance of new intra- or extrahepatic lesions ²⁸. Metastases were localized according to the Bismuth classification ²⁹.

Serum carcinoembryonic antigen (CEA) levels were determined in colorectal cancer patients prior to treatment and at all follow-up visits.

Statistics

All data were analyzed using SPSS (version 12.0) software and presented as mean +/- SD or median followed by the range. All survival and disease progression analysis were performed using Kaplan-Meier statistics.

RESULTS

Patient characteristics

Demographics and tumour characteristics of the patient population are listed in Table 1. In total 11 ASA 1-2 patients were treated with escalating doses of oxaliplatin. Three women were treated and eight men with a mean age of 57.9 years (range 40-64 years). The liver metastases originated from uveal melanoma in three patients and from colorectal cancer in the other eight patients. In all patients there was more than 75% healthy liver tissue. One of the included patients (patient no. 5) in retrospect showed extrahepatic disease prior to IHP. Therefore one extra

TABLE I. Characteristics of 11 patients treated with IHP with oxaliplatin and melphalan

Patient No.	Sex	ASA-score	Age (Y)	Primary tumour	Number of metastases in liver	Size of largest tumour (mm)	Healthy liver tissue	Previous systemic treatment	Dose Melphalan (mg)	Dose Oxaliplatin (mg)	AUC		Response	Duration response (months)	Overall survival (months)
											Hepatic inflow Melphalan (mg/L x h)	Hepatic inflow Oxaliplatin (mg/L x h)			
1	F	2	51	Uveal melanoma	throughout liver	43	>80%	none	100	50	9.6	4.1	partial	7.6	30.7
2	M	2	64	Colorectal cancer	>10	30	80%	RT rectum	100	50	2.8	6.2	progressive	-	26.8
3	M	2	54	Uveal melanoma	throughout liver	11	>90%	CT (DTIC)	100	50	7.3	6.9	progressive	-	18.7
4	M	2	59	Colorectal cancer	5	68	90%	CT	100	100	6.4	12.6	progressive	-	4.9
5*	F	1	40	Colorectal cancer	>20		75%	CT	100	100	15.4	16.5	-	-	5.5
6	F	2	61	Uveal melanoma	4	34	>80%	none	100	100	10.3	16.5	progressive	-	7.8
7	M	2	63	Colorectal cancer	multiple	23	>90%	CT	100	100	2.8	11.9	progressive	-	22.0
8	M	2	63	Colorectal cancer	5	50	>90%	CT	100	150	6.7	19.6	partial	6.5	27.3
9 ^a	M	2	63	Colorectal cancer	10	30	>90%	RT rectum	100	150	4.8	16.7	partial	11.1	71.3 ^a
10*	M	2	57	Colorectal cancer	throughout liver	9	90%	CT	100	150	9.9	20.6	-	-	0.5
11*	M	2	62	Colorectal cancer	throughout liver	25	90%	RT rectum	100	150	6.5	18.2	-	-	1.0

* In retrospect patient showed extrahepatic metastases prior to IHP, which were immediately progressive after IHP.

^a Both patients died perioperatively. Patient no. 10 due to excessive bleeding and patient no. 11 due to hepatotoxicity.

^α Patient still alive.

CT = chemotherapy RT= radiotherapy (5x5 Gy)



patient was included at this dose-level. Some of the patients have been treated with chemotherapy after resection of the primary tumour. One uveal melanoma patient with DTIC (Dacarbazine) and most colorectal patients with combinations of oxaliplatin and capecitabine (Xeloda).

Treatment characteristics

Treatment characteristics are shown in Table 2. In 10 patients the perfusion took place for the intended 60 minutes. None of the patients showed more than one percent leakage during the entire procedure. Patients were admitted in the hospital for 16.8 days (mean \pm 10.5). Time of surgery, blood loss, hospital stay and hepatic artery and portal vein flow rates and pressures are similar as previously reported in 73 and 105 treated patients. [17, 30].

Pharmacokinetics

Samples for pharmacokinetic analysis were collected from all patients. Individual data of the AUC of both melphalan and oxaliplatin are shown in Table 1. Escalating doses of oxaliplatin corresponded to an increasing AUC, with the maximum of 20.6 mg/L x h achieved at the highest dose level of 150 mg oxaliplatin. The maximum peak concentration of oxaliplatin was 40.8 mg/L and was achieved in patient no 9, also at the highest dose level. Little difference was observed between the oxaliplatin concentrations in the hepatic inflow and outflow tract, suggesting only limited hepatic extraction of oxaliplatin. This is shown in Figure 1, for different dose levels of oxaliplatin in different patients. An increasing dose-level shows an increasing peak in concentration within five minutes. All curves show a decline over time.

Toxicity and complications

Major complications occurred in four patients of which two patients died perioperatively. One perioperative death was due to massive blood loss, due to damage to the hepatic artery, which was repaired with a venous interponate. This perioperative death was attributed to the procedure and not toxicity. Therefore another patient was included at this dose-level. The other perioperative death was due to hepatotoxicity as a result of sinusoidal obstruction syndrome (SOS). Toxicity levels according to dose-level are shown in Table 3. Reversible grade 3-4 hepatotoxicity occurred in seven patients. DLT consisted of irreversible grade 4 hepatotoxicity requiring hepatic-replacement therapy due to SOS and was reached at 150mg oxaliplatin combined with 100mg melphalan.

Tumour response and patient survival

Of the five patients with colorectal cancer with an elevated CEA prior to IHP, three showed 50% or more reduction in CEA after IHP. Only eight patients were

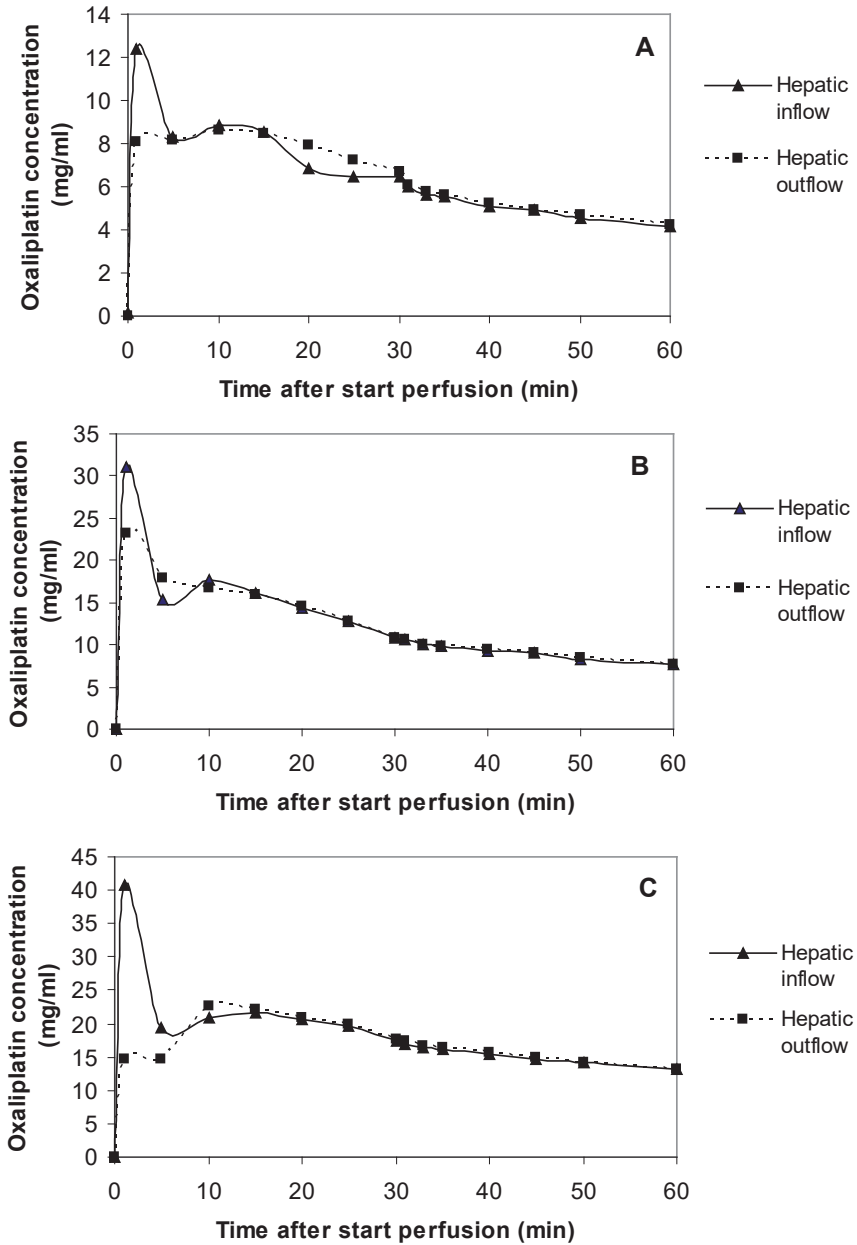


FIGURE 1 Typical examples of concentration time curves of oxaliplatin for each dose-level (A = 50 mg oxaliplatin, B = 100 mg oxaliplatin, C = 150 mg oxaliplatin). Increasing dose-levels show increasing peak concentrations of oxaliplatin. All concentration curves show a gradual decline over time.



TABLE 2. IHP Treatment parameters

<i>Parameter</i>	<i>Mean ± SD</i>	<i>n</i>
Flow rate hepatic artery (mL/min)	293.9 ± 68.1	
Flow rate portal vein (mL/min)	312.8 ± 31.3	
Pressure hepatic artery (mm/Hg)	129.4 ± 20.0	
Pressure portal vein (mm/Hg)	49.1 ± 4.0	
Percentage leakage during perfusion (%)	0.4 ± 0.5	
Blood loss (L)	5.5 ± 5.8	
Operative time (h)	8.4 ± 1.6	
Hospital stay (days)	16.8 ± 10.5	
Perioperative mortality		2
Major complications		4
Sinusoidal obstruction syndrome		1
Hepatic artery obstruction		1
Wound infection		1
Re-operation due to bleeding		1

available for response evaluation of which three patients showed a partial response according to the RECIST criteria, with a duration of response of 6.5 – 11.1 months. After a follow up of 71 months, one patient is still alive. This was measured from the day of treatment until the last appointment in the hospital. The median overall survival was 18,7 months (SD 20,44) including three uveal melanoma patients, as displayed in Table 1.

DISCUSSION

In this study we evaluated escalating doses of oxaliplatin combined with a fixed dose of 100mg melphalan in an isolated hepatic perfusion setting for patients with metastatic disease confined to the liver. Dose limiting toxicity (DLT), consisting of sinusoidal obstruction syndrome (SOS), occurred at a relatively low dose level of 150mg oxaliplatin.

In previous IHP studies DLT also consisted of SOS as one of the main limitations of IHP with melphalan [15, 16]. Nonetheless, we did not expect DLT to occur at such a low dose of oxaliplatin, especially considering the 50% reduction in melphalan dose compared to our previous IHP trials[17, 31]. At the time of development of this study protocol, oxaliplatin was considered a non-hepatotoxic drug, with only limited hepatotoxicity reported in both systemic and hepatic arterial infusion (HAI)

TABLE 3. Toxicity according to National Cancer Institute Common Toxicity Criteria version 3.0 (n=11)

	Grade 0	Grade 1	Grade 2	Grade 3	Grade 4
Leukocyte nadir					
- Dose level I	3	0	0	0	0
- Dose level II	4	0	0	0	0
- Dose level III	4	0	0	0	0
Bilirubin					
- Dose level I	2	1	0	0	0
- Dose level II	2	0	0	1	1
- Dose level III	0	0	0	2	2
Alkaline phosphatase					
- Dose level I	1	2	0	0	0
- Dose level II	0	1	2	0	1
- Dose level III	0	2	2	0	0
Alanine aminotransferase (ALAT)					
- Dose level I	2	0	0	1	0
- Dose level II	1	1	1	0	1
- Dose level III	0	1	2	0	1
Asparate aminotransferase (ASAT)					
- Dose level I	0	1	2	0	0
- Dose level II	0	2	0	2	0
- Dose level III	0	1	1	1	1

trials [32-36]. These findings combined with the synergistic interaction between melphalan and oxaliplatin, as demonstrated by our previously published *in vitro* data, supported the development of this study protocol³⁷. However, more recently, after development of our study protocol, an increasing number of studies reported on the hepatotoxicity, especially the risk of SOS, after treatment with oxaliplatin prior to hepatectomy of colorectal liver metastases. Incidence rates of SOS have been reported of up to 59% and oxaliplatin-based chemotherapy has been shown an independent risk factor for complications associated with hepatectomy with conflicting data concerning impact on both morbidity and mortality [38-42]. In view of the above, the addition of a cytostatic agent with a high incidence of SOS to a procedure with already a high risk of SOS, can explain the occurrence of DLT at only 150mg of oxaliplatin.



Similarly to our study, Zeh *et al.* published a phase I study of IHP with oxaliplatin, but instead of oxaliplatin combination therapy, the perfusate consisted of oxaliplatin alone⁴³. Dose-limiting toxicity, also consisting of SOS, was observed at only 60 mg/m², again indicating the high potential of inducing SOS if oxaliplatin is applied in isolated hepatic perfusion circuit, irrespective of combination with other agents. This study reported an overall response rate of 66%, but IHP was performed under hyperthermic conditions and combined with HAI, complicating the interpretation of both toxicity and response rates.

Recently Zeh *et al.* published another study combining oxaliplatin with a fixed dose of 40mg/m² with escalating doses of 5-FU. Dose limiting toxicity occurred at the second dose (300 mg/m²) and consisted of hyperbilirubinemia and ascites because of hepatic failure⁴⁴. In our study meaningful interpretation of the response rate is complicated because of the phase I design and the inclusion of both uveal melanoma and colorectal cancer patients. Of the 8 colorectal cancer patients included, only two patients showed a partial response, both were treated at the highest dose level of 150mg oxaliplatin. All patients treated at the MTD of 100mg oxaliplatin showed progressive disease 3 months after IHP. Considering the dose of oxaliplatin used in regular systemic combination treatment in colorectal cancer patients of over 100mg/m² per treatment cycle, conducting a phase II IHP trial based on the MTD dose of 100mg oxaliplatin seems hardly beneficial.

Although the C_{max} in our study was higher than the C_{max} reported after a 2-hour infusion of oxaliplatin at 130mg/m² in systemic trials, the AUC of oxaliplatin at the MTD in our study ranged from 11.9 mg/L x h to 16.5 mg/L x h and was similar to the AUC reported in systemic trials⁴⁵. A possible survival benefit for IHP over systemic treatment can only be achieved at this dose if response to oxaliplatin therapy is concentration- rather than dose-dependent. Our previous experience with melphalan showed that an increase in melphalan concentration in the perfusate did not increase response rates, but did increase toxicity³¹. Moreover, current HAI study protocols already apply a dose of oxaliplatin of up to 150mg/m² [32-36]. Similarly to IHP, HAI offers the advantage of high concentrations of the cytostatic agent in the liver metastases, but contrary to IHP, HAI is a minimally invasive procedure and is suitable for repetitive treatment, further limiting the possible role of oxaliplatin in IHP.

For IHP to remain a treatment option for isolated liver metastases, perioperative morbidity and mortality needed to be reduced, most likely by adapting the procedure. Recently, percutaneous hepatic perfusion (PHP) was developed. This percutaneous approach to treat liver metastases with melphalan aims to decrease

morbidity compared to the open procedure. Another aim is to increase the response rate, since the procedure can be performed more than once and a selection of patients can undergo a curative resection after tumour response to the perfusion. [46-49]. Our team is currently investigating this new technique in a phase I/II trial aiming to include 34 patients.

In conclusion, we have established the MTD of oxaliplatin in combination with 100mg melphalan in IHP at 100mg. Further escalation is limited by the occurrence of SOS. In view of similar and even higher doses of oxaliplatin applied in both systemic treatment and HAI, applying this dose in IHP will not result in a further improvement of the treatment of patients with isolated hepatic metastases. Improvement of the treatment must be sought in improving the perfusion system, such as a percutaneous procedure.



REFERENCES

1. Jessup JM, McGinnis LS, Steele GD, Jr., Menck HR, Winchester DP. The National Cancer Data Base. Report on colon cancer. *Cancer* 1996 Aug 15;78(4):918-26.
2. Weiss L, Grundmann E, Torhorst J, Hartveit F, Moberg I, Eder M, et al. Haematogenous metastatic patterns in colonic carcinoma: an analysis of 1541 necropsies. *J Pathol* 1986 Nov;150(3):195-203.
3. Welch JP, Donaldson GA. The clinical correlation of an autopsy study of recurrent colorectal cancer. *Ann Surg* 1979 Apr;189(4):496-502.
4. Tomlinson JS, Jarnagin WR, DeMatteo RP, Fong Y, Kornprat P, Gonen M, et al. Actual 10-year survival after resection of colorectal liver metastases defines cure. *J Clin Oncol* 2007 Oct 10;25(29):4575-80.
5. Nordlinger B, Van CE, Rougier P, Kohne CH, Ychou M, Sobrero A, et al. Does chemotherapy prior to liver resection increase the potential for cure in patients with metastatic colorectal cancer? A report from the European Colorectal Metastases Treatment Group. *Eur J Cancer* 2007 Sep;43(14):2037-45.
6. Bismuth H, Adam R, Levi F, Farabos C, Waechter F, Castaing D, et al. Resection of nonresectable liver metastases from colorectal cancer after neoadjuvant chemotherapy. *Ann Surg* 1996 Oct;224(4):509-20.
7. Adam R, Wicherts DA, de Haas RJ, Ciaccio O, Levi F, Paule B, et al. Patients with initially unresectable colorectal liver metastases: is there a possibility of cure? *J Clin Oncol* 2009 Apr 10;27(11):1829-35.
8. Alberts SR, Horvath WL, Sternfeld WC, Goldberg RM, Mahoney MR, Dakhil SR, et al. Oxaliplatin, fluorouracil, and leucovorin for patients with unresectable liver-only metastases from colorectal cancer: a North Central Cancer Treatment Group phase II study. *J Clin Oncol* 2005 Dec 20;23(36):9243-9.
9. Folprecht G, Gruenberger T, Bechstein WO, Raab HR, Lordick F, Hartmann JT, et al. Tumour response and secondary resectability of colorectal liver metastases following neoadjuvant chemotherapy with cetuximab: the CELIM randomised phase 2 trial. *Lancet Oncol* 2010 Jan;11(1):38-47.
10. van Iersel LB, Koopman M, van de Velde CJ, Mol L, van Persijn van Meerten EL, Hartgrink HH, et al. Management of isolated nonresectable liver metastases in colorectal cancer patients: a case-control study of isolated hepatic perfusion with melphalan versus systemic chemotherapy. *Ann Oncol* 2010 Aug;21(8):1662-7.
11. Hafstrom LR, Holmberg SB, Naredi PL, Lindner PG, Bengtsson A, Tidebrant G, et al. Isolated hyperthermic liver perfusion with chemotherapy for liver malignancy. *Surg Oncol* 1994 Apr;3(2):103-8.
12. Aigner K, Walther H, Tonn JC, Krahl M, Wenzl A, Merker G, et al. Isolated liver perfusion with 5-fluorouracil (5-FU) in the human. *Chirurg* 1982 Sep;53(9):571-3.
13. Marinelli A, de Brauw LM, Beerman H, Keizer HJ, van Bockel JH, Tjaden UR, et al. Isolated liver perfusion with mitomycin C in the treatment of colorectal cancer metastases confined to the liver. *Jpn J Clin Oncol* 1996 Oct;26(5):341-50.

14. Oldhafer KJ, Lang H, Frerker M, Moreno L, Chavan A, Flemming P, et al. First experience and technical aspects of isolated liver perfusion for extensive liver metastasis. *Surgery* 1998 Jun;123(6):622-31.
15. Vahrmeijer AL, van Dierendonck JH, Keizer HJ, Beijnen JH, Tollenaar RA, Pijl ME, et al. Increased local cytostatic drug exposure by isolated hepatic perfusion: a phase I clinical and pharmacologic evaluation of treatment with high dose melphalan in patients with colorectal cancer confined to the liver. *Br J Cancer* 2000 May;82(9):1539-46.
16. Alexander HR, Jr., Bartlett DL, Libutti SK, Fraker DL, Moser T, Rosenberg SA. Isolated hepatic perfusion with tumor necrosis factor and melphalan for unresectable cancers confined to the liver. *J Clin Oncol* 1998 Apr;16(4):1479-89.
17. Rothbarth J, Pijl ME, Vahrmeijer AL, Hartgrink HH, Tijl FG, Kuppen PJ, et al. Isolated hepatic perfusion with high-dose melphalan for the treatment of colorectal metastasis confined to the liver. *Br J Surg* 2003 Nov;90(11):1391-7.
18. Chabot GG, Abigergeres D, Catimel G, Culine S, Deforni R, Extra JM, et al. Population Pharmacokinetics and Pharmacodynamics of Irinotecan (Cpt-11) and Active Metabolite Sn-38 During Phase-I Trials. *Annals of Oncology* 1995 Feb;6(2):141-51.
19. Rothenberg ML, Oza AM, Bigelow RH, Berlin JD, Marshall JL, Ramanathan RK, et al. Superiority of oxaliplatin and fluorouracil-leucovorin compared with either therapy alone in patients with progressive colorectal cancer after irinotecan and fluorouracil-leucovorin: Interim results of a phase III trial. *Journal of Clinical Oncology* 2003 Jun 1;21(11):2059-69.
20. Ramanathan RK, Clark JW, Kemeny NE, Lenz HJ, Gococo KO, Haller DG, et al. Safety and toxicity analysis of oxaliplatin combined with fluorouracil or as a single agent in patients with previously treated advanced colorectal cancer. *J Clin Oncol* 2003 Aug 1;21(15):2904-11.
21. van Iersel LB, Koudijs TM, Hoekman EJ, Janssen-van Rhijn CM, Vahrmeijer AL, Nortier JW, et al. In vitro Schedule-Dependent Interaction Between Melphalan and Oxaliplatin in Human Colorectal Cancer Cell Lines. *J Surg Res* 2009 Aug 7.
22. Marinelli A, de Brauw LM, Beerman H, Keizer HJ, van Bockel JH, Tjaden UR, et al. Isolated liver perfusion with mitomycin C in the treatment of colorectal cancer metastases confined to the liver. *Jpn J Clin Oncol* 1996 Oct;26(5):341-50.
23. Runia RD, de Brauw LM, Kothuis BJ, Pauwels EK, van de Velde CJ. Continuous measurement of leakage during isolated liver perfusion with a radiotracer. *Int J Rad Appl Instrum B* 1987;14(2):113-8.
24. Alexander HR, Libutti SK, Bartlett DL, Puhlmann M, Fraker DL, Bachenheimer LC. A phase I-II study of isolated hepatic perfusion using melphalan with or without tumor necrosis factor for patients with ocular melanoma metastatic to liver. *Clin Cancer Res* 2000 Aug;6(8):3062-70.
25. Alexander HR, Jr., Libutti SK, Pingpank JF, Steinberg SM, Bartlett DL, Helsabeck C, et al. Hyperthermic isolated hepatic perfusion using melphalan for patients with ocular melanoma metastatic to liver. *Clin Cancer Res* 2003 Dec 15;9(17):6343-9.
26. Bartlett DL, Libutti SK, Figg WD, Fraker DL, Alexander HR. Isolated hepatic perfusion for unresectable hepatic metastases from colorectal cancer. *Surgery* 2001 Feb;129(2):176-87.
27. Sparidans RW, Silvertand L, Dost F, Rothbarth J, Mulder GJ, Schellens JH, et al. Simple high-performance liquid chromatographic assay for melphalan in perfusate, rat liver and tumour tissue. *Biomed Chromatogr* 2003 Oct;17(7):458-64.



28. Therasse P, Arbuck SG, Eisenhauer EA, Wanders J, Kaplan RS, Rubinstein L, et al. New guidelines to evaluate the response to treatment in solid tumors. European Organization for Research and Treatment of Cancer, National Cancer Institute of the United States, National Cancer Institute of Canada. *J Natl Cancer Inst* 2000 Feb 2;92(3):205-16.
29. Bismuth H. Surgical anatomy and anatomical surgery of the liver. *World J Surg* 1982 Jan;6(1):3-9.
30. van Iersel LB, Gelderblom H, Vahrmeijer AL, van Persijn van Meerten EL, Tijl FG, Putter H, et al. Isolated hepatic melphalan perfusion of colorectal liver metastases: outcome and prognostic factors in 154 patients. *Ann Oncol* 2008 Feb 27.
31. van Iersel LB, Verlaan MR, Vahrmeijer AL, van Persijn van Meerten EL, Tijl FG, Sparidans RW, et al. Hepatic artery infusion of high-dose melphalan at reduced flow during isolated hepatic perfusion for the treatment of colorectal metastases confined to the liver: a clinical and pharmacologic evaluation. *Eur J Surg Oncol* 2007 Sep;33(7):874-81.
32. Kern W, Beckert B, Lang N, Stemmler J, Beykirch M, Stein J, et al. Phase I and pharmacokinetic study of hepatic arterial infusion with oxaliplatin in combination with folinic acid and 5-fluorouracil in patients with hepatic metastases from colorectal cancer. *Ann Oncol* 2001 May;12(5):599-603.
33. Ducreux M, Ychou M, Laplanche A, Gamelin E, Lasser P, Hussein F, et al. Hepatic arterial oxaliplatin infusion plus intravenous chemotherapy in colorectal cancer with inoperable hepatic metastases: a trial of the gastrointestinal group of the Federation Nationale des Centres de Lutte Contre le Cancer. *J Clin Oncol* 2005 Aug 1;23(22):4881-7.
34. Fiorentini G, Rossi S, Dentico P, Meucci F, Bonechi F, Bernardeschi P, et al. Oxaliplatin hepatic arterial infusion chemotherapy for hepatic metastases from colorectal cancer: a phase I-II clinical study. *Anticancer Res* 2004 May;24(3b):2093-6.
35. Guthoff I, Lotspeich E, Fester C, Wallin I, Schatz M, Ehrsson H, et al. Hepatic artery infusion using oxaliplatin in combination with 5-fluorouracil, folinic acid and mitomycin C: oxaliplatin pharmacokinetics and feasibility. *Anticancer Res* 2003 Nov;23(6D):5203-8.
36. Mancuso A, Giuliani R, Accettura C, Palma M, D'Auria G, Cecere F, et al. Hepatic arterial continuous infusion (HACI) of oxaliplatin in patients with unresectable liver metastases from colorectal cancer. *Anticancer Res* 2003 Mar;23(2C):1917-22.
37. van Iersel LB, Koudijs TM, Hoekman EJ, Janssen-van Rhijn CM, Vahrmeijer AL, Nortier JW, et al. In vitro Schedule-Dependent Interaction Between Melphalan and Oxaliplatin in Human Colorectal Cancer Cell Lines. *J Surg Res* 2009 Aug 7.
38. Soubrane O, Brouquet A, Zalinski S, Terris B, Brezault C, Mallet V, et al. Predicting high grade lesions of sinusoidal obstruction syndrome related to oxaliplatin-based chemotherapy for colorectal liver metastases: correlation with post-hepatectomy outcome. *Ann Surg* 2010 Mar;251(3):454-60.
39. Vauthey JN, Pawlik TM, Ribero D, Wu TT, Zorzi D, Hoff PM, et al. Chemotherapy regimen predicts steatohepatitis and an increase in 90-day mortality after surgery for hepatic colorectal metastases. *J Clin Oncol* 2006 May 1;24(13):2065-72.
40. Aloia T, Sebagh M, Plasse M, Karam V, Levi F, Giacchetti S, et al. Liver histology and surgical outcomes after preoperative chemotherapy with fluorouracil plus oxaliplatin in colorectal cancer liver metastases. *J Clin Oncol* 2006 Nov 1;24(31):4983-90.

41. Nakano H, Oussoultzoglou E, Rosso E, Casnedi S, Chenard-Neu MP, Dufour P, et al. Sinusoidal injury increases morbidity after major hepatectomy in patients with colorectal liver metastases receiving preoperative chemotherapy. *Ann Surg* 2008 Jan;247(1):118-24.
42. Tamandl D, Klinger M, Eipeldauer S, Herberger B, Kaczirek K, Gruenberger B, et al. Sinusoidal obstruction syndrome impairs long-term outcome of colorectal liver metastases treated with resection after neoadjuvant chemotherapy. *Ann Surg Oncol* 2011 Feb;18(2):421-30.
43. Zeh HJ, III, Brown CK, Holtzman MP, Egorin MJ, Holleran JL, Potter DM, et al. A phase I study of hyperthermic isolated hepatic perfusion with oxaliplatin in the treatment of unresectable liver metastases from colorectal cancer. *Ann Surg Oncol* 2009 Feb;16(2):385-94.
44. Magge D, Zureikat AH, Bartlett DL, Holtzman MP, Choudry HA, Beumer JH, et al. A phase I trial of isolated hepatic perfusion (IHP) using 5-FU and oxaliplatin in patients with unresectable isolated liver metastases from colorectal cancer. *Ann Surg Oncol* 2013 Jul;20(7):2180-7.
45. Graham MA, Lockwood GF, Greenslade D, Brienza S, Bayssas M, Gamelin E. Clinical pharmacokinetics of oxaliplatin: a critical review. *Clin Cancer Res* 2000 Apr;6(4):1205-18.
46. Miao N, Pingpank JF, Alexander HR, Steinberg SM, Beresneva T, Quezado ZM. Percutaneous hepatic perfusion in patients with metastatic liver cancer: anesthetic, hemodynamic, and metabolic considerations. *Ann. Surg. Oncology* 2008;15:815-23.
47. Pingpank JF, Libutti SK, Chang R, et al. Phase I study of hepatic arterial melphalan infusion and hepatic venous hemofiltration using percutaneously placed catheters in patients with unresectable hepatic malignancies. *Journal of clinical oncology : official journal of the American Society of Clinical Oncology* 2005;23:3465-74.

