



Universiteit  
Leiden  
The Netherlands

## Transcatheter interventions for structural heart disease

Kley, F. van der

### Citation

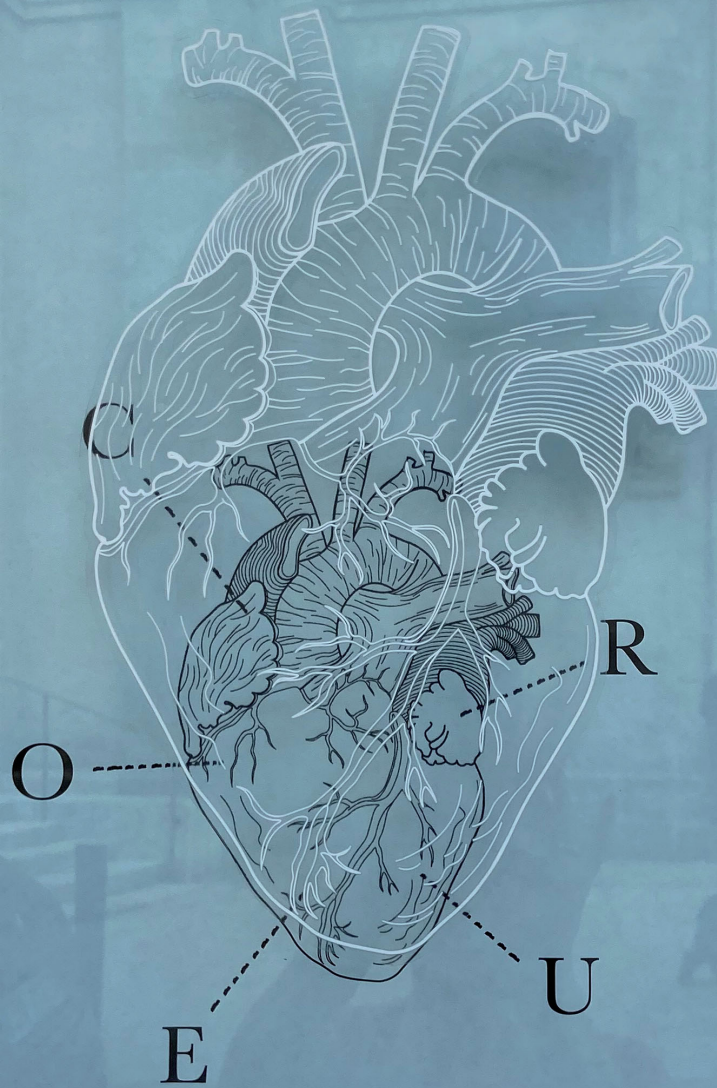
Kley, F. van der. (2021, September 23). *Transcatheter interventions for structural heart disease*. Retrieved from <https://hdl.handle.net/1887/3239318>

Version: Publisher's Version

License: [Licence agreement concerning inclusion of doctoral thesis in the Institutional Repository of the University of Leiden](#)

Downloaded from: <https://hdl.handle.net/1887/3239318>

**Note:** To cite this publication please use the final published version (if applicable).



# CŒUR

ATTENTION à la MARCH

## Transcatheter interventions for structural heart disease

Frank van der Kley



# **Transcatheter interventions for structural heart disease**

**Frank van der Kley**





**Transcatheter interventions for structural heart disease**

**Frank van der Kley**

**Transcatheter interventions for structural heart disease**

**Proefschrift**

ter verkrijging van de graad van doctor aan de Universiteit Leiden,  
op gezag van rector magnificus prof.dr.ir. H. Bijl,  
volgens besluit van het college voor promoties  
te verdedigen op donderdag 23 september 2021 klokke 10.00 uur

door Frank van der Kley

**Title:**

**Transcatheter interventions for structural heart disease**

Frank van der Kley

**Promotor:** Prof. Dr. M.J. Schalij

**Co-promotor:** Dr. V Delgado

**Promotie commissie:**

Prof. dr. R.J.M. Klautz

Prof. dr. J.J. Bax

Prof. dr. J.H.C. Reiber

Prof. dr. M. Gilard (University of Brest Hospital, France)

Prof. dr. J.L. Zamorano (Hospital Universitario Ramón y Cajal, Madrid, Spain)

Dr N. Ajmone Marsan

Dr M. Bootsma

## TABLE OF CONTENTS

<b>Outline Thesis</b>	<b>9</b>
<b>Chapter 1:</b>	<b>15</b>
<b>Introduction</b>	
Optimal imaging for planning and guiding interventions in structural heart disease: a multi-modality imaging approach. <b>Frank van der Kley</b> , Victoria Delgado, Martin J. Schalij Jeroen J. Bax. <i>European Heart Journal Supplements</i> , Volume 12, Issue suppl_E, 1 September 2010, Pages E10–E23, <a href="https://doi.org/10.1093/eurheartj/suq005">https://doi.org/10.1093/eurheartj/suq005</a>	
<b>Chapter 2:</b>	<b>41</b>
Impact of age on transcatheter aortic valve implantation outcomes: a comparison of patients aged $\leq 80$ years versus patients $> 80$ years. <b>van der Kley F</b> , van Rosendael PJ, Katsanos S, Kamperidis V, Marsan NA, Karalis I, de Weger A, Palmem M, Bax JJ, Schalij MJ, Delgado V. <i>J Geriatr Cardiol</i> . 2016 Jan;13(1):31-6. doi:10.11909/j.issn.1671-5411.2016.01.004. PubMed PMID: 26918010; PubMed CentralPMCID: PMC4753009.	
<b>Chapter 3:</b>	<b>53</b>
Timing of staged percutaneous coronary intervention before transcatheter aortic valve implantation. <b>van der Kley F</b> , van Rosendael PJ, Kamperidis V, Katsanos S, Al Amri I, Regeer M, Schalij MJ, Ajmone Marsan N, Bax JJ, Delgado V. <i>Am J Cardiol</i> . 2015 Jun 15;115(12):1726-32. doi: 10.1016/j.amjcard.2015.03.019. Epub 2015 Mar 24. PubMed PMID: 25890631.	
<b>Chapter 4:</b>	<b>69</b>
Predictors of residual tricuspid regurgitation after percutaneous closure of atrial septal defect. <i>Eur Heart J Cardiovasc Imaging</i> . Nassif M, <b>van der Kley F</b> , Abdelghani M, Kalkman DN, de Bruin-Bon RHACM, Bouma BJ, Schalij MJ, Koolbergen DR, Tijssen JGP, Mulder BJM, de Winter RJ. 2018 Jun 13. doi: 10.1093/ehjci/jey080.	
<b>Chapter 5:</b>	<b>91</b>
Transcatheter mitral valve repair in osteogenesis imperfecta associated mitral valve regurgitation. <b>van der Kley F</b> , Delgado V, Ajmone Marsan N, Schalij MJ. <i>Heart Lung Circ</i> . 2014 Aug;23(8):e169-71. doi: 10.1016/j.hlc.2014.03.025. Epub 2014 Apr 2. PubMed PMID: 24791663	

<b>Chapter 6:</b>	<b>101</b>
How should I treat recurrent concomitant para-ring and valvular mitral regurgitation after surgical mitral valve repair in a high-risk patient? van der Kley F, van Rosendael P, Martina B, Palmen M, Delgado V, Schillinger W, von Bardeleben RS, Yeo KK, Ho KW, Jack Tan WC. EuroIntervention. 2015 Apr;10(12):1488-92. doi: 10.4244/EIJY14M09_02.	
<b>Future perspectives</b>	<b>117</b>
<b>Summary</b>	
<b>Samenvatting en toekomstperspectieven</b>	<b>123</b>
<b>List of publications</b>	<b>129</b>
<b>Dankwoord</b>	<b>145</b>
<b>Curriculum Vitae</b>	<b>149</b>








---

## **Outline of the present thesis**





Treatment of valvular heart disease changed significantly in the last two decades. This thesis focuses on diagnosis, patient selection and transcatheter therapies for structural heart disease. Recent advances in catheter-based interventions have provided effective alternative treatments to surgery for several structural heart diseases such as atrial or ventricular septal defects. Particularly, the advent of transcatheter valve implantation/repair techniques constitutes one of the main breakthroughs of the last decades offering an effective alternative to patients with symptomatic valvular heart disease and high mortality operative risk. In addition, the role of novel catheter-based interventions has been explored in several clinical conditions that convey an increased risk of cerebrovascular stroke such as patent foramen ovale or atrial fibrillation. Specific devices have been developed to treat all these clinical conditions. To improve the procedural success rate and minimize the frequency of complications, multimodality cardiac imaging plays a central role providing an accurate selection of patients and invaluable assistance during the procedure. Technological advances in the equipment and image post-processing software have provided improved accuracy of the image quality and analysis leading to an increasing implementation of these imaging techniques in the clinical practice. **Chapter 1** reviews the important role of multimodality imaging for planning and guiding interventions in structural heart disease.

Transcatheter aortic valve implantation (TAVI) is now generally accepted as a standard care in high risk patient populations with symptomatic aortic valve stenosis. Implants were mainly performed in octogenarians or patients with multi-comorbidities. In **Chapter 2** the role of age in patients treated with transcatheter aortic valve implantation is discussed. In the study two groups of patients were compared for procedural outcomes and survival. **Chapter 3** highlights treatment of comorbidity in patients with aortic stenosis. Significant coronary artery disease is highly prevalent in patients who underwent TAVI. Timing of staged percutaneous coronary intervention (PCI) in TAVI candidates remains debated. The present study assessed the impact of timing of the staged PCI on TAVI outcomes.

Functional tricuspid regurgitation (TR) associated with atrial septal defects (ASDs) is frequently present due to right-sided volume-overload. Tricuspid valve (TV) repair is often considered in candidates for surgical ASD closure, and percutaneous TV repair is currently under clinical investigation. **Chapter 4** proposes a prediction model to identify patients with residual moderate/severe TR after percutaneous ASD closure.

**Chapters 5 and 6** describe clinical challenging cases in which new transcatheter techniques effectively treated high risk patients even if the techniques are consid-



ered bail-out therapies. In **Chapter 5** we explained a case where the heart team discussion is crucial for optimal decision making. Osteogenesis imperfecta is associated with increased prevalence of significant mitral valve regurgitation. Surgical mitral valve repair and replacement are feasible but are associated with increased risk of bleeding and dehiscence of implanted valves may occur more frequently. The present case report describes the outcomes of transcatheter mitral valve repair in a patient with osteogenesis imperfecta. In **Chapter 6** we discuss the case of a 74-year-old male with symptomatic severe recurrent mitral regurgitation after surgical mitral valve repair and high surgical risk who was referred for transcatheter mitral valve-in-ring implantation. We explained periprocedural problems and how we solved it. In the same article two experts in the field explain how they would have treated the case.





# Chapter 1

---

## Introduction

### Optimal Imaging for Planning and Guiding Interventions in Structural Heart Disease - A Multi-Imaging Modality Approach

**Authors:** Victoria Delgado, MD; Frank van der Kley, MD; Martin J. Schalij, MD, PhD; Jeroen J. Bax, MD, PhD.

**From:** Department of Cardiology, Leiden University Medical Center, Leiden, The Netherlands  
European Heart Journal Supplements (2010) 12 (Supplement E), E10–E23.

## ABSTRACT

Recent advances in catheter-based interventions have provided effective alternative treatments to surgery for several structural heart diseases such as atrial or ventricular septal defects. Particularly, the advent of transcatheter valve implantation/repair techniques constitutes one of the main breakthroughs of the last decades offering an effective alternative to patients with symptomatic valvular heart disease and high mortality operative risk. In addition, the role of novel catheter-based interventions has been explored in several clinical conditions that convey an increased risk of cerebrovascular stroke such as patent foramen ovale or atrial fibrillation. Specific devices have been developed to treat all these clinical conditions. To improve the procedural success rate and minimize the frequency of complications, multimodality cardiac imaging plays a central role providing an accurate selection of patients and invaluable assistance during the procedure. Technological advances in the equipments and image post-processing softwares have provided improved accuracy of the image quality and analysis leading to an increasing implementation of these imaging techniques in the clinical practice. The present state-of-the art article reviews the role of multimodality imaging for planning and guiding interventions in structural heart disease.

**Keywords:** Multimodality cardiac imaging; Cardiac interventions; Structural heart disease

### **Abbreviations:**

2D = Two-dimensional

3D = Three-dimensional

ASD = Atrial septal defect

MDCT = Multi-detector row computed tomography

MRI = Magnetic resonance imaging

TAVI = Transcatheter aortic valve implantation

TEE = Transesophageal echocardiography

TTE = Transthoracic echocardiography

VSD = Ventricular septal defect



## INTRODUCTION

Recent advances in catheter-based intervention procedures have provided effective therapeutic alternatives to surgery for selected patients with structural heart disease. A large body of evidence has demonstrated that, for example, percutaneous device closure is an effective and safe treatment of hemodynamically significant atrial septal defects (ASD).<sup>1</sup> In addition, although technically more challenging than ASD closure, percutaneous device closure of ventricular septal defects (VSD) has been shown to have comparable results to surgery in several multicenter registries.<sup>2</sup> Finally, transcatheter valve implantation procedures have been one of the main therapeutic breakthroughs of the last decade and the feasibility of this treatment alternative has been demonstrated in recent experiences including over 8000 symptomatic, severe aortic stenosis patients with high operative risk.<sup>3</sup>

In order to achieve the highest procedural success rate with the lowest complication rate, accurate patient selection and guidance of interventions are crucial. Cardiac multimodality imaging plays a pivotal role providing an accurate selection of patients and invaluable assistance during the procedure. Two-dimensional (2D) echocardiography is the most widely used imaging technique in the pre-procedural patient evaluation. However, 3-dimensional (3D) imaging modalities (3D echocardiography, multi-detector row computed tomography [MDCT] or cardiac magnetic resonance imaging [MRI]) provide detailed information on the dimensions and spatial relationships of the cardiac structures that are crucial to anticipate the device size and the procedural approach. During the intervention, fluoroscopy remains the mainstay imaging tool to guide the procedures in spite of lacking spatial information. However, sophisticated technological developments in other imaging modalities have enabled the performance of the interventional procedures while minimizing the need for fluoroscopic control with better spatial information.

The current article reviews the role of multi-modality imaging for planning and guiding interventions in the most common structural heart diseases: aortic and mitral valvular disease, ASD and VSD. In addition, novel catheter-based interventions developed to treat cardiac conditions related with high risk of stroke (patent foramen ovale and atrial fibrillation) will be discussed.

### **Transcatheter aortic valve implantation**

Degenerative aortic stenosis is the most common valvular heart disease in the western countries.<sup>4</sup> Aortic valve replacement is the only effective treatment for symptomatic, severe aortic stenosis. However, the operative risk of some patients

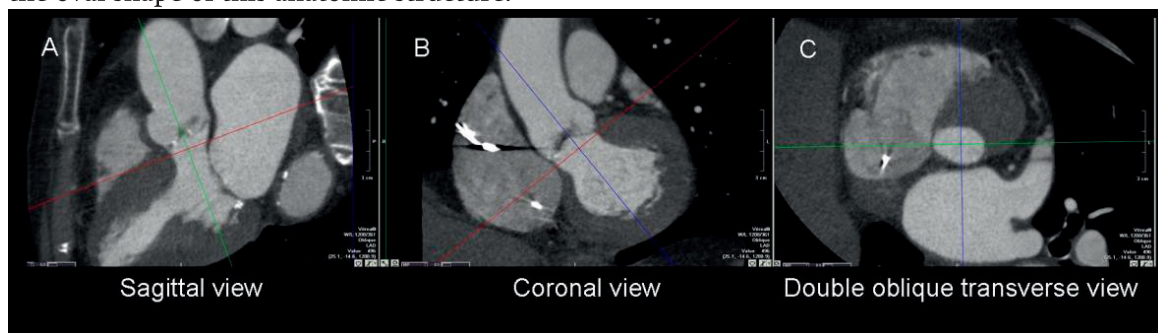
outweighs the benefits of aortic valve replacement and, consequently, these patients are denied for surgery.<sup>4</sup> The advent of transcatheter aortic valve implantation (TAVI) procedures in the last years has provided an alternative therapy for high risk patients with symptomatic severe aortic stenosis. Since the first-in-man experience in 2002, over 8000 high risk patients have been treated with TAVI.<sup>3, 5</sup> Currently, TAVI procedures are performed through transarterial retrograde approach (transfemoral or transsubclavian) or transapical approach. Two types of catheter-delivered prosthesis are available. The first one is the balloon-expandable Sapien Edwards prosthesis (Edwards Lifesciences Inc.). This prosthesis is currently available in two sizes: 23-mm for aortic valve annular diameters between 18-22 mm and 26-mm for aortic valve annular diameters between 21-25 mm. These prostheses require delivery system sizes of 22-F and 24-F, respectively, for retrograde approach, and 26-F size for transapical approach. The other catheter-delivered prosthesis is the self-expandable CoreValve Revalving system (CoreValve Inc., Irvine, CA). The currently available sizes are 26-mm for aortic valve annular diameters between 20-24 mm and 29-mm for aortic valve annular diameters between 24-27 mm. The delivery systems have reduced the size and currently a 18-F sheath is used through retrograde approach.

Several single-center non-controlled studies and registries have reported short- and mid-term survival rates of TAVI that are comparable to surgical aortic valve replacement.<sup>6-9</sup> However, the technical challenges of this novel therapy require accurate pre-procedural patient selection and exact procedural guiding. In summary, the assessment of the procedural feasibility and exclusion of contraindications for TAVI are key issues to be assessed. Accurate sizing of the aortic valve annulus and evaluation of the peripheral arteries and thoracic aorta are crucial pre-procedural screening steps to select the prosthesis size and the procedural approach (transfemoral or transapical).

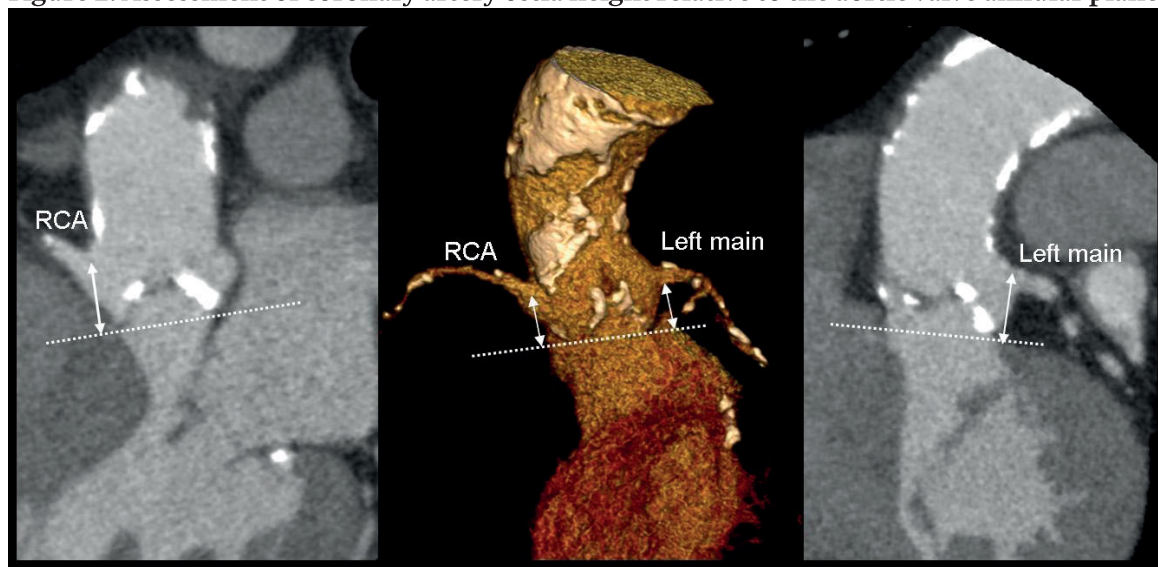
Two-dimensional transthoracic echocardiography (TTE) is the most used imaging technique to size the aortic valve annulus. However, 2D TTE may significantly underestimate the aortic valve annular size as compared to 2D transesophageal echocardiography (TEE) leading to inaccurate selection of the prosthesis size and subsequent procedural-related complications such as paravalvular regurgitation or prosthesis migration.<sup>10</sup> As shown by Smid et al.,<sup>11</sup> 3D imaging techniques may provide the most accurate measurements of the aortic valve annulus. Particularly, MDCT and MRI yield accurate 3D visualization of the aortic valve annulus, showing the characteristic oval shape of this structure (Figure 1).<sup>11</sup> Using as a reference peri-operative measurements of the aortic valve annulus, MDCT and MRI measurements yielded smaller biases ( $-1.5 \pm 3.5$  mm and  $0.7 \pm 4.2$  mm, respectively) than 2D TTE

or TEE ( $-4.5 \pm 1.1$  mm and  $-5.5 \pm 2.0$  mm, respectively).<sup>11</sup> In addition, extent and location of the aortic valve calcifications, the dimensions of the other components of the aortic root (sinus of Valsalva, sino-tubular junction and ascending aorta) and their spatial relationship with the surrounding structures such as coronary arteries can be evaluated.<sup>12</sup> Two-dimensional TTE or TEE provide reliable information on the valve anatomy, calcification extent and dimensions of the aortic root. However, the assessment of the relative height of the coronary ostia to the aortic valve annular plane is not feasible with these 2D imaging modalities. MDCT may provide the most comprehensive 3D evaluation the aortic root and surrounding structures of patients undergoing TAVI.<sup>12</sup> Particularly, the height of the coronary ostia relative the aortic valve annular plane and the risk of coronary ostium occlusion by a bulky calcified aortic leaflet during prosthesis implantation may be evaluated (Figure 2).

**Figure 1. Aortic valve annulus sizing with MDCT.** Multiplanar reformatting planes across the aortic valve annular plane provide the most accurate assessment of the dimensions of the aortic valve annulus. Aortic valve annular diameters can be measured at two orthogonal views (sagittal, panel A, and coronal, panel B) or at the double oblique transverse view (panel C) demonstrating the oval shape of this anatomic structure.



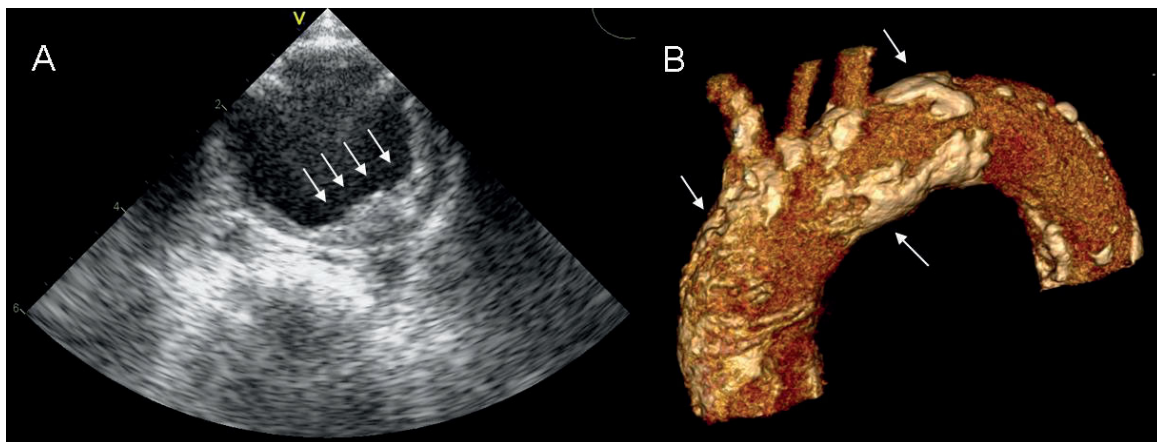
**Figure 2. Assessment of coronary artery ostia height relative to the aortic valve annular plane.**



Abbreviations: RCA = right coronary artery

Finally, the evaluation of the dimensions, tortuosity and calcifications of the peripheral arteries and aorta provides important information to anticipate the procedural approach (transfemoral or transapical). Invasive angiography is considered the reference method to measure the luminal diameter and the tortuosity of the peripheral arteries.<sup>13</sup> However, the poor soft-tissue contrast resolution of the fluoroscopy limits its accuracy to evaluate the arterial wall and, consequently, calcified, mobile plaques or mural thrombosis may be misdiagnosed with increased risk of stroke during manipulation of catheter-delivering systems inside the aorta. MDCT, MRI and TEE yield invaluable information in this regard and may assist to select the transapical approach rather than the transfemoral approach (Figure 3).<sup>13</sup> (PERHAPS SOME METION TO THE TORTUOSITY AND DIFFERENT ANGULATIONS OF THE VESSELS EXTENDING FROM THE GROIN TO THE AORTIC BIFURCATION WHICH CANNOT BE DEPICTED WELL IN FLUOROSCOPY BY CAN BE DEFINED BY CTA OR MRI, SHOULD BE MENTIONED)

**Figure 3. Aortic atherosclerosis and calcification extent.** The presence of extensive atherosclerosis and calcification of the peripheral arteries or thoracic aorta may indicate a transapical approach rather than transfemoral. Panel A shows an extensive atherosclerotic plaque in the thoracic aortic wall as evaluated with TEE. Panel B demonstrates an extensively calcified aortic arch as assessed with MDCT.

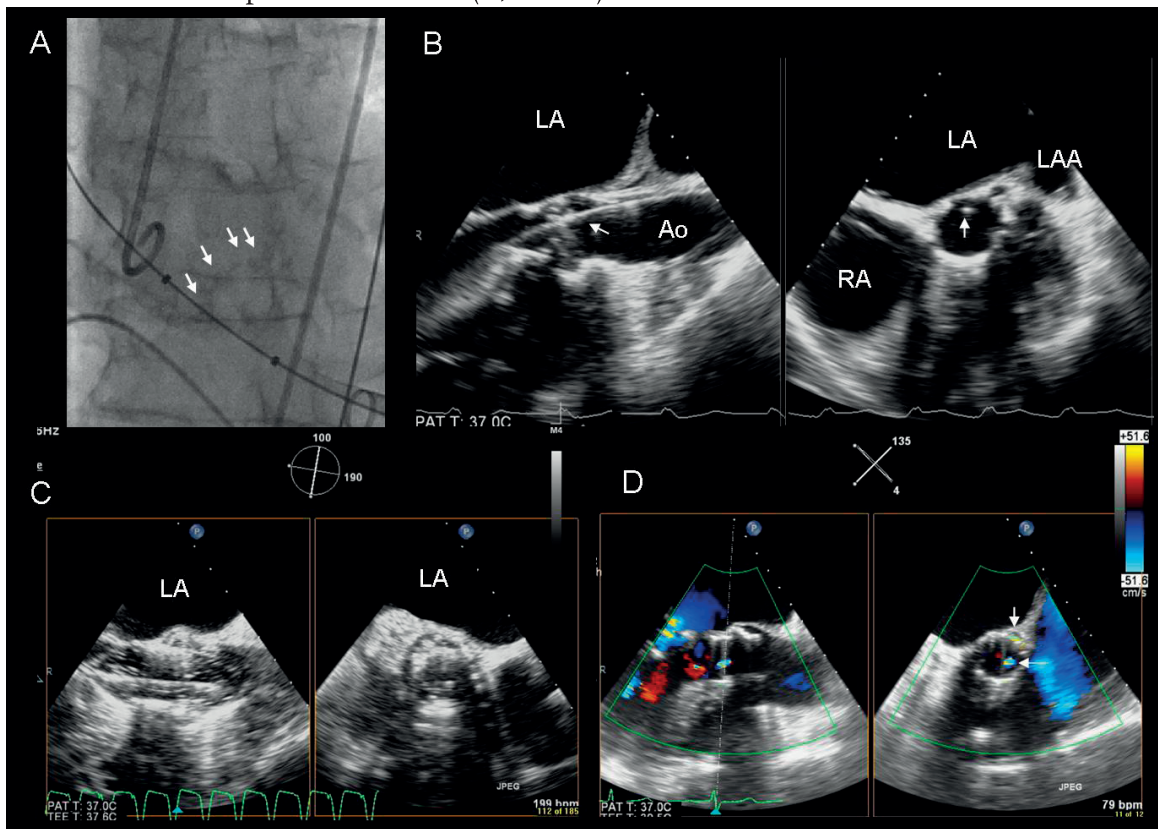


During TAVI procedure, fluoroscopy and TEE play a central role to guide the sequential procedural steps. There is limited experience using intracardiac echocardiography to guide the procedure.<sup>14</sup> Crossing the aortic valve with the guide wire and positioning the waist of the balloon at the aortic valve annular level are usually guided with fluoroscopy, using as landmarks the calcifications of the non-coronary leaflet, or with direct visualization of the valve with TEE (Figure 4A,B). Afterwards, exact positioning and deployment of the prosthesis are crucial to minimize complications such as paravalvular regurgitation (Figure 4C). Combination of fluoroscopy and TEE may provide the most accurate guidance to position the prosthesis (WHAT



ABOUT THE OVERLAY OF FLUORO-CTA OR THE 3D-VOLUME RENDERED CINE-ANGIOGRAPHY). Finally, after prosthesis deployment, the results can be evaluated with TEE providing valuable information on transvalvular gradient reduction and on aortic valve regurgitation. The presence of mild paravalvular regurgitation is rather common (up to 50%).<sup>9</sup> In contrast, significant valvular regurgitation is infrequent and suggests the presence of misdeployment of one of the leaflets or overexpansion of the prosthesis.<sup>15</sup> Orthogonal color-Doppler views of the prosthetic valve permit differentiate paravalvular and valvular regurgitation whereas fluoroscopy may have limitations to differentiate them (Figure 4D). In addition, TEE permits the detection of other potential procedural-related complications such as cardiac tamponade, aortic dissection or occlusion of the coronary ostia by bulky calcified leaflets immediately after prosthesis deployment.

**Figure 4. Transcatheter aortic valve implantation.** The procedure is usually performed with fluoroscopic and 2D or 3D TEE guidance. With fluoroscopy, calcifications of the coronary leaflets (arrows) are used as landmarks to guide the wire crossing the valve and to position the balloon (A). With X-plane TEE images, the guide wire is directly visualized crossing the valve in two orthogonal planes simultaneously (arrows) (B). After aortic valve ballooning, the prosthesis is deployed (C) and the positioning and the function can be assessed immediately after deployment, evaluating the presence of valvular leaks (D). In this example, the arrows indicate the presence of mild central and paravalvular leaks (D, arrows).



Abbreviations: Ao = aorta; LA = left atrium; LAA = left atrial appendage; RA = right atrium.



In summary, multimodality imaging combining echocardiography and MDCT or MRI may constitute the most accurate approach to evaluate the candidates to TAVI and to define the procedural feasibility. During the procedure, combination of fluoroscopy and TEE is crucial to achieve the highest procedural success rate with the lowest complication rate. (SHOULD YOU ALSO MENTION THE IMAGING ASPECTS FOR THE SELF-EXPANDING AORTIC VALVE PROSTHESIS?)

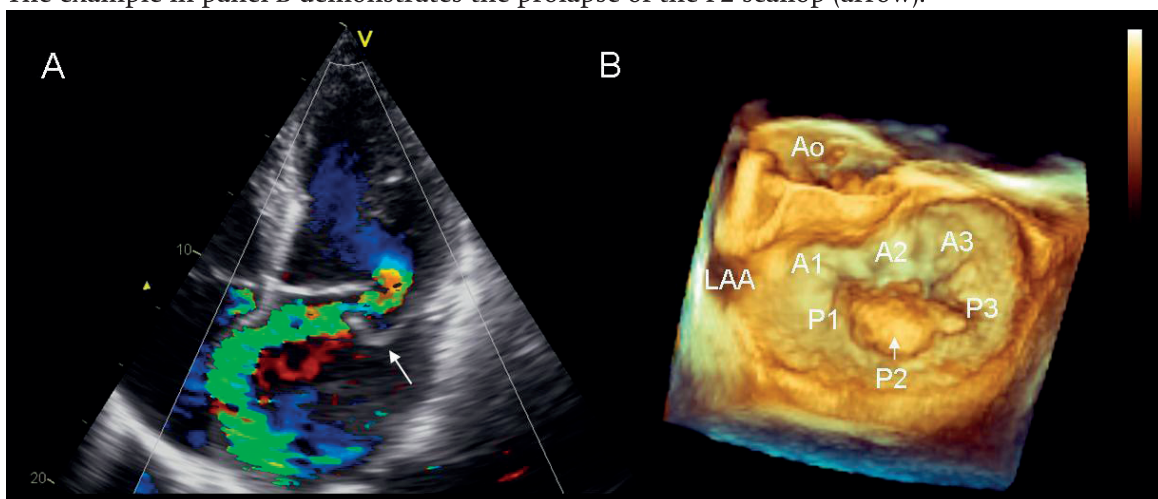
## **Transcatheter mitral valve repair**

Contemporary registries have demonstrated that mitral regurgitation is the second most prevalent valvular heart disease.<sup>4</sup> Surgical mitral valve repair, combining leaflet repair techniques and restrictive ring annuloplasty, remain the treatment of choice for symptomatic severe mitral regurgitation. In the last decade, elderly patients have benefited most of recent advances in surgical repair techniques.<sup>16</sup> However, the presence of depressed left ventricular systolic function or associated co-morbidities increase the mortality operative risk and, consequently, the denial of surgery in this subgroup of patients rises up to 50%.<sup>17</sup> Several transcatheter mitral valve repair techniques have been developed in order to provide an effective and less invasive alternative to surgery. These techniques include leaflet repair (edge-to-edge), coronary sinus annuloplasty or direct mitral annuloplasty, and direct remodeling.<sup>18</sup> The complex anatomical and functional interactions between the mitral valve apparatus, left ventricle and left atrium challenge transcatheter mitral valve repair techniques. Exact characterization of the mitral valve anatomy and mitral regurgitation mechanism is crucial to select the appropriate transcatheter mitral valve repair technique. Accordingly, imaging plays a central role in the pre-procedural screening and during the procedure.

Mitral regurgitation can be divided into primary or secondary (functional) according to the underlying pathophysiologic mechanism.<sup>19</sup> In primary mitral regurgitation, the mitral valve itself is affected and leaflet coaptation failure results of derangements of one or more components of the mitral valve (leaflets, tendinous cords or annulus). In contrast, in functional mitral regurgitation the mitral valve is preserved whereas the left ventricle is damaged. Prior left ventricular myocardial infarction or dilated cardiomyopathy induces dysfunction and displacement of the papillary muscles towards apical and posterior levels, mitral annulus dilatation and finally tethering of the mitral leaflets resulting in coaptation failure. Two-dimensional TTE is the first imaging technique to evaluate the cause and severity of mitral regurgitation. Barlow's disease and fibroelastic deficiency are the most common causes of primary mitral regurgitation.<sup>19</sup> Both diseases result in excessive motion and prolapse of one or more scallops of the mitral leaflets and varying grades of mitral regurgitation

but commonly with characteristic eccentric regurgitant jets (Figure 5A). In contrast, functional mitral regurgitation is characterized by restrictive motion of the mitral leaflets. Current recommendations of the American Society of Echocardiography advocate quantitative assessments of mitral regurgitation by means of vena contracta width, regurgitant volume or effective orifice area by proximal isovelocity surface area method.<sup>20</sup> However, eccentric regurgitant jets challenge mitral regurgitation quantification with 2D imaging techniques. In addition, systematic examination of the mitral valve and accurate identification of the scallops with 2D TEE requires high experience. Real time 3D TTE yields an improved accuracy in the estimation of the mitral regurgitation by direct visualization of the vena contracta without geometrical assumptions.<sup>21, 22</sup> Current 3D transesophageal echocardiographic probes incorporate novel matrix-array transducers with approximately 3000 elements that provide superb image quality and display of the mitral valve, either from the left atrial view (surgeon's view) or from the left ventricular view (Figure 5B). Interventional procedures on mitral valve demand accurate visualization of the mitral valve to select the most suited repair technique and to guide the procedure. Technical features of the different transcatheter mitral valve repair procedures require tailored imaging approach to evaluate the procedural feasibility. In addition, fluoroscopy may be insufficient to guide the procedure due to its poor soft-tissue contrast resolution. Therefore, combination of fluoroscopy and TEE (2D or real-time 3D TEE) may be ideal to accurately guide the sequential procedural steps while minimizing the radiation exposure.

**Figure 5. Transcatheter mitral valve repair: pre-procedural evaluation.** Echocardiography is the mainstay imaging modality to evaluate the mitral regurgitation mechanism (primary or secondary). Panel A shows the example of a patient with primary mitral regurgitation due to prolapse of the posterior mitral leaflet (arrow). Real-time 3D TEE provides the surgical view of the mitral valve and accurate anatomical segmentation in scallops and commissures (panel B). The example in panel B demonstrates the prolapse of the P2 scallop (arrow).

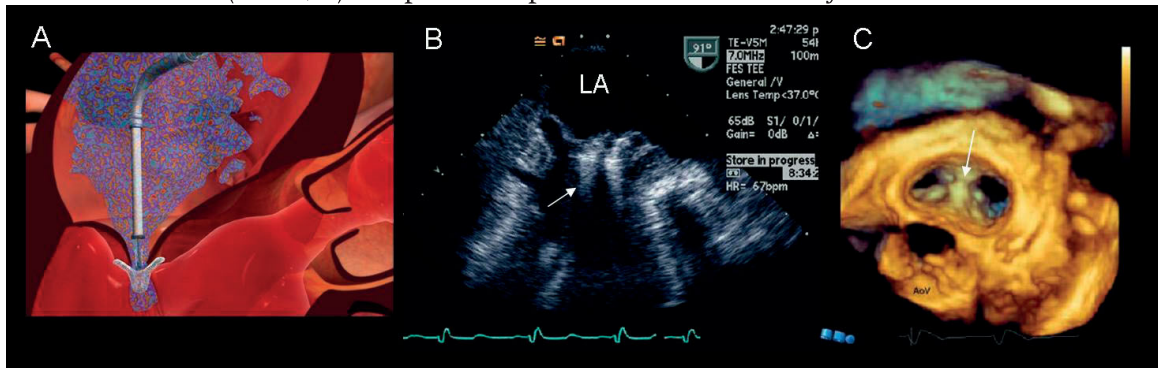


Abbreviations: Ao = aortic valve; LAA = left atrial appendage.

**Transcatheter leaflet mitral (edge-to edge) repair** mimics the surgical edge-to-edge repair pioneered by Alfieri and coworkers two decades ago.<sup>23</sup> This technique improves the leaflet coaptation by suturing a segment of the anterior mitral leaflet to the posterior leaflet, resulting in a double-orifice mitral valve. The MitraClip device (Evalve Inc., Menlo Park, CA) provides the largest body of evidence in this field. The safety and mid-term durability results of the initial Endovascular Valve Edge-to-Edge REpair Study (EVEREST) cohort have been recently reported with a 74% acute procedural success rate (placement of 1 or more clips resulting in a discharge mitral regurgitation severity of  $\leq 2+$ ).<sup>24</sup> In addition, the 1-, 2- and 3-year survival rates were 96%, 94% and 90%, respectively, whereas the freedom from mitral surgery rates were 86%, 83% and 76%, respectively.<sup>24</sup> To maximize the procedural success rate, accurate patient selection is crucial. This procedural technique may be suitable for patients with degenerative (primary) or functional moderate-to-severe or severe mitral regurgitation who fulfil the following key anatomic criteria: regurgitant jet origin at the middle scallops of the mitral valve (A2-P2) in the absence of severe dilatation of the mitral annulus, and for patients with leaflet flail, a flail gap  $< 10$  mm and flail width  $< 15$  mm, and for patients with functional mitral regurgitation, a coaptation length  $\geq 2$  mm and a coaptation depth  $< 11$  mm.<sup>24</sup> As mentioned before, real-time 3D TEE yields a comprehensive and accurate evaluation of these patients. However, other 3D imaging modalities such as MRI or MDCT may provide invaluable information on mitral regurgitation quantification and mitral valve geometry, respectively.<sup>22, 25-27</sup> During the procedure, TEE plays a central role guiding the puncture of the posterior and superior portion of the interatrial septum and guiding the advancement and positioning of the catheter-delivery devices. Initial experimental studies have also shown the usefulness of intracardiac echocardiography to guide the procedure.<sup>14</sup> After transseptal puncture, the MitraClip is steered, aligned perpendicularly to the mitral coaptation line and centered over the origin of the regurgitant jet. The two arms of the device are opened and the clip is advanced into the left ventricle below the mitral leaflets. Then, the clip is retracted until the two leaflets are grasped and then closed to coapt the mitral leaflets (Figure 6). The immediate reduction in mitral regurgitation can be evaluated with TEE.

The spatial relationship between the coronary sinus and the mitral annulus has promoted the development of **percutaneous coronary sinus annuloplasty** techniques that simulate the surgical restrictive ring annuloplasty. By placing anchors or stents at the distal coronary sinus or the great cardiac vein and at the ostium of the coronary sinus connected by a bridging device, the coronary sinus is constrained and the cross sectional area of the mitral annulus is reduced with consequent improvement of the mitral leaflet coaptation. Several devices have been tested in the last years.<sup>18</sup>

**Figure 6. Transcatheter edge-to-edge mitral valve repair.** The MitraClip device (Evalve Inc., Menlo Park, CA) (A) is a 4-mm wide cobalt/chromium implant with 2 clip arms covered with polyester fabric to promote tissue ingrowth. The distal gripping elements secure the leaflet fixation (arrow, B). Real-time 3D TEE demonstrates the final double-orifice mitral valve viewed from the left atrial side (arrow, C). Adapted with permission from Silvestry et al.<sup>54</sup> and Swaans et al.<sup>55</sup>



Abbreviations: AoV = aortic valve; LA = left atrium

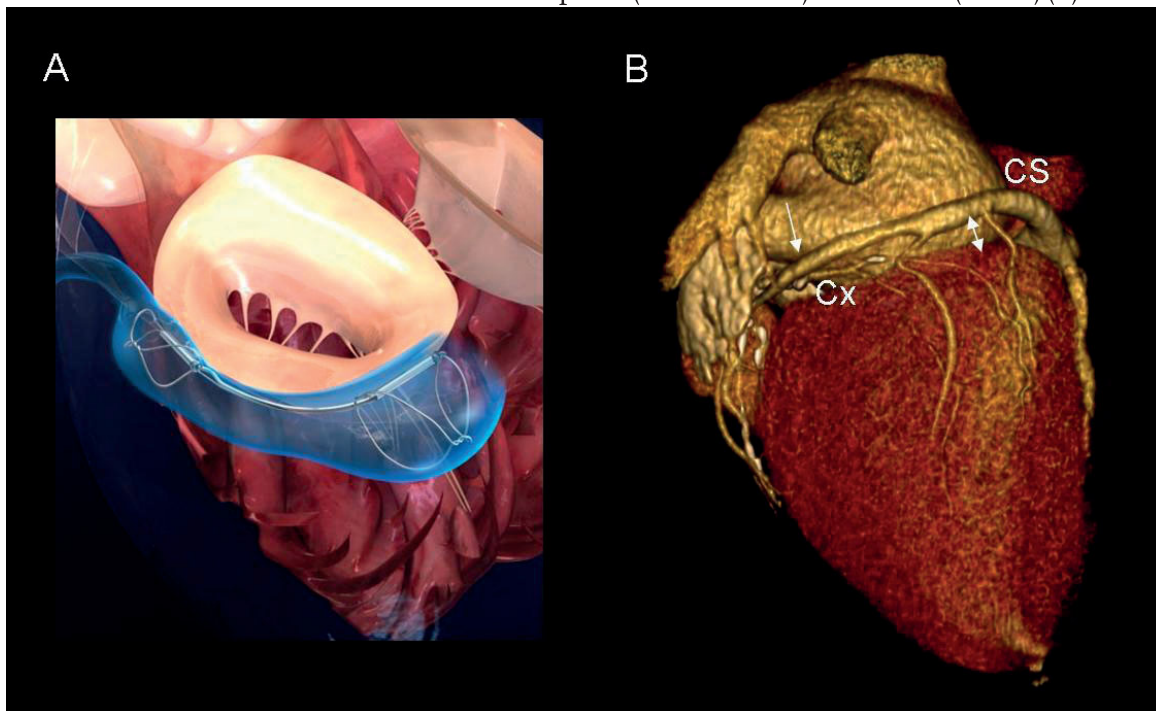
Recently, the results of the CARILLON Mitral Annuloplasty Device European Union Study (AMADEUS) trial have demonstrated the feasibility of this interventional procedure in 48 patients with moderate or severe functional mitral regurgitation.<sup>28</sup> The CARILLON Mitral Contour System (Cardiac Dimensions Inc., Kirkland, WA), consists of a fixed-length, double-anchor, nitinol device and, as advantages, this device can be removed or adjusted at the time of implantation. The CARILLON device could be implanted in 30 patients with significant and sustained reductions in regurgitant volumes at 6 months follow-up.<sup>28</sup> This technique is challenged by the location of the coronary sinus relative to the mitral annulus and to the circumflex artery. MDCT provides 3D visualization of these anatomical structures and may constitute a valuable pre-procedural screening tool to select the patients amenable for this repair technique.<sup>29, 30</sup> Recently, Tops et al.<sup>30</sup> studied these anatomical relationships with 64-row MDCT in 105 patients, including 34 patients with functional mitral regurgitation.<sup>30</sup> In the majority of the patients, the coronary sinus coursed superiorly to the mitral annulus and, therefore, the effectiveness of the percutaneous coronary sinus annuloplasty in reducing mitral regurgitation severity may be limited (Figure 7). In addition, in 68% of the patients, the circumflex artery coursed between the coronary sinus and the mitral valve annulus, increasing the risk of arterial impingement and myocardial infarction.<sup>30</sup> These anatomical relationships should be also taken into account during the procedure. The implant procedure is performed with fluoroscopy and echocardiography guidance. First, a venogram is performed to assure the luminal dimensions of the coronary sinus and the great cardiac vein. The positioning of the distal anchor is guided with fluoroscopy and, during deployment of the anchor, an arteriogram is performed to assure patency of the circumflex artery. Once, the distal anchor is deployed, the delivery system is manually tracked to reduce the



cross sectional area of the mitral annulus. Reduction of mitral regurgitation severity is evaluated with echocardiography and finally, the proximal anchor is deployed.

(PERHAPS LESS EMPHASIS ON THE PROCEDURE ITSELF AND CLINICAL RESULTS – BOTH FOR THE TAVI AND FOR THE MVR<sub>p</sub> – AND MORE EMPHASIS ON THE DETAILS OF THE DIFFERENT IMAGING TECHNIQUES WOULD BE BEST FOR THIS PAPER, SINCE THERE WILL BE OTHER PAPERS ON THE SAME SUPPLEMENT THAT WILL ADDRESS THEM)

**Figure 7. Transcatheter coronary sinus annuloplasty.** The CARILLON Mitral Contour System (Cardiac Dimensions Inc., Kirkland, WA) is designed to be implanted within the coronary sinus (CS) or the great cardiac vein to reduce the cross sectional area of the mitral annulus and, subsequently, to reduce the functional mitral regurgitation (A). The procedural feasibility and the effectiveness of this device to reduce mitral regurgitation severity depend on the anatomical course of the coronary sinus in relation to the mitral annular plane and the circumflex artery (Cx). MDCT provides 3D visualization of these spatial relationships and enables the relative distance between the CS and the mitral annular plane (double arrow) and the Cx (arrow) (B).



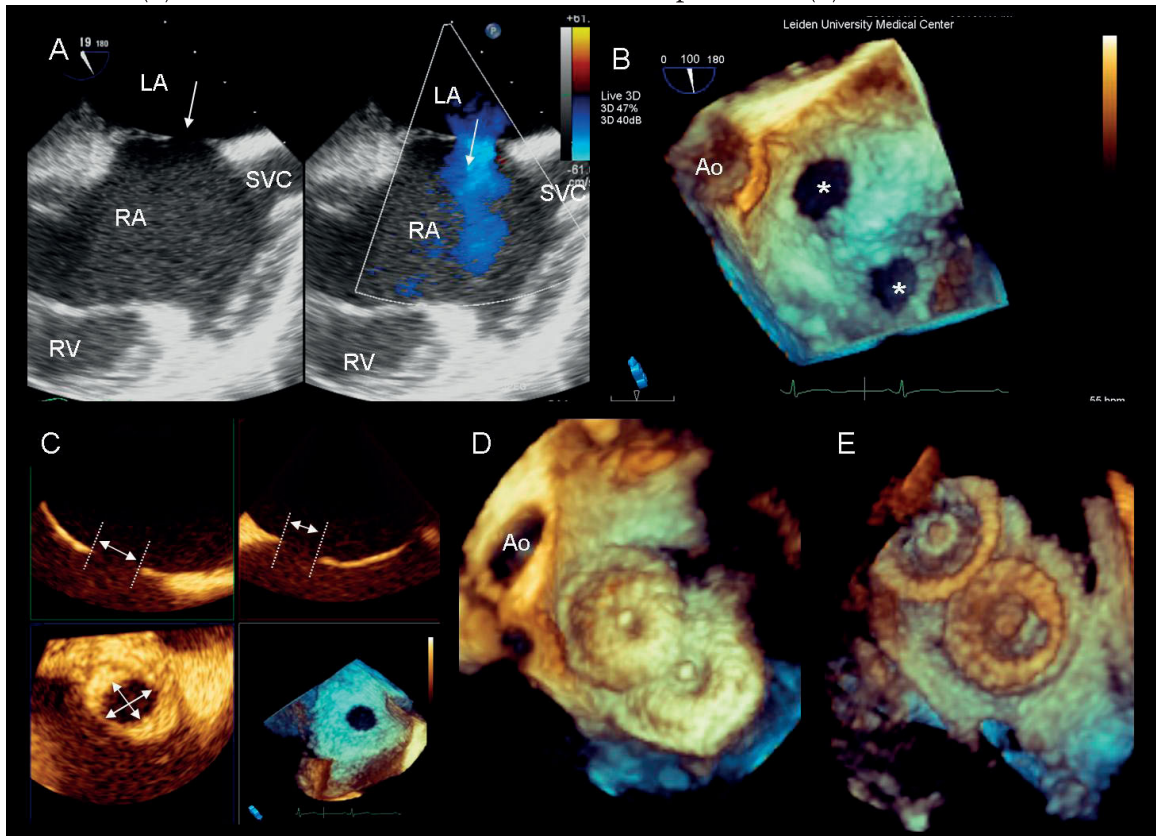
### *Transcatheter closure of ASD and patent foramen ovale*

Transcatheter closure is a well-established treatment for secundum type ASD in children and adults. Compared to surgery, transcatheter closure procedures provide similar hemodynamic benefits and favourable cardiac remodeling while minimizing the hospital stay and recovery.<sup>1</sup> In experienced hands, the procedural success rate is 95% with a low rate of major complications such as cardiac perforation or device embolization (<1%).<sup>31</sup> The indications for transcatheter closure of ASD are the

same than for surgery: presence of hemodynamically significant left-to-right shunt (a ratio of pulmonary blood flow [Qp] to systemic blood flow [Qs] of >1.5:1.0) and/or enlargement of right chambers with an ASD of >10 mm and without significant pulmonary hypertension.<sup>32</sup> However, there are several additional features that define the candidates for transcatheter closure. Secundum type ASD amenable for transcatheter closure should be smaller than 36-40 mm diameter and have adequate septal rims (> 4mm) for stable anchoring of the occluder device.<sup>32</sup> In addition, the procedural feasibility depends on the presence of abnormal pulmonary vein drainage and the exact position of the ASD relative to other structures such as atrioventricular valves, coronary sinus or inferior vena cava. The presence of abnormal pulmonary vein drainage or close relation to any of the aforementioned structures indicate preferably surgical treatment. Therefore, in the pre-procedural screening, cardiac imaging plays a central role with echocardiography as the imaging modality of reference. Two-dimensional echocardiography permits the evaluation of all the aforementioned issues (Figure 8A). However, recent advances in real-time 3D TEE have provided en face ASD images with improved accuracy in real-time estimation of the defect size and morphology (Figure 8B,C).<sup>33</sup> Recently, using as a reference sizing balloons, Taniguchi et al.<sup>34</sup> demonstrated that real-time 3D TEE provided more accurate ASD dimensions than 2D TEE.<sup>34</sup> In addition, the intra- and inter-observer variability for maximal ASD diameter estimation was significantly lower with the use of real-time 3D TEE than 2D TEE (3.6% and 4.8% vs. 8.9% and 9.9%, respectively;  $p < 0.0001$ ).<sup>34</sup>

Among several ASD occluder devices, the Amplatzer Septal Occluder (AGA Medical Corporation, Golden Valley, MN) is the most commonly used. This device consists of two, self-expandable, nitinol alloy wire-mesh discs joined at a waist. Transcatheter ASD closure is performed through an antegrade approach, via the femoral vein, with fluoroscopic and echocardiographic (transesophageal or intracardiac echocardiography) guidance. The ASD is imaged by echocardiography and with the use of a sizing balloon, the dimensions of the septal defect are measured to select the most appropriate device size. The defect is crossed with a semistiff wire and the delivery system passes orthogonally through the septal defect. Thereafter, the left and the right discs are sequentially unfolded and before the device is released, the exact positioning of the occluder should be ensured. In this key step, real-time 3D TEE may provide a superb on-line view of the device position in the interatrial septum and its spatial relationship with surrounding cardiac structures (atrioventricular valves or coronary sinus) (Figure 8D,E). Finally, the presence of residual shunting should be evaluated. Hemodynamically non-significant shunts are often observed at the end of the procedure but most of them close spontaneously within the first year.<sup>1</sup>

**Figure 8. Transcatheter atrial septal defect closure.** Echocardiography is the first choice imaging modality to localize and evaluate the dimensions of the atrial septal defect (A). Doppler echocardiographic techniques permit the assessment of the left-to-right shunt (A). During the procedure, real-time 3D TEE may provide a more accurate visualization and measurement of the ASD (B). The presence of multiple ASD may be rather common (stars, B) and real-time 3D TEE enables the en face view of the entire atrial septum and the spatial relationship between the defects. This imaging modality permits also multiplanar reformatting planes to accurately measure the size of the defect (C). Finally, 3D reconstructions from the left atrial view (D) and the right atrial view (E) illustrate the final result of the device implantation (E).



Abbreviations: Ao = aortic valve; LA = left atrium; RA = right atrium; RV = right ventricle; SVC = superior vena cava.

The number of transcatheter patent foramen ovale closure procedures has increased dramatically in the last years. Over 1100 patients have received an Amplatzer PFO occluder (AGA Medical Corporation, Golden Valley, MN) for secondary prevention of stroke.<sup>35</sup> The prevalence of patent foramen ovale in the general population is rather high (15% to 27% according to echocardiography- or anatomy-based series) and frequently, is associated with an atrial septal aneurysm.<sup>36</sup> Diagnosis of patent foramen ovale relies on echocardiography demonstrating an interatrial communication with right-to-left transit of contrast microbubbles within 3 or 4 beats after opacification of right atrium.<sup>32</sup> Atrial septal aneurysm is diagnosed by the visualization of a redundant and hypermobile portion of the interatrial septum with more 10 mm excursion from the centreline during the cardiac cycle.<sup>32</sup> During the last decades, several observational, non-controlled studies have related the presence of a

patent foramen ovale to increased risk of cryptogenic cerebral stroke or paradoxical thromboembolism.<sup>35</sup> In the Patent Foramen Ovale in Cryptogenic Stroke Study (PICCS) a patent foramen ovale was present almost 39% of the patients with a cryptogenic stroke vs. 30% of the patients with known cause of stroke.<sup>37</sup> Pooled data from non-randomized studies favour transcatheter closure of patent foramen ovale over medical therapy, with reduced 1-year rates of recurrent neurological thromboembolism (0-5% vs. 4-12%, respectively) and with a mean frequency of major complications of 2.3%.<sup>38</sup> Nevertheless, current guidelines recommend transcatheter closure of patent foramen ovale only in patients with recurrent cryptogenic stroke despite optimal medical therapy (class IIB, level of evidence C).<sup>35</sup> Ongoing randomized, controlled trials will provide the best evidence on the safety and efficacy of transcatheter patent foramen ovale closure relative to antithrombotic therapy.<sup>35</sup>

Although highly experienced centers have demonstrated successful transcatheter closure of patent foramen ovale with only fluoroscopic guidance,<sup>39</sup> the combination of fluoroscopy and echocardiography (transesophageal or intracardiac) may constitute the best approach to achieve the highest success rate while minimizing the complications rate.<sup>40</sup> The interventional procedure is similar to the ASD closure procedure. With fluoroscopy, the so-called Pacman sign may be visualized before the device is released.<sup>39</sup> The cranial halves of the left and the right discs should appear as open jaws biting the thick septum secundum. However, the goal of the patent foramen ovale closure is to eliminate the shunt between right and left atria, abolishing, therefore, the risk of recurrent paradoxical thromboembolism. In patients with tunnel defects, atrial septal aneurysm or who require large occluder devices, the risk of residual shunting is higher and therefore, the use of echocardiography during the procedure may be helpful to accurately measure the defect, select the most appropriate device size and to help in the positioning and delivering of the occluder device.<sup>41</sup>

(AGAIN, I THINK THE EMPHASIS SHOULD BE MORE ON THE IMAGING RATHER THAN DESCRIBING DEVICES OR RESULTS. HOW TO BEST DEFINE THE 5 SEGMENTS OF THE ASD RIMS, 2D-TTE, 2D-TEE, ICE AND RT-3D TEE)

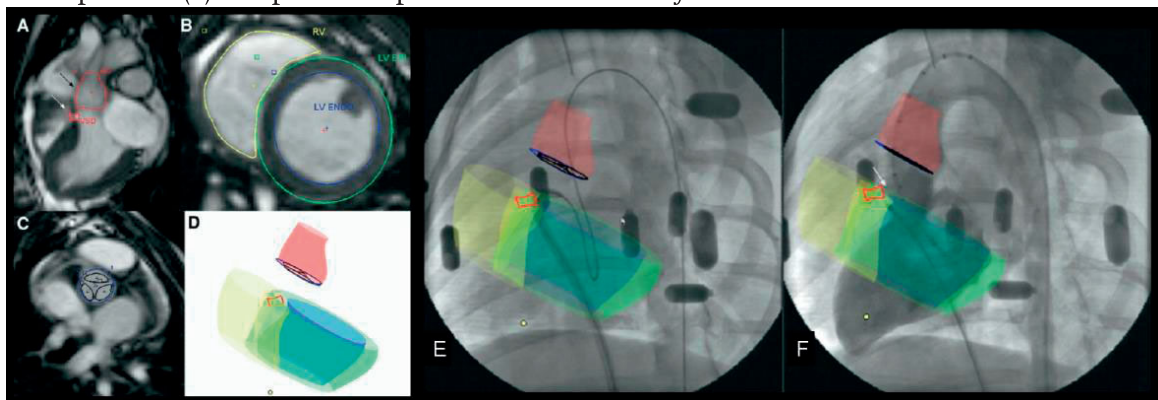
## Transcatheter closure of VSD

Ventricular septal defects account for 20% of the congenital heart disease.<sup>2</sup> In up to 70% of the patients, the location of the VSD is perimembranous whereas muscular VSD are observed in 15%.<sup>2</sup> Supracrystal or multiple VSD are rarely observed. Indications for VSD closure include heart failure symptoms, enlargement of left cardiac chambers or history of endocarditis.<sup>2</sup> Surgical closure remains the first choice



treatment of VSD. However, in highly experienced centers, transcatheter closure of both perimembranous and muscular VSD compares favourably to surgical (NOT SO FOR THE PERIMEMBRANOUS) closure with procedural success rates around 95% and limited number of complications.<sup>2</sup> Compared to transcatheter closure of ASD, closure of VSD is more challenging due to the contraction of the interventricular septum. (UNDERSTANDING THE SPATIAL CONFIGURATION OF THE RV RAPPING AROUND THE LV AS WELL AS THE CONCRETE ANATOMICAL LOCATION OF THE VSD - APICAL, ANTERIOR, INLET, OUTLET, SUB-ARTERIAL ETC, IS PRIMORDIAL TO SELECT WHICH PATIENTS ARE AMENABLE TO CLOSURE BY CURRENT DEVICES) Particularly, the closure of perimembranous VSD faces an increased risk of complete atrioventricular block with the subsequent need for pacemaker. Accurate morphologic assessment and location of a hemodynamically significant VSD are crucial pre-procedural screening steps. Echocardiography constitutes the imaging technique of choice to evaluate all these parameters. Specifically, transcatheter closure of perimembranous VSD is feasible when a rim of at least 1 mm separating the aortic valve from the VSD exists.<sup>42</sup> Patients with infundibular defects, perimembranous VSD and prolapse of one of the aortic leaflets or malalignment are not amenable for transcatheter closure and should be referred to surgery. The interventional procedure is performed with fluoroscopic and echocardiographic guidance. First, a left ventricular angiogram helps to localize the septal defect and echocardiography helps to accurately measure the maximum diameter of the defect. According to the size and the location of the defect, the occluder device size and type will be selected. Different occluder devices exist for each type of VSD: muscular (Amplatzer mVSD) and perimembranous (Amplatzer pmVSD) (AGA Medical Corporation, Golden Valley, MN). An antegrade approach is commonly used to advance the delivery system and to cross the muscular VSD.<sup>43</sup> Once the left ventricular disc is deployed and pulled against the septum, the correct position of the occluder device is confirmed with echocardiography or fluoroscopy. Thereafter, the right ventricular disc is deployed and the device is released. In contrast, a retrograde approach is preferred to close the perimembranous VSD since there are no fluoroscopic landmarks to cross the defect.<sup>42</sup> Subsequently, the right ventricular disc of the device is deployed and pulled against the septum and finally, the left ventricular disc is deployed and the device is released. Recently, advances in image fusion have facilitated the antegrade approach to percutaneously close the perimembranous septal defects.<sup>44</sup> Ratnayaka et al. demonstrated that fluoroscopy image fused with magnetic resonance imaging roadmaps permits antegrade approach reducing the radiation exposure compared to conventional retrograde approach (Figure 9).<sup>44</sup> Finally, the results can be evaluated with echocardiography with special attention to the residual shunt.

**Figure 9. Novel image fusion technologies to assist transcatheter VSD closure.** Antegrade transcatheter closure of perimembranous VSD assisted by X-ray fused with MRI roadmaps (XFM). First, from a long-axis 3-chamber steady-state free precession MRI the contours of the aortic root (in red) and the perimembranous VSD (in red) are traced (A) whereas the endocardial borders of the right (in yellow) and left (in green) ventricles are traced from the short-axis views (B). In addition, the aortic root and the aortic leaflets contours are traced from the short-axis views (C). These MRI-derived contours provide the data to render the aforementioned structures in three dimensions (D). During the procedure, the VSD is identified with XFM guidance. Through an antegrade approach, the delivery system is directed towards the left ventricular apex (E) and confirmatory XFM ventriculography demonstrates the deployment of the occluder device in the exact position (F). Adapted with permission from Ratnayaka et al.<sup>44</sup>



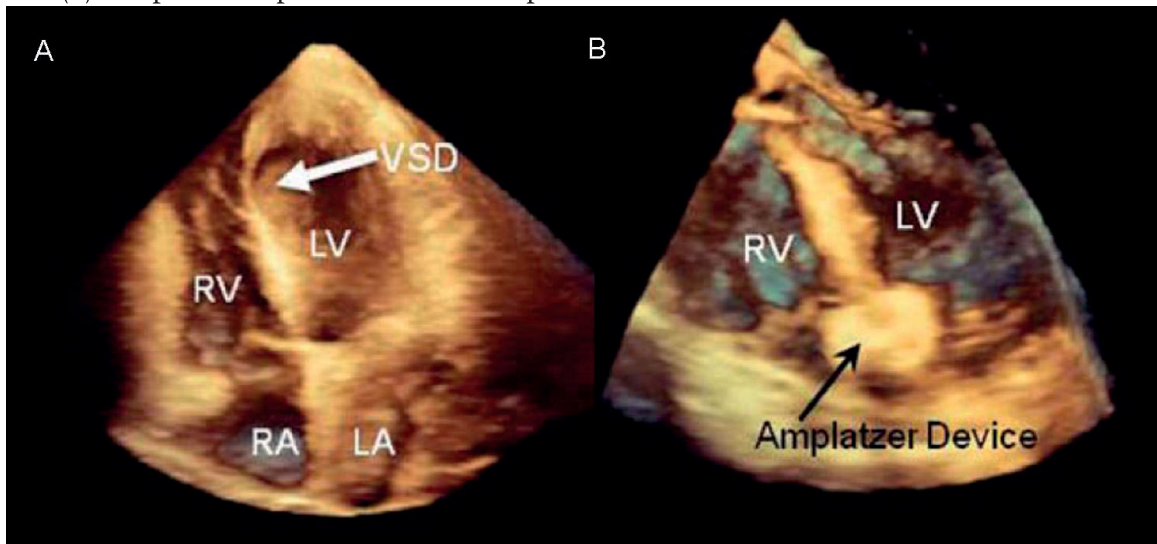
Limited experience exists on transcatheter closure of post-myocardial infarction ventricular septal rupture.<sup>45, 46</sup> With primary coronary intervention, this complication is currently rather uncommon and when it occurs, surgery is the preferred treatment. However, in high-risk patients such as elderly patients or with associated co-morbidities, transcatheter closure of ventricular septal rupture may be an alternative option. Limited registries and several case reports have demonstrated the feasibility of this intervention.<sup>45, 46</sup> Ischemic ventricular septal ruptures show usually a complex morphology with multiple orifices and tunnels. Real-time 3D echocardiography may be a valuable imaging technique to assist the procedure. As mentioned previously, real-time 3D echocardiography provides accurate information on the location and size and morphology of the septal defect (Figure 10).<sup>45</sup> However, the still high 30-day mortality rate (28%) after the procedure warrants further studies before this technique is widely implemented in the clinical practice. (AGAIN, LESS EMPHASIS ON DEVICES AND RESULTS, AND PERHAPS MORE ON IMAGING DETAILS WOULD BE PREFERABLE)

### Transcatheter left atrial appendage closure

Atrial fibrillation is the most common sustained cardiac arrhythmia with a prevalence of 6 millions of individuals in United States.<sup>47</sup> Atrial fibrillation is related to an increased risk of stroke (5%/year).<sup>48</sup> Despite the efficacy of anticoagulation to

prevent future strokes, recent registries demonstrated that only 50% of the patients who would benefit of long-term warfarin are treated with it.<sup>49</sup> Based on anatomical and echocardiography series, the left atrial appendage is the site of thrombi formation and embolism in 90% of the patients.<sup>50, 51</sup> Therefore, the closure of this anatomic structure in patients with non-valvular atrial fibrillation may prevent future strokes. The Percutaneous Left Atrial Appendage Transcatheter Occlusion (PLAATO) trial demonstrated the feasibility and the safety of the occlusion of the left atrial appendage with the PLAATO system (Appriva Medical Inc., ev3, Sunnyvale, CA).<sup>52</sup> This non-randomized trial was the first in reporting significant reductions in the annualized stroke/transient ischemic attack rate (3.8% vs. the 6.6% expected rate based on the CHADS<sub>2</sub> score) with limited procedure-related complication rates.<sup>52</sup> Recently, the randomized PROTECT AF (WATCHMAN Left Atrial Appendage System for Embolic Protection in Patients with Atrial Fibrillation) trial have extended these results and confirmed the non-inferiority of the occluder device (Atritech Inc., Plymouth, MN) against chronic warfarin therapy.<sup>53</sup> Successful implantation of the device was achieved in 88% of the patients whereas the procedural complication rate was relatively low (4.8%).<sup>53</sup>

**Figure 10. Transcatheter closure of post-myocardial infarction muscular VSD.** Real-time 3D TTE demonstrates the apical septal thinning and ventricular septal defect (A). After the transcatheter closure, real-time 3D TTE demonstrates the final position of the deployed occluder device (B). Adapted with permission from Halpern et al.<sup>45</sup>



Abbreviations: LA = left atrium; LV = left ventricle; RA = right atrium; RV = right ventricle; VSD = ventricular septal defect.

Cardiac imaging plays a central role in the pre-procedural screening with TEE as the mainstay imaging technique. The orifice of the left atrial appendage should be measured in two orthogonal views to select the most appropriate device size. Therefore,

real-time 3D TEE may improve the accuracy of the measurements by providing en face views where the left atrial appendage orifice could be visualized and measured without geometric assumptions. However, to date there is no experience with this imaging technique. In addition, echocardiography is a valuable imaging modality to rule out the presence of procedural contraindications (significant mitral or aortic stenosis, moderate or severe mitral regurgitation, mobile or planar clot in the left atrium or atrial appendage and enlarged left atrium [ $>65$  mm]). During the procedure, combination of fluoroscopy and transesophageal or intracardiac echocardiography provides the most accurate guidance. A left atrial appendogram (APPENDAGE ANGIOGRAM) is performed to measure the dimensions of the left atrial appendage and to select the size of the device (usually 10-20% larger than the diameter of the left atrial appendage). After transseptal puncture the delivery system is positioned into the left atrial appendage. Once satisfied, the device can be released and the final position is confirmed by cineangiography or with color Doppler echocardiography to evaluate potential leaks around the implant's edges.

## CONCLUSIONS AND FUTURE PERSPECTIVES

Accurate visualization of different cardiac structures is mandatory to maximize the success rate of current catheter-based intervention procedures. Recent advances in cardiac imaging modalities such as real-time 3D TEE, MDCT or MRI have improved significantly the visualization and characterization of cardiac structures and have facilitated the dissemination of several transcatheter procedures. Some procedures are challenging and require high experience. However, combination of fluoroscopy and, most frequently, echocardiography yields an accurate procedural guidance to achieve the highest success rate with the lowest complication rates. Current catheterization laboratories may evolve to hybrid operating rooms with sufficient space to hold multi-modality imaging capabilities (3D echocardiography, MDCT and MRI). This is particularly of interest in the emerging field of transcatheter valve implantation. However, other procedures such as transcatheter closure of perimembranous VSD may be facilitated by novel image-fusion technologies that require MRI or MDCT. Ongoing research will provide novel tools to increase the number of catheter-based procedures to treat several structural heart diseases that remain currently in the surgery domain.

## DISCLOSURES

Jeroen J. Bax receives grants from Biotronik, BMS medical imaging, Boston Scientific, Edwards Lifesciences, GE Healthcare, Medtronic and St. Jude Medical. Martin J. Schalij receives grants from Biotronik, Boston Scientific & Medtronic. The remaining authors: none.



## REFERENCES

- (1) Webb G, Gatzoulis MA. Atrial septal defects in the adult: recent progress and overview. *Circulation* 2006;114:1645-1653.
- (2) Carminati M, Butera G, Chessa M, De GJ, Fisher G, Gewillig M, Peuster M, Piechaud JF, Santoro G, Sievert H, Spadoni I, Walsh K. Transcatheter closure of congenital ventricular septal defects: results of the European Registry. *Eur Heart J* 2007;28:2361-2368.
- (3) Zajarias A, Cribier AG. Outcomes and safety of percutaneous aortic valve replacement. *J Am Coll Cardiol* 2009;53:1829-1836.
- (4) Lung B, Baron G, Butchart EG, Delahaye F, Gohlke-Barwolf C, Levang OW, Tornos P, Vanoverschelde JL, Vermeer F, Boersma E, Ravaud P, Vahanian A. A prospective survey of patients with valvular heart disease in Europe: The Euro Heart Survey on Valvular Heart Disease. *Eur Heart J* 2003;24:1231-1243.
- (5) Cribier A, Eltchaninoff H, Tron C, Bauer F, Agatiello C, Sebah L, Bash A, Nusimovici D, Litzler PY, Bessou JP, Leon MB. Early experience with percutaneous transcatheter implantation of heart valve prosthesis for the treatment of end-stage inoperable patients with calcific aortic stenosis. *J Am Coll Cardiol* 2004;43:698-703.
- (6) Kapadia SR, Goel SS, Svensson L, Roselli E, Savage RM, Wallace L, Sola S, Schoenhagen P, Shishehbor MH, Christofferson R, Halley C, Rodriguez LL, Stewart W, Kalahasti V, Tuzcu EM. Characterization and outcome of patients with severe symptomatic aortic stenosis referred for percutaneous aortic valve replacement. *J Thorac Cardiovasc Surg* 2009;137:1430-1435.
- (7) Lefevre T. The SOURCE Registry. Paper presented at: *Transcatheter Cardiovascular Therapeutics, October 13, 2008; Washington, DC 2008.*
- (8) Piazza N, Grube E, Gerckens U, den HP, Linke A, Luha O, Ramondo A, Ussia G, Wenaweser P, Windecker S, Laborde JC, De JP, Serruys PW. Procedural and 30-day outcomes following transcatheter aortic valve implantation using the third generation (18 Fr) corevalve revalving system: results from the multicentre, expanded evaluation registry 1-year following CE mark approval. *EuroIntervention* 2008;4:242-249.
- (9) Webb JG, Altwegg L, Boone RH, Cheung A, Ye J, Lichtenstein S, Lee M, Masson JB, Thompson C, Moss R, Carere R, Munt B, Nietlispach F, Humphries K. Transcatheter aortic valve implantation: impact on clinical and valve-related outcomes. *Circulation* 2009;119:3009-3016.
- (10) Moss RR, Ivens E, Pasupati S, Humphries K, Thompson CR, Munt B, Sinhal A, Webb JG. Role of Echocardiography in Percutaneous Aortic Valve Implantation. *J Am Coll Cardiol Img* 2008;1:15-24.
- (11) Smid M, Ferda J, Baxa J, Cech J, Hajek T, Kreuzberg B, Rokyta R. Aortic annulus and ascending aorta: Comparison of preoperative and perioperative measurement in patients with aortic stenosis. *Eur J Radiol* 2009 in press DOI:10.1016/j.ejrad.2009.01.028.
- (12) Tops L, Wood D, Delgado V, Schuijf J, Mayo J, Pasupati S, Lamers F, van der Wall E, Schalij M, Webb J, Bax J. Non-invasive Evaluation of the Aortic Root With Multislice Computed Tomography Implications for Transcatheter Aortic Valve Replacement. *J Am Coll Cardiol Img* 2008;1:321-330.

- (13) Kurra V, Schoenhagen P, Roselli EE, Kapadia SR, Tuzcu EM, Greenberg R, Akhtar M, Desai MY, Flamm SD, Halliburton SS, Svensson LG, Sola S. Prevalence of significant peripheral artery disease in patients evaluated for percutaneous aortic valve insertion: Preprocedural assessment with multidetector computed tomography. *J Thorac Cardiovasc Surg* 2009;137:1258-1264.
- (14) Naqvi TZ. Echocardiography in percutaneous valve therapy. *JACC Cardiovasc Imaging* 2009;2:1226-1237.
- (15) Ng AC, van der KF, Delgado V, Shanks M, van Bommel RJ, de WA, Tavilla G, Holman ER, Schuijf JD, van d, V, Schalij MJ, Bax JJ. Percutaneous valve-in-valve procedure for severe paravalvular regurgitation in aortic bioprosthesis. *JACC Cardiovasc Imaging* 2009;2:522-523.
- (16) Detaint D, Sundt TM, Nkomo VT, Scott CG, Tajik AJ, Schaff HV, Enriquez-Sarano M. Surgical correction of mitral regurgitation in the elderly: outcomes and recent improvements. *Circulation* 2006;114:265-272.
- (17) Mirabel M, Iung B, Baron G, Messika-Zeitoun D, Detaint D, Vanoverschelde JL, Butchart EG, Ravaud P, Vahanian A. What are the characteristics of patients with severe, symptomatic, mitral regurgitation who are denied surgery? *Eur Heart J* 2007;28:1358-1365.
- (18) Tops LF, Kapadia SR, Tuzcu EM, Vahanian A, Alfieri O, Webb JG, Bax JJ. Percutaneous valve procedures: an update. *Curr Probl Cardiol* 2008;33:417-457.
- (19) Carabello BA. The current therapy for mitral regurgitation. *J Am Coll Cardiol* 2008;52:319-326.
- (20) Zoghbi WA, Enriquez-Sarano M, Foster E, Grayburn PA, Kraft CD, Levine RA, Nihoyannopoulos P, Otto CM, Quinones MA, Rakowski H, Stewart WJ, Waggoner A, Weissman NJ. Recommendations for evaluation of the severity of native valvular regurgitation with two-dimensional and Doppler echocardiography. *J Am Soc Echocardiogr* 2003;16:777-802.
- (21) Ajmone Marsan N, Westenberg J, Ypenburg C, Delgado V, van Bommel RJ, Roes S, Nucifora G, van der Geest J, de Roos A, Reiber J, Schalij MJ, Bax JJ. Quantification of mitral regurgitation by real-time three-dimensional echocardiography: head-to-head comparison with 3D velocity-encoded magnetic resonance imaging. *J Am Coll Cardiol Img* 2010 in press.
- (22) Little SH, Pirat B, Kumar R, Igo SR, McCulloch M, Hartley CJ, Xu J, Zoghbi WA. Three-dimensional color Doppler echocardiography for direct measurement of vena contracta area in mitral regurgitation: in vitro validation and clinical experience. *JACC Cardiovasc Imaging* 2008;1:695-704.
- (23) Alfieri O, Elefteriades JA, Chapolini RJ, Steckel R, Allen WJ, Reed SW, Schreck S. Novel suture device for beating-heart mitral leaflet approximation. *Ann Thorac Surg* 2002;74:1488-1493.
- (24) Feldman T, Kar S, Rinaldi M, Fail P, Hermiller J, Smalling R, Whitlow PL, Gray W, Low R, Herrmann HC, Lim S, Foster E, Glower D. Percutaneous mitral repair with the MitraClip system: safety and midterm durability in the initial EVEREST (Endovascular Valve Edge-to-Edge REpair Study) cohort. *J Am Coll Cardiol* 2009;54:686-694.
- (25) Delgado V, Tops LF, Schuijf JD, de RA, Brugada J, Schalij MJ, Thomas JD, Bax JJ. Assessment of mitral valve anatomy and geometry with multislice computed tomography. *JACC Cardiovasc Imaging* 2009;2:556-565.

- (26) O’Gara PT, Sugeng L, Lang RM, Sarano M, Hung J, Raman S, Fischer G, Carabello BA, Adams D, Vannan M. The role of imaging in chronic degenerative mitral regurgitation. *J Am Coll Cardiol Img* 2008;1:221-237.
- (27) Westenberg JJ, Doornbos J, Versteegh MI, Bax JJ, van der Geest RJ, de RA, Dion RA, Reiber JH. Accurate quantitation of regurgitant volume with MRI in patients selected for mitral valve repair. *Eur J Cardiothorac Surg* 2005;27:462-466.
- (28) Schofer J, Siminiak T, Haude M, Herrman JP, Vainer J, Wu JC, Levy WC, Mauri L, Feldman T, Kwong RY, Kaye DM, Duffy SJ, Tubler T, Degen H, Brandt MC, Van BR, Goldberg S, Reuter DG, Hoppe UC. Percutaneous mitral annuloplasty for functional mitral regurgitation: results of the CARILLON Mitral Annuloplasty Device European Union Study. *Circulation* 2009;120:326-333.
- (29) Choure AJ, Garcia MJ, Hesse B, Sevensma M, Maly G, Greenberg NL, Borzi L, Ellis S, Tuzcu EM, Kapadia SR. In vivo analysis of the anatomical relationship of coronary sinus to mitral annulus and left circumflex coronary artery using cardiac multidetector computed tomography: implications for percutaneous coronary sinus mitral annuloplasty. *J Am Coll Cardiol* 2006 November;48:1938-1945.
- (30) Tops LF, van de Veire N, Schuijf JD, de RA, van der Wall EE, Schalij MJ, Bax JJ. Noninvasive evaluation of coronary sinus anatomy and its relation to the mitral valve annulus: implications for percutaneous mitral annuloplasty. *Circulation* 2007;115:1426-1432.
- (31) Du ZD, Hijazi ZM, Kleinman CS, Silverman NH, Larntz K. Comparison between transcatheter and surgical closure of secundum atrial septal defect in children and adults: results of a multicenter nonrandomized trial. *J Am Coll Cardiol* 2002;39:1836-1844.
- (32) Krasuski RA. When and how to fix a ‘hole in the heart’: approach to ASD and PFO. *Cleve Clin J Med* 2007;74:137-147.
- (33) Balzer J, van HS, Rassaf T, Boring YC, Franke A, Lang RM, Kelm M, Kuhl HP. Feasibility, safety, and efficacy of real-time three-dimensional transoesophageal echocardiography for guiding device closure of interatrial communications: initial clinical experience and impact on radiation exposure. *Eur J Echocardiogr* 2009 in press doi:10.1093/ejehocard/jep116.
- (34) Taniguchi M, Akagi T, Watanabe N, Okamoto Y, Nakagawa K, Kijima Y, Toh N, Ohtsuki S, Kusano K, Sano S. Application of real-time three-dimensional transesophageal echocardiography using a matrix array probe for transcatheter closure of atrial septal defect. *J Am Soc Echocardiogr* 2009;22:1114-1120.
- (35) O’Gara PT, Messe SR, Tuzcu EM, Catha G, Ring JC. Percutaneous device closure of patent foramen ovale for secondary stroke prevention: a call for completion of randomized clinical trials. A science advisory from the American Heart Association/American Stroke Association and the American College of Cardiology Foundation. *J Am Coll Cardiol* 2009;53:2014-2018.
- (36) Garg P, Walton AS. The new world of cardiac interventions: a brief review of the recent advances in non-coronary percutaneous interventions. *Heart Lung Circ* 2008;17:186-199.
- (37) Homma S, Sacco RL, Di Tullio MR, Sciacca RR, Mohr JP. Effect of medical treatment in stroke patients with patent foramen ovale: patent foramen ovale in Cryptogenic Stroke Study. *Circulation* 2002;105:2625-2631.



- (38) Khairy P, O'Donnell CP, Landzberg MJ. Transcatheter closure versus medical therapy of patent foramen ovale and presumed paradoxical thromboemboli: a systematic review. *Ann Intern Med* 2003;**139**:753-760.
- (39) Wahl A, Tai T, Praz F, Schwerzmann M, Seiler C, Nedeltchev K, Windecker S, Mattle H, Meier B. Late results after percutaneous closure of patent foramen ovale for secondary prevention of paradoxical embolism using the Amplatzer PFO occluder without intraprocedural echocardiography: effect of device size. *J Am Coll Cardiol Interv* 2009;**2**:116-123.
- (40) Sorajja P, Nishimura RA. Patent foramen ovale closure without echocardiography: are we closing the door too fast too soon? *J Am Coll Cardiol Interv* 2009;**2**:124-126.
- (41) Balzer J, Kelm M, Kuhl HP. Real-time three-dimensional transoesophageal echocardiography for guidance of non-coronary interventions in the catheter laboratory. *Eur J Echocardiogr* 2009;**10**:341-349.
- (42) Butera G, Carminati M, Chessa M, Piazza L, Micheletti A, Negura DG, Abella R, Giamberti A, Frigiola A. Transcatheter closure of perimembranous ventricular septal defects: early and long-term results. *J Am Coll Cardiol* 2007;**50**:1189-1195.
- (43) Holzer R, Balzer D, Cao QL, Lock K, Hijazi ZM. Device closure of muscular ventricular septal defects using the Amplatzer muscular ventricular septal defect occluder: immediate and mid-term results of a U.S. registry. *J Am Coll Cardiol* 2004;**43**:1257-1263.
- (44) Ratnayaka K, Raman VK, Faranesh AZ, Sonmez M, Kim JH, Gutierrez LF, Ozturk C, McVeigh ER, Slack MC, Lederman RJ. Antegrade percutaneous closure of membranous ventricular septal defect using X-ray fused with magnetic resonance imaging. *JACC Cardiovasc Interv* 2009;**2**:224-230.
- (45) Halpern DG, Perk G, Ruiz C, Marino N, Kronzon I. Percutaneous closure of a post-myocardial infarction ventricular septal defect guided by real-time three-dimensional echocardiography. *Eur J Echocardiogr* 2009;**10**:569-571.
- (46) Holzer R, Balzer D, Amin Z, Ruiz CE, Feinstein J, Bass J, Vance M, Cao QL, Hijazi ZM. Transcatheter closure of postinfarction ventricular septal defects using the new Amplatzer muscular VSD occluder: Results of a U.S. Registry. *Catheter Cardiovasc Interv* 2004;**61**:196-201.
- (47) Miyasaka Y, Barnes ME, Gersh BJ, Cha SS, Bailey KR, Abhayaratna WP, Seward JB, Tsang TS. Secular trends in incidence of atrial fibrillation in Olmsted County, Minnesota, 1980 to 2000, and implications on the projections for future prevalence. *Circulation* 2006;**114**:119-125.
- (48) Sick PB, Schuler G, Hauptmann KE, Grube E, Yakubov S, Turi ZG, Mishkel G, Almany S, Holmes DR. Initial worldwide experience with the WATCHMAN left atrial appendage system for stroke prevention in atrial fibrillation. *J Am Coll Cardiol* 2007;**49**:1490-1495.
- (49) Go AS, Hylek EM, Borowsky LH, Phillips KA, Selby JV, Singer DE. Warfarin use among ambulatory patients with nonvalvular atrial fibrillation: the anticoagulation and risk factors in atrial fibrillation (ATRIA) study. *Ann Intern Med* 1999 December;**131**:927-934.
- (50) Aberg H. Atrial fibrillation. I. A study of atrial thrombosis and systemic embolism in a necropsy material. *Acta Med Scand* 1969;**185**:373-379.
- (51) Stoddard MF, Dawkins PR, Prince CR, Ammash NM. Left atrial appendage thrombus is not uncommon in pa-

- tients with acute atrial fibrillation and a recent embolic event: a transesophageal echocardiographic study. *J Am Coll Cardiol* 1995;25:452-459.
- (52) Block P, Burstein S, Casale P, Kramer P, Teirstein P, Williams D, Reisman M. Percutaneous left atrial appendage occlusion for patients in atrial fibrillation suboptimal for warfarin therapy: 5-year results of the PLAATO (Percutaneous Left Atrial Appendage Transcatheter Occlusion) study. *J Am Coll Cardiol Intv* 2009;2:594-600.
- (53) Holmes DR, Reddy VY, Turi ZG, Doshi SK, Sievert H, Buchbinder M, Mullin CM, Sick P. Percutaneous closure of the left atrial appendage versus warfarin therapy for prevention of stroke in patients with atrial fibrillation: a randomised non-inferiority trial. *Lancet* 2009;374:534-542.
- (54) Silvestry FE, Rodriguez LL, Herrmann HC, Rohatgi S, Weiss SJ, Stewart WJ, Homma S, Goyal N, Pulerwitz T, Zunamon A, Hamilton A, Merlino J, Martin R, Krabill K, Block PC, Whitlow P, Tuzcu EM, Kapadia S, Gray WA, Reisman M, Wasserman H, Schwartz A, Foster E, Feldman T, Wieggers SE. Echocardiographic guidance and assessment of percutaneous repair for mitral regurgitation with the Evalve MitraClip: lessons learned from EVEREST I. *J Am Soc Echocardiogr* 2007;20:1131-1140.
- (55) Swaans MJ, Van den Branden BJ, Van der Heyden JA, Post MC, Rensing BJ, Eefting FD, Plokker HW, Jaarsma W. Three-dimensional transoesophageal echocardiography in a patient undergoing percutaneous mitral valve repair using the edge-to-edge clip technique. *Eur J Echocardiogr* 2009 in press doi:10.1093/ejechocard/jep101.



# Chapter 2

---

**Impact of age on transcatheter aortic valve  
implantation outcomes: a comparison of patients  
aged  $\leq 80$  years versus patients  $> 80$  years**

Frank van der Kley, Philippe J van Rosendael, Spyridon Katsanos, Vasileios Kamperidis, Nina A Marsan, Ioannis Karalis, Arend de Weger, Meindert Palmen, Jeroen J Bax, Martin J SchaliJ, and Victoria Delgado

## ABSTRACT

### Objective

To investigate the procedural outcomes and the long-term survival of patients undergoing transcatheter aortic valve implantation (TAVI) and compare study results of patients  $\leq 80$  years and patients  $> 80$  years old.

### Methods

A total of 240 patients treated with TAVI were divided into two groups according to age  $\leq 80$  years ( $n = 105$ ; 43.8%) and  $> 80$  years ( $n = 135$ ; 56.2%). The baseline characteristics and the procedural outcomes were compared between these two groups of patients.

### Results

With the exception of peripheral artery disease and hypercholesterolemia, which were more frequently observed in the older age group, baseline characteristics were comparable between groups. Complication rates did not differ significantly between patients  $\leq 80$  years and patients  $> 80$  years. There were no differences in 30-day mortality rates between patients aged  $\leq 80$  years and patients  $> 80$  years old (9.5% vs. 7.4%, respectively;  $P = 0.557$ ). After a median follow-up of 28 months (interquartile range: 16–42 months), 50 (47.6%) patients aged  $\leq 80$  years died compared to 57 (42%) deaths in the group of patients  $> 80$  years old ( $P = 0.404$ ).

### Conclusion

The results of the present single center study showed that age did not significantly impact the outcomes of TAVI.

**Keywords:** Age, Survival rate, Transcatheter aortic valve implantation

*J Geriatr Cardiol* 2016; 13: 31–36. doi:10.11909/j.issn.1671-5411.2016.01.004

## 1. INTRODUCTION

Current evidence shows that transcatheter aortic valve implantation (TAVI) is a safe and feasible alternative treatment modality for patients with severe aortic stenosis and contraindications or at high risk for surgical intervention.<sup>[1]-[3]</sup> However, selection of patients is pivotal to ensure a high procedural success rate, minimize the risk of complications and improve the long-term survival of the patients. As the population becomes older, the prevalence of patients with severe aortic stenosis increases significantly.<sup>[4]</sup> There remains however concerns whether TAVI in very old patients is associated with increased procedural risks and if this treatment conveys any significant improvement in survival compared with “younger” patients. With regard to inoperable patients, TAVI has been demonstrated more cost-effective therapy compared to medical treatment, and in high-risk patients the cost-effectiveness of TAVI is less favorable compared to surgical aortic valve replacement.<sup>[5]</sup> Age is one of the variables included in currently used risk stratification engines. However, the evidence showing that TAVI is beneficial in terms of long-term survival across the several age subgroups is scarce.<sup>[6]-[9]</sup> Therefore, we evaluated the procedural outcomes and the long-term survival of patients undergoing TAVI and compared the results of patients  $\leq 80$  years and patients  $> 80$  years old.

## 2. METHODS

A total of 240 patients who underwent TAVI between November 2007 and March 2013, at the Leiden University Medical Centre (the Netherlands) were included in the present evaluation. All patients were diagnosed with symptomatic severe aortic valve stenosis and had high surgical risk or contraindications for surgery. A logistic European System for Cardiac Operative Risk Evaluation I (EuroSCORE I)  $> 20\%$  defined high operative risk.<sup>[10]</sup> Patients who underwent valve-in-valve procedure were excluded.

Patients were clinically evaluated in a multidisciplinary team of clinical, imaging and interventional cardiologists, cardiothoracic surgeons and anesthesiologists, to assess operative risk, comorbidities,<sup>[11]</sup> frailty and procedural feasibility. In addition, transthoracic echocardiography, invasive coronary angiography, and multi-detector row computed tomography (unless contraindicated) were performed to assess aortic stenosis severity, left ventricular (LV) function, associated valvular heart disease, coronary artery disease and anatomy, dimensions of the aortic annulus and peripheral arteries. After TAVI, patients underwent clinical and echocardiographic evaluation at 1, 3, 6 and 12 months follow-up. Clinical and imaging data were prospectively collected in an electronic clinical patient file (EPD Vision version 11.3, Leiden, the

Netherlands) and retrospectively analyzed. The institutional review board approved this retrospective analysis and waived the need of written patient informed consent.

TAVI was performed at the catheterization laboratory or a hybrid operating room under general anesthesia. A balloon expandable system [Edwards Sapien or Sapien XT valve (Edwards Lifesciences, Irvine, CA, USA)] or the self-expandable CoreValve System (Medtronic, Minneapolis, MN, USA) were the transcatheter valves implanted. Transfemoral access was the preferred approach in all patients. Transapical access was performed in patients with inappropriate peripheral artery anatomy. Both accesses were performed by surgical cut-down. Procedures were assisted by transesophageal echocardiography (iE33, Philips Medical Systems, Andover, MA, USA) and the hemodynamics of the transcatheter valve and the presence and grade of (para-) valvular aortic regurgitation were assessed immediately after implantation of the valve. Procedural success and complications were evaluated according to the Valve Academic Research Consortium (VARC) criteria;<sup>[12]</sup> mortality, myocardial infarction, stroke, bleeding, acute kidney injury, vascular complications, and prosthetic valve performance were recorded.

A commercially available ultrasound system (Vivid 7, E9, General Electric Horten, Norway) was used for pre- and post-TAVI transthoracic echocardiography (TTE). The pre-procedural evaluation included the assessment of the valve morphology at the parasternal short-axis view, and the left ventricular outflow tract diameter was measured at the parasternal long-axis view.<sup>[13]</sup> The peak and mean transaortic pressure gradients were assessed in the apical long-axis or 5-chamber views and the aortic valve area was calculated with the continuity equation.<sup>[13]</sup> Aortic stenosis was considered severe if the aortic valve area was  $< 1.0 \text{ cm}^2$  and/or the transaortic mean gradient was  $\geq 40 \text{ mmHg}$  or peak jet velocity  $> 4 \text{ m/s}$ .<sup>[14]</sup> LV end-diastolic and end-systolic volumes were calculated by the method of Simpson and the LV ejection fraction was derived.<sup>[15]</sup> After TAVI, the presence of para-valvular aortic regurgitation was evaluated with color Doppler echocardiography as previously described, and graded according to the VARC-2 criteria.<sup>[16]</sup>

Follow-up was performed in our institution (Leiden University Medical Centre, the Netherlands) during the first year according to the clinical care track. After this period, patients were controlled on a yearly basis in our institution or at the referral hospital. The primary endpoint was all-cause mortality. Survival follow-up data were retrieved from municipality registries. Secondary endpoints included procedure related complications, defined as procedural mortality, stroke, vascular injury, major bleeding, renal failure, a repeat procedure, atrio-ventricular block and pacemaker implantation.<sup>[16]</sup>



A package of SPSS software version 20 (IBM Corp, Armonk, NY, USA) was used for statistical analyses. According to the Kolmogorov-Smirnov test and visual inspection of the histograms, continuous variables were categorized as normally distributed and were presented as mean  $\pm$  SD or as non-normally distributed and were presented as median and inter-quartile range. The categorical variables were presented as number and frequency. Continuous variables were compared with the unpaired Student's *t*-test if they were normally distributed, or otherwise, the Mann-Whitney test. Categorical variables were compared with the  $\chi^2$  test or Fisher's exact test, as indicated. The Kaplan Meier method was used to estimate the cumulative mortality. The Log-rank test was used to compare the two age groups. A two-sided  $P < 0.05$  was considered statistically significant.

**Table 1.** Baseline characteristics.

	All patients (n = 240)	≤ 80 years (n = 105)	> 80 years (n = 135)	P-value
Age, yrs	81 $\pm$ 6.9	74.8 $\pm$ 5.5	85.8 $\pm$ 3.1	-
Female	119 (49.6%)	39 (37.1%)	80 (59.3%)	0.001
Hypertension	180 (75%)	79 (75.2%)	101 (74.8%)	0.940
Smoking	105 (43.8%)	53 (50.5%)	52 (38.5%)	0.064
Diabetes	70 (29.2%)	30 (28.6%)	40 (29.6%)	0.858
Hypercholesterolemia	148 (61.7%)	78 (74.3%)	70 (51.9%)	< 0.001
Ischemic heart disease	152 (63.3%)	70 (66.7%)	82 (60.7%)	0.345
Peripheral artery disease	119 (49.6%)	60 (57.1%)	59 (43.7%)	0.039
Chronic obstructive pulmonary disease	74 (30.8%)	36 (34.3%)	38 (25.9%)	0.307
Creatinine clearance, mL/min per 1.73 m <sup>2</sup> (median: percentiles 25–7 5)	53 $\pm$ 21.9 (43–67.7)	54 $\pm$ 27.6 (43–8 2.5)	52.0 $\pm$ 14.5 (43–5 9)	0.494
Logistic EuroSCORE I	23.2% $\pm$ 14.6%	21.2% $\pm$ 14.8%	24.6% $\pm$ 14.1%	0.072
NYHA Class 1–2	96 (40%)	44 (41.9%)	52 (38.5%)	0.595
NYHA Class 3–4	144 (60%)	61 (58.1%)	83 (61.5%)	0.595
Angina	88 (36.7%)	40 (38.1%)	48 (35.6%)	0.685
Syncope	40 (16.7%)	14 (13.3%)	26 (19.3%)	0.222
Sinus rhythm	171 (71.3%)	79 (75.2%)	92 (68.1%)	0.229
Atrial fibrillation	44 (18.3%)	15 (14.3%)	29 (21.5%)	0.153
Pacemaker	25 (10.4%)	11 (10.5%)	14 (10.4%)	0.979
LV ejection fraction	52.1% $\pm$ 14.5%	50.1% $\pm$ 14.6%	53.6% $\pm$ 14.3%	0.064
Mean transaortic pressure gradient, mmHg	44.3 $\pm$ 19.3	41.7 $\pm$ 19.3	46.4 $\pm$ 19.1	0.062
AVA, cm <sup>2</sup>	0.78 $\pm$ 0.8	0.76 $\pm$ 0.2	0.80 $\pm$ 1.0	0.673
Pulmonary artery pressure, mmHg	36.3 $\pm$ 11.5	36.2 $\pm$ 11.6	36.3 $\pm$ 11.4	0.912
Mitral regurgitation (moderate-severe)	72 (30%)	27 (25.7%)	45 (33.3%)	0.201

Data are presented as mean  $\pm$  SD or *n* (%). Hypertension: history of high blood pressure and/or on antihypertensive treatment; hypercholesterolaemia: history of hypercholesterolemia and/or on statin therapy; diabetes (type 1 and 2) was defined as a fasting plasma glucose level  $\geq 126$  mg/dL, use of oral glucose lowering medication or insulin. AVA: aortic valve area; EuroSCORE I: logistic European System for Cardiac Operative Risk Evaluation I; LV: left ventricle; NYHA: New York Heart Association.

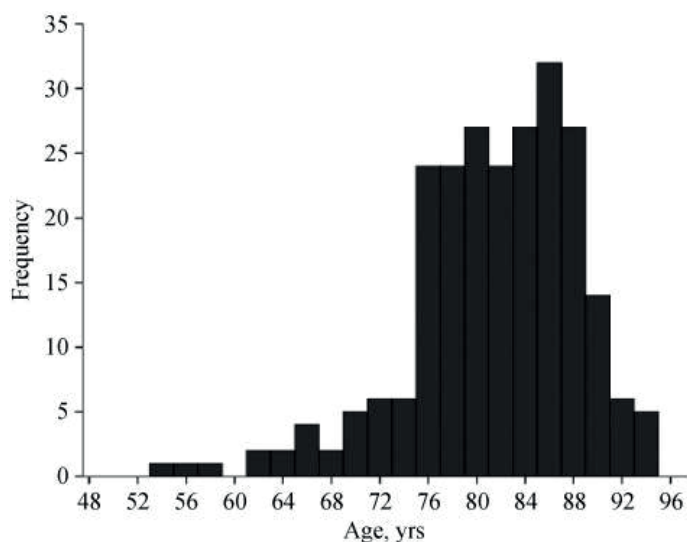
### 3. RESULTS

Table 1 summarizes the clinical and echocardiographic characteristics of the overall population and two subgroups according to age ( $\leq 80$  years old versus  $> 80$  years old). Of the 240 patients, 105 (43.8%) were included in the age group of  $\leq 80$  years and the remaining 135 were older than 80 years. Mean age was  $81 \pm 7$  years. Age distribution



is shown in Figure 1. Patients aged > 80 years were more frequently women and had significantly less frequent hypercholesterolemia and peripheral vascular disease than their younger counterparts. The remaining clinical characteristics were not significantly different between the groups. Logistic EuroSCORE I trended higher in the group of patients aged > 80 years (24.6% vs. 21.2%,  $P = 0.072$ ).

Figure 1.



The transfemoral access was used in 99 (41.3%) patients whereas the remaining patients underwent TAVI through a transapical access. The Edwards Sapien or Sapien XT was implanted in 222 patients. Eighteen patients received a CoreValve bioprosthesis. TAVI was successfully performed in all patients. Peri-procedural complications according to the VARC-2 criteria are described in Table 2. The incidence of peri-procedural complications between the two age groups was not significantly different.

Table 2. Procedural characteristics and peri-procedural complications.

	All patients (n = 240)	≤ 80 years (n = 105)	> 80 years (n = 135)	P-value
Access				
Transfemoral	99 (41.3%)	39 (37.1%)	60 (44.4%)	0.254
Transapical	141 (58.8%)	66 (62.9%)	75 (55.6%)	0.254
Edwards sapien (XT)	222 (92.5%)	99 (94.3%)	123 (91.1%)	0.354
CoreValve	18 (7.5%)	6 (5.7%)	12 (8.9%)	0.354
Vascular injury	23 (9.6%)	10 (9.5%)	13 (9.6%)	0.978
Major	13 (5.4%)	7 (6.7%)	6 (4.4%)	0.451
Minor	12 (5.0%)	4 (3.8%)	8 (5.9%)	0.455
Bleeding	19 (7.9%)	8 (7.6%)	11 (8.1%)	0.880
Major	4 (1.7%)	2 (1.9%)	2 (1.5%)	0.799
Minor	15 (6.3%)	6 (5.7%)	9 (6.7%)	0.762
Stroke	8 (3.3%)	1 (1%)	7 (5.2%)	0.070
Major	5 (2.1%)	1 (1%)	4 (3%)	0.279
Minor	3 (1.3%)	0	3 (2.2%)	0.124
All-cause death (in hospital)	16 (6.7%)	9 (8.6%)	7 (5.2%)	0.297
Non cardiac complications	30 (12.5%)	17 (16.2%)	13 (9.6%)	0.127
Valve migration	1 (0.4%)	0 (0%)	1 (0.7%)	0.377
Acute kidney injury	11 (4.6%)	5 (4.8%)	6 (4.4%)	0.907
AR ≥ 3	12 (5%)	5 (4.8%)	7 (5.2%)	0.881
AV block	13 (5.4%)	6 (5.7%)	7 (5.2%)	0.857
Cardiac tamponade	8 (3.3%)	2 (1.9%)	6 (4.4%)	0.277
Myocardial infarction	0	0	0	

Data are presented as n (%). AR: aortic regurgitation; AV: atrial-ventricular.

Moderate to severe aortic valve regurgitation (valvular or paravalvular) was observed in 5% of the total population and an emergency valve-in-valve implantation was performed in four (1.7%) patients to reduce the grade of aortic regurgitation. Subsequently, valve-in-valve implantation procedures were performed in four (1.7%) additional patients: two patients presented with recurrent, symptomatic, moderate, paravalvular regurgitation within one week, and one patient at three months follow-up after the initial TAVI, and one patient presented with symptomatic aortic stenosis due to degenerative trans-catheter valve prosthesis four years after the initial procedure. The non-cardiac complications were mainly infectious disorders such as pneumonia and post-procedural fever without positive cultures.

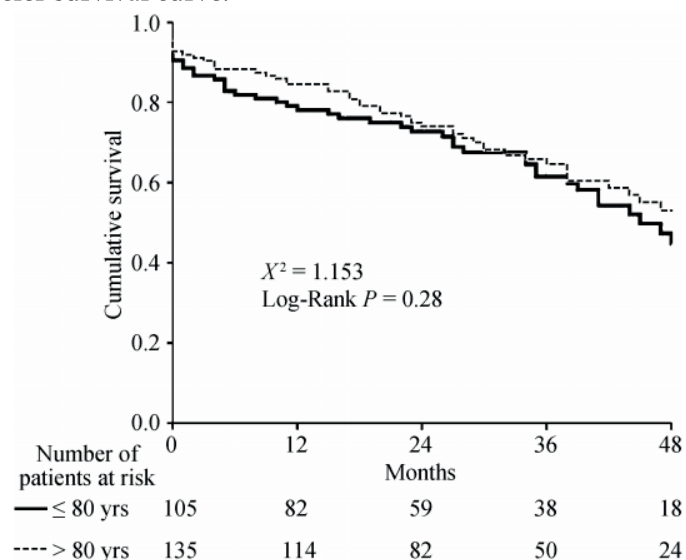
There were no differences in the 30-day all-cause mortality rates between patients aged  $\leq 80$  years and patients  $> 80$  years old (9.5% vs. 7.4%, respectively;  $P = 0.557$ ) (Table 3). During a median follow-up of 28 months (interquartile range: 16–42 months), 50 (47.6%) patients aged  $\leq 80$  years died compared with 57 (42%) deaths in the group of patients  $> 80$  years old ( $P = 0.404$ ) (Figure 2). The cumulative 1- and 2-year all-cause mortality rates among patients aged  $\leq 80$  years were 20.9% and 26.7% respectively compared with 15.6% and 24.4% in patients  $> 80$  years old.

**Table 3.** Cumulative all-cause mortality according to transcatheter aortic valve implantation access.

	30 days			1-yr			2-yr			Total follow up		
	$\leq 80$ yrs	$> 80$ yrs	<i>P</i> -value	$\leq 80$ yrs	$> 80$ yrs	<i>P</i> -value	$\leq 80$ yrs	$> 80$ yrs	<i>P</i> -value	$\leq 80$ yrs	$> 80$ yrs	<i>P</i> -value
Transfemoral	4 (10.3%)	5 (8.3%)	0.746	7 (17.9%)	9 (15%)	0.704	31 (20.5%)	46 (23.3%)	0.840	16 (41%)	23 (38.3%)	0.591
Transapical	6 (9.1%)	5 (6.7%)	0.594	15 (22.7%)	12 (16%)	0.309	46 (30.3%)	56 (25.3%)	0.467	34 (51.5%)	34 (45.3%)	0.452
Total	10 (9.5%)	10 (7.4%)	0.557	22 (20.9%)	21 (15.6%)	0.276	77 (26.7%)	102 (24.4%)	0.592	50 (47.6%)	57 (42.2%)	0.283

Data are presented as *n* (%).

**Figure 2.** Kaplan Meier survival curve.



## 4. DISCUSSION

The present evaluation showed that TAVI is associated with comparable short- and mid-term outcomes in patients aged  $\leq 80$  years and patients older than 80 years.

Data from randomized controlled trials comparing TAVI versus surgical aortic valve replacement or medical treatment demonstrated that age was not an independent determinant of 1-year all-cause mortality.<sup>[1],[17],[18]</sup> In the Placement of Aortic Transcatheter Valves (PARTNER) trial cohort B, which showed that TAVI presented better outcomes than medical treatment in patients with severe aortic stenosis and contraindications for surgical replacement, in which 46% of included patients were aged  $> 85$  years and showed similar benefits from TAVI than patients  $\leq 85$  years old.<sup>[17]</sup> Similarly, the trials that have compared TAVI versus surgical aortic valve replacement in patients with high operative risk included 47% of patients aged  $> 85$  years and showed that both therapeutic arms provided similar outcomes.<sup>[1],[18]</sup> In addition, data from single- or multi-center registries have also shown that age does not significantly impact on the mid- and long-term outcomes of patients undergoing TAVI.<sup>[19]-[22]</sup> For example, in the Society of Thoracic Surgeons/American College of Cardiology Transcatheter Valve Therapy Registry including 7,710 patients undergoing TAVI (80% high-risk patients, 20% inoperable patients), the median age was 84 (interquartile range 78–88 years) and the reported 30-day mortality was 7.6%.<sup>[21]</sup> Similarly, the FRANCE-2 registry including 3,195 patients treated by TAVI (mean age  $82.7 \pm 7.2$  years) showed a 30-day mortality rate of 9.7%,<sup>[20]</sup> while in the Sentinel Registry, including 4,571 patients (mean age  $81.4 \pm 7.1$  years), the in-hospital mortality rate was 7.4%.<sup>[19]</sup> However, in the Sentinel registry, each 8-year increase in age was significantly associated with in-hospital mortality (OR: 1.18; 95% CI: 1.01–1.37,  $P = 0.04$ ).<sup>[19]</sup> Notably, the percentage of patients aged  $> 80$  years was 62.4%. These data are comparable to the data provided by the present study where 57% of patients were  $> 80$  years old. The lack of significant differences in logistic EuroSCORE indicates that the younger group of patients had significantly more comorbidities to justify the high operative risk. These may have influenced the short- and long-term outcomes of these patients leading to similar survival rates between the groups. Pilgrim, *et al.*<sup>[22]</sup> recently showed that in high-risk patients the independent determinants of 5-year mortality were body mass index  $\leq 20$  kg/m<sup>2</sup>, diabetes, peripheral artery disease, atrial fibrillation and pulmonary hypertension, whereas age was not associated. Therefore, these data suggest that the associated co-morbidities may have a larger impact on outcomes by TAVI than age.

A sub-study of the FRANCE-2 registry including 2,254 patients aged > 80 years showed in patients within the age group between 80–84 years old, that the prevalence of diabetes, prior myocardial infarction, prior cardiac surgery, chronic obstructive pulmonary disease and reduced LVEF was significantly higher than in the groups of patients aged 85–89 years and > 90 years.<sup>[9]</sup> In addition, the transapical access, frequently used in patients with increased morbidity and mortality risks, was more frequently used in younger patients (80–84 years old) than in the other two groups (85–89 years and > 90 years) (20.5% vs. 14.7 % and 11.6%, respectively;  $P < 0.001$ ).<sup>[9]</sup> Upon multivariate analysis, female sex, higher logistic EuroSCORE, New York Heart Association functional class III-IV, renal failure and transapical access were independently associated with one-year mortality. However, age was not associated with outcome.

The present study has additional value by showing similar short- and mid-term outcomes of patients treated by TAVI independent of age. Along with previous studies, the present study reinforces the concept of age as no longer a valid parameter to select patients for TAVI. Age is one of the variables included in currently used risk scores (Logistic EuroSCORE I and II and the STS-PROM score).<sup>[10],[23]</sup> However, several studies have demonstrated the modest discrimination and calibration properties of current risk scores,<sup>[24],[25]</sup> and several engines have been proposed to better identify the patients who will benefit from TAVI.<sup>[24],[26]</sup> While the engine derived from the FRANCE-2 registry included the parameter age  $\geq 90$  years,<sup>[26]</sup> the TAVI2-SCORE included a cut-off value of > 85 years.<sup>[24]</sup> The Harrel's C-statistic (measure of discrimination property) for the FRANCE-2 derived score was 0.59,<sup>[26]</sup> while the TAVI2-SCORE had a C-statistic of 0.71.<sup>[24]</sup> The number of patients aged > 85 years in the present study was 27.9%.

In conclusion, the results of the present single center study showed that age is not associated with outcomes after TAVI. The impact of developments in valvular technology and long term experience based on procedural outcomes has not been considered.

## ACKNOWLEDGMENTS

The Department of Cardiology received research grants from Biotronik, Medtronic and Boston Scientific, Germany. Delgado V received speaking fees from Abbott Vascular. Kamperidis V received a European Society of Cardiology training grant, a European Association of Cardiovascular Imaging research grant, a Hellenic Cardiological Society training grant and a Hellenic Foundation of Cardiology research grant.

## REFERENCES

1. Adams DH, Popma JJ, Reardon MJ, et al. Transcatheter aortic-valve replacement with a self-expanding prosthesis. *N Engl J Med*. 2014;370:1790–1798.
2. Kodali SK, Williams MR, Smith CR, et al. Two-year outcomes after transcatheter or surgical aortic-valve replacement. *N Engl J Med*. 2012;366:1686–1695.
3. Makkar RR, Fontana GP, Jilaihawi H, et al. Transcatheter aortic-valve replacement for inoperable severe aortic stenosis. *N Engl J Med*. 2012;366:1696–1704.
4. Lung B, Vahanian A. Epidemiology of acquired valvular heart disease. *Can J Cardiol*. 2014;962–970.
5. Boothroyd LJ, Spaziano M, Guertin JR, et al. Transcatheter aortic valve implantation: recommendations for practice based on a multidisciplinary review including cost-effectiveness and ethical and organizational issues. *Can J Cardiol*. 2013;29:718–726.
6. Havakuk O, Finkelstein A, Steinvil A, et al. Comparison of outcomes in patients  $\leq 85$  versus  $>85$  years of age undergoing transcatheter aortic-valve implantation. *Am J Cardiol*. 2014;113:138–141.
7. Pilgrim T, Kalesan B, Wenaweser P, et al. Predictors of clinical outcomes in patients with severe aortic stenosis undergoing TAVI: a multistate analysis. *Circ Cardiovasc Interv*. 2012;5:856–861.
8. Yamamoto M, Meguro K, Mouillet G, et al. Comparison of effectiveness and safety of transcatheter aortic valve implantation in patients aged  $\geq 90$  years versus  $< 90$  years. *Am J Cardiol*. 2012;110:1156–1163.
9. Yamamoto M, Mouillet G, Meguro K, et al. Clinical results of transcatheter aortic valve implantation in octogenarians and nonagenarians: insights from the FRANCE-2 registry. *Ann Thorac Surg*. 2014;97:29–36.
10. Nashef SA, Roques F, Michel P, et al. European system for cardiac operative risk evaluation (EuroSCORE) *Eur J Cardiothorac Surg*. 1999;16:9–13.
11. Wendt D, Osswald BR, Kayser K, et al. Society of Thoracic Surgeons score is superior to the EuroSCORE determining mortality in high risk patients undergoing isolated aortic valve replacement. *Ann Thorac Surg*. 2009;88:468–474.
12. Leon MB, Piazza N, Nikolsky E, et al. Standardized endpoint definitions for transcatheter aortic valve implantation clinical trials: a consensus report from the valve academic research consortium. *Eur Heart J*. 2011;32:205–217.
13. Baumgartner H, Hung J, Bermejo J, et al. Echocardiographic assessment of valve stenosis: EAE/ASE recommendations for clinical practice. *Eur J Echocardiogr*. 2009;10:1–25.
14. Vahanian A, Alfieri O, Andreotti F, et al. Guidelines on the management of valvular heart disease (version 2012) *Eur Heart J*. 2012;33:2451–2496.
15. Lang RM, Bierig M, Devereux RB, et al. Recommendations for chamber quantification. *Eur J Echocardiogr*. 2006;7:79–108.
16. Kappetein AP, Head SJ, Genereux P, et al. Updated standardized endpoint definitions for transcatheter aortic valve implantation: the Valve Academic Research Consortium-2 consensus document (VARC-2) *Eur J Cardiothorac Surg*. 2012;42:S45–S60.
17. Leon MB, Smith CR, Mack M, et al. Transcatheter aortic-valve implantation for aortic stenosis in patients who

- cannot undergo surgery. *N Engl J Med.* 2010;363:1597–1607.
18. Smith CR, Leon MB, Mack MJ, et al. Transcatheter versus surgical aortic-valve replacement in high-risk patients. *N Engl J Med.* 2011;364:2187–2198.
  19. Mario C, Eltchaninoff H, Moat N, et al. The 2011–2012 pilot European Sentinel Registry of Transcatheter Aortic Valve Implantation: in-hospital results in 4,571 patients. *EuroIntervention.* 2013;8:1362–1371.
  20. Gilard M, Eltchaninoff H, Iung B, et al. Registry of transcatheter aortic-valve implantation in high-risk patients. *N Engl J Med.* 2012;366:1705–1715.
  21. Mack MJ, Brennan JM, Brindis R, et al. Outcomes following transcatheter aortic valve replacement in the United States. *JAMA.* 2013;310:2069–2077.
  22. Pilgrim T, Englberger L, Rothenbuhler M, et al. Long-term outcome of elderly patients with severe aortic stenosis as a function of treatment modality. *Heart.* 2015;101:30–36.
  23. Edwards FH, Clark RE, Schwartz M. Coronary artery bypass grafting: the Society of Thoracic Surgeons National Database experience. *Ann Thorac Surg.* 1994;57:12–19.
  24. Debonnaire P, Fusini L, Wolterbeek R, et al. Value of the “TAVI2-SCORE” versus surgical risk scores for prediction of one year mortality in 511 patients who underwent transcatheter aortic valve implantation. *Am J Cardiol.* 2015;115:234–242.
  25. Sedaghat A, Sinning JM, Vasa-Nicotera M, et al. The revised EuroSCORE II for the prediction of mortality in patients undergoing transcatheter aortic valve implantation. *Clin Res Cardiol.* 2013;102:821–829.
  26. Iung B, Laouenan C, Himbert D, et al. Predictive factors of early mortality after transcatheter aortic valve implantation: individual risk assessment using a simple score. *Heart.* 2014;100:1016–1023.



# Chapter 3

---

## Timing of Staged Percutaneous Coronary Intervention Before Transcatheter Aortic Valve Implantation

Philippe J. van Rosendael MD, Frank van der Kley MD, Vasileios Kamperidis MD, PhD, Spyridon Katsanos MD, PhD, Ibtihal Al Amri MD, Madelien Regeer MD, Martin J. Schalij MD, PhD, Nina Ajmone Marsan MD, PhD, Jeroen J. Bax MD, PhD, Victoria Delgado MD, PhD

Am J Cardiol 2015;115:1726e1732



## ABSTRACT

Significant coronary artery disease is highly prevalent in patients who underwent transcatheter aortic valve implantation (TAVI). Timing of staged percutaneous coronary intervention (PCI) in TAVI candidates remains debated. The present study assessed the impact of timing of the staged PCI on TAVI outcomes. Ninety-six patients (age  $81 \pm 5$  years, 57% men) who had undergone staged PCI within 1 year before TAVI were included. The population was dichotomized according to the median time elapsed between PCI and TAVI (<30 and  $\geq 30$  days). In-hospital events and 30-day outcomes after TAVI were defined according to Valve Academic Research Consortium-2 definitions. Forty-eight patients underwent PCI <30 days and 48 patients underwent PCI  $\geq 30$  days before TAVI. Patients treated with PCI <30 days had lower hemoglobin levels at baseline ( $7.2 \pm 0.9$  mmol/L vs  $7.9 \pm 0.9$  mmol/L,  $p = 0.002$ ), more frequently atrial fibrillation (27% vs 13%,  $p = 0.018$ ), and a shorter time interval between computed tomography acquisition and TAVI (7 days [2 to 10] vs 22 days [6 to 39],  $p < 0.001$ ) than their counterparts. Minor bleedings (13% vs 0%,  $p = 0.011$ ) and overall vascular injury (27% vs 8%,  $p = 0.016$  [minor injury: 17% vs 2%,  $p = 0.014$ ; major injury: 10% vs 6%,  $p = 0.460$ ]) were more frequently recorded in patients with staged PCI <30 days before TAVI. There were no differences in the incidence of other events and in 2-year survival. In conclusion, shortly (<30 days) or remote ( $\geq 30$  days) staged PCI before TAVI resulted in comparable outcomes with the exception of minor vascular injury and minor bleeding events which were more frequently observed in patients treated with shortly staged PCI.

Severe aortic stenosis is frequently associated with significant coronary artery disease (CAD).<sup>1, 2, 3, 4, 5, 6</sup> In patients who underwent transcatheter aortic valve implantation (TAVI), the reported prevalence of significant CAD ranges from 41% to 75%.<sup>2, 3, 4, 7, 8</sup> The impact of significant CAD on the outcome of TAVI remains uncertain. The randomized Placement of Aortic Transcatheter Valves trial excluded patients with significant CAD who required revascularization.<sup>2, 8</sup> However, accumulating evidence shows that severe CAD is associated with adverse clinical outcome after TAVI,<sup>3</sup> and consequently, current recommendations advocate for percutaneous coronary intervention (PCI) in patients with severe, proximal coronary artery lesions with a large area of myocardium at risk.<sup>2, 3, 4, 5, 6, 9</sup> However, the performance of a staged PCI before TAVI is inevitably associated with an additional vascular puncture, repeated injection of contrast material, and dual antiplatelet therapy that may increase the rates of complications after TAVI.<sup>2, 10, 11</sup> Timing of staged PCI (short- or long-term before TAVI) may, therefore, affect the TAVI outcome. However, there is currently no consensus on the optimal timing of staged PCI before TAVI.<sup>2, 6</sup> The present study compared the outcomes of patients who underwent staged PCI shortly (short term) or remotely (long term) before TAVI.

## METHODS

From a cohort of 308 patients treated with TAVI for severe aortic stenosis or a failing aortic bioprosthesis at the Leiden University Medical Center, 96 patients who had undergone staged PCI within 1 year before the TAVI were evaluated. Patients were treated with TAVI as they were considered to have contraindications or to be at increased risk for surgical aortic valve replacement. Before TAVI, all patients underwent a comprehensive clinical and multitechnique imaging evaluation, including coronary angiography.<sup>12</sup> Aortic valve area was calculated by the continuity equation and the aortic valve pressure gradients by the Bernoulli equation on transthoracic echocardiography.<sup>13</sup> Aortic annulus dimensions and iliofemoral arterial system anatomy were assessed with multidetector row computed tomography (MDCT) as previously described.<sup>12</sup> In patients without previous coronary artery bypass surgery, baseline coronary angiograms were reviewed to assess the extent and complexity of significant CAD using the SYNTAX score.<sup>14</sup> In addition, in patients in whom PCI was performed, the type of targeted lesion was classified as previously described.<sup>15</sup> Data were prospectively collected in the departmental electronic clinical files (EPD Vision, version 11.2.9.0; EPD Vision, Leiden, The Netherlands) and retrospectively analyzed. Periprocedural complications and 30-day outcomes were defined according to the Valve Academic Research Consortium-2 (VARC-2).<sup>16</sup> The institutional review board approved the study and waived the need of patient written informed consent for this retrospective analysis of clinically acquired data.

MDCT scans were performed with a 64-row computed tomography scanner (Aquilion 64; Toshiba Medical Systems, Otawara, Japan) or with a 320-detector row computed tomography scanner (AquilionOne; Toshiba Medical Systems, Tochigi-ken, Japan) using protocols that have been previously described.<sup>12</sup> Adjusted to the patient's body weight, 80 to 100 ml of nonionic contrast material (Ultravist 370; Bayer, Whippany, New Jersey) were administered intravenously if the 64-row system was used (flow rate of 5.0 ml/s), and 60 to 100 ml of contrast material were infused in 3 phases if the 320-detector row system was used: first 60 to 80 ml of contrast material (flow rate 5.0 to 6.0 ml/s), followed by a 1:1 mixture of contrast and saline and additional 25 ml of saline (flow rate 3.0 ml/s). Median time elapsed between computed tomography acquisition and TAVI was 10 days (interquartile range 3 to 24). Patients with chronic kidney disease (defined as an estimated glomerular filtration rate  $<60$  ml/min/1.73 m<sup>2</sup>) received intravenous hydration (isotonic saline 0.9%) before the scan.

Significant CAD was defined on invasive coronary angiography as  $\geq 70\%$  diameter stenosis of an epicardial coronary artery of  $>1.5$  mm. The decision to perform PCI was

based on the presence of symptoms, extent of the viable myocardial tissue at risk, infarcted area, and CAD complexity as assessed with the SYNTAX score.<sup>14</sup> The extent of myocardial tissue at risk was visually estimated by evaluating the myocardial territories being supplied by coronary arteries with significant stenosis. Timing of staged PCI was based on patient's clinical status and logistical convenience. Staged PCI was performed at a median of 29 days (interquartile range 9 to 81) before TAVI. However, there were no patients treated exactly 29 days before the TAVI, and for simplicity, the groups were divided into patients who underwent PCI <30 days (shortly) before TAVI and ≥30 days (remotely). PCI was preferably performed through the femoral artery using standard techniques. Patients with chronic kidney disease received intravenous hydration (isotonic saline 0.9%) before and after the procedure. Antithrombotic therapy included periprocedural intravenous heparin (5,000 IU) and loading doses of 600 mg of clopidogrel and 300 mg aspirin continued by daily doses of 75 and 100 mg, respectively. Aspirin was prescribed life long, whereas clopidogrel was prescribed for 3 months if a bare-metal stent was implanted and for at least 1 year if a drug-eluting stent was used. If concomitant oral anticoagulants were used, aspirin was not prescribed.

TAVI procedures were performed under general anesthesia and were guided by fluoroscopy and transesophageal echocardiography. During the procedure, intravenous unfractionated heparin was administered to maintain an activated clotting time of >300 ms. The balloon-expandable Edwards SAPIEN valve (23, 26, and 29 mm; Edwards Lifesciences, Irvine, California) was implanted using a transfemoral or transapical approach, whereas the self-expandable Medtronic CoreValve System (23, 26, 29, and 31 mm; Medtronic, Minneapolis, Minnesota) was implanted through a transfemoral access. Aortic valve balloon dilation was performed during rapid right ventricular pacing, and subsequently, deployment of a balloon- or self-expandable prosthesis was performed as previously described.<sup>12</sup> Iomeron 350 (Bracco Imaging Deutschland GmbH, Konstanz, Germany) was used as contrast medium. Patients with chronic kidney disease received intravenous hydration (isotonic saline 0.9%) before and after the procedure. Vascular access was closed using surgical sutures. After TAVI, clopidogrel was indicated for 1 month.

All in-hospital events and 30-day outcomes were defined according to the VARC-2 criteria.<sup>16</sup> In addition, the VARC-2 composite end point of early safety (at 30 days), including all-cause mortality, stroke, life-threatening bleeding, stages 2 or 3 of acute kidney injury, coronary artery obstruction requiring intervention, major vascular complication, and valve-related dysfunction requiring a repeat procedure, was recorded.<sup>16</sup> Outpatient visits were scheduled at 1, 3, 6, and 12 months after discharge and thereafter on discretion of the treating physician. Survival status was obtained by review of the medical files and the Dutch Civil Registry.

Continuous variables are expressed as mean  $\pm$  SD or as median and interquartile range. Categorical variables are displayed as frequencies and percentages. Based on the median number of days that the staged PCI was performed before TAVI, the population was divided into 2 groups ( $<30$  or  $\geq 30$  days). Differences between patients who had undergone staged PCI within 30 days before TAVI and patients who had undergone staged PCI remotely ( $\geq 30$  days) before TAVI were analyzed using the unpaired Student *t* test or the Mann-Whitney *U* test for continuous data and with the chi-square test for categorical data. Survival rates were evaluated with Kaplan-Meier analysis and compared between the 2 groups using the log-rank test. Statistical analyses were 2 sided, and *p* values  $<0.05$  were considered significant. All statistical analyses were performed with SPSS software (version 20.0; SPSS Inc., Chicago, Illinois).

## RESULTS

Baseline clinical and echocardiographic characteristics of the patient population (mean age  $81 \pm 5$  years, 57% men) are summarized in [Table 1](#). Mean logistic EuroSCORE was  $23.2 \pm 13.9$ . Baseline characteristics were comparable between the 2 groups of patients (PCI shortly and remote before TAVI; [Table 1](#)). Patients treated with PCI within the time range of 30 days before TAVI (shortly before TAVI) had a lower level of hemoglobin before PCI ( $7.7 \pm 1.1$  mmol/L vs  $8.2 \pm 0.9$ , *p* = 0.012) and before TAVI ( $7.2 \pm 0.9$  mmol/L vs  $7.9 \pm 0.9$  mmol/L, *p* = 0.002) and showed more frequently atrial fibrillation (27% vs 13%, *p* = 0.018) than those revascularized with a remote staged PCI ( $\geq 30$  days). The time interval from MDCT to TAVI was significantly shorter in the patients treated with staged PCI shortly before TAVI than in patients treated remotely (7 days [2 to 10] vs 22 days [6 to 39], *p*  $<0.001$ ).

Procedural characteristics of PCI and TAVI are displayed in [Table 2](#). Extent and complexity of the CAD as assessed by the SYNTAX score and the complexity of the targeted lesions were comparable between groups ([Table 2](#)). Patients in whom staged PCI was performed  $<30$  days before TAVI were treated with a higher number of stents than those in whom staged PCI was performed  $\geq 30$  days before TAVI ( $2.3 \pm 1.6$  vs  $1.5 \pm 1.2$ , *p* = 0.011). The preferred access was femoral, and in both groups, the radial or brachial access was used in only 5 patients (10%). In addition, the frequency of implanting a drug-eluting stent instead of a bare-metal stent and the amount of used contrast during staged PCI did not differ between groups. During TAVI, there were no differences in terms of procedural access or size of implanted prosthesis ([Table 2](#)).

**Table 1.**

Baseline and echocardiographic characteristics before transcatheter aortic valve implantation

Variable	Overall population (n = 96)	Staged percutaneous coronary intervention performed		p-value
		≥30 days (n = 48)	<30 days (n = 48)	
Age (years)	81 ± 5.4	81 ± 5.4	82 ± 5.4	0.808
Male sex	55 (57%)	31 (65%)	24 (50%)	0.149
Body surface area (m <sup>2</sup> )	1.85 ± 0.20	1.88 ± 0.21	1.82 ± 0.18	0.117
Heart rhythm				0.018
Sinus rhythm	68 (71%)	34 (71%)	34 (71%)	
Atrial fibrillation	19 (20%)	6 (13%)	13 (27%)	
Pacemaker	9 (9%)	8 (17%)	1 (2%)	
Hypertension	74 (77%)	36 (75%)	38 (79%)	0.627
Diabetes mellitus	30 (31%)	14 (29%)	16 (33%)	0.660
Hypercholesterolaemia	70 (73%)	35 (73%)	35 (73%)	1
Smoking	37 (39%)	16 (33%)	21 (44%)	0.294
Previous myocardial infarction	26 (27%)	14 (29%)	12 (25%)	0.646
Previous coronary artery bypass grafting	29 (30%)	15 (31%)	14 (29%)	0.824
Preoperative creatinine level (µmol/L)	98 ± 41	98 ± 41	98 ± 41	0.943
Estimated glomerular filtration rate (ml/min/1.73m <sup>2</sup> )	69 ± 26	71 ± 26	67 ± 25	0.432
Hemoglobin (mmol/L)	7.5 ± 1.0	7.9 ± 0.9	7.2 ± 0.9	0.002
Logistic EuroSCORE (%)	23.2 ± 13.9	24.0 ± 16	22.6 ± 11.6	0.619
Time elapsed between multi-detector row computed tomography and transcatheter aortic valve implantation (days)	10 [3-24]	22 [6-39]	7 [2-10]	<0.001
<b>Echocardiography</b>				
Left ventricular ejection fraction, %	54 ± 13	53 ± 14	56 ± 13	0.235
Aortic valve area, cm <sup>2</sup> /m <sup>2</sup>	0.74 ± 0.21	0.75 ± 0.21	0.73 ± 0.21	0.655
Mean aortic gradient, mmHg	40 ± 16	37 ± 13	43 ± 18	0.065
Maximal aortic gradient, mmHg	66 ± 25	60 ± 20	71 ± 29	0.037
<b>Medication</b>				
β-blockers	73 (76%)	37 (77%)	36 (75%)	0.811
Angiotensin converting enzyme inhibitors / Angiotensin receptor blockers	58 (60%)	31 (65%)	27 (56%)	0.404
Diuretics	62 (64%)	30 (63%)	32 (67%)	0.670
Calcium channel blocker	31 (32%)	15 (31%)	16 (33%)	0.827
Statins	82 (85%)	41 (85%)	41 (85%)	1
Aspirin	58 (60%)	27 (56%)	31 (65%)	0.404
Clopidogrel	94 (98%)	46 (96%)	48 (100%)	0.153
Oral anticoagulants	35 (36%)	18 (38%)	17 (35%)	0.832

Hypertension = history of high blood pressure and/or on antihypertensive treatment; Hypercholesterolaemia = history of hypercholesterolaemia and/or on statin therapy.

**Table 2.**

Procedural characteristics

Variable	Overall population (n = 96)	Staged percutaneous coronary intervention performed		p-value
		≥30 days (n = 48)	<30 days (n = 48)	
<b>Staged percutaneous coronary intervention</b>				
Stable coronary artery disease	93 (97%)	45 (94%)	48 (100%)	0.078
Acute coronary syndrome	3 (3%)	3 (6%)	0 (0%)	0.078
Syntax score	14 ± 10	12 ± 10	16 ± 9	0.079
Syntax score 0-22	55 (82%)	28 (85%)	27 (79%)	
Syntax score 23-32	10 (15%)	4 (12%)	6 (18%)	
Syntax score ≥33	2 (3%)	1 (3%)	1 (3%)	
Type B2 or C targeted lesion	59 (61%)	26 (54%)	33 (69%)	0.142
Number of stents used per patient	1.9 ± 1.4	1.5 ± 1.2	2.3 ± 1.6	0.011
Stent in left main	12 (13%)	5 (10%)	7 (15%)	0.537
Stent in left anterior descending	41 (43%)	17 (35%)	24 (50%)	0.149
Stent in left circumflex	27 (28%)	14 (29%)	13 (27%)	0.820
Stent in right coronary artery	33 (34%)	12 (25%)	21 (44%)	0.053
Stent in graft	6 (6%)	4 (8.3)	2 (4%)	0.399
Drug-eluting stent	42 (44%)	23 (48%)	19 (40%)	0.411
Amount of contrast media (ml)	191 ± 99	200 ± 109	183 ± 88	0.421
Use of closure device	24 (26%)	8 (18%)	16 (33%)	0.098
<b>Transcatheter aortic valve implantation</b>				
Transapical approach	54 (56%)	27 (56%)	27 (56%)	1
Prosthesis size				0.457
Edwards SAPIEN, 23 mm	18 (19%)	7 (15%)	11 (23%)	
Edwards SAPIEN, 26 mm	61 (64%)	29 (60%)	32 (67%)	
Edwards SAPIEN, 29 mm	5 (5%)	4 (8%)	1 (2%)	
Medtronic CoreValve, 26 mm	3 (3%)	2 (4%)	1 (2%)	
Medtronic CoreValve, 29 mm	8 (8%)	5 (10%)	3 (6%)	
Medtronic CoreValve, 31 mm	1 (1%)	1 (2%)	0 (0%)	
Amount of contrast media (ml)	106 ± 62	99 ± 40	114 ± 79	0.272

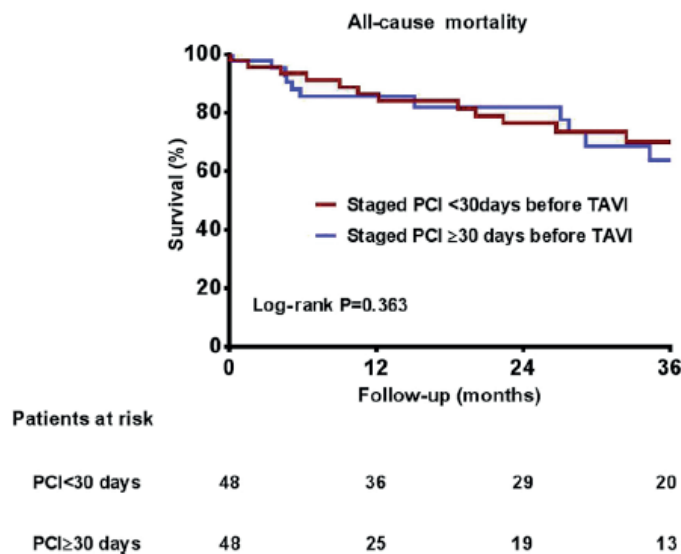


In-hospital events and 30-day outcomes of the study population are summarized in [Table 3](#). Patients revascularized with staged PCI <30 days before TAVI had more frequently vascular injury as postprocedural complication than their counterparts treated with staged PCI ≥30 days (27% vs 8%,  $p = 0.016$ ). This was mainly because of a higher frequency of minor vascular injury (17% vs 2%,  $p = 0.014$ ) rather than major vascular injury (10% vs 6%,  $p = 0.460$ ) ([Table 3](#)). In addition, the patients treated with staged PCI <30 days before TAVI more frequently had minor bleedings than their counterparts (13% vs 0%,  $p = 0.011$ ). Other in-hospital events and 30-day outcomes did not differ between the 2 groups ([Table 3](#)). During a median follow-up of 2.0 years (0.6 to 3.5), survival rates were comparable between the 2 groups ( $p = 0.363$ ; [Figure 1](#)). The 2-year survival rate of patients who underwent staged PCI <30 days before TAVI was 75% and for patients treated earlier within the year 77%.

**Table 3.**  
In-hospital events and 30-day outcomes

Variable	Overall population (n = 96)	Staged percutaneous coronary intervention performed		p-value
		≥30 days (n = 48)	<30 days (n = 48)	
Acute kidney injury	16 (18%)	8 (19%)	8 (18%)	0.959
In-hospital death	6 (6%)	4 (8%)	2 (4%)	0.339
Vascular injury	17 (18%)	4 (8%)	13 (27%)	0.016
Major	8 (8%)	3 (6%)	5 (10%)	0.460
Minor	9 (9%)	1 (2%)	8 (17%)	0.014
Bleeding	14 (15%)	4 (8%)	10 (21%)	0.083
Major	8 (8%)	4 (8%)	4 (8%)	1
Minor	6 (6%)	0 (0%)	6 (13%)	0.011
Stroke	2 (2%)	1 (2%)	1 (2%)	1
Atrioventricular-block	9 (9%)	7 (15%)	2 (4%)	0.08
Composite safety endpoint	15 (16%)	9 (19%)	6 (13%)	0.399

**Figure 1.** Kaplan-Meier curves of survival after staged PCI within 30 days before TAVI versus staged PCI earlier in the year before TAVI.



## DISCUSSION

The main finding of present study is that shortly (<30 days) or remote ( $\geq 30$  days) staged PCI before TAVI result in comparable TAVI outcomes with the exception of overall vascular injury (particularly minor injuries) and minor bleeding events that were more frequently observed in patients treated with staged PCI performed <30 days before TAVI.

Significant CAD is relatively frequent in patients with severe aortic stenosis who underwent TAVI (41% to 75%).<sup>2, 3, 4, 7, 8</sup> The influence of significant CAD on the outcomes of patients who underwent TAVI has been evaluated in several registries providing conflicting results.<sup>2, 5, 17, 18, 19, 20, 21, 22, 23</sup> The initial results reported by Dewey et al<sup>17</sup> showing an increased risk of 30-day mortality and overall mortality among patients with CAD compared with patients without CAD were not confirmed by larger series such as the Italian CoreValve registry or the Edwards SAPIEN Aortic Bioprosthesis European Outcome (SOURCE) registry that showed similar outcomes in patients with and without CAD.<sup>20, 22</sup> These discrepancies may be related to differences in patient populations, definition of CAD, and presence of PCI before TAVI.

Compared with patients without CAD, patients with CAD have frequently a higher risk profile at baseline with higher operative risks, more frequently diabetes, hypercholesterolemia, poor left ventricular ejection fraction, and peripheral vascular disease.<sup>3</sup> In addition, within the group of patients with CAD, the severity of the coronary lesions and the area of myocardium at risk may differ significantly and may define a subgroup of patients with higher procedural risks. Most series defined significant CAD as having previous PCI, previous coronary artery bypass grafting, myocardial infarction, or  $\geq 70\%$  stenosis severity of major epicardial coronary artery ( $\geq 50\%$  if left main).<sup>17, 20, 23</sup> However, it may be more clinically meaningful to define the severity of CAD based on physiological scores that take into account the area of myocardium at risk or define the extent and complexity of CAD.<sup>3, 18</sup> Using the SYNTAX score, Stefanini et al<sup>3</sup> divided a group of severe aortic stenosis patients with CAD who underwent TAVI into low (0 to 22) and high (>22) SYNTAX score and showed that patients with high SYNTAX score had worse prognosis at 1-year follow-up compared with patients with low score.<sup>3</sup>

Furthermore, in earlier studies, 11% to 23% of patients who underwent TAVI were previously treated with PCI.<sup>2, 18, 21, 23</sup> This may also affect the short- and long-term outcomes of patients. Revascularization before TAVI may be protective, reducing the ischemia burden during valve ballooning and prosthesis deployment. Goel et al<sup>24</sup>

showed that PCI before TAVI was safe in most patients with severe aortic stenosis. However, patients with severe aortic stenosis and reduced left ventricular ejection fraction ( $\leq 30\%$ ) or high Society of Thoracic Surgeons score ( $\geq 10\%$ ) had a significantly increased risk of all-cause mortality 30 days after PCI. Furthermore, in the series reported by Stefanini et al,<sup>3</sup> almost 50% of patients with significant CAD underwent PCI before TAVI and those patients with incomplete revascularization, as defined by a higher residual SYNTAX score, had higher rates of the primary combined end point (cardiovascular death, stroke or myocardial infarction) at 1 year than patients with low residual SYNTAX score (26.3% vs 16.5%;  $p = 0.043$ ). In contrast, van Mieghem et al<sup>4</sup> showed that revascularization status (complete vs incomplete) did not have prognostic implications.

These findings underscore the importance of several factors that need to be weighted when considering PCI before TAVI: clinical characteristics and associated co-morbidities of patients, severity of CAD, and possibility of performing complete or incomplete revascularization are associated with short- and long-term outcomes of PCI and TAVI. However, little is known about timing of PCI in relation to TAVI. Staged PCI before TAVI and combined PCI and TAVI are the most frequent strategies used.<sup>2, 5</sup> In selected patients, staged PCI is feasible and safe<sup>9, 10, 21, 24</sup> and may be associated with less risk of ischemia or hemodynamic instability during TAVI and less risk of contrast nephropathy because the contrast volume used is less and divided into 2 different time points.<sup>2</sup> However, patients who underwent staged PCI before TAVI are loaded with dual antiplatelet treatment that may increase the risk of bleeding complications after TAVI.<sup>2</sup> In contrast, combined PCI and TAVI may be preferred in some patients because both procedures share the same arterial access reducing the risks of vascular injury and bleedings.<sup>2</sup> Few series have compared staged PCI with combined PCI and TAVI.<sup>21, 25, 26</sup> Conradi et al<sup>25</sup> compared the short-term outcomes of 21 patients who underwent staged PCI before TAVI ( $14.3 \pm 9.6$  days) with 7 patients who underwent combined PCI and TAVI. Patients who underwent PCI combined with TAVI received a higher amount of contrast volume compared with those who underwent staged PCI ( $292.3 \pm 117.5$  vs  $171.9 \pm 68.4$  ml,  $p = 0.006$ ).<sup>25</sup> In addition, 2 patients of the combined PCI and TAVI group presented with acute kidney injury after the procedure.<sup>25</sup> In contrast, in the group of patients treated with staged PCI, 1 patient had a nonsevere bleeding complication. Wenaweser et al<sup>21</sup> compared the outcomes of 167 patients with severe aortic stenosis and known CAD who underwent isolated TAVI with 36 and 23 patients who were treated with staged and combined PCI, respectively. There were no differences in terms of 30-day all-cause mortality (5.6% vs 11.1% and 8.7%, respectively;  $p = 0.43$ ) or the VARC-combined safety end point (31.0% vs 22.2% and 26.1%, respectively;  $p = 0.54$ ).



The mean time elapsed between PCI and TAVI in the group of patients who underwent PCI was 34 days.<sup>21</sup> The present study provides additional insights into the field comparing staged PCI performed >30 or ≤30 days before TAVI and showing that both strategies are safe and provide similar short-term outcomes. However, PCI performed within 30 days before TAVI was associated more frequently with minor vascular injuries and bleeding, which may be associated with loading doses of dual antiplatelet treatment. This may also explain the relatively lower hemoglobin levels of patients who underwent PCI within 30 days before TAVI than their counterparts. In this regard, the results of the ongoing Percutaneous Coronary Intervention Prior to Transcatheter Aortic Valve Implantation (ACTIVATION) trial<sup>22</sup> will shed light into the optimal revascularization strategy before TAVI, whereas the ongoing Aspirin Versus Aspirin+Clopidogrel Following Transcatheter Aortic Valve Implantation (ARTE) trial<sup>28</sup> will show the most appropriate antiplatelet treatment (aspirin vs aspirin and clopidogrel) in patients without indications for anticoagulation. In addition, future studies are needed to determine whether vascular complications after TAVI could be reduced using a radial instead of femoral access for the staged PCI.

Several limitations should be acknowledged. The present study concerns a single-center and retrospective analysis. The number of patients who underwent a staged PCI before TAVI is limited, which precluded performing multivariate analysis or propensity score matching study. In addition, timing of the staged PCI was based on patient's clinical condition and logistical issues that might have resulted in selection bias. Larger studies comparing the outcomes of patients with severe aortic stenosis and CAD randomized to isolated TAVI or to revascularization, and TAVI (staged or combined PCI) will provide more evidence to derive robust recommendations. In addition, within the group of patients who underwent revascularization, randomization between staged and combined PCI will help to select the best timing of revascularization.

## Acknowledgment

Drs. van Rosendaal, van der Kley, Kamperidis, Katsanos, and Delgado contributed to conception and design of the study; collection, analysis, and interpretation of data; drafting of the manuscript; and final approval of the manuscript. Drs. Al Amri, Regeer, Schalijs, Ajmone Marsan, and Bax contributed to conception and design of the study; revising of the manuscript; and final approval of the manuscript.

## Disclosures

The Department of Cardiology received research grants from Biotronik, Medtronic, and Boston Scientific. Dr. Kamperidis received a European Society of Cardiology

training grant, a European Association of Cardiovascular Imaging research grant, a Hellenic Cardiological Society training grant, and a Hellenic Foundation of Cardiology research grant. Dr. Delgado received speaking fees from Abbott Vascular. The other authors have no conflicts of interest to declare.

## REFERENCES

1. B.A. Carabello, W.J. Paulus. Aortic stenosis. *Lancet*, 373 (2009), pp. 956-966
2. S.S. Goel, M. Ige, E.M. Tuzcu, S.G. Ellis, W.J. Stewart, L.G. Svensson, B.W. Lytle, S.R. Kapadia. Severe aortic stenosis and coronary artery disease—implications for management in the transcatheter aortic valve replacement era: a comprehensive review. *J Am Coll Cardiol*, 62 (2013), pp. 1-10
3. G.G. Stefanini, S. Stortecky, D. Cao, J. Rat-Wirtzler, C.J. O'Sullivan, S. Gloekler, L. Buellesfeld, A.A. Khattab, F. Nietlispach, T. Pilgrim, C. Huber, T. Carrel, B. Meier, P. Juni, P. Wenaweser, S. Windecker. Coronary artery disease severity and aortic stenosis: clinical outcomes according to SYNTAX score in patients undergoing transcatheter aortic valve implantation. *Eur Heart J*, 35 (2014), pp. 2530-2540
4. N.M. van Mieghem, R.M. van der Boon, E. Faqiri, R. Diletti, C. Schultz, R.J. van Geuns, P.W. Serruys, A.P. Kappetein, R.T. van Domburg, P.P. de Jaegere. Complete revascularization is not a prerequisite for success in current transcatheter aortic valve implantation practice. *JACC Cardiovasc Interv*, 6 (2013), pp. 867-875
5. J.M. Paradis, J. Fried, T. Nazif, A. Kirtane, K. Harjai, O. Khalique, K. Grubb, I. George, R. Hahn, M. Williams, M.B. Leon, S. Kodali. Aortic stenosis and coronary artery disease: what do we know? what don't we know? A comprehensive review of the literature with proposed treatment algorithms. *Eur Heart J*, 35 (2014), pp. 2069-2082
6. G.G. Stefanini, S. Stortecky, P. Wenaweser, S. Windecker. Coronary artery disease in patients undergoing TAVI: why, what, when and how to treat. *EuroIntervention*, 10 (suppl U) (2014), pp. U69-U75
7. H. Eltchaninoff, A. Prat, M. Gilard, A. Leguerrier, D. Blanchard, G. Fournial, B. Iung, P. Donzeau-Gouge, C. Tribouilloy, J.L. Debrux, A. Pavie, P. Gueret. Transcatheter aortic valve implantation: early results of the FRANCE (FRench Aortic National CoreValve and Edwards) registry. *Eur Heart J*, 32 (2011), pp. 191-197
8. C.R. Smith, M.B. Leon, M.J. Mack, D.C. Miller, J.W. Moses, L.G. Svensson, E.M. Tuzcu, J.G. Webb, G.P. Fontana, R.R. Makkar, M. Williams, T. Dewey, S. Kapadia, V. Babaliaros, V.H. Thourani, P. Corso, A.D. Pichard, J.E. Bavaria, H.C. Herrmann, J.J. Akin, W.N. Anderson, D. Wang, S.J. Pocock. Transcatheter versus surgical aortic-valve replacement in high-risk patients. *N Engl J Med*, 364 (2011), pp. 2187-2998
9. S. Windecker, P. Kolh, F. Alfonso, J.P. Collet, J. Cremer, V. Falk, G. Filippatos, C. Hamm, S.J. Head, P. Jüni, A.P. Kappetein, A. Kastrati, J. Knuuti, U. Landmesser, G. Laufer, F.J. Neumann, D.J. Richter, P. Schauerte, M. Sousa, G.G. Stefanini, D.P. Taggart, L. Torracca, M. Valgimigli, W. Wijns, A. Witkowski. 2014 ESC/EACTS Guidelines on myocardial revascularization: the Task Force on myocardial revascularization of the European Society of Cardiology (ESC) and the European Association for Cardio-Thoracic Surgery (EACTS) developed with the special contribution of the European Association of Percutaneous Cardiovascular Interventions (EAPCI). *Eur Heart J*, 35 (2014), pp. 2541-2619
10. Abdel-Wahab M, Mostafa AE, Geist V, Stocker B, Gordian K, Merten C, Richardt D, Toelg R, Richardt G.

- Comparison of outcomes in patients having isolated transcatheter aortic valve implantation versus combined with preprocedural percutaneous coronary intervention. *Am J Cardiol* 2012;109:581e586.
11. Y. Abramowitz, S. Banai, G. Katz, A. Steinvil, Y. Arbel, O. Havakuk, A. Halkin, Y. Ben-Gal, G. Keren, A. Finkelstein. Comparison of early and late outcomes of TAVI alone compared to TAVI plus PCI in aortic stenosis patients with and without coronary artery disease. *Catheter Cardiovasc Interv*, 83 (2014), pp. 649-654
  12. V. Delgado, A.C. Ng, N.R. van de Veire, F. Van der Kley, J.D. Schuijf, L.F. Tops, A. de Weger, G. Tavilla, A. de Roos, L.J. Kroft, M.J. Schalij, J.J. Bax. Transcatheter aortic valve implantation: role of multi-detector row computed tomography to evaluate prosthesis positioning and deployment in relation to valve function. *Eur Heart J*, 31 (2010), pp. 1114-1123
  13. J.L. Zamorano, L.P. Badano, C. Bruce, K.L. Chan, A. Goncalves, R.T. Hahn, M.G. Keane, G. La Canna, M.J. Monaghan, P. Nihoyannopoulos, F.E. Silvestry, J.L. Vanoverschelde, L.D. Gillam. EAE/ASE recommendations for the use of echocardiography in new transcatheter interventions for valvular heart disease. *Eur Heart J*, 32 (2011), pp. 2189-2214
  14. P.W. Serruys, M.C. Morice, A.P. Kappetein, A. Colombo, D.R. Holmes, M.J. Mack, E. Stahle, T.E. Feldman, M. van den Brand, E.J. Bass, N. Van Dyck, K. Leadley, K.D. Dawkins, F.W. Mohr. Percutaneous coronary intervention versus coronary-artery bypass grafting for severe coronary artery disease. *N Engl J Med*, 360 (2009), pp. 961-972
  15. S.G. Ellis, M.G. Vandormael, M.J. Cowley, G. DiSciascio, U. Deligonul, E.J. Topol, T.M. Bulle. Coronary morphologic and clinical determinants of procedural outcome with angioplasty for multivessel coronary disease. Implications for patient selection. Multivessel Angioplasty Prognosis Study Group. *Circulation*, 82 (1990), pp. 1193-1202
  16. A.P. Kappetein, S.J. Head, P. Genereux, N. Piazza, N.M. van Mieghem, E.H. Blackstone, T.G. Brott, D.J. Cohen, D.E. Cutlip, G.A. van Es, R.T. Hahn, A.J. Kirtane, M.W. Krucoff, S. Kodali, M.J. Mack, R. Mehran, J. Rodes-Cabau, P. Vranckx, J.G. Webb, S. Windecker, P.W. Serruys, M.B. Leon. Updated standardized endpoint definitions for transcatheter aortic valve implantation: the Valve Academic Research Consortium-2 consensus document. *J Am Coll Cardiol*, 60 (2012), pp. 1438-1454
  17. T.M. Dewey, D.L. Brown, M.A. Herbert, D. Culica, C.R. Smith, M.B. Leon, L.G. Svensson, M. Tuzcu, J.G. Webb, A. Cribier, M.J. Mack. Effect of concomitant coronary artery disease on procedural and late outcomes of transcatheter aortic valve implantation. *Ann Thorac Surg*, 89 (2010), pp. 758-767
  18. J.B. Masson, M. Lee, R.H. Boone, A. A. Ali, S. Al Bugami, J. Hamburger, G.B. John Mancini, J. Ye, A. Cheung, K.H. Humphries, D. Wood, F. Nietlispach, J.G. Webb. Impact of coronary artery disease on outcomes after transcatheter aortic valve implantation. *Catheter Cardiovasc Interv*, 76 (2010), pp. 165-173
  19. G.G. Stefanini, S. Stortecky, B. Meier, S. Windecker, P. Wenaweser. Severe aortic stenosis and coronary artery disease. *EuroIntervention*, 9 (Suppl) (2013), pp. S63-S68

20. G.P. Ussia, M. Barbanti, A. Colombo, G. Tarantini, A.S. Petronio, F. Ettori, A. Ramondo, G. Santoro, S. Klugmann, F. Bedogni, D. Antoniucci, F. Maisano, A. Marzocchi, A. Poli, M. De Carlo, C. Fiorina, F. De Marco, M. Napodano, R. Violini, A.S. Bortone, C. Tamburino. Impact of coronary artery disease in elderly patients undergoing transcatheter aortic valve implantation: insight from the Italian CoreValve Registry. *Int J Cardiol*, 167 (2013), pp. 943-950
21. P. Wenaweser, T. Pilgrim, E. Guerios, S. Stortecky, C. Huber, A.A. Khattab, A. Kadner, L. Buellesfeld, S. Gloekler, B. Meier, T. Carrel, S. Windecker. Impact of coronary artery disease and percutaneous coronary intervention on outcomes in patients with severe aortic stenosis undergoing transcatheter aortic valve implantation. *EuroIntervention*, 7 (2011), pp. 541-548
22. O. Wendler, T. Walther, P. Nataf, P. Rubino, H. Schroefel, M. Thielmann, H. Treede, M. Thomas. Trans-apical aortic valve implantation: univariate and multivariate analyses of the early results from the SOURCE registry. *Eur J Cardiothorac Surg*, 38 (2010), pp. 119-127
23. M. Gautier, M. Pepin, D. Himbert, G. Ducrocq, B. Iung, M.P. Dilly, D. Attias, P. Nataf, A. Vahanian. Impact of coronary artery disease on indications for transcatheter aortic valve implantation and on procedural outcomes. *EuroIntervention*, 7 (2011), pp. 549-555
24. S.S. Goel, S. Agarwal, E.M. Tuzcu, S.G. Ellis, L.G. Svensson, T. Zaman, N. Bajaj, L. Joseph, N.S. Patel, O. Aksoy, W.J. Stewart, B.P. Griffin, S.R. Kapadia. Percutaneous coronary intervention in patients with severe aortic stenosis: implications for transcatheter aortic valve replacement. *Circulation*, 125 (2012), pp. 1005-1013
25. L. Conradi, M. Seiffert, O. Franzen, S. Baldus, J. Schirmer, T. Meinertz, H. Reichenspurner, H. Treede. First experience with transcatheter aortic valve implantation and concomitant percutaneous coronary intervention. *Clin Res Cardiol*, 100 (2011), pp. 311-316
26. D.P. Griese, W. Reents, A. Toth, S. Kerber, A. Diegeler, J. Babin-Ebell. Concomitant coronary intervention is associated with poorer early and late clinical outcomes in selected elderly patients receiving transcatheter aortic valve implantation. *Eur J Cardiothorac Surg*, 46 (2014), pp. e1-e7
27. Thomas M. Percutaneous Coronary Intervention Prior to Transcatheter Aortic Valve Implantation: a randomised controlled trial (ACTIVATION).
28. Rodes-Cabau J, Webb JG. Aspirin versus Aspirin + Clopidogrel Following Transcatheter Aortic Valve Implantation: the ARTE trial.







# Chapter 4

---

## Predictors of residual tricuspid regurgitation after percutaneous closure of atrial septal defect

Martina Nassif, Frank van der Kley, Mohammad Abdelghani, Deborah N Kalkman, Rianne H A C M de Bruin-Bon, Berto J Bouma, Martin J Schalijs, David R Koolbergen, Jan G P Tijssen, Barbara J M Mulder, Robbert J de Winter

*European Heart Journal - Cardiovascular Imaging*, Volume 20, Issue 2, February 2019, Pages 225–232,

## ABSTRACT

### Aims

Functional tricuspid regurgitation (TR) associated with atrial septal defects (ASDs) is frequently present due to right-sided volume-overload. Tricuspid valve (TV) repair is often considered in candidates for surgical ASD closure, and percutaneous TV repair is currently under clinical investigation. In this study, we develop a prediction model to identify patients with residual moderate/severe TR after percutaneous ASD closure.

### Methods and results

In this observational study, 172 adult patients (26% male, age  $49 \pm 17$  years) with successful percutaneous ASD closure had pre- and post-procedural echocardiography. Right heart dimensions/function were measured. TR was assessed semi-quantitatively. A prediction model for 6-month post-procedural moderate/severe TR was derived from uni- and multi-variable logistic regression. Clinical follow-up (FU) was updated and adverse events were defined as cardiovascular death or hospitalization for heart failure. Pre-procedural TR was present in 130 (76%) patients (moderate/severe:  $n = 64$ ) of which 72 (55%) had  $\geq 1$  grade reduction post-closure. Independent predictors of post-procedural moderate/severe TR ( $n = 36$ ) were age  $\geq 60$  years [odds ratio (OR) 2.57;  $P = 0.095$ ], right atrial end-diastolic area  $\geq 10 \text{ cm}^2/\text{m}^2$  (OR 3.36;  $P = 0.032$ ), right ventricular systolic pressure  $\geq 44$  mmHg (OR 6.44;  $P = 0.001$ ), and tricuspid annular plane systolic excursion  $\leq 2.3$  cm (OR 3.29;  $P = 0.037$ ), producing a model with optimism-corrected C-index = 0.82 ( $P < 0.001$ ). Sensitivity analysis excluding baseline none/mild TR yielded similar results. Patients with moderate/severe TR at 6-month FU had higher adverse event rates [hazard ratio = 6.2 (95% confidence interval 1.5–26); log-rank  $P = 0.004$ ] across a median of 45 (30–76) months clinical FU.

### Conclusion

This study shows that parallel to reduction of volume-overload and reverse remodeling after percutaneous ASD closure, TR improved substantially despite significant TR at baseline. Our proposed risk model helps identify ASD patients in whom TR regression is unlikely after successful percutaneous closure.

## INTRODUCTION

Secundum atrial septal defects (ASDs) are one of the most common adult congenital heart defects.<sup>1</sup> Functional tricuspid regurgitation (TR) can occur secondary to ASD-based volume-overload due to right heart- and tricuspid annular dilatation. Percutaneous ASD closure may improve functional TR by reverse remodelling and prevent further right heart deterioration from volume- to eventual pressure-overload.

Functional TR is the most prevalent tricuspid valve (TV) disease in the West and independently predicts cardiovascular morbidity and mortality,<sup>1</sup> especially if moderate/severe.<sup>2-4</sup> Following the recognition of the clinical relevance of functional TR, an active therapeutic strategy is currently advocated.<sup>5-7</sup> TV repair is considered in candidates for surgical ASD closure with annular diameter  $\geq 40$  mm. However, current European<sup>8</sup> and American<sup>9</sup> guidelines recommend repair of functional TR as part of left-sided heart disease only, therefore, management of ASD-based TR remains undetermined and simultaneous surgical ASD and TV repair is often performed.

Apart from a few studies reporting the frequency and risk factors of significant TR after ASD closure,<sup>10,11</sup> no risk stratification of moderate/severe TR at post-procedural follow-up (FU) exists for adult candidates of ASD closure. Our aim was to develop a clinical prediction model for the risk of persistent TR after percutaneous ASD closure to help identify patients in whom TR improvement may not occur.

## METHODS

### Study design

In this retrospective cohort study, all adult ASD patients from two university hospitals who underwent percutaneous closure were evaluated. The study cohort comprised consecutive patients who underwent successful percutaneous ASD closure (i.e. without device embolization/thrombosis or significant residual shunting) and who had transthoracic echocardiography (TTE) at baseline and at approximately 6-month FU (inclusion range of 3–18 months). Patient characteristics and echocardiographic studies were gathered from medical records, and clinical outcomes were updated from patient contact by telephone or alternatively gathered from the last medical FU. This study complies with the declaration of Helsinki and is in compliance with national legislation; each centre's local medical ethical committee approved this study with a waiver and all patients provided informed consent.

### *ASD closure*

The Grown-Up Congenital Heart disease heart team determined the indication for ASD closure according to recommendations of the current European guidelines, based on either haemodynamically significant left-to-right shunting with pulmonary vascular resistance  $<5$  Woods units (Class I, level B) or suspicion of paradoxical embolism (Class IIa, level C).<sup>12</sup> Percutaneous ASD closure was performed under either general or local anaesthesia and an Amplatzer Septal Occluder (St. Jude Medical, Minneapolis, MN, USA) of appropriate size was implanted. Post-procedural therapy included a 6-month regimen of either dual antiplatelet therapy with aspirin 100 mg and clopidogrel 75 mg daily after a 600 mg loading dose, or only aspirin 300 mg daily, depending on the treating centre's protocol.

### **Echocardiography**

2D TTE was performed both at baseline and post-procedural follow-up as part of routine clinical outpatient visits. Echocardiographic views were acquired on a Vivid 7-9.5 (GE Healthcare, Horten, Norway) based on guideline recommendations,<sup>13</sup> and analyses were performed offline on EchoPAC PC v.201 (GE Healthcare, Horten, Norway). Right atrial (RA) and ventricular (RV) dimensions and maximal tricuspid annular diameter were obtained from the apical four-chamber view, and RV systolic function was assessed by fractional area change, tricuspid annular plane systolic excursion (TAPSE) and tricuspid annular systolic motion velocity. TR was semi-quantitatively scored based on valve morphology, visual assessment of colour-flow TR jet, vena contracta width, shape and intensity of the continuous wave Doppler TR jet signal, and hepatic venous flow pattern.<sup>14</sup> In the absence of inferior vena cava measurements ( $n=64$  baseline,  $n=54$  FU), RA pressure was estimated at 8 mmHg when RA area  $>18\text{cm}^2$  and 3 mmHg if smaller.<sup>15</sup> Peak TR jet velocity was obtained from multiple Doppler views, and RV systolic pressure was calculated using the modified Bernoulli equation.<sup>16</sup>

### **Definition of outcomes**

The main outcome measure of this study was moderate/severe TR on echocardiography at 6-month post-procedural FU. Secondly, to assess the predictive value of the TV severity on clinical outcome, all patients were contacted by telephone to update clinical information and assess symptomatology between June and November 2017. An adverse clinical event was defined as the composite of cardiovascular death or hospitalization for heart failure. All deaths were marked cardiovascular unless an unequivocal non-cardiac cause could be established. Heart failure hospitalization was defined as hospital admission of  $\geq 12$  h for worsening heart failure symptoms that required parenteral therapy. Time-to-event was time to first event, whichever

came first. In addition, symptoms of dyspnoea, peripheral oedema, chest pain, palpitations, dizziness, syncope, and fatigue were assessed at latest clinical FU.

### *Statistical analysis*

Analyses were performed on R v.3.4.0 (R Foundation for Statistical Computing, Vienna, Austria) and SPSS v.23 (IBM Corp., Armonk, NY, USA). Baseline characteristics, haemodynamics and pulmonary function parameters are presented as mean  $\pm$  standard deviation, median (25th–75th percentile), or frequency (percentage) according to variable type and distribution. The two-tailed paired- and independent *t*-tests were used for paired respectively between-group testing in continuous variables. Categorical variables were compared using the  $\chi^2$  test and the McNemar test in independent respectively paired testing. Correlations were linearly tested unless mentioned otherwise. A  $P < 0.05$  was considered statistically significant.

Two investigators (M.N. and M.A) who were blinded to patient information and clinical outcome, assessed TR severity in 60 randomly selected cases. Inter-observer agreement was then analysed using Cohen's kappa for TR grading.

Univariable logistic regression analyses were used to identify determinants of moderate/severe TR at post-procedural FU. Candidate risk factors were clinically relevant patient and ASD characteristics, and baseline echocardiographic parameters that statistically differed between the outcome and the non-outcome group. Continuous variables were dichotomized using the Youden index to facilitate potential use of this prediction model in clinical practice.

Variables with  $P \leq 0.10$  in univariable analysis were initially incorporated in three multivariable analyses; one with only clinical variables, another with additional echocardiographic parameters, and the third from a backwards selection in which variables with  $P < 0.10$  by the Wald statistic were identified. The discriminative value of these models was compared using the C-index, Akaike Information Criterion, Net Reclassification Improvement, and Integrated Discrimination Improvement.<sup>17</sup> The final model was defined as the simplest and highest discriminative model of these. Sensitivity analysis excluding patients with  $\leq$  mild TR was performed to validate the model specifically in patients with moderate/severe TR at baseline. Proportional to their odds ratio (OR), independent predictors in the final model were assigned scores in which a higher cumulative score indicated higher estimated risk of moderate/severe TR at 6-month FU.



Adverse event rates were based on the Kaplan–Meier estimates in time-to-event analyses with a landmark at 6-month post-closure. FU of patients was censored at the time of last telephone contact or, if not available, at the last medical contact. For time-to-event analyses between patients with and without moderate/severe TR at FU, the hazard ratio was determined by Cox regression analysis and Kaplan–Meier curves were compared using the log-rank test.

## RESULTS

### Study population

The total cohort consisted of 202 adult patients (Supplementary data , *Figure S1*), of which 172 patients (74% female, mean age  $49 \pm 17$  years, range 18–84 years) were included in this study for having complete baseline [median 4.0 (2.0–7.0) months before closure] and FU echocardiograms [median 6.0 (5.0–7.0) months after closure]. The indication for ASD closure was haemodynamically significant left-to-right shunting in 83% and paradoxical embolism in 17% of patients. Patient characteristics and ASD-related measurements are shown in *Table 1*, and baseline cardiac medication is listed in Supplementary data , *Table S1*.

### TR and reverse remodelling

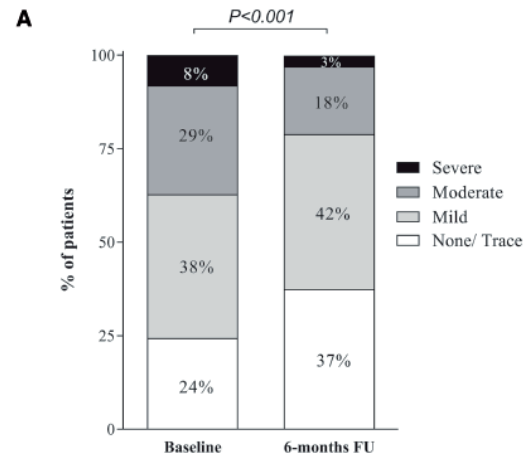
At baseline, 130 (76%) patients had  $\geq$  mild TR (*Figure 1A*) and of these, 72 (55%) patients experienced  $\geq 1$  TR grade reduction at post-procedural FU. Of the 64 patients who had moderate/severe TR at baseline, 34 (53%) patients improved to none/mild at FU (*Figure 1B*). Six patients were classified from baseline mild TR to post-procedural moderate TR, thus 36 patients eventually had moderate/severe TR at 6-month post-procedural FU. Mild residual shunting was present in three patients ( $n=2$  with none/mild TR), one of which had a small second ASD not intended for closure. The inter-observer variability in TR severity assessment yielded a very good agreement ( $n=56$  out of  $n=60$ ) with Cohen's kappa=0.830 [95% confidence interval (CI) 0.669–0.991],  $P < 0.001$ .

The echocardiographic parameters of reverse remodelling are given in *Table 2*. Overall, RA and RV dimensions and RV systolic pressure regressed, even more significantly in patients with baseline moderate/severe TR, possibly explained by larger right-sided dimensions and a higher RV systolic pressure at baseline. RV systolic function parameters, RV fractional area change, and TAPSE significantly reduced after closure, which reflect the volume-load dependency of these variables together with the volume reduction that results from shunt closure. Left ventricular ejection fraction was  $\geq 50\%$  in all patients and remained unchanged after closure.

**Table 1** Baseline patient characteristics

<b>n = 172</b>	
<b>Demographics</b>	
Age (years)	49 ± 17
Female gender	128 (74)
BSA (m <sup>2</sup> )	1.8 ± 0.2
<b>Medical history</b>	
Hypertension	58 (34)
Dyslipidaemia	34 (20)
Diabetes mellitus	13 (8)
Coronary intervention	4 (2)
Cerebrovascular accident	29 (17)
Atrial arrhythmia	40 (23)
Paroxysmal atrial fibrillation	27 (16)
Persistent atrial fibrillation	10 (6)
Atrial flutter	3 (2)
Pulmonary hypertension <sup>a</sup>	14 (8)
Right ventricular systolic pressure (mmHg)	37 ± 12
<b>Symptoms</b>	
Palpitations	50 (29)
<b>NYHA class</b>	
I	87 (52)
II	59 (34)
III	22 (13)
Unknown	4 (2)
<b>ASD-related characteristics</b>	
TOE maximum defect size (mm; n = 161)	19 ± 7.5
Device size (mm)	21 ± 7.3
Qp:Qs ratio <sup>b</sup>	1.9 ± 0.6

Data are presented as mean ± SD or frequencies (%).  
 BSA, body surface area; NYHA, New York Heart Association; TOE, transoesophageal echocardiography; Qp:Qs, pulmonary to systemic flow ratio.  
<sup>a</sup>Right ventricular systolic pressure ≥50 mmHg by TTE.<sup>15</sup>  
<sup>b</sup>By echocardiography or CMR (n = 74).



**B**

N	TR grade at 6-month FU				Total	
	None/trace	Mild	Moderate	Severe		
Baseline	None/trace	27	14	1	0	42
TR grade	Mild	33	28	5	0	66
	Moderate	3	24	20	3	50
	Severe	2	5	5	2	14
Total		65	71	31	5	172

**Figure 1** Pre- and post-closure tricuspid regurgitation. Pre- and post-procedural tricuspid regurgitation grades in percentages (A) and number of patients (B). Percentages may not sum to 100% due to rounding. FU, follow-up; TR, tricuspid regurgitation.

Tricuspid annular diameter showed modest association with TR grade, both at baseline and at FU ( $r=0.32$  and  $r=0.37$ , respectively;  $P<0.001$ ), see Supplementary data online, *Figure S2*. Tricuspid annular diameter reduction was more significant in patients who had  $\geq 1$  TR grade improvement ( $\Delta -13 \pm 13\%$  vs.  $\Delta -8 \pm 16\%$ ;  $P=0.018$ ).

### Predictors of post-procedural TR

Univariable predictors of moderate/severe TR at post-procedural FU are shown in *Table 3*. After comparing three multivariable models (Supplementary data, *Table S2*), the final model included age  $\geq 60$  years (OR 2.57;  $P=0.10$ ), RA end-diastolic area index  $\geq 10$  cm<sup>2</sup>/m<sup>2</sup> (OR 3.36;  $P=0.03$ ), RV systolic pressure  $\geq 44$  mmHg (OR 6.44;  $P=0.001$ ), and TAPSE  $\leq 2.3$  cm (OR 3.29;  $P=0.04$ ) as independent predictors. This model was statistically significant ( $\chi^2 [4] = 35.57$ ;  $P<0.001$ ), and correctly classified 82% of cases by internal validation [C-index=0.85 (95% CI 0.76–0.93);  $P<0.001$ ]. In a sensitivity analysis including only patients with baseline moderate/severe TR ( $n=64$ ), this model remained significantly predictive of residual moderate/severe TR [C-index=0.72 (95%

**Table 2** Baseline and post-procedural change in haemodynamic parameters stratified to TR severity at baseline

	None/mild TR				Moderate/severe TR				P-value <sup>a</sup>
	n	Baseline	Δ (%)	P-value (paired)	N	Baseline	Δ (%)	P-value (paired)	
Chamber dimensions									
RA end-systolic area (cm <sup>2</sup> /m <sup>2</sup> )	106	12 ± 3.6	-16 ± 27	<0.001	61	16 ± 6.1*	-26 ± 17	<0.001	0.006
RA end-diastolic area (cm <sup>2</sup> /m <sup>2</sup> )	106	7.5 ± 3.0	-14 ± 35	<0.001	61	11 ± 5.9*	-24 ± 19	<0.001	0.04
RV end-systolic basal diameter (cm)	107	3.8 ± 0.8	-3 ± 38	0.05	62	4.0 ± 0.7	-2 ± 50	0.46	0.92
RV end-systolic length (cm)	107	6.3 ± 1.0	0.5 ± 19	0.54	62	6.2 ± 0.7	-1 ± 17	0.36	0.60
RV end-systolic area (cm <sup>2</sup> )	107	19 ± 6.2	-10 ± 29	<0.001	62	20 ± 5.0	-16 ± 27	<0.001	0.24
RV end-diastolic basal diameter (cm)	107	4.3 ± 1.0	-14 ± 16	<0.001	62	4.4 ± 0.9	-12 ± 12	<0.001	0.54
RV end-diastolic length, cm	107	8.1 ± 1.1	-3 ± 18	0.02	62	7.8 ± 0.9	-5 ± 16	0.004	0.54
RV end-diastolic area (cm <sup>2</sup> )	107	31 ± 9.2	-18 ± 23	<0.001	62	32 ± 6.3	-26 ± 16	<0.001	0.009
TV									
TV annular diameter (cm)	108	3.7 ± 0.7	-8 ± 17	<0.001	64	3.9 ± 0.6	-11 ± 13	<0.001	0.28
Vena contracta (mm)	108	2.1 ± 1.5	-12 ± 84	0.21	64	5.1 ± 0.02*	-21 ± 61	<0.001	0.003
RV systolic pressure (mmHg)	81	32 ± 8.5	-2 ± 42	0.01	62	44 ± 13*	-15 ± 21	<0.001	0.03
RV fractional area change (%)	107	38 ± 14	-13 ± 47	0.005	62	38 ± 15	-16 ± 62	0.01	0.73
TAPSE (cm)	93	2.8 ± 0.5	-6 ± 21	<0.001	50	2.6 ± 0.06**	-6 ± 23	0.01	1.00
RVS' (cm/s)	36	14 ± 3.0	-5 ± 15	0.08	21	17 ± 0.2	-14 ± 27	0.26	0.24

Data are presented as mean ± SD of both absolute values (baseline) and percentages (delta of post- vs. pre-procedural values).

ED, end-diastolic; ES, end-systolic; RA, right atrial; RV, right ventricular; RVS', tricuspid annular systolic motion velocity; TAPSE, tricuspid annular plane systolic excursion; TR, tricuspid regurgitation; TV, tricuspid valve.

<sup>a</sup>Comparison of percentage change stratified by baseline TR severity.

\*P < 0.001 for all comparisons of baseline value stratified by TR severity.

\*\*P < 0.05 for all comparisons of baseline value stratified by TR severity.

**Table 3** Uni- and multivariable logistic regression for moderate/severe tricuspid regurgitation at follow-up

	Variable present	Variable absent	Univariable			Multivariable		
			OR	95% CI	P-value	OR	95% CI	P-value
Patient characteristics								
Age at closure ≥ 60 years	38% (19/50)	14% (17/122)	3.8	1.8–8.2	0.001	2.6	0.9–7.6	0.10
Female gender	23% (30/128)	14% (6/44)	1.9	0.8–5.0	0.17			
Hypertension	29% (17/58)	17% (19/114)	2.1	1.0–4.4	0.06			
Atrial arrhythmia	38% (15/40)	16% (21/132)	3.2	1.4–7.0	0.004			
NYHA class ≥ III	45% (10/22)	17% (26/150)	4.0	1.6–10.2	0.004			
ASD characteristic								
TOE maximum defect size ≥ 24 mm	29% (12/41)	19% (23/120)	1.8	0.8–3.9	0.18			
Device size ≥ 26 mm	29% (13/45)	18% (23/127)	1.8	0.8–4.0	0.14			
Qp:Qs ratio ≥ 2.3	26% (5/19)	16% (9/55)	1.8	0.5–6.3	0.34			
Baseline echocardiography								
RA ES area ≥ 15 cm <sup>2</sup> /m <sup>2</sup>	35% (18/51)	15% (17/116)	3.2	1.5–6.9	<0.001			
RA ED area ≥ 10 cm <sup>2</sup> /m <sup>2</sup>	45% (19/42)	13% (16/125)	5.7	2.5–12.6	<0.001	3.4	1.1–10.1	0.03
RV ES basal diameter ≥ 4 cm	31% (23/75)	13% (12/94)	3.0	1.4–6.6	0.005			
RV ED basal diameter ≥ 5 cm	30% (10/33)	18% (25/136)	1.9	0.8–4.6	0.13			
TV annular diameter ≥ 4 cm	36% (20/55)	14% (16/117)	3.6	1.7–7.7	0.001			
Vena contracta ≥ 5 mm	50% (20/40)	12% (16/132)	7.7	3.4–17.6	<0.001			
RV systolic pressure ≥ 44 mmHg	54% (20/37)	14% (15/106)	7.1	3.1–16.6	<0.001	6.4	2.1–19.7	0.001
RV fractional area change ≤ 30%	25% (8/32)	20% (27/137)	1.4	0.6–3.4	0.51			
TAPSE ≤ 2.3 cm	35% (13/37)	15% (16/106)	3.1	1.3–7.2	0.01	3.3	1.1–10.1	0.04

Data are presented as percentages (frequencies) and odds ratios with their 95% confidence intervals. Cut-off values correspond to the 75th percentile.

NYHA, New York Heart Association; TOE, transoesophageal echocardiography; Qp:Qs, pulmonary to systemic flow ratio.

CI 0.58–0.86); P=0.008]. Figure 2 shows a simplified risk stratification using OR-based risk score, along with corresponding predicted and observed rate of moderate/severe TR at 6-month FU. A risk score of ≥4 yielded a predicted probability of ≥75% for

**Table 4** Patient symptoms at latest clinical follow-up

	Moderate/ severe TR before and after closure (n = 27)	Moderate/ severe TR reduced to none/mild TR (n = 32)	None/mild TR before and after closure (n = 101)
Dyspnoea	8 (30)	5 (16)	15 (15)
Peripheral oedema	11 (41)	5 (16) <sup>a</sup>	20 (20)
Chest pain	2 (7)	0 (0)	6 (6)
Palpitations	12 (44)	16 (50)	42 (42)
Dizziness	9 (33)	7 (22)	32 (32)
Syncope	3 (11)	2 (6)	5 (5)
Fatigue	9 (33)	10 (31)	31 (31)

Data are presented as frequencies (%) of surviving patients' reported symptoms at median 45 (30–76) months post-procedural follow-up.

<sup>a</sup>P < 0.05 for moderate/severe TR that persisted vs. reduced to none/mild TR.

moderate/severe TR at FU, see *Figure 2B*. In patients with a risk score of  $\geq 4$  ( $n = 12$ ), 9 (75%) patients actually had moderate/severe TR at post-procedural FU.

Prediction model for moderate/severe TR after percutaneous ASD closure in adults. (A) Risk model scores per independent predictor, weighted according to respective odds ratios. (B) Plotted cumulative risk score against predicted and observed probability of moderate/severe TR 6 months after ASD closure. A higher cumulative risk score (range 0–5) indicated a higher predicted probability (5%, 14%, 29%, 52%, 75%, and 90%, respectively) and showed a higher observed rate (4%, 13%, 37%, 50%, 63%, and 100%, respectively) of post-closure moderate/severe TR; C-index = 0.85 (95% CI 0.76–0.93),  $P < 0.001$ . RA, right atrial; RV, right ventricular; TR, tricuspid regurgitation.

## Clinical outcomes

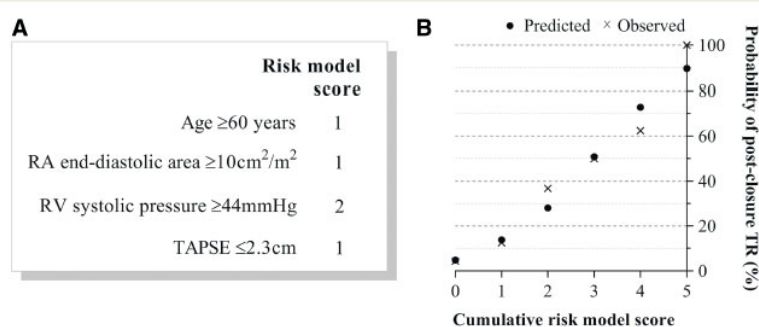
The median clinical post-procedural FU duration was 45 (30–76) months (range 9–146 months). Six patients died during FU; three in each outcome group, i.e. with and without moderate/severe TR at 6-month FU, and in each two cardiovascular deaths occurred. One patient died of ovarian carcinoma (outcome group) and another of bladder cancer (non-outcome group).

Between June and November 2017, 155 (93%) of the surviving patients could be contacted by telephone to update clinical FU. The unavailable patients had a median FU of 33 (24–54) months. Patients with moderate/severe TR at FU had significantly higher adverse event rates (*Figure 3*) with a hazard ratio of 6.2 (95% CI 1.5–26) and log-rank  $P = 0.004$ . This was mainly driven by a higher rate of heart failure hospitalizations ( $n = 3$  in outcome group and  $n = 1$  in non-outcome group).

**Table 3** Uni- and multivariable logistic regression for moderate/severe tricuspid regurgitation at follow-up

	Variable present	Variable absent	Univariable			Multivariable		
			OR	95% CI	P-value	OR	95% CI	P-value
<b>Patient characteristics</b>								
Age at closure $\geq 60$ years	38% (19/50)	14% (17/122)	3.8	1.8–8.2	0.001	2.6	0.9–7.6	0.10
Female gender	23% (30/128)	14% (6/44)	1.9	0.8–5.0	0.17			
Hypertension	29% (17/58)	17% (19/114)	2.1	1.0–4.4	0.06			
Atrial arrhythmia	38% (15/40)	16% (21/132)	3.2	1.4–7.0	0.004			
NYHA class $\geq$ III	45% (10/22)	17% (26/150)	4.0	1.6–10.2	0.004			
<b>ASD characteristic</b>								
TOE maximum defect size $\geq 24$ mm	29% (12/41)	19% (23/120)	1.8	0.8–3.9	0.18			
Device size $\geq 26$ mm	29% (13/45)	18% (23/127)	1.8	0.8–4.0	0.14			
Qp:Qs ratio $\geq 2.3$	26% (5/19)	16% (9/55)	1.8	0.5–6.3	0.34			
<b>Baseline echocardiography</b>								
RA ES area $\geq 15$ cm <sup>2</sup> /m <sup>2</sup>	35% (18/51)	15% (17/116)	3.2	1.5–6.9	<0.001			
RA ED area $\geq 10$ cm <sup>2</sup> /m <sup>2</sup>	45% (19/42)	13% (16/125)	5.7	2.5–12.6	<0.001	3.4	1.1–10.1	0.03
RV ES basal diameter $\geq 4$ cm	31% (23/75)	13% (12/94)	3.0	1.4–6.6	0.005			
RV ED basal diameter $\geq 5$ cm	30% (10/33)	18% (25/136)	1.9	0.8–4.6	0.13			
TV annular diameter $\geq 4$ cm	36% (20/55)	14% (16/117)	3.6	1.7–7.7	0.001			
Vena contracta $\geq 5$ mm	50% (20/40)	12% (16/132)	7.7	3.4–17.6	<0.001			
RV systolic pressure $\geq 44$ mmHg	54% (20/37)	14% (15/106)	7.1	3.1–16.6	<0.001	6.4	2.1–19.7	0.001
RV fractional area change $\leq 30\%$	25% (8/32)	20% (27/137)	1.4	0.6–3.4	0.51			
TAPSE $\leq 2.3$ cm	35% (13/37)	15% (16/106)	3.1	1.3–7.2	0.01	3.3	1.1–10.1	0.04

Data are presented as percentages (frequencies) and odds ratios with their 95% confidence intervals. Cut-off values correspond to the 75th percentile. NYHA, New York Heart Association; TOE, transoesophageal echocardiography; Qp:Qs, pulmonary to systemic flow ratio.

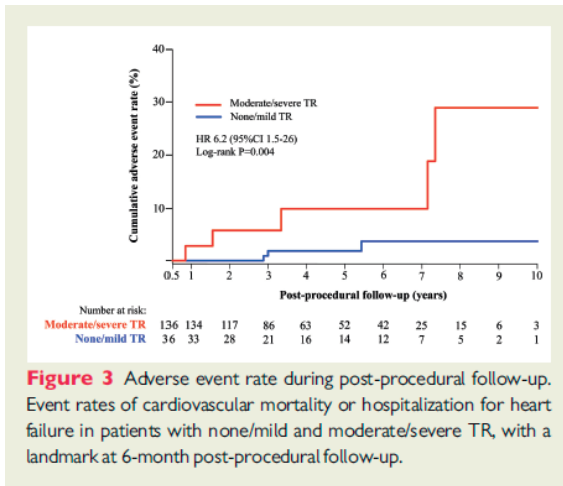


**Figure 2** Prediction model for moderate/severe TR after percutaneous ASD closure in adults. (A) Risk model scores per independent predictor, weighted according to respective odds ratios. (B) Plotted cumulative risk score against predicted and observed probability of moderate/severe TR 6 months after ASD closure. A higher cumulative risk score (range 0–5) indicated a higher predicted probability (5%, 14%, 29%, 52%, 75%, and 90%, respectively) and showed a higher observed rate (4%, 13%, 37%, 50%, 63%, and 100%, respectively) of post-closure moderate/severe TR; C-index = 0.85 (95% CI 0.76–0.93),  $P < 0.001$ . RA, right atrial; RV, right ventricular; TR, tricuspid regurgitation.

Symptoms at latest clinical FU are shown in Table 4. Patients with persistent moderate/severe TR had more symptoms of dyspnoea and peripheral oedema than patients in whom TR had reduced to none/mild (30% vs. 16% and 41% vs. 16%, respectively). The latter were comparable to patients who maintained none/mild TR (15% and 20%, respectively). Regardless of TR severity at FU, palpitations and fatigue were the most frequently reported symptoms post-closure.

This study is the first to propose a clinical prediction model for residual TR after successful percutaneous ASD closure in adults. Age  $\geq 60$  years, RA end-diastolic area





**Table 4** Patient symptoms at latest clinical follow-up

	Moderate/severe TR before and after closure (n = 27)	Moderate/severe TR reduced to none/mild TR (n = 32)	None/mild TR before and after closure (n = 101)
Dyspnoea	8 (30)	5 (16)	15 (15)
Peripheral oedema	11 (41)	5 (16) <sup>a</sup>	20 (20)
Chest pain	2 (7)	0 (0)	6 (6)
Palpitations	12 (44)	16 (50)	42 (42)
Dizziness	9 (33)	7 (22)	32 (32)
Syncope	3 (11)	2 (6)	5 (5)
Fatigue	9 (33)	10 (31)	31 (31)

Data are presented as frequencies (%) of surviving patients' reported symptoms at median 45 (30–76) months post-procedural follow-up.  
<sup>a</sup>P < 0.05 for moderate/severe TR that persisted vs. reduced to none/mild TR.

index  $\geq 10 \text{ cm}^2/\text{m}^2$ , RV systolic pressure  $\geq 44 \text{ mmHg}$  and TAPSE  $\leq 2.3 \text{ cm}$  each independently predicted moderate/severe TR at 6-month post-procedural FU, and together yielded a highly predictive model. Patients with persistent significant TR at 6-month post-closure had a higher adverse event rate during long-term FU.

### TR and reverse remodelling

Functional TR in patients with ASD and left-to-right shunting is mainly the result of RV dilatation and free wall stretch causing both tricuspid annular dilatation as well as leaflet malcoaptation and tethering.<sup>6,18</sup> Atrial tachyarrhythmia and/or increased pulmonary artery pressures contribute to this pathophysiology. In turn, functional TR can further contribute to RA and RV dilatation irrespective of pulmonary artery pressure.<sup>19</sup>

In line with previous studies,<sup>10,11,20</sup> our study reports significant TR reduction at 6-month FU post-ASD closure despite significant TR at baseline. Successful closure unloads the right heart and initiates a reduction of right heart dimensions, occurring mostly within 1-month post-closure<sup>21</sup> followed by slow additional improvement up to 6–24 months.<sup>4,22</sup> Our observed improvement of functional TR was parallel to significant reduction of the tricuspid annulus diameter and RV reverse remodelling. In line with previous studies,<sup>20,23</sup> post-procedural decrease in RV systolic pressure (RVSP) also contributed to TR improvement and took place even in patients with mildly elevated pulmonary pressures. Six patients had increase from baseline none/trace to post-procedural moderate TR. Fang *et al.*<sup>10</sup> reported similar observations and suggested a mechanical influence of the ASD occluder.

## Predictors of post-procedural TR

Despite general TR improvement after ASD closure, persistent moderate/severe TR was observed in 30/64 (47%) patients, consistent with previous reports.<sup>10,11</sup> The predicted probability of post-closure moderate/severe TR was translated into a more practical 6-point cumulative risk score which performed satisfactorily in all risk strata (see Figure 2). For example, patients with the highest cumulative score ( $\geq 4$ ) had a predicted and observed probability of 75% for post-closure moderate/severe TR.

In line with our findings, most studies investigating ASD-based TR agree that in a subgroup of patients with significantly elevated RVSP, post-closure TR regression is less likely.<sup>11,20,24</sup> Toyono *et al.*<sup>11</sup> even recommend TV repair to be considered in all ASD patients with concomitant pulmonary hypertension. Rather than maintaining TR intrinsically, elevated RVSP provokes RV dysfunction by pressure-overload<sup>22,24–26</sup> causing leaflet tethering and further annular dilatation.<sup>6,18,27</sup> Leaflet tethering is therefore expected to be a stronger predictor than RVSP, which Fang *et al.*<sup>10</sup> demonstrated indeed. Although TV geometry assessment is an appealing approach to predict post-closure TR, this is difficult to measure from 2D echocardiographic images,<sup>18</sup> and high-quality 3D echocardiographic techniques were yet unavailable when most of this patient cohort underwent ASD closure.

Older age increases the risk of atrial fibrillation among others, and RA dilatation cannot be seen separately from atrial arrhythmia; it induces atrial arrhythmia and vice versa.<sup>18,28</sup> Therefore, we found a strong collinearity between the presence of atrial arrhythmia and both age and end-diastolic RA size, which explains its exclusion from our model. Older age is also associated with higher pulmonary artery pressure,<sup>20</sup> yet although the latter is the strongest predictor in our model, age does independently contribute to significant TR, since it remained significant in the multivariable model.

Atrial fibrillation and New York Heart Association class, which are previously reported predictors of moderate/severe TR,<sup>4</sup> were eliminated in the final multivariable model because of strong associations with RA size and TAPSE, respectively. Exclusion of these clinical variables provided a higher discrimination in our final model based on the optimism-corrected C-index and Akaike Information Criterion (Supplementary data online, Table S2). Although it can be argued that a model comprising only clinical variables would facilitate its use in daily practice, such a model also lowers its discriminative properties (Supplementary data online, Table S2) compared with the combination of age with echocardiographic parameters that are still routinely collected in candidates for ASD closure.



## Clinical implications

ASD patients are at high risk of functional TR, therefore, it is essential not to overlook the improvement of TR as an important target of ASD closure. TR regression is however not guaranteed in all patients, which prevents it from being an indication for ASD closure itself. Our predictive model may help in identifying patients in whom TR may remain after successful percutaneous ASD closure. Among other factors such as anatomical suitability, the likelihood of moderate/severe TR to persist after ASD closure should be considered by the interventional heart-team when deciding between surgical and percutaneous ASD closure. The debate as to whether a high likelihood of moderate/severe TR post ASD closure justifies that surgical closure be favoured over percutaneous closure merely to facilitate simultaneous TV repair, is far from being settled.<sup>29</sup> The optimal strategy has yet to be explored in future studies, particularly in light of the rapidly evolving less-invasive percutaneous TV repair techniques which currently show promising results.<sup>30,31</sup>

## Limitations

This study has a retrospective design, therefore, we cannot account for all potential confounders in our prediction model despite multivariable analysis. Given the relatively low frequency of moderate/severe TR even with our multicentre data, predictors' regression coefficients may be overestimated even after optimism-correction. The limited number of adverse clinical events did not allow for additional multivariable analysis. Our study did not validate our prediction model in a second patient cohort so future studies are needed to externally validate our model. Finally, echocardiographic FU duration was limited to 6 months, however, as shown in previous studies,<sup>4,21</sup> the largest reverse remodelling and consequent TR change occurs within 6-month post-closure.

## CONCLUSIONS

This study is the first to provide a practical prediction model for the risk of residual TR after percutaneous ASD closure. TR significantly improved in some patients despite significant TR at baseline, and moderate/severe TR post-closure is best predicted by the combination of age, RA size, RV systolic pressure, and the extent of RV dysfunction. This model may help identify a subgroup of patients in whom TR regression after ASD closure is unlikely.

## **Acknowledgements**

The authors thank Dr. Victoria Delgado (Cardiologist at Leiden University Medical Center, Leiden, The Netherlands) for making this multicentre collaboration possible.

**Conflict of interest:** R.J.d.W. received an institutional unrestricted educational research grant for the Academic Medical Center from Abbott Vascular BV. F.v.d.K. reports personal fees from Boston Scientific and Edwards Lifesciences outside the submitted work. All other authors have no conflict of interest.

## REFERENCES

1. Webb G, Gatzoulis MA. Atrial septal defects in the adult: recent progress and overview. *Circulation* 2006;114:1645–53.
2. Nath J, Foster E, Heidenreich PA. Impact of tricuspid regurgitation on long-term survival. *J Am Coll Cardiol* 2004;43:405–9.
3. Topilsky Y, Nkomo VT, Vatury O, Michelena HI, Letourneau T, Suri RM. Clinical outcome of isolated tricuspid regurgitation. *JACC Cardiovasc Imaging* 2014;7: 1185–94.
4. Takaya Y, Akagi T, Kijima Y, Nakagawa K, Ito H. Functional tricuspid regurgitation after transcatheter closure of atrial septal defect in adult patients: long-term follow-up. *JACC Cardiovasc Interv* 2017;10:2211–8.
5. Di Mauro M, Bezante GP, Di Baldassarre A, Clemente D, Cardinali A, Acitelli A et al. Functional tricuspid regurgitation: an underestimated issue. *Int J Cardiol* 2013;168:707–15.
6. Taramasso M, Vanermen H, Maisano F, Guidotti A, La Canna G, Alfieri O. The growing clinical importance of secondary tricuspid regurgitation. *J Am Coll Cardiol* 2012;59:703–10.
7. Dreyfus GD, Corbi PJ, Chan KM, Bahrami T. Secondary tricuspid regurgitation or dilatation: which should be the criteria for surgical repair? *Ann Thorac Surg* 2005;79:127–32.
8. Vahanian A, Alfieri O, Andreotti F, Antunes MJ, Baron-Esquivias G, Baumgartner H et al. Guidelines on the management of valvular heart disease (version 2012): the Joint Task Force on the Management of Valvular Heart Disease of the European Society of Cardiology (ESC) and the European Association for Cardio-Thoracic Surgery (EACTS). *Eur J Cardiothorac Surg* 2012;42:S1–44.
9. Nishimura RA, Otto CM, Bonow RO, Carabello BA, Erwin JP 3rd, Guyton RA et al. 2014 AHA/ACC guideline for the management of patients with valvular heart disease: a report of the American College of Cardiology/American Heart Association Task Force on Practice Guidelines. *J Am Coll Cardiol* 2014;63: e57–185.
10. Fang F, Wang J, Yip GW, Lam YY. Predictors of mid-term functional tricuspid regurgitation after device closure of atrial septal defect in adults: impact of preoperative tricuspid valve remodeling. *Int J Cardiol* 2015;187:447–52.
11. Toyono M, Krasuski RA, Pettersson GB, Matsumura Y, Yamano T, Shiota T. Persistent tricuspid regurgitation and its predictor in adults after percutaneous and isolated surgical closure of secundum atrial septal defect. *Am J Cardiol* 2009; 104:856–61.
12. Baumgartner H, Bonhoeffer P, De Groot NM, de Haan F, Deanfield JE, Galie N et al. ESC Guidelines for the management of grown-up congenital heart disease (new version 2010). *Eur Heart J* 2010;31:2915–57.
13. Lang RM, Badano LP, Mor-Avi V, Afilalo J, Armstrong A, Ernande L et al. Recommendations for cardiac chamber quantification by echocardiography in adults: an update from the American Society of Echocardiography and the European Association of Cardiovascular Imaging. *Eur Heart J Cardiovasc Imaging* 2015;16:233–70.
14. Lancellotti P, Tribouilloy C, Hagendorff A, Popescu BA, Edvardsen T, Pierard LA et al. Recommendations for the echocardiographic assessment of native valvular regurgitation: an ex-

- ecutive summary from the European Association of Cardiovascular Imaging. *Eur Heart J Cardiovasc Imaging* 2013;14:611–44.
15. Galie N, Humbert M, Vachiery JL, Gibbs S, Lang I, Torbicki A et al. 2015 ESC/ERS Guidelines for the diagnosis and treatment of pulmonary hypertension: the Joint Task Force for the Diagnosis and Treatment of Pulmonary Hypertension of the European Society of Cardiology (ESC) and the European Respiratory Society (ERS): endorsed by: association for European Paediatric and Congenital Cardiology (AEPC), International Society for Heart and Lung Transplantation (ISHLT). *Eur Heart J* 2016;37:67–119.
  16. Yock PG, Popp RL. Noninvasive estimation of right ventricular systolic pressure by Doppler ultrasound in patients with tricuspid regurgitation. *Circulation* 1984;70:657–62.
  17. Pencina MJ, D'Agostino RB, D'Agostino RB, Vasan RS. Evaluating the added predictive ability of a new marker: from area under the ROC curve to reclassification and beyond. *Stat Med* 2008;27:157–72; discussion 207–12.
  18. Badano LP, Muraru D, Enriquez-Sarano M. Assessment of functional tricuspid regurgitation. *Eur Heart J* 2013;34:1875–85.
  19. Grapsa J, Gibbs JSR, Cabrita IZ, Watson GF, Pavlopoulos H, Dawson D et al. The association of clinical outcome with right atrial and ventricular remodelling in patients with pulmonary arterial hypertension: study with real-time three-dimensional echocardiography. *Eur Heart J Cardiovasc Imaging* 2012;13:666–72.
  20. Yalonetsky S, Lorber A. Comparative changes of pulmonary artery pressure values and tricuspid valve regurgitation following transcatheter atrial septal defect closure in adults and the elderly. *Congenit Heart Dis* 2009;4:17–20.
  21. Monfredi O, Luckie M, Mirjafari H, Willard T, Buckley H, Griffiths L et al. Percutaneous device closure of atrial septal defect results in very early and sustained changes of right and left heart function. *Int J Cardiol* 2013;167:1578–84.
  22. Kort HW, Balzer DT, Johnson MC. Resolution of right heart enlargement after closure of secundum atrial septal defect with transcatheter technique. *J Am Coll Cardiol* 2001;38:1528–32.
  23. Balint OH, Samman A, Haberer K, Tobe L, McLaughlin P, Siu SC et al. Outcomes in patients with pulmonary hypertension undergoing percutaneous atrial septal defect closure. *Heart* 2008;94:1189–93.
  24. Yong G, Khairy P, De Guise P, Dore A, Marcotte F, Mercier LA et al. Pulmonary arterial hypertension in patients with transcatheter closure of secundum atrial septal defects: a longitudinal study. *Circ Cardiovasc Interv* 2009;2:455–62.
  25. Van De Bruaene A, La Gerche A, Prior DL, Voigt JU, Delcroix M, Budts W. Pulmonary vascular resistance as assessed by bicycle stress echocardiography in patients with atrial septal defect type secundum. *Circ Cardiovasc Imaging* 2011;4:237–45.
  26. Veldtman GR, Razack V, Siu S, El-Hajj H, Walker F, Webb GD et al. Right ventricular form and function after percutaneous atrial septal defect device closure. *J Am Coll Cardiol* 2001;37:2108–13.
  27. Min SY, Song JM, Kim JH, Jang MK, Kim YJ, Song H et al. Geometric changes after tricuspid annuloplasty and predictors of residual tricuspid regurgitation: a realtime three-dimensional

- echocardiography study. *Eur Heart J* 2010;31:2871–80.
28. Gatzoulis MA, Freeman MA, Siu SC, Webb GD, Harris L. Atrial arrhythmia after surgical closure of atrial septal defects in adults. *N Engl J Med* 1999;340:839–46.
29. Webb GD, Opatowsky AR. Strategies for managing functional tricuspid regurgitation in adults with a secundum atrial septal defect. *JACC Cardiovasc Interv* 2017;10:2219–21.
30. Rodes-Cabau J, Hahn RT, Latib A, Laule M, Lauten A, Maisano F et al. Transcatheter therapies for treating tricuspid regurgitation. *J Am Coll Cardiol* 2016;67:1829–45.
31. Latib A, Mangieri A. Transcatheter tricuspid valve repair: new valve, new opportunities, new challenges. *J Am Coll Cardiol* 2017;69:1807–10.

## SUPPLEMENTARY DATA

**Table S1-** Cardiac medication at baseline.

	n=172
<b>Diuretics</b>	
Hydrochloorthiazide	6 (3)
Furosemide	12 (7)
Spirolacton	6 (3)
Bumetanide	6 (3)
<b>β-blocking agents</b>	
Metoprolol	18 (10)
Bisoprolol	6 (3)
Propranolol	1 (1)
Nebivolol	2 (1)
Atenolol	2 (1)
<b>Calcium channel blockers</b>	
Verapamil	3 (2)
Amlodipine	4 (2)
Nifedipine	2 (1)
Barnidipine	1 (1)
<b>Renin-angiotensin system agents</b>	
Perindopril	6 (3)
Lisinopril	6 (3)
Enalapril	3 (2)
Fosinopril	1 (1)
Irbesartan	3 (2)
Candesartan	2 (1)
Losartan	1 (1)
<b>Antiarrhythmics</b>	
Sotalol	5 (3)
Amiodaron	2 (1)
Digoxin	6 (3)
Flecainide	2 (1)
<b>Anticoagulation</b>	
Acenocoumarol	15 (9)
Fenprocoumon	5 (3)
Rivaroxaban	1 (1)
Dabigatran	2 (1)

*Data are presented as frequencies (%). Medication remained unchanged at six-month post-closure follow-up.*

**Table S2.** Comparison of three prediction models for moderate/severe TR at six-month follow-up.

	Model containing only clinical variables n=172			Model of both clinical and echocardiographic variables n=119			Final simplified model of clinical and echocardiographic variables n=119		
	B	SE	P-value	B	SE	P-value	B	SE	P-value
<b>Model predictors</b>									
Age ≥60 years	0.871	0.439	0.048	0.888	0.583	0.128	0.942	0.564	0.095
Atrial arrhythmia	0.796	0.451	0.078	0.229	0.702	0.744			
NYHA class ≥III	1.096	.515	0.033	0.216	0.756	0.775			
RAEDA ≥10cm <sup>2</sup> /m <sup>2</sup>				1.096	0.646	0.090	1.212	0.564	0.032
RVSP ≥44 mmHg				1.779	0.620	0.004	1.863	0.572	0.001
TAPSE ≤2.3 cm				1.164	0.578	0.044	1.192	0.572	0.037
<b>Model properties</b>									
C- index		0.707			0.846			0.845	
Optimism-corrected C-index*		0.690			0.803			0.820	
Nagelkerke's R <sup>2</sup>		0.160			0.395			0.393	
Hosmer-Lemeshow		0.999			0.980			0.991	
<b>Model comparison</b>									
Akaike Information Criterion		166			106			102	
Net Reclassification Improvement†		Reference			0.310; P<0.001			0.310; P<0.001	
Integrated Discrimination Improvement‡		Reference			0.167; P<0.001			0.165; P<0.001	

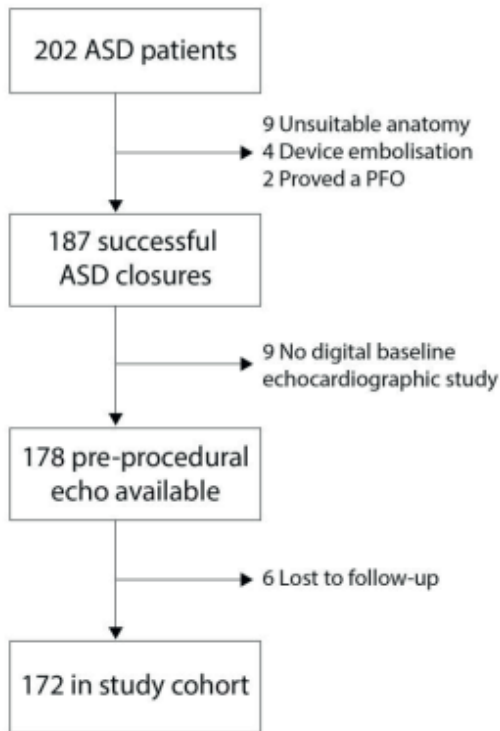
B= Regression coefficient; SE= Standard error; NYHA= New York Heart Association; RAEDA= Right atrial end-diastolic area in cm<sup>2</sup>/m<sup>2</sup>; RVSP= Right ventricular systolic pressure; TAPSE= Tricuspid annular plane systolic excursion.

\* By n=1000 bootstrapping of the model.

† Defined as (Pimproved\_prediction\_among\_outcome + Pimproved\_prediction\_among\_no\_outcome) – (Pworse\_prediction\_among\_outcome + Pworse\_prediction\_among\_no\_outcome) for continuous predicted probabilities with P= proportion of patients.

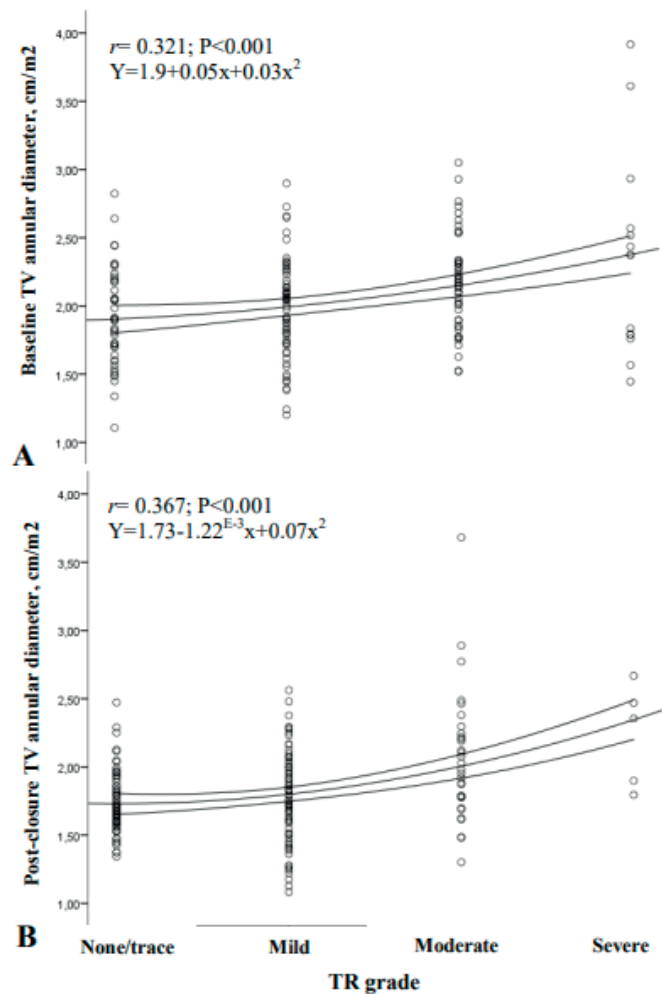
‡ Defined as (Σoutcome(Pnew(i) – Pold(i)) / n(outcome)) - (Σno\_outcome(Pnew(j) – Pold(j)) / n(no\_outcome)) with P= predicted probability for the outcome.





**Figure S1.** Study flow chart. ASD= atrial septal defect; PFO= patent foramen ovale.

**Figure S2.** BSA-indexed tricuspid annular diameter shows a moderate association with increasing TR grade at baseline (A) and six-month follow-up (B).







# Chapter 5

---

## Clinical Spotlight Transcatheter Mitral Valve Repair in Osteogenesis Imperfecta Associated Mitral Valve Regurgitation

Frank van der Kley MD Victoria Delgado MD, PhD Nina Ajmone Marsan MD,  
PhD Martin J. Schalij MD, PhD



## OBJECTIVES

Osteogenesis imperfecta is associated with increased prevalence of significant mitral valve regurgitation. Surgical mitral valve repair and replacement are feasible but are associated with increased risk of bleeding and dehiscence of implanted valves may occur more frequently. The present case report describes the outcomes of transcatheter mitral valve repair in a patient with osteogenesis imperfecta.

## PATIENTS/METHODS

A 60 year-old patient with osteogenesis imperfecta and associated symptomatic moderate to severe mitral regurgitation underwent transthoracic echocardiography which showed a nondilated left ventricle with preserved systolic function and moderate to severe mitral regurgitation. On transoesophageal echocardiography the regurgitant jet originated between the anterolateral scallops of the anterior and posterior leaflets (A1-P1). Considering the comorbidities associated with osteogenesis imperfecta the patient was accepted for transcatheter mitral valve repair using the Mitraclip device (Abbott vascular, Menlo, CA).

## RESULTS

Under fluoroscopy and 3D transoesophageal echocardiography guidance, a Mitraclip device was implanted between the anterolateral and central scallops with significant reduction of mitral regurgitation. The postoperative evolution was uneventful. At one month follow-up, transthoracic echocardiography showed a stable position of the Mitraclip device with no mitral regurgitation.

## CONCLUSIONS

Transcatheter mitral valve repair is feasible and safe in patients with osteogenesis imperfecta and associated symptomatic significant mitral regurgitation.

Patients with osteogenesis imperfecta have an increased prevalence of significant mitral valve regurgitation. [1] This inherited connective tissue disease causes quantitative and qualitative defects in type I collagen, the most abundant collagen type in the human body. Bone fragility is the most characteristic clinical manifestation.



Type I collagen is also a major component of the extracellular matrix of the cardiac structures and a defect in its synthesis may cause mitral valve regurgitation. [2] Although surgical mitral valve repair or replacement are feasible, the associated platelet dysfunction, causing prolonged bleeding time and impaired platelet-endothelial cell interaction, increase significantly the risk of bleeding in these patients. [3] In addition, dehiscence of implanted valves, due to fragile tissue, may occur more frequently in patients with osteogenesis imperfecta. [2] Bearing in mind the risks of surgical mitral valve repair/replacement, transcatheter mitral valve repair technologies may be a feasible and safe therapeutic alternative in this group of patients.

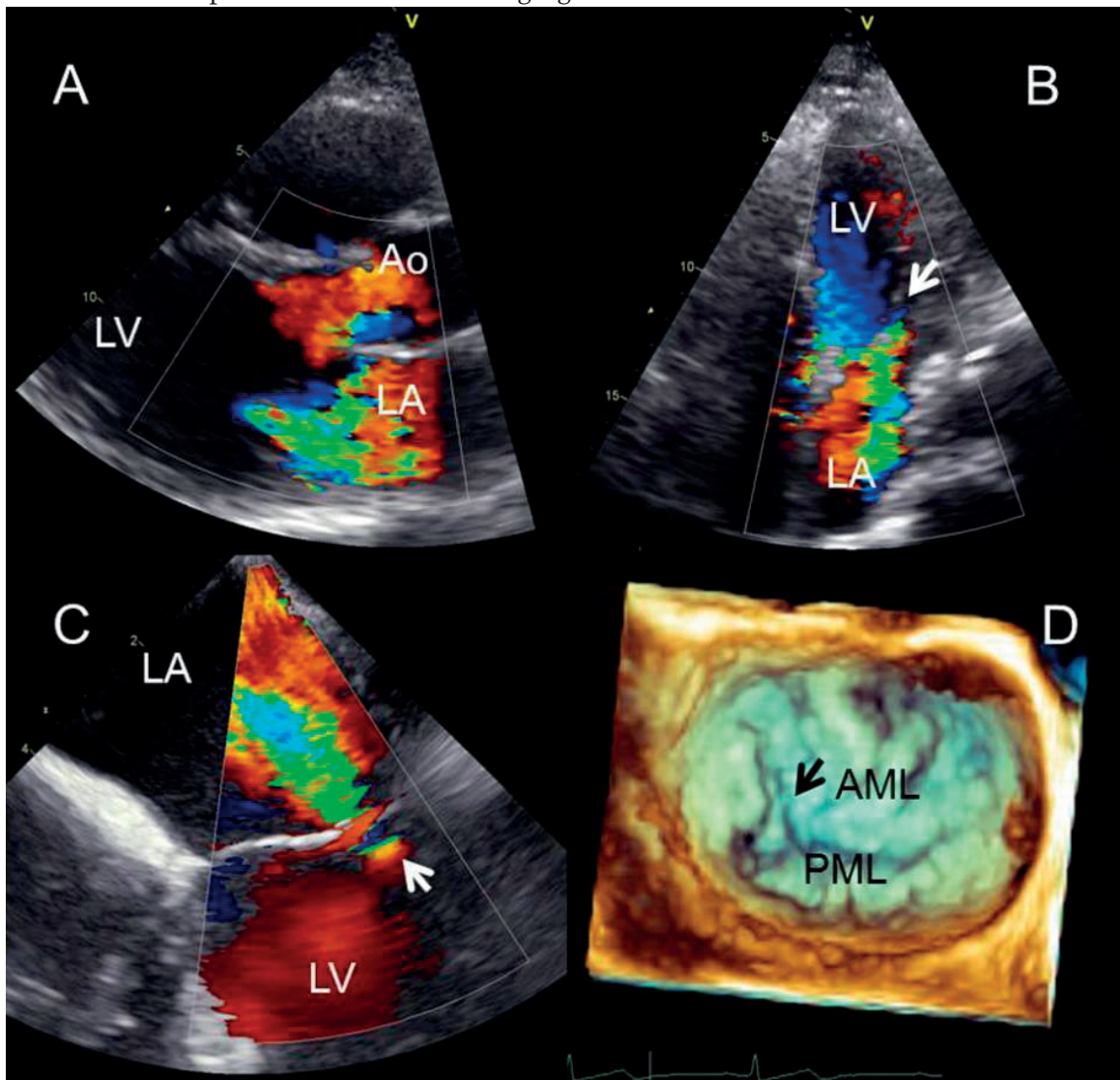
The present case report describes the outcomes of transcatheter mitral valve repair in a 60 year-old patient with osteogenesis imperfecta and associated symptomatic moderate to severe mitral regurgitation. The patient had a mild non-deforming type of osteogenesis imperfecta with blue sclera, several bone fractures, mild joint laxity and impaired hearing and presented to the outpatient clinic with dyspnoea complaints. Transthoracic echocardiography showed a non-dilated left ventricle with preserved systolic function (left ventricular end-systolic diameter 33 mm, ejection fraction 65%) and moderate aortic regurgitation and moderate to severe mitral regurgitation (Figure 1, panels A and B). Transoesophageal echocardiography confirmed a degenerative moderate to severe mitral regurgitation with the regurgitant jet originating between the anterolateral scallops of the anterior and posterior leaflets: level A1-P1 (Figure 1, panels C and D). Considering the comorbidities associated with osteogenesis imperfecta, despite a low calculated logistic EuroSCORE of 2.22%, the patient was accepted for transcatheter mitral valve repair using the Mitraclip device (Abbott vascular, Menlo, CA). Under fluoroscopy and 3D transoesophageal echocardiography guidance, a Mitraclip device was implanted between the anterolateral and central scallops with significant reduction of mitral regurgitation and without causing significant stenosis (Figure 1, panels E-H).

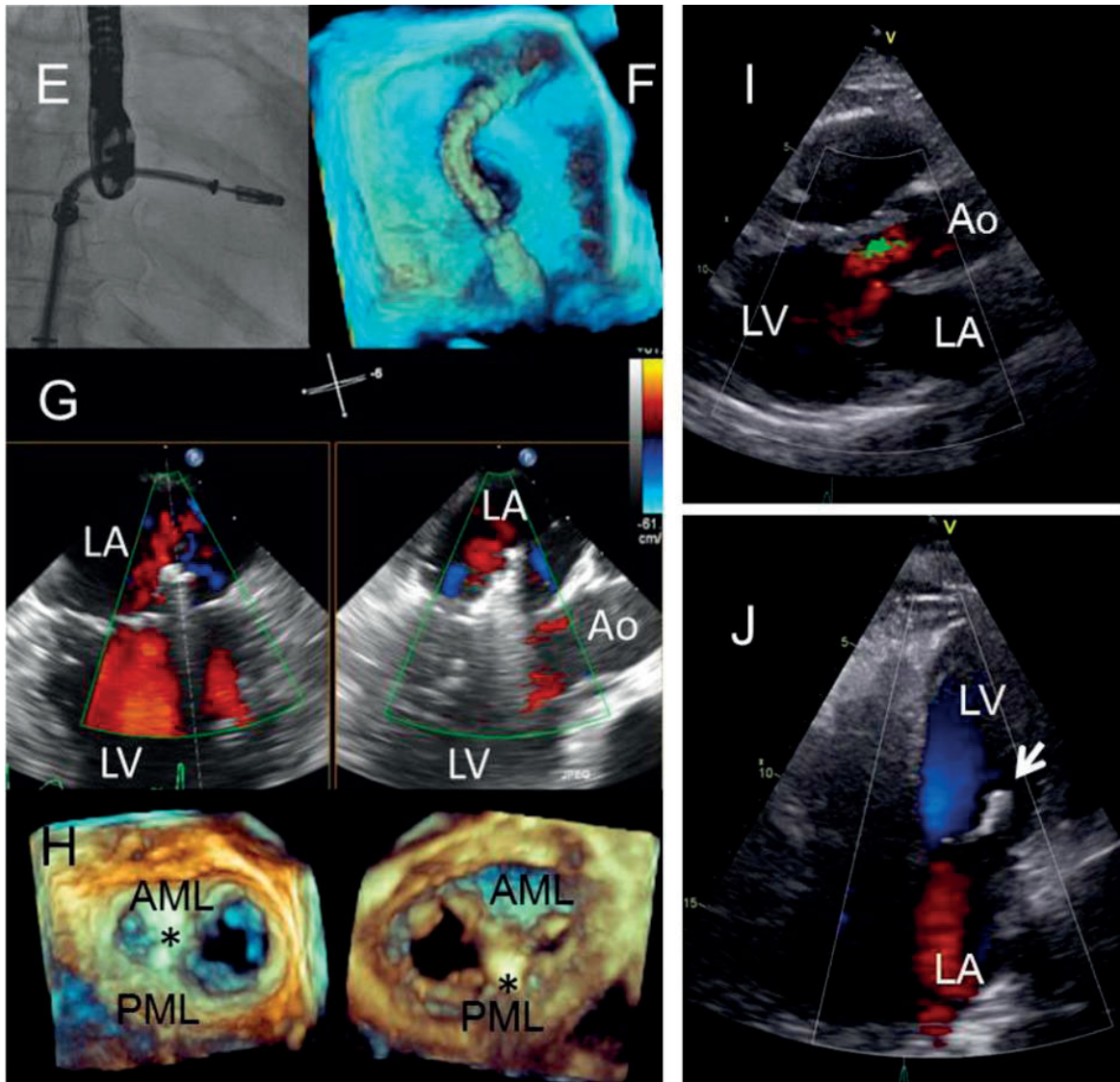
The postoperative evolution was uneventful and the patient was discharged at the fourth post-procedure day. At one month follow-up, transthoracic echocardiography showed a stable position of the Mitraclip device with no mitral regurgitation (Figure 1, panels I and J).

This is the first case report on the safety and efficacy of transcatheter mitral valve implantation in a patient with osteogenesis imperfecta. Current literature is limited to several case reports describing the feasibility of surgical mitral valve repair/replacement in this subgroup of patients. [2] Bleeding is the complication most frequently described and the intra-hospital mortality rate is not significant. Of note,

the patient will be followed-up for eventual progression of the aortic regurgitation. If symptomatic, transcatheter aortic valve implantation seems a promising therapy for these patients. [4] Novel transcatheter technologies may be safe and feasible alternatives to surgery in high risk subpopulations such as patients with osteogenesis imperfecta who, although not having an increased logistic EuroSCORE, show an increased frailty.

**Figure 1.** Panels A-B: Pre-procedural transthoracic echocardiography shows moderate to severe mitral regurgitation (arrow) and moderate aortic regurgitation at the anterolateral level. Panels C-D: Transoesophageal echocardiography shows the origin of the mitral regurgitant jet at the anterolateral level (A1-P1)(arrow) and the 3D reconstruction of the mitral valve showing the left atrial view indicates the regurgitant orifice at that level. Panels E-H: Peri-procedural imaging: The poor soft-tissue resolution of the fluoroscopy demands the use of transoesophageal echocardiography to guide the procedure and set the anatomical landmarks. Full volume reconstructions obtained during 3D transoesophageal echocardiography permit visualisation of the guiding catheter crossing the interatrial septum and directing the Mitraclip towards the mitral valve. In addition, simultaneous biplane reconstructions permit evaluation of the grasping of the mitral leaflets by the device. Three-dimensional reconstructions of the mitral valve allow evaluation of the final results with the mitral leaflets grasped by the device creating a double orifice mitral valve (seen from the left atrium and left ventricle). Panels I-J: Transthoracic echocardiography at 1 month follow-up shows no mitral valve regurgitation.





Abbreviations: AML: anterior mitral leaflet; Ao: aorta; LA: left atrium; LV: left ventricle; PML: posterior mitral leaflet.

## REFERENCES

1. Z. Radunovic, L.L. Wekre, L.M. Diep, K. Steine **Cardiovascular abnormalities in adults with osteogenesis imperfecta** Am Heart J, 161 (3) (2011), pp. 523-529
2. A. Lamanna, T. Fayers, S. Clarke, W. Parsonage **Valvular and aortic diseases in osteogenesis imperfecta** Heart Lung Circ, 22 (10) (2013), pp. 801-810
3. B.M. Siegel, L.A. Friedman, S.O. Schwartz **Hemorrhagic disease in osteogenesis imperfecta; study of platelet functional defect** Am J Med, 22 (2) (1957), pp. 315-321
4. D.A. Roy, U. Schaefer, V. Guetta, D. Hildick-Smith, H. Mollmann, N. Dumonteil, *et al.* **Transcatheter aortic valve implantation for pure severe native aortic valve regurgitation.** J Am Coll Cardiol, 61 (15) (2013), pp. 1577-1584







# Chapter 6

---

## HOW SHOULD I TREAT?

**How should I treat recurrent concomitant para-ring and valvular mitral regurgitation after surgical mitral valve repair in a high-risk patient?**

EuroIntervention 2015;10:1488-1492

Philippe van Rosendael, MD; Frank van der Kley, MD; Bryan Martina, MD; Meindert Palmen, MD, PhD; Victoria Delgado\*, MD, PhD

*Department of Cardiothoracic Surgery and Cardiology, Leiden University Medical Center, Leiden, The Netherlands*



## CASE SUMMARY

**BACKGROUND:** A 74-year-old male with symptomatic severe recurrent mitral regurgitation after surgical mitral valve repair and high surgical risk was referred for transcatheter mitral valve-in-ring implantation.

**INVESTIGATION:** Two- and three-dimensional transoesophageal echocardiography, fluoroscopy.

**DIAGNOSIS:** After transapical deployment of a 26 mm SAPIEN XT (Edwards Lifesciences, Irvine, CA, USA) in a mitral ring (Physio II ring, size 30; Edwards Lifesciences) and removal of the guidewire, severe para-ring mitral regurgitation originating at the level of the posterior commissure was detected.

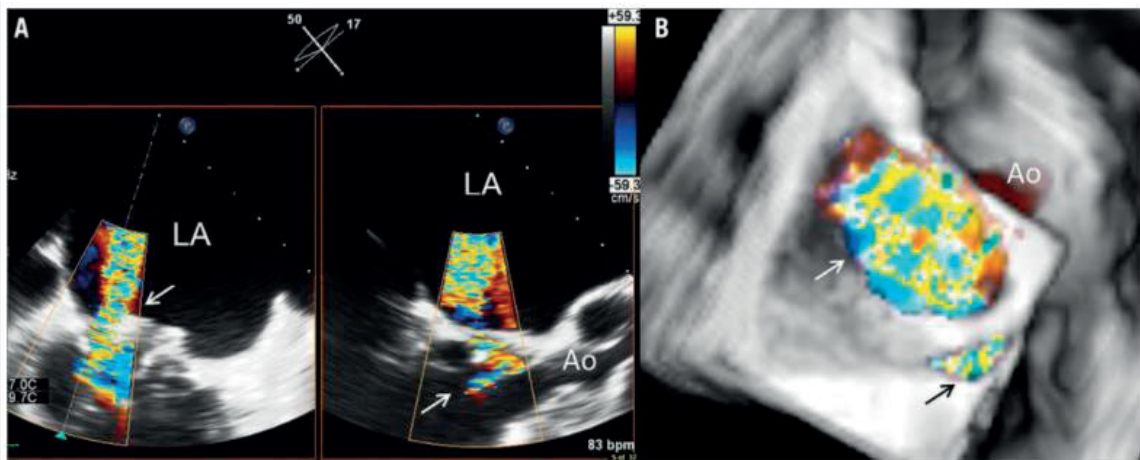
**MANAGEMENT:** A 6 mm AMPLATZER™ septal occluder system (St. Jude Medical, St. Paul, MN, USA) was implanted at the level of the para-ring dehiscence with significant reduction in para-ring mitral regurgitation. Transthoracic echocardiography pre-discharge showed a mean transmitral gradient of 7 mmHg and minimal mitral regurgitation.

**KEYWORDS:** structural heart interventions, transcatheter mitral valve replacement, valve-in-valve, valvular heart disease

## PRESENTATION OF THE CASE

A 74-year-old male with chronic atrial fibrillation, three-vessel coronary artery disease revascularised with coronary artery bypass grafting in 1997, and progressive symptomatic moderate to severe functional mitral regurgitation after inferior myocardial infarction in 2005 underwent transcatheter mitral valve repair in 2012 based on relatively high operative risk (logistic EuroSCORE of 13.9%). Associated comorbidities included chronic kidney disease and a prior cerebrovascular accident. Two MitraClips (Abbott Vascular, Santa Clara, CA, USA) were implanted at A2-P2 and A3-P3 levels of the mitral valve leaving the mitral valve without causing stenosis. At six-month follow-up, the patient presented with New York Heart Association (NYHA) functional Class III heart failure symptoms and recurrent severe mitral regurgitation was diagnosed on transthoracic colour Doppler echocardiography. The transoesophageal echocardiography (TEE) showed moderate to severe mitral regurgitation with two regurgitant jets between the two, well attached, MitraClips

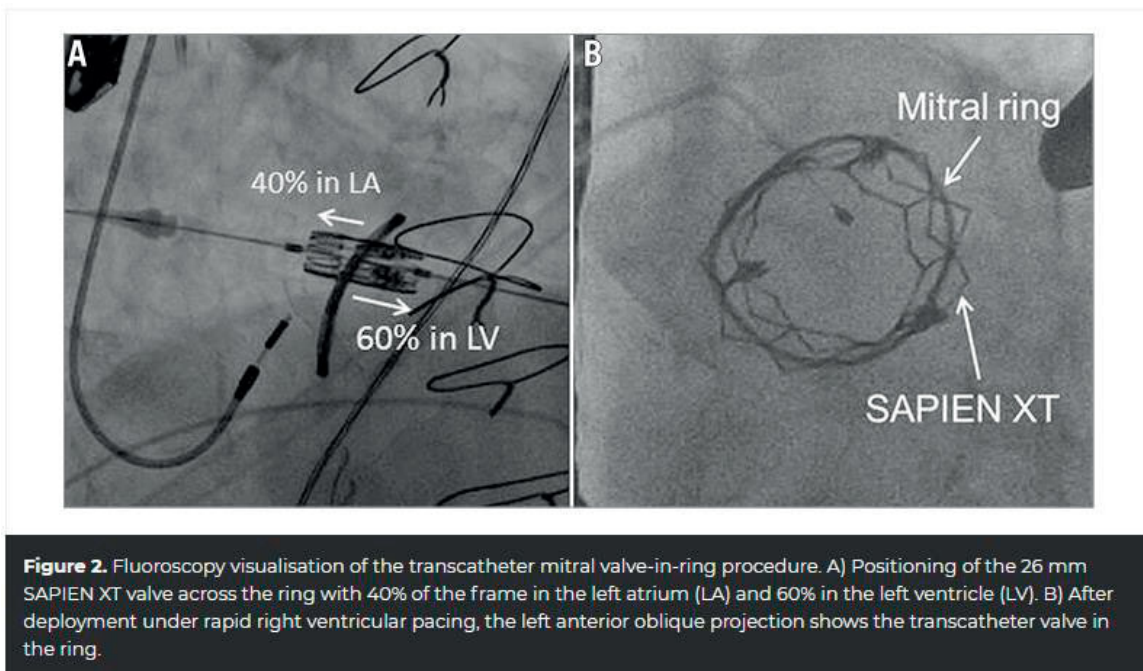
and between the device positioned at A3-P3 and the posterior commissure. The patient underwent surgical mitral valve repair and the direct surgical inspection of the mitral valve revealed a failed gripping of the MitraClip at the A3-P3 location caused by a severely calcified posterior mitral leaflet body and the lack of sufficient posterior leaflet tissue in that area. After removal of both clips, mitral annuloplasty was performed using a semi-rigid Physio II ring (model 5200, size 30L; Edwards Lifesciences, Irvine, CA, USA). Intraoperative TEE demonstrated a successful repair with no residual mitral regurgitation and a mean inflow gradient of 2.7 mmHg. However, at four-month follow-up, the patient was re-hospitalised with acute pulmonary oedema and remained in NYHA functional Class III afterwards, despite optimal medical treatment. Transthoracic echocardiography showed a non-dilated left ventricle with moderate reduction in ejection fraction (45%) and severe mitral valve regurgitation with restricted posterior mitral leaflet and broad vena contracta along the medial and posterior coaptation line. The mean gradient through the mitral valve was 3.8 mmHg and the estimated pulmonary pressure was 59 mmHg. The TEE showed the regurgitant jet impinging on the posterior annulus and small dehiscence at the level of the posterior commissure (Figure 1, Moving image 1-Moving image 3). Endocarditis, as a potential mechanism of recurrent mitral regurgitation, was excluded.



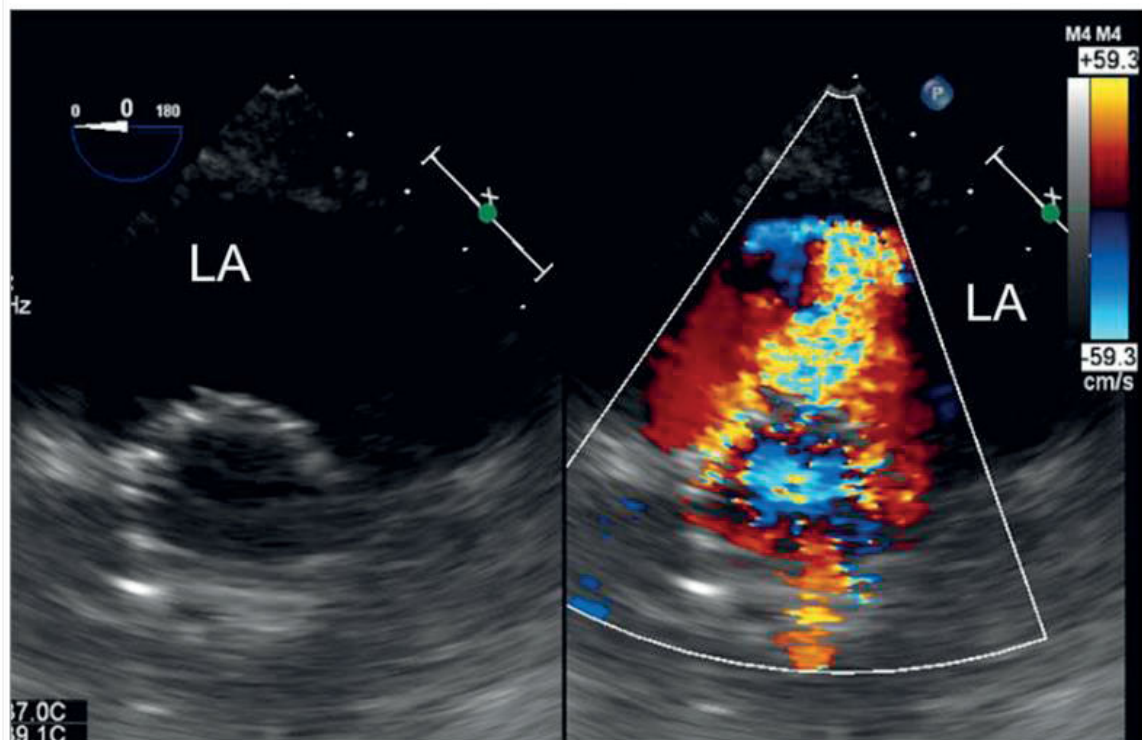
**Figure 1.** Three-dimensional transoesophageal echocardiography. A) Biplane view of the para-ring dehiscence with the regurgitant jet through the valve (arrow) in the right panel and the orthogonal view in the left panel showing the central regurgitant jet impinging on the ring. B) Three-dimensional reconstruction with an en face view of the ring. The central regurgitant jet through the valve (white arrow) can be observed together with the regurgitant jet through the para-ring dehiscence at the level of the posterior commissure (black arrow). Ao: aorta; LA: left atrium

Based on the associated comorbidities (chronic kidney disease and prior cerebrovascular accident), multiple cardiac surgical interventions (coronary artery bypass grafting and mitral valve repair) and the calculated logistic EuroSCORE of 24.8%, the Heart Team considered transcatheter mitral valve-in-ring the least invasive and most suitable treatment for this patient.

The procedure was performed under general anaesthesia assisted by fluoroscopic and two- and three-dimensional TEE guidance (EPIQ; Philips Medical Systems, Andover, MA, USA) equipped with a fully sampled matrix-array TEE transducer (X7-2t Live 3D-TEE transducer; Philips Medical Systems). Right femoral arterial access was obtained for continuous arterial pressure monitoring in the aorta and right femoral venous access for positioning of a temporary pacemaker wire using 7 Fr and 6 Fr sheaths, respectively. Through a left mini-thoracotomy, the left ventricular apex was exposed and purse-string suture was performed. A J guide was advanced through the mitral ring and positioned in the right inferior pulmonary vein. Next, the J guide was exchanged for an Amplatz 0.035" extra stiff wire (Cook Medical, Bloomington, IN, USA) followed by the introduction of a 24 Fr Ascendra sheath (Edwards Lifesciences) in the left ventricle. Subsequently, the mitral valve ring was ballooned under rapid right ventricular pacing with a 20×30 mm balloon (Ascendra Balloon Aortic Valvuloplasty Catheter; Edwards Lifesciences). Thereafter, the SAPIEN XT 26 mm (Edwards Lifesciences) was positioned across the mitral ring with 40% of the frame in the left atrium and 60% in the left ventricle and was deployed under rapid pacing (**Figure 2**). After removal of the Amplatz 0.035" extra stiff wire, colour Doppler TEE demonstrated the increase in mitral regurgitation originating from the dehiscence located at the posterior commissure (**Figure 3, Moving image 4, Moving image 5**).







**Figure 3.** Transgastric view of the deployed transcatheter valve and evaluation of the results. Immediately after removal of the wire, transgastric transoesophageal colour Doppler echocardiography showed severe mitral regurgitation at the level of the posterior commissure.

## HOW WOULD I TREAT?

### THE INVITED EXPERTS' OPINION

The simplest, safest and fastest approach is the immediate closure of the leak with an AMPLATZER™ Vascular Plug III (AVP III; St. Jude Medical, St. Paul, MN, USA) and the use of the transapical Ascendra sheath (Edwards Lifesciences, Irvine, CA, USA) that is already in place as the access route. The considerations behind this decision are the following. 1) The valvular regurgitant jet has been successfully treated with the Edwards SAPIEN XT 26 (Edwards Lifesciences) using the valve-in-ring approach and the posteromedial paravalvular jet has significantly increased thereafter. If any doubt exists about the significance of the paravalvular jet, more elaborate echocardiographic measurements (3D vena contracta area) should be performed immediately, and additional measurements such as measuring v-wave in the left atrium (via the Ascendra sheath and the Edwards SAPIEN XT valve) could be carried out. However, we do not consider the latter necessary. 2) The patient has undergone repeated procedures and therefore a staged procedure involving additional general anaesthesia is unfavourable. In particular, a repeat transapical access route would be considerably more difficult, although not impossible. Moreover, an antegrade,

transfemoral, and transseptal approach as a staged procedure does not offer any advantage and implies more limited steering capabilities. 3) All necessary staff and equipment are already present or available and the leak closure should be done within 30 minutes.

The mechanism behind the paravalvular regurgitant jet probably is that the Edwards Physio II ring had been sutured in soft not solid tissue in the posteromedial commissure, i.e., valve leaflet not fibrous annulus, which explains the tearing out of a few sutures (and valve tissue) only four months after ring implantation. At the time of Edwards SAPIEN XT valve-in-ring implantation and the resulting change into a more circular shape of the Physio II ring, two to three further sutures were torn out resulting in a significant increase in regurgitation. Yet despite this, an AVP III is considered safe when careful manipulation is performed.

The procedure in brief. Exact quantification of the short and long distance of the leak will be performed by colour Doppler imaging and the size of the AVP III will be selected accordingly. The leak will be crossed under fluoroscopy and 2D/3D TEE guidance via the Ascendra sheath with a standard 0.035'' hydrophilic plastic-coated guidewire using a 5 Fr multipurpose diagnostic catheter for steering. The multipurpose catheter will be advanced into the left atrium and the plastic guidewire will be exchanged for an Amplatz 0.035'' extra stiff wire (Cook Medical, Bloomington, IN, USA) followed by a 7 Fr or 9 Fr multipurpose guiding catheter as appropriate. The AVP III will be released by pushing the distal disc out of the sheath and pulling the sheath with the AVP III into the leak. Proper alignment of the long axis of the AVP III to the long axis of the leak can be well controlled by 3D echocardiography. The AVP III will be completely deployed by pulling back the sheath and sealing of the leak can be visualised immediately by colour Doppler imaging. After releasing the AVP III, removal of the Ascendra sheath and closure of the transapical access site will be performed as intended.

#### ***Conflict of interest statement***

W. Schillinger has received proctor and lecture fees and travel expenses from St. Jude Medical, Edwards Lifesciences, and Abbott Vascular. R.S. von Bardeleben has received proctor and lecture fees and/or travel expenses from Philips Healthcare, Siemens and Abbott Vascular.

## HOW WOULD I TREAT?

### THE INVITED EXPERTS' OPINION

The authors describe a very complex case of a patient who has undergone a series of complex structural valvular interventions. These included the use of two MitraClips (Abbott Vascular, Santa Clara, CA, USA) to repair functional mitral regurgitation (MR), followed by surgical annuloplasty for recurrent MR. The patient then suffered from recurrent MR again and this was shown on echocardiography to be due to two mechanisms: malcoaptation of valve leaflets and dehiscence of the ring at the posterior commissure. The use of the Edwards SAPIEN XT 26 mm valve (Edwards Lifesciences, Irvine, CA, USA) adequately treated the central MR that was due to leaflet malcoaptation. However, the MR arising from the ring dehiscence remained and appears to be significant.

We propose the following treatment. First, the residual MR should be assessed for defect morphology and size. On the basis of the limited echocardiographic images provided, it would appear that the MR is at least 3+ in severity. As the MR from the ring dehiscence is worse at the end of the valve-in-valve procedure, we would proceed to treat the residual MR at the same time. This would take advantage of the existing access from the apex and offer a favourable trajectory for wiring the paravalvular leak.

An important consideration is the sizing of the paravalvular leak. The authors describe the leak as extending to 25% of the valve circumference, suggesting that more than one device may be necessary to close the defect. We anticipate that two devices may be necessary. A guide catheter (e.g., multipurpose) with angled Terumo Glidewire® (Terumo Corp., Tokyo, Japan) can be used to cross the paravalvular leak. The positioning of the catheters and wire will have to be carefully guided by TEE to ensure that they do not impinge on the newly deployed SAPIEN valve. Using the guide catheter, an AMPLATZER™ Muscular VSD plug (St. Jude Medical, St. Paul, MN, USA) can be delivered across the defect. The sizing will depend on TEE estimates but we suspect a 14 mm waist diameter device may be suitable initially. The device can be assessed to ensure stability, to evaluate residual MR and also to ensure that the SAPIEN valve is not impinged upon or affected. Depending on the residual MR, a second device, probably a smaller plug such as an AMPLATZER™ Vascular Plug 4 (St. Jude Medical) may be used to occlude the residual MR. Again sizing will depend on TEE guidance.

A catheter is then advanced via a wire next to the AMPLATZER Muscular VSD plug. Care should be taken not to dislodge the first device. The Vascular Plug 4 can then be positioned next to the first plug. Again, TEE should be used to assess stability, residual MR and effect on the SAPIEN valve. Once stability, efficacy and safety have been verified, the vascular plug can be deployed. Patients should remain anticoagulated throughout the procedure.

### *Conflict of interest statement*

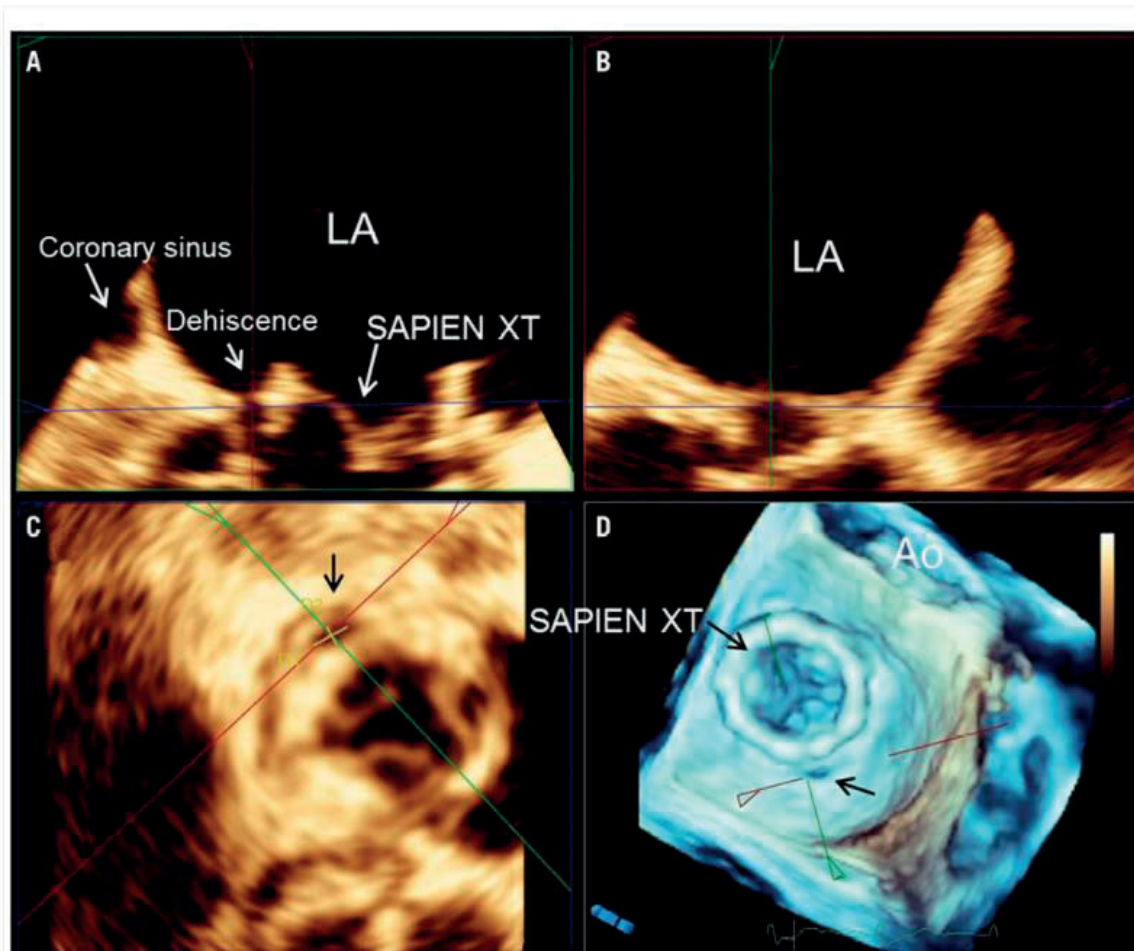
K.K. Yeo is a speaker for Abbott Vascular. The other authors have no conflicts of interest to declare.

## HOW DID I TREAT?

### ACTUAL TREATMENT AND MANAGEMENT OF THE CASE

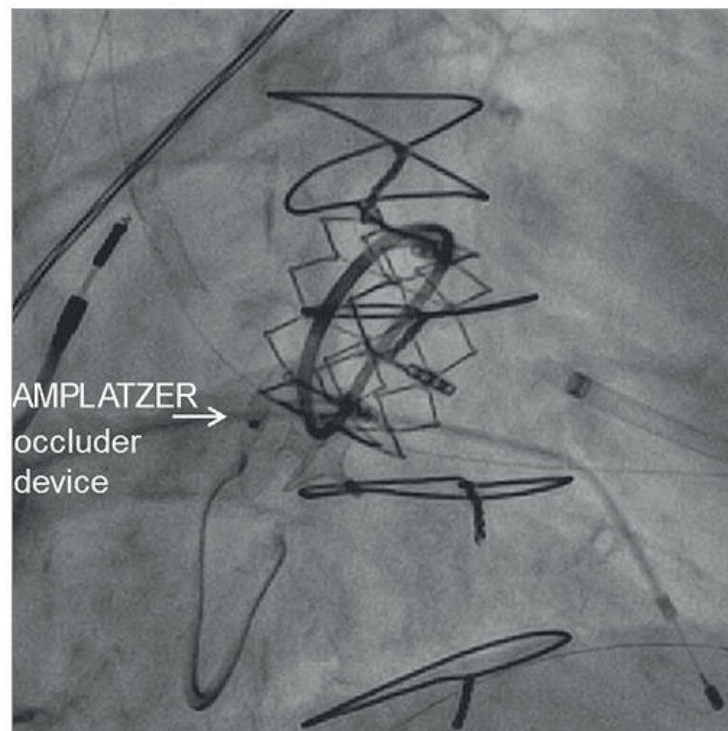
Severe para-ring mitral regurgitation left untreated may have important clinical prognostic implications and, therefore, conversion to surgical mitral valve replacement or transcatheter closure of the dehiscence was considered. Due to the high surgical risk, occlusion of the para-ring regurgitation using a transcatheter closure device was performed as bail-out manoeuvre. By aligning multiplanar reformation planes in the three-dimensional TEE images, an en face view parallel to the regurgitant orifice was reconstructed and in this view the size of the regurgitant orifice area was assessed (**Figure 4, Moving image 6**): 52 mm×39 mm. The left ventricular apex was partially closed and a 6 Fr sheath was reintroduced. With the support of a multipurpose catheter, a 0.038" J guide could be advanced through the para-ring regurgitation (**Moving image 7**) and a 0.014" BHW back-up wire was positioned next to it. By using a 6 Fr TorqVue™ 45° AMPLATZER™ delivery sheath, a 6 mm AMPLATZER™ septal occluder (St. Jude Medical, St. Paul, MN, USA) was implanted (**Moving image 8**): the first disc was deployed within the left atrium, just above the stent frame of the SAPIEN XT prosthesis, the waist was positioned at the level of the Physio II ring and the second disc just beneath the Physio II ring in the left ventricle (**Figure 5**). The regurgitant orifice was successfully occluded with residual mild para-ring regurgitation (**Figure 6, Moving image 9, Moving image 10**). The postoperative course was uneventful and the patient could be extubated within a few hours after the procedure. The transthoracic echocardiography performed before hospital discharge showed the stable position of the SAPIEN XT valve within the ring, with a mean gradient of 7 mmHg and minimal para-ring regurgitation.



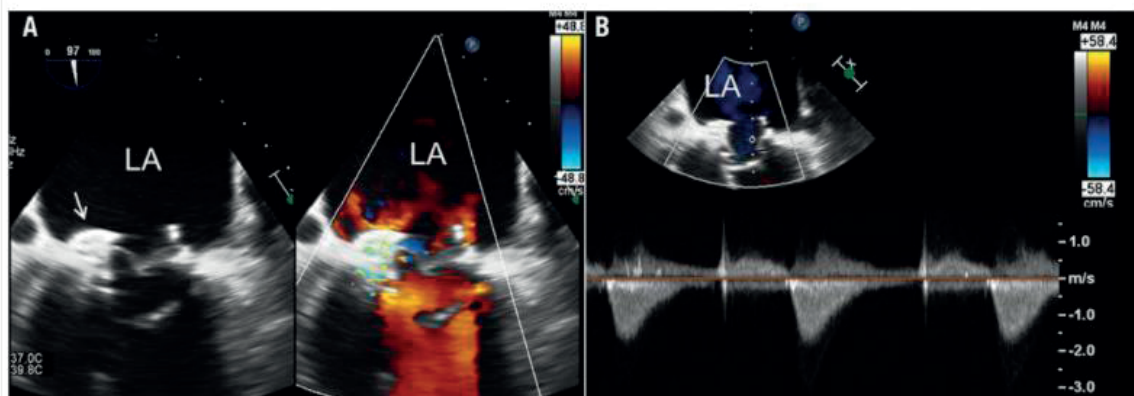


**Figure 4.** Three-dimensional multiplanar reformation planes across the para-ring dehiscence. By aligning multiplanar reformation planes across the dehiscence, the orthogonal long-axis views of the valve (A & B) and the transversal (C) views are shown. The en face view of the three-dimensional volume rendering with the crosshair through the dehiscence (D). The dimensions of the dehiscence can be obtained on the transversal view (C) in the three-dimensional transoesophageal echocardiography images.

Transcatheter valve-in-valve implantation has successfully become a feasible treatment option in patients with failed bioprostheses in aortic and mitral positions who are at high risk for redo surgery<sup>1</sup>. However, experience with transcatheter mitral valve implantation in a failed mitral valve ring annuloplasty is limited<sup>2-7</sup>. After a successful demonstration of the feasibility of implanting a 26 mm SAPIEN in a failed, 28 mm semi-rigid mitral Physio ring (Edwards Lifesciences, Irvine, CA, USA)<sup>2</sup>, this specific procedure has only been reported in case reports and small series<sup>3-7</sup>. Recently, Descoutures et al reported 17 high-risk patients with a failing surgical ring annuloplasty who underwent transcatheter mitral valve-in-ring implantation using a transvenous transseptal (n=8) or transapical approach (n=9)<sup>5</sup>. The procedural success rate was 88% and the 30-day survival was 82%, indicating that transcatheter valve-in-ring implantation is a feasible treatment option for these patients<sup>5</sup>. However, inappropriate deployment of the transcatheter valve within the ring (too high



**Figure 5.** Final position of the AMPLATZER occluder device. To occlude the para-ring regurgitation, a 6 mm AMPLATZER septal occluder was implanted: the first disc was deployed within the left atrium, just above the stent frame of the SAPIEN XT prosthesis, the waist was positioned at the level of the Physio II ring and the second disc beneath the Physio II ring within the left ventricle.



**Figure 6.** Evaluation of residual mitral regurgitation and haemodynamics of the valve-in-ring. A) On transoesophageal echocardiography the simultaneous visualisation of two-dimensional greyscale image and colour Doppler image permits the assessment of the position of the AMPLATZER occluder device and resolution of mitral regurgitation at the level of the para-ring dehiscence. B) Measurement of the transmitral gradient with continuous wave Doppler. At the end of the procedure, the regurgitant orifice was successfully occluded with residual mild para-ring regurgitation. The mean gradient was 7 mmHg.

in the atrium or too low in the ventricle) and acute ring detachment after prosthesis deployment may result in insufficient reduction of mitral regurgitation<sup>5</sup>. Bail-out strategies such as implantation of a second transcatheter valve or conversion to

open heart surgery may be needed. Transcatheter occlusion of paravalvular regurgitation in patients with dehiscence biological or mechanical mitral valve prostheses is a feasible and safe treatment in selected patients<sup>8</sup>. This is the first case report showing the feasibility of transcatheter occlusion of para-ring mitral regurgitation due to partial dehiscence of the ring after transcatheter valve-in-ring implantation.

## **Conclusion**

Mitral ring dehiscence may occur after a valve-in-ring procedure causing significant mitral regurgitation. Dehiscence closure with an atrial septal defect closure device is a feasible bail-out manoeuvre to treat para-ring mitral regurgitation.

## **FUNDING**

The Department of Cardiology received research grants from Biotronik, Medtronic, Boston Scientific, BMS Medical Imaging, Edwards Lifesciences, St. Jude Medical & GE Healthcare.

## **CONFLICT OF INTEREST STATEMENT**

V. Delgado has received consulting fees from Medtronic and St. Jude Medical. The other authors have no conflicts of interest to declare.

## **ONLINE DATA SUPPLEMENT**

**Moving image 1.** Colour Doppler transoesophageal echocardiography. Mid-oesophageal view of the mitral annuloplasty at 0° showing the four-chamber views. The failure of coaptation between the anterior and posterior mitral leaflets leads to a severe regurgitation through the valve. The regurgitant jet impinges on the posterior annulus.

**Moving image 2.** Colour Doppler biplane view of the para-ring dehiscence. With three-dimensional transoesophageal echocardiography, the biplane view of the mitral valve permits simultaneous visualisation of the regurgitant jet through the para-ring dehiscence in two orthogonal views.



**Moving image 3.** Colour Doppler three-dimensional echocardiography. En face view of the mitral valve from the left atrial perspective. Colour Doppler data show the regurgitant jet through the valve and through the para-ring dehiscence located at the level of the posterior commissure.

**Moving image 4.** Simultaneous visualisation of two-dimensional greyscale and colour Doppler data of the mitral valve after deployment of the 26 mm SAPIEN XT valve. The normal function of the deployed transcatheter valve can be visualised with good coaptation of the leaflets and no regurgitation through it. However, the colour Doppler data show a significant regurgitation through the para-ring dehiscence.

**Moving image 5.** Simultaneous visualisation of two-dimensional greyscale and colour Doppler data of the mitral valve from a transgastric view. This view permits visualisation of the location and extent of the para-ring dehiscence. On colour Doppler data, 25% of the circumference of the valve is occupied by the regurgitant jet.

**Moving image 6.** Three-dimensional transoesophageal echocardiography. En face view of the mitral valve annuloplasty with the SAPIEN XT valve deployed. The para-ring dehiscence is located at the level of the posterior commissure.

**Moving image 7.** Three-dimensional transoesophageal echocardiography showing the guidewire through the para-ring dehiscence.

**Moving image 8.** Deployment of the AMPLATZER occluder device under three-dimensional transoesophageal echocardiography.

**Moving image 9.** Simultaneous visualisation of two-dimensional greyscale and colour Doppler data of the mitral valve from a transgastric view after deployment of the AMPLATZER occluder device. Note the significant reduction in para-ring regurgitation.

**Moving image 10.** Simultaneous visualisation of two-dimensional greyscale and colour Doppler data of the mitral valve after deployment of the AMPLATZER occluder device. Note the AMPLATZER occluder device with effective reduction of mitral regurgitation and the SAPIEN XT within the mitral ring with the native mitral valve leaflets beneath.

## REFERENCES

1. Gurvitch R, Cheung A, Ye J, Wood DA, Willson AB, Toggweiler S, Binder R, Webb JG. Transcatheter valve-in-valve implantation for failed surgical bioprosthetic valves. *J Am Coll Cardiol*. 2011;58:2196-209.
2. de Weger A, Ewe SH, Delgado V, Bax JJ. First-in-man implantation of a trans-catheter aortic valve in a mitral annuloplasty ring: novel treatment modality for failed mitral valve repair. *Eur J Cardiothorac Surg*. 2011;39:1054-6.
3. Hammerstingl C, Sinning JM, Schiller W, Buchbinder M, Nickenig G. Percutaneous implantation of a 26 mm Edwards SAPIEN-XT aortic valve prosthesis in a degenerated 30 mm mitral annuloplasty ring. *Eur Heart J*. 2013;34:1748.
4. Mazzitelli D, Bleiziffer S, Noebauer C, Ruge H, Mayr P, Opitz A, Tassani-Prell P, Schreiber C, Piazza N, Lange R. Transatrial antegrade approach for double mitral and tricuspid "valve-in-ring" implantation. *Ann Thorac Surg*. 2013;95:e25-7.
5. Descoutures F, Himbert D, Maisano F, Casselman F, De Weger A, Bodea O, Van der Kley F, Colombo A, Giannini C, Rein KA, De Bruyne B, Petronio AS, Dahle G, Alfieri O, Vahanian A. Transcatheter valve-in-ring implantation after failure of surgical mitral repair. *Eur J Cardiothorac Surg*. 2013;44:e8-15.
6. Himbert D, Descoutures F, Brochet E, Iung B, Detaint D, Messika-Zeitoun D, Alkhoder S, Mimoun L, Sordi M, Depoix JP, Ducrocq G, Nataf P, Vahanian A. Transvenous mitral valve replacement after failure of surgical ring annuloplasty. *J Am Coll Cardiol*. 2012;60:1205-6.
7. Wilbring M, Alexiou K, Tugtekin SM, Arzt S, Ibrahim K, Matschke K, Kappert U. Pushing the limits-further evolutions of transcatheter valve procedures in the mitral position, including valve-in-valve, valve-in-ring, and valve-in-native-ring. *J Thorac Cardiovasc Surg*. 2014;147:210-9.
8. Sorajja P, Cabalka AK, Hagler DJ, Rihal CS. Percutaneous repair of paravalvular prosthetic regurgitation: acute and 30-day outcomes in 115 patients. *Circ Cardiovasc Interv*. 2011; 4:314-21.





---

## **Conclusions and future perspectives**







## Chapter 1

Accurate visualization of different cardiac structures is mandatory to maximize the success rate of current catheter-based intervention procedures. Recent advances in cardiac imaging modalities such as real-time 3D TEE, MDCT, or MRI have significantly improved the visualization and characterization of cardiac structures and have facilitated the dissemination of several transcatheter procedures. Some procedures are challenging and require high experience. However, the combination of fluoroscopy and, most frequently, echocardiography yields an accurate procedural guidance to achieve the highest success rate with the lowest complication rates. Current catheterization laboratories may evolve to hybrid operating rooms with sufficient space to hold multimodality imaging capabilities (3D echocardiography, MDCT, and MRI). This is particularly of interest in the emerging field of transcatheter valve implantation. However, other procedures such as transcatheter closure of perimembranous VSD may be facilitated by novel image-fusion technologies that require MRI or MDCT. Ongoing research will provide novel tools to increase the number of catheter-based procedures to treat several structural heart diseases that remain currently in the surgery domain.

In **Chapter 2** procedural outcomes and long-term survival were compared in two age-based groups (80 years old and younger versus >80 years). The results of the present single center study showed that age is not associated with outcomes after TAVI. This is in line with other registries and eventually randomized controlled trials showed that TAVI is effective in young patients with low operative risk (PARTNER-3 trial for example). These studies have been pivotal for the development of new practice guidelines where age is the main factor to select surgical versus transcatheter aortic valve replacement, such as the AHA/ACC guidelines. The rationale behind this change is that the life-expectancy versus the durability of the valve should be considered rather than just the operative risk.

In **Chapter 3**, timing of percutaneous coronary intervention (PCI) prior to transcatheter aortic valve implantation (TAVI) was evaluated. PCI performed within less than 30 days prior to TAVI resulted in more frequent minor bleedings and overall vascular injury compared to patients with a longer interval between PCI and TAVI. Furthermore, no differences in the incidence of other events and in 2-year survival were reported. This has resulted in a change in the management of patients with severe aortic stenosis and significant coronary artery disease who are candidates for TAVI. Currently, we use transradial access for PCI, which results in less vascular complications and bleedings, and the PCI if needed is preferably performed at least 30 days before TAVI.

**Chapter 4** investigates a practical prediction model for the risk of residual tricuspid regurgitation (TR) after percutaneous ASD closure. TR significantly improved in some patients despite significant TR at baseline, and moderate/severe TR post-closure is best predicted by the combination of age, right atrial size, right ventricular systolic pressure, and the extent of right ventricular dysfunction. This model may help identify a subgroup of patients in whom TR reduction after closure of the atrial septum defect is unlikely and therefore, surgical tricuspid valve repair and ASD closure would be preferable.


Clinical cases are described in chapters 5 and 6 to discuss implementation of new transcatheter interventions in challenging structural heart diseases who are not included in randomized clinical trials. In **chapter 5** describes the outcomes of transcatheter mitral valve repair in a patient with osteogenesis imperfecta. In osteogenesis imperfecta bleeding risks are high and wound healing process is impaired. Therefore, surgical intervention of mitral valve regurgitation can be associated with many complications during and after surgery. We concluded that transcatheter mitral valve repair is feasible, safe and effective in patients with osteogenesis imperfecta and associated symptomatic significant mitral regurgitation. In **chapter 6** a complex transcatheter valve implantation in a failed mitral annuloplasty with complete ring is complicated by a severe paravalvular leakage. In this How-to-treat case report an important learning message is provided by the operator and two independent experts. They explained how they would treat the unexpected problems. We concluded that mitral ring dehiscence may occur after a valve-in-ring procedure causing significant mitral regurgitation. Dehiscence closure with an atrial septal defect closure device is a feasible bail-out maneuver to treat para-ring mitral regurgitation.





---

## Samenvatting en toekomstperspectieven





## Hoofdstuk 1

Nauwkeurige visualisatie van verschillende cardiale structuren is essentieel om het succespercentage van de transcatheter interventieprocedures te maximaliseren. Huidige verbeteringen in cardiale beeldvormingsmodaliteiten zoals real-time 3D TEE, MDCT of MRI hebben de visualisatie en karakterisering van hartstructuren aanzienlijk verbeterd en hebben daarmee de verspreiding van verschillende transcatheterprocedures vergemakkelijkt. Sommige procedures zijn uitdagend en vereisen veel ervaring. De combinatie van fluoroscopie en echocardiografie levert echter een nauwkeurige procedurele begeleiding op om het hoogste slagingspercentage te bereiken met de laagste complicaties. De huidige katheterisatielaboratoria worden frequenter omgebouwd naar hybride operatiekamers met voldoende ruimte voor multimodale beeldvormingsmogelijkheden (3D-echocardiografie, MDCT en MRI). Dit is met name van belang bij implantatie van transkatheterkleppen. Andere procedures, zoals transcatheter-sluiting van atrium of ventrikel septum defect, kunnen echter worden vergemakkelijkt door nieuwe beeldfusietechnologieën (MRI of MDCT). Lopend onderzoek zal nieuwe technieken opleveren om het aantal transcatheter procedures te verhogen voor de behandeling van diverse structurele hartaandoeningen die momenteel nog in het domein van de chirurgie blijven.

In **Hoofdstuk 2** werden de procedurele uitkomsten en overleving op lange termijn vergeleken tussen twee leeftijdsgroepen (80 jaar en jonger versus > 80 jaar). De resultaten van deze single center-studie toonden aan dat leeftijd niet geassocieerd is met uitkomsten na TAVI. Dit is in lijn met andere registraties en uiteindelijk hebben gerandomiseerde gecontroleerde onderzoeken aangetoond dat TAVI effectief is bij jonge patiënten met een laag operatierisico (PARTNER-3-onderzoek voor voorbeeld). Deze onderzoeken zijn cruciaal geweest voor de ontwikkeling van nieuwe richtlijnen waarbij leeftijd de belangrijkste factor is bij het selecteren van chirurgische versus transkatheter aortaklepvervanging, zoals de AHA / ACC-richtlijnen. De grondgedachte achter deze verandering is dat de levensverwachting van patiënten versus de duurzaamheid van de klep moet worden overwogen in plaats van alleen het operationele risico.

In **Hoofdstuk 3** werd de timing van percutane coronaire interventie (PCI) voorafgaand aan transcatheter aortaklep implantatie (TAVI) geëvalueerd. Wanneer een PCI werd uitgevoerd binnen 30 dagen voorafgaand aan TAVI resulteerde dit in frequentere kleine bloedingen en letsel van de vasculaire toegang in vergelijking met patiënten met een langer interval tussen PCI en TAVI. Er werden geen verschillen in de incidentie van andere uitkomstparameters en in 2-jaars overleving gerapporteerd. Dit heeft geleid tot een verandering in de behandeling van patiënten met



ernstige aortastenose en significante coronaire hartziekte die in aanmerking komen voor TAVI. Momenteel gebruiken we vooral de transradiale toegang voor PCI, wat resulteert in minder vasculaire complicaties en bloedingen. Daarnaast heeft het de voorkeur een PCI tenminste 30 dagen voorafgaand aan de TAVI te verrichten.

**Hoofdstuk 4** onderzoekt een praktisch model voor het risico van resterende tricuspidalis insufficiëntie (TI) na percutane sluiting van een atrium septum defect (ASD) te voorspellen. De ernst van de tricuspidalisklep insufficiëntie verbeterde significant bij sommige patiënten ondanks significante TI voor aanvang van de ASD sluiting. Matige / ernstige TI na ASD sluiting wordt het best voorspeld door de combinatie van leeftijd, rechter atrium grootte, rechterventrikel systolische druk en de mate van rechterventrikeldysfunctie. Dit model kan helpen om een subgroep van patiënten te identificeren bij wie afname van tricuspidalis insufficiëntie na sluiting van het atriale septumdefect onwaarschijnlijk is. In deze groep zou chirurgische tricuspidalisklepplastiek en ASD-sluiting de voorkeur hebben.


Klinische cases worden beschreven in hoofdstuk 5 en 6 om de implementatie van nieuwe transkatheterinterventies te bespreken bij uitdagende structurele hartaandoeningen die niet zijn opgenomen in gerandomiseerde klinische onderzoeken. In **hoofdstuk 5** worden de resultaten beschreven van transkatheter mitralisklepplastiek bij een patiënt met osteogenesis imperfecta. Bij osteogenesis imperfecta is het bloedingsrisico hoog en is het wondgenezingsproces verstoord. Daarom kan chirurgische ingreep van de mitralisklep insufficiëntie gepaard gaan met vele complicaties tijdens en na de operatie. We concludeerden dat herstel van de mitralisklepinsufficiëntie door middel van transkatheter technieken haalbaar, veilig en effectief is bij patiënten met osteogenesis imperfecta. In **hoofdstuk 6** wordt een transkatheterklepimplantatie in de mitralispositie, na eerdere mislukte mitralisklep annuloplastiek met volledige ring, gecompliceerd door een ernstige paravalvulaire lekkage. In dit How-to-treat casusrapport wordt een belangrijke boodschap gegeven. De casus wordt besproken door de operator, maar ook door twee onafhankelijke experts. Ze legden uit hoe ze de onverwachte problemen zouden aanpakken. We concludeerden dat dehiscentie van de mitralisklepring kan optreden na een klep-in-ring procedure, waardoor een significante (para ring) mitralisklep insufficiëntie kan ontstaan. De insufficiëntie ten gevolge van de dehiscentie kan gesloten worden met een atrium septum closure device.





---

## **Publications**





1: Fortuni F, van der Kley F, Delgado V, Ajmone Marsan N. Pacemaker lead-induced tricuspid regurgitation: consider leaflet remodeling. *Int J Cardiovasc Imaging*. 2021 Jan 27. doi: 10.1007/s10554-020-02131-w. Epub ahead of print. PMID: 33502655.

2: Fortuni F, Butcher SC, van der Kley F, Lustosa RP, Karalis I, de Weger A, Priori SG, van der Bijl P, Bax JJ, Delgado V, Ajmone Marsan N. Left Ventricular Myocardial Work in Patients with Severe Aortic Stenosis. *J Am Soc Echocardiogr*. 2020 Nov 9:S0894-7317(20)30714-8. doi: 10.1016/j.echo.2020.10.014. Epub ahead of print. PMID: 33181281.

3: Brouwer J, Nijenhuis VJ, Delewi R, Hermanides RS, Holvoet W, Dubois CLF, Frambach P, De Bruyne B, van Houwelingen GK, Van Der Heyden JAS, Toušek P, van der Kley F, Buyschaert I, Schotborgh CE, Ferdinande B, van der Harst P, Roosen J, Peper J, Thielen FWF, Veenstra L, Chan Pin Yin DRPP, Swaans MJ, Rensing BJWM, van 't Hof AWJ, Timmers L, Kelder JC, Stella PR, Baan J, Ten Berg JM. Aspirin with or without Clopidogrel after Transcatheter Aortic-Valve Implantation. *N Engl J Med*. 2020 Oct 8;383(15):1447-1457. doi: 10.1056/NEJMoa2017815. Epub 2020 Aug 30. PMID: 32865376.

4: Spence MS, Baan J, Iacovelli F, Martinelli GL, Muir DF, Saia F, Bortone AS, Densem CG, Owens CG, van der Kley F, Vis M, van Mourik MS, Costa G, Sykorova L, Lüske CM, Deutsch C, Kurucova J, Thoenes M, Bramlage P, Tamburino C, Barbanti M. Pre-specified Risk Criteria Facilitate Adequate Discharge and Long-Term Outcomes After Transfemoral Transcatheter Aortic Valve Implantation. *J Am Heart Assoc*. 2020 Aug 4;9(15):e016990. doi: 10.1161/JAHA.120.016990. Epub 2020 Jul 25. PMID: 32715844; PMCID: PMC7792272.

05: Fortuni F, van der Kley F, Ajmone Marsan N, Delgado V. Computed tomography-derived transesophageal echocardiographic views for pre-procedural planning of direct transcatheter mitral valve annuloplasty. *EuroIntervention*. 2020 Jul 7;EIJ-D-20-00649. doi: 10.4244/EIJ-D-20-00649. Epub ahead of print. PMID: 32624463.

6: Nijenhuis VJ, Brouwer J, Delewi R, Hermanides RS, Holvoet W, Dubois CLF, Frambach P, De Bruyne B, van Houwelingen GK, Van Der Heyden JAS, Toušek P, van der Kley F, Buyschaert I, Schotborgh CE, Ferdinande B, van der Harst P, Roosen J, Peper J, Thielen FWF, Veenstra L, Chan Pin Yin DRPP, Swaans MJ, Rensing BJWM, van 't Hof AWJ, Timmers L, Kelder JC, Stella PR, Baan J, Ten Berg JM. Anticoagulation with or without Clopidogrel after Transcatheter Aortic-Valve Implantation. *N Engl J*

Med. 2020 Apr 30;382(18):1696-1707. doi: 10.1056/NEJMoa1915152. Epub 2020 Mar 29. PMID: 32223116.

7: Gegenava T, van der Bijl P, Vollema EM, van der Kley F, de Weger A, Hautemann D, Reiber JHC, Ajmone Marsan N, Bax JJ, Delgado V. Prognostic Influence of Feature Tracking Multidetector Row Computed Tomography-Derived Left Ventricular Global Longitudinal Strain in Patients with Aortic Stenosis Treated With Transcatheter Aortic Valve Implantation. *Am J Cardiol.* 2020 Mar 15;125(6):948-955. doi: 10.1016/j.amjcard.2019.12.024. Epub 2019 Dec 27. PMID: 31928719.

8: Gegenava T, van der Bijl P, Hirasawa K, Vollema EM, van Rosendael A, van der Kley F, de Weger A, Hautemann DJ, Reiber JHC, Ajmone Marsan N, Bax JJ, Delgado V. Feature tracking computed tomography-derived left ventricular global longitudinal strain in patients with aortic stenosis: a comparative analysis with echocardiographic measurements. *J Cardiovasc Comput Tomogr.* 2020 May- Jun;14(3):240-245. doi: 10.1016/j.jcct.2019.11.004. Epub 2019 Dec 1. PMID: 31812459.

9: Dolci G, Vollema EM, van der Kley F, de Weger A, Ajmone Marsan N, Delgado V, Bax JJ. One-Year Follow-Up of Conduction Abnormalities After Transcatheter Aortic Valve Implantation With the SAPIEN 3 Valve. *Am J Cardiol.* 2019 Oct 15;124(8):1239-1245. doi: 10.1016/j.amjcard.2019.07.035. Epub 2019 Jul 30. PMID: 31439281.

10: Gegenava T, Vollema EM, van Rosendael A, Abou R, Goedemans L, van der Kley F, de Weger A, Ajmone Marsan N, Bax JJ, Delgado V. Changes in Left Ventricular Global Longitudinal Strain after Transcatheter Aortic Valve Implantation according to Calcification Burden of the Thoracic Aorta. *J Am Soc Echocardiogr.* 2019 Sep;32(9):1058-1066.e2. doi: 10.1016/j.echo.2019.05.011. Epub 2019 Jul 13. PMID: 31311704.

11: Barbanti M, van Mourik MS, Spence MS, Iacovelli F, Martinelli GL, Muir DF, Saia F, Bortone AS, Densem CG, van der Kley F, Bramlage P, Vis M, Tamburino C. Optimising patient discharge management after transfemoral transcatheter aortic valve implantation: the multicentre European FAST-TAVI trial. *EuroIntervention.* 2019 Jun 20;15(2):147-154. doi: 10.4244/EIJ-D-18-01197. PMID: 30777842.

12: Huygens SA, van der Kley F, Bekkers JA, Bogers AJJC, Takkenberg JJM, Rutten-van Mülken MPMH. Beyond the clinical impact of aortic and pulmonary valve implantation: health-related quality of life, informal care and productivity†. *Eur J Cardiothorac Surg.* 2019 Apr 1;55(4):751-759. doi: 10.1093/ejcts/ezy382. PMID: 30496373.



- 13: Montero-Cabezas JM, van der Meer RW, van der Kley F, Elzo Kraemer CV, López Matta JE, SchaliJ MJ, de Weger A. Percutaneous Decannulation of Femoral Venous Arterial ECMO Cannulas Using MANTA Vascular Closure Device. *Can J Cardiol*. 2019 Jun;35(6):796.e9-796.e11. doi: 10.1016/j.cjca.2019.02.010. Epub 2019 Feb 21. PMID: 31151721.
- 14: Nassif M, van der Kley F, Abdelghani M, Kalkman DN, de Bruin-Bon RHACM, Bouma BJ, SchaliJ MJ, Koolbergen DR, Tijssen JGP, Mulder BJM, de Winter RJ. Predictors of residual tricuspid regurgitation after percutaneous closure of atrial septal defect. *Eur Heart J Cardiovasc Imaging*. 2019 Feb 1;20(2):225-232. doi: 10.1093/ehjci/jey080. PMID: 29905827.
- 15: Gegenava T, Vollema EM, Abou R, Goedemans L, van Rosendael A, van der Kley F, de Weger A, Ajmone Marsan N, Bax JJ, Delgado V. Prognostic Value of Thoracic Aorta Calcification Burden in Patients Treated With TAVR. *JACC Cardiovasc Imaging*. 2019 Jan;12(1):216-217. doi: 10.1016/j.jcmg.2018.08.030. Epub 2018 Nov 15. Erratum in: *JACC Cardiovasc Imaging*. 2019 May;12(5):953. PMID: 30448133.
- 16: Kamperidis V, van Wijngaarden SE, van Rosendael PJ, Kong WKF, Regeer MV, van der Kley F, Sianos G, Ajmone Marsan N, Bax JJ, Delgado V. Mitral valve repair for secondary mitral regurgitation in non-ischaemic dilated cardiomyopathy is associated with left ventricular reverse remodelling and increase of forward flow. *Eur Heart J Cardiovasc Imaging*. 2018 Feb 1;19(2):208-215. doi: 10.1093/ehjci/jex011. PMID: 28329173.
- 17: van Wijngaarden SE, Kamperidis V, Al-Amri I, van der Kley F, SchaliJ MJ, Ajmone Marsan N, Bax JJ, Delgado V. Effects of Transcatheter Mitral Valve Repair With MitraClip on Left Ventricular and Atrial Hemodynamic Load and Myocardial Wall Stress. *J Card Fail*. 2018 Mar;24(3):137-145. doi: 10.1016/j.cardfail.2017.12.008. Epub 2017 Dec 29. PMID: 29292112.
- 18: Podlesnikar T, Prihadi EA, van Rosendael PJ, Vollema EM, van der Kley F, de Weger A, Ajmone Marsan N, Naji F, Frasz Z, Bax JJ, Delgado V. Influence of the Quantity of Aortic Valve Calcium on the Agreement Between Automated 3-Dimensional Transesophageal Echocardiography and Multidetector Row Computed Tomography for Aortic Annulus Sizing. *Am J Cardiol*. 2018 Jan 1;121(1):86-93. doi: 10.1016/j.amjcard.2017.09.016. Epub 2017 Oct 10. PMID: 29096883.

19: Barbanti M, Baan J, Spence MS, Iacovelli F, Martinelli GL, Saia F, Bortone AS, van der Kley F, Muir DF, Densem CG, Vis M, van Mourik MS, Seilerova L, Lüske CM, Bramlage P, Tamburino C. Feasibility and safety of early discharge after transfemoral transcatheter aortic valve implantation - rationale and design of the FAST-TAVI registry. *BMC Cardiovasc Disord.* 2017 Oct 10;17(1):259. doi: 10.1186/s12872-017-0693-0. PMID: 29017461; PMCID: PMC5635502.

20: Debonnaire P, van der Kley F, Ajmone Marsan N, Delgado V. MitraClip improves mitral valve geometry in complex organic mitral regurgitation: insights from three-dimensional-echocardiography. *Eur Heart J.* 2017 Oct 7;38(38):2913. doi: 10.1093/eurheartj/ehw645. PMID: 28073864.

21: van Rosendael AR, Koning G, Dimitriu-Leen AC, Smit JM, Montero-Cabezas JM, van der Kley F, Jukema JW, Reiber JHC, Bax JJ, Scholte AJHA. Accuracy and reproducibility of fast fractional flow reserve computation from invasive coronary angiography. *Int J Cardiovasc Imaging.* 2017 Sep;33(9):1305-1312. doi: 10.1007/s10554-017-1190-3. Epub 2017 Jun 22. PMID: 28642995; PMCID: PMC5539270.

22: Vollema EM, Kong WKF, Katsanos S, Kamperidis V, van Rosendael PJ, van der Kley F, de Weger A, Ajmone Marsan N, Delgado V, Bax JJ. Transcatheter aortic valve thrombosis: the relation between hypo-attenuated leaflet thickening, abnormal valve haemodynamics, and stroke. *Eur Heart J.* 2017 Apr 21;38(16):1207-1217. doi: 10.1093/eurheartj/ehx031. PMID: 28369242.

23: van Rosendael PJ, Kamperidis V, Kong WK, van Rosendael AR, van der Kley F, Ajmone Marsan N, Delgado V, Bax JJ. Computed tomography for planning transcatheter tricuspid valve therapy. *Eur Heart J.* 2017 Mar 1;38(9):665-674. doi: 10.1093/eurheartj/ehw499. PMID: 27807057.

24: Regeer MV, Merkestein LR, de Weger A, Kamperidis V, van der Kley F, van Rosendael PJ, Marsan NA, Klautz RJ, Schalijs MJ, Bax JJ, Delgado V. Left bundle branch block after sutureless, transcatheter, and stented biological aortic valve replacement for aortic stenosis. *EuroIntervention.* 2017 Jan 20;12(13):1660-1666. doi: 10.4244/EIJ-D-15-00256. PMID: 28106000.

25: Gaede L, Di Bartolomeo R, van der Kley F, Elsässer A, Iung B, Möllmann H. Aortic valve stenosis: what do people know? A heart valve disease awareness survey of over 8,800 people aged 60 or over. *EuroIntervention.* 2016 Sep 18;12(7):883-9. doi: 10.4244/EIJY16M06\_02. PMID: 27283409.

- 26: Kong WK, van Rosendael PJ, van der Kley F, de Weger A, Kamperidis V, Regeer MV, Marsan NA, Bax JJ, Delgado V. Impact of Different Iterations of Devices and Degree of Aortic Valve Calcium on Paravalvular Regurgitation After Transcatheter Aortic Valve Implantation. *Am J Cardiol*. 2016 Aug 15;118(4):567-71. doi: 10.1016/j.amjcard.2016.05.053. Epub 2016 May 29. PMID: 27328953.
- 27: Al Amri I, Debonnaire P, van der Kley F, SchaliJ MJ, Bax JJ, Marsan NA, Delgado V. Acute effect of MitraClip implantation on mitral valve geometry in patients with functional mitral regurgitation: insights from three-dimensional transoesophageal echocardiography. *EuroIntervention*. 2016 Apr 20;11(13):1554-61. PMID: 27107264.
- 28: Al Amri I, Debonnaire P, van der Kley F, SchaliJ MJ, Bax JJ, Marsan NA, Delgado V. Acute effect of MitraClip implantation on mitral valve geometry in patients with functional mitral regurgitation: insights from three-dimensional transoesophageal echocardiography. *EuroIntervention*. 2016 Apr 20;11(13):1554-61. doi: 10.4244/EIJY15M09\_09. PMID: 26348680.
- 29: Tomšič A, Palmen M, Versteegh MI, van der Kley F, Siebelink HJ, Berendsen RR, SchaliJ MJ. Prosthesis Dislocation After Transapical Valve-In-Valve Mitral Valve Implantation. *Can J Cardiol*. 2016 Dec;32(12):1576.e7-1576.e9. doi: 10.1016/j.cjca.2016.03.006. Epub 2016 Mar 19. PMID: 27345607.
- 30: van der Kley F, van Rosendael PJ, Katsanos S, Kamperidis V, Marsan NA, Karalis I, de Weger A, Palmen M, Bax JJ, SchaliJ MJ, Delgado V. Impact of age on transcatheter aortic valve implantation outcomes: a comparison of patients aged  $\leq 80$  years versus patients  $> 80$  years. *J Geriatr Cardiol*. 2016 Jan;13(1):31-6. doi: 10.11909/j.issn.1671-5411.2016.01.004. PMID: 26918010; PMCID: PMC4753009.
- 31: Nijenhuis VJ, Bennaghmouch N, Hassell M, Baan J Jr, van Kuijk JP, Agostoni P, van 't Hof A, Kievit PC, Veenstra L, van der Harst P, van den Heuvel AF, den Heijer P, Kelder JC, Deneer VH, van der Kley F, Onorati F, Collet JP, Maisano F, Latib A, Huber K, Stella PR, Ten Berg JM. Rationale and design of POPular-TAVI: antiPlatelet therapy fOr Patients undergoing Transcatheter Aortic Valve Implantation. *Am Heart J*. 2016 Mar;173:77-85. doi: 10.1016/j.ahj.2015.11.008. Epub 2015 Dec 1. PMID: 26920599.
- 32: Montero-Cabezas JM, van der Kley F, Karalis I, SchaliJ MJ. The "De Winter Pattern" Can Progress to ST-segment Elevation Acute Coronary Syndrome. Response. *Rev Esp Cardiol (Engl Ed)*. 2015 Nov;68(11):1043. doi: 10.1016/j.rec.2015.08.004. Epub 2015 Sep 26. PMID: 26419579.

33: van Rosendaal PJ, Joyce E, Katsanos S, Debonnaire P, Kamperidis V, van der Kley F, Schalijs MJ, Bax JJ, Ajmone Marsan N, Delgado V. Tricuspid valve remodelling in functional tricuspid regurgitation: multidetector row computed tomography insights. *Eur Heart J Cardiovasc Imaging*. 2016 Jan;17(1):96-105. doi: 10.1093/ehjci/jev140. Epub 2015 Jun 9. PMID: 26060205.

34: Kamperidis V, van Rosendaal PJ, Katsanos S, van der Kley F, Regeer M, Al Amri I, Sianos G, Marsan NA, Delgado V, Bax JJ. Low gradient severe aortic stenosis with preserved ejection fraction: reclassification of severity by fusion of Doppler and computed tomographic data. *Eur Heart J*. 2015 Aug 14;36(31):2087-2096. doi: 10.1093/eurheartj/ehv188. Epub 2015 Jun 1. PMID: 26033985.

35: Montero-Cabezas JM, van-der-Kley F, Karalis I, Schalijs MJ. Proximal Left Anterior Descending Artery Acute Occlusion With an Unusual Electrocardiographic Pattern: Not Everything Is ST Elevation. *Rev Esp Cardiol (Engl Ed)*. 2015 Jun;68(6):541-3. doi: 10.1016/j.rec.2015.02.014. Epub 2015 May 7. PMID: 25957805.

36: Kamperidis V, van Rosendaal PJ, de Weger A, Katsanos S, Regeer M, van der Kley F, Mertens B, Sianos G, Ajmone Marsan N, Bax JJ, Delgado V. Surgical sutureless and transcatheter aortic valves: hemodynamic performance and clinical outcomes in propensity score-matched high-risk populations with severe aortic stenosis. *JACC Cardiovasc Interv*. 2015 Apr 27;8(5):670-7. doi: 10.1016/j.jcin.2014.10.029. PMID: 25946438.

37: van Rosendaal P, van der Kley F, Martina B, Palmes M, Delgado V, Schillinger W, von Bardeleben RS, Yeo KK, Ho KW, Jack Tan WC. How should I treat recurrent concomitant para-ring and valvular mitral regurgitation after surgical mitral valve repair in a high-risk patient? *EuroIntervention*. 2015 Apr;10(12):1488-92. doi: 10.4244/EIJY14M09\_02. PMID: 25244565.

38: van Rosendaal PJ, van der Kley F, Kamperidis V, Katsanos S, Al Amri I, Regeer M, Schalijs MJ, Ajmone Marsan N, Bax JJ, Delgado V. Timing of staged percutaneous coronary intervention before transcatheter aortic valve implantation. *Am J Cardiol*. 2015 Jun 15;115(12):1726-32. doi: 10.1016/j.amjcard.2015.03.019. Epub 2015 Mar 24. PMID: 25890631.

39: Al Amri I, van der Kley F, Schalijs MJ, Ajmone Marsan N, Delgado V. Transcatheter mitral valve repair therapies for primary and secondary mitral regurgitation. *Future Cardiol*. 2015 Mar;11(2):153-69. doi: 10.2217/fca.15.8. PMID: 25760875.

40: van Rosendael PJ, Kamperidis V, van der Kley F, Katsanos S, Al Amri I, Regeer MV, Schalij MJ, de Weger A, Marsan NA, Bax JJ, Delgado V. Atherosclerosis burden of the aortic valve and aorta and risk of acute kidney injury after transcatheter aortic valve implantation. *J Cardiovasc Comput Tomogr*. 2015 Mar- Apr;9(2):129-38. doi: 10.1016/j.jcct.2015.01.012. Epub 2015 Jan 26. PMID: 25819195.

41: Ewe SH, Muratori M, van der Kley F, Pepi M, Delgado V, Tamborini G, Fusini L, de Weger A, Gripari P, Bartorelli A, Bax JJ, Marsan NA. Effect of aortic regurgitation following transcatheter aortic valve implantation on outcomes. *Am J Cardiol*. 2015 Mar 1;115(5):664-9. doi: 10.1016/j.amjcard.2014.12.018. Epub 2014 Dec 18. PMID: 25591895.

42: Katsanos S, Debonnaire P, van der Kley F, van Rosendael PJ, Joyce E, de Graaf MA, Schalij MJ, Scholte AJ, Bax JJ, Ajmone Marsan N, Delgado V. Position of Edwards SAPIEN transcatheter valve in the aortic root in relation with the coronary ostia: implications for percutaneous coronary interventions. *Catheter Cardiovasc Interv*. 2015 Feb 15;85(3):480-7. doi: 10.1002/ccd.25718. Epub 2014 Nov 12. PMID: 25367809.

43: Debonnaire P, Fusini L, Wolterbeek R, Kamperidis V, van Rosendael P, van der Kley F, Katsanos S, Joyce E, Tamborini G, Muratori M, Gripari P, Bax JJ, Marsan NA, Pepi M, Delgado V. Value of the "TAVI2-SCORE" versus surgical risk scores for prediction of one year mortality in 511 patients who underwent transcatheter aortic valve implantation. *Am J Cardiol*. 2015 Jan 15;115(2):234-42. doi: 10.1016/j.amjcard.2014.10.029. Epub 2014 Oct 29. PMID: 25432413.

44: Kamperidis V, van Rosendael PJ, Ng AC, Katsanos S, van der Kley F, Debonnaire P, Joyce E, Sianos G, Marsan NA, Bax JJ, Delgado V. Impact of flow and left ventricular strain on outcome of patients with preserved left ventricular ejection fraction and low gradient severe aortic stenosis undergoing aortic valve replacement. *Am J Cardiol*. 2014 Dec 15;114(12):1875-81. doi: 10.1016/j.amjcard.2014.09.030. Epub 2014 Sep 28. PMID: 25438916.

45: Katsanos S, van Rosendael P, Kamperidis V, van der Kley F, Joyce E, Debonnaire P, Karalis I, Bax JJ, Marsan NA, Delgado V. Insights into new-onset rhythm conduction disorders detected by multi-detector row computed tomography after transcatheter aortic valve implantation. *Am J Cardiol*. 2014 Nov 15;114(10):1556-61. doi: 10.1016/j.amjcard.2014.08.020. Epub 2014 Aug 27. PMID: 25245414.

46: Katsanos S, van Rosendaal P, Kamperidis V, van der Kley F, Regeer M, Al-Amri I, Karalis I, Palmen M, de Weger A, Marsan NA, Bax JJ, Delgado V. Pericardial effusion following transcatheter aortic valve implantation: echocardiography and multi-detector row computed tomography evaluation. *Int J Cardiovasc Imaging*. 2015 Jan;31(1):37-43. doi: 10.1007/s10554-014-0520-y. Epub 2014 Aug 17. PMID: 25129473.

47: Kamperidis V, Joyce E, Debonnaire P, Katsanos S, van Rosendaal PJ, van der Kley F, Sianos G, Bax JJ, Ajmone Marsan N, Delgado V. Left ventricular functional recovery and remodeling in low-flow low-gradient severe aortic stenosis after transcatheter aortic valve implantation. *J Am Soc Echocardiogr*. 2014 Aug;27(8):817-25. doi: 10.1016/j.echo.2014.04.021. Epub 2014 Jun 3. PMID: 24906801.

48: van der Kley F, Delgado V, Ajmone Marsan N, SchaliJ MJ. Transcatheter mitral valve repair in osteogenesis imperfecta associated mitral valve regurgitation. *Heart Lung Circ*. 2014 Aug;23(8):e169-71. doi: 10.1016/j.hlc.2014.03.025. Epub 2014 Apr 2. PMID: 24791663.

49: Kamperidis V, van der Kley F, Katsanos S, Delgado V. CoreValve stent frame misdeployment and increased transvalvular gradient. *Eur Heart J Cardiovasc Imaging*. 2014 Jul;15(7):832. doi: 10.1093/ehjci/jeu005. Epub 2014 Feb 4. PMID: 24497519.

50: Nijenhuis VJ, Stella PR, Baan J, Brueren BR, de Jaegere PP, den Heijer P, Hofma SH, Kievit P, Slagboom T, van den Heuvel AF, van der Kley F, van Garsse L, van Houwelingen KG, Van't Hof AW, Ten Berg JM. Antithrombotic therapy in patients undergoing TAVI: an overview of Dutch hospitals. *Neth Heart J*. 2014 Feb;22(2):64-9. doi: 10.1007/s12471-013-0496-6. PMID: 24287807; PMCID: PMC3967563.

51: Nazeri I, Abdi S, Mandegar MH, Naemi S, Roshanali F, Tehrai M, Shahabi P, Debonnaire P, van der Kley F, Katsanos S, Delgado V, Van Mieghem NM. How should I treat acute left main coronary obstruction after transapical aortic valve implantation? *EuroIntervention*. 2013 Oct;9(6):761-4, 3 p following p764. doi: 10.4244/EIJV9I6A122. PMID: 24169138.

52: Katsanos S, Ewe SH, Debonnaire P, van der Kley F, de Weger A, Palmen M, Scholte AJ, SchaliJ MJ, Bax JJ, Marsan NA, Delgado V. Multidetector row computed tomography parameters associated with paravalvular regurgitation after transcatheter aortic valve implantation. *Am J Cardiol*. 2013 Dec 1;112(11):1800-6. doi: 10.1016/j.amjcard.2013.07.049. Epub 2013 Sep 13. PMID: 24035163.



- 53: Al Amri I, Debonnaire P, Witkowski T, van der Kley F, Palmen M, de Weger A, Klautz RJ, Bax JJ, Schalijs MJ, Ajmone Marsan N, Delgado V. Mitral valve geometry and hemodynamics after surgical mitral valve annuloplasty and implications for percutaneous treatment of patients with recurrent mitral regurgitation. *Am J Cardiol*. 2013 Sep 1;112(5):714-9. doi: 10.1016/j.amjcard.2013.04.044. Epub 2013 May 24. PMID: 23711814.
- 54: Katsanos S, Yiu KH, Clavel MA, Rodés-Cabau J, Leong D, van der Kley F, Ajmone Marsan N, Bax JJ, Pibarot P, Delgado V. Impact of valvuloarterial impedance on 2-year outcome of patients undergoing transcatheter aortic valve implantation. *J Am Soc Echocardiogr*. 2013 Jul;26(7):691-8. doi: 10.1016/j.echo.2013.04.003. Epub 2013 May 11. PMID: 23669595.
- 55: Descoutures F, Himbert D, Maisano F, Casselman F, de Weger A, Bodea O, Van der Kley F, Colombo A, Giannini C, Rein KA, De Bruyne B, Petronio AS, Dahle G, Alfieri O, Vahanian A. Transcatheter valve-in-ring implantation after failure of surgical mitral repair. *Eur J Cardiothorac Surg*. 2013 Jul;44(1):e8-15. doi: 10.1093/ejcts/ezt155. Epub 2013 Mar 25. PMID: 23530029.
- 56: Debonnaire P, Van Herck PL, Katsanos S, van der Kley F, de Weger A, Palmen M, Marsan NA, Schalijs MJ, Delgado V. How should I treat acute aortic annulus rupture during transcatheter aortic valve implantation? *EuroIntervention*. 2013 Jan 22;8(9):1103-9. doi: 10.4244/EIJV8I9A169. PMID: 23339817.
- 57: Houthuizen P, Van Garsse LA, Poels TT, de Jaegere P, van der Boon RM, Swinkels BM, Ten Berg JM, van der Kley F, Schalijs MJ, Baan J Jr, Cocchieri R, Brueren GR, van Straten AH, den Heijer P, Bentala M, van Ommen V, Kluin J, Stella PR, Prins MH, Maessen JG, Prinzen FW. Left bundle-branch block induced by transcatheter aortic valve implantation increases risk of death. *Circulation*. 2012 Aug 7;126(6):720-8. doi: 10.1161/CIRCULATIONAHA.112.101055. Epub 2012 Jul 12. PMID: 22791865.
- 58: Ewe SH, Ng AC, Schuijff JD, van der Kley F, Colli A, Palmen M, de Weger A, Marsan NA, Holman ER, de Roos A, Schalijs MJ, Bax JJ, Delgado V. Location and severity of aortic valve calcium and implications for aortic regurgitation after transcatheter aortic valve implantation. *Am J Cardiol*. 2011 Nov 15;108(10):1470-7. doi: 10.1016/j.amjcard.2011.07.007. Epub 2011 Aug 17. PMID: 21855831.
- 59: Ng AC, Yiu KH, Ewe SH, van der Kley F, Bertini M, de Weger A, de Roos A, Leung DY, Schuijff JD, Schalijs MJ, Bax JJ, Delgado V. Influence of left ventricular geometry



and function on aortic annular dimensions as assessed with multi-detector row computed tomography: implications for transcatheter aortic valve implantation. *Eur Heart J*. 2011 Nov;32(22):2806-13. doi: 10.1093/eurheartj/ehr237. Epub 2011 Jul 23. PMID: 21785108.

60: Ng AC, Delgado V, Bertini M, Antoni ML, van Bommel RJ, van Rijnsoever EP, van der Kley F, Ewe SH, Witkowski T, Auger D, Nucifora G, Schuijf JD, Poldermans D, Leung DY, Schalij MJ, Bax JJ. Alterations in multidirectional myocardial functions in patients with aortic stenosis and preserved ejection fraction: a two-dimensional speckle tracking analysis. *Eur Heart J*. 2011 Jun;32(12):1542-50. doi: 10.1093/eurheartj/ehr084. Epub 2011 Mar 29. PMID: 21447510.

61: Ewe SH, Delgado V, Ng AC, Antoni ML, van der Kley F, Marsan NA, de Weger A, Tavilla G, Holman ER, Schalij MJ, Bax JJ. Outcomes after transcatheter aortic valve implantation: transfemoral versus transapical approach. *Ann Thorac Surg*. 2011 Oct;92(4):1244-51. doi: 10.1016/j.athoracsur.2011.01.059. Epub 2011 Mar 21. PMID: 21420661.

62: Delgado V, Ng AC, Schuijf JD, van der Kley F, Shanks M, Tops LF, van de Veire NR, de Roos A, Kroft LJ, Schalij MJ, Bax JJ. Automated assessment of the aortic root dimensions with multidetector row computed tomography. *Ann Thorac Surg*. 2011 Mar;91(3):716-23. doi: 10.1016/j.athoracsur.2010.09.060. PMID: 21352985.

63: Ewe SH, Ajmone Marsan N, Pepi M, Delgado V, Tamborini G, Muratori M, Ng AC, van der Kley F, de Weger A, Schalij MJ, Fusari M, Biglioli P, Bax JJ. Impact of left ventricular systolic function on clinical and echocardiographic outcomes following transcatheter aortic valve implantation for severe aortic stenosis. *Am Heart J*. 2010 Dec;160(6):1113-20. doi: 10.1016/j.ahj.2010.09.003. PMID: 21146666.

64: Shanks M, Delgado V, Ng AC, van der Kley F, Schuijf JD, Boersma E, van de Veire NR, Nucifora G, Bertini M, de Roos A, Kroft L, Schalij MJ, Bax JJ. Mitral valve morphology assessment: three-dimensional transesophageal echocardiography versus computed tomography. *Ann Thorac Surg*. 2010 Dec;90(6):1922-9. doi: 10.1016/j.athoracsur.2010.06.116. PMID: 21095337.

65: Delgado V, Ewe SH, Ng AC, van der Kley F, Marsan NA, Schuijf JD, Schalij MJ, Bax JJ. Multimodality imaging in transcatheter aortic valve implantation: key steps to assess procedural feasibility. *EuroIntervention*. 2010 Nov;6(5):643-52. doi: 10.4244/EIJV6I5A107. PMID: 21044920.

66: Delgado V, Ng AC, van de Veire NR, van der Kley F, Schuijf JD, Tops LF, de Weger A, Tavilla G, de Roos A, Kroft LJ, Schalij MJ, Bax JJ. Transcatheter aortic valve implantation: role of multi-detector row computed tomography to evaluate prosthesis positioning and deployment in relation to valve function. *Eur Heart J*. 2010 May;31(9):1114-23. doi: 10.1093/eurheartj/ehq018. Epub 2010 Feb 19. PMID: 20173197.

67: de Weger A, Tavilla G, Ng AC, Delgado V, van der Kley F, Schuijf JD, Bax JJ, Klautz RJ. Successful transapical transcatheter valve implantation within a dysfunctional mitral bioprosthesis. *JACC Cardiovasc Imaging*. 2010 Feb;3(2):222-3. doi: 10.1016/j.jcmg.2009.10.011. PMID: 20159651.

68: Pundziute G, Schuijf JD, van Velzen JE, Jukema JW, van Werkhoven JM, Nucifora G, van der Kley F, Kroft LJ, de Roos A, Boersma E, Reiber JH, Schalij MJ, van der Wall EE, Bax JJ. Assessment with multi-slice computed tomography and gray-scale and virtual histology intravascular ultrasound of gender-specific differences in extent and composition of coronary atherosclerotic plaques in relation to age. *Am J Cardiol*. 2010 Feb 15;105(4):480-6. doi: 10.1016/j.amjcard.2009.09.054. Epub 2010 Jan 5. PMID: 20152242.

69: Delgado V, Ng AC, Shanks M, van der Kley F, Schuijf JD, van de Veire NR, Kroft L, de Roos A, Schalij MJ, Bax JJ. Transcatheter aortic valve implantation: role of multimodality cardiac imaging. *Expert Rev Cardiovasc Ther*. 2010 Jan;8(1):113-23. doi: 10.1586/erc.09.135. PMID: 20030025.

70: Delgado V, Tops LF, van Bommel RJ, van der Kley F, Marsan NA, Klautz RJ, Versteegh MI, Holman ER, Schalij MJ, Bax JJ. Strain analysis in patients with severe aortic stenosis and preserved left ventricular ejection fraction undergoing surgical valve replacement. *Eur Heart J*. 2009 Dec;30(24):3037-47. doi: 10.1093/eurheartj/ehp351. PMID: 19726436.

71: Ng AC, Delgado V, van der Kley F, Shanks M, van de Veire NR, Bertini M, Nucifora G, van Bommel RJ, Tops LF, de Weger A, Tavilla G, de Roos A, Kroft LJ, Leung DY, Schuijf J, Schalij MJ, Bax JJ. Comparison of aortic root dimensions and geometries before and after transcatheter aortic valve implantation by 2- and 3-dimensional transesophageal echocardiography and multislice computed tomography. *Circ Cardiovasc Imaging*. 2010 Jan;3(1):94-102. doi: 10.1161/CIRCIMAGING.109.885152. Epub 2009 Nov 17. PMID: 19920027.

72: Atary JZ, Bergheanu SC, van der Hoeven BL, Atsma DE, Bootsma M, van der Kley F, Zeppenfeld K, Jukema JW, Schalij MJ. Impact of sirolimus-eluting stent implantation compared to bare-metal stent implantation for acute myocardial infarction on coronary plaque composition at nine months follow-up: a Virtual Histology intravascular ultrasound analysis. Results from the Leiden MISSION! intervention study. *EuroIntervention*. 2009 Nov;5(5):565-72. doi: 10.4244/eijv5i5a92. PMID: 20142177.

73: Tops LF, Delgado V, van der Kley F, Bax JJ. Percutaneous aortic valve therapy: clinical experience and the role of multi-modality imaging. *Heart*. 2009 Sep;95(18):1538-46. doi: 10.1136/hrt.2008.151498. PMID: 19717704.

74: Hassan AK, Liem SS, van der Kley F, Bergheanu SC, Wolterbeek R, Bosch J, Bootsma M, Zeppenfeld K, van der Laarse A, Atsma DE, Jukema JW, Schalij MJ. In-ambulance abciximab administration in STEMI patients prior to primary PCI is associated with smaller infarct size, improved LV function and lower incidence of heart failure: results from the Leiden MISSION! acute myocardial infarction treatment optimization program. *Catheter Cardiovasc Interv*. 2009 Aug 1;74(2):335-43. doi: 10.1002/ccd.21980. PMID: 19642182.

75: Ng AC, van der Kley F, Delgado V, Shanks M, van Bommel RJ, de Weger A, Tavilla G, Holman ER, Schuijf JD, van de Veire NR, Schalij MJ, Bax JJ. Percutaneous valve-in-valve procedure for severe paravalvular regurgitation in aortic bioprosthesis. *JACC Cardiovasc Imaging*. 2009 Apr;2(4):522-3. doi: 10.1016/j.jcmg.2009.01.006. PMID: 19580737.

76: Delgado V, Tops LF, Schuijf JD, van der Kley F, van de Veire NR, Schalij MJ, Bax JJ. Successful deployment of a transcatheter aortic valve in bicuspid aortic stenosis: role of imaging with multislice computed tomography. *Circ Cardiovasc Imaging*. 2009 Mar;2(2):e12-3. doi: 10.1161/CIRCIMAGING.108.809434. PMID: 19808568.

77: Hassan AK, Jukema JW, van der Laarse A, Hasan-Ali H, Wolterbeek R, van der Kley F, Spano F, Atsma DE, Schalij MJ. Incidence, patient characteristics and predictors of aborted myocardial infarction in patients undergoing primary PCI: prospective study comparing pre- and in-hospital abciximab pretreatment. *EuroIntervention*. 2009 Mar;4(5):662-8. doi: 10.4244/eijv4i5a110. PMID: 19378689.

78: The first multicentre study on coronary anomalies in the Netherlands: MuSCAT. Koppel CJ, Driesen BW, de Winter RJ, van den Bosch AE, van Kimmenade R, Wagenaar LJ, Jukema JW, Hazekamp MG, van der Kley F, Jongbloed MRM, Kiès P, Egorova


AD, Verheijen DBH, Damman P, Schoof PH, Wilschut J, Stoel M, Speekenbrink RGH, Voskuil M, Vliegen HW. *Neth Heart J*. 2021 Jun;29(6):311-317. doi: 10.1007/s12471-021-01556-9.

79: Reversal of Femoral Vein Pulsatility Due to Severe Tricuspid Regurgitation After Transcatheter Tricuspid Valve-in-Valve Implantation: A “Wave Dissipation” Effect. Pereira AR, van der Kley F, Montero-Cabezas JM, de Weger A, Delgado V. *Heart Lung Circ*. 2021 Jul 6:S1443-9506(21)00584-9. doi: 10.1016/j.hlc.2021.05.104.PMID: 34244064



---

## Dankwoord







Vele Jaren heeft Martin mij aangespoord om dit project af te maken. Dank voor het vertrouwen en de vrijheid die je mij geboden hebt in het werk op de hartcatheterisatiekamer. De ingrepen die we daar verrichten zijn de basis voor het onderzoek en resultaten zoals in dit boekje samengevat.

Zonder Victoria stond dit alles niet op papier. Zij hebt heeft een ongekenne drang om mensen scherp te houden en resultaten te krijgen, muchisimas gracias!

Samen met Victoria en Nina de vele casussen besproken in teamverband en zoeken naar mogelijkheden om problemen op te lossen. Om vervolgens op de catheterisatiekamer het plan uit te voeren onder soms lastige omstandigheden maar altijd met de best mogelijke beeldvorming. "You are simply the best."


Beste Ardiene, Joost en Arend, "last men standing", op 8 november 2007 zijn we gestart met de eerste allereerste TAVI, en hebben veel ontwikkelingen meegemaakt, maar ook zelf doorgevoerd. Dank voor de vele spannende momenten, hilariteit, slechte grappen en alles wat de revue is gepasseerd. Maar ook het huidige team van cathkamer verpleging, thoraxchirurgen en cardiologen dank voor alle goede momenten.

Alle ingrepen kunnen uiteraard niet plaats vinden zonder de hulp van de planning, cathkamerverpleging en nazorg op de shortstay, WAAK, verpleegafdeling en polikliniek.



---

## Curriculum Vitae





Frank van der Kley slaagde in 1994 voor zijn VWO examen aan het Rijnlands Lyceum in Wassenaar. Aansluitend begon hij met de geneeskunde studie aan de Erasmus Universiteit Rotterdam. Einde 2000 behaalde hij zijn diploma geneeskunde. Na een korte periode als assistent interne geneeskunde in het LUMC startte hij de opleiding cardiologie. Allereerst de vooropleiding interne geneeskunde in het Rijnland ziekenhuis bij dr F.H.M. Cluitmans. Aansluitend de cardiologie opleiding (B jaar) bij dr C. van Rees in het Rijnland ziekenhuis. In het LUMC volgden nog 3 jaren opleiding bij Prof dr E.E. van der Wall. Na afronding van de opleiding cardiologie in 2007 startte hij als interventiecardioloog. In 2007 begon hij met de transcatheter aortaklep implantaties, gevolgd door diverse andere soorten transcatheter behandelingen van structurele cardiale afwijkingen.

