Universiteit Leiden
The Netherlands

The role of inflammation in sciatica: the contradictory effect of macrophages

Djuric, N.

Citation
Djuric, N. (2021, November 4). *The role of inflammation in sciatica: the contradictory effect of macrophages*. Retrieved from https://hdl.handle.net/1887/3239007

Version:	Publisher's Version
License:	Licence agreement concerning inclusion of doctoral thesis in the Institutional Repository of the University of Leiden
Downloaded from:	https://hdl.handle.net/1887/3239007

Note: To cite this publication please use the final published version (if applicable).

5

Chapter 5

Gadolinium enhancement is not associated with disc inflammation in patients with sciatica

N. Djuric[1], X. Yang[1], A. el Barzouhi[1], R.W.J.G. Ostelo[2,3], S.G. van Duinen[4], G.J. Lycklama à Nijeholt[5], B.F.W. van der Kallen[5], W.C. Peul[1,5] and C.L.A. Vleggeert-Lankamp[1]

[1]Department of Neurosurgery, Leiden University Medical Center, Leiden, [2]Department of Epidemiology, VU Medical Centre, Amsterdam, [3]Department of Health Sciences, Faculty of Science, Amsterdam Movement Sciences research institute, Vrije Universiteit, Amsterdam, Netherlands [4]Department of Pathology, Leiden University Medical Center, Leiden. [5]Haaglanden Medical Centre, the Hague, the Netherlands

Spine (Phila Pa 1976). 2019 Jun 15;44(12):E742-E748

"There are no shortcuts, everything is reps, reps, reps."
(Arnold Schwarzenegger)

Abstract

Study design
Retrospective observational histological study

Objective
To evaluate the reliability of gadolinium enhancement as a marker for inflammation by associating gadolinium enhancement findings with the degree of inflammation as measured by macrophage infiltration in disc material retrieved during disc surgery in patients with sciatica.

Summary of the background data
Disc inflammation often occurs in sciatica patients, a non-invasive tool that is used to assess disc inflammation is gadolinium enhanced MR imaging.

Methods
Disc tissue was retrieved from patients in the Sciatica trial (N = 119), A multicentre randomized controlled trial in patients with sciatica. Disc tissue was embedded in paraffin and stained with haematoxylin and CD68. Tissue samples were categorized as mild (0-10 macrophages/cm^2), moderate (10-100 macrophages/cm^2), and considerable (>100 macrophages/cm^2) inflammation. Of the 119 MRI's, 96 were additionally performed with contrast-enhanced gadolinium.

Results
74 patients showed gadolinium enhancement of the disc herniation and 26 of the nerve root. Degree of inflammation by macrophages was not associated with gadolinium enhancement of nerve roots or herniated discs. These results did not change if the patient groups with and without Modic type 2 changes were evaluated separately. Furthermore, no associations were observed between gadolinium enhancement and presence of Modic type 2 changes.

Conclusions
This study found gadolinium enhanced MRI findings to be unreliable as an indicator for inflammation of disc herniation or nerve root in patients with sciatica.

Introduction

A highly prevalent medical condition is lumbar disc herniation [1], often accompanied by sciatica, also known as radicular pain syndrome. Since 1934, it has been widely accepted that this condition is caused by compression of the nerve root of the herniated lumbar disc [2, 3]. Disruptions of the annulus fibrosus or of its attachments to the adjacent endplate may result in a herniation of nucleus pulposus tissue into the epidural space. This concept was later fine-tuned with theories involving micro traumata of the vertebral endplate and/or micro traumata leading to disruption of the annulus fibrosus. In addition to the abovementioned nerve root compression, disruption of the annulus fibrosus can also induce a foreign-body reaction aimed at the nucleus pulposus tissue in the epidural space, which is accompanied by neovascularization and macrophage infiltration [4-6]. Subsequently, infiltrated macrophages have the ability to exacerbate the sciatic symptoms by excreting pro inflammatory cytokines [7-9]. Both the nerve root compression and inflammatory response may contribute to the irritation of the nerve root and thus to pain in the innervated dermatome [10]. However, the foreign-body reaction could also have a positive effect: it may help to accelerate the healing process through resorption of the herniated material mediated by infiltrated macrophages [8, 11, 12].

In order to further explore the role of inflammation in sciatica, it would be of benefit if non-invasive tools for inflammation could be identified. Such a tool might be Magnetic Resonance Imaging (MRI) accompanied by intravenous injection of gadolinium diethylenetriamine penta-acetic acid (Gd-DTPA). This contrast enhancement method helps visualizing vascular supply to tissue. It is widely thought that the herniated disc is only vascularized in case of an inflammatory response [13]. Consequently, some studies have suggested that this technique provides a good predictor for inflammatory reactions in the disc. However, evidence is limited [14, 15].

An additional MRI feature that is often described in sciatica patients are Modic changes. Recently, Dudli et al. added a characteristic. The authors showed that both Modic type 1 and type 2 changes are associated with an inflammatory dysmyelopoiesis with fibrogenic changes [16]. This suggests that Modic changes interact with the inflammatory process in the disc. This is supported by our previous study that showed an interaction effect of Modic type 2 changes and disc inflammation on clinical outcome in sciatica [17]. Because of this interaction, it could be that the correlation between gadolinium enhancement and inflammation is different in patients with and without Modic Changes. The aim of this study is to investigate the association between gadolinium enhanced MR imaging and the extent of disc inflammation in sciatica patients with, and without Modic changes.

Materials and Methods

Study population

Patients for this study were participants in the Sciatica Trial [18]. This was a multicentre randomized trial involving 283 patients who suffered from sciatica for 6-12 weeks and had MRI disc herniation. Patients were included if they suffered from a dermatomal pattern of pain distribution with accompanying neurological dysfunction that corresponded to the same nerve root being affected on the MRI. Exclusion criteria were cauda equina syndrome, muscle paralysis, insufficient strength to move against gravity, occurrence of another episode of symptoms similar to those of the current episode during the previous 12 months, previous spine surgery, bony stenosis, spondylolisthesis, pregnancy, or severe coexisting disease. In the trial, early surgery was compared to prolonged conservative care. 141 patients were randomized to surgery and 125 patients actually underwent surgery (16 recovered before surgery could be performed). The other 142 patients were randomized to prolonged conservative care, of which 55 patients underwent surgery within 1 year, with a mean time to surgery of 15 weeks after randomization. Thus, in the first year after randomization a total of 180 patients underwent surgery for sciatica. The protocol, which included analysis of the disc material, was approved by the medical ethics committees at all participating hospitals.

Histological analysis

Disc material of all operated patients was collected and fixed in 4% formaldehyde solution. For assessment, the tissue was subsequently embedded in blocks of paraffin. Thin slices were prepared and the tissue was evaluated histologically for inflammation by investigating the presence of macrophages. For the haematoxylin staining, a 5-µm thick slice was taken from the middle of the paraffin blocks. Each slice was stained with Harris haematoxylin according to the program from the Leica ST 5020-mulitstainer. For the immunohistochemistry, 5-µm paraffin slices were rinsed in ethanol and methanol solutions and prepared for the expression of CD68 (macrophages) (DAKO, Denmark). Immunohistochemistry was performed using a three-step indirect method. Antibodies were cooked in EDTA pH 9.0 buffer as a pre-treatment. Subsequently, a avidin-biotin complex technique was performed with the Vectastain ABC-Elite Kit (Vector Lab. USA) and the appropriate biotinylated antibodies. Visualization of the peroxidase reaction was done with DAB solution (Sigma). Moreover, the samples were counterstained with Harris haematoxylin. All of these samples were accompanied by a positive control. In control samples, primary antibodies were omitted, which resulted in the expected absence of any cellular labelling. In order to standardize the evaluation of the samples, all samples were photographed under the microscope before they were evaluated.

The evaluation was done by two independent investigators, who were blinded to clinical information and MRI. The training of these independent researchers was carried out by a senior pathologist. The number of macrophages on each sample was counted and estimated. Using this method, the tissue samples were categorized according to their inflammation grade. The categories consisted of mild (0-10 macrophages per cm^2), moderate (10-100 macrophages per cm^2), and considerable (>100 macrophages per cm^2) inflammation. Subsequently, a consensus score between the independent researchers was determined. An acceptable consensus score was predefined as 60%. It was pre-defined that all samples would be re-assessed with a senior pathologist if the consensus was less than 60%.

MRI protocol and Image evaluation of the sciatica trial

MRI scans were performed at baseline by a 1.5 Tesla scanner, and both sagittal T1- and T2-weighted images of the lumbar spine were obtained. T1 images were gathered with contrast-enhanced gadolinium dithylenetriamine penta-acetic acid [DTPA] at a standard dose of 0.1 mmol/kg body weight. Image evaluation of Modic changes was according to the criteria of Modic changes et al[19, 20]. Image evaluation was done according to a predefined protocol (Supplementary Table S1)[21]**.**MRIs were evaluated by 2 neuro radiologists and 1 neurosurgeon. All three were blinded to histological data and clinical information. The readers were not involved in the selection or treatment of the patients included. Inter-observer agreement analyses regarding the MRI findings were published earlier [22, 23]. For the statistical analyses, the majority opinion of the three independent researchers (answered by at least two of the three) was used.

The structure enhancement by gadolinium were scored in the following categories: 1. Enhancement of herniated disc: no or little enhancement, full or diffuse enhancement. 2. Enhancement of target nerve root: enhancement versus no enhancement. Regarding Modic changes, Type was scored as: 1, 2, or 3. Because in earlier findings no Modic changes were observed at level L1-L2 [24], only images from L2-L3 through L5-S1 were evaluated.

The inter-observer agreement was substantial for the Modic changes (69-97%), as described by el Barzouhi (2014) [25]. The inter-observer agreement was moderate regarding the scoring of enhancement of the herniated disc (56.2%, kappa = 0.42). Enhancement of the target nerve root inter-observer agreement was moderate (63.4%, kappa = 0.27).

Statistical analysis

Firstly, we correlated gadolinium enhancement with the presence of Modic changes. Secondly, the categorized histological findings were associated with gadolinium enhancement of the nerve root and herniated disc. In addition, we repeated the analyses separately in patients with and without Modic changes. All comparisons were done using X^2 tests for categorical data. P-values of < 0.05 were regarded as significant.

Preceding this additional subgroup analysis, the data was tested for an association between Modic type 2 changes and inflammation, no association was found (p = 0.68), a more detailed description was previously described [17]. All comparisons were done using X^2 tests for categorical data. P-values of < 0.05 were regarded as significant.

Results

Demographics

Of the 180 patients that underwent surgery, 119 patients disc samples were preserved and analyzed. Missing samples were due to multiple reasons: samples were either not collected during surgery, got lost after surgery, were not preserved properly, or got lost after preservation. 96 of the 119 patients received gadolinium enhanced MRI's. The baseline characteristics age, gender, BMI and duration of sciatica prior to surgery of the three inflammation groups were comparable (Table 1).

The histological data analysis

CD68 staining to identify macrophages resulted in the following distribution: 47 (39.5%) patients had 0-10 macrophages per cm^2 (indicating mild inflammation), 45(37.8%) patients had 10-100 macrophages per cm^2 (indicating moderate inflammation), and 27 (22.7%) patients had >100 macrophages per cm^2 (indicating considerable inflammation) (Table 2).The consensus score was excellent (0.96). (Table 2). Examples of the CD68 samples and their categories are shown in Figure 1.

The MRI data analysis

Of the 119 patients, a total of 1 patient showed Modic type 1 changes, 33 patients Modic type 2 changes, no patients Modic type 3 changes, and 85 patients had no Modic changes. Because only one patient showed Modic type 1 changes, this sample was excluded from the statistical analyses and thus only Modic type 2 changes were taken into account. Out of the 96 patients with gadolinium enhanced MRI's, 26 showed gadolinium enhancement of the root, and 74 showed gadolinium enhancement of the herniated disc.

Association between Modic changes and gadolinium

No significant associations were found between the presence of Modic type 2 changes and enhancement of the nerve root ($p = 0.51$) or herniated disc ($p = 0.61$) (Table 3).

Association between inflammation and gadolinium

The degree of inflammation by macrophages was not associated with enhancement of nerve root in the entire population ($p = 0.66$), and neither in the subgroups (no Modic changes $p = 0.90$ and for Modic Type 2 changes $p = 0.66$) (Table 4). Enhancement of the herniated disc was also not associated with the degree of inflammation in the entire population ($p = 0.30$) or in the subgroups (no Modic versus Modic Type 2 changes) (Table 5).

Discussion

The most important finding of this study is that gadolinium enhancement assessed on MRI is not associated with disc inflammation by macrophages. This indicates that gadolinium enhancement is probably unreliable as a marker tool for inflammation in sciatica.

In contrast with previous literature, the expected association between histologically defined inflammation by macrophages and gadolinium enhancement on MRI was not observed in this study. This questions the reliability of gadolinium as a proper indicator for disc inflammation, as it was suggested earlier [14, 15]. In addition, we did not observe an association between gadolinium enhancement and the presence of Modic type 2 changes, which is also in contradiction with previous research in which an increase of enhancement was found in patients with Modic changes [26]. However, in that study the investigators did not make any difference between type 1 and 2 Modic Changes [26]. The correlation might not have been caused by Modic type 2 but by Modic type 1, or that gadolinium enhancement is not sensitive enough to point out the difference in vascularization in patients with and without Modic changes. As we also did not observe an association between gadolinium enhancement and histologically defined inflammation by macrophages, we expect the latter to be more likely [26].

Our findings may be explained by the great inter-observer variability among the evaluators with respect to gadolinium enhancement. This indicates that it is often unclear in which enhancement category a sample fits best. the fact that most other MRI parameters that were observed during this study demonstrated a good to excellent inter-observer agreement[22, 23, 27], makes it more likely that the poor inter-observer agreement was due to visibility of gadolinium instead of the incompetence of the evaluators. However, before we conclude that gadolinium is unreliable as an imaging tool in disc herniation, we must take the possibility into account that the lack of associations was due to methodological or equipment reasons. This stresses the importance of replication studies.

This study has several strong points. For the histological analysis we used multiple evaluators and demonstrated substantial consensus score. Moreover, this study was the first study to compare histology to gadolinium enhancement between patients with and without Modic type 2 changes. This study also has some limitations. the inter agreement analysis of gadolinium revealed only moderate kappa values, which points out that human error remains an obstacle in the present research environment that has yet to be overcome. The samples used for the pathological analysis were old, which might have reduced their quality. Nevertheless, the CD68 staining did show properly identifiable macrophages. Hence we assume that the age of the sample did not alter our result. Also, since this study measured the degree of inflammation in number of macrophages, it cannot be out ruled that T or B lymphocytes would associate differently with gadolinium enhancement. However, previous findings have shown that macrophages are the main type of inflammatory cells found in discus samples [28] [14], and macrophages in disc material are associated with neovascularization [14], we do not expect T and B lymphocytes to associate differently with gadolinium enhancement.

This study points out the limited and now contra dictionary evidence available on the reliability of gadolinium enhancement as an indicator for inflammation in patients with sciatica due to a lumbar disc herniation [14, 15, 20]. In order to put our findings in perspective, future studies should focus on evaluating the usage of gadolinium in disc herniations.

Acknowledgements
The authors thank Stefan Hoyng for his training of the researchers in cell-counting, and Ingrid Hegeman and Annemarie Sinke for the preparation and staining of the samples.

Conflict of interest
None of the authors has any conflict of interest. No funding was received for the conductance of this study.

Bibliography

1. Jordan J, Konstantinou K, and O'Dowd J, *Herniated lumbar disc.* BMJ Clin Evid, 2011. 2011: 1118
2. Mixter WJ BJ, *Rupture of Intervertebral Disc with Involvement of Spinal Canal.* New England Journal of Medicine, 1934. 211(210): p. 5.
3. Robinson JS, *Sciatica and the Lumbar-Disk Syndrome - a Historic Perspective.* Southern Medical Journal, 1983. 76(2): p. 232-238.
4. Lotz JC, Fields AJ, and Liebenberg EC, *The role of the vertebral end plate in low back pain.* Global Spine J, 2013. 3(3): p. 153-64.
5. Rothoerl R, Woertgen C, Holzschuh M et al, *Macrophage tissue infiltration, clinical symptoms, and signs in patients with lumbar disc herniation. A clinicopathological study on 179 patients.* Acta Neurochir (Wien), 1998. 140(12): p. 1245-8.
6. Kobayashi S, Meir A, Kokubo Y et al, *Ultrastructural analysis on lumbar disc herniation using surgical specimens: role of neovascularization and macrophages in hernias.* Spine (Phila Pa 1976), 2009. 34(7): p. 655-62.
7. Pedersen LM, Schistad E, Jacobsen LM et al, *Serum levels of the pro-inflammatory interleukins 6 (IL-6) and -8 (IL-8) in patients with lumbar radicular pain due to disc herniation: A 12-month prospective study.* Brain Behav Immun, 2015. 46: p. 132-6.
8. Arango Duque G and Descoteaux A, *Macrophage cytokines: involvement in immunity and infectious diseases.* Front Immunol, 2014. 5: p. 491.
9. Wang K, Bao JP, Yang S et al, *A cohort study comparing the serum levels of pro- or anti-inflammatory cytokines in patients with lumbar radicular pain and healthy subjects.* Eur Spine J, 2016. 25(5): p. 1428-1434.
10. Marshall LL, Trethewie ER, and Curtain CC, *Chemical Radiculitis - Clinical, Physiological and Immunological Study.* Clinical Orthopaedics and Related Research, 1977(129): p. 61-67.
11. Peluffo H, Solari-Saquieres P, Negro-Demontel ML et al, *CD300f immunoreceptor contributes to peripheral nerve regeneration by the modulation of macrophage inflammatory phenotype.* J Neuroinflammation, 2015. 12: p. 145.
12. Arai Y, Yasuma T, Shitoto K et al, *Immunohistological study of intervertebral disc herniation of lumbar spine.* J Orthop Sci, 2000. 5(3): p. 229-31.
13. Saifuddin A, Mitchell R, and Taylor BA, *Extradural inflammation associated with annular tears: demonstration with gadolinium-enhanced lumbar spine MRI.* Eur Spine J, 1999. 8(1): p. 34-9.
14. Lohr M, Lebenheim L, Berg F et al, *Gadolinium enhancement in newly diagnosed patients with lumbar disc herniations are associated with inflammatory peridiscal tissue reactions - Evidence of fragment degradation?* Clinical Neurology and Neurosurgery, 2014. 119: p. 28-34.
15. Yamashita K, Hiroshima K, and Kurata A, *Gadolinium-DTPA--enhanced magnetic resonance imaging of a sequestered lumbar intervertebral disc and its correlation with pathologic findings.* Spine (Phila Pa 1976), 1994. 19(4): p. 479-82.
16. Dudli S, Sing DC, Hu SS et al, *ISSLS PRIZE IN BASIC SCIENCE 2017: Intervertebral disc/bone marrow cross-talk with Modic changes.* Eur Spine J, 2017. 26(5): p. 1362-1373.
17. Djuric N, Yang X, Ostelo R et al, *Disc inflammation and Modic changes show an interaction effect on recovery after surgery for lumbar disc herniation.* Eur Spine J, 2019. 28(11): p. 2579-2587.
18. Peul WC, van Houwelingen HC, van den Hout WB et al, *Surgery versus prolonged conservative treatment for sciatica.* N Engl J Med, 2007. 356(22): p. 2245-56.
19. Modic MT, Steinberg PM, Ross JS et al, *Degenerative disk disease: assessment of changes in vertebral body marrow with MR imaging.* Radiology, 1988. 166(1 Pt 1): p. 193-9.

20. Modic MT, Masaryk TJ, Ross JS et al, *Imaging of degenerative disk disease.* Radiology, 1988. 168(1): p. 177-86.
21. Fardon DF, Williams AL, Dohring EJ et al, *Lumbar disc nomenclature: version 2.0: Recommendations of the combined task forces of the North American Spine Society, the American Society of Spine Radiology and the American Society of Neuroradiology.* Spine J, 2014. 14(11): p. 2525-45.
22. el Barzouhi A, Vleggeert-Lankamp CL, Lycklama a Nijeholt GJ et al, *Reliability of gadolinium-enhanced magnetic resonance imaging findings and their correlation with clinical outcome in patients with sciatica.* Spine J, 2014. 14(11): p. 2598-607.
23. el Barzouhi A, Vleggeert-Lankamp CL, Lycklama a Nijeholt GJ et al, *Magnetic resonance imaging in follow-up assessment of sciatica.* N Engl J Med, 2013. 368(11): p. 999-1007.
24. Kuisma M, Karppinen J, Niinimaki J et al, *A three-year follow-up of lumbar spine endplate (Modic) changes.* Spine (Phila Pa 1976), 2006. 31(15): p. 1714-8.
25. el Barzouhi A, Vleggeert-Lankamp CL, van der Kallen BF et al, *Back pain's association with vertebral end-plate signal changes in sciatica.* Spine J, 2014. 14(2): p. 225-33.
26. Tibiletti M, Galbusera F, Ciavarro C et al, *Is the transport of a gadolinium-based contrast agent decreased in a degenerated or aged disc? A post contrast MRI study.* PLoS One, 2013. 8(10): p. e76697.
27. El Barzouhi A, Vleggeert-Lankamp CL, Lycklama ANGJ et al, *Magnetic resonance imaging interpretation in patients with sciatica who are potential candidates for lumbar disc surgery.* PLoS One, 2013. 8(7): p. e68411.
28. Habtemariam A, Gronblad M, Virri J et al, *A comparative immunohistochemical study of inflammatory cells in acute-stage and chronic-stage disc herniations.* Spine (Phila Pa 1976), 1998. 23(20): p. 2159-65; discussion 2166.

Appendix

Table 1. Baseline characteristics of the three histologically defined inflammation groups

	Mild (N=48)	moderate (N=45)	considerable (N=27)
Age	40.4±9.6	42.1±10.3	43.7±6.6
Male gender	36 (75.0%)	28 (62.2%)	22 (81%)
Body-mass index	26.0±4.1	25.8±3.5	25.9±3.2
Duration of sciatica in weeks	9.6±1.9	9.7±2.3	8.7±2.1
Received gadolinium	37 (77.1%)	40 (88.9%)	19 (70.4%)

Values for gender are n and (%) or means ± SD.
No significant baseline differences were observed between the three inflammation groups.

Table 2. Consensus score of the pathological findings

	A vs. B % agreement
Inflammation at baseline (3 categories)	95.8
Mild	96.8
Moderate	94.6
considerable	96.2

A and B both represent independent observers. The agreement was assessed after the consensus reading.

Table 3. Association between Modic changes and gadolinium enhancement of the herniated disc

X^2 test	No MC (N = 67)	MC2 (N = 26)	P value
Nerve root enhancement			0.51
• No enhancement	47 (70.1%)	20 (76.9%)	
• Enhancement	20 (29.9%)	6 (23.1%)	
X^2 test	**No MC (N = 67)**	**MC2 (N = 26)**	**P value**
Disc herniation enhancement			0.61
• No or little enhancement	42 (63.6%)	18 (69.2%)	
• Full or diffuse enhancement	24 (36.4%)	8 (30.8%)	

95 of 96 Gd-MRI's were scored for MC 2 changes. X^2 tests for no MC vs MC2 compared to enhancement of the nerve root and herniated disc.

5

Table 4. Association between gadolinium nerve root enhancement and inflammation for all patients and separately for patients with and without Modic changes

X^2 test (All patients)	Mild (N = 37)	Moderate (N = 40)	Considerable (N = 19)	P value
Nerve root enhancement				0.66
• No enhancement	25 (67.6%)	30 (75%)	14 (77.8%)	
• Enhancement	12 (32.4%)	10 (25%)	4 (22.2%)	
X^2 test (without MC*)	**Mild (N = 28)**	**Moderate (N = 27)**	**Considerable (N = 12)**	**P value**
Nerve root enhancement				0.90
• No enhancement	19 (67.8%)	19 (70.4%)	9 (75%)	
• Enhancement	9 (32.2%)	8 (29.6%)	3 (25%)	
X^2 test (with MC2 changes)**	**Mild (N = 9)**	**Moderate (N = 12)**	**Considerable (N = 6)**	**P value**
Nerve root enhancement				0.66
• No enhancement	6 (66.7%)	10 (83.3%)	4 (80%)	
• Enhancement	3 (33.3%)	2 (16.7%)	1 (20%)	

X^2 tests for mild vs moderate vs considerable inflammation compared to enhancement of the nerve root. First in all patients, then in patients without MC and last in patients with MC2.
* One value missing for patients without MC, in the moderate inflammation group.
** One value missing for patients with MC2, in considerable inflammation group.

Table 5. Association between gadolinium enhancement of the herniated disc and inflammation for all patients, and separate for patients with and without Modic changes

X^2 test for all patients	Mild (N = 37)	Moderate (N = 40)	Considerable (N = 19)	P value
Disc herniation enhancement				0.30
• No or little enhancement	20 (55.6%)	29 (72.5%)	12 (66.7%)	
• Full or diffuse enhancement	16 (44.4%)	11 (27.5%)	6 (33.7)	
X^2 test (without MC*)	**Mild (N = 28)**	**Moderate (N = 27)**	**Considerable (N = 12)**	**P value**
Disc herniation enhancement				0.60
• No or little enhancement	16 (57,1%)	19 (70.4%)	7 (63.6%)	
• Full or diffuse enhancement	12 (42.9%)	8 (29.6%)	4 (36.4%)	
X^2 test (with MC2 changes)**	**Mild (N = 9)**	**Moderate (N = 12)**	**Considerable (N = 6)**	**P value**
Disc herniation enhancement				0.45
• No or little enhancement	4 (50%)	10 (83.3%)	4 (66.7%)	
• Full or diffuse enhancement	4 (50%)	2 (17.7%)	2 (33.3%)	

X^2 tests for mild vs moderate vs considerable inflammation compared to enhancement of the nerve root. First in all patients, then in patients without MC and last in patients with MC2**.**
* Disc bulging was scored once in the considerable inflammation group.
** Disc bulging was scored once in the mild inflammation group.

Figure 1. Macrophage infiltration categories

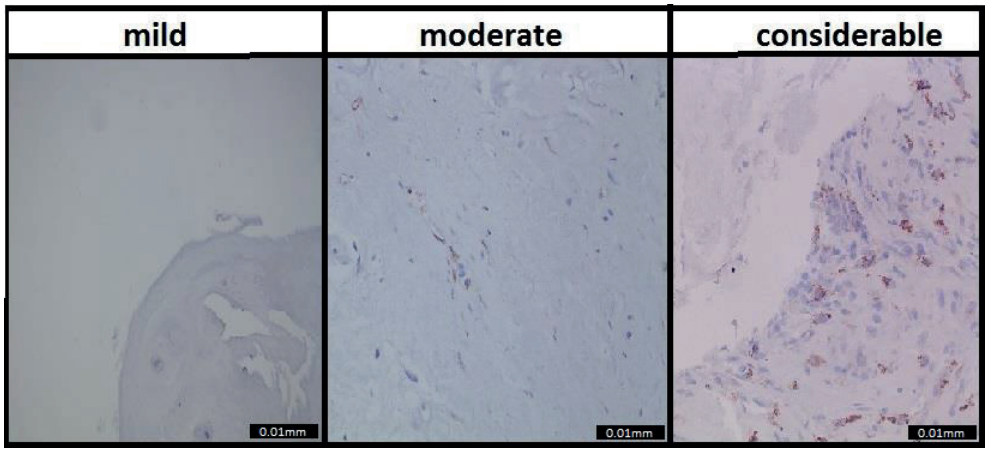

Examples of mild (0-10 macrophages per cm^2), moderate (10-100 macrophages per cm^2), and considerable (>100 macrophages per cm^2) inflammation.

Figure 2. Example of gadolinium enhancement

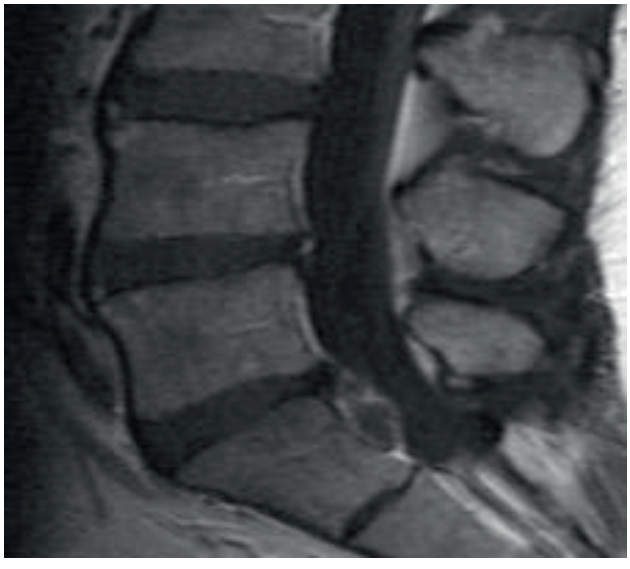

A patient who showed circumferential gadolinium enhancement of a disc herniation at level L5-S1.

Supplementary appendix

Table S1. MRI study variables (gadolinium)

MRI variable	Type	Categories
Disc level that most likely caused the lumbosacral radicular syndrome of the patient	Disc level	1. L2L3 2. L3L4 3. L4L5 4. L5S1 5. Not applicable, all disc levels have a normal disc contour: no disc extension beyond the normal margins of the intervertebral disc space at any disc level
	Disc contour at this disc level	1. Normal: no disc extension beyond the normal margins of the intervertebral disc space 2. Bulging: presence of disc tissue circumferentially (50-100%) beyond the edges of the ring apophyses 3. Consideration of a disc herniation: localized displacement of disc material beyond the normal margins of the intervertebral disc space
	Certainty about the presence of a disc herniation	1. Definite about the presence: no doubt about the presence 2. Probable about the presence: some doubt but probability > 50% 3. Possible about the presence: reason to consider but probability < 50% 4. Definite about the absence: no doubt about the absence of a disc herniation.
If a herniation at the disc level is considered	**Gadolinium enhancement of the intervertebral disc herniation**	**1. No enhancement** **2. Any edge enhancement** **3. Complete circumferential enhancement** **4. Diffuse staining**
Nerve root compression	Probability of nerve root compression	1. Definite about the presence: no doubt about the presence 2. Probable about the presence: some doubt but likelihood > 50% 3. Possible about the presence: reason to consider but likelihood < 50% 4. Definitely no nerve root compression
	If nerve root compression is present, which nerve root is affected	1. L3 2. L4 3. L5 4. S1 5. Not applicable, definitely no nerve root compression
	Side nerve root compression	1. Right 2. Left
	Gadolinium enhancement of the affected nerve root	1. No enhancement 2. Yes, mild enhancement 3. Yes, considerable enhancement
	Nerve root thickness distal to the site of compression	1. Normal 2. Thickened 3. Narrowed

Table S2. MRI study variables (Modic changes)

Disc level	Variable	Category
Disc level with the most severe nerve root compression	Disc level	1. Not applicable: no nerve root compression 2. L2L3 3. L3L4 4. L4L5 5. L5S1
	Disc contour at this level	1. Bulging: presence of disc tissue circumferentially (50-100%) beyond the edges of the ring apophyses 2. Herniation: localized displacement of disc material beyond the normal margins of the intervertebral disc space
	Certainty about the presence of disc herniation	1. Definite about the presence: no doubt about the presence 2. Probable about the presence: some doubt but probability > 50% 3. Possible about the presence: reason to consider but probability < 50% 4. Definite about the absence: no doubt about the absence
	Loss of disc height at this level	1. Yes 2. No
	Signal intensity of nucleus pulposus on T2 images at this level	1. Hypointensity 2. Normal 3. Hyperintensity
	Certainty about the presence of nerve root compression	1. Definite about the presence: no doubt about the presence 2. Probable about the presence: some doubt but probability > 50% 3. Possible about the presence: reason to consider but probability < 50% 4. Definite about the absence: no doubt about the absence
	Spinal canal stenosis	1. Yes 2. No
	Disappearance of epidural fat	1. Completely disappeared 2. Partly disappeared 3. No disappearance
	Presence of vertebral end plate changes and its extent	1. No VESC (Vertebral Endplate Signal Changes) 2. VESC type 1: hypointense on T1-weighted sequences and hyperintense on T2-weighted sequences 3. VESC type 2: increased signal on T1 weighted sequences and isointense or slightly hyperintense signal on T2 weighted sequences 4. VESC type 3: hypointense both on T1- and T2-weighted sequences 5. VESC type 1 and 2