



Universiteit
Leiden
The Netherlands

Conversion from knee arthrodesis to arthroplasty: systematic review

Kernkamp, W.A.; Verra, W.C.; Pijls, B.G.; Schoones, J.W.; Linden, H.M.J. van der; Nelissen, R.G.H.H.

Citation

Kernkamp, W. A., Verra, W. C., Pijls, B. G., Schoones, J. W., Linden, H. M. J. van der, & Nelissen, R. G. H. H. (2016). Conversion from knee arthrodesis to arthroplasty: systematic review. *International Orthopaedics*, 40(10), 2069-2074. doi:10.1007/s00264-016-3150-2

Version: Not Applicable (or Unknown)

License: [Leiden University Non-exclusive license](#)

Downloaded from: <https://hdl.handle.net/1887/113280>

Note: To cite this publication please use the final published version (if applicable).

Conversion from knee arthrodesis to arthroplasty: systematic review

Willem Alexander Kernkamp¹ · Wiebe Christiaan Verra¹ · Bart Godefridus Pijls¹ · Jan Wilhelmus Schoones² · Henrica Maria Jannetta van der Linden¹ · Rob Gerardus Henricus Hubertus Nelissen¹

Received: 14 November 2015 / Accepted: 7 February 2016 / Published online: 16 March 2016
© The Author(s) 2016. This article is published with open access at Springerlink.com

Abstract

Purpose Arthrodesis (AD) of the knee reduces pain and provides stability, but has severe functional and social limitations. There has been ample discussion on the value of a conversion of an AD to a total knee arthroplasty (TKA). The aim of this study was to perform a review and meta-analysis of the current literature on conversion of an AD to TKA and assess clinical outcome, complication rate, surgical technique and overall patient-related outcome measures.

Methods PubMed, Embase, Web of Science, Cochrane, CENTRAL, CINAHL, Academic Search Premier, ScienceDirect and searching by hand for papers on conversion of AD of the knee to TKA. Two reviewers independently reviewed all titles and abstracts, and extracted the available data. Study eligibility criteria were: conversion of knee AD to TKA, five cases or more and non-oncology patients. Data consisted of study characteristics, patient demographics, clinical outcome and complications. Additionally, details on surgical technique were reviewed.

Results Of the 866 unique references identified, six papers were included for further analyses, comprising a total of 123 knees with conversion of AD of the knee to TKA. Mean gain of knee flexion was 80 degrees and the mean HSS score improved with 20 points. A complicated postoperative course was found in 65 % of all cases. The most

frequent complication was skin necrosis (25 %), followed by arthrofibrosis (13 %), infection (11 %) and revision (11 %). Major complications such as refusion, amputation and death occurred in less than 5 % of all cases.

Discussion The majority of the papers consisted of small case series of moderate methodological quality, resulting in 123 included knees. Further series are necessary to draw definitive conclusions.

Conclusions This is the first systematic review and meta-analysis on conversion of a knee arthrodesis to TKA. Good clinical results can be expected after conversion, albeit at a high risk of postoperative complications.

Keywords Total knee arthroplasty · Arthrodesis · Joint fusion · Systematic review · Clinical outcome

Introduction

Arthrodesis (AD) of the knee has been performed since the early 1900s [1]. Originally it was used to treat tuberculosis of the knee joint, severe osteoarthritis and even juvenile arthritis of the knee until the 1970s. The main advantages of an AD of the knee are creating knee stability and relief of pain, both enhancing mobility. However, AD of the knee has its limitations to physical and social functioning. Kim et al. [2] mentioned that 17 out of the 30 patients with a fused knee attempted to commit suicide because of social discrimination towards their disability. Conversion of the AD to a total knee arthroplasty (TKA) is an option for patients with AD. The conversion of a fused knee to a TKA is not only a challenging surgical procedure [3] but it is also associated with a high incidence of complications [2, 4–7]. Sufficient soft tissue and an intact extensor mechanism are important factors in achieving good clinical results of a conversion. Therefore,

✉ Willem Alexander Kernkamp
wakernkamp@gmail.com

¹ Department of Orthopaedic Surgery, Leiden University Medical Centre, Albinusdreef 2, PO Box 9600, 2300 RC Leiden, The Netherlands

² Walaeus Library, Leiden University Medical Center, Leiden, The Netherlands

conversion should be evaluated on a case-by-case basis [7, 8]. It is important that patients are highly motivated and have realistic expectations about the procedure, risk of complications and postoperative results in order to be successful [7–9]. Judgment of patients generally has been positive and satisfied after conversion, even after a complicated postoperative course or outcome [3, 7, 8].

There has been discussion on whether a painless knee fusion should be converted to a potentially painful TKA with concomitant high risks for severe complications of this surgery. Some authors advocate the procedure [5, 6, 9–11], while others have expressed concern over its efficacy in the presence of the high complication rate [1, 2, 7, 12]. Thus, a systematic review and meta-analyses of the current literature was done, to examine the role of TKA after AD of the knee and assess the clinical outcome, complications, surgical technique, patient-related outcome measures and methodological quality.

Materials and methods

The reporting of this meta-analysis is in accordance to the PRISMA guidelines [13].

Literature search

We adapted a search strategy (see ‘Appendix’) using the following bibliographies up to and including August 2015: PubMed, Embase, Web of Science, Cochrane, CENTRAL, CINAHL, Academic Search Premier, ScienceDirect, with additional searching by hand. We identified all articles on TKAs after AD. Two independent reviewers (W.K. and W.V.) reviewed all titles and abstracts for inclusion. Studies were included when the title or the abstract met the following criteria: conversion of knee AD to TKA, simultaneously conversion of hip arthrodesis to total hip arthroplasty, a minimum of five cases and non-oncology patients. Papers in English, German, French, Dutch, Italian and Spanish were considered for inclusion. If no consensus was reached on whether to include the study by reviewing the title and abstract, the entire article was read.

Quality assessment

The methodological quality of all included studies was assessed with the use of the Assessment of Quality In Lower Limb Arthroplasty (AQUILA) checklist, a tool specifically designed to appraise the quality of observational studies concerning total hip (THA) and knee replacement [14, 15]. Two authors (W.K. and W.V.) independently assessed the quality of all included studies using predefined data extraction sheets. Inconsistencies between the two authors were resolved by consensus.

Data extraction

Data were extracted independently by two authors (W.K. and B.P.) using an electronic data collection sheet. Data consisted of study characteristics, patient demographics, clinical outcome (range of motion [ROM], extension lag, pain) and complications (e.g. infection, refusion). Additionally, the surgical technique was reviewed. In case of non-parametric data, the mean and standard deviation (SD) were calculated according to internationally accepted guidelines or the SD was estimated according to the weighted variance method [16].

Summary measures and synthesis of results

After AD of the knee, all postoperative improvement of function after TKA is due to the surgical intervention. The meta-analysis was based on the assumption that each patient can be considered to be its own control [17]. All data were combined for meta-analysis with the random effects model according to the pooled Mantel-Haenszel test for risk differences (RDs) and the pooled standard error for mean differences (MDs). All analyses were performed with the metafor package for R version 2.13 [18]. Heterogeneity between studies was tested with the I^2 statistic. This test describes the variation across studies that are due to heterogeneity. Possible sources of heterogeneity were explored with meta-regression using the random-effects regression model which previously has been used to study the effectiveness of the BCG vaccine against tuberculosis [19]. This model searches for modifying variables that affect the outcome of interest between studies and therefore can help resolve contradictory outcomes of different studies. In the present study, we focused on patient-specific variables (age, gender, initial diagnosis for AD, time to conversion after AD, etc.) that could influence the gain in ROM.

Results

Literature review

The search strategy revealed a total of 944 hits. A search by hand identified three more eligible studies. After removal of the duplicates, 866 unique papers remained. Screening of titles and abstracts revealed 31 papers eligible for inclusion. Further assessment of eligibility, based on full-text papers, led to the exclusion of 25 papers: 12 papers described less than five cases, six papers did not concern knee AD to TKA conversion, three papers considered only knee ankylosis to TKA conversions, two papers included patients of an earlier performed study by the same research group, one paper concerned oncology patients and one paper was a review. This left six papers for further analysis; 123 knees were available for meta-analysis [3–5, 7, 12, 20]. Details of these studies are

presented in Table 1. The follow-up in the six papers ranged from 0.2 to 20.2 years.

Clinical outcome

The meta-analysis on five studies including 105 patients showed that postoperatively there was an average improvement of 80° flexion (95 % CI, 67–92°; $p < 0.001$) after TKA (Fig. 1). The results of the meta-regression indicated that the type of TKA influenced the postoperative gain in ROM favouring semi-constrained (SC) TKA over posterior stabilised (PS) TKA. For every 10 % more semi-constrained TKA in a study, the postoperative ROM increased 2.3° (95 % CI, 0.2–4.4°; $p = 0.03$). For every 10 % more posterior stabilised TKA in a study, the postoperative ROM decreased 2.2° (95 % CI, 0–4.3°; $p = 0.05$). Age, gender and reason for fusion were not associated with postoperative ROM. With the number and data available, the influence of surgical techniques (e.g. VY quadricepsplasty) on clinical outcome could not be evaluated. The meta-analysis on three studies including 81 patients showed that on average there was 13° extension lag (95 % CI, 6–20°; $p < 0.001$) after TKA. The increase in Hospital for Special Surgery Score (HSS) score was on average 20 points (95 % CI, 11–29 points; $p < 0.001$) after TKA, based on two studies, 43 knees. The meta-analysis on three studies including 76 patients showed that on average there were 18 % of patients with moderate-to-severe pain (95 % CI, 0–45 %).

Complications

The complications are shown in Table 2. The meta-analysis on five studies including 105 patients showed an incidence of 25 % of skin necrosis (95 % CI, 6.3–43 %). The meta-analysis on six studies including 123 patients showed that the incidence of infection was 11 % (95 % CI, 5–17 %), or revision 11 % (95 % CI, 1.9–21 %), or refusion of the knee 4.9 % (95 % CI, 0.3–9.4 %) and an event-free course, indicating no complications had occurred in 35 % of the cases (95 % CI, 22–47 %).

Surgical technique

Preoperatively, Cameron and Hu [4] used a tissue expander in one patient to provide adequate skin coverage. The preferred incision was a medial parapatellar approach, when useable prior incisions are present, the most lateral one was chosen in order to minimise the revascularisation of the lateral skin [3–5]. If the patella was fused to the femoral condyles, an osteotomy was performed to mobilise the patella from its femoral attachment without damaging the extensor mechanism [3, 5, 7]. In order to achieve adequate surgical exposure, a tibial tubercle osteotomy was performed; refixation was done with two to three screws [3–5, 7, 12]. The tibiofemoral fusion site was osteotomised at the estimated junction with care taken to preserve bone stock [3, 5]. In order to overcome the quadriceps contraction, some authors performed a VY quadricepsplasty to enhance postoperative knee flexion [3, 12]. Soft tissue releases were performed as needed to correct angular and flexion deformity [3–5, 12]. Henkel et al. [7] resurfaced the patella in two cases. Careful attention should be given to the collateral ligaments during surgery for potential deficiency or dysfunction [3, 7]. Different types of prosthesis were used: non-constrained [7], semi-constrained [4, 5], posterior stabilised [3, 4], constrained [7] and rotational true hinge [4]. Adequately preserved soft-tissue sleeves of the knee joint allow the use of a less constrained type of knee prosthesis [3, 7].

Patient related outcome measures

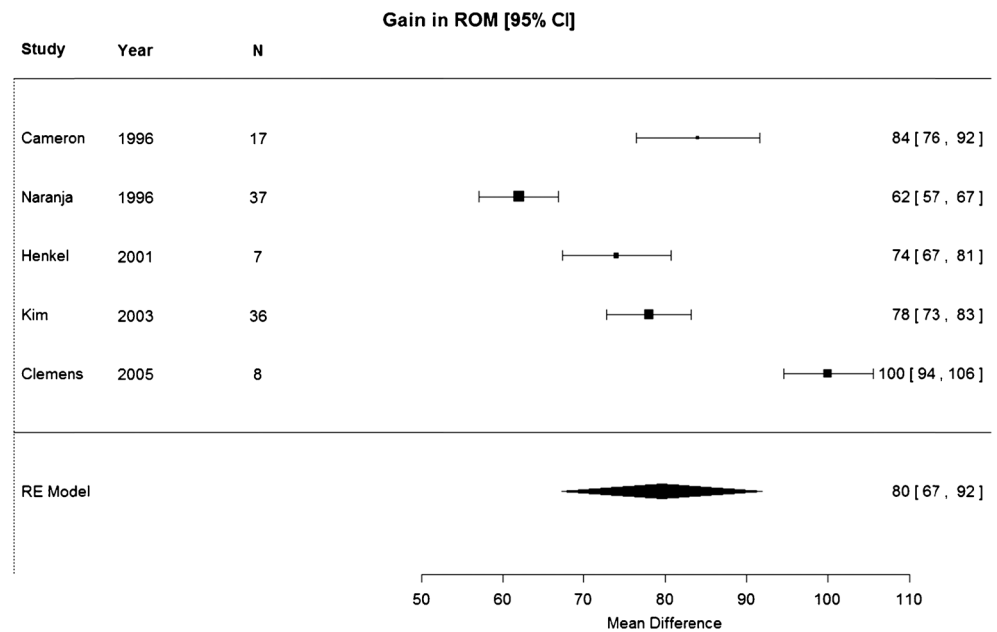
One study reported on patient reported outcome measures using validated questionnaires [5]. The mean WOMAC and EQ5D questionnaires were 37 (range, 9–47) and 0.7 (range, 0.1–0.8). Pain scores varied from 3 to 14 out of a possible 0–20 points, and with a mean of 7.8. In the study of Henkel et al. [7], the HSS pain score decreased from 22.5 to 19 out of a possible 0–30 points. In the study by Naranja et al. [12] 27 patients had no pain, three had mild pain, three had moderate

Table 1 Details of included studies for meta-analysis

Study	Year	<i>n</i>	Age	Gender	Reason fusion INF/OA, RA or other diagnosis	TKA PS/SC/hinge	Mean follow-up (range)
Cameron	1996	17	59	7	11/4/2	5/9/3	NA (1–10)
Naranja	1996	37	53	28	7/28/2	NA	7.5 (0.2–20.2)
Kreder	1999	18	61	7	NA	NA	4 (NA)
Henkel	2001	7	58	6	5/2/0	4/3/0	4.7 (1.3–5.4)
Kim	2003	36	39	16	34/2/0	36/0/0	7.7 (5–9)
Clemens	2005	8	51	6	1/3/4	0/8/0	2.7 (0.7–4.6)

Gender number of females, *INF* infection, *OA*, *RA* osteoarthritis, rheumatoid arthritis, *PS* posterior stabilised, *SC* semi-constrained, *NA* not available

Fig. 1 Improvement of flexion after TKP for patients with previous arthrodesis



and two had severe pain. Kim et al. [3], found 22 patients to be free of pain, and 14 with mild pain after prolonged walking.

All but one paper [20] mentioned patient satisfaction. Most patients are satisfied with their TKA and prefer their knee prosthesis to their fused one, even after a complicated postoperative course, walking with a cane or experiencing persistent postoperative pain [3–5]. Naranja et al. [12] found a satisfactory result in 29 % of their cases: these patients had no postoperative pain and were able to walk an unlimited distance. Regarding satisfaction, Henkel et al. [7] reported two patients with excellent satisfaction, three were satisfied and two were disappointed with their postoperative results.

Quality assessment

The methodological quality assessment was carried out with the use of the AQUILA checklist. The mean AQUILA score

was 4.3 (out of possible 11) ranging from 3 to 8. Three out of six studies clearly stated a primary research question or hypothesis and three studies had enrolled subjects consecutively. Follow-up was predefined in only one study, and one study had patients seen if complaints occurred. Follow-up was complete for one study, two studies had over 5 % of loss to follow-up and for three studies the adequacy of follow-up was unknown.

Discussion

The results of our meta-analysis show that on average there was 80° (95 % CI, 67–92°) improvement of flexion during a mean follow up of 5.5 years. The postoperative improvement of flexion was only influenced by type of TKA slightly favouring semi-constrained TKA over posterior stabilised

Table 2 Complication rates as determinate with random effects meta-analysis

Complication	Number of studies	Number of knees	Incidence	95 % CI
Event free	6	123	35 %	22–47 %
Skin necrosis	5	105	25 %	6.3–43 %
Arthrofibrosis	5	105	13 %	1.8–24 %
Revision	6	123	11 %	1.9–21 %
Infection	6	123	11 %	5–17 %
Extensor problem	5	105	5.6 %	1.3–9.9 %
Refusion	6	123	4.9 %	0.3–9.4 %
Death	6	123	2.7 %	0–5.4 %
Amputation	5	105	2.2 %	0–5 %
Myositis ossificans	5	105	1.8 %	0–4.2 %

TKA. The extensor lag was on average 13 degrees. There was a clinically relevant and statistically significant increase in HSS score: 20 points (95 % CI, 11–29 points). The extension lag was a mean of 13° (95 % CI, 6–20°). Most patients were pain-free or experienced only slight pain. Most patients were satisfied. The procedure is associated with a high rate of post-operative complications; the majority of the patients (65 %) experienced at least one complication. The most frequent complication was skin necrosis, followed by arthrofibrosis, infection and early revision. Major complications, such as refusal, amputation and death, were seen in less than 5 % of all cases. Nevertheless, most patients—including those with a complicated postoperative course—preferred their mobile knee to the fused knee [3–5].

Surgical technique is paramount. The skin of the knees after AD conversion to TKA is exposed to significant stretch and might not be able to tolerate the tension that is placed upon it. In order to reduce the incidence of skin necrosis, skin grafting [3], vascularised gastrocnemius flap [4, 5, 7] and tissue expanders [4] have been used. Mahomed et al. [11] was the first to mention the use of soft-tissue expanders in AD conversion to TKA. They found that the use of soft-tissue expanders helped to provide adequate soft tissue for wound closure in their patients. No problems with wound dehiscence or skin sloughing were seen and they stated that the extensor mechanism might have been better mobilised due to using the expanders aiding for excellent ROM. This was confirmed in the study carried out by Cho et al. [6]. Adequate exposure can also be difficult as the patella is often fused to the femur requiring an osteotomy; in addition, a tibial tubercle osteotomy is often necessary. Kim et al. [3], have used a VY quadricepsplasty to lengthen the quadriceps muscle, avoid patellar tendon avulsion, facilitate exposure and improve ROM. Their rehabilitation ranged from 6 to 20 months to overcome the weakness of the prolonged quadriceps muscle [3]. Cameron and Hu [4] advocated against lengthening the extensor apparatus because the quadriceps is seldom adhered to the femur and a release is relatively easy. In addition, flexion improves with time and exercise [4]. Clemens et al. [5] preoperatively assessed the muscle strength of both quadriceps and hamstrings in three patients showing deficits of 75 % and 78 % for quadriceps and hamstrings respectively. Postoperative extension lag might, therefore, be related to overall weakness of the extensor apparatus.

Anterior ‘overstuffing’ could result in increased tension of soft tissue, difficulties for wound closure and impaired post-operative function. In order to avoid anterior overstuffing Cameron and Hu [4] suggested placing the femoral component as posteriorly as possible and reducing the patellar thickness. In case a stemmed femoral component is used, a very thin anterior flange with a very deep trochlea is preferred [4]. Balancing of collateral ligaments is paramount, because collateral laxity may require a constrained prosthesis. A patellar

component is not always appropriate. With knees in fixed extension, a posterior cruciate ligament (PCL) sacrificing design should be anticipated in order to allow release of the PCL and maximise the flexion potential. It has been advocated to use a constrained prosthesis to substitute for absent or deficient collateral ligaments [6, 7]. In case of collateral ligament instability, care should be taken not to use polyethylene thicker than 18 mm, as this has been shown to elevate the joint line, increase patellar instability and to complicate skin closure [4]. However, Kim et al. [3] showed that adequately preserved soft-tissue sleeves were able to provide stability and were able to use a relatively non-constrained posterior stabilised TKA.

We should also consider some limitations. Most studies were of low-to-moderate methodological quality: the majority of studies did not describe a well-defined primary research question or hypothesis, or missed a predefined follow-up procedure. Included studies consisted of small case series; leaving 123 knees for analysis in this study; therefore, no definitive conclusions could be demonstrated. The most recent included paper was published in 2005, dealing with patients who were operated on between 1998 and 2002. Therefore, there is a need for high methodological quality patient series using contemporary prosthesis and surgical technique. As only one of the included studies reported PROMs [5], future studies should also include PROMs.

In conclusion, for most patients good clinical results are achieved albeit at a high risk of postoperative complications. Conversion of AD to TKA should, therefore, only be performed on a highly individualised basis with both patients and surgeons being aware of the clinical results and complications. Future studies should include PROMs and could benefit from improved methodological design.

Compliance with ethical standards

Conflicts of interests None.

Appendix

PubMed search strategy

```
((("knee arthrodeses"[tw] OR "knee arthrodesing"[tw] OR "knee arthrodesis"[tw] OR "knee fusion"[tw] OR "knee fusions"[tw] OR "fusion of knee"[tw] OR "fused knee"[tw] OR "fused knees"[tw]) AND ("Arthroplasty, Replacement, Knee"[Mesh] OR "Knee Replacement"[tw] OR "Knee Replacements"[tw] OR "Total Knee"[tw] OR "Knee Prosthesis"[mesh] OR "Knee Prosthesis"[tw] OR "Knee Prostheses"[tw] OR "Knee Prothesis"[tw] OR "Knee Protheses"[tw]) AND "total"[tw]) OR ("Arthrodesis"[Mesh:noexp] OR "arthrodesis"[tw] OR "arthrodeses"[tw] OR arthrodes*[tw] OR "arthodesis"[tw] OR "arthodeses"[tw] OR arthodes*[tw] OR "joint fusion"[tw]
```

OR "knee arthrodeses"[tw] OR "knee arthrodesing"[tw] OR "knee arthrodesis"[tw] OR "knee fusion"[tw] OR "knee fusions"[tw] OR "fusion of knee"[tw] OR "fused knee"[tw] OR "fused knees"[tw] AND ("Total Knee"[tw] OR "Total Knees"[tw]))

Details of the search strategies for all consulted databases can be obtained from the authors.

Open Access This article is distributed under the terms of the Creative Commons Attribution 4.0 International License (<http://creativecommons.org/licenses/by/4.0/>), which permits unrestricted use, distribution, and reproduction in any medium, provided you give appropriate credit to the original author(s) and the source, provide a link to the Creative Commons license, and indicate if changes were made.

References

- Conway JD, Mont MA, Bezwada HP (2004) Arthrodesis of the knee. *J Bone Joint Surg Am* 86-a(4):835–848
- Kim YH, Kim JS, Cho SH (2000) Total knee arthroplasty after spontaneous osseous ankylosis and takedown of formal knee fusion. *J Arthroplast* 15(4):453–460. doi:10.1054/arth.2000.4640
- Kim YH, Oh SH, Kim JS (2003) Conversion of a fused knee with use of a posterior stabilized total knee prosthesis. *J Bone Joint Surg Am* 85-a(6):1047–1050
- Cameron HU, Hu C (1996) Results of total knee arthroplasty following takedown of formal knee fusion. *J Arthroplast* 11(6):732–737
- Clemens D, Lereim P, Holm I, Reikeras O (2005) Conversion of knee fusion to total arthroplasty: complications in 8 patients. *Acta Orthop* 76(3):370–374
- Cho SH, Jeong ST, Park HB, Hwang SC, Kim DH (2008) Two-stage conversion of fused knee to total knee arthroplasty. *J Arthroplast* 23(3):476–479. doi:10.1016/j.arth.2007.06.013
- Henkel TR, Boldt JG, Drobny TK, Munzinger UK (2001) Total knee arthroplasty after formal knee fusion using unconstrained and semiconstrained components: a report of 7 cases. *J Arthroplast* 16(6):768–776. doi:10.1054/arth.2001.24375
- Ruggieri P, Kasimatis G, Errani C, Bosco G, Mercuri M (2010) Desarthrodesis and prosthetic reconstruction of the knee after resection of bone tumors. *J Surg Oncol* 102(7):832–837. doi:10.1002/jso.21726
- Jamshidi K, Hadi H, Ramezan Shirazi M, Moslem A (2013) Conversion of fused knee following distal femur tumor surgery to total knee arthroplasty. *Iran Red Crescent Med J* 15(9):870–872. doi:10.5812/ircmj.7693
- Cermak K, Baillon B, Tsepedidis D, Vancabeke M (2013) Total knee arthroplasty after former knee fusion in a patient with Ehlers Danlos syndrome. *Acta Orthop Belg* 79(3):347–350
- Mahomed N, McKee N, Solomon P, Lahoda L, Gross AE (1994) Soft-tissue expansion before total knee arthroplasty in arthrodesed joints. A report of two cases. *J Bone Joint Surg (Br)* 76(1):88–90
- Naranjan RJ Jr, Lotke PA, Pagnano MW, Hanssen AD (1996) Total knee arthroplasty in a previously ankylosed or arthrodesed knee. *Clin Orthop Relat Res* 331:234–237
- Liberati A, Altman DG, Tetzlaff J, Mulrow C, Gotzsche PC, Ioannidis JP, Clarke M, Devereaux PJ, Kleijnen J, Moher D (2009) The PRISMA statement for reporting systematic reviews and meta-analyses of studies that evaluate healthcare interventions: explanation and elaboration. *BMJ (Clin Res Ed)* 339:b2700. doi:10.1136/bmj.b2700
- Pijls BG, Dekkers OM, Middeldorp S, Valstar ER, van der Heide HJ, Van der Linden-Van der Zwaag HM, Nelissen RG (2011) AQUILA: assessment of quality in lower limb arthroplasty. An expert Delphi consensus for total knee and total hip arthroplasty. *BMC Musculoskelet Disord* 12:173. doi:10.1186/1471-2474-12-173
- Cowan JB, Mlynarek RA, Nelissen RG, Pijls BG, Gagnier JJ (2015) Evaluation of Quality of Lower Limb Arthroplasty Observational Studies Using the AQUILA Checklist. *J Arthroplast*. doi:10.1016/j.arth.2015.03.020
- Hozo SP, Djulbegovic B, Hozo I (2005) Estimating the mean and variance from the median, range, and the size of a sample. *BMC Med Res Methodol* 5:13. doi:10.1186/1471-2288-5-13
- Kim YH, Oh SH, Kim JS (2003) Conversion of a fused knee with use of a posterior stabilized total knee prosthesis. *J Bone Joint Surg Am* 85(6):1047–1050.e1942. doi:10.1016/j.jhsa.2014.06.003
- Viechtbauer W (2010) Conducting meta-analyses in R with the metafor package. *J Stat Softw* 36(33):31–48
- Colditz GA, Brewer TF, Berkey CS, Wilson ME, Burdick E, Fineberg HV, Mosteller F (1994) Efficacy of BCG vaccine in the prevention of tuberculosis. Meta-analysis of the published literature. *JAMA* 271(9):698–702
- Kreder HJ, Williams JI, Jaglal S, Axcell T, Stephen D (1999) A population study in the Province of Ontario of the complications after conversion of hip or knee arthrodesis to total joint replacement. *Can J Surg* 42(6):433–439