



Universiteit
Leiden
The Netherlands

Surgical solutions for complex aortic root pathology

Schneider, A.W.

Citation

Schneider, A. W. (2021, September 15). *Surgical solutions for complex aortic root pathology*. Retrieved from <https://hdl.handle.net/1887/3210132>

Version: Publisher's Version

License: [Licence agreement concerning inclusion of doctoral thesis in the Institutional Repository of the University of Leiden](#)

Downloaded from: <https://hdl.handle.net/1887/3210132>

Note: To cite this publication please use the final published version (if applicable).

Cover Page



Universiteit Leiden




The handle <https://hdl.handle.net/1887/3210132> holds various files of this Leiden University dissertation.

Author: Schneider, A.W.

Title: Surgical solutions for complex aortic root pathology

Issue Date: 2021-09-15



STENTLESS BIOPROSTHESES:

*A versatile and durable solution in
extensive aortic valve endocarditis*

Adriaan W. Schneider, Mark G. Hazekamp, Michel I.M. Versteegh, Eline F.
Bruggemans, Eduard R. Holman,
Robert J.M. Klautz, Jerry Braun

Eur J Cardiothorac Surg 2016;49:1699–704

Presented at the 29th Annual Meeting of the European Association for
Cardio-Thoracic Surgery, Amsterdam, Netherlands, 3–7 October 2015.

ABSTRACT

OBJECTIVES

Infective endocarditis of the aortic valve with local aortic root destruction requires radical resection of infected tissues and subsequent reconstruction of periannular structures and the left ventricular outflow tract (LVOT). Homografts or stentless bioprostheses are recommended for use in this specific patient group. The Freestyle stentless bioprosthesis is a porcine aortic root prosthesis, which approaches the surgical versatility of the homograft, but has the advantage of ready availability and uniform quality. We assessed clinical and echocardiographic outcome following the use of this prosthesis in extensive aortic valve endocarditis.

METHODS

Between June 2000 and December 2014, 55 Freestyle prostheses were implanted for aortic valve endocarditis involving the root in 54 patients (74% male). The mean age at operation was 61 ± 13 years. The mean EuroSCORE II was 20.1 ± 13.5 . Twenty-nine (54%) patients had prosthetic valve endocarditis. The median follow-up time after surgery was 3.5 years, ranging from 0 to 15 years.

RESULTS

Early and late mortality were 11% (6 patients) and 14% (7 patients), respectively. Estimated overall survival at 1 and 5 years was 83 and 70%, respectively. There was no survival difference between patients with native or prosthetic valve endocarditis. One patient underwent reoperation for recurrent endocarditis 2.3 years after the initial procedure. No other prosthesis failure occurred. At a median follow-up of 3.3 years, mean gradient over the prosthesis was 4.3 ± 2.3 mmHg. No patient had more than mild aortic regurgitation.

CONCLUSIONS

The Freestyle stentless bioprosthesis is a valuable option to reconstruct the LVOT after debridement in extensive aortic valve endocarditis. It is readily available with a versatility and clinical outcome comparable with that of homografts. Although early mortality remains considerable in this high-risk group of patients, late survival is good with low rates of recurrence of endocarditis, immediate local control and good haemodynamic performance on echocardiography.

INTRODUCTION

Infective endocarditis (IE) is a serious condition with in-hospital mortality rates ranging from 15 to 30%, even when treated with antibiotics or surgical interventions [1]. Patients with aortic valve endocarditis with extended local destruction of the aortic root and adjacent structures have even worse prognosis, with mortality rates of up to 79% [1]. Early surgery is indicated in patients with IE complicated by heart block, annular or aortic abscess, destructive penetrating lesions or as prevention of embolism in patients with vegetations larger than 15 mm or large (>10 mm) vegetations following one or more embolic episodes [1, 2]. Surgery comprises radical resection of all infected tissues followed by reconstruction of periannular structures and the left ventricular outflow tract (LVOT). Several techniques and prostheses are available to perform this reconstruction. The choice of prosthesis depends on the surgeon's preference and intrinsic factors of the prosthesis used, such as resistance to infection, pliability, durability and availability.

In patients with complicated IE involving the aortic root, European guidelines advise the use of homografts or stentless bioprostheses to reconstruct the LVOT [1]. The Society of Thoracic Surgeons considers homografts to be the gold standard in extended endocarditis [3]. Due to the limited availability of homografts and the equal durability of homografts and stentless bioprostheses, the use of stentless bioprostheses in this subset of patients has increased [4]. These prostheses approach the surgical versatility of homografts due to their shape and pliability, but have the advantage of ready availability and uniform quality. The Medtronic Freestyle stentless bioprosthesis (Medtronic, Inc., Minneapolis, MN, USA) is a porcine aortic root prosthesis with documented good long-term clinical and haemodynamic outcomes [5, 6]. We evaluated outcomes of patients with IE of the aortic valve with root destruction in whom the Freestyle stentless bioprosthesis was used, in order to assess the value of this prosthesis in this patient group.

MATERIALS AND METHODS

This study was approved by the local ethics committee. Between June 2000 and December 2014, 54 patients with IE of the aortic valve with extensive root involvement underwent surgery including implantation of a Freestyle stentless bioprosthesis. Data were collected prospectively in the database of the

department of cardiothoracic surgery and retrospectively analysed. Clinical and echocardiographic follow-up data were collected through outpatient clinic visits, by contacting referring cardiologists and, if needed, through telephone calls with patients. IE was diagnosed according to the modified Dukes criteria [7]. Antibiotic treatment was started after blood cultures were taken. When patients remained haemodynamically stable, surgery was planned not within 48 h after the initiation of antibiotic treatment directed at the causative micro-organism and depending on echocardiographic parameters. Urgent surgery (<48 h) was performed only in patients who deteriorated clinically. Antibiotic treatment was typically continued for 6 weeks after surgery. In patients with septic emboli, antibiotic treatment was continued for a longer period, depending on size and location.

Operative technique

All patients were operated through median sternotomy using standard techniques for extracorporeal circulation. Antegrade warm blood cardioplegia was used for cardioprotection in all patients. The aortic valve and all macroscopically infected tissues were carefully removed and sent for microbacterial culture. This included the roof of the left atrium, the aortic-mitral continuity and, if necessary, parts of the mitral valve (usually the body of the anterior leaflet). Reconstruction of the resected structures was performed with xenopericardial patch material. If the mitral valve was involved, it was reconstructed or replaced through the roof of the left atrium. If the free edge of the anterior mitral valve leaflet was intact, an annuloplasty ring was first implanted in the region of the posterior leaflet, followed by reconstruction of the body of the anterior leaflet with a pericardial patch, up to the ring. In case of more extensive involvement of the mitral valve, the valve was excised and replaced with sutures placed only in the posterior part of the annulus, covering two thirds to three quarters of the prosthesis. Next, a folded xenopericardial patch was attached to the ring with its fold. After unfolding, one part of the patch was used to reconstruct the roof of the left atrium and the other part to reconstruct the aortic-mitral continuity and LVOT in the region of the non-coronary sinus. The aortic root was then replaced with a Freestyle stentless prosthesis (Medtronic, Inc., Minneapolis, MN, USA) sutured in the LVOT with interrupted TiCron 4-0 sutures. Coronary buttons were reimplemented using running Prolene 5-0 sutures (Ethicon, Somerville, NJ, USA). The distal anastomosis was made using a running Prolene 4-0 or 5-0 suture. Depending on anatomical

features, the prosthesis was rotated 120° for optimal placement of the coronary buttons. The remaining coronary button of the prosthesis was oversewn.

Definitions and statistical analysis

Data are reported according to the guidelines for reporting mortality and morbidity after cardiac valve interventions [8]. Echocardiographic follow-up data were acquired through transthoracic echocardiography (TTE) in our outpatient clinic or from the referring cardiologist. Follow-up closed on 1 September 2015.

Continuous variables are expressed as mean \pm standard deviation or median and range, as appropriate. Categorical data are expressed as numbers and percentages. Estimates of overall survival were calculated using the Kaplan–Meier method and expressed as percentages with 95% confidence interval (CI). Survival curves were compared using the log-rank test. Survival analysis was performed using GraphPad Prism 6 (GraphPad Software, Inc., La Jolla, CA, USA). All other analyses were performed using the statistical software package SPSS 20 (IBM Corp., Armonk, NY, USA). A *P*-value of less than 0.05 (two-sided) was considered statistically significant.

RESULTS

Patients

Fifty-four consecutive patients with extensive aortic valve endocarditis were operated. Twenty-nine (54%) patients had prosthetic valve endocarditis (19 mechanical prostheses, 2 homografts). Patient demographics are presented in Table 1 and microbiologic data are presented in Table 2. Blood cultures remained negative in 9 (16%) patients. Guided antibiotic treatment was initiated as described and typically continued for 6 weeks after surgery. In selected patients, antibiotic treatment was continued for a longer period (i.e. endocarditis caused by propionibacterium species, or patients with septic emboli or peripheral abscess formation). The median duration of preoperative guided antibiotic pretreatment was 10 days (range, 0–70 days). The median duration of total antibiotic treatment was 53 days (range, 35–481 days).

Table 1: Patient demographics

Patient demographics	n (%)
n	54
Age (years, mean \pm SD)	61.1 \pm 13.4
Male	40 (74)
Poor LVF (EF \leq 40)	1 (2)
eGFR $<$ 50 ml/min/1.73 m ²	9 (17)
Preoperative renal dialysis	3 (6)
Prior cerebrovascular accident	10 (19)
Previous cardiac surgery	34 (63)
Previous aortic valve replacement	29 (54)
Logistic EuroSCORE I (mean \pm SD)	42.6 \pm 19.4
EuroSCORE II (mean \pm SD)	20.1 \pm 13.5
Antibiotic pretreatment (days, median; range)	10; range 0–70
Preoperative septic emboli	13 (24)
Cerebral	6 (11)

EF: ejection fraction; eGFR: estimated glomerular filtration rate; LVF: left ventricular function; SD: standard deviation.

Table 2: Microbiologic data

Micro-organism in culture	n (%)
<i>Staphylococcus aureus</i>	13 (24)
<i>Staphylococcus epidermidis</i>	2 (4)
CNS n.o.s.	2 (4)
Propionibacterium	7 (13)
<i>Streptococcus bovis</i>	1 (2)
<i>Streptococcus pneumoniae</i>	2 (4)
Other <i>Streptococcus</i> spp.	10 (18)
<i>Enterococcus faecalis</i>	8 (15)
Culture negative	9 (16)

n.o.s.: not otherwise specified; CNS: coagulase-negative *Staphylococcus*.

Operative details

The mean cardiopulmonary bypass time was 283 \pm 91 min and the mean aortic cross-clamping time was 219 \pm 69 min. Five patients were operated under deep hypothermic circulatory arrest with antegrade cerebral perfusion (mean duration 22 \pm 12 min) for replacement of the distal ascending aorta or proximal aortic arch. One patient with abscess extension into the right ventricular outflow tract and pulmonary valve underwent concomitant pulmonary valve replacement with a

Freestyle stentless bioprosthesis. Other concomitant procedures are presented in Table 3 .

Table 3: Operative details

Operative details	<i>n</i> (%)
Concomitant procedures	
Coronary artery bypass grafting	10 (18)
Mitral valve replacement	6 (11)
Mitral valve repair	13 (24)
Tricuspid valve repair	5 (9)
Pulmonary valve replacement	2 (4)
Aortic-mitral continuity reconstruction	9 (16)
Hemiarch replacement	1 (2)
Prosthesis size	
21 mm	1 (2)
23 mm	9 (16)
25 mm	16 (29)
27 mm	12 (22)
29 mm	17 (31)

Early mortality and postoperative complications

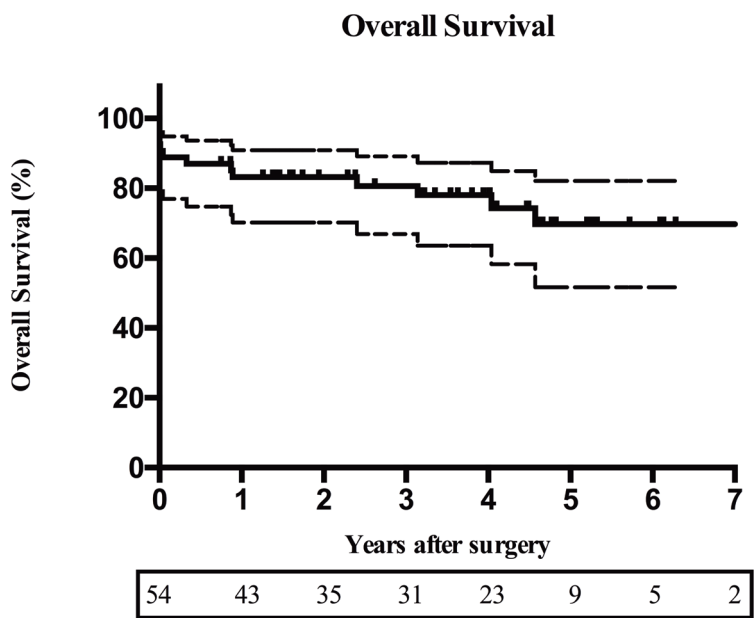
There were 6 (11%) early deaths, all in-hospital, 2 of which during surgery due to left and right ventricular failure, respectively. All patients but one in the early death group were operated for prosthetic valve endocarditis. Two patients died of multiorgan failure, 1 patient had right ventricular failure, 1 patient had left ventricular failure and 1 patient had intractable circulatory failure secondary to sepsis. The patient with native valve endocarditis died of postanoxic encephalopathy after cardiopulmonary resuscitation for cardiac arrest.

Temporary circulatory support was necessary in 3 patients using intra-aortic balloon counterpulsation, 1 patient needed additional extracorporeal membrane oxygenation support. Six patients had postoperative kidney failure requiring temporary haemodialysis. Five patients underwent reoperation for bleeding. Thirteen patients required permanent pacemaker implantation. In all patients, the operation achieved local control of the infection.

Long-term survival

Follow-up was complete in all patients. Median follow-up time was 3.5 years, ranging from 0 to 15 years, and consisted of 180 patient-years. Estimated overall survival at 1 and 5 years was 83 (95% CI: 70–91%) and 70% (95% CI: 52–82%), respectively. Seven cases of late mortality were observed at postoperative days 121, 316 and 325, and after 2.4, 3.1, 4.0 and 4.6 years postoperatively (Fig. 1). Causes of death were acute myocardial infarction, intestinal ischaemia, respiratory insufficiency after surgery on the mitral valve, congestive heart failure, urosepsis, acute myeloid lymphoma and pancreatic carcinoma, respectively.

Figure 1:



Kaplan–Meier curve of estimated overall survival. Dashed lines denote 95% confidence interval. Numbers under the curve depict numbers at risk.

Valve-related events

One patient developed endocarditis with pneumococcus species 2.3 years after surgery. There was extensive involvement of adjacent structures (left main coronary artery, roof of the left atrium, left atrial appendage and anterior mitral

valve leaflet). After resection of all infected tissues, a bovine pericardial patch was used to reconstruct the LVOT and a new Freestyle prosthesis was implanted. The patient was put on lifelong antibiotic Pneumococcus prophylaxis. At latest follow-up, the patient was doing well and TTE showed good function of the Freestyle prosthesis. No other valve-related event was seen during follow-up.

Echocardiographic follow-up

Echocardiographic follow-up in alive patients was 100% complete. At latest echocardiographic follow-up (median follow-up time: 3.3 years; range, 0.2–14.2 years), all prostheses were functioning well. Mean gradients across the valve were 7.2 ± 4.2 mmHg peak and 4.3 ± 2.3 mmHg mean gradient. No patient had more than mild aortic regurgitation.

DISCUSSION

IE of the aortic valve with extended aortic root involvement remains a clinically and surgically challenging condition. After resection of all infected tissues, several approaches are available to reconstruct the destructed geometry of the LVOT and adjacent structures. Patch reconstruction followed by mechanical or biological valve replacement, homograft root replacement or stentless bioprosthetic root replacement are all part of the surgeon's armamentarium. Guidelines do not specifically favour either mechanical or biological prostheses since mortality and recurrence of endocarditis rates are similar, provided that complete resection of all infected tissues is assured [1]. However, they do support the use of homografts or stentless bioprostheses in IE patients with periannular abscess formation. The advantage of homografts and stentless bioprostheses is their versatility during implantation in anatomically challenging situations. Several studies have reported outcomes of homografts in IE. A 20-year follow-up study in 221 patients who received an aortic homograft for extensive IE reported an early mortality rate of 16.2% for patients with native valve endocarditis and 25.4% for patients with prosthetic valve endocarditis. Reported freedom from reoperation for recurrent endocarditis after 10 years was 92% and comparable between the native and prosthetic valve endocarditis groups (92.9 and 92.1%, respectively) [9]. Another group described a hospital mortality rate of 24% in 69 patients with IE who received aortic homografts (61 implanted as full root). In this group, 7% had recurrent endocarditis, predominantly early after surgery [10].

Because suitable homografts are scarce, the use of stentless bioprostheses in patients requiring aortic root replacement has gained popularity. The versatility of the Freestyle prosthesis is comparable with that of a homograft. Implantation of the prosthesis as a full root replacement maintains the normal anatomical relations. Depending on the extent of resection of the LVOT, the prosthesis can be placed below the annular level at the aortic-mitral continuity, at the annular level or even above the level of the original annulus.

The Freestyle prosthesis has shown excellent long-term clinical and haemodynamic results [5, 11]. The present study focused on 54 patients who received the Freestyle stentless bioprosthesis for LVOT and aortic root reconstruction in extensive IE. Only a limited number of reports are available in which the outcomes of the Freestyle prosthesis in patients with extended IE are reported. A study by Heinz *et al.* [12] describing their experience with the Freestyle prosthesis in 32 IE patients reported an early mortality rate of 18.8%. Another study by Miceli *et al.* [13] in 18 patients reported 11.1% early mortality. Our early mortality rate of 11% in this very high-risk group of patients is similar. These mortality rates are comparable with the previously mentioned mortality rates after homograft implantation in IE patients [9, 10]. A study by El-Hamamsy *et al.* compared late outcomes of Freestyle versus homograft aortic root replacement for all indications in 166 patients with a median follow-up time of 7.6 years [4]. They concluded that late survival was similar in both groups, but progression of aortic valve dysfunction and need for reoperation was lower in the Freestyle group. This might be due to earlier onset of calcification in homografts compared with the Freestyle prosthesis [14].

The ideal timing of surgery in patients with IE is subject to debate. Congestive heart failure due to severe regurgitation or stenosis of the infected valve is a Class I indication for urgent surgery [1]. Furthermore, abscess formation and embolic risk from vegetations are reasons to consider urgent surgery [1, 15]. Although surgery in the active phase has higher risks, in patients with the most severe forms of IE it is associated with improved 6-month survival [15]. The risk of embolic events decreases after the start of antibiotic treatment, with an incidence of 4.8/1000 in the first week and 1.7/1000 in the second week of antibiotic treatment. Prevention of embolic events as the sole indication for surgery should therefore be rejected after 1 week of antibiotic treatment [16]. However, there is little gain in waiting to operate on these patients after the bloodstream is sterilized due to the antibiotics,

usually achieved within 48 h. As resection of all infected tissue is the cornerstone of this operation, waiting for tissues to be healed seems irrational. This is supported by a study by Kim *et al.* [17], who found that early surgery (within 7 days after diagnosis) in patients with severe valvular disease and large vegetations was associated with better clinical outcomes compared with postponing surgery.

Identifying vegetations and, especially, periannular abscesses with transoesophageal echocardiography (TOE) remains challenging. In our series, 8 of 35 abscesses were not identified on preoperative TOE. Hill *et al.* [18] described their experience with TOE detection of periannular abscesses in aortic and mitral valve endocarditis with findings during surgery as definitive diagnosis. They reported periaortic abscess detection with TOE in 63% of patients. Mitral abscesses were even more difficult to detect with a detection rate of 30%. In our series, missed abscesses occurred mainly in the earlier years of our experience, possibly related to improved TOE imaging over the last years. In general, the local destruction is more severe than might be expected from imaging modalities. Other imaging techniques, such as multislice computed tomography (CT) scans, might improve the identification of abscesses in IE and their extension in surrounding tissues [1, 19]. A study by Saby *et al.* demonstrated the added value of positron emission tomography/computed tomography (PET/CT) imaging in the diagnosis of IE [20]. PET/CT was able to identify infective processes in an earlier stage compared with TOE. Furthermore, whole body imaging was useful for detecting emboli, metastatic infection and occult primary tumours.

During follow-up, no patient required reoperation for structural valve deterioration, although it should be emphasized that follow-up was shorter than the expected durability of the Freestyle prosthesis. Like all other bioprostheses, the Freestyle prosthesis is subject to structural valve deterioration in time. There was 1 case of recurrent endocarditis 2.3 years after implantation. This low recurrence rate is most likely due to the aggressive nature of the surgery and the antibiotic treatment that we continue for a minimum of 6 weeks after surgery, both in native and prosthetic valve endocarditis patients. Although topical antibiotic treatment with rifampicin is applied to the LVOT, to the implanted prosthesis and to the sutures used to implant the valve, the additional benefit is difficult to assess.

Study limitations

This is a retrospective study with its inherent limitations. Since we do not use homografts on a large scale in adult patients, we could not compare our Freestyle data to that of homografts. A comparison of outcomes between homografts and the Freestyle prosthesis is thus based on available literature. A definite strength of this study, however, is that the vast majority of echocardiographic follow-up was performed in our institution, providing a homogeneous dataset and the clinical follow-up was 100% complete.

CONCLUSION

To our knowledge, this study describes the largest series of patients to receive a Freestyle stentless bioprosthesis for IE with local destruction of surrounding tissues. The prosthesis is a valuable option and its use should be considered in LVOT reconstruction after extensive debridement. Clinical outcomes in patients receiving this prosthesis are as good as those of patients receiving homografts, even in patients with IE. Haemodynamic performance is excellent, and the risk of recurrent aortic valve endocarditis is very low. Early mortality, however, remains relatively high in this group of patients.

FUNDING

This study was supported by an unrestricted research grant from Medtronic, Inc., Minneapolis, MN, USA.

Conflict of interest: none declared.

REFERENCES

1. Habib G, Lancellotti P, Antunes MJ, Bongiorni MG, Casalta J-P, Del Zotti F, et al. 2015 ESC Guidelines for the management of infective endocarditis: The Task Force for the Management of Infective Endocarditis of the European Society of Cardiology (ESC) Endorsed by: European Association for Cardio-Thoracic Surgery (EACTS), the European Association of Nuclear Medicine (EANM). *European Heart Journal* 2015;ehv319. doi:10.1093/eurheartj/ehv319.
2. Nishimura RA, Otto CM, Bonow RO, Carabello BA, Erwin JP, Guyton RA, et al. 2014 AHA/ACC guideline for the management of patients with valvular heart disease: a report of the American College of Cardiology/American Heart Association Task Force on Practice Guidelines. *Journal of the American College of Cardiology* 2014;63:e57–185. doi:10.1016/j.jacc.2014.02.536.
3. Byrne JG, Rezai K, Sanchez JA, Bernstein RA, Okum E, Leacche M, et al. Surgical Management of Endocarditis: The Society of Thoracic Surgeons Clinical Practice Guideline. *The Annals of Thoracic Surgery* 2011;91:2012–9. doi:10.1016/j.athoracsur.2011.01.106.
4. El-Hamamsy I, Clark L, Stevens LM, Sarang Z, Melina G, Takkenberg JJM, et al. Late outcomes following freestyle versus homograft aortic root replacement: results from a prospective randomized trial. *Journal of the American College of Cardiology* 2010;55:368–76. doi:10.1016/j.jacc.2009.09.030.
5. Bach DS, Kon ND. Long-Term Clinical Outcomes 15 Years After Aortic Valve Replacement With the Freestyle Stentless Aortic Bioprosthesis. *The Annals of Thoracic Surgery* 2014;97:544–51. doi:10.1016/j.athoracsur.2013.08.047.
6. Mohammadi S, Kalavrouziotis D, Voisine P, Dumont E, Doyle D, Perron J, et al. Bioprosthetic valve durability after stentless aortic valve replacement: the effect of implantation technique. *The Annals of Thoracic Surgery* 2014;97:2011–8. doi:10.1016/j.athoracsur.2014.02.040.
7. Li JS, Sexton DJ, Mick N, Nettles R, Fowler VG, Ryan T, et al. Proposed modifications to the Duke criteria for the diagnosis of infective endocarditis. *Clin Infect Dis* 2000;30:633–8. doi:10.1086/313753.
8. Akins CW, Miller DC, Turina MI, Kouchoukos NT, Blackstone EH, Grunkemeier GL, et al. Guidelines for reporting mortality and morbidity after cardiac valve interventions. *The Journal of Thoracic and Cardiovascular Surgery* 2008;135:732–8. doi:10.1016/j.jtcvs.2007.12.002.

9. Musci M, Weng Y, Hübler M, Amiri A, Pasic M, Kosky S, et al. Homograft aortic root replacement in native or prosthetic active infective endocarditis: twenty-year single-center experience. *The Journal of Thoracic and Cardiovascular Surgery* 2010;139:665–73. doi:10.1016/j.jtcvs.2009.07.026.
10. Flameng W, Daenen W, Jashari R, Herijgers P, Meuris B. Durability of homografts used to treat complex aortic valve endocarditis. *The Annals of Thoracic Surgery* 2015;99:1234–8. doi:10.1016/j.athoracsur.2014.11.002.
11. Mohammadi S, Tchana-Sato V, Kalavrouziotis D, Voisine P, Doyle D, Baillot R, et al. Long-Term Clinical and Echocardiographic Follow-Up of the Freestyle Stentless Aortic Bioprosthesis. *Circulation* 2012;126:S198–S204. doi:10.1161/CIRCULATIONAHA.111.084806.
12. Heinz A, Dumfarth J, Ruttman-Ulmer E, Grimm M, Müller LC. Freestyle root replacement for complex destructive aortic valve endocarditis. *The Journal of Thoracic and Cardiovascular Surgery* 2014;147:1265–70. doi:10.1016/j.jtcvs.2013.05.014.
13. Miceli A, Crocchia M, Simeoni S, Varone E, Murzi M, Farneti PA, et al. Root replacement with stentless Freestyle bioprostheses for active endocarditis: a single centre experience. *Interactive CardioVascular and Thoracic Surgery* 2012;16:27–30. doi:10.1093/icvts/ivs438.
14. El-Hamamsy I, Zaki M, Stevens LM, Clark LA, Rubens M, Melina G, et al. Rate of progression and functional significance of aortic root calcification after homograft versus freestyle aortic root replacement. *Circulation* 2009;120:S269–75. doi:10.1161/CIRCULATIONAHA.108.843748.
15. Thuny F, Beurtheret S, Mancini J, Gariboldi V, Casalta J-P, Riberi A, et al. The timing of surgery influences mortality and morbidity in adults with severe complicated infective endocarditis: a propensity analysis. *European Heart Journal* 2011;32:2027–33. doi:10.1093/eurheartj/ehp089.
16. Dickerman SA, Abrutyn E, Barsic B, Bouza E, Cecchi E, Moreno A, et al. The relationship between the initiation of antimicrobial therapy and the incidence of stroke in infective endocarditis: an analysis from the ICE Prospective Cohort Study (ICE-PCS). *American Heart Journal* 2007;154:1086–94. doi:10.1016/j.ahj.2007.07.023.
17. Hill EE, Herijgers P, Claus P, Vanderschueren S, Peetermans WE, Herregods M-C. Abscess in infective endocarditis: The value of transesophageal echocardiography and outcome. *American Heart Journal* 2007;154:923–8. doi:10.1016/j.ahj.2007.06.028.
18. Habets J, Tanis W, Reitsma JB, van den Brink RBA, Mali WPTM, Chamuleau SAJ, et al. Are novel non-invasive imaging techniques needed in patients with suspected prosthetic heart valve endocarditis? A systematic review and meta-analysis. *Eur Radiol* 2015;25:2125–33. doi:10.1007/s00330-015-3605-7.

19. Saby L, Laas O, Habib G, Cammilleri S, Mancini J, Tessonnier L, et al. Positron emission tomography/computed tomography for diagnosis of prosthetic valve endocarditis: increased valvular ¹⁸F-fluorodeoxyglucose uptake as a novel major criterion. *Journal of the American College of Cardiology* 2013;61:2374–82. doi:10.1016/j.jacc.2013.01.092.