Universiteit Leiden
The Netherlands

Surgical solutions for complex aortic root pathology

Schneider, A.W.

Citation
Schneider, A. W. (2021, September 15). *Surgical solutions for complex aortic root pathology*. Retrieved from https://hdl.handle.net/1887/3210132

Version:	Publisher's Version
License:	Licence agreement concerning inclusion of doctoral thesis in the Institutional Repository of the University of Leiden
Downloaded from:	https://hdl.handle.net/1887/3210132

Note: To cite this publication please use the final published version (if applicable).

Cover Page

Universiteit Leiden

Leiden University Repository

The handle https://hdl.handle.net/1887/3210132 holds various files of this Leiden University dissertation.

Author: Schneider, A.W.
Title: Surgical solutions for complex aortic root pathology
Issue Date: 2021-09-15

Surgical solutions for complex aortic root pathology

Adriaan Willem Schneider

Surgical Solutions for Complex Aortic Root Pathology

PhD thesis, Leiden University, Leiden, the Netherlands

ISBN: 978-94-6416-465-7
Cover design: Friso Rijnberg en Adriaan Schneider
Lay-out: Ridderprint | www.ridderprint.nl
Printing: Ridderprint | www.ridderprint.nl

Copyright © 2021 Adriaan Willem Schneider, Oegstgeest, the Netherlands

All rights are reserved. No part of this thesis may be reproduced or transmitted in any form or by any means without permission of the author or the publishers of the included scientific papers.

Financial support by The Dutch Heart Foundation for the publication of this thesis is gratefully acknowledged.

Publication of this thesis was kindly supported by: Stichting ETB-BISLIFE, Krijnen Medical Innovations

SURGICAL SOLUTIONS FOR COMPLEX AORTIC ROOT PATHOLOGY

PROEFSCHRIFT

ter verkrijging van

de graad van doctor aan de Universiteit Leiden,

op gezag van rector magnificus prof.dr.ir. H. Bijl,

volgens besluit van het college voor promoties

woensdag 15 september 2021

klokke 13:45 uur

door

Adriaan Willem Schneider

geboren te Alkmaar

in 1989

Promotores

Prof. dr. J. Braun
Prof. dr. M.G. Hazekamp
Prof. dr. R.J.M. Klautz

Leden promotiecommissie

Prof. dr. N.A. Blom
Prof. dr. W.J. Morshuis, *Radboud Universiteit Nijmegen*
Prof. dr. J.J.M. Takkenberg, *Erasmus Universiteit Rotterdam*

CONTENTS

Chapter	**1**	General introduction	9
PART	**1**	***THE PULMONARY AUTOGRAFT***	**29**
Chapter	**2**	Twenty-year Experience with the Ross-Konno Procedure Eur J Cardiothorac Surg 2016;49:1564–70	31
Chapter	**3**	Long-Term follow-up After the Ross Procedure: *a Single Center 22-Year Experience* The Annals of Thoracic Surgery 2017;103:1976–83	51
Chapter	**4**	The Ross Reimplantation Technique Multimed Man Cardiothorac Surg 2017;2017	71
PART	**2**	***THE STENTLESS BIOPROSTHESIS***	**81**
Chapter	**5**	20-Year Experience with the Freestyle Stentless Bioprosthesis: *Informing patients of risks and benefits* Eur J Cardiothorac Surg 2018;53:1272-8	83
Chapter	**6**	Stentless Bioprostheses: *a Versatile and Durable Solution in Extensive Aortic Valve Endocarditis* Eur J Cardiothorac Surg 2016;49:1699–704	123
Chapter	**7**	A Multi-Center, Propensity Scored Comparison between Stentless Biological and Mechanical Composite Aortic Root Replacement	139
Chapter	**8**	Reinterventions after Freestyle Stentless Aortic Valve replacement**:** *an Assessment of Procedural Risks* Eur J Cardiothorac Surg 2019;56:1117-1123	155

Chapter 9	Summary and future perspectives	175
Chapter 10	Nederlandse samenvatting	185
Chapter 11	List of publications	196
	Dankwoord	198
	Curriculum Vitae	200

Voor mijn ouders en June



GENERAL INTRODUCTION

CHAPTER 1

THE HEART

The heart is the first functioning organ during human embryology and continues to beat over 2 billion times during an average humans' lifetime. It consists of four chambers: 2 atria and 2 ventricles (Figure 1). Functionally, it can be divided into the 'right' sided heart, which receives blood from the body and pumps it to the lungs for oxygenation, and the 'left' sided heart, which receives oxygenized blood from the lungs and distributes it to the rest of the body. Although its function is simple – to distribute oxygenated blood to the rest of the body – the functional and structural components underlying this action are far from simple. Several processes are working simultaneously to achieve adequate cardiac function. Electric conduction needs to be optimal to provide synchronized contractions of both atria and, sequentially, the ventricles; contractility of the myocytes in the ventricular wall needs to be sufficient to overcome the hearts afterload; and the valves in the heart must facilitate easy forward flow, while preventing backward flow of blood. All these components must function optimally and in close cooperation with systemic factors such as vascular resistance and fluid status. In addition, they need to be able to adjust to altering systemic demands, for example during physical activity or illness. Any failure in one of these components will affect all other processes, eventually resulting in less efficient cardiac function and, ultimately, heart failure.

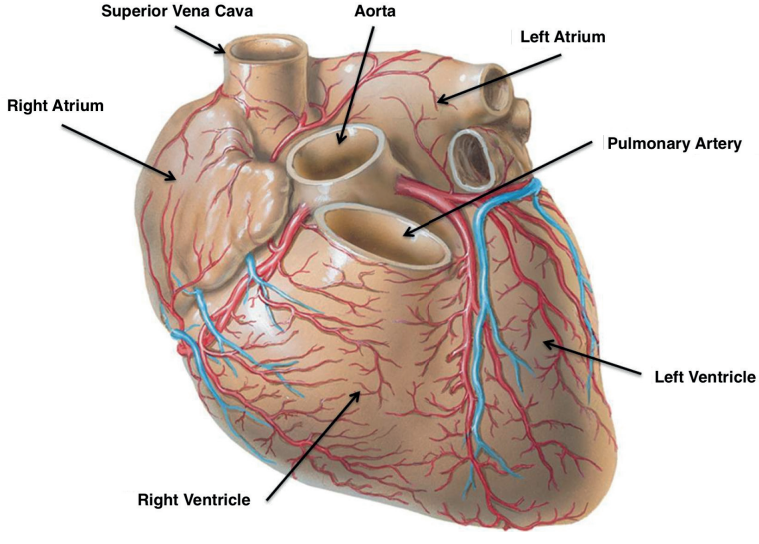

Figure 1. The human heart. *Adapted Netter illustration used with permission from Elsevier Inc.*

The aortic valve and root

The aortic valve is located between the left ventricle and the aorta. Its function is to permit unrestricted ejection of blood from the left ventricle, and prevent backflow once ventricular ejection stops. Rather than a simple trapdoor, the aortic valve is a complex three dimensional apparatus consisting of 3 semilunar cusps – or leaflets – three sinuses – the sinuses of Valsalva – the interleaflet triangles, and the sinotubular junction. These structures combined are called the aortic root. The sinuses are dilated pouches at the most proximal part of the aorta. The leaflets are suspended in these sinuses, giving them its crown-like shape (Figure 2). Out of two of these sinuses, the left and right coronary arteries originate. The three cusps and sinuses are named after these respective coronary arteries, resulting in left-, right- and non-coronary cusps and sinuses. The interleaflet triangles are the parts at the ventricular side between the hinges of the valve leaflets with its lower border at the nadir of the leaflets. Finally, the sinotubular junction is located at the highest point of the attached leaflets, the commissures, and marks the junction between the sinuses of the aortic root, and the tubular ascending aorta. The close relation between all these components can be explained by the embryonic development of the left (and right) ventricular outflow tract.

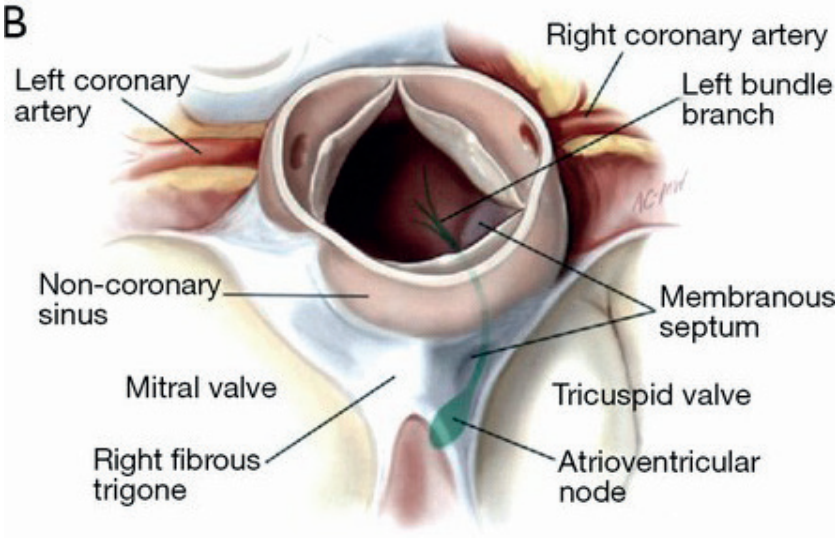

Figure 2. The aortic root and surrounding structures. *Adapted from Carpentier et al., 2010.*

Embryonic development of the left ventri-cular outflow tract and aortic valve complex

The ventricular outflow tracts can be divided into three parts: the most proximal part, consisting of the ventricular part of the outflow tract; the middle part, starting at the hinges of the valve leaflets and extending up to the sinotubular junction; and the distal part, the intrapericardial part of the aorta from the sinotubular junction to the pericardial lining. By the 4th week of gestation, the primordial heart has a tubular shape, consisting of 2 layers; the primary myocardium and endocardium. During the process of cardiac looping, the primary myocardium secretes 'cardiac jelly', which forms endocardial cushions at the outflow (and inflow) portion of the looped cardiac tube. Fusion of these two primary endocardial

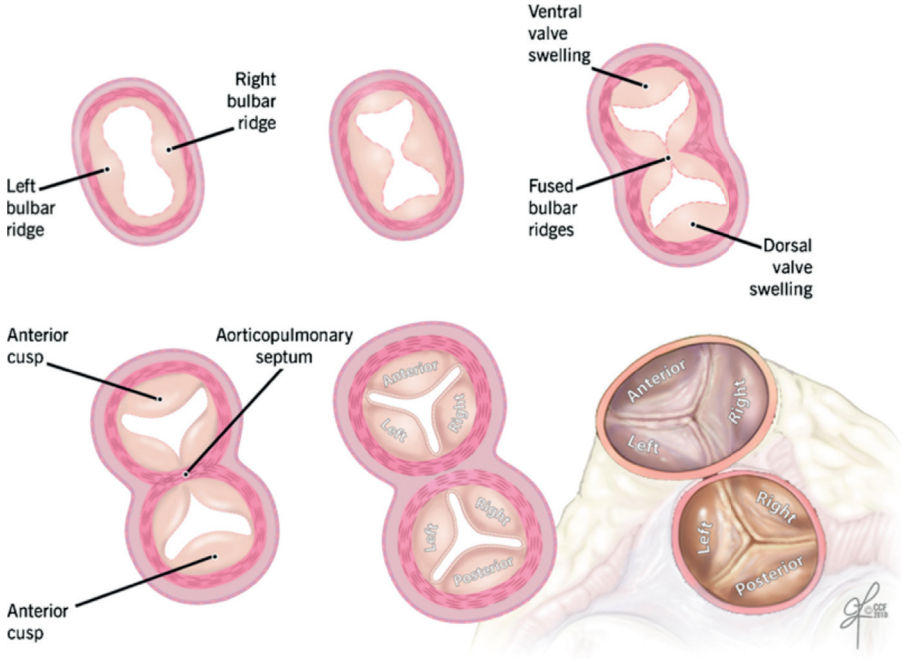

Source: Lawrence H. Cohn, David H. Adams:
Cardiac Surgery in the Adult, Fifth Edition
Copyright © McGraw-Hill Education. All rights reserved.

Figure 3. Development of the aortic and pulmonary valve leaflets. *Reproduced with permission*

cushions results in a separation of the left and right sided outflow tracts. This fusion starts in the distal part of the outflow tract and progresses proximally. Simultaneously, two intercalated cushions form at the middle part of the outflow

tract, at the remaining two quadrants of the original common trunk. It is the location of these intercalated cushions that determine the location of the arterial valve apparatus in the outflow tract [1,2].

The lateral margins of the primary cushions do not fuse, resulting in what will become the left and right leaflets of the aortic and pulmonary valves (Figure 3). The intercalated cushions will become the non-coronary (posterior) cusp of the aortic valve, and anterior leaflet of the pulmonary valve. The valve leaflets are formed by a process in which the endocardial cushions are excavated, with simultaneous ingrowth of non-myocardial cells which form the arterial wall of the sinuses. As the myocardium moves proximally, these tissues fill the gaps between the semi-lunar shaped leaflets, and will thin, ultimately forming the interleaflet triangles.

These processes, which form the outflow tract including the aortic root, show how interrelated all these structures are, and that failure in one of these processes, or one of these structures, can result in aortic valve disease and ventricular outflow tract obstructions.

Histology of the aortic valve leaflets

As shown previously, the aortic valve apparatus is a three dimensional structure. When observed from the aortic side, the three leaflets each cover 120 degrees of the circumference of the aortic root wall. The free margins of the valve leaflets, the coaptation areas (or lunulae) of the respective leaflets, appose to provide a tight seal. In the middle, where all three leaflets meet, there is a small thickening, the nodule of Arantius. This nodule demarcates the middle of the free margin. Small fenestrations in the coaptation area are often present, but do not impact valve competence.

Histologically, three distinct layers can be observed in the leaflets: the lamina fibrosa at the aortic side, the lamina spongiosa in the middle and the lamina ventricularis on the ventricular side. The lamina fibrosa consist of circumferentially orientated collagen fibers, which diverge from the commissures towards the middle of the leaflets, where they intertwine and form a dense honeycomb figuration. This thick and dense layer contributes most to the structural strength of the leaflets. Collagen fibers from the fibrosa curve inward into the sinus wall where they interdigitate with elastic and muscular layers of the sinus wall, sharing the mechanical stress during valve closure[3].

The central lamina spongiosa is thicker at the basal part of the leaflet, and thins or even disappears towards the free margin. It is rich in proteoglycans and glycosaminoglycans, which allow smooth sliding of the other layers. Furthermore, the proteoglycans act as a shock absorber during valve opening and closure.

The lamina ventricularis is primarily composed of radially orientated elastin fibers, giving the leaflet its elasticity. A continuous layer of endothelial cells cover the layers of the valve leaflets from the sinuses and continue into the endocardium on the ventricular side.

The endothelial cells are aligned circumferentially, perpendicular to the direction of blood flow. This is in contrast to endothelial orientation in the rest of the vascular system [4]. Even when cultured with a matrix parallel to flow, valvular endothelial cells were oriented perpendicular to the flow. This suggests that underlying fiber direction is not responsible for endothelial orientation [4]. Biaxial forces, rather than shear stress might be responsible for the orientation of endothelial cells in the aortic valve leaflets [5]. Furthermore, valvular endothelial cells may be important in regulating interstitial cell phenotype and extracellular matrix synthesis [6].

Valvular interstitial cells (VIC's) regulate and synthesize the extracellular matrix (ECM). They are predominantly smooth muscle a-actin-positive cells and fibroblasts. Continuous remodeling of the valve is achieved by synthesis of ECM components. This plays an important role in coping with the wear and tear during the valve's lifetime. Valvular interstitial cells have shown to be able to change their phenotype [7]. This alteration in VIC phenotype (e.g. into osteoblastic VIC) may play an important role in the pathogenesis of (senile) valvular diseases.

Stress/strain properties of the aortic valve

The aortic valve leaflets are subject to several forces during each cardiac cycle: shear stresses, leaflet strain (both radially and circumferentially), mechanical pressure, and bending forces. The ventricular side of the leaflets is subject to laminar shear stresses with a high velocity as a result of ventricular ejection, but the arterial side of the leaflets are subject to low-velocity multidirectional shear stresses. As a result of these forces, the valve leaflets stretch during diastole and shorten during systole, more so in the radial direction than circumferentially[8]. This interaction between stress and strain on the valve leaflets is shown in Figure 4. At the beginning of systole, the elastin fibers stretch with minimal stress while

the collagen fibers start unwrinkling. At end-systole with increasing stress on the valve leaflets, the collagen fibers are uncrimped and take the load of diastolic pressure, with high stress and minimally increasing strain. As described in the previous section, this high stress is shared with the wall of the sinuses of Valsalva through the interdigitated collagen fibers, resulting in an inward motion of the commissures during diastole. At the end of the cardiac cycle, the inverse occurs as pressure on the leaflets minimizes and the elastin fibers recoil the leaflet.

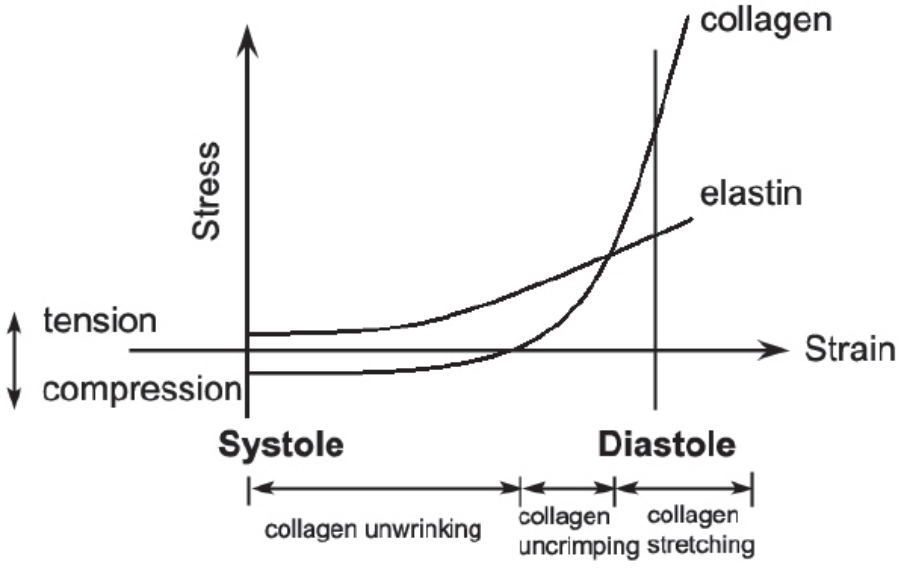

Figure 4. Stress/strain properties of the aortic valve. *Reused from Schoen FJ, Levy RJ. Journal of Biomedical Materials Research. 1999 Dec 15;47(4):439–65, with permission.*

Dynamics of the aortic root during the cardiac cycle

The aortic root is a dynamic structure, which changes during the cardiac cycle. Studies in canine aortic roots with markers placed at the leaflets and sinus wall, analyzed with fluoroscopy, show movement of these structures during the cardiac cycle [3]. The direction of these movements depends on the type of tissue forming these structures. In the sinuses, at the level of the commissures, the compliant characteristics of smooth muscle cells in the aortic wall result in a passive, outward direction during systole as a result of increased pressure [3]. At end-systole and during diastole, outward pressure on the aortic wall decreases, and pressures on the aortic valve leaflets increase, resulting in a decrease in diameter

at the level of the commissures [3]. Functionally, these changes in diameter have several consequences. More space between the leaflets and sinus wall prevents obstruction of the coronary arteries during systole. Furthermore, vortex formation in the sinuses improves coronary blood flow[9], and may also exhibit an inward force on the valve leaflets, facilitating easier valve closure [10-12].

The diameter at the base of the valve leaflets reaches its maximum during early systole, enabling easy valve opening. During systole, the diameter decreases as the ventricular wall, in which the leaflets are suspended, contracts. At end of systole, just before coaptation of the valve leaflets, the diameter of the base of the aortic valve is minimal, facilitating easy valve closure. During diastole, this diameter increases again [13]. The normal ratio between annular diameter and the diameter at the level of the sinotubular junction is 1.15 / 1 in diastole.

AORTIC VALVE DISEASE

Prevalence and etiology

Aortic valve disease is the second most common valvular disease in the general population of developed countries and its prevalence increases with age. [14] Aortic valve stenosis is more common than aortic valve regurgitation. A population-based study in North-America showed an increasing prevalence of aortic valve stenosis from 0.02% in persons aged between 18 and 44, to 2.8% in the population over 75 years of age [14]. Within patients who undergo valve intervention, aortic valve stenosis is the most common disease, accounting for over half of the interventions [15].

Aortic valve disease in neonates and children

Congenital aortic valve stenosis represents approximately 5% of congenital cardiac malformations [16]. The most common congenital anomaly is a bicuspid aortic valve, with a prevalence of ~1–2% [17]. Often, one or more commissures are absent or severely underdeveloped; this can be accompanied by underdevelopment of the left ventricular outflow tract. In neonates with critical aortic valve stenosis, adequate systemic and coronary blood flow is dependent on a patent ductus arteriosus, which necessitates early intervention.

Noncritical aortic valve stenosis is often the result of a malformed valve (e.g. a bicuspid valve) [18]. Patients with severe stenosis often present early in life due to (severe) symptoms. However, patients with less severe stenosis go through a latent phase in which progressive stenosis occurs, but symptoms are absent or mild. These patients may present later in life as disease progression results in the presentation of symptoms.

In order to maintain left ventricular ejection, the left ventricle will become hypertrophic as a compensatory mechanism to the higher pressure needed to pass blood through the stenotic valve. Depending on the severity of LV hypertrophy secondary to aortic valve stenosis, coronary perfusion of the hypertrophic ventricular wall may be insufficient. This can lead to relative ischemia of the endocardium, resulting in endocardial fibroelastosis. This further diminishes ventricular function and is a surgical challenge to remove, often with poor outcomes.

Isolated congenital aortic valve regurgitation due to absence or under development of a valve leaflet is very rare, with an incidence of 0.3% of congenital heart disease. [19]. It is, however, associated with several congenital heart diseases, such as tetralogy of Fallot and ventricular septum defects. Furthermore, connective tissue diseases may result in aortic valve regurgitation due to dilatation of the aortic root.

Aortic valve disease in the adult

The most common causes of aortic valve stenosis in developed countries is senile degeneration. In developing countries, rheumatic valve disease plays a more important role. In senile degeneration, progressive calcification of the valve leaflets leads to progressive sclerosis and stenosis. This calcification is mostly seen at the areas with most flexion of the leaflets, i.e. the coaptation line and the valvular attachment in the sinus wall [20]. Furthermore, stiffening of the valve leaflets reduces their elasticity and limits proper leaflet coaptation, resulting in some degree of valve regurgitation. Approximately half of the patients operated for aortic valve stenosis have a bicuspid valve. Although the exact mechanism of valvular calcification remains unclear, several factors are thought to influence its initiation and progression. Among these are the development of VIC's to the osteoblastic type due to stress, specific signaling pathways, and lipid and macrophage accumulation which resembles the process of atherosclerosis [21].

Patients with aortic valve stenosis can remain asymptomatic for a long time, as compensating mechanisms of the heart can cope with the increased mechanical demands for quite some time. In response to the increased ejection pressure, the myocardium of the left ventricle will become hypertrophic. By the time the compensating mechanisms fail, severe symptoms become present and patients' life expectancy is considerably impaired (Figure 5).

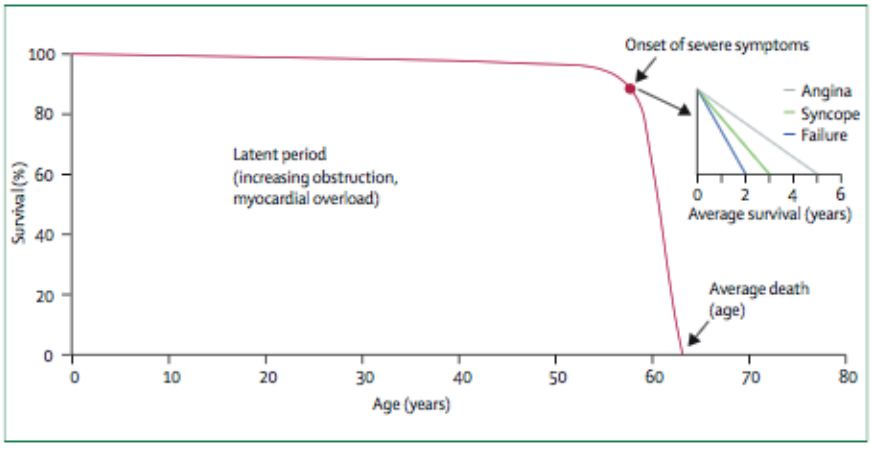

Figure 5. Survival of patients with aortic valve stenosis over time. *Adapted from Ross et. al. With permission)*

Aortic valve regurgitation can have several causes, depending on which part of the apparatus is affected. As previously mentioned, calcific disease, as well as bicuspid valves can lead to regurgitation due to decreased leaflet pliability resulting in inadequate coaptation. Furthermore, connective tissue diseases which lead to aortic root or ascending aorta dilatation (or even dissection or rupture) pull the commissures outward, resulting in malcoaptation of the valve leaflets. In these circumstances, the valve leaflets can still be normal, which may enable valve repair.

Infective endocarditis of the aortic valve is a life-threatening condition which requires urgent care. Destruction of the leaflets, as well as surrounding tissues, results in acute aortic valve regurgitation which can result in cardiac decompensation.

Rheumatic valve disease is characterized by fibrous leaflet thickening, often with fusion of one or more of the commissures. It has become rare in Western countries, but still remains an important cause in developing countries. Isolated aortic valve stenosis in rheumatic disease is uncommon, as it is often combined with mitral valve stenosis.

Treatment of rare causes of aortic valve disease, such as tumors, trauma and drug-induced aortic valve disease, depends on the reparability (e.g. removal of a fibroelastoma) of the valve. If a durable repair is not deemed possible, the valve needs to be replaced.

SURGICAL TREATMENT OPTIONS FOR AORTIC VALVE DISEASE

Several treatment options are available for the diseased aortic valve. Since the first (documented) aortic valve operation performed in 1912 by the French surgeon Theodore Tuffier[22], in which he pushed the aortic wall through a stenotic valve in a 26-year old male, many improvements have been made.

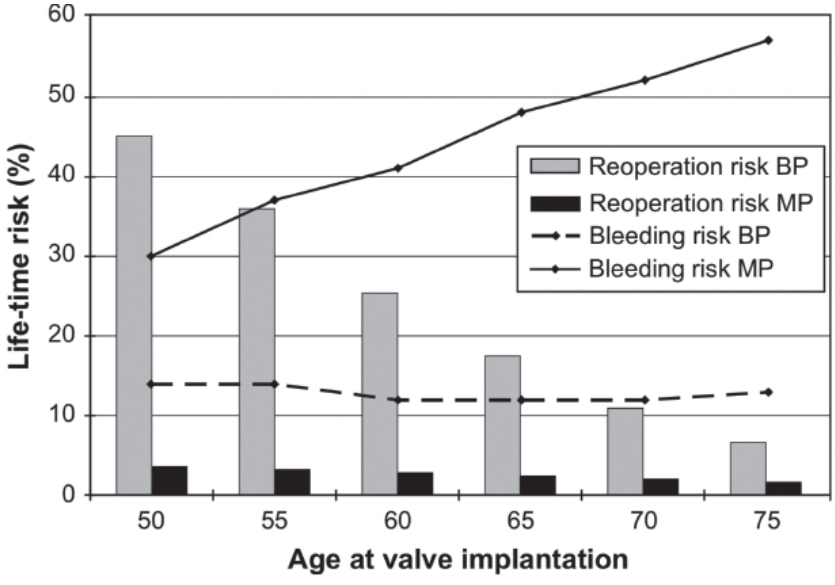

Figure 6. Lifetime risks of reoperation and bleeding after AVR with mechanical and bioprostheses. BP, Bioprostheis; MP, mechanical prosthesis. *Reused from Van Geldorp et al., JTCVS 2009;137:881-6, with permission.*

Depending on the underlying mechanism of failure, the valve and/or root can be repaired or replaced. An individual assessment of the valve leaflets needs to be made, in order to decide whether a valve repair is considered durable. In general, calcific disease of the valve leaflets is not suited for valve repair. When the valve or root needs to be replaced, several prostheses are available. Valve prostheses can be categorized in mechanical and biological prostheses. Within the biological prostheses, a further distinction between prostheses with and without a stent can be made. Furthermore, patients' own pulmonary valve (the pulmonary autograft), and human donor aortic valves (allograft) can be used to replace the aortic root.

Mechanical prostheses

Modern mechanical prostheses are composed of 2 semicircular leaflets rotating in struts attached to the valve housing. They are designed to last a lifetime, which is their biggest advantage, although replacement is still needed in approximately 5% after 10 years [23]. The thrombogenicity of these prostheses necessitates lifelong anticoagulant treatment with vitamin K antagonists. This puts patients at higher risks for bleeding events, although with strict (home) monitoring, these risks can be minimized.

Stented biological prostheses

Stented bioprostheses are the most commonly used aortic valve prostheses, especially in older patients [24]. Several stented biological prostheses are available. They can be categorized in pericardial prostheses and porcine valves. In pericardial valves, treated bovine, porcine or equine pericardium is mounted on a frame to construct valve leaflets, whereas in porcine valves, the aortic valve itself is mounted on a stent. As a result of these stents, the geometric orifice area, and consequently the effective orifice area (EOA), of stented valves is reduced.

Stentless bioprostheses

Stentless bioprostheses were developed to maximize the EOA thereby improving hemodynamics. Furthermore, it was believed that the more natural way the leaflets were incorporated in these prostheses would help improve their longevity. Studies have shown that left ventricular mass regression occurs faster after stentless valve replacement compared to stented valves, but that this difference disappears 1 year after prosthesis implantation [25]. Because of their larger EOA, stentless

prostheses are valuable options in patients with a small aortic annulus, and they facilitate larger prostheses during future transcatheter valve-in-valve procedures. Furthermore, some of these prostheses can be used as a root replacement in patients with an indication for aortic root replacement.

Homografts

Human donor valves (homografts or allografts) were introduced in the 1960's, and its successful orthotopic use was first described by Ross in 1962 [26]. Aortic and pulmonary homografts are procured from suited post-mortem donors and heart transplant recipients. They are generally sterilized with antibiotics and subsequently cryopreserved. As the number of available homografts is limited, and durability has shown to be comparable with some bioprostheses [27], the use of aortic homografts is limited, and mainly reserved for patients with extensive endocarditis affecting the surrounding tissues. Pulmonary homografts in the aortic position have shown to have a very limited durability [28].

Pulmonary autograft (Ross procedure)

Also introduced by Ross [29], the patient's own pulmonary root can be used to replace the aortic root. The pulmonary root is then replaced with a cryopreserved pulmonary homograft. Hemodynamics of the pulmonary autograft closely resemble that of a native aortic root. Furthermore, its capability to grow is a huge advantage in children, as replacement of the autograft due to growth of the child is not necessary. The valve leaflets of the autograft have shown to adapt well to the increased pressure in the systemic circulation compared to the pulmonary circulation. However, although the autograft wall thickens, the autograft stiffness is reduced compared to native aortic root walls, which may lead to dilatation in the long run [30]. The most often mentioned downside of this procedure is that it creates a dual valve problem for a single valve disease. Furthermore, technical difficulties limit its use to experienced centers.

Transcatheter aortic valve replacement

Since the first transcatheter aortic valve replacement (TAVR) in 2002 [31], the role of TAVR within aortic valve replacement is still being explored. In high-risk patients, TAVR is accepted as an alternative to surgery [32]. In the short term, TAVR seems

a reasonable alternative to surgery in the older (³75 years) intermediate- and low-risk patients with severe stenosis of their tricuspid aortic valve [33-36]. Long-term data, especially regarding structural valve deterioration, are still lacking and need to be awaited before its definite role in these patients can be established. The NOTION 2 trial, analyzing TAVR versus SAVR in all-comer patients between the age of 18 an 75 years is currently enrolling, and its outcomes need to be awaited to see if TAVR has a role in younger patients.

Valve sparing root replacement and aortic valve repair

In selected patients, the aortic valve may be preserved and surgically repaired. This depends on the size and pliability of the valve leaflets and surface of coaptation between the leaflets. If the valve is insufficient due to dilatation of the aortic root and/or ascending aorta, the valvular function can be restored by means of valve sparing root replacement.

Treatment options in aortic valve disease in neonates and children

As mentioned, critical aortic valve stenosis requires early intervention. Depending on the severity of outflow tract hypoplasia, a management strategy will be made which will in- or exclude the left ventricle. Often, (intra-uterine) balloon dilatation of the stenotic valve will be the first intervention, and growth of the left ventricle and outflow tract can sometimes be awaited. Balloon expansion of the stenotic aortic valve can result in subsequent regurgitation. However, this is generally well tolerated and postpones surgical intervention to later in life. In too severely hypoplastic left ventricles, a strategy towards a univentricular heart, in which the right ventricle provides both pulmonary and systemic circulation, will be adopted. When valve replacement is necessary, the Ross procedure, with our without LVOT enlargement using a Konno incision, provides a valuable solution, as the pulmonary autograft is capable of growing with the child. Replacement of the aortic valve with valve prostheses is often suboptimal, but may be required in specific situations, such as the inability to perform a Ross procedure due to a non-suited pulmonary valve. Furthermore, other indications for oral anticoagulation in older children, such as an existing cardiomyopathy, may plead in favor of mechanical valve replacement, provided an adequately sized prosthesis can be implanted.

Outline of this thesis

Aortic valve and root disease comes in many forms. This thesis is focused on complex aortic root pathology and the surgical possibilities that are available and the accompanying challenges that need to be overcome. Outcomes after aortic root surgery in complex root pathology, both in children and adults, will be presented and discussed, focusing on biological solutions. The data presented in this thesis can help patients, cardiologists and cardiac surgeons in their choice of therapy in complex aortic root disease.

Part 1 of this thesis is focused on the use of the pulmonary autograft in patients who need aortic root replacement (the so-called Ross procedure). Neonates and small children with concomitant left ventricular outflow tract obstruction next to their aortic valve stenosis require aortic root replacement with concomitant enlargement of the left ventricular outflow tract. One way to achieve this with the use of the pulmonary autograft is the so-called Ross-Konno procedure, in which the interventricular septum is incised to widen the outflow tract. In Chapter 2, the Ross-Konno technique and long-term outcomes are described. When no outflow tract obstruction is present, aortic root replacement with the pulmonary autograft remains a valuable option, especially in adolescents and younger adults. In Chapter 3, outcomes after root replacement with the pulmonary autograft are reported. In Chapter 4, a modified technique of the Ross procedure is presented in which the pulmonary autograft is reimplanted into a vascular graft to prolong its durability.

Part 2 of this thesis is focused on a biological stentless aortic root prosthesis, called the Freestyle prosthesis. This porcine aortic root can be used to replace the aortic valve and root for several indications. In Chapter 5 long-term outcome data on this prosthesis, with a special focus on the expected trajectory for each patient to aid in their choice of prosthesis, are presented. The Freestyle prosthesis can be used in several root pathologies, one of which is the challenging condition of infective endocarditis of the aortic root and surrounding structures. In Chapter 6, surgical techniques for this complex surgery are presented and outcomes in this high-risk patient group are discussed. In Chapter 7, outcomes after aortic root replacement using the Freestyle prosthesis are compared with outcomes after aortic root replacement using a composite mechanical prosthesis. Both

advantages and disadvantages of both types of prosthesis are discussed, and outcomes in a matched cohort are presented. Finally, in Chapter 8, clinical outcomes after reintervention on a Freestyle prosthesis that need to be replaced are reported. Both the underlying modes of failure and the types of reintervention are discussed with their respective procedural challenges and outcomes.

REFERENCES

1. Spicer DE, Bridgeman JM, Brown NA, Mohun TJ, Anderson RH. The anatomy and development of the cardiac valves. Cardiol Young 2014;24:1008–22. doi:10.1017/S1047951114001942.

2. Anderson RH, Webb S, Brown NA, Lamers W, Moorman A. Development of the heart: (3) formation of the ventricular outflow tracts, arterial valves, and intrapericardial arterial trunks. Heart 2003;89:1110–8.

3. Thubrikar MJ, Nolan SP, Aouad J, Deck JD. Stress Sharing Between the Sinus and Leaflets of Canine Aortic Valve. Ats 1986;42:434–40. doi:10.1016/S0003-4975(10)60554-1.

4. Butcher JT, Penrod AM, García AJ, Nerem RM. Unique morphology and focal adhesion development of valvular endothelial cells in static and fluid flow environments. Arterioscler Thromb Vasc Biol 2004;24:1429–34. doi:10.1161/01.ATV.0000130462.50769.5a.

5. Misfeld M, Sievers HH. Heart valve macro- and microstructure. Philosophical Transactions of the Royal Society B: Biological Sciences 2007;362:1421–36. doi:10.1098/rstb.2007.2125.

6. Butcher JT, Nerem RM. Valvular endothelial cells regulate the phenotype of interstitial cells in co-culture: effects of steady shear stress. Tissue Eng 2006;12:905–15. doi:10.1089/ten.2006.12.905.

7. Osman L, Yacoub MH, Latif N, Amrani M, Chester AH. Role of human valve interstitial cells in valve calcification and their response to atorvastatin. Circulation 2006;114:I547–52. doi:10.1161/CIRCULATIONAHA.105.001115.

8. Brewer RJ, Mentzer RM, Deck JD, Ritter RC, Trefil JS, Nolan SP. An in vivo study of the dimensional changes of the aortic valve leaflets during the cardiac cycle. The Journal of Thoracic and Cardiovascular Surgery 1977;74:645–50.

9. Bellhouse BJ, Bellhouse FH, Reid KG. Fluid mechanics of the aortic root with application to coronary flow. Nature 1968;219:1059–61.
10. Bellhouse BJ, Bellhouse FH. Mechanism of closure of the aortic valve. Nature 1968;217:86–7.

11. Higashidate M, Tamiya K, Beppu T, Imai Y. Regulation of the aortic valve opening. In vivo dynamic measurement of aortic valve orifice area. The Journal of Thoracic and Cardiovascular Surgery 1995;110:496–503. doi:10.1016/S0022-5223(95)70246-6.

12. Thubrikar M, Bosher LP, Nolan SP. The mechanism of opening of the aortic valve. The Journal of Thoracic and Cardiovascular Surgery 1979;77:863–70.

13. Thubrikar M, Nolan SP, Bosher LP, Deck JD. The cyclic changes and structure of the base of the aortic valve. American Heart Journal 1980;99:217–24.

14. Nkomo VT, Gardin JM, Skelton TN, Gottdiener JS, Scott CG, Enriquez-Sarano M. Burden of valvular heart diseases: a population-based study. Lancet 2006;368:1005–11. doi:10.1016/S0140-6736(06)69208-8.

15. Iung B, Baron G, Butchart EG, Delahaye F, Gohlke-Bärwolf C, Levang OW, et al. A prospective survey of patients with valvular heart disease in Europe: The Euro Heart Survey on Valvular Heart Disease. European Heart Journal 2003;24:1231–43.

16. Samánek M, Slavík Z, Zborilová B, Hrobonová V, Vorísková M, Skovránek J. Prevalence, treatment, and outcome of heart disease in live-born children: a prospective analysis of 91,823 live-born children. Pediatr Cardiol 1989;10:205–11. doi:10.1007/BF02083294.

17. Hoffman JIE, Kaplan S. The incidence of congenital heart disease. Journal of the American College of Cardiology 2002;39:1890–900. doi:10.1016/S0735-1097(02)01886-7.

18. Lewin MB, Otto CM. The bicuspid aortic valve: adverse outcomes from infancy to old age. Circulation 2005;111:832–4. doi:10.1161/01.CIR.0000157137.59691.0B.

19. Donofrio MT, Engle MA, O'Loughlin JE, Snyder MS, Levin AR, Ehlers KH, et al. Congenital aortic regurgitation: natural history and management. Journal of the American College of Cardiology 1992;20:366–72.

20. Thubrikar MJ, Aouad J, Nolan SP. Patterns of calcific deposits in operatively excised stenotic or purely regurgitant aortic valves and their relation to mechanical stress. Am J Cardiol 1986;58:304–8.

21. Bäck M, Gasser TC, Michel J-B, Caligiuri G. Biomechanical factors in the biology of aortic wall and aortic valve diseases. Cardiovascular Research 2013;99:232–41. doi:10.1093/cvr/cvt040.

22. Tuffier T. Etat actuel de la chirurgie intrathoracique. Trans Int Congr Med 1913;7:249.

23. Mookhoek A, Korteland NM, Arabkhani B, Di Centa I, Lansac E, Bekkers JA, et al. Bentall Procedure: A Systematic Review and Meta-Analysis. The Annals of Thoracic Surgery 2016;101:1684–9. doi:10.1016/j.athoracsur.2015.10.090.

24. Isaacs AJ, Shuhaiber J, Salemi A, Isom OW, Sedrakyan A. National trends in utilization and in-hospital outcomes of mechanical versus bioprosthetic aortic valve replacements. The Journal of Thoracic and Cardiovascular Surgery 2015;149: 1262–3. doi:10.1016/j.jtcvs.2015.01.052.

25. Kunadian B, Vijayalakshmi K, Thornley AR, de Belder MA, Hunter S, Kendall S, et al. Meta-analysis of valve hemodynamics and left ventricular mass regression for stentless versus stented aortic valves. The Annals of Thoracic Surgery 2007;84: 73–8. doi:10.1016/j.athoracsur.2007.02.057.

26. Ross DN. Homograft replacement of the aortic valve. Lancet 1962;2:487.

27. El-Hamamsy I, Clark L, Stevens LM, Sarang Z, Melina G, Takkenberg JJM, et al. Late outcomes following freestyle versus homograft aortic root replacement: results from a prospective randomized trial. Journal of the American College of Cardiology 2010;55:368–76. doi:10.1016/j.jacc.2009.09.030.

28. Koolbergen DR, Hazekamp MG, de Heer E, van Hoorn F, Huysmans HA, Bruijn JA, et al. Structural degeneration of pulmonary homografts used as aortic valve substitute underlines early graft failure. European Journal of Cardio-Thoracic Surgery 2002;22:802–7.

29. Ross DN. Replacement of aortic and mitral valves with a pulmonary autograft. Lancet 1967;2:956–8.

30. Mookhoek A, Krishnan K, Chitsaz S, Kuang H, Ge L, Schoof PH, et al. Biomechanics of Failed Pulmonary Autografts Compared to Native Aortic Roots. The Annals of Thoracic Surgery 2017;103:1482–8. doi:10.1016/j.athoracsur.2016.08.061.

31. Cribier A, Eltchaninoff H, Bash A, Borenstein N, Tron C, Bauer F, et al. Percutaneous transcatheter implantation of an aortic valve prosthesis for calcific aortic stenosis: first human case description. Circulation 2002;106:3006–8.

32. Leon MB, Smith CR, Mack M, Miller DC, Moses JW, Svensson LG, et al. Transcatheter aortic-valve implantation for aortic stenosis in patients who cannot undergo surgery. N Engl J Med 2010;363:1597–607. doi:10.1056/NEJMoa1008232.

33. Leon MB, Smith CR, Mack MJ, Makkar RR, Svensson LG, Kodali SK, et al. Transcatheter or Surgical Aortic-Valve Replacement in Intermediate-Risk Patients. N Engl J Med 2016;374:1609–20. doi:10.1056/NEJMoa1514616.

34. Reardon MJ, Van Mieghem NM, Popma JJ, Kleiman NS, Sondergaard L, Mumtaz M, et al. Surgical or Transcatheter Aortic-Valve Replacement in Intermediate-Risk Patients. N Engl J Med 2017;376:1321–31. doi:10.1056/NEJMoa1700456.

35. Mack MJ, Leon MB, Thourani VH, Makkar R, Kodali SK, Russo M, et al. Transcatheter Aortic-Valve Replacement with a Balloon-Expandable Valve in Low-Risk Patients. N Engl J Med 2019:NEJMoa1814052. doi:10.1056/NEJMoa1814052.

36. Popma JJ, Deeb GM, Yakubov SJ, Mumtaz M, Gada H, O'Hair D, et al. Transcatheter Aortic-Valve Replacement with a Self-Expanding Valve in Low-Risk Patients. N Engl J Med 2019;380:1706–15. doi:10.1056/NEJMoa1816885.

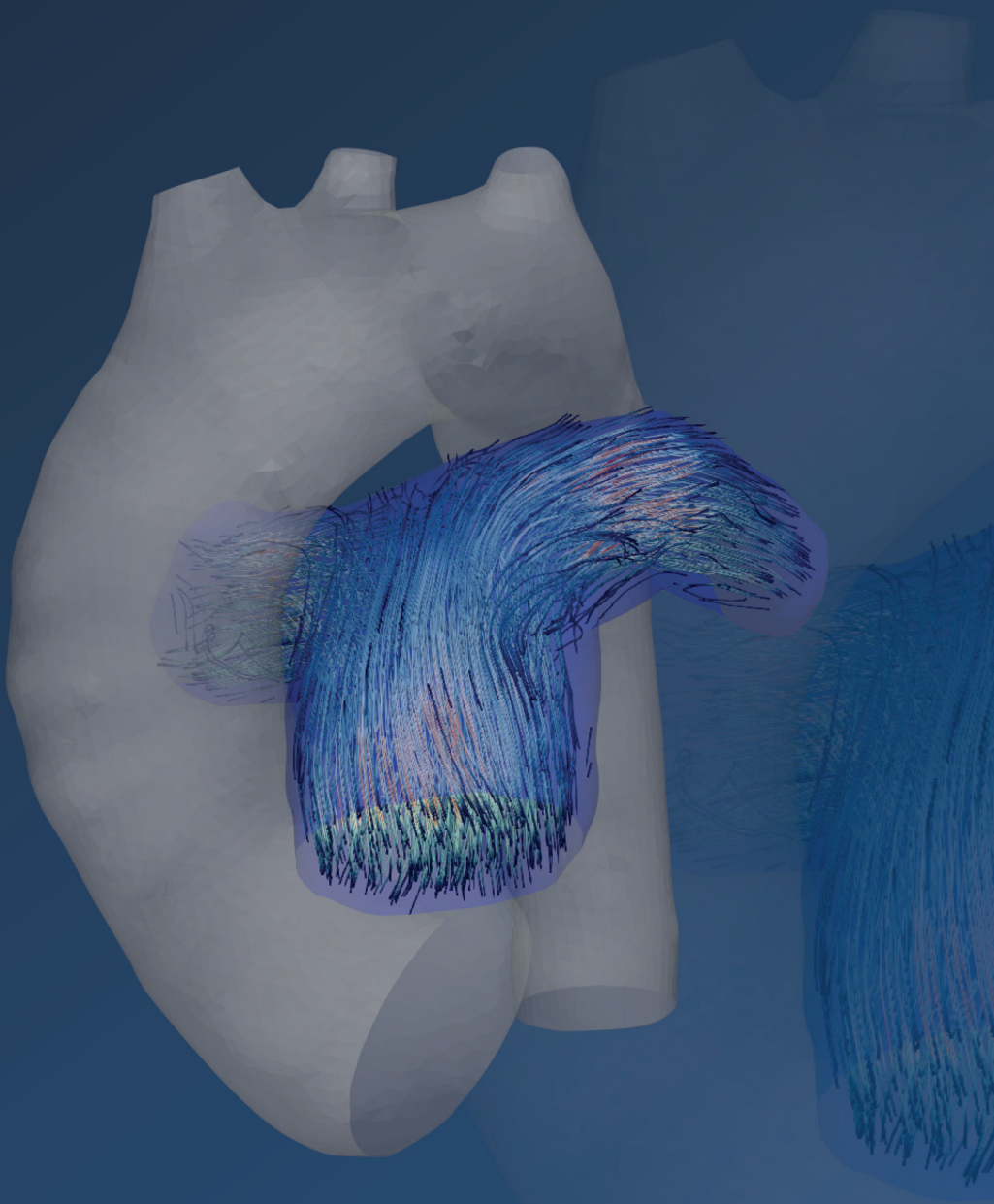

PART 1

THE PULMONARY AUTOGRAFT

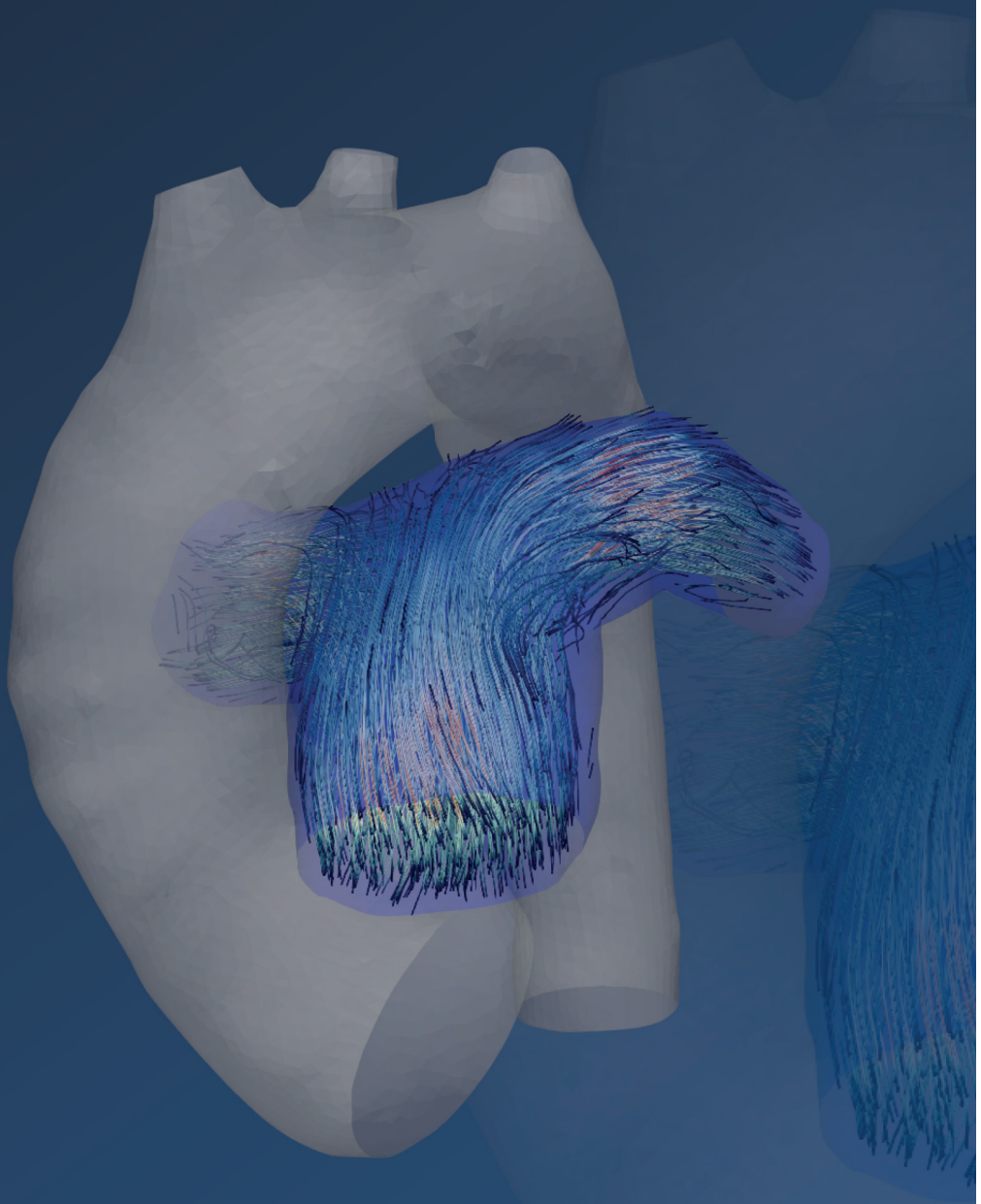

TWENTY-YEAR EXPERIENCE WITH THE ROSS-KONNO PROCEDURE

Adriaan W. Schneider, Regina Bökenkamp, Eline F. Bruggemans, Mark G. Hazekamp

Eur J Cardiothorac Surg 2016;49:1564–70

Presented at the 29th annual meeting of the European Association for Cardio-Thoracic Surgery, Tuesday 6 October 2015, Amsterdam, The Netherlands

CHAPTER 2

ABSTRACT

OBJECTIVES

The Ross–Konno procedure is a last resort for patients with complex multilevel left ventricular outflow tract obstruction (LVOTO) often having other cardiovascular anomalies. It is typically preceded by multiple surgeries. Literature is scarce on long-term follow-up series. Therefore, we have reviewed our 20-year experience with this procedure in order to provide insights in patients' outcomes and to optimize patient selection.

METHODS

Between January 1995 and December 2014, 48 patients underwent the Ross–Konno procedure. The median age at operation was 12.8 months (range, 11 days to 31 years). Twenty-two (46%) patients were under 1 year of age. Forty-four (92%) patients had undergone a total of 82 previous procedures. Eleven (23%) patients had concomitant surgery, predominantly mitral valve (n = 5) and aortic arch surgery (n = 5).

RESULTS

The median follow-up time was 4.3 years (range, 0–20 years). There were 6 (12.5%) early deaths and 4 (8.3%) late deaths. Estimated overall survival at 5, 10 and 15 years was 83, 79 and 70%, respectively. Poor LV function was a risk factor for early mortality (odds ratio = 9.5; 95% confidence interval = 1.4–63.7; P = 0.020). Twelve patients required a total of 29 procedures in 17 reoperations. Five patients required reoperation for autograft failure at a median of 14 years (range, 5–15 years) postoperatively. Estimated freedom from all causes of reoperation at 5, 10 and 15 years was 82, 55 and 30%, respectively. All patients had complete and durable relief of LVOTO. At latest follow-up, 5 patients had a sinus of Valsalva Z -score of 5 or greater. One patient had Grade II autograft insufficiency.

CONCLUSIONS

The Ross–Konno procedure is a durable solution for multilevel LVOTO in a highly complex patient population with high incidence of previous procedures. High early mortality rates in patients with impaired left ventricular function emphasize the

importance of patient selection. Freedom from reoperation shows a continuous attrition rate. Reoperation for autograft failure may occur late after the Ross–Konno procedure.

INTRODUCTION

The Ross–Konno operation is a complex procedure for severe or multilevel (sub) aortic stenosis. It consists of using the patients' pulmonary valve as a neoaortic autograft (Ross procedure), combined with the opening of a narrowed left ventricular outflow tract (LVOT) by incising the outflow septum. Patients in need of a Ross–Konno procedure often have accompanying congenital anomalies, such as coarctation of the aorta (CoA), an interrupted aortic arch (IAA) and ventricular septal defects (VSDs). Careful patient selection is important in predicting the success of the procedure, especially in patients with a borderline left ventricle (LV) and/or endocardial fibroelastosis (EFE). The capability of the autograft to grow with the child is one of the main advantages of the Ross–Konno procedure in infants and children. Downsides of the Ross–Konno operation are the need for reoperations for the right ventricle to pulmonary artery (RV–PA) conduit and possible dilatation of the autograft root.

Literature is scarce on long-term follow-up series of the Ross–Konno operation. The aim of this study was to review our 20-year experience with the Ross–Konno procedure in a large cohort of patients to evaluate outcomes and optimize patient selection.

MATERIALS AND METHODS

Patients and data collection

The Ethics Committee of the Leiden University Medical Center approved this retrospective observational study and waived the need for patients' or parental informed consent. All patients who underwent the Ross–Konno procedure between January 1995 and December 2014 were identified. Only patients requiring a generous interventricular incision to augment the LVOT were included in this study. Young patients with a Ross operation in whom the septum was slightly incised to make the autograft fit into the smaller aortic annulus were excluded. Data were collected from medical records, including patient charts, operative reports and echocardiographic examinations.

Surgical technique

Median sternotomy was performed in all patients. Cardiopulmonary bypass was achieved with bicaval cannulation and mild hypothermia (deep hypothermia in

case of aortic arch reconstruction). Antegrade cold crystalloid cardioplegia with external myocardial cooling was administered. Both coronary arteries were excised and mobilized, and the aortic valve and sinuses of Valsalva were removed. The pulmonary autograft was excised with a muscular tongue of the right ventricular (RV) anterior wall. The Konno incision was made in the interventricular septum starting under the commissure between the left and right coronary leaflets, towards the VSD if present (resecting the outflow septum). This incision was extended as far as necessary for full relief of LVOT obstruction (LVOTO). Fibrous and/or muscular LVOTO was resected or enucleated. The pulmonary autograft was placed in aortic position, typically closing the interventricular incision using the RV anterior wall tongue (in 2 early patients, the septal incision was closed with a patch). Care was taken to precisely position the RV anterior wall tongue as a minor rotation could lead to some degree of aortic insufficiency. Both coronary artery buttons were reimplanted into the autograft and the distal anastomosis with the ascending aorta was made. The RV–PA connection was restored, using a homograft or bovine jugular vein conduit. Running sutures were universally used, with sutures at the base of the root being reinforced with a thin strip of pericardium in all patients. Reinforcement of the sinotubular junction anastomosis was mainly used in older children.

Echocardiographic data

For each patient, echocardiographic data were collected to examine ventricular and valvular functions as well as neoaortic dilatation. Preoperative and most recent (or before reoperation) measurements of the LVOT (minimal diameter), aortic annulus, sinus and sinotubular junction diameters were retrospectively collected and analysed. Echocardiographic *Z* -scores of annular and sinus of Valsalva diameters were based on data from Pettersen *et al* . and Roman *et al*., respectively[1, 2].

Statistical analysis

Continuous variables are expressed as mean ± standard deviation (SD) or median and (interquartile) range, as appropriate. Categorical variables are reported as numbers and percentages. Early mortality was defined as death within 30 days after the Ross–Konno operation or during the same hospital admission. Overall survival and freedom from reoperation were estimated using the Kaplan–Meier

method and differences in survival curves between subgroups of patients were tested using the log-rank test. Estimates of overall survival and freedom from reoperation are expressed as percentage with 95% confidence interval (CI). Univariable binary logistic regression analysis was performed to identify risk factors for early mortality. Univariable Cox regression analysis was performed to examine risk factors for late mortality and reoperation. The predictor variables considered were age at operation and preoperative poor LV function, EFE and aortic annular size. The non-parametric Mann–Whitney *U* -test was used to evaluate the difference in neoaortic dilatation between patients aged under or above 1 year at operation. A *P* -value of less than 0.05 (two-sided) was considered statistically significant. Survival analysis was performed using GraphPad Prism 6 (GraphPad Software, Inc., La Jolla, CA, USA). All other analyses were performed with SPSS 20 (IBM Corp., Armonk, NY, USA).

RESULTS

Patient population

Forty-eight (73% male) patients underwent the Ross–Konno procedure. The median age at operation was 12.8 months, ranging from 11 days to 31 years (interquartile range, 3.7 months to 9.4 years). Twenty-two patients were under 1 year of age, 9 of which were under 3 months of age and 3 were younger than 1 month at the time of surgery. One patient was older than 18 years. Almost half of the patients (48%) had associated cardiac or aortic anomalies. Two patients had a bicuspid pulmonary valve at the time of surgery. Five patients had a preoperative poor LV function and important EFE. Patient characteristics and initial diagnoses are presented in Table 1.

Table 1: Patient characteristics and initial diagnoses

Patient characteristics	***n* (%)**
Male sex	35 (73)
Age at operation in months (median; range)	12.8 months (11 days–31 years)
<1 year of age	22
<3 months	9
<1 month	3
Aortic annulus *Z* -score (mean ± SD)	−1.7 ± 2.3
Initial diagnosis	
AoS/LVOTO	25 (52)
IAA–VSD	11 (23)
AoS + CoA + arch hypoplasia (±VSD)	10 (21)
AVSD	2 (4)
HOCM	1 (2)
Bicuspid aortic valve	24 (50)
Bicuspid pulmonary valve	2 (4)
AR after balloon dilatation	7 (15)
Mitral valve stenosis/insufficiency	5 (10)
Poor LV function	5 (10)
Important EFE	5 (10)

AoS: aortic valve stenosis; AR: aortic regurgitation; AVSD: atrioventricular septal defect; CoA: coarctation of the aorta; EFE: endocardial fibroelastosis; HOCM: hypertrophic obstructive cardiomyopathy; IAA: interrupted aortic arch; LV: left ventricle; LVOTO: left ventricular outflow tract obstruction; SD: standard deviation; VSD: ventricular septal defect.

There were a total of 82 previous interventions in 44 patients. Nineteen procedures were percutaneous, namely foetal balloon valvuloplasty (*n* = 1), balloon valvuloplasty (*n* = 15) and balloon dilatation of the CoA (*n* = 3). One patient had an intrauterine balloon valvulotomy of the aortic valve at a gestational age of 24 + 4 weeks, dilating the aortic annulus from 2.5 to 2.9 mm. Two days after birth, another balloon valvuloplasty was performed. Eventually, at the age of 16 days, the Ross–Konno procedure was performed. One 31-year-old patient required a Ross–Konno procedure because of LVOTO after coarctation repair twice, resection of a subaortic stenosis and balloon valvuloplasty of a bicuspid aortic valve. The aortic annulus of this patient had a diameter of 12 mm and the autograft had a diameter of 25 mm. In 3 patients, balloon valvuloplasty resulted in significant aortic regurgitation (AR). A complete overview of previous procedures is presented in Table 2.

Table 2: Previous procedures

Procedure	*n* (%)
Percutaneous balloon dilatation	19 (40)
Aortic valve repair	11 (23)
Subaortic stenosis repair	18 (38)
Aortic arch repair	16 (33)
IAA + VSD repair	8 (17)
VSD closure	6 (13)
AVSD repair	2 (4)
Hybrid Norwood	3 (6)
Mitral valve replacement	2 (4)
Mitral valve repair	1 (2)
Tricuspid valve repair	1 (2)
Pacemaker implantation	2 (4)
Operation for constrictive pericarditis	1 (2)
Aortopexy	1 (2)

AVSD: atrioventricular septal defect; IAA: interrupted aortic arch; VSD: ventricular septal defect.

Operative data and complications

Operative details are presented in Table 3. The septal incision was closed using the RV free wall tongue attached to the pulmonary autograft in all but 2 early patients in whom a xenopericardial patch was used. Eleven patients had concomitant procedures, namely, aortic arch repair (n = 5), mitral valve surgery (n = 5) and ascending aorta replacement (n = 1). In most patients (69%), the RV–PA connection was restored, using a Contegra (Medtronic, Minneapolis, MN, USA) bovine jugular vein graft. Three patients required postoperative extracorporeal membrane oxygenation (ECMO) support because of low cardiac output. ECMO could be weaned in 2 patients who survived. There were 6 (12.5%) early deaths, of whom 2 were neonates and 4 were infants. Preoperative poor LV function with or without EFE was present in 4 out of the 6 early deaths. The 2 neonatal patients in this group had severe LV dysfunction and important EFE (Table 4). Univariable binary logistic regression analysis identified poor LV function (odds ratio = 9.5; 95% CI = 1.4–63.7; P = 0.020) as the only risk factor for early mortality.

Table 3: Operative details

Operative details	*n* (%)
Emergency setting	3 (6)
Cross-clamp time in minutes (median; range)	147 (80–305)
Concomitant procedures	11 (23)
Aortic arch repair	5 (10)
Ascending aorta replacement	1 (2)
Mitral valve repair	2 (4)
Mitral valve replacement	1 (2)
Mitral valve rereplacement	2 (4)
RV–PA conduits	
Bovine jugular vein conduit	33 (69)
Cryopreserved pulmonary homograft	11 (23)
Cryopreserved aortic homograft	4 (8)
Complications	
LCO requiring ECMO	3 (6)
Permanent pacemaker	2 (4)

ECMO: extracorporeal membranous oxygenation; LCO: low cardiac output; RV–PA: right ventricle to pulmonary artery.

Table 4: Mortality causes

Patient no.	Age at operation	Time between surgery and death	Diagnosis	Previous surgery	Concomitant procedures	Cause of death
1	11 days	0 days	AoS, CoA, arch hypo-plasia, VSD, poor LVF, EFE	AVP, aortic arch repair	None	LV failure
2	123 days	0 days	IAA, VSD, severe LVOTO, poor LVF	IAA + VSD repair, aortopexy	None	LV failure
3	4 months	0 days	IAA, VSD, LVOTO	Hybrid Norwood	Arch repair	Massive lung bleeding
4	3 months	6 days	IAA, VSD, LVOTO	Hybrid Norwood	Arch repair	Postop ECMO, thrombus in neoaortic root and MI
5	54 days	10 days	IAA, VSD	IAA + VSD repair	None	LV failure

Patient no.	Age at operation	Time between surgery and death	Diagnosis	Previous surgery	Concomitant procedures	Cause of death
6	26 days	24 days	AoS, poor LVF, EFE	Balloon dilatation resulting in AR	None	Septic shock
7	15 months	6 months	CoA, iAVSD	CoA + AVSD repair, MVR	None	Unexplained (no autopsy)
8	16 years	7 months	AoS, AR, DSAS	DSAS removal	None	Pulmonary embolism during balloon dilatation of the RV–PA conduit
9	74 days	1.1 year	AoS, severe EFE	Balloon dilatation resulting in AR	None	Sepsis, cardiac and pulmonary insufficiency
10	37 days	12.7 years	Unknown syndrome, AoS, CoA, arch hypoplasia, VSD	AVP, aortic arch + VSD repair	None	Recurrent pneumonia/ empyema, with secondary heart failure

AoS: aortic stenosis; AR: aortic regurgitation; AVP: aortic valve plasty; CoA: coarctation of the aorta; DSAS: discrete subaortic stenosis; ECMO: extracorporeal membrane oxygenation; EFE: endocardial fibroelastosis; IAA: interrupted aortic arch; iAVSD: incomplete atrioventricular septal defect; LV: left ventricle; LVF: left ventricular function; MI: myocardial infarction; LVOTO: left ventricular outflow tract obstruction; MVR: mitral valve replacement; RV–PA: right ventricle to pulmonary artery; VSD: ventricular septal defect.

Follow-up

Follow-up was complete, with recent follow-up for all alive patients. Median follow-up for the total study population was 4.3 years (range, 0–20 years).

A total of 10 (20.8%) patients died, including early deaths. Causes of mortality for the whole series are presented in Table 4. Estimated overall survival at 5, 10 and 15 years was 83 (95% CI: 69–91%), 79 (95% CI: 63–89%) and 70% (95% CI: 43–85%), respectively (Fig. 1). There were 4 (8.3%) late deaths. The linearized occurrence rate of late mortality was 1.4% per patient-year. No risk factor for late mortality could be identified.

Figure 1:

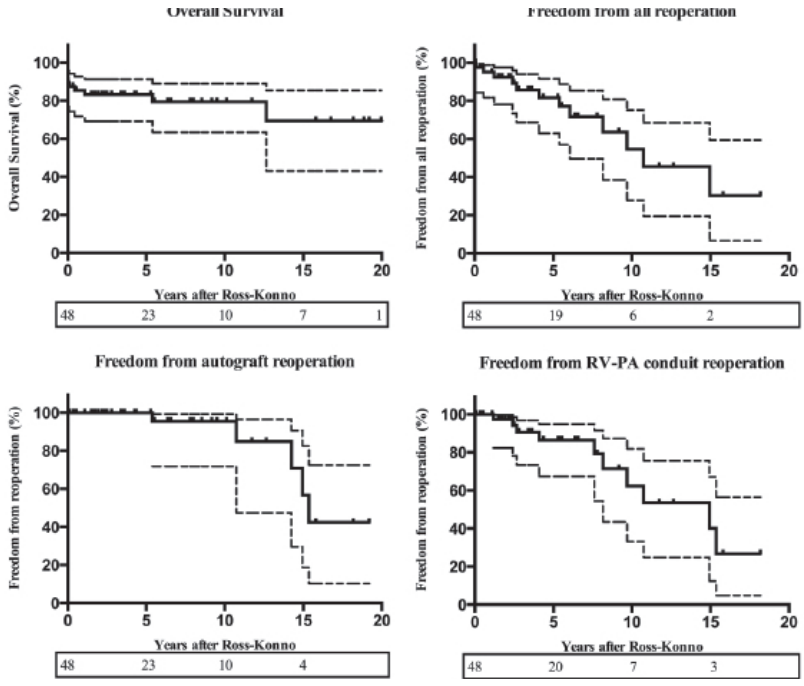

Kaplan–Meier curves for estimated overall survival (upper left), freedom from all reoperation (upper right), freedom from autograft reoperation (lower left) and freedom from right ventricular to pulmonary artery conduit reoperation (lower right). Dashed lines denote 95% confidence intervals. Numbers under the curves depict numbers at risk. RV–PA: right ventricle to pulmonary artery.

Table 5: Reoperation procedures

Reoperation procedures	***n* (%)**
RV–PA conduit change	10 (21)
Second RV–PA conduit change	3 (6)
Pulmonary autograft replacement	5 (10)
Mitral valve repair	2 (4)
Mitral valve replacement	1 (2)
Tricuspid valve repair	3 (6)
Residual VSD closure	1 (2)
Aortic arch rerepair	2 (4)
Ascending aorta plasty	1 (2)
Ostium plasty of LCA	1 (2)

LCA: left coronary artery; RV–PA: right ventricle to pulmonary artery; VSD: ventricular septal defect.

Table 6: Autograft reoperations

Patient no.	Age at operation	Years between surgery and reoperation	Indication for reoperation	Reoperation procedure
1	3 months	5.4	AR	Mechanical Bentall
2	17 years	10.7	Autograft dilatation (49 mm), PS, MS	Stentless aortic bioprosthesis, PVR (homograft), MVP
3	5 years	14.2	Autograft dilatation (45 mm), PS	Mechanical Bentall, PVR (homograft)
4	10 years	14.9	Autograft dilatation (50 mm), AR, PR, MR, TR	Stentless aortic bioprosthesis, PVR (homograft), MVP, TVP
5	10 years	15.3	AR, PS	Mechanical Bentall, PVR (bovine jugular vein)

AR: aortic regurgitation; MR: mitral regurgitation; MS: mitral stenosis; MVP: mitral valve plasty; PR: pulmonary regurgitation; PS: pulmonary stenosis; PVR: pulmonary valve replacement; TR: tricuspid regurgitation; TVP: tricuspid valve plasty.

Twelve patients required a total of 29 procedures in 17 reoperations. Reoperative procedures are presented in Table 5. Freedom from any reoperation, autograft reoperation and RV–PA conduit reoperation curves are presented in Fig. 1. Estimated freedom from all causes of reoperation was 82 (95% CI: 63–92%), 55 (95% CI: 28–75%) and 30% (95% CI: 7–59%) at 5, 10 and 15 years, respectively. Five patients required reoperation for autograft failure at a median of 14 years (range, 5–15 years) postoperatively (Table 6). One of these patients was under the age of 1 year at the time of the Ross–Konno procedure. This patient had a bicuspid pulmonary autograft which became insufficient after 5.4 years and had to be replaced with a mechanical prosthesis. Three patients had dilatation of the pulmonary autograft resulting in AR and underwent redo surgery. Two of them received a mechanical Bentall procedure and 1 patient received a stentless bioprosthetic aortic root replacement. One patient had aortic root dilatation without AR and underwent a Bentall procedure and RV–PA conduit change. For autograft reoperation, estimated 5-, 10- and 15-year freedom from reoperation rates were 100, 96 (95% CI: 72–99%) and 57% (95% CI: 19–83%), respectively. The

linearized occurrence rate of autograft reoperation was 1.8% per patient-year. No risk factor for autograft reoperation could be identified. Estimated freedom from RV–PA conduit reoperation at 5, 10 and 15 years was 87 (95% CI: 67–95%), 62 (95% CI: 33–82%) and 40% (95% CI: 12–67%), respectively. Freedom from RV–PA conduit reoperation curves was not significantly different for patients with a homograft versus patients with a bovine jugular vein conduit (log-rank test: $P = 0.806$).

Echocardiographic follow-up

At latest (or before reoperation) echocardiographic follow-up (median follow-up time = 4.4 years; range, 1 month to 19 years), 4 patients had mild (Grade I) AR and 1 patient had moderate (Grade II) AR. All other patients had none or trivial AR.

Figure 2:

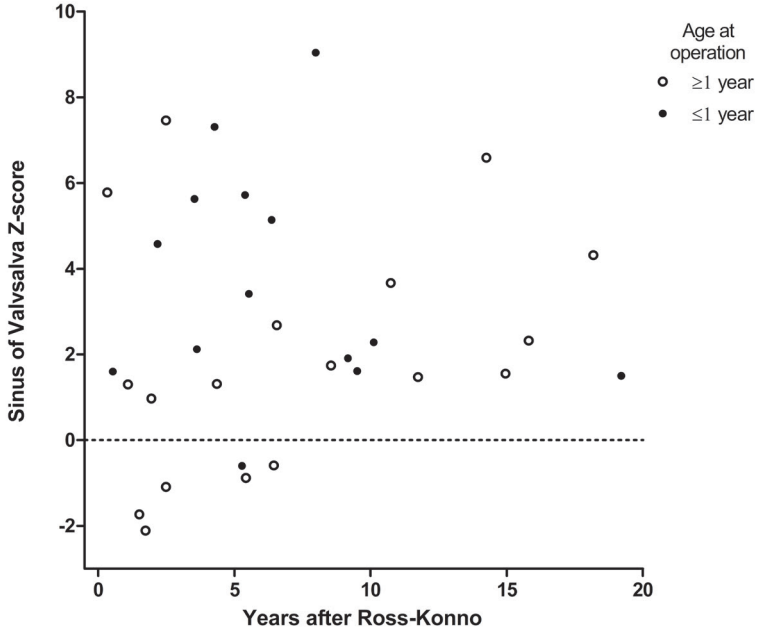

Autograft sinus of Valsalva *Z* -scores at latest echocardiographic follow-up. No association between operation before the age of 1 year and a reduced incidence of autograft dilatation could be demonstrated.

Reliable measurements of the autograft sinus of Valsalva at last follow-up could be obtained for 32 patients. The sinus of Valsalva *Z* -scores for patients younger

versus those above 1 year of age at the time of the Ross–Konno procedure are shown in Fig. 2. The *Z* -scores were not significantly different between both age groups. Left ventricular function was good in all but 4 patients who had moderate impairment of the LV function. Three patients had a moderate RV dysfunction; all other patients had good RV function. Mean gradient over the RV–PA conduit was 27 ± 15 mmHg. Two patients had severe pulmonary regurgitation (PR) which was tolerated well, 2 patients had moderate to severe PR, 4 had moderate PR and all other patients had none to mild PR.

DISCUSSION

This study describes 48 patients who underwent the Ross–Konno procedure for severe multilevel LVOTO. All but 1 patient were under 18 years of age at the time of surgery, with half of all patients being under 3 years of age. The vast majority of patients had undergone one or more procedures prior to the Ross–Konno operation. The Ross–Konno procedure was and also should be a last resort operation. We believe that the Ross–Konno procedure is safer in older patients and that, whenever possible, this operation should be avoided in the neonatal or early infancy period.

Damage to the first septal branch of the left anterior descending coronary artery is extremely rare as the septal incision usually does not interfere with this artery. However, there are several other technical challenges associated with the Ross–Konno procedure. First, the use of the attached tongue of the RV anterior wall typically directs the positioning of the autograft on top of the LV. Care should be taken to obtain a perfect fit of this autograft 'tongue' into the interventricular incision as the failure to do so may result in postoperative autograft insufficiency. In the present series, neoaortic valve regurgitation mostly occurred much later in the follow-up. Second, especially in neonates and infants with a small aorta, coronary artery reimplantation can be difficult, as the distance between both coronary ostia has to be much greater when implanted in the pulmonary autograft. In neonates and small children in our series, the right coronary artery had to be directed to the non-coronary sinus in several patients. Lastly, coronary kinking has to be avoided at all costs.

The Ross–Konno procedure remains a high-risk procedure. In our series, the early mortality rate was 12.5%. This is consistent with a recent report by Vergnat *et*

al. [3], reporting an early mortality rate of 10.2%. We found preoperative poor LV function to be a risk factor for early mortality, which was also found by Vergnat *et al*. Mitral valve disease in our series, however, was predominantly valve insufficiency, whereas in the report by Vergnat and his group it was mainly valve stenosis. This difference might be due to patient selection or chance. Others have reported more positve early mortality outcomes. Aszyk *et al.* described their experience with 16 patients under the age of 1 year undergoing the Ross–Konno procedure. They reported no early mortality [4]. Maeda *et al.* [5] reported 1 early death in 24 patients operated under the age of 1 year.

Deciding which patient is eligible for the Ross–Konno procedure can be very difficult, especially in patients with borderline LV and EFE. We had a learning curve in selecting patients for either biventricular repair, i.e. the Ross–Konno procedure, or univentricular palliation. In our series, a preoperative poor LV function with or without EFE was present in 3 of the 6 early deaths. Most of our early deaths with preoperative LV impairment were in the earlier years. In retrospect, 2 patients with both poor LV function and EFE would nowadays not have been selected for Ross–Konno surgery. We now believe that the Ross–Konno procedure can be performed even when the LV function is seriously depressed. However, this statement is only valid when the LV dysfunction is caused by aortic valve stenosis and/or AR. In these cases, the LV dysfunction appears to be reversible following the Ross–Konno operation. On the other hand, in our experience, when the LV dysfunction is (also) present because of some degree of LV hypoplasia, especially when combined with more than mild EFE, results are much worse and one should probably refrain from the Ross–Konno procedure. Our experience with EFE resection combined with a Ross–Konno operation is however limited; others have reported better outcomes [6]. It should be noted though, that the grey area for choosing between biventricular repair, i.e. Ross–Konno, or univentricular management, i.e. Fontan circulation, remains broad and the diagnostic criteria are not always clear. In 3 patients that eventually underwent the Ross–Konno procedure, we first performed a hybrid Norwood procedure (ductal stenting and bilateral pulmonary artery banding) to allow the LV to grow, postponing the decision for uni- or biventricular correction. Two of these patients died (Table 4). The third patient was doing well 3 months after surgery.

Estimated freedom from autograft reoperation in our study was 100, 96 and 57% at 5, 10 and 15 years, respectively. This is consistent with other reports about autograft reoperation after Ross or Ross–Konno procedures in the same age group [3 , 7–9]. Autograft reoperation was indicated by either neoaortic root dilatation or regurgitation. It has been postulated that surgery early in life might protect against autograft dilatation. Lo Rito *et al.* [7] have shown the neoaortic root to be more stable in children operated on at an age younger than 18 months when compared with patients operated on at an age of over 18 months. We were not able to demonstrate such association between younger age (i.e. operation before the age of 1 year) and more stable autograft diameters. In our series, only 1 out of 22 patients operated on under 1 year of age needed later autograft replacement. This patient had a dysplastic bicuspid pulmonary valve at the time of the Ross–Konno procedure and this bicuspid pulmonary autograft developed valve insufficiency and was replaced by a mechanical prosthesis 5.4 years after the Ross–Konno procedure. In one other patient with a bicuspid pulmonary valve, the autograft showed complete normal function 5 years after the Ross–Konno procedure. Some patients in whom the autograft was dilated showed no aortic insufficiency in our series. This has been observed also in a study by others on autograft dilatation in patients after the Ross procedure [10]. Finally, without any exception, the Ross–Konno operation resulted in complete and durable relief of LVOTO. There were no residual or recurrent LVOT gradients.

Limitations

This is a retrospective study. Patient selection and operative care have improved over the years with likely improved outcomes. Although this is a relatively large patient cohort, in the survival analyses, the numbers of patients at risk after 10 years of follow-up were too small to allow for reliable estimates. Small patient numbers also hampered the analyses for potential risk factors for mortality and reoperation. The *Z* -score reference formulas for the preoperative and latest echocardiographic data were necessarily retrieved from two sources. For latest echocardiographic aortic sinus diameter, the *Z* -score formula for children was used in our patients under 18 years of age; the *Z* -score formula for adults till 40 years was used in our adult population.

CONCLUSION

The Ross–Konno operation is a valuable procedure that can fully and durably relieve multilevel LVOTO in a highly complex patient population with often multiple associated anomalies and previous interventions. High early mortality rates in patients with impaired LV function emphasize the importance of adequate patient selection. Freedom from reoperation shows a continuous attrition rate, most often for RV–PA conduit replacement. Reoperation for autograft failure may occur late after the Ross–Konno procedure.

ACKNOWLEDGEMENTS

The authors express their gratitude to F. Villagrá Blanco (Madrid), T. Podnar (Ljubljana), J. Sachweh (Hamburg) and J. Vazquez-Jimenez (Aachen), for their help in data collection.

Conflict of interest: none declared.

REFERENCES

1. Pettersen MD, Du W, Skeens ME, Humes RA. Regression equations for calculation of z scores of cardiac structures in a large cohort of healthy infants, children, and adolescents: an echocardiographic study. J Am Soc Echocardiogr 2008;21:922–34.

2. Roman MJ, Devereux RB, Kramer-Fox R, O'Loughlin J. Two-dimensional echocardiographic aortic root dimensions in normal children and adults. Am J Cardiol 1989;64:507–12.

3. Vergnat M, Roubertie F, Lambert V, Laux D, Ly M, Roussin R, et al. Mitral Disease: The Real Burden for Ross-Konno Procedure in Children. The Annals of Thoracic Surgery 2014;98:2165–72.

4. Aszyk P, Thiel C, Sinzobahamvya N, Luetter S, Photiadis J, Haun C, et al. Ross-Konno procedure in infants: mid-term results. European Journal of Cardio-Thoracic Surgery 2012;42:687–94.

5. Maeda K, Rizal RE, Lavrsen M, Malhotra SP, Akram SA, Davies R, et al. Midterm Results of the Modified Ross/Konno Procedure in Neonates and Infants. Ats 2012;94:156–63.

6. Emani SM, Bacha EA, McElhinney DB, Marx GR, Tworetzky W, Pigula FA, et al. Primary left ventricular rehabilitation is effective in maintaining two-ventricle physiology in the borderline left heart. The Journal of Thoracic and Cardiovascular Surgery 2009;138:1276–82.

7. Rito Lo M, Davies B, Brawn WJ, Jones TJ, Khan N, Stickley J, et al. Comparison of the Ross/Ross-Konno aortic root in children before and after the age of 18 months. European Journal of Cardio-Thoracic Surgery 2014;46:450–7.

8. Nelson JS, Pasquali SK, Pratt CN, Yu S, Donohue JE, Loccoh E, et al. Long-Term Survival and Reintervention After the Ross Procedure Across the Pediatric Age Spectrum. The Annals of Thoracic Surgery 2015;99:2086–94–discussion2094–5.

9. Brown JW, Ruzmetov M, Vijay P, Rodefeld MD, Turrentine MW. The Ross-Konno Procedure in Children: Outcomes, Autograft and Allograft Function, and Reoperations. The Annals of Thoracic Surgery 2006;82:1301–6.

10. Pasquali SK, Cohen MS, Shera D, Wernovsky G, Spray TL, Marino BS. The Relationship Between Neo-Aortic Root Dilation, Insufficiency, and Reintervention Following the Ross Procedure in Infants, Children, and Young Adults. Journal of the American College of Cardiology 2007;49:1806–12.

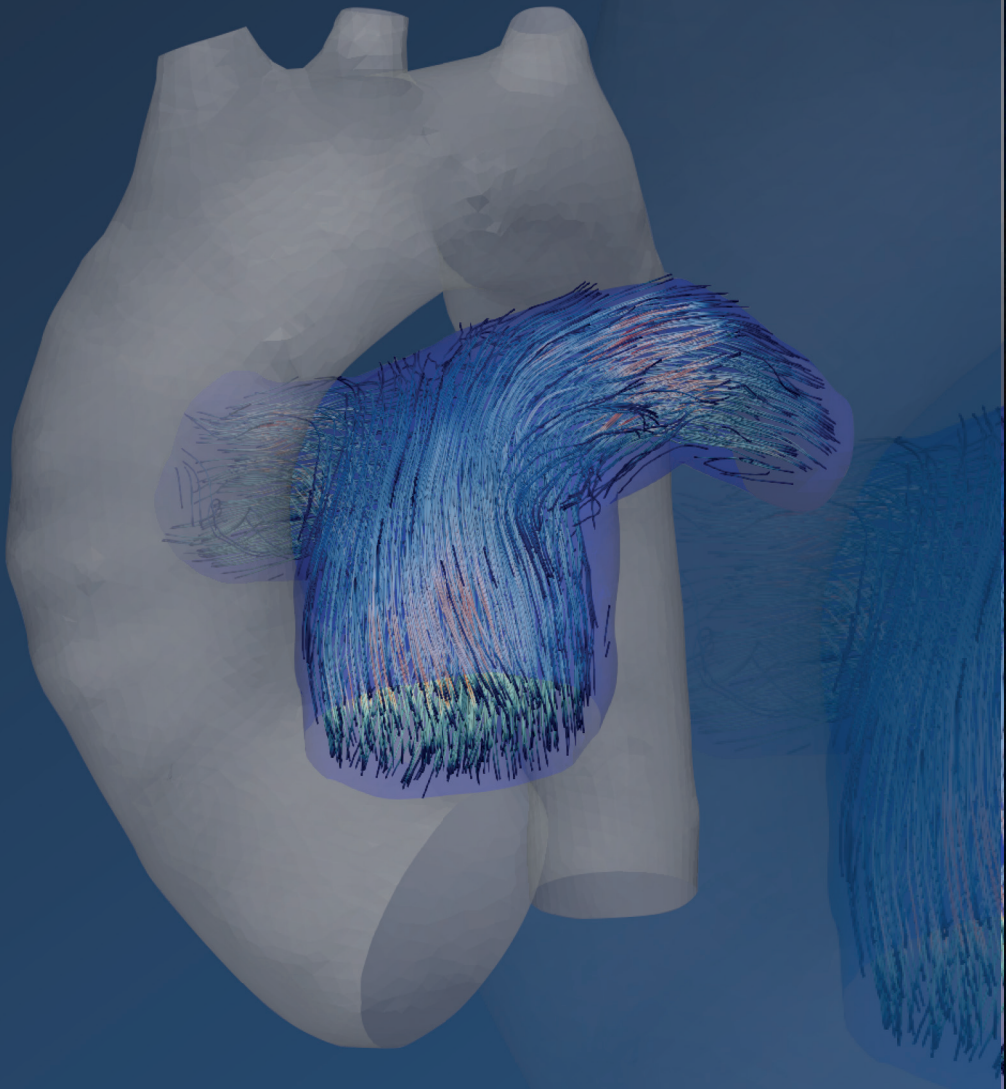

LONG-TERM FOLLOW-UP AFTER THE ROSS PROCEDURE:

A Single Center 22-Year Experience

Adriaan W. Schneider, Hein Putter, Robert J.M. Klautz, Eline F. Bruggemans, Eduard R. Holman, Regina Bökenkamp, Mark G. Hazekamp

Ann Thorac Surg. 2017 Jun;103(6):1976-1983.

CHAPTER 3

ABSTRACT

Background: The aim of this study was to analyze long-term outcomes after the Ross procedure, focusing on autograft function and risk of reoperation in time.

Methods: Between February 1994 and February 2016, 154 patients underwent the Ross (n = 105) and Ross-Konno (n = 49) procedure at our institution and were included in this study. Data were collected retrospectively from patients' medical records or through telephone contact. Competing risks analyses were performed to determine incidences of death and reoperation. A multistate model was constructed to provide insights in the clinical trajectory after operation.

Results: Median age was 12 years, 74% were pediatric patients, and 66% had previous surgical procedures. There were 8 (5%) early deaths, 6 of whom underwent the Ross-Konno procedure, and 10 (7%) late deaths. Survival rates at 15 and 20 years were 86% in the total cohort and 91% in the isolated Ross subgroup. Linearized occurrence rates of endocarditis and valve thrombosis, thromboembolism, and bleeding events combined were 0.30% per patient-year and 0.15% per patient-year, respectively. Cumulative incidences of all-cause reoperation at 15 and 20 years were 35.2% and 45.3%, respectively. Twenty-six patients needed autograft reoperation, 20 due to dilatation. Cumulative incidences of autograft reoperation at 15 and 20 years were 20.1% and 31.1%, respectively. At latest echocardiogram, 4 patients had moderate aortic regurgitation and none had stenosis.

Conclusions: The Ross procedure can be performed safely in young patients with low number of valve-related events. Autograft function remains stable in the first decade after operation, but autograft dilatation in the second decade necessitates reintervention.

INTRODUCTION

Several prostheses are available to replace a dysfunctioning aortic valve. In younger patients, the American and European guidelines currently recommend mechanical prostheses [1, 2]. Their advantage over biological prostheses of longer durability comes at the cost of lifelong anticoagulant treatment.

For young patients in whom a mechanical prosthesis is contraindicated, or who prefer a biological prosthesis, the choice of prosthesis is subject to debate. Several bioprostheses are currently available, but all have relatively short lifetime in younger patients [3]. Alternatively, the pulmonary autograft can be used to replace the diseased aortic valve. This technique has several advantages over other bioprostheses. One of the most important advantages is the growth potential of the pulmonary autograft in children. Furthermore, long-term outcomes might be superior to other biological prostheses [4]. A main disadvantage of the Ross procedure, however, is that a dual valve problem is created for only a single diseased valve. Furthermore, the need for autograft reoperation might impose a problem during late follow-up [4].

Most studies on the Ross procedure have limited follow-up times of about 10 years [5 - 8]. In the present study, we describe our single institution, 22-year experience with the Ross procedure, focusing mainly on autograft function and risk of reoperation in the long-term follow-up.

PATIENTS AND METHODS

Patients and Data Collection

The Ethics Committee of the Leiden University Medical Center approved this retrospective observational study and waived the need for informed consent. All patients who underwent the Ross(-Konno) procedure between February 1994 and February 2016 at the Center for Congenital Heart Disease Amsterdam Leiden, a collaboration between the Leiden University Medical Center, the Academic Medical Center, and the VU Medical Center in the Netherlands, were identified in the center's database and included. Data were collected from patients' medical records or through contact by telephone.

Surgical Technique

After initiation of cardiopulmonary bypass with mild hypothermia and cardiac arrest with cold crystalloid cardioplegia, the aortic valve was inspected. When a repair of the aortic valve did not seem to be durable, the Ross procedure was performed. A subcoronary and root-inclusion technique was used in a small number of patients. In most patients, the autograft was implanted as a neo-root. The pulmonary autograft was placed in the aortic position, generally reinforcing the proximal suture line with a strip of autologous pericardium. In patients with a too narrow aortic annulus or left ventricular outflow tract obstruction, a Konno incision was made to enlarge the aortic annulus [9]. In some fully grown patients, the autograft and ascending aorta were reinforced with a vascular graft above the coronary arteries to prevent autograft dilatation. In others, the autograft was implanted in a Gelweave Valsalva (Vascutek, Renfrewshire, Scotland) vascular prosthesis, starting at the proximal anastomosis. Then, the commissures were fixed into the graft, and the sinuses of Valsalva of the autograft were fully scalloped in a way similar to the valve-sparing root replacement (VSRR) reimplantation technique described by David and Feindel [10]. The distal suture line of the autograft into the vascular graft was made. Finally, an end-to-end anastomosis was made between the vascular graft and native aorta.

Data Reporting

Data are reported according to the 2008 guidelines for reporting mortality and morbidity after cardiac valve interventions [11]. Early mortality was defined as all-cause mortality within 30 days after operation or during the initial hospital admission. Echocardiographic variables were reported according to current guidelines 1, 12. Valve-related events were counted until reoperation on the concerning valve. Data are reported for the total patient cohort and separately for patients who underwent a Ross procedure without the Konno incision (Ross subgroup). The results on most of the patients who underwent a Ross-Konno procedure have been published previously [9]. It was decided to include these patients in the present analysis, because autograft dilatation is one of the most important issues with the Ross(-Konno) procedure and is independent of the Konno incision.

Follow-Up

Ten patients were lost to follow-up because they returned to their country of origin or emigrated from the Netherlands and were censored from the survival analyses at latest known follow-up. For the remaining 144 patients, clinical follow-up was 100% complete with recent echocardiographic data available for 87% of patients. Median follow-up time for the total patient cohort was 10 years (interquartile range [IQR]: 3 to 19 years) and for the Ross subgroup 17 years (IQR: 4 to 20 years). Total follow-up was 1663 patient-years for the total cohort and 1330 patient-years for the Ross subgroup. Follow-up closed on February 29, 2016.

Statistical Analysis

Continuous variables are expressed as mean ± SD for normally distributed data or as median (interquartile range) for non-normally distributed data. Categorical variables are reported as numbers and percentages. Overall survival was estimated using the Kaplan-Meier method and reported as percentage (95% CI). Differences in overall survival between the Ross and Ross-Konno subgroups were tested using the log-rank test. To avoid informative censoring in the analysis of freedom from reoperation, a competing risks analysis was performed considering death as a competing risk of autograft and all-cause reoperation. Furthermore, to provide more reliable information on reoperation occurrence after surviving the index procedure, early mortality was excluded from the competing risks analysis. The cumulative incidences of death and first autograft reoperation or first all-cause reoperation were estimated using the mstate package version 0.2.8 [13] in R (R version 3.1.2; R Foundation for Statistical Computing, Vienna, Austria) and reported as incidence (95% CI). A multistate model was constructed to estimate the time-dependent probability of being in a specific state, excluding early mortality. Patients started in the event-free state (state 1) and could remain there until censored or pass to one of the following states: right ventricle to pulmonary artery (RV-PA) conduit reoperation (state 2), autograft reoperation (state 3), or death (state 4). Patients who underwent surgical procedures on their RV-PA conduit and autograft simultaneously passed to state 3. Patients in state 2 could either pass to state 3 or state 4. Patients in state 3 could only pass to state 4. Risk factors for autograft reoperation (age, Konno, non-tricuspid valve, and hemodynamics) were analyzed using a Cox proportional hazards model. A p value of less than 0.05 (two-sided) was considered statistically significant.

RESULTS

Of the total of 154 patients who underwent the Ross(-Konno) procedure, 115 patients (75%) were male. The median age at operation was 12 years, ranging from 19 days to 48 years, and 114 patients (74%) were younger than 18 years of age at the time of operation. Two-thirds of the patients had had previous cardiac operations. Most patients had either aortic valve stenosis (46%) or combined stenosis and regurgitation (29%). For the Ross subgroup, the main hemodynamic profiles were mixed (43%) and regurgitant (36%) disease. Most patients (60%) had a bicuspid aortic valve. Patient characteristics are shown in Table 1.

Table 1. Patient Characteristics

Characteristic	Ross (n = 105)	Ross-Konno (n = 49)	Total (n = 154)
Male sex	79 (75)	36 (74)	115 (75)
Age at operation, years	14 (8–25)	1 (0.25–9)	12 (5–19)
Pediatric	66 (63)	48 (98)	114 (74)
Previous operation	58 (55)	44 (90)	102 (66)
Aortic valvulotomy	19 (18)	11 (22)	30 (19)
Trusler plasty	4 (4)	...	4 (3)
Balloon valvuloplasty	25 (24)	20 (41)	45 (29)
Second balloon valvuloplasty	5 (5)	3 (6)	8 (5)
Aortic valve replacement	7 (7)	...	7 (5)
Second aortic valve replacement	2 (2)	...	2 (1)
Hemodynamics			
Stenosis	22 (21)	49 (100)	71 (46)
Regurgitation	38 (36)	...	38 (25)
Mixed	45 (43)	...	45 (29)
Cause			
Degenerative	3 (3)	...	
Rheumatic	7 (7)	...	
Endocarditis	3 (3)	...	
Failed prosthesis	4 (4)	...	
Congenital	80 (76)	49 (100)	
Other	8 (8)	...	

Values are n (%) or median (interquartile range).

Operative Details

Median cross-clamping time was 134 minutes (range, 65 to 238 minutes). Twenty-nine patients (19%) had concomitant surgical procedure, ranging from bypass surgery to mitral valve replacement. A Konno incision was needed in 49 patients

(32%). In the Ross subgroup, 18 patients (12%) required either small annular extension by incising the annular fibrous ring or annular reduction to make the

Table 2. Operative Details

Operative Details	Ross (n = 105)	Ross-Konno (n = 49)	Total (n = 154)
Cross-clamp time, median (range), minutes	125 (65–238)	150 (80–305)	134 (65–238)
Aortic valve cusps, n (%)			
Unicuspid	2 (2)	...	2 (1)
Bicuspid	65 (62)	27 (55)	92 (60)
Tricuspid	37 (35)	22 (45)	59 (38)
Quadricuspid	1 (1)	...	1 (1)
Implantation technique, n (%)			
Subcoronary	2 (2)	...	2 (1)
Root-inclusion	2 (2)	...	2 (1)
Root replacement	101 (96)	49 (100)	150 (97)
Wrapped pulmonary autograft, n (%)	8 (8)	...	8 (5)
Of which scalloped, n	6	...	6
Additional aortic annulus procedures, n (%)	18 (17)	...	18 (12)
Annular extension	14 (13)	...	14 (9)
Annular reduction	3 (3)	...	3 (2)
Autograft annular reduction, n (%)	1 (1)	...	1 (1)
Right ventricle to pulmonary artery conduit			
Cryopreserved pulmonary homograft	81 (77)	12 (25)	93 (60)
Decellularized pulmonary homograft	2 (2)	...	2 (1)
Cryopreserved aortic homograft	...	4 (8)	4 (3)
Bovine jugular vein graft	22 (21)	33 (67)	55 (36)
Right ventricle to pulmonary artery graft size, mean (SD)	23 (3)	18 (5)	22 (5)
Concomitant procedure, n (%)	19 (18)	10 (20)	29 (19)

pulmonary autograft fit into the aortic annulus. In the later years of our series, the pulmonary autograft was implanted into a vascular tube graft in 8 patients to prevent later dilatation of the autograft. In 6 of these patients, the sinuses of Valsalva were scalloped. Most earlier patients (61%) received a pulmonary homograft to restore the RV-PA connection. Since 2001, a Contegra (Medtronic, Minneapolis,

MN) bovine jugular vein graft was used more often (Table 2). Five patients required postoperative extracorporeal membrane oxygenation for low cardiac output, 7 patients had a postoperative conduction block and required pacemaker implantation.

Survival

Table 3. Causes of Death in the Ross Group

Patient	Age at Operation	Time Between Operation and Death	Year of Operation	Previous Operation	Concomitant Procedures	Cause of Death
1	28 years	0 days	1997	PDA closure	DSAS removal	LV failure, MI due to split-like ostium LCA
2	19 days	57 days	2015	None	None	iCVA after resuscitation
3	31 years	5 months	1995	None	None	End-stage heart failure due to DCM
4	6 months	1 year	2011	Balloon valvuloplasty	None	iCVA after dissection of pulmonary trunk during balloon dilatation RV-PA -> surgical conduit
5	7 years	4 years	1996	Valvuloplasty, PDA + ASD closure	None	Diastolic heart failure due to severe EFE (proved by autopsy)
6	13 years	7 years	2006	None	MVP	Sudden, unexplained
7	35 years	9 years	1995	AVR	None	Sudden, unexplained
8	13 years	9 years	1996	Valvuloplasty, later balloon valvuloplasty	None	Unknown

ASD = atrial septal defect; AVR = aortic valve replacement; DCM = dilated cardiomyopathy; DSAS = discrete subaortic stenosis; EFE = endocardial fibroelastosis; iCVA = ischemic cerebrovascular accident; LCA = left coronary artery; LV = left ventricle; MI = myocardial infarction; MVP = mitral valve plasty; PDA = patent ductus arteriosus; RV-PA = right ventricle to pulmonary artery.

There were 8 early deaths (5%), 6 of whom underwent the Ross-Konno procedure. In total, there were 10 late deaths (7%), 4 of whom underwent the Ross-Konno procedure. A detailed summary of death causes in the Ross subgroup is shown in Table 3. Causes of death in patients who underwent a Ross-Konno procedure have been previously published in detail by our group [9]. For the total study population, 10-, 15-, and 20-year survival rates were 87.0% (95% CI, 81.2% to 93.1%), 85.9% (95% CI, 79.5% to 92.3%), and 85.7% (95% CI, 79.5% to 92.3%),

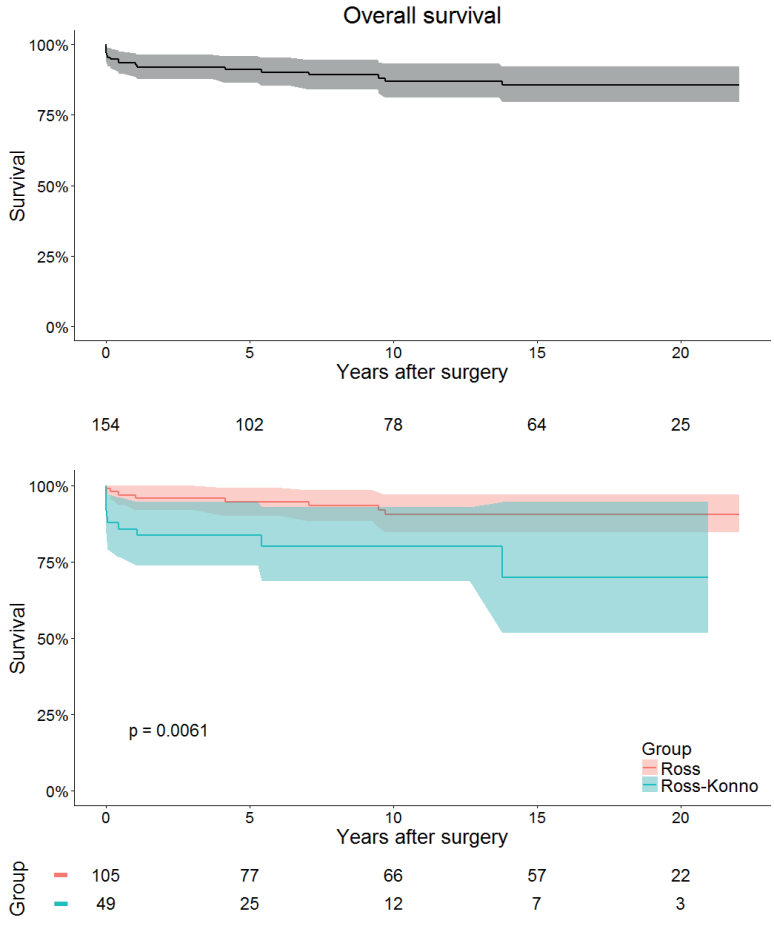

Figure 1. Survival plots for the total study population (top) and subgroups (bottom). Bands denote 95% CIs. Numbers under the curves denote numbers at risk.

respectively. For the Ross subgroup, the 5-year survival rate was 94.6% (95% CI, 90.2% to 99.3%), and 10-, 15-, and 20-year survival rates were 90.7% (95% CI, 84.6% to 97.1%). For the Ross-Konno subgroup, 5- and 10-year survival rates were 83.6% (95% CI, 73.9% to 94.7%) and 80.0% (95% CI, 68.7% to 93.1%), respectively, and the 15- and 20-year survival rates were 70.0% (95% CI, 51.7% to 94.7%). Survival in the Ross subgroup was significantly higher than in the Ross-Konno subgroup (p = 0.006). The linearized occurrence rate (LOR) of late mortality for the total cohort and the Ross subgroup were 0.60% and 0.45% per patient-year, respectively. Survival curves are shown in Figure 1.

Valve-Related Events in the Ross Subgroup

Four patients experienced endocarditis of their pulmonary homograft, 3 of whom needed pulmonary valve replacement. One patient experienced a *Coxiella burnetii* endocarditis but did not need reoperation. The LOR of endocarditis was 0.30% per patient-year. One patient with an impaired left ventricular function and pacemaker experienced a cerebral transient ischemic attack 18 years after Ross procedure, and 1 patient had an idiopathic small pulmonary embolism 6 years postoperatively. No other valve-related events occurred. The LOR of valve thrombosis, thromboembolism, and bleeding events combined was 0.15% per patient-year.

Freedom From Reoperation

The risks of reoperation in hospital survivors using the competing risks model are shown in Table 4. Twenty-six patients (18%) required reoperation on their autograft. Indications for autograft reoperation were autograft dilatation (diameter, >50 to 60 mm; rapid progression; or marked asymmetry of dilatation) in 20 patients, autograft regurgitation in 5 patients, and an iatrogenic perforation of one of the autograft leaflets during Ross procedure in 1 patient. No relationship between age and time to autograft reoperation was found. Fourteen patients received a mechanical prosthesis with (n = 12) or without (n = 2) ascending aorta replacement, 9 patients received a stentless aortic root bioprosthesis (Freestyle, Medtronic, Minneapolis, MN), 2 patients underwent VSRR (reimplantation technique), and 1 patient with an iatrogenic perforation of one of the autograft leaflets had a patch reconstruction of the defect. No risk factors for autograft reoperation were found (Table 5). Thirty-one patients (21%) required reoperation on their RV-PA conduit, some of them several times. The cumulative incidence of

RV-PA reoperation for the total group at 10, 15 and 20 years was 10.8% (95% CI, 4.9% to 16.7%), 25.6% (95% CI, 16.6% to 34.7%), and 35.5% (95% CI, 25.2% to 45.8%), respectively. For the Ross subgroup, 10-, 15-, and 20-year cumulative incidence of RV-PA reoperation was 5.8% (95% CI, 0.9% to 10.8%), 20.5% (95% CI, 11.2% to 29.8%), and 30.5% (95% CI, 19.6% to 41.5%), respectively, and for the Ross-Konno subgroup, 10- and 15-year cumulative incidence of RV-PA reoperation was 31.9% (95% CI, 11.0% to 52.9%) and 50.5% (95% CI, 26.1% to 75.0%), respectively.

Table 4. Cumulative Incidences of Reoperation

	Ross	Ross-Konno	Total Group
All-cause reoperation			
5 Years	9.2 (3.1–15.3)	13.9 (2.6–25.2)	10.5 (5.1–16.0)
10 Years	14.4 (6.9–21.9)	37.0 (16.1–57.9)	18.8 (11.5–26.2)
15 Years	30.8 (20.3–41.4)	57.2 (33.4–81.1)	35.2 (25.4–45.1)
20 Years	42.6 (30.8–54.3)		45.3 (34.6–56.0)
Autograft reoperation			
5 Years	3.5 (0–7.4)	0	2.4 (0–5.2)
10 Years	7.4 (1.7–13.0)	4.1 (0–11.9)	6.4 (1.8–11.0)
15 Years	20.0 (10.6–29.5)	26.3 (0.6–52.0)	20.1 (11.4–28.8)
20 Years	30.7 (19.4–42.0)	39.7 (10.8–68.6)	31.1 (20.5–41.7)

Values are incidence (95% CI).

Table 4. Risk factor analyses

Risk factors	Hazard ratio	95%CI	P-value
Autograft reoperation (Univariable Cox regression)			
Age	1.007	0.976–1.039	0.648
Konno	1.543	0.561–4.250	0.401
Non-tricuspid	0.951	0.412–2.192	0.906
Stenosis	0.974	0.432–2.195	0.949
Regurgitation	0.729	0.274–1.937	0.526

Multistate Model

The multistate model (Fig 2) showed a calculated probability of being event free after operation (ie, alive and without reoperation) of 88%, 75%, 58%, and 47%, respectively, at 5, 10, 15, and 20 years after operation. The probability of having had a reoperation on the pulmonary autograft (either combined with RV-PA

conduit reoperation or not) at 5, 10, 15, and 20 years was 3%, 6%, 22%, and 32%, respectively (Table 6).

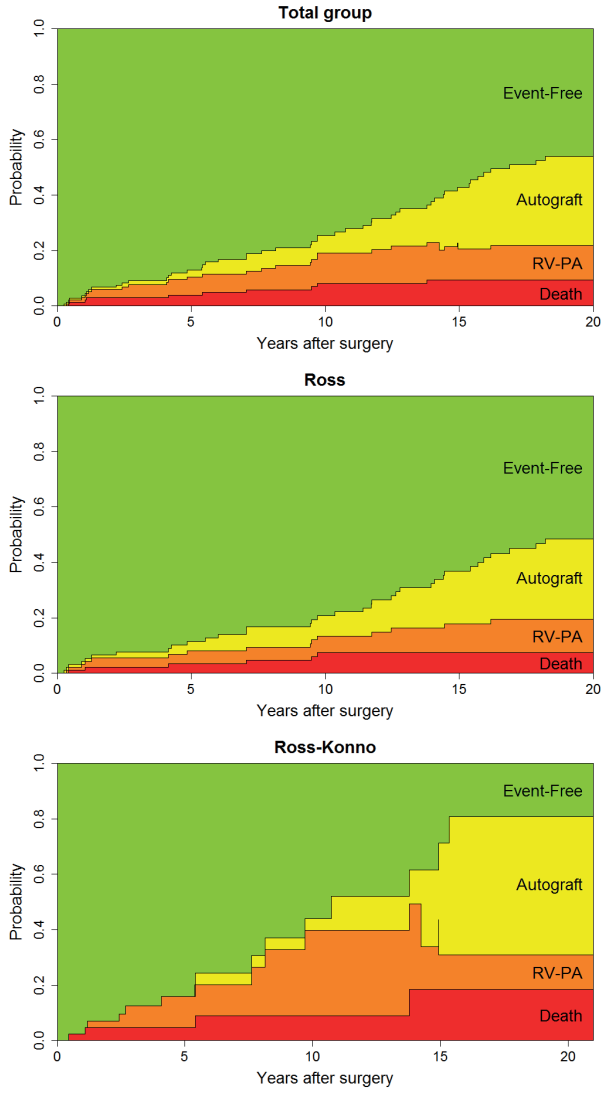

Fig 2. Multistate models of the states "event-free", right ventricle to pulmonary artery (RV-PA) reoperation ("RV-PA"), autograft with or without RV-PA reoperation ("autograft") and "death", excluding early mortality. This model follows each patient during follow-up and shows the proportion of patients in each state at any time. Multiple transitions per patient are possible. Patients started in the event-free state and could go to all other states. Patients within the RV-PA state could go to the autograft or death state, and patients in the autograft state could go to the death state.

Table 6. Multi state model estimates (all numbers are percentages, numbers between parentheses denote 95% confidence interval)

Total group	Event free	RV-PA reoperation	Autograft reoperation	Death
5 year	88.0 (82.2–93.6)	5.6 (1.7–9.6)	2.5 (0–5.2)	3.9 (0.6–7.2)
10 year	75.3 (67.0–83.5)	10.1 (4.4–15.7)	6.4 (1.8–11.1)	8.2 (3.1–13.3)
15 year	57.8 (47.6–67.9)	10.5 (3.6–17.6)	22.2 (13.1–31.4)	9.5 (3.8–15.1)
20 year	46.5 (35.7–57.2)	11.9 (4.6–19.2)	32.2 (21.6–42.7)	9.5 (3.8–15.1)
Ross group	**Event Free**	**RV-PA reoperation**	**Autograft reoperation**	**Death**
5year	89.7 (83.3–96.0)	3.4 (0–6.9)	3.5 (0–7.4)	3.4 (0–7.1)
10 year	80.3 (71.7–89.0)	4.7 (0.3–9.2)	7.4 (1.7–13.1)	7.5 (1.8–13.2)
15 year	64.0 (53.0–74.9)	9.2 (2.8–15.6)	19.3 (10.2–28.4)	7.5 (1.8–13.2)
20 year	52.2 (40.4–64.1)	10.9 (3.8–17.9)	29.4 (18.5–40.2)	7.5 (1.8–13.2)
Ross-Konno group	**Event Free**	**RV-PA reoperation**	**Autograft reoperation**	**Death**
5 year	84.0 (72.2–95.8)	11.3 (0.9–21.7)	0	4.7 (0–11.0)
10 year	56.0 (34.6–77.4)	30.9 (10.7–51.1)	4.2 (0–12.0)	8.9 (0–18.8)
15 year	19.2 (0–38.8)	12.5 (0–29.2)	40.2 (16.6–63.7)	18.5 (0.5–36.5)
20 year	19.2 (0–38.8)	12.5 (0–29.2)	49.8 (25.6–73.9)	18.5 (0.5–36.5)

Echocardiographic Follow-Up

Recent echocardiographic follow-up was available for 109 of 126 surviving patients with a median time to echocardiogram of 9 years (IQR, 3 to 17 years). Left ventricular function was good in all but 16 patients, of whom 13 had mild impairment and 3 had moderate impairment of left ventricular function. Right ventricular function was mildly impaired in 10 patients. Of patients who did not undergo reoperation on their autograft, 27 patients had mild aortic regurgitation (AR) and 4 patients had moderate AR. All had normal gradients (<20 mm Hg) over their autograft. Mean sinus of Valsalva diameter was 38 ± 7 mm, and 5 patients had sinus dilatation more than 45 mm in diameter, without more than mild AR.

Comment

Choosing an aortic valve substitute in children and young adults imposes some difficult decisions. The ideal prosthesis has a growing capacity in children, does not need anticoagulant treatment, and has a long durability. Mechanical

prostheses do have a long durability but need anticoagulant treatment. Of the available biological valve substitutes, limited durability was described 3, 14. The pulmonary autograft lacks the need of anticoagulant treatment and has a growing potential in children, but it comes at the cost of creating a double valve problem for a single valve disease. Its technical difficulty might impose a limitation for its use. In our series, early mortality was 5% for the total study population. However, if we only consider our straightforward Ross patients, that is, excluding the much more complex Ross-Konno patient group, early mortality was only 1.7%, which is lower than the pooled percentage in a meta-analysis [4]. Furthermore, one of the two early deaths in our Ross subgroup was due to a technical problem in the earlier years of our experience. Therefore, in experienced hands, early mortality approaches the postulated upper limit of operative mortality for elective aortic valve replacement of about 1%. Our 15- and 20-year survival rate of 91% in the Ross subgroup is comparable with that of other recent reports 5, 6, 7, 8.

Only 4 patients (0.3% per patient-year) experienced an endocarditis of the RV-PA conduit, of whom 3 needed reoperation, and none of the pulmonary autograft. This is lower compared with the 20% reported by Charitos and colleagues [15] and the pooled percentage reported by Takkenberg in a meta-analysis [4]. The low number of valve-related events seen in this present and other studies advocates the use of the Ross procedure.

After 20 years, cumulative incidence of reoperation was 45%, and cumulative incidence of autograft reintervention was 31%. This is also comparable with other recent reports 5, 6, 7, 8 and is better than expected from other conventional bioprostheses, especially considering the young age of the patient group. We could not identify risk factors for autograft reoperation. Most autograft reoperations consisted of either mechanical or biological valve and root replacement. We only performed two VSRR procedures. A recent article by Mookhoek and colleagues [16] showed a freedom from pulmonary autograft reoperation after VSRR of only 76% at 8 years. In our opinion, this rate does not justify the use of this technique. Furthermore, in our experience, at reoperation, autograft valve leaflets were very thin and often showed large fenestrations and low cuspal heights, which may limit the durability of VSRR in these patients. Hence, this technique should be reserved for either young patients with a shorter expected durability of a conventional prosthesis or patients with a strict contraindication for a mechanical prosthesis.

The German Ross Registry report [6] shows a higher freedom from autograft reoperation in subcoronary implanted autografts compared with root replacements. Because our series shows that most of the indications for autograft reoperation were due to dilatation of the autograft, this higher freedom from reoperation may be expected when the native aortic wall tissue is preserved [17]. The thinner autograft wall is more prone to dilate in the high-pressure systemic circulation. Several techniques of root reinforcement are available [18, 19]. Wrapping the autograft in a vascular tube graft has shown promising results in the mid-term [18]. We have adapted a technique in which we implant the pulmonary autograft in a vascular tube graft, removing the sinuses of Valsalva in a way similar to VSRR. Although we have no long-term outcomes of this procedure, we believe this might postpone autograft reoperation in this group of patients. The diameter of the vascular prosthesis should not interfere with somatic growth. Hence, the technique is limited to teenagers and adults. A potential downside to this technique is the more complex nature of the operation, reserving it to experienced centers only.

In our series, reoperations on the RV-PA conduit occurred earlier than reoperation on the autograft. This difference was the largest in the Ross-Konno patients, as expected because of the much younger patient group and growth of the child. Postponing autograft reoperation even more by recent wrapping techniques, RV-PA reoperation may become the real burden after the Ross procedure. However, in experienced hands, RV-PA reoperation has a lower operative risk and can even be performed with the use of transcatheter valve replacement. In our series, 7 patients received a transcatheter pulmonary valve. Recent developments with decellularized homografts [20] and tissue-engineered heart valves may also reduce the need for reoperation on the RV-PA conduit. Although no reoperation whatsoever after the Ross procedure will probably remain an utopia, providing a durable solution until the age in which conventional (biological) valve prostheses are accepted treatment options pleads in favor of the use of the Ross operation in young patients.

Mechanical prostheses are an alternative for the Ross procedure. A recent meta-analysis by Etnel and colleagues [21] comparing the Ross-procedure with, among others, mechanical aortic valve replacement in children, showed that the rate of reoperations was higher in the Ross group, mainly because of right-

sided reinterventions in growing children. Furthermore, endocarditis rates were comparable between both groups, but the Ross procedure was associated with significantly less thromboembolic events, and there was a trend toward lower bleeding rates in the Ross group. Risks and benefits of both type of interventions should be discussed with patients, their parents, or both.

The retrospective nature of this study comes with its accompanying limitations. This report describes an extensive study period in which surgical and perioperative treatment has changed and may have improved in time. The completeness and very long nature of follow-up provides valuable insights in the functioning of the pulmonary autograft and RV-PA conduits in time.

In conclusion, the Ross procedure can be performed safely in young patients in need of aortic valve replacement with very low number of valve-related events during a considerable long-term follow-up. Autograft function remains stable during the first decade after operation, but autograft dilatation in the second decade necessitates reintervention. New techniques that prevent dilatation of the pulmonary autograft will delay the need for autograft reoperation. Recent developments in less-invasive valve replacement techniques lower the reoperation risk, thus lowering the disadvantage of creating a double valve problem for single valve disease.

REFERENCES

1. Nishimura RA, Otto CM, Bonow RO, et al. 2014 AHA/ACC guideline for the management of patients with valvular heart disease: a report of the American College of Cardiology/ American Heart Association Task Force on Practice Guidelines. Journal of the American College of Cardiology 2014;63:e57–185.

2. Vahanian A, Alfieri O, Andreotti F, et al. Guidelines on the management of valvular heart disease (version 2012). European Heart Journal 2012;33:2451–96.

3. Chan V, Malas T, Lapierre H, et al. Reoperation of left heart valve bioprostheses according to age at implantation. Circulation 2011;124:S75–80.

4. Takkenberg JJM, Klieverik LMA, Schoof PH, et al. The Ross procedure: a systematic review and meta-analysis. Circulation 2009;119:222–8.

5. Miskovic A, Monsefi N, Karimian-Tabrizi A, Zierer A, Moritz A. A 17-year, single-centre experience with the Ross procedure: fulfilling the promise of a durable option without anticoagulation? Eur J Cardiothorac Surg 2016;49:514–9.

6. Sievers H-H, Stierle U, Charitos EI, et al. A multicentre evaluation of the autograft procedure for young patients undergoing aortic valve replacement: update on the German Ross Registry. Eur J Cardiothorac Surg 2016;49:212–8.

7. Kalfa D, Mohammadi S, Kalavrouziotis D, et al. Long-term outcomes of the Ross procedure in adults with severe aortic stenosis: single-centre experience with 20 years of follow-up. Eur J Cardiothorac Surg 2015;47:159–67.

8. Mastrobuoni S, de Kerchove L, Solari S, et al. The Ross procedure in young adults: over 20 years of experience in our Institution. Eur J Cardiothorac Surg 2016;49:507–12.

9. Schneider AW, Bökenkamp R, Bruggemans EF, Hazekamp MG. Twenty-year experience with the Ross-Konno procedure. Eur J Cardiothorac Surg 2016;49:1564–70.

10. David TE, Feindel CM. An aortic valve-sparing operation for patients with aortic incompetence and aneurysm of the ascending aorta. The Journal of Thoracic and Cardiovascular Surgery 1992;103:617–21.

11. Akins CW, Miller DC, Turina MI, et al. Guidelines for reporting mortality and morbidity after cardiac valve interventions. The Journal of Thoracic and Cardiovascular Surgery 2008;135:732–8.

12. Lang RM, Badano LP, Mor-Avi V, et al. Recommendations for cardiac chamber quantification by echocardiography in adults: an update from the American Society of Echocardiography and the European Association of Cardiovascular Imaging. J Am Soc Echocardiogr 2015;28:1–39.e14.

13. de Wreede LC, Fiocco M, Putter H. The mstate package for estimation and prediction in non- and semi-parametric multi-state and competing risks models. Comput Methods Programs Biomed 2010;99:261–74.

14. Jaquiss RDB. Bioprosthetic aortic valve replacement in the young: a cautionary tale. Circulation 2014;130:7–9.

15. Charitos EI, Takkenberg JJM, Hanke T, et al. Reoperations on the pulmonary autograft and pulmonary homograft after the Ross procedure: An update on the German Dutch Ross Registry. The Journal of Thoracic and Cardiovascular Surgery 2012;144:813–21.

16. Mookhoek A, de Kerchove L, Khoury El G, et al. European multicenter experience with valve-sparing reoperations after the Ross procedure. The Journal of Thoracic and Cardiovascular Surgery 2015;150:1132–7.

17. Schoof PH, Gittenberger-de Groot AC, de Heer E, Bruijn JA, Hazekamp MG, Huysmans HA. Remodeling of the porcine pulmonary autograft wall in the aortic position. The Journal of Thoracic and Cardiovascular Surgery 2000;120:55–65.

18. Juthier F, Banfi C, Vincentelli A, et al. Modified Ross operation with reinforcement of the pulmonary autograft: Six-year results. The Journal of Thoracic and Cardiovascular Surgery 2010;139:1420–3.

19. Skillington PD, Mokhles MM, Takkenberg JJM, et al. The Ross procedure using autologous support of the pulmonary autograft: techniques and late results. The Journal of Thoracic and Cardiovascular Surgery 2015;149:S46–52.

20. Sarikouch S, Horke A, Tudorache I, et al. Decellularized fresh homografts for pulmonary valve replacement: a decade of clinical experience. Eur J Cardiothorac Surg 2016;50:281–90.

21. Etnel JRG, Elmont LC, Ertekin E, et al. Outcome after aortic valve replacement in children: A systematic review and meta-analysis. The Journal of Thoracic and Cardiovascular Surgery 2016;151:143–52.e1–3.

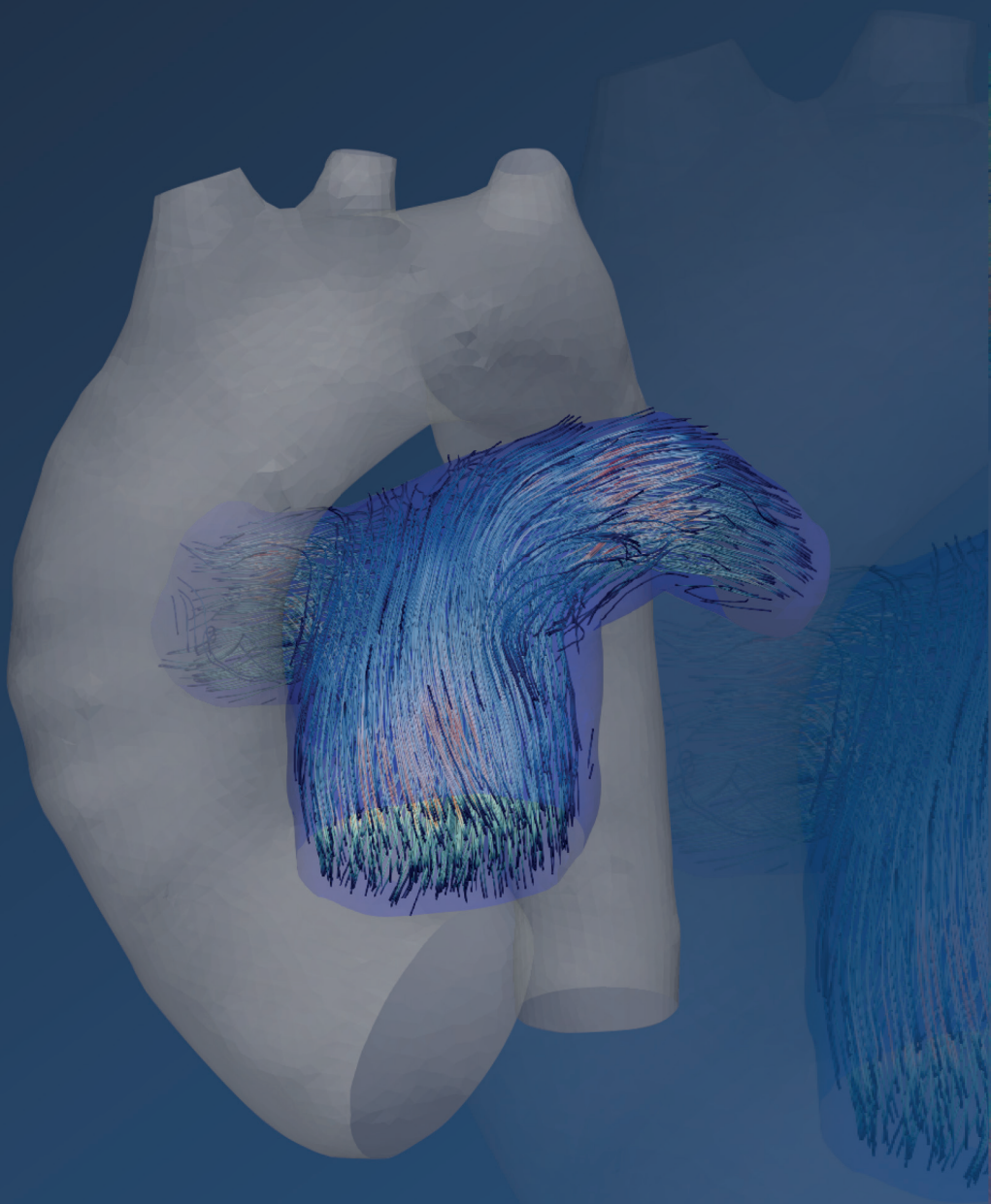

THE ROSS REIMPLANTATION TECHNIQUE

Scan this QR code to go to the movie

Adriaan W. Schneider, Robert J.M. Klautz, Mark G. Hazekamp

Multimed Man Cardiothorac Surg 2017;2017

CHAPTER 4

ABSTRACT

Pulmonary autograft replacement of a diseased aortic valve (the Ross procedure) is effective in children, where growth is essential, and in young patients for whom a biological solution is preferred. Long-term outcomes are generally good. However eventual autograft dilatation may necessitate reoperation. In order to diminish the risk of autograft dilatation, several 'wrapping' techniques have been developed. Here, we present our technique of choice: the reimplantation of the pulmonary autograft in a vascular tube graft, scalloping the sinuses of Valsalva. This leaves no bulky tissue inside the vascular tube graft and makes autograft dilatation impossible.

Patient Presentation

This 20-year-old male patient had a stenotic bicuspid aortic valve for which he underwent balloon valvuloplasty at the age of 6 months. This procedure resulted in moderate aortic valve regurgitation, which remained stable for over 18 years. However, the aortic regurgitation eventually increased to severe and the patient became symptomatic, with dyspnea on exertion. Preoperative echocardiography showed a dilated left ventricle (left ventricular internal end-systolic diameter of 36 mm) with good function (ejection fraction of 56%) and a severe aortic valve regurgitation with holodiastolic flow reversal. The patient was discussed in the Heart Team and accepted for surgery. The valve was considered to be unrepairable after preoperative assessment, and after providing extensive information on all treatment options, the patient opted for the Ross procedure if the valve was indeed found to be unrepairable.

Surgical Technique

1 - Aortic valve inspection and removal (0:07)

After initiation of cardiopulmonary bypass, the aorta is transected just above the sinotubular junction and cardioplegia is administered (intermittent crystalloid cardioplegia with external cooling, repeated every 30 minutes). The aortic valve is inspected. In this case, a bicuspid valve with thickened leaflets and an abnormal commissure between the right and non-coronary 'cusp' was seen. A repair of this valve would not have been durable. The aortic valve and cusps are removed, as well as the sinuses of Valsalva, leaving the coronary buttons. The aortic valve annulus is sized.

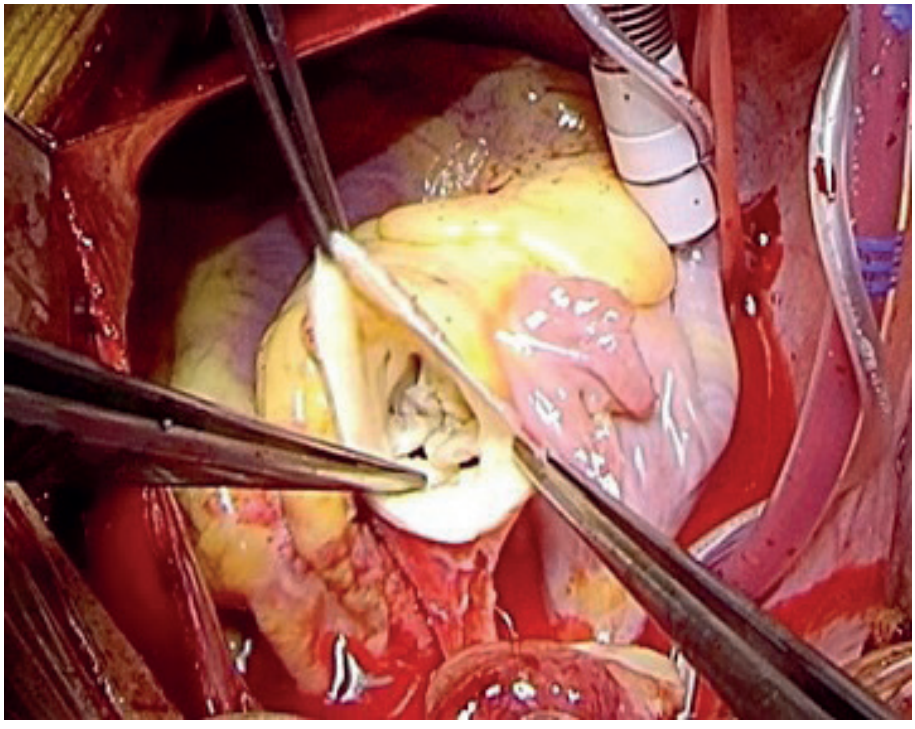

Figure 1: This bicuspid valve with thickened leaflets was deemed to be unrepairable.

2 - Autograft harvesting (0:44)

The pulmonary trunk is transected just beneath the confluence of the left and right pulmonary arteries and is dissected free from the aorta, taking care not to damage the left (main) coronary artery and left anterior descending artery (LAD). The pulmonary valve leaflets are inspected.

A right-angled clamp is guided through the pulmonary valve and positioned 5 mm below the base of the pulmonary valve leaflets in order to guide the right ventriculotomy. The right ventricular outflow tract (RVOT) is opened and, under direct sight of the pulmonary valve leaflets, this incision is continued laterally and medially.

Medially, at the level of the interventricular septum, a difference in orientation of the fibers of the right and left ventricular wall is always observed (01:28). In between these layers is the dissection plane that needs to be followed. By doing so,

the first septal perforator branch of the LAD can easily be identified and preserved (in this particular case, two large perforating branches were seen (02:10 min).

The last part of dissection is next to the LAD, where small branches must be identified and closed.

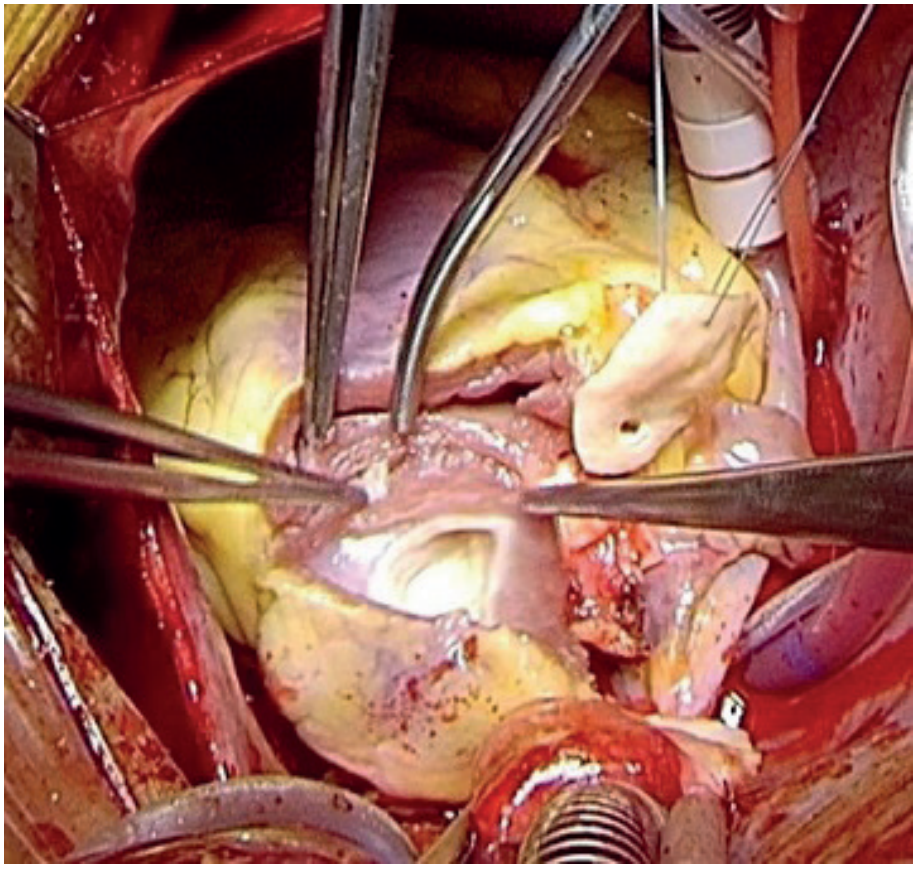

Figure 2. During dissection in the plane between the muscle fibers of the left and right chamber, two large septal perforator branches are seen.

3 - Autograft preparation and reimplantation (2:57)

The autograft is sized (26 mm) at its proximal side.It is important to trim off all excess muscle tissue (if not, this will bulge into the LVOT later). A 2-mm larger (28 mm) Valsalva vascular graft (Vascutek, Renfrewshire, Scotland, UK) is trimmed proximally, leaving 1 ring in situ. After measuring the length that we need, the rest of the Valsalva graft is removed.

The autograft is proximally fixed into the vascular prosthesis under the commissures using 3 5-0 polypropylene monofilament sutures. The proximal suture line is then run continuously using these 3 sutures. Distally, the height and the exact position of the commissures is carefully assessed and each commissure is fixed onto the vascular graft using separate 5-0 polypropylene sutures. This part of the operation must be done very carefully as distortions may cause autograft valve insufficiency later.

All 3 sinuses of Valsalva are removed ("scalloped") and then the distal suture lines are made using 3 separate running 5-0 polypropylene sutures. Each of these 3 sutures is started at the deepest point, in between 2 commissures, to avoid misalignment and distortion.

After completion of reimplantation a water test is helpful to assess correct placement of the pulmonary autograft.

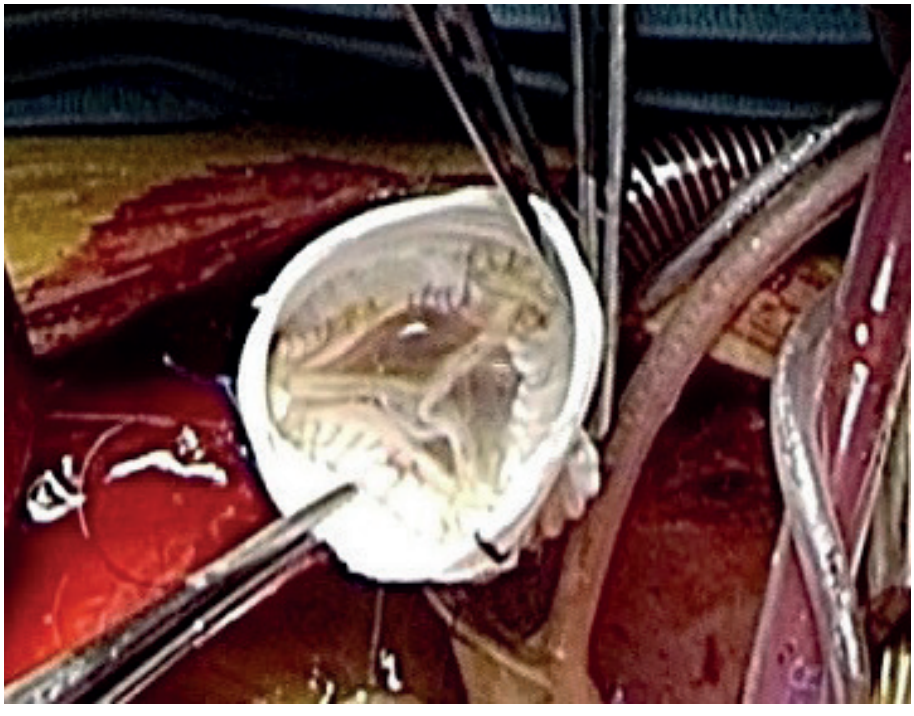

Figure 3: A watertest of the reimplanted autograft shows good function and leaflet coaptation.

4 - Autograft implantation into the LVOT (7:44)

Three polypropylene 4-0 sutures are placed at annular level in the LVOT in such a way that coronary reimplantation is easy. Usually, but not always, the position of the commissures of the original aortic valve can be used for guidance. Using these 3 sutures, the proximal suture line is made in a running fashion, passing each suture through both the vascular graft and the base of the autograft. Care is taken that the needle does not reach the valve tissue. Correct placement of the autograft is assured.

Using cautery, a hole is made in the vascular graft for reimplantation of the left coronary artery (using a 5-0 polypropylene).

5 - Distal suture lines and right coronary button reimplantation (8:59)

The distal suture line between a cryopreserved pulmonary homograft (30 mm diameter) and the pulmonary artery is made using a continuous 5-0 polypropylene suture. Then the ascending aorta is anastomosed to the Valsalva graft with the pulmonary autograft (continuous 4-0 polypropylene).

A hole in the vascular graft is made using cautery to accommodate the right coronary artery button, which is then reimplanted using a continuous 5-0 polypropylene suture. As the right coronary artery will usually be in a higher position than before, this part of the operation is not done earlier.

Ventilation is restarted and, after inserting a de-airing needle in the ascending aorta, the cross-clamp is removed.

6 - RVOT hemostasis and homograft implantation (10:33)

On the beating heart (regular sinus rhythm), careful hemostasis of the RVOT is performed. It is important to take as much time as needed to do this thoroughly now, as any remaining bleeding after proximal implantation of the homograft is very difficult to address, and may even need a breakdown of the proximal suture line.

After satisfactory hemostasis of the RVOT, the proximal suture line is made using 2 continuous 4-0 polypropylene sutures, reinforced with a strip of autologous pericardium. Reinforcement of the posterior part of this suture line is especially important as the muscle tissue can be quite fragile here.

Outcome & Discussion

The patient's recovery was uneventful. Follow-up echocardiograpy (after 2 months) showed good function of both ventricles, and good function of both the autograft (mean gradient 3.5 mmHg, no regurgitation) and the homograft (mean gradient 8 mmHg, no regurgitation).

As shown previously by our group [1], dilatation of the pulmonary autograft is the main reason for autograft failure and cause of reoperation. Reimplanting the autograft in a vascular graft makes dilatation of the autograft wall impossible. Several authors describe a technique in which the autograft is implanted into a 2–6 mm oversized graft using a 'root-inclusion technique '[2-5], or in the patient's own aortic root [6]. Other authors reinforce the annulus with a strip of graft material or pericardium, combined with sinotubular reinforcement [7] or opt for an ascending aorta replacement with a vascular graft [8]. This might not, however, prevent dilatation of the autograft root wall as dilatation also occurs in the sinus walls of the pulmonary autograft.

The technique presented here makes dilatation of the autograft impossible. Furthermore, removing the autograft sinuses results in optimal blood flow without bulky excess wall tissue. Care should be taken, though, to correctly implant the commissures into the vascular graft, as distortion might result in early or late regurgitation.

One concern might be the longer operative and cross-clamping time. However, the extra cross-clamping time did not result in any deleterious effects in our series.

It is important to note that this reimplantation technique is not possible in all patients. The diameter of the vascular graft should not interfere with somatic growth. Therefore, autograft wrapping and reimplantation techniques are only feasible in (almost) fully grown patients. This assessment should be made individually in older children.

Funding Disclosures & Competing Interests

None declared

REFERENCES

1. Schneider AW, Putter H, Klautz RJM, Bruggemans EF, Holman ER, Bökenkamp R, et al. Long-Term Follow-Up After the Ross Procedure: A Single Center 22-Year Experience. The Annals of Thoracic Surgery 2017;103:1976–83.

2. Ungerleider RM, Walsh M, Ootaki Y. A modification of the pulmonary autograft procedure to prevent late autograft dilatation. Semin Thorac Cardiovasc Surg Pediatr Card Surg Annu 2014;17:38–42.

3. Carrel T, Kadner A. Long-Term Clinical and Imaging Follow-Up After Reinforced Pulmonary Autograft Ross Procedure. Semin Thorac Cardiovasc Surg Pediatr Card Surg Annu 2016;19:59–62.

4. Jacobsen RM, Earing MG, Hill GD, Barnes M, Mitchell ME, Woods RK, et al. The Externally Supported Ross Operation: Early Outcomes and Intermediate Follow-Up. The Annals of Thoracic Surgery 2015;100:631–8.

5. Juthier F, Banfi C, Vincentelli A, Ennezat P-V, Le Tourneau T, Pinçon C, et al. Modified Ross operation with reinforcement of the pulmonary autograft: Six-year results. The Journal of Thoracic and Cardiovascular Surgery 2010;139:1420–3.

6. Skillington PD, Mokhles MM, Takkenberg JJM, Larobina M, O'Keefe M, Wynne R, et al. The Ross procedure using autologous support of the pulmonary autograft: techniques and late results. The Journal of Thoracic and Cardiovascular Surgery 2015;149:S46–52.

7. Charitos EI, Hanke T, Stierle U, Robinson DR, Bogers AJJC, Hemmer W, et al. Autograft reinforcement to preserve autograft function after the ross procedure: a report from the german-dutch ross registry. Circulation 2009;120:S146–54.

8. Brown JW, Ruzmetov M, Shahriari AP, Rodefeld MD, Mahomed Y, Turrentine MW. Modification of the Ross aortic valve replacement to prevent late autograft dilatation. Eur J Cardiothorac Surg 2010;37:1002–7.



PART 2

THE STENTLESS BIOPROSTHESIS



TWENTY-YEAR EXPERIENCE WITH STENTLESS BIOLOGICAL AORTIC VALVE AND ROOT REPLACEMENT:

Informing patients of risks and benefits

Adriaan W. Schneider, Hein Putter,
Mark G. Hazekamp, Eduard R. Holman, Eline F. Bruggemans,
Michel I.M. Versteegh, Martin J. Schalij, Rens R.B. Varkevisser,
Robert J.M. Klautz, Jerry Braun

Eur J Cardiothorac Surg. 2018 Jun 1;53(6):1272-1278.

Presented at the 31st Annual Meeting of the European Association for Cardio-Thoracic Surgery, Vienna, Austria, 7–10 October 2017.

CHAPTER 5

ABSTRACT

OBJECTIVES

The aim of this study was to provide predictive data on the performance of the Freestyle stentless bioprosthesis that can be used to support and improve the shared decision-making process of prosthetic valve choice for aortic valve replacement.

METHODS

Between 1993 and 2014, 604 patients received the Freestyle stentless bioprosthesis (143 subcoronary, 58 root inclusion and 403 full-root replacement). Perioperative data were collected retrospectively, and follow-up data were collected prospectively from 2015. Follow-up was 96% complete (median 4.3 years), with 114 (19%) patients having a follow-up period exceeding 10 years. A competing risks regression model was developed to predict the probability of mortality, structural valve deterioration (SVD) and reoperation for other causes than SVD.

RESULTS

The median age of patients was 64 years, 91 (15%) patients had undergone previous aortic valve replacement and 351 (58%) underwent concomitant procedures. The 15-year probability of SVD, reoperation for other causes and death were 16.9%, 8.1% and 47.7%, respectively. Linearized occurrence rates for prosthesis endocarditis, thromboembolic events and bleeding were 0.5%, 0.9% and 0.1% per patient-year, respectively. The constructed predictive model, including age, renal function and implantation technique as significant covariates, had good to fair predictive performance up to 19 years.

CONCLUSIONS

The Freestyle stentless bioprosthesis is an efficient prosthesis for aortic valve replacement or root replacement, with low incidences of SVD and valve-related events at long-term follow-up. The predictive model designed in this study can be used to fully inform patients about their expected individual trajectory after implantation of this prosthesis. This improves the shared decision-making process between patients and clinicians.

INTRODUCTION

In recent years, prosthesis selection for valve replacement has become more complex because of the availability of an increasing number of cardiac valve prostheses. Both the American [1] and the European [2] guidelines on the management of patients with valvular heart disease recommend that prosthesis selection should be a shared decision-making process that takes into account the desires of the fully informed patient (Class 1, level of evidence C). Advantages and limitations of the different prostheses should therefore be discussed with the patient.

The choice of an appropriate valve prosthesis requires considering factors such as durability and short- and long-term risks of adverse events. The obvious advantage of biological prostheses is the absence of the need for anticoagulation, which might especially be beneficial in younger and more active patients. Despite the disadvantage of structural valve deterioration (SVD), the use of bioprostheses in younger patients has increased in recent years [3]. This might partly be due to advances in percutaneous valve-in-valve procedures, offering a less invasive reintervention option in case of SVD.

The Freestyle stentless porcine bioprosthesis (Medtronic Inc., Minneapolis, MN, USA) can be used for aortic valve replacement (AVR) and/or root replacement. Since its introduction in 1993, several studies have shown good haemodynamic function up to 18 years after implantation [4–6]. Its stentless design offers a relatively large effective orifice area, which might facilitate future valve-in-valve procedures.

The Freestyle prosthesis has been used since June 1993 in our institution for a variety of indications [7]. This is a single-centre study, with more than 20 years of experience with the Freestyle bioprosthesis. The objective of this study was to provide predictive information to guide patients, cardiologists and surgeons in their shared process of choosing a prosthesis.

METHODS

This is a single-centre observational study. Details of patients who received the Freestyle stentless bioprosthesis in the aortic position between June 1993 and December 2014 at the Leiden University Medical Center, Netherlands, were

identified from the department's database and all patients were included in this study. Preoperative, operative and discharge data were retrospectively obtained from medical records. Surviving patients were prospectively followed up from January 2015. The study end-points were the development of SVD, the occurrence of valve-related events and mortality. SVD and valve-related events were defined according to the 2008 guidelines for reporting mortality and morbidity after cardiac valve interventions [8]. The Ethics Committee of the institution approved the study design and granted permission to conduct the study.

Indications, prosthesis choice, surgical technique and anticoagulation management

Indications for aortic valve and/or root replacement have changed over time, but procedures were always performed according to the recommendations or guidelines that were pertinent at that time. Prosthesis choice was a result of comprehensively weighing several factors, with the wishes of the well-informed patient as a cornerstone. Patient information always included insight into the risks of anticoagulation and thrombosis in mechanical prostheses, and the possible need for reintervention in bioprostheses, with their associated risks. Generally, a stentless valve was preferred over a stented bioprosthesis in younger patients because of the larger effective orifice area and presumably longer durability.

The different techniques used for implantation of the Freestyle prosthesis have been described previously [9]. Until 2005, most prostheses were implanted using subcoronary (SC) or root inclusion (RI) techniques based on the surgeon's preference. Thereafter, the full root replacement (FR) technique was used exclusively to fully maintain prosthesis geometry with the intention of maintaining better durability.

Anticoagulation management after the Freestyle implantation also changed. Initially, patients typically received no anticoagulants. Since the year 2000, patients without indication for vitamin K antagonists receive low-dose aspirin for 3 months after the implantation.

Follow-up

For deceased patients, information on the cause of death, SVD and valve-related events was obtained from hospital and/or general practitioners' databases.

Surviving patients were sent questionnaires regarding their health status and were invited to visit the outpatient clinic to undergo transthoracic echocardiography. When patients declined this invitation, clinical and echocardiographic follow-up data were obtained from the patients' cardiologists after signed informed consent. Patients were mostly followed up annually or biannually after the implantation. Patients who received a second Freestyle prosthesis were censored for SVD and valve-related events. Vital status of the patients were checked on 25 May 2016 and follow-up ended the same day.

Statistical analysis

Continuous variables were expressed as mean ± standard deviation (normally distributed) or as median and interquartile range (IQR) (non-normally distributed). Categorical variables were reported as numbers and percentages. Group differences were tested using a 1-way analysis of variance (ANOVA) (normally distributed), the Kruskal–Wallis test (non-normally distributed) and the χ^2 test (categorical data). Early mortality was defined as death within 30 days after surgery or during the same hospital admission. Univariable risk factor analysis (data complete for all 604 patients) for early mortality was performed using the Student's *t*-test or the χ^2 test. Factors with a *P*-value of <0.10 or clinically relevant variables were tested in a multivariable logistic regression model using the backwards stepwise conditional entry method (entry and removal probabilities of 0.05 and 0.10, respectively). Overall survival was estimated using the Kaplan–Meier method. Difference in overall survival between groups was tested using the log-rank test. To avoid informative censoring in the analysis of freedom from SVD, a competing risks analysis was performed considering death and explant for other causes (e.g. endocarditis) as competing risks of SVD occurrence. Excluding the early mortality cases to provide more reliable information on SVD occurrence during the long-term follow-up, the cumulative incidences of mortality, SVD occurrence and prosthesis explant for other causes than SVD were estimated for the remaining 556 patients using the mstate package version 0.2.8 [10] in R (version 3.1.2, R foundation for statistical computing, Vienna, Austria). Cumulative incidences were reported as estimate (95% confidence interval). Deceased patients with signs of SVD in their medical or echocardiographic reports were classified as having SVD. A predictive model for SVD incidence was constructed using a competing risks regression model (cmprsk package version 2.2-7 [11]),

using known risk factors for SVD and death (age, renal function and implantation technique [4, 12]) as covariates. Internal validation of the model was done using 1000 bootstrap samples ['cindex' function in the 'pec' package (version 2.4.9)]. Except for the competing risks analyses, all analyses were performed using IBM SPSS statistics for Windows, version 23.0 (IBM Corp., Armonk, NY, USA). A *P*-value of <0.05 (2-sided) was considered statistically significant.

RESULTS

A total of 604 consecutive patients who received the Freestyle prosthesis were identified from the department database. At the start of the study (January 2015), 385 (64%) patients were alive. Implantation technique was SC in 143 patients, RI in 58 patients and FR in 403 patients. Preoperative patient characteristics for the total study population and for the subgroups based on the implantation technique are listed in Table 1. Patients were younger in the FR group; as this implantation technique has been exclusively used since 2005, this coincides with the global trend of implanting bioprostheses in younger patients in the past decade. Operative details are listed in Table 2.

Table 1: Patient characteristics

Variables	SC	RI	FR	Total
Number of patients	143	58	403	604
Male gender, *n* (%)	83 (58.0)	40 (69.0)	254 (63.0)	377 (62.4)
Age at operation (years), median (IQR)*	69.9 (56.4–74.6)	68.0 (56.4–74.6)	61.8 (51.0–69.9)	64.3 (52.2–72.9)
Preoperative NYHA functional class, *n* (%)*				
I	17 (11.9)	2 (3.4)	172 (42.7)	191 (31.6)
II	57 (39.9)	22 (37.9)	122 (30.3)	201 (33.3)
III	56 (39.2)	32 (55.2)	98 (24.3)	186 (30.8)
IV	13 (9.1)	2 (3.4)	11 (2.7)	26 (4.3)
Atrial fibrillation, *n* (%)	11 (7.7)	5 (8.6)	33 (8.2)	49 (8.1)
Previous cardiac surgery, *n* (%)*	18 (12.6)	5 (8.6)	108 (26.8)	131 (21.7)
Coronary artery bypass grafting	2 (1.4)	1 (1.7)	15 (3.7)	18 (13.7)
Aortic valve repair	3 (2.1)	1 (1.7)	4 (0.9)	8 (6.1)
Aortic valve replacement*	9 (6.3)	3 (5.2)	79 (19.6)	91 (69.5)

Variables	SC	RI	FR	Total
History of cerebrovascular accident, *n* (%)	11 (7.7)	6 (10.3)	48 (11.9)	65 (10.8)
Diabetes, *n* (%)*	20 (13.9)	0	43 (10.7)	63 (10.4)
Hypertension, *n* (%)*	75 (52.4)	22 (37.9)	224 (55.6)	321 (53.1)
History of malignancy, *n* (%)	13 (9.1)	7 (12.1)	29 (7.2)	49 (8.1)
Chronic obstructive pulmonary disease, *n* (%)	17 (11.9)	4 (6.9)	33 (8.1)	54 (8.9)
Renal function, *n* (%)*				
eGFR >85 ml/kg/min	35 (24.5)	17 (29.3)	227 (56.3)	279 (46.2)
eGFR 50–85 ml/kg/min	81 (56.6)	32 (55.5)	139 (34.5)	252 (41.7)
eGFR <50 ml/kg/min	26 (18.2)	9 (15.5)	33 (8.2)	68 (11.3)
Dialysis	1 (0.7)	0	4 (1.0)	5 (0.8)
Coronary artery disease, *n* (%)*	39 (27.3)	16 (27.6)	69 (17.1)	124 (20.5)
LVEF function (*n* = 546), *n* (%)				
>50%	91 (84.3)	29 (74.4)	315 (78.9)	435 (79.7)
31–50%	11 (10.2)	8 (20.5)	68 (17.0)	87 (15.9)
21–30%	6 (5.6)	2 (5.1)	13 (3.3)	21 (3.8)
<20%	0	0	3 (0.8)	3 (0.5)
Aortic valve lesion, *n* (%)*				
Normal	1 (0.7)	0	29 (7.2)	30 (5.0)
Stenosis	67 (46.9)	28 (48.3)	139 (34.5)	234 (38.7)
Insufficiency	30 (21.0)	11 (19.0)	181 (44.9)	222 (36.8)
Mixed	45 (31.5)	19 (32.8)	54 (13.4)	118 (19.5)
Aetiology, *n* (%)*				
Normal	0	1 (1.7)	3 (0.7)	4 (0.7)
Senile degeneration	82 (57.3)	31 (53.4)	137 (34.0)	250 (41.4)
Rheumatic	8 (5.6)	1 (1.7)	11 (2.7)	20 (3.3)
Congenital	24 (16.8)	17 (29.3)	57 (14.1)	98 (16.2)
Healed endocarditis	5 (3.5)	1 (1.7)	7 (1.7)	13 (2.2)
Active endocarditis	11 (7.7)	0	50 (12.4)	61 (10.1)
Failed aortic valve repair	3 (2.1)	0	1 (0.2)	4 (0.7)
Failed aortic valve prosthesis	7 (4.9)	3 (5.2)	47 (11.7)	57 (9.4)
Aortic dissection	0	0	32 (7.9)	32 (5.3)
Aortic dilatation	2 (1.4)	4 (6.9)	57 (14.1)	63 (10.4)

Variables	SC	RI	FR	Total
Other	1 (0.7)	0	1 (0.2)	2 (0.3)
Bicuspid [native valves (n = 514)], n (%)*	43 (32.1)	33 (60.0)	152 (46.8)	228 (44.2)

*$P < 0.05$ between groups.
eGFR: estimated glomerular filtration rate; FR: full root replacement; IQT: interquartile range; LVEF: left ventricular ejection fraction; NYHA: New York Heart Association; RI: root inclusion; SC: subcoronary.

Table 2: Operative details

Variables	SC	RI	FR	Total
Number of patients, n (%)	143 (23.7)	58 (9.6)	403 (66.7)	604
CPB time (min), median (IQR)	150 (120–180)		209 (173–273)	205 (169–266)
Cross-clamping time (min), median (IQR)	95 (83–117)	104 (94–120)	161 (128–212)	137 (106–180)
Circulatory arrest time (min), median (IQR)			43 (29–64)	43 (29–64)
ACP time (min), median (IQR)			40 (24–67)	40 (24–67)
Logistic EuroSCORE I, median (IQR)	4.54 (2.89–7.26)	3.29 (2.22–4.48)	10.91 (5.62–19.88)	7.3 (4.7–16.3)
For elective patients, median (IQR)	4.05 (2.75–6.87)	3.43 (2.19–4.65)	7.37 (4.65–15.60)	6.35 (4.09–11.73)
EuroScore II, median (IQR)	1.63 (1.10–3.44)	1.31 (0.84–2.22)	3.94 (2.19–8.40)	3.1 (1.6–6.7)
For elective patients, median (IQR)	1.51 (1.04–2.85)	1.28 (0.82–2.08)	3.03 (1.83–5.57)	2.31 (1.36–4.47)
Urgent settting, n (%)	7 (4.9)	1 (1.7)	82 (20.3)	90 (14.9)
Emergent setting, n (%)	8 (5.6)	1 (1.7)	33 (8.2)	42 (7.0)
Prosthesis size, n (%)				
21mm	20 (14.0)	6 (10.3)	37 (9.2)	63 (10.4)
23mm	51 (35.7)	21 (36.2)	62 (15.4)	134 (22.2)

Variables	SC	RI	FR	Total
25mm	35 (24.5)	17 (29.3)	90 (22.3)	142 (23.5)
27mm	36 (25.2)	14 (24.1)	108 (26.8)	158 (26.2)
29mm	1 (0.7)		106 (26.3)	107 (17.7)
Concomitant surgery, *n* (%)	48 (33.6)	13 (22.4)	290 (72.0)	351 (58.1)
Coronary artery bypass grafting, *n* (%)	31 (21.7)	5 (8.6)	62 (15.4)	98 (16.2)
Mitral valve surgery, *n* (%)	8 (5.6)	2 (3.4)	66 (16.4)	76 (12.6)
Tricuspid valve surgery, *n* (%)	2 (1.4)	1 (1.7)	24 (6.0)	27 (4.5)
Ascending aorta/hemiarch replacement, *n* (%)	0	0	129 (32.0)	129 (21.4)

ACP: antegrade cerebral perfusion; CPB: cardiopulmonary bypass; FR: full root replacement; IQR: interquartile range; RI: root inclusion; SC: subcoronary.

5

Early postoperative course

In total, there were 48 (7.9%) early deaths. The early mortality rate decreased over time from 10.6% before 2000 to 5.1% in the last 5 years (Table 3). In elective, isolated AVR or root replacement patients, the early mortality rate decreased from 7.2% to 0% (Table 3). Multivariable risk factor analysis showed that age, surgical period, previous cardiac surgery, previous cerebrovascular accident, chronic obstructive pulmonary disease, concomitant coronary artery bypass grafting, concomitant mitral valve surgery and urgent/emergent surgery were independent risk factors for early mortality (Supplementary Material, File A). Postoperative complications for the whole group and the subgroups are listed in Table 3. Echocardiography taken at discharge showed mild patient–prosthesis mismatch (indexed effective orifice area between 0.65 cm^2/m^2 and 0.85 cm^2/m^2) in 37 (6%) patients.

Table 3: Postoperative complications

Variables	SC	RI	FR	Total
Early complications, *n* (%)				
(Temporary) dialysis	9 (6.3)	2 (3.4)	18 (4.5)	29 (4.8)
Low cardiac output	9 (6.3)	4 (6.9)	13 (3.2)	26 (4.3)
Surgical re-exploration for bleeding/tamponade	19 (13.3)	12 (20.7)	33 (8.2)	64 (10.6)

Variables	SC	RI	FR	Total
Myocardial infarction	4 (2.8)	0	8 (2.0)	12 (2.0)
Multiorgan failure	0	1 (1.7)	8 (2.0)	9 (1.5)
CVA	3 (2.1)	0	10 (2.5)	13 (2.2)
Prolonged intubation (>48 h)	6 (4.2)	4 (6.9)	30 (7.4)	40 (6.6)
Intra-aortic balloon pump	2 (1.4)	0	12 (3.0)	14 (2.3)
Extracorporeal membrane oxygenation	0	0	4 (1.0)	4 (0.7)
Permanent pacemaker placement	7 (4.9)	2 (3.4)	33 (8.2)	42 (7.0)
De novo arrhythmia at discharge	15 (10.5)	5 (8.6)	54 (13.4)	74 (12.3)
Late complications				
Mode of structural valve deterioration				
Leaflet tear	19	7	10	36
Leaflet perforation	2	0	2	4
Stenosis	5	2	0	7
Dilatation	0	1	0	1
Valve-related events				
Valve thrombosis	0	0	0	0
Embolism	0	0	0	0
Stroke	6	3	9	18
Ischaemic	4	3	6	13
Haemorrhagic	2	0	3	5
TIA	8	0	6	14
Bleeding event	1	0	2	3
Endocarditis	4	3	12	19
Mortality	**Total group *(n = 604)***	**Elective patients *(n = 472)***	**Elective, isolated AVR/ARR patients *(n = 316)***	
Early mortality, *n* (%)				
Total	48 (7.9)	29 (6.1)	13 (4.1)	
Before 2000	21/199 (10.6)	18/186 (9.7)	10/138 (7.2)	
2000–2010	13/128 (10.2)	7/102 (6.9)	3/64 (4.7)	
2010–2014	14/277 (5.1)	4/184 (2.2)	0/114 (0)	
Late mortality				
All cause	221			
Late valve related	52			
Sudden, unexplained	14			
Unknown	27			
Late non-valve related	121			

AVR: aortic valve replacement; ARR: aortic root replacement; CVA: cerebrovascular accident; FR: full root replacement; RI: root inclusion; SC: subcoronary; TIA: transient ischaemic attack.

Follow-up

A flow diagram on follow-up data of the study population is shown in Supplementary Material, File B. Clinical follow-up was 96% complete, with recent echocardiography (<1 year prior to the last follow-up) in 91% and 94% of all and surviving patients, respectively. Total follow-up comprised 3293 patient-years. The median follow-up period was 4.3 years (IQR 2.1–8.1 years; maximum 20.5 years), with 114 (19%) patients having a follow-up period exceeding 10 years and 46 (8%) exceeding 15 years.

Structural valve deterioration

SVD developed in 48 (7.9%) patients, of whom 43 underwent reintervention. Four patients did not undergo reintervention because of severe comorbidity (3 of them died during follow-up). One patient was under echocardiographic surveillance to determine the timing of reintervention. The mode of deterioration was leaflet tear in 36 patients, leaflet perforation in 4 patients, calcific stenosis in 7 patients and insufficiency due to dilatation of the ascending aorta in 1 patient. The prosthesis became stenotic due to calcification only after SC or RI implantation. After FR implantation, torn leaflets or valve insufficiency without leaflet tear were the mechanisms of SVD. In most of these cases, the valve leaflets had no-to-mild calcifications, but the aortic root wall was calcified instead. Competing risk analysis showed a cumulative incidence of SVD occurrence in hospital survivors of 7.1% (95% confidence interval 4.5–11.0%) and 16.9% (12.7–22.4%) at 10 and 15 years, respectively.

Valve-related events

Nineteen (3.1%) patients developed prosthetic valve endocarditis; 5 of whom underwent surgery for endocarditis during initial AVR. Late postoperative stroke occurred in 18 (3.0%) patients: 13 ischaemic and 5 haemorrhagic. Haemorrhagic stroke was associated with anticoagulant therapy for arrhythmias in 3 patients. Seventeen patients were diagnosed with a transient ischaemic attack. There were no non-cerebral embolic events. Upper gastrointestinal bleeding was seen in 3 patients (2 on oral anticoagulation). The linearized occurrence rates for prosthesis endocarditis, thromboembolic events (non-cerebral embolism, stroke and transient ischaemic attack combined) and bleeding events were 0.5%, 0.9% and 0.1% per patient-year, respectively. Valve-related events are listed in Table 3.

Reinterventions

In total, 75 (12.4%) patients underwent aortic valve or root reintervention, with a median time to reintervention of 7.9 years (IQR 3.2–11.5 years). Primary implantation technique was SC in 34 patients, RI in 15 patients and FR replacement in 26 patients. Thirty-two (5.3%) patients were reoperated for other causes than SVD at a median time to reintervention of 2.7 years (IQR 0.8–5.5 years). Indications for non-SVD reoperation were prosthesis endocarditis in 15 patients, suture line dehiscence in 9 patients, pseudoaneurysm in 4 (2 at the proximal suture line and 2 at a coronary button) patients, (para)valvular leakage in 3 patients and Type A aortic dissection in 1 patient. One patient underwent mitral valve repair 10 years after the Freestyle implantation; the Freestyle prosthesis with normal function was replaced pre-emptively. Competing risks regression analysis showed a cumulative incidence of prosthesis explant for other causes than SVD of 6.5% (3.9–9.1%) at 10 years and 8.1% (4.9–11.0%) at 15 years.

Survival

Overall survival rates for the total patient cohort at 10, 15 and 20 years were 58.8% (53.2–63.9%), 42.4% (36.3–48.3%) and 29.1% (21.4–37.3%), respectively. Causes of late mortality were non-valve-related in 121 (70%) patients, valve-related in 11 (6%) patients and sudden unexplained in 14 (8%) patients. In 27 (16%) patients, the cause of death could not be retrieved.

Prediction model for shared decision-making

A prediction model using a competing risk regression formula was constructed to predict mortality, the chance of developing SVD and the chance of prosthesis reoperation for other causes than SVD based on age, renal function and implantation technique. Internal validation of the model showed good to fair predictive performance for SVD, with a concordance index of 80.5 at 15 years. Regression coefficients and the estimated concordance indices of the internal validation analysis are listed in Table 4. An example of predicted outcomes for a 55-year-old patient with good renal function after root replacement is shown in Fig. 1. An extensive overview of the outcomes from the predictive model is shown in Supplementary Material, Files C and D.

Table 4: Competing risks regression model with internal validation

	Death			**Reoperation for other causes than SVD**			**SVD**		
	B	**SE**	***P*-value**	*B*	**SE**	***P*-value**	*B*	**SE**	***P*-value**
Implantation technique									
Non-root									
Root	0.060	0.189	0.750	−0.495	0.433	0.250	−0.912	0.313	0.004
Age group (years)									
<40									
40–50	0.871	0.630	0.170	0.627	0.762	0.410	−0.864	0.415	0.037
50–60	0.548	0.614	0.370	0.7449	0.677	0.270	−1.306	0.411	0.002
60–70	1.522	0.543	0.005	0.540	0.654	0.410	−2.648	0.482	<0.001
>70	2.172	0.568	<0.001	−0.431	0.761	0.570	−2.481	0.507	<0.001
eGFR (ml/kg/min)									
>85									
50–85	0.121	0.275	0.660	−0.371	0.446	0.41	−0.074	0.342	0.830
<50	0.778	0.313	0.013	0.046	0.713	0.95	−0.970	0.743	0.190
Estimated concordance index									
5-year	63.6			47.2					
10-year	69.5			50.5			81.0		
15-year	70.6			51.8			80.5		
19-year	71.5			51.8			76.4		

eGFR: estimated glomerular filtration rate; SE: standard error; SVD: structural valve deterioration.

Figure 1:

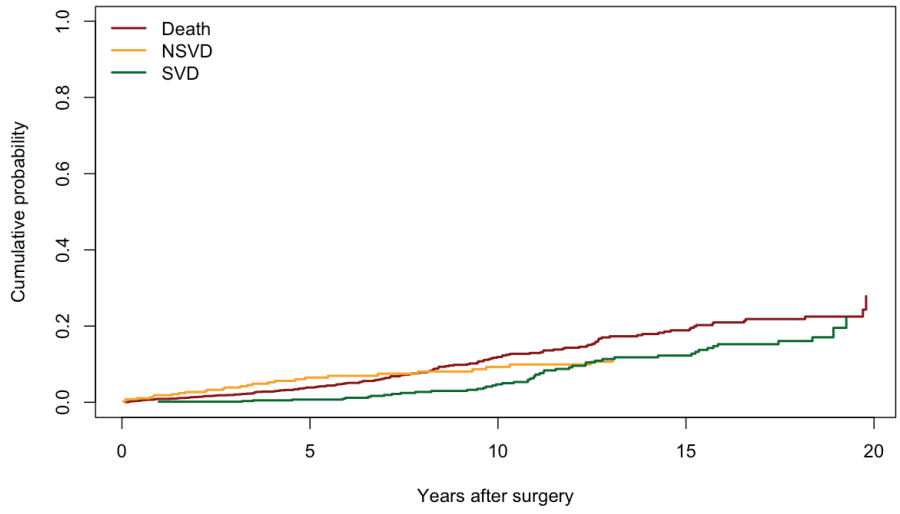

Results from the competing risks regression model for a 55-year-old patient with normal renal function after root replacement. NSVD: non-structural valve deterioration; SVD: structural valve deterioration.

DISCUSSION

This article describes over 20 years of experience with the Freestyle stentless bioprosthesis, which has been used for various pathologies with different implantation techniques at our institution. This report provides predictive data that can aid patients, cardiologists and surgeons in their shared decision-making on using this prosthesis for AVR, giving a comprehensive summary of both the risks in the short (perioperative) term and on the occurrence of SVD and other valve-related events during follow-up. The Freestyle prosthesis can be used with an acceptable early mortality rate, given the often complex patient group. The early mortality rate decreased over time from ~10% in the beginning to ~5% in recent years. Since 2010, elective procedures have been performed with an early mortality rate of ~2% for patients with concomitant surgery and 0% for isolated surgery. During follow-up, fewer valve-related events were observed. Furthermore, the relatively large effective orifice area of the Freestyle prosthesis, as reflected by the low incidence of moderate patient–prosthesis mismatch (i.e. a risk factor for

all-cause and cardiac mortality [12, 13]), enables future valve-in-valve procedures. The elective patient with an indication for aortic root replacement with or without the ascending aorta replacement can therefore be treated with this prosthesis with a minimal risk.

As with all bioprostheses, the Freestyle prosthesis will degenerate in time. The cumulative incidence of SVD at 15 years was 17% in this series. Leaflet tear was the predominant mode (75%) of SVD. As a result of the sudden failure of the prosthesis, patients presented mostly with subacute symptoms of moderate decompensation.

FR replacement was associated with higher freedom from SVD compared with other implantation techniques in our competing risks model. Since late 2005, the FR implantation technique has been used exclusively at our institution. Increased durability of the Freestyle prosthesis after FR replacement was previously reported by Mohammadi *et al.* [4]. In a randomized trial, El-Hamamsy *et al.* [14] have reported higher freedom from SVD and reoperation for SVD of the Freestyle prosthesis compared with homografts.

SVD developed earlier in younger patients. In patients <40 years of age, 57% had developed SVD 15 years after surgery. For these patients, other alternatives offer a better solution. In a previous series published by our group on young patients (median age 12 years, all under 40 years of age) undergoing the Ross procedure [15], an analysis with death as a competing risk for autograft reoperation showed a cumulative incidence of autograft reoperation at 20 years of 31%. For patients <40 years of age, the pulmonary autograft appears to be the best bioprosthesis available for AVR in terms of durability [16].

There is an increasing recognition that patients' wishes and expectations regarding valve prostheses have to be taken into account in the process known as shared decision-making. Korteland *et al.* [17], in their study among patients aged <60 years and who received either a mechanical or a biological aortic valve prosthesis, reported that the majority of the patients consider it important that they are involved in deciding on the type of prosthesis. Furthermore, they found that patients who were more actively involved in choosing the prosthesis type showed better mental health after surgery, as measured with the 36-Item Short Form Health Survey.

Recent guidelines underscore that the choice of valve intervention and type of valve prosthesis should be a shared decision [1, 2]. Yet for patients to be able to make a good decision, they need to be informed with full disclosure about all benefits and risks that accompany certain interventions. A study in patients undergoing AVR in the Netherlands analysed patients' knowledge about valve substitutes and patients' numeracy [18]. It was not only found that almost half of the patients felt that they had insufficient knowledge about different valve prostheses after having received information but half of the patients also had impaired numeracy, implying that they experienced difficulty in weighing benefits and risks. Presenting data in pictograms may improve patient understanding of the benefits and risks of different types of valve prostheses [19].

In this study, a competing risks regression model was constructed for the Freestyle bioprosthesis to provide patients, cardiologists and surgeons with information on expected clinical outcomes, given the relevant predictors (age, renal function and implantation technique). Internal validation of this model showed good to fair predictive performance with respect to SVD occurrence up to 19 years and fair predictive performance with respect to mortality. As expected, this model was unable to accurately predict reoperation due to other causes than SVD. Such events may be attributed more to chance than to patient characteristics. The information from this model, showing both risks of events and the probability of remaining event-free, can be presented graphically to patients, improving their understanding of the presented data. This aids patients, cardiologists and surgeons in their shared decision-making in choosing a prosthesis.

Limitations

The retrospective part of this study comes with its accompanying limitations. Changes in (peri)operative management during the long study period may have influenced both early (as shown in this article) and late outcomes. Because of the small number of events, the results of this logistic regression model should be considered with some caution, because the possibility of some overfitting cannot be excluded. The several different indications and patient characteristics make this a heterogeneous series. Although internal validation of our competing risks prediction model showed good predictive capabilities, it needs to be validated externally.

CONCLUSION

The choice of the aortic valve prosthesis is a shared decision between patients, cardiologists and surgeons. For patients to make a well-informed decision, clinicians need to fully disclose the risks and benefits accompanying the different treatment options and present them in a comprehensible manner. The Freestyle stentless bioprosthesis is a valuable option for patients with an indication for aortic root replacement, with low incidence of SVD and valve-related events, especially in older patients. The competing risk regression model of this study can be used to clearly and fully inform patients about their expected individual trajectory after the implantation of this prosthesis. This improves the shared decision-making process between patients and clinicians.

FUNDING

This work was supported by an unrestricted research grant from Medtronic, Inc.

Conflict of interest: none declared.

REFERENCES

1. Fitzgerald C. 2017 AHA/ACC Focused Update of the 2014 AHA/ACC Guideline for the Management of Patients With Valvular Heart Disease 2017:1–123.

2. Vahanian A, Alfieri O, Andreotti F, Antunes MJ, Barón-Esquivias G, Baumgartner H, et al. Guidelines on the management of valvular heart disease (version 2012). European Heart Journal 2012;33:2451–96.

3. Isaacs AJ, Shuhaiber J, Salemi A, Isom OW, Sedrakyan A. National trends in utilization and in-hospital outcomes of mechanical versus bioprosthetic aortic valve replacements. The Journal of Thoracic and Cardiovascular Surgery 2015;149:1262–3.

4. Mohammadi S, Kalavrouziotis D, Voisine P, Dumont E, Doyle D, Perron J, et al. Bioprosthetic valve durability after stentless aortic valve replacement: the effect of implantation technique. The Annals of Thoracic Surgery 2014;97:2011–8.

5. Mohammadi S, Tchana-Sato V, Kalavrouziotis D, Voisine P, Doyle D, Baillot R, et al. Long-term clinical and echocardiographic follow-up of the Freestyle stentless aortic bioprosthesis. Circulation 2012;126:S198–204.

6. Bach DS, Kon ND. Long-Term Clinical Outcomes 15 Years After Aortic Valve Replacement With the Freestyle Stentless Aortic Bioprosthesis. The Annals of Thoracic Surgery 2014;97:544–51.

7. Schneider AW, Hazekamp MG, Versteegh MIM, Bruggemans EF, Holman ER, Klautz RJM, et al. Stentless bioprostheses: a versatile and durable solution in extensive aortic valve endocarditis. Eur J Cardiothorac Surg 2016;49:1699–704.

8. Akins CW, Miller DC, Turina MI, Kouchoukos NT, Blackstone EH, Grunkemeier GL, et al. Guidelines for reporting mortality and morbidity after cardiac valve interventions. The Journal of Thoracic and Cardiovascular Surgery 2008;135:732–8.

9. Doty DB, Cafferty A, Kon ND, Huysmans HA, Krause AH, Westaby S. Medtronic Freestyle aortic root bioprosthesis: Implant techniques. Journal of Cardiac Surgery 1998;13:369–75.

10. de Wreede LC, Fiocco M, Putter H. The mstate package for estimation and prediction in non- and semi-parametric multi-state and competing risks models. Comput Methods Programs Biomed 2010;99:261–74.

11. Fine JP, Gray RJ. A Proportional Hazards Model for the Subdistribution of a Competing Risk. Journal of the American Statistical Association 1999;94:496–509.

12. Johnston DR, Soltesz EG, Vakil N, Rajeswaran J, Roselli EE, Sabik JF, et al. Long-term durability of bioprosthetic aortic valves: implications from 12,569 implants. The Annals of Thoracic Surgery 2015;99:1239–47.

13. Head SJ, Mokhles MM, Osnabrugge RLJ, Pibarot P, Mack MJ, Takkenberg JJM, et al. The impact of prosthesis-patient mismatch on long-term survival after aortic valve replacement: a systematic review and meta-analysis of 34 observational studies comprising 27186 patients with 133141 patient-years. European Heart Journal 2012;33:1518–29.

14. El-Hamamsy I, Clark L, Stevens LM, Sarang Z, Melina G, Takkenberg JJM, et al. Late outcomes following freestyle versus homograft aortic root replacement: results from a prospective randomized trial. Journal of the American College of Cardiology 2010;55:368–76.

15. Schneider AW, Putter H, Klautz RJM, Bruggemans EF, Holman ER, Bökenkamp R, et al. Long-Term Follow-Up After the Ross Procedure: A Single Center 22-Year Experience. The Annals of Thoracic Surgery 2017;103:1976–83.

16. Richardt D, Hemmer W, Moritz A, Hetzer R, Gorski A, Franke UFW, et al. Age-related reoperation rate after the Ross procedure: a report from the German Ross Registry. J Heart Valve Dis 2015;24:220–7.

17. Korteland NM, Top D, Borsboom GJJM, Roos-Hesselink JW, Bogers AJJC, Takkenberg JJM. Quality of life and prosthetic aortic valve selection in non-elderly adult patients. Interactive CardioVascular and Thoracic Surgery 2016;22:723–8.

18. Korteland NM, Bras FJ, van Hout FMA, Kluin J, Klautz RJM, Bogers AJJC, et al. Prosthetic aortic valve selection: current patient experience, preferences and knowledge. Open Heart 2015;2:e000237–7.

19. Fagerlin A, Zikmund-Fisher BJ, Ubel PA. Helping patients decide: ten steps to better risk communication. J Natl Cancer Inst 2011;103:1436–43.

Supplementary Material

Supplemental File A. Risk factor analysis

	Univariable analysis (Student's T-test or Chi-square test)	Multivariable logistic regression		
Variable	**P-value**	**Odds Ratio**	**95% CI**	**P-value**
Isolated surgery	0.063			
NYHA class III or IV	0.10			
Previous cardiac surgery	0.19	2.465	1.090 – 5.573	0.030
Previous AVR	0.62			
Previous MVR	0.16			
Active endocarditis	0.093			
Previous MI	0.002			
Previous revascularization	0.005			
Diabetes	0.97			
Periferal artery disease	0.095			
CVA	<0.001	4.590	2.105 – 10.008	<0.001
COPD	0.002	2.714	1.115 – 6.607	0.028
Renal impairment (eGFR < 85ml/kg/min)	<0.001			
Impaired left ventricular function	0.85			
Urgent/emergent surgery	<0.001	9.471	3.701 – 24.238	<0.001
Root replacement	0.11			
Concomitant CABG	<0.001	2.329	1.120 – 4.843	0.024
Concomitant MV surgery	0.024	3.363	1.374 – 8.228	0.008
Surgical era	0.053			0.003
Before 2000		-	-	-
2000 – 2010		0.748	0.378 – 2.012	0.75
After 2010		0.246	0.103 – 0.585	0.002
Age (continuous)	<0.001	1.058	1.025 – 1.092	<0.001

Multivariable logistic regression model: Hosmer and Lemeshow goodness-of-fit: P = 0.955; AUC: 0.850

Supplemental File B. Flow diagram on follow-up

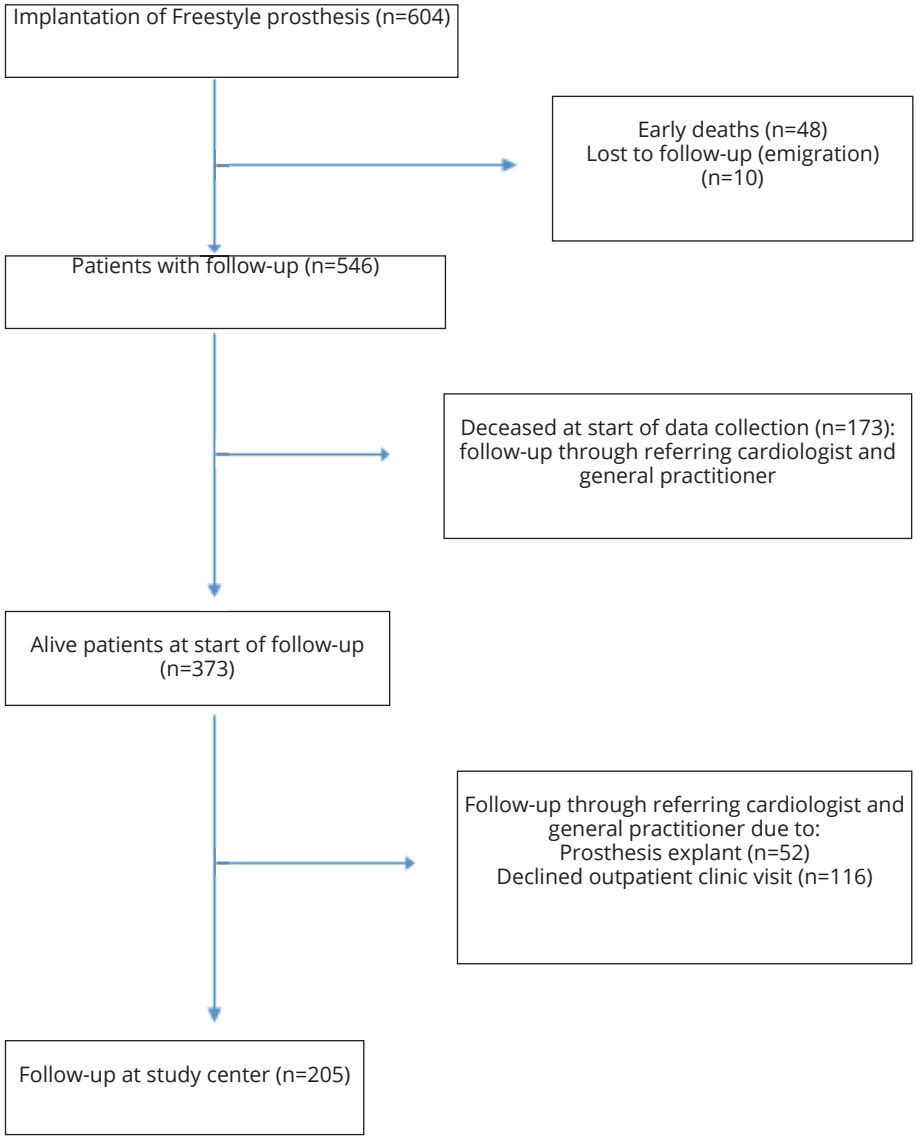

Supplemental File C. Predicted probabilities from the competing risks regression model at 5, 10 and 15 years.

5 Year

	>85			50-85			<50		
Root	Death	NSVD	SVD	Death	NSVD	SVD	Death	NSVD	SVD
<40	2.26	3.13	2.58	2.54	2.17	2.40	4.85	3.27	0.99
40-50	5.31	5.77	1.10	5.97	4.02	1.02	11.20	6.03	0.42
50-60	3.87	6.47	0.71	4.35	4.51	0.66	8.23	6.76	0.27
60-70	9.93	5.31	0.19	11.12	3.69	0.17	20.36	5.55	0.07
>70	18.15	2.04	0.22	20.22	1.41	0.20	35.34	2.14	0.08
	>85			**50-85**			**<50**		
Non-root	Death	NSVD	SVD	Death	NSVD	SVD	Death	NSVD	SVD
<40	2.13	5.08	6.30	2.40	3.53	5.87	4.57	5.31	2.44
40-50	5.01	9.29	2.71	5.63	6.51	2.52	10.58	9.70	1.03
50-60	3.65	10.39	1.75	4.11	7.29	1.62	7.77	10.85	0.67
60-70	9.38	8.55	0.46	10.51	5.98	0.43	19.29	8.93	0.17
>70	17.19	3.33	0.54	19.17	2.31	0.50	33.68	3.48	0.21

10 Year

	>85			50-85			<50		
Root	Death	NSVD	SVD	Death	NSVD	SVD	Death	NSVD	SVD
<40	7.06	4.52	16.28	7.92	3.14	15.21	14.73	4.72	6.51
40-50	16.05	8.29	7.22	17.91	5.80	6.72	31.67	8.66	2.80
50-60	11.89	9.27	4.70	13.30	6.50	4.37	24.08	9.69	1.81
60-70	28.49	7.62	1.25	31.49	5.33	1.16	51.81	7.97	0.48
>70	47.39	2.96	1.48	51.55	2.05	1.37	75.30	3.09	0.56
	>85			**50-85**			**<50**		
Non-root	Death	NSVD	SVD	Death	NSVD	SVD	Death	NSVD	SVD
<40	6.66	7.30	35.74	7.48	5.10	33.68	13.93	7.63	15.43
40-50	15.19	13.22	17.01	16.96	9.33	15.89	30.14	13.80	6.82
50-60	11.24	14.75	11.29	12.58	10.43	10.53	22.86	15.39	4.44
60-70	27.08	12.19	3.08	29.97	8.59	2.87	49.72	12.73	1.18
>70	45.39	4.80	3.63	49.47	3.34	3.38	73.21	5.02	1.39

15 year

	>85			50-85			<50		
Root	Death	NSVD	SVD	Death	NSVD	SVD	Death	NSVD	SVD
<40	11.39	5.57	38.38	12.76	3.88	36.12	23.15	5.82	16.71
40-50	25.11	10.18	18.41	27.84	7.14	17.21	46.72	10.63	7.42
50-60	18.88	11.38	12.26	21.02	8.00	11.43	36.58	11.87	4.83
60-70	42.55	9.37	3.36	46.49	6.57	3.12	70.08	9.79	1.29
>70	65.42	3.66	3.96	69.82	2.54	3.68	90.09	3.82	1.52
	>85			**50-85**			**<50**		
Non-root	Death	NSVD	SVD	Death	NSVD	SVD	Death	NSVD	SVD
<40	10.77	8.98	69.91	12.06	6.28	67.22	21.97	9.37	36.56
40-50	23.84	16.14	39.73	26.45	11.44	37.51	44.73	16.83	17.45
50-60	17.88	17.97	27.77	19.93	12.78	26.08	34.88	18.72	11.60
60-70	40.67	14.90	8.15	44.51	10.54	7.59	67.91	15.54	3.17
>70	63.22	5.93	9.56	67.64	4.13	8.91	88.67	6.19	3.74

5

Supplemental File D. Cumulative probability curves from the competing risks regression model for all covariates.

Root, normal renal function, <40 year

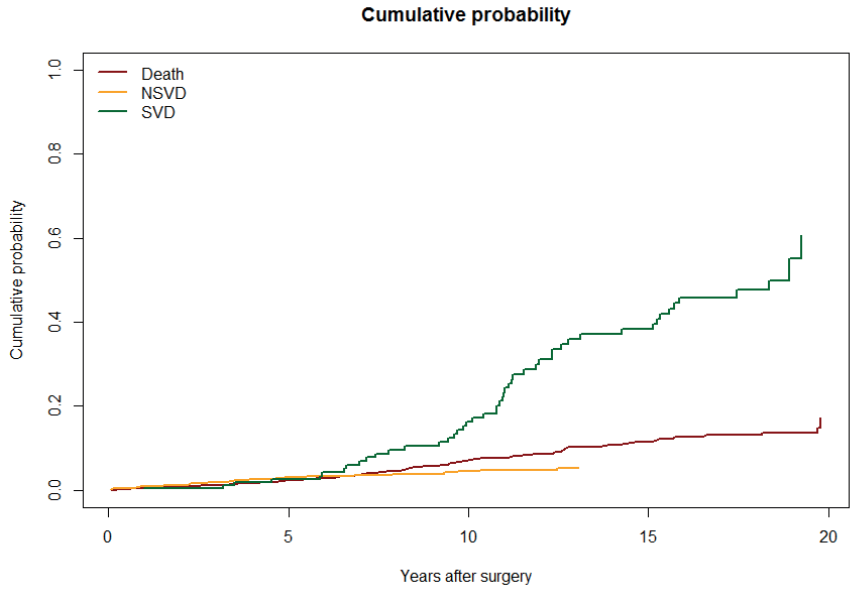

Root, normal renal function, 40-50 years

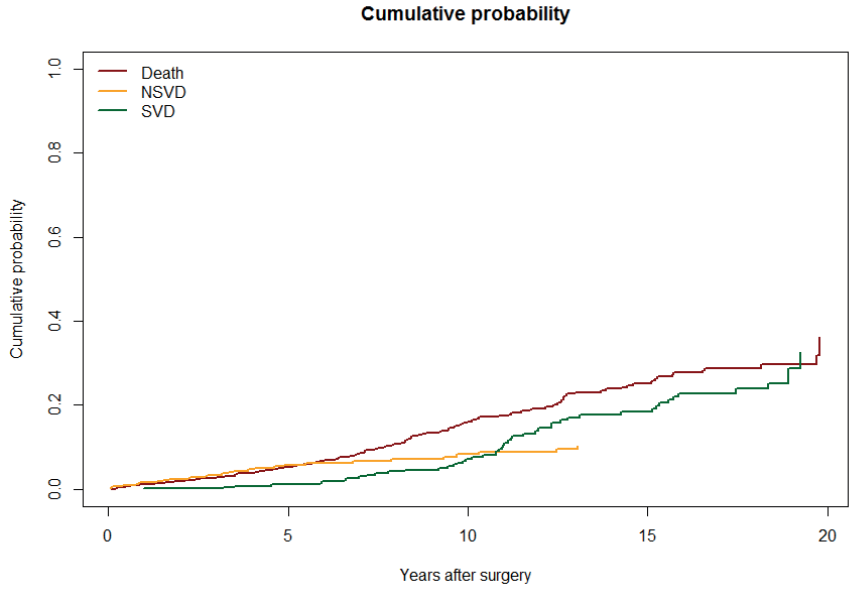

Root, normal renal function, 50-60 years

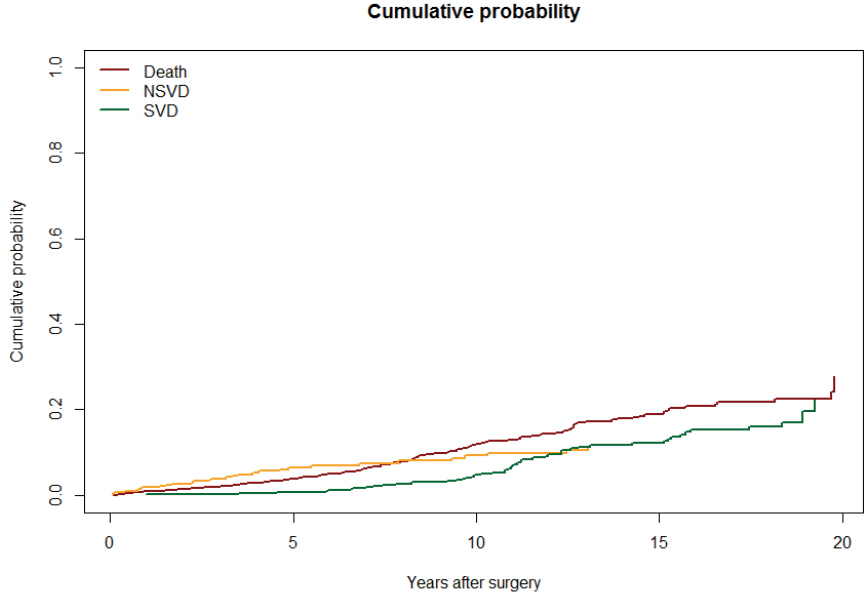

Root, normal renal function, 60-70 years

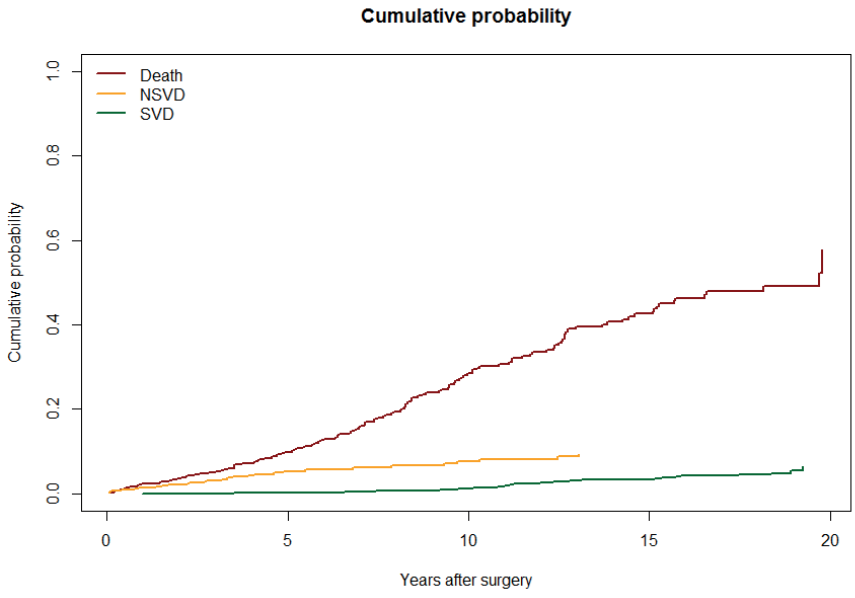

Root, normal renal function, >70 years

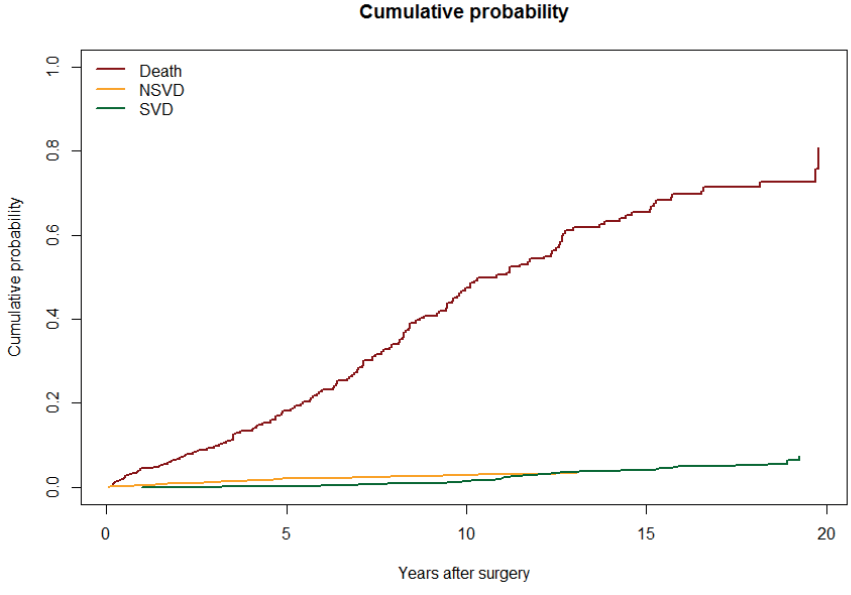

Root, moderately impaired renal function, <40

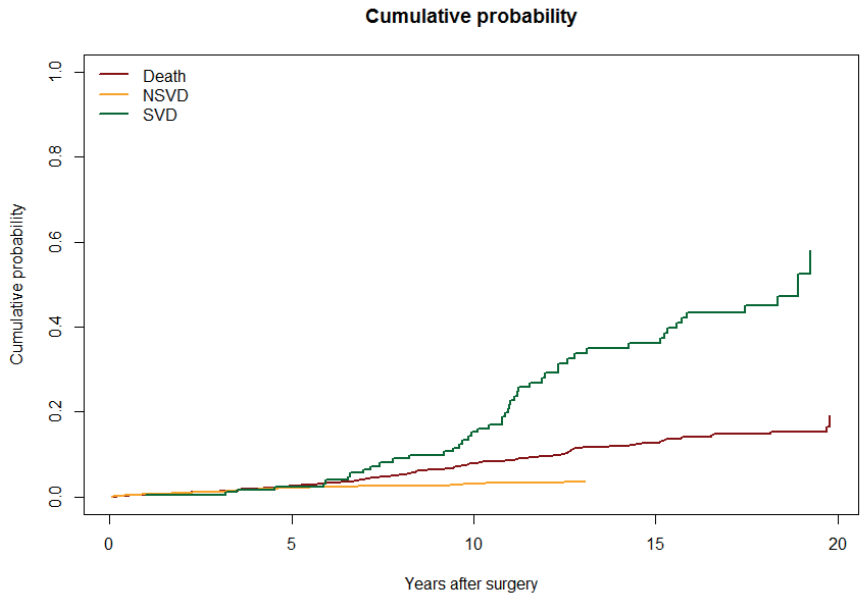

Root, moderately impaired renal function, 40-50

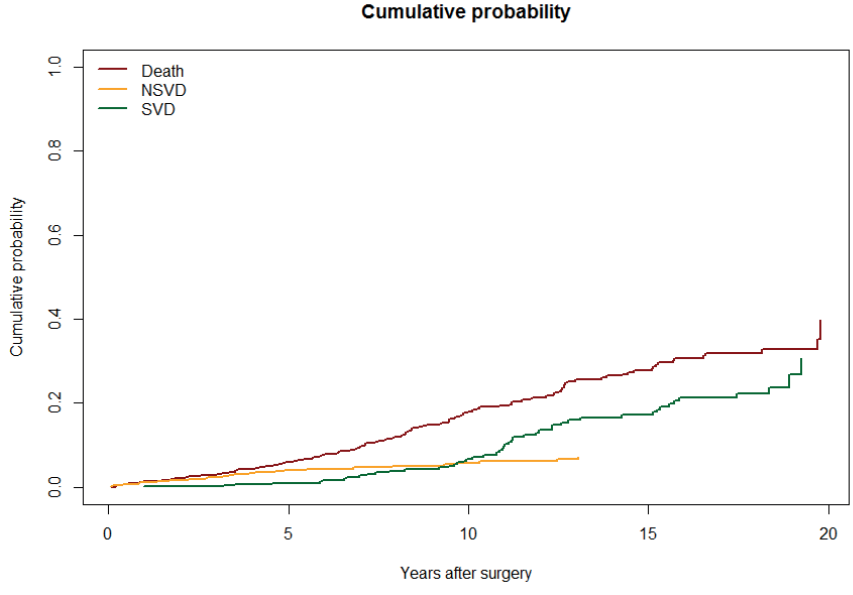

Root, moderately impaired renal function, 50-60

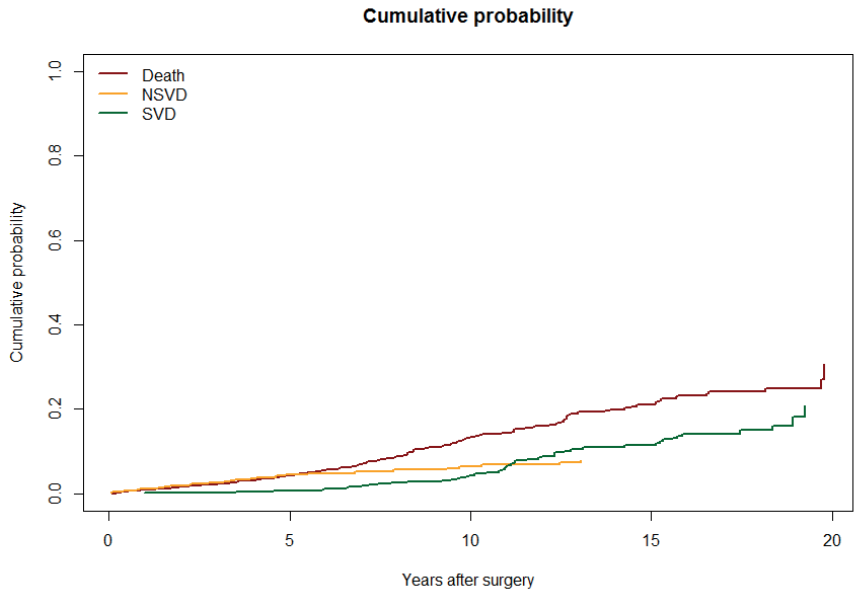

Root, moderately impaired renal function, 60-70

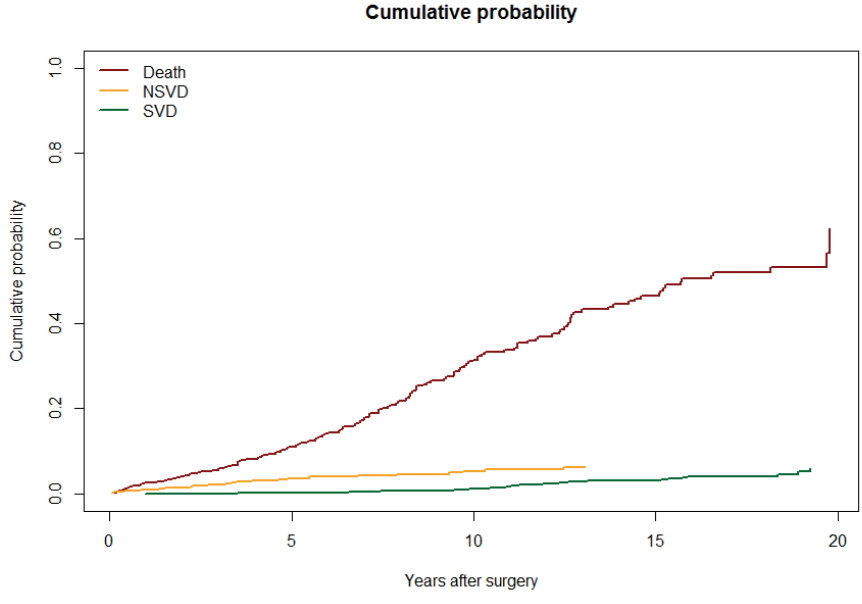

Root, moderately impaired renal function, >70

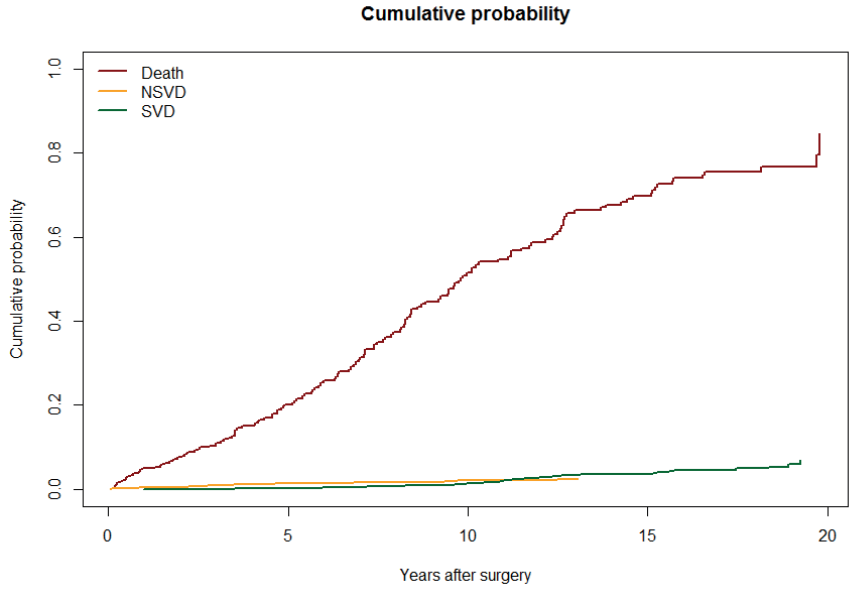

Root, severely impaired renal function, <40

Root, severely impaired renal function, 40-50

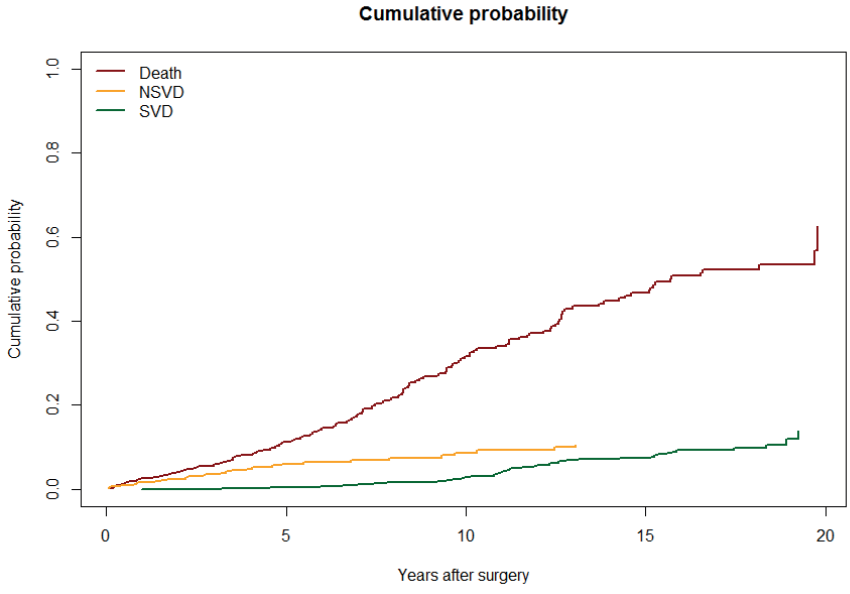

Root, severely impaired renal function, 50-60

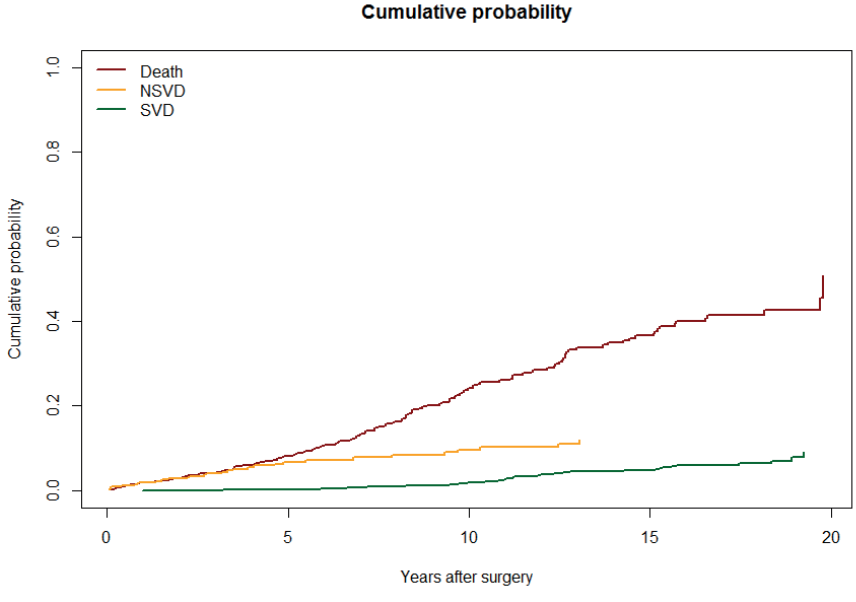

Root, severely impaired renal function, 60-70

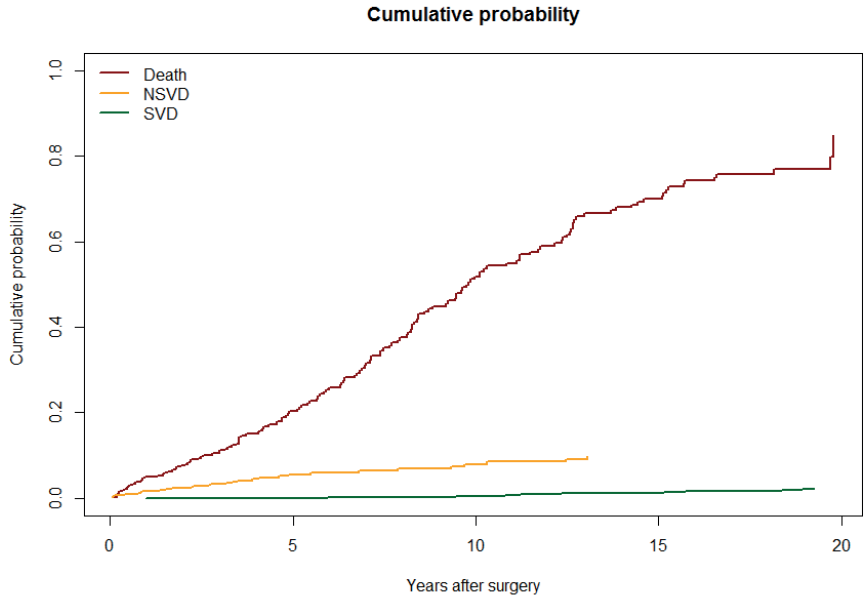

Root, severely impaired renal function, >70

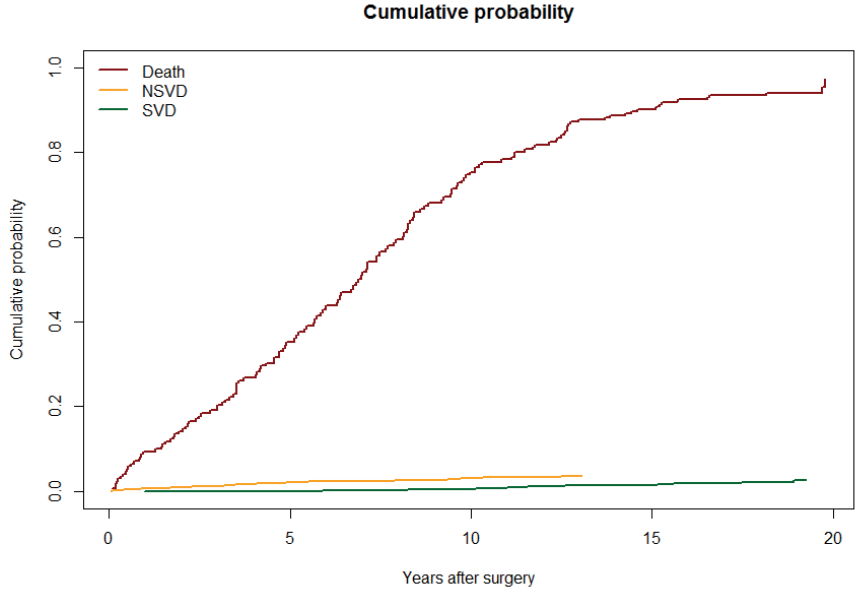

Non-root, normal renal function, <40 year

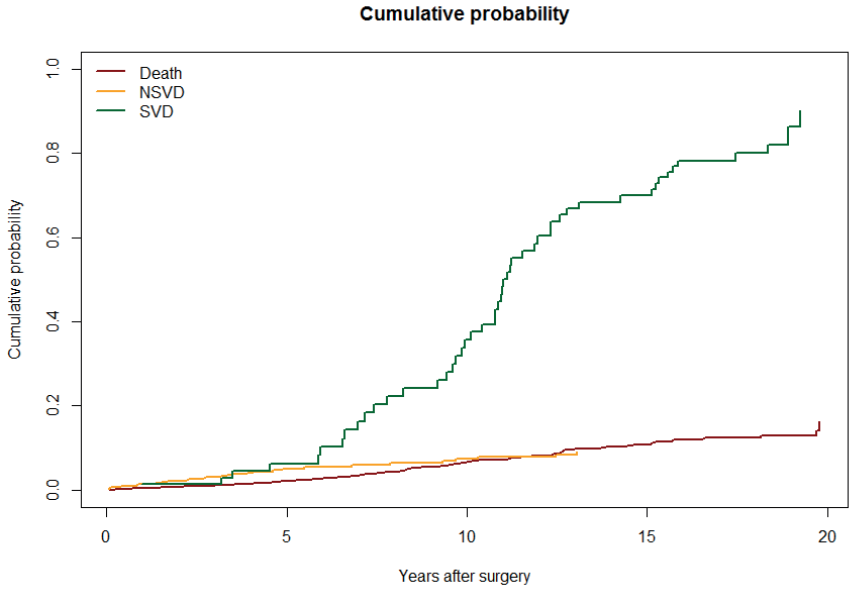

Non-root, normal renal function, 40-50 years

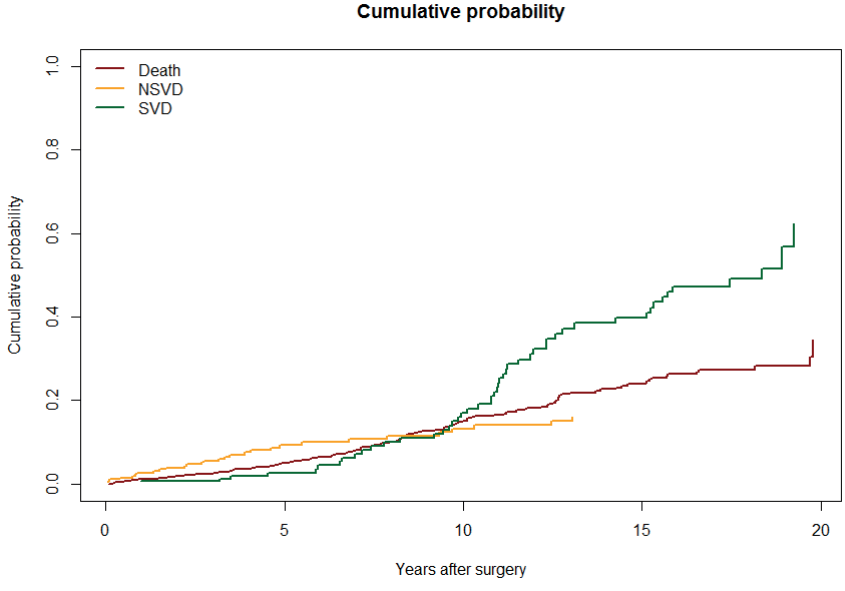

Non-root, normal renal function, 50-60 years

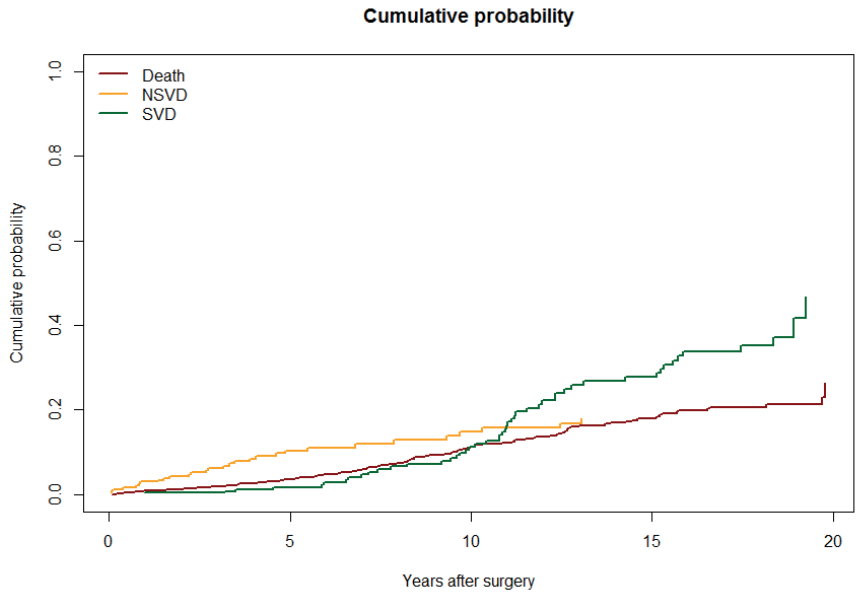

Non-root, normal renal function, 60-70 years

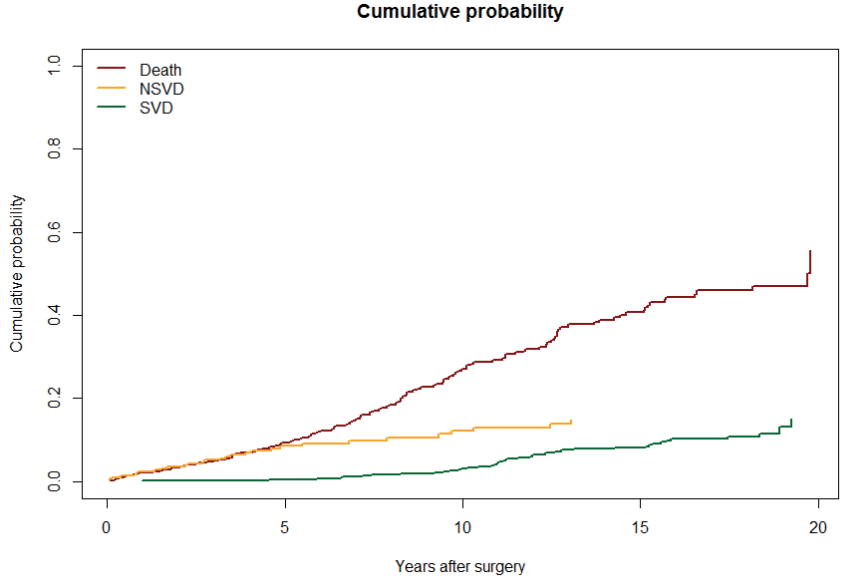

Non-root, normal renal function, >70 years

Non-root, moderately impaired renal function, <40

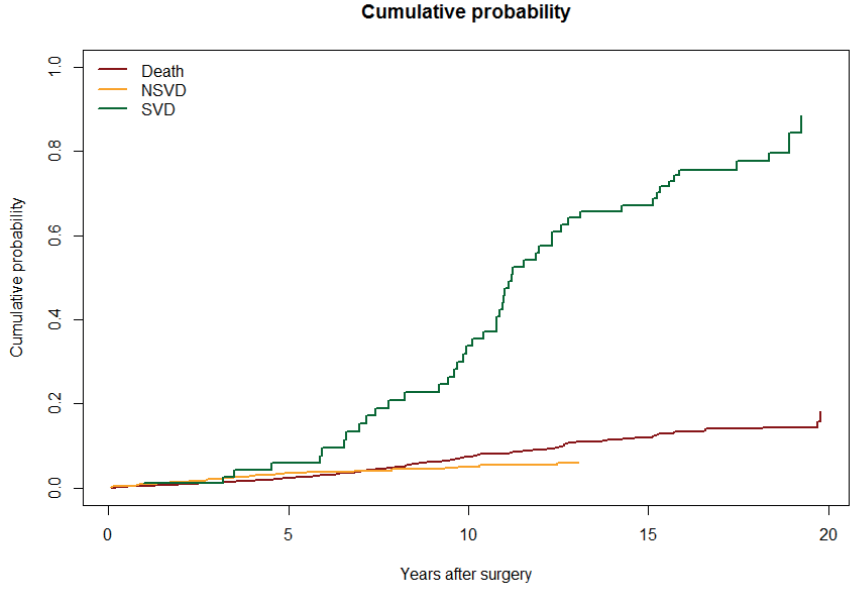

Non-root, moderately impaired renal function, 40-50

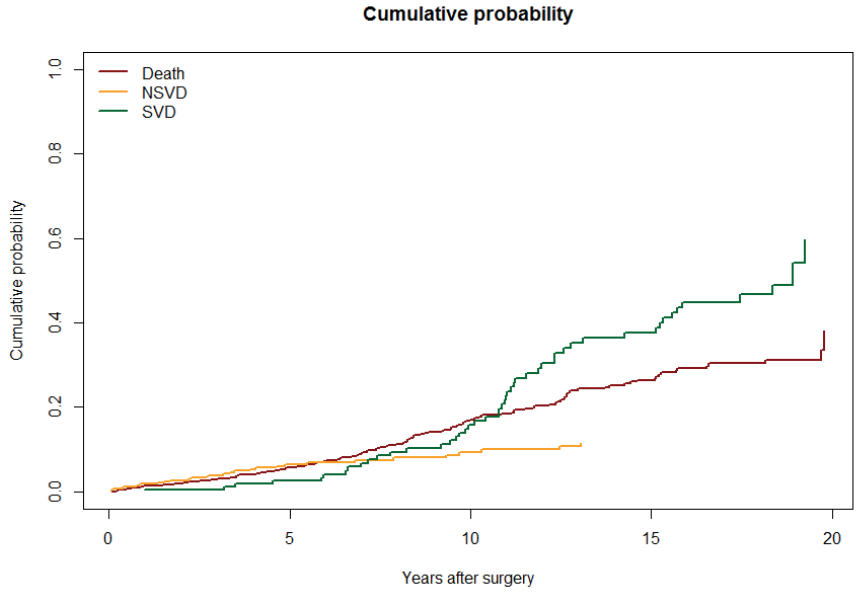

Non-root, moderately impaired renal function, 50-60

Non-root, moderately impaired renal function, 60-70

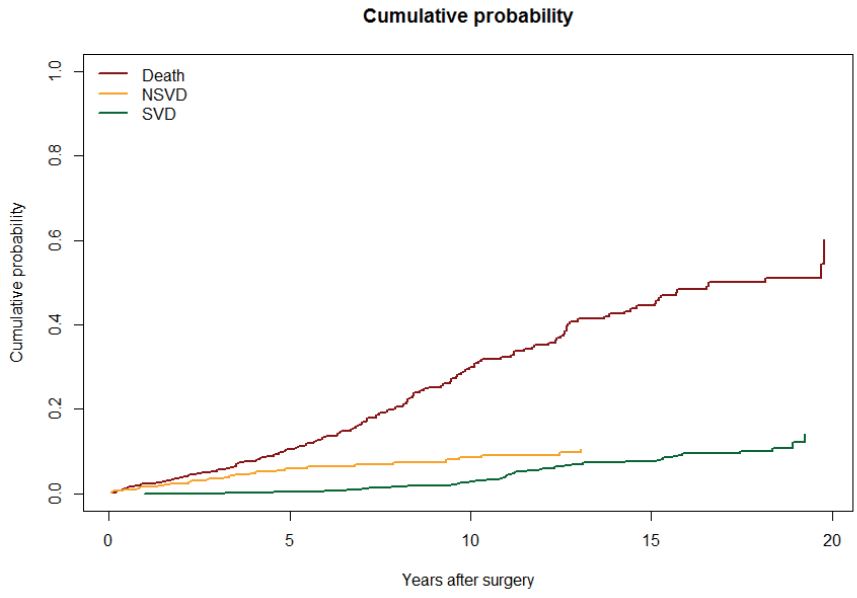

Non-root, moderately impaired renal function, >70

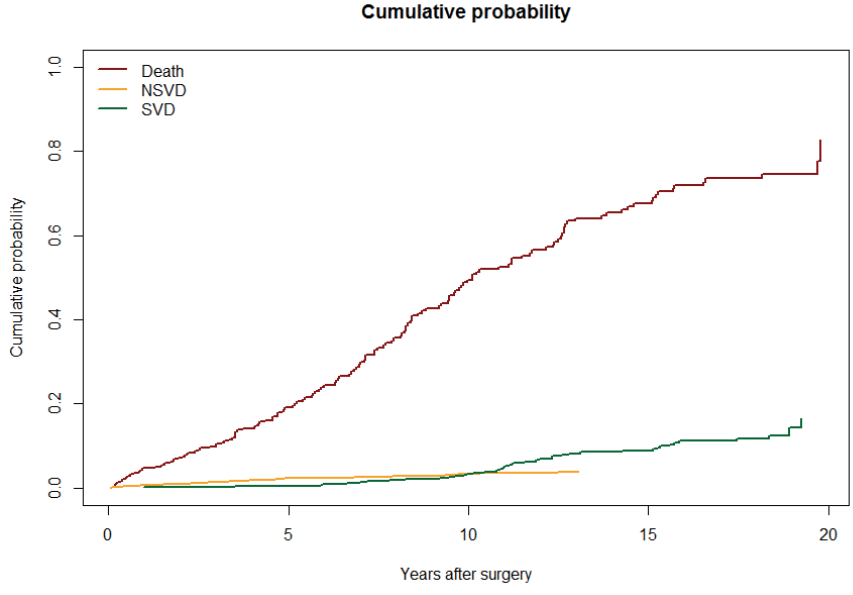

Non-root, severely impaired renal function, <40

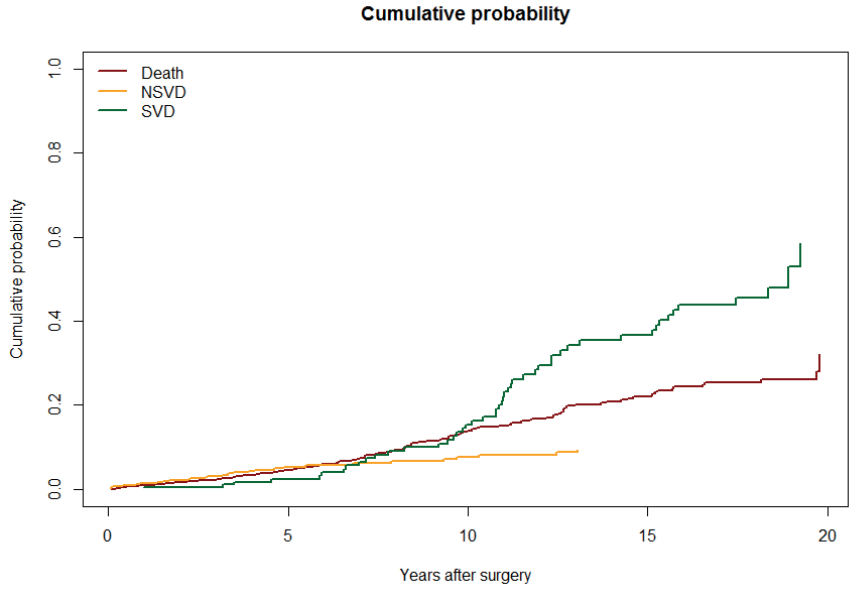

Non-root, severely impaired renal function, 40-50

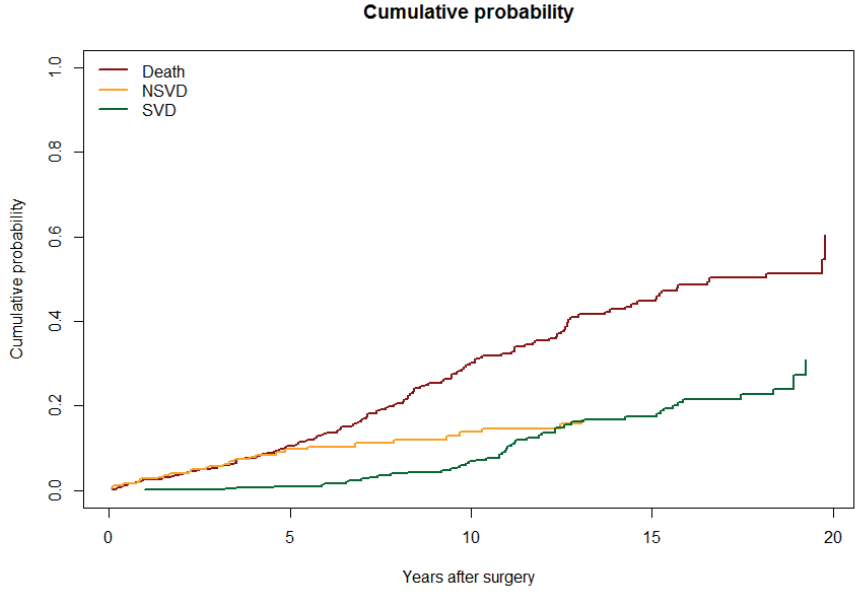

Non-root, severely impaired renal function, 50-60

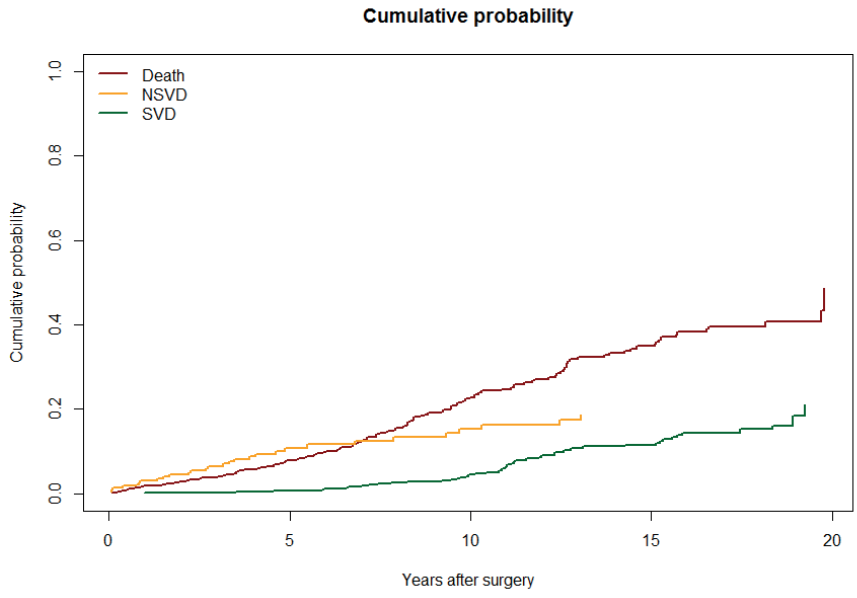

Non-root, severely impaired renal function, 60-70

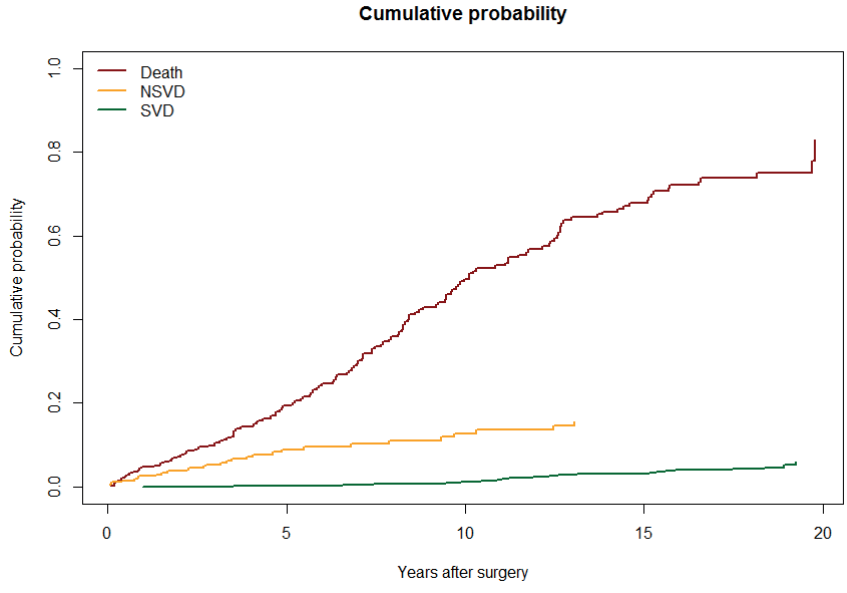

Non-root, severely impaired renal function, >70

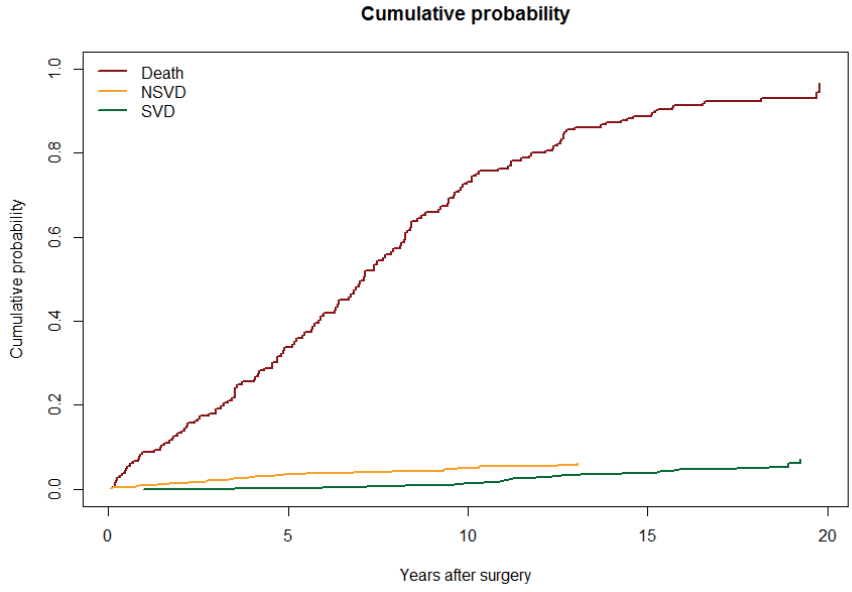



STENTLESS BIOPROSTHESES:

A versatile and durable solution in extensive aortic valve endocarditis

Adriaan W. Schneider, Mark G. Hazekamp, Michel I.M. Versteegh, Eline F. Bruggemans, Eduard R. Holman, Robert J.M. Klautz, Jerry Braun

Eur J Cardiothorac Surg 2016;49:1699–704

Presented at the 29th Annual Meeting of the European Association for Cardio-Thoracic Surgery, Amsterdam, Netherlands, 3–7 October 2015.

CHAPTER 6

ABSTRACT

OBJECTIVES

Infective endocarditis of the aortic valve with local aortic root destruction requires radical resection of infected tissues and subsequent reconstruction of periannular structures and the left ventricular outflow tract (LVOT). Homografts or stentless bioprostheses are recommended for use in this specific patient group. The Freestyle stentless bioprosthesis is a porcine aortic root prosthesis, which approaches the surgical versatility of the homograft, but has the advantage of ready availability and uniform quality. We assessed clinical and echocardiographic outcome following the use of this prosthesis in extensive aortic valve endocarditis.

METHODS

Between June 2000 and December 2014, 55 Freestyle prostheses were implanted for aortic valve endocarditis involving the root in 54 patients (74% male). The mean age at operation was 61 ± 13 years. The mean EuroSCORE II was 20.1 ± 13.5. Twenty-nine (54%) patients had prosthetic valve endocarditis. The median follow-up time after surgery was 3.5 years, ranging from 0 to 15 years.

RESULTS

Early and late mortality were 11% (6 patients) and 14% (7 patients), respectively. Estimated overall survival at 1 and 5 years was 83 and 70%, respectively. There was no survival difference between patients with native or prosthetic valve endocarditis. One patient underwent reoperation for recurrent endocarditis 2.3 years after the initial procedure. No other prosthesis failure occurred. At a median follow-up of 3.3 years, mean gradient over the prosthesis was 4.3 ± 2.3 mmHg. No patient had more than mild aortic regurgitation.

CONCLUSIONS

The Freestyle stentless bioprosthesis is a valuable option to reconstruct the LVOT after debridement in extensive aortic valve endocarditis. It is readily available with a versatility and clinical outcome comparable with that of homografts. Although early mortality remains considerable in this high-risk group of patients, late survival is good with low rates of recurrence of endocarditis, immediate local control and good haemodynamic performance on echocardiography.

INTRODUCTION

Infective endocarditis (IE) is a serious condition with in-hospital mortality rates ranging from 15 to 30%, even when treated with antibiotics or surgical interventions [1]. Patients with aortic valve endocarditis with extended local destruction of the aortic root and adjacent structures have even worse prognosis, with mortality rates of up to 79% [1]. Early surgery is indicated in patients with IE complicated by heart block, annular or aortic abscess, destructive penetrating lesions or as prevention of embolism in patients with vegetations larger than 15 mm or large (>10 mm) vegetations following one or more embolic episodes [1, 2]. Surgery comprises radical resection of all infected tissues followed by reconstruction of periannular structures and the left ventricular outflow tract (LVOT). Several techniques and prostheses are available to perform this reconstruction. The choice of prosthesis depends on the surgeon's preference and intrinsic factors of the prosthesis used, such as resistance to infection, pliability, durability and availability.

In patients with complicated IE involving the aortic root, European guidelines advise the use of homografts or stentless bioprostheses to reconstruct the LVOT [1]. The Society of Thoracic Surgeons considers homografts to be the gold standard in extended endocarditis [3]. Due to the limited availability of homografts and the equal durability of homografts and stentless bioprostheses, the use of stentless bioprostheses in this subset of patients has increased [4]. These prostheses approach the surgical versatility of homografts due to their shape and pliability, but have the advantage of ready availability and uniform quality. The Medtronic Freestyle stentless bioprosthesis (Medtronic, Inc., Minneapolis, MN, USA) is a porcine aortic root prosthesis with documented good long-term clinical and haemodynamic outcomes [5, 6]. We evaluated outcomes of patients with IE of the aortic valve with root destruction in whom the Freestyle stentless bioprosthesis was used, in order to assess the value of this prosthesis in this patient group.

MATERIALS AND METHODS

This study was approved by the local ethics committee. Between June 2000 and December 2014, 54 patients with IE of the aortic valve with extensive root involvement underwent surgery including implantation of a Freestyle stentless bioprosthesis. Data were collected prospectively in the database of the

department of cardiothoracic surgery and retrospectively analysed. Clinical and echocardiographic follow-up data were collected through outpatient clinic visits, by contacting referring cardiologists and, if needed, through telephone calls with patients. IE was diagnosed according to the modified Dukes criteria [7]. Antibiotic treatment was started after blood cultures were taken. When patients remained haemodynamically stable, surgery was planned not within 48 h after the initiation of antibiotic treatment directed at the causative micro-organism and depending on echocardiographic parameters. Urgent surgery (<48 h) was performed only in patients who deteriorated clinically. Antibiotic treatment was typically continued for 6 weeks after surgery. In patients with septic emboli, antibiotic treatment was continued for a longer period, depending on size and location.

Operative technique

All patients were operated through median sternotomy using standard techniques for extracorporeal circulation. Antegrade warm blood cardioplegia was used for cardioprotection in all patients. The aortic valve and all macroscopically infected tissues were carefully removed and sent for microbacterial culture. This included the roof of the left atrium, the aortic-mitral continuity and, if necessary, parts of the mitral valve (usually the body of the anterior leaflet). Reconstruction of the resected structures was performed with xenopericardial patch material. If the mitral valve was involved, it was reconstructed or replaced through the roof of the left atrium. If the free edge of the anterior mitral valve leaflet was intact, an annuloplasty ring was first implanted in the region of the posterior leaflet, followed by reconstruction of the body of the anterior leaflet with a pericardial patch, up to the ring. In case of more extensive involvement of the mitral valve, the valve was excised and replaced with sutures placed only in the posterior part of the annulus, covering two thirds to three quarters of the prosthesis. Next, a folded xenopericardial patch was attached to the ring with its fold. After unfolding, one part of the patch was used to reconstruct the roof of the left atrium and the other part to reconstruct the aortic-mitral continuity and LVOT in the region of the non-coronary sinus. The aortic root was then replaced with a Freestyle stentless prosthesis (Medtronic, Inc., Minneapolis, MN, USA) sutured in the LVOT with interrupted TiCron 4-0 sutures. Coronary buttons were reimplanted using running Prolene 5-0 sutures (Ethicon, Somerville, NJ, USA). The distal anastomosis was made using a running Prolene 4-0 or 5-0 suture. Depending on anatomical

features, the prosthesis was rotated 120° for optimal placement of the coronary buttons. The remaining coronary button of the prosthesis was oversewn.

Definitions and statistical analysis

Data are reported according to the guidelines for reporting mortality and morbidity after cardiac valve interventions [8]. Echocardiographic follow-up data were acquired through transthoracic echocardiography (TTE) in our outpatient clinic or from the referring cardiologist. Follow-up closed on 1 September 2015.

Continuous variables are expressed as mean ± standard deviation or median and range, as appropriate. Categorical data are expressed as numbers and percentages. Estimates of overall survival were calculated using the Kaplan–Meier method and expressed as percentages with 95% confidence interval (CI). Survival curves were compared using the log-rank test. Survival analysis was performed using GraphPad Prism 6 (GraphPad Software, Inc., La Jolla, CA, USA). All other analyses were performed using the statistical software package SPSS 20 (IBM Corp., Armonk, NY, USA). A *P* -value of less than 0.05 (two-sided) was considered statistically significant.

RESULTS

Patients

Fifty-four consecutive patients with extensive aortic valve endocarditis were operated. Twenty-nine (54%) patients had prosthetic valve endocarditis (19 mechanical prostheses, 2 homografts). Patient demographics are presented in Table 1 and microbiologic data are presented in Table 2 . Blood cultures remained negative in 9 (16%) patients. Guided antibiotic treatment was initiated as described and typically continued for 6 weeks after surgery. In selected patients, antibiotic treatment was continued for a longer period (i.e. endocarditis caused by proprionibacterium species, or patients with septic emboli or peripheral abscess formation). The median duration of preoperative guided antibiotic pretreatment was 10 days (range, 0–70 days). The median duration of total antibiotic treatment was 53 days (range, 35–481 days).

Table 1: Patient demographics

Patient demographics	***n* (%)**
n	54
Age (years, mean ± SD)	61.1 ± 13.4
Male	40 (74)
Poor LVF (EF ≤ 40)	1 (2)
eGFR < 50 ml/min/1.73 m^2	9 (17)
Preoperative renal dialysis	3 (6)
Prior cerebrovascular accident	10 (19)
Previous cardiac surgery	34 (63)
Previous aortic valve replacement	29 (54)
Logistic EuroSCORE I (mean ± SD)	42.6 ± 19.4
EuroSCORE II (mean ± SD)	20.1 ± 13.5
Antibiotic pretreatment (days, median; range)	10; range 0–70
Preoperative septic emboli	13 (24)
Cerebral	6 (11)

EF: ejection fraction; eGFR: estimated glomerular filtration rate; LVF: left ventricular function; SD: standard deviation.

Table 2: Microbiologic data

Micro-organism in culture	***n* (%)**
Staphylococcus aureus	13 (24)
Staphylococcus epidermidis	2 (4)
CNS n.o.s.	2 (4)
Proprionibacterium	7 (13)
Streptococcus bovis	1 (2)
Streptococcus pneumoniae	2 (4)
Other *Streptococcus* spp.	10 (18)
Enterococcus faecalis	8 (15)
Culture negative	9 (16)

n.o.s.: not otherwise specified; CNS: coagulase-negative *Staphylococcus* .

Operative details

The mean cardiopulmonary bypass time was 283 ± 91 min and the mean aortic cross-clamping time was 219 ± 69 min. Five patients were operated under deep hypothermic circulatory arrest with antegrade cerebral perfusion (mean duration 22 ± 12 min) for replacement of the distal ascending aorta or proximal aortic arch. One patient with abscess extension into the right ventricular outflow tract and pulmonary valve underwent concomitant pulmonary valve replacement with a

Freestyle stentless bioprosthesis. Other concomitant procedures are presented in Table 3 .

Table 3: Operative details

Operative details	***n* (%)**
Concomitant procedures	
Coronary artery bypass grafting	10 (18)
Mitral valve replacement	6 (11)
Mitral valve repair	13 (24)
Tricuspid valve repair	5 (9)
Pulmonary valve replacement	2 (4)
Aortic-mitral continuity reconstruction	9 (16)
Hemiarch replacement	1 (2)
Prosthesis size	
21 mm	1 (2)
23 mm	9 (16)
25 mm	16 (29)
27 mm	12 (22)
29 mm	17 (31)

Early mortality and postoperative complications

There were 6 (11%) early deaths, all in-hospital, 2 of which during surgery due to left and right ventricular failure, respectively. All patients but one in the early death group were operated for prosthetic valve endocarditis. Two patients died of multiorgan failure, 1 patient had right ventricular failure, 1 patient had left ventricular failure and 1 patient had intractable circulatory failure secondary to sepsis. The patient with native valve endocarditis died of postanoxic encephalopathy after cardiopulmonary resuscitation for cardiac arrest.

Temporary circulatory support was necessary in 3 patients using intra-aortic balloon counterpulsation, 1 patient needed additional extracorporeal membrane oxygenation support. Six patients had postoperative kidney failure requiring temporary haemodialysis. Five patients underwent reoperation for bleeding. Thirteen patients required permanent pacemaker implantation. In all patients, the operation achieved local control of the infection.

Long-term survival

Follow-up was complete in all patients. Median follow-up time was 3.5 years, ranging from 0 to 15 years, and consisted of 180 patient-years. Estimated overall survival at 1 and 5 years was 83 (95% CI: 70–91%) and 70% (95% CI: 52–82%), respectively. Seven cases of late mortality were observed at postoperative days 121, 316 and 325, and after 2.4, 3.1, 4.0 and 4.6 years postoperatively (Fig. 1). Causes of death were acute myocardial infarction, intestinal ischaemia, respiratory insufficiency after surgery on the mitral valve, congestive heart failure, urosepsis, acute myeloid lymphoma and pancreatic carcinoma, respectively.

Figure 1:

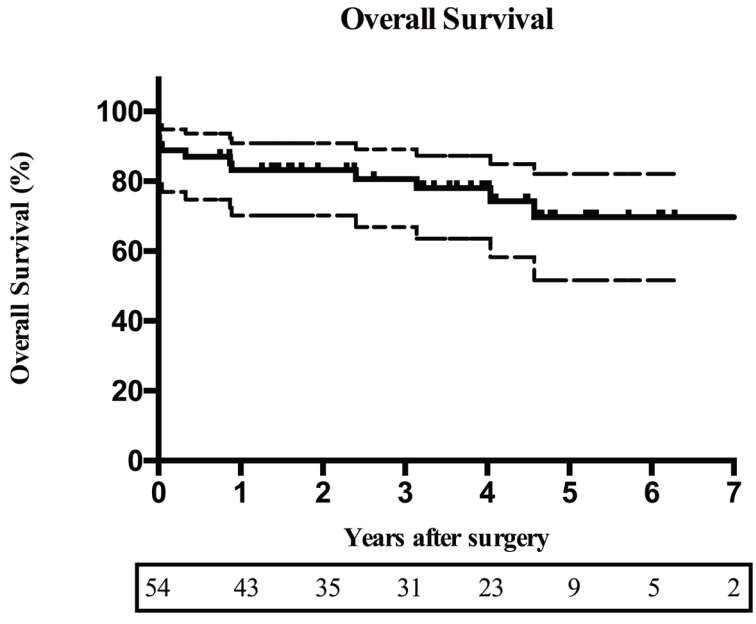

Kaplan–Meier curve of estimated overall survival. Dashed lines denote 95% confidence interval. Numbers under the curve depict numbers at risk.

Valve-related events

One patient developed endocarditis with pneumococcus species 2.3 years after surgery. There was extensive involvement of adjacent structures (left main coronary artery, roof of the left atrium, left atrial appendage and anterior mitral

valve leaflet). After resection of all infected tissues, a bovine pericardial patch was used to reconstruct the LVOT and a new Freestyle prosthesis was implanted. The patient was put on lifelong antibiotic Pneumococcus prophylaxis. At latest follow-up, the patient was doing well and TTE showed good function of the Freestyle prosthesis. No other valve-related event was seen during follow-up.

Echocardiographic follow-up

Echocardiographic follow-up in alive patients was 100% complete. At latest echocardiographic follow-up (median follow-up time: 3.3 years; range, 0.2–14.2 years), all prostheses were functioning well. Mean gradients across the valve were 7.2 ± 4.2 mmHg peak and 4.3 ± 2.3 mmHg mean gradient. No patient had more than mild aortic regurgitation.

DISCUSSION

IE of the aortic valve with extended aortic root involvement remains a clinically and surgically challenging condition. After resection of all infected tissues, several approaches are available to reconstruct the destructed geometry of the LVOT and adjacent structures. Patch reconstruction followed by mechanical or biological valve replacement, homograft root replacement or stentless bioprosthetic root replacement are all part of the surgeon's armamentarium. Guidelines do not specifically favour either mechanical or biological prostheses since mortality and recurrence of endocarditis rates are similar, provided that complete resection of all infected tissues is assured [1]. However, they do support the use of homografts or stentless bioprostheses in IE patients with periannular abscess formation. The advantage of homografts and stentless bioprostheses is their versatility during implantation in anatomically challenging situations. Several studies have reported outcomes of homografts in IE. A 20-year follow-up study in 221 patients who received an aortic homograft for extensive IE reported an early mortality rate of 16.2% for patients with native valve endocarditis and 25.4% for patients with prosthetic valve endocarditis. Reported freedom from reoperation for recurrent endocarditis after 10 years was 92% and comparable between the native and prosthetic valve endocarditis groups (92.9 and 92.1%, respectively) [9]. Another group described a hospital mortality rate of 24% in 69 patients with IE who received aortic homografts (61 implanted as full root). In this group, 7% had recurrent endocarditis, predominantly early after surgery [10].

Because suitable homografts are scarce, the use of stentless bioprostheses in patients requiring aortic root replacement has gained popularity. The versatility of the Freestyle prosthesis is comparable with that of a homograft. Implantation of the prosthesis as a full root replacement maintains the normal anatomical relations. Depending on the extent of resection of the LVOT, the prosthesis can be placed below the annular level at the aortic-mitral continuity, at the annular level or even above the level of the original annulus.

The Freestyle prosthesis has shown excellent long-term clinical and haemodynamic results [5, 11]. The present study focused on 54 patients who received the Freestyle stentless bioprosthesis for LVOT and aortic root reconstruction in extensive IE. Only a limited number of reports are available in which the outcomes of the Freestyle prosthesis in patients with extended IE are reported. A study by Heinz *et al.* [12] describing their experience with the Freestyle prosthesis in 32 IE patients reported an early mortality rate of 18.8%. Another study by Miceli *et al.* [13] in 18 patients reported 11.1% early mortality. Our early mortality rate of 11% in this very high-risk group of patients is similar. These mortality rates are comparable with the previously mentioned mortality rates after homograft implantation in IE patients [9, 10]. A study by El-Hamamsy *et al.* compared late outcomes of Freestyle versus homograft aortic root replacement for all indications in 166 patients with a median follow-up time of 7.6 years [4]. They concluded that late survival was similar in both groups, but progression of aortic valve dysfunction and need for reoperation was lower in the Freestyle group. This might be due to earlier onset of calcification in homografts compared with the Freestyle prosthesis [14].

The ideal timing of surgery in patients with IE is subject to debate. Congestive heart failure due to severe regurgitation or stenosis of the infected valve is a Class I indication for urgent surgery [1]. Furthermore, abscess formation and embolic risk from vegetations are reasons to consider urgent surgery [1, 15]. Although surgery in the active phase has higher risks, in patients with the most severe forms of IE it is associated with improved 6-month survival [15]. The risk of embolic events decreases after the start of antibiotic treatment, with an incidence of 4.8/1000 in the first week and 1.7/1000 in the second week of antibiotic treatment. Prevention of embolic events as the sole indication for surgery should therefore be rejected after 1 week of antibiotic treatment [16]. However, there is little gain in waiting to operate on these patients after the bloodstream is sterilized due to the antibiotics,

usually achieved within 48 h. As resection of all infected tissue is the cornerstone of this operation, waiting for tissues to be healed seems irrational. This is supported by a study by Kim *et al.* [17], who found that early surgery (within 7 days after diagnosis) in patients with severe valvular disease and large vegetations was associated with better clinical outcomes compared with postponing surgery.

Identifying vegetations and, especially, periannular abscesses with transoesophageal echocardiography (TOE) remains challenging. In our series, 8 of 35 abscesses were not identified on preoperative TOE. Hill *et al.* [18] described their experience with TOE detection of periannular abscesses in aortic and mitral valve endocarditis with findings during surgery as definitive diagnosis. They reported periaortic abscess detection with TOE in 63% of patients. Mitral abscesses were even more difficult to detect with a detection rate of 30%. In our series, missed abscesses occurred mainly in the earlier years of our experience, possibly related to improved TOE imaging over the last years. In general, the local destruction is more severe than might be expected from imaging modalities. Other imaging techniques, such as multislice computed tomography (CT) scans, might improve the identification of abscesses in IE and their extension in surrounding tissues [1, 19]. A study by Saby *et al.* demonstrated the added value of positron emission tomography/computed tomography (PET/CT) imaging in the diagnosis of IE [20]. PET/CT was able to identify infective processes in an earlier stage compared with TOE. Furthermore, whole body imaging was useful for detecting emboli, metastatic infection and occult primary tumours.

During follow-up, no patient required reoperation for structural valve deterioration, although it should be emphasized that follow-up was shorter than the expected durability of the Freestyle prosthesis. Like all other bioprostheses, the Freestyle prosthesis is subject to structural valve deterioration in time. There was 1 case of recurrent endocarditis 2.3 years after implantation. This low recurrence rate is most likely due to the aggressive nature of the surgery and the antibiotic treatment that we continue for a minimum of 6 weeks after surgery, both in native and prosthetic valve endocarditis patients. Although topical antibiotic treatment with rifampicin is applied to the LVOT, to the implanted prosthesis and to the sutures used to implant the valve, the additional benefit is difficult to assess.

Study limitations

This is a retrospective study with its inherent limitations. Since we do not use homografts on a large scale in adult patients, we could not compare our Freestyle data to that of homografts. A comparison of outcomes between homografts and the Freestyle prosthesis is thus based on available literature. A definite strength of this study, however, is that the vast majority of echocardiographic follow-up was performed in our institution, providing a homogeneous dataset and the clinical follow-up was 100% complete.

CONCLUSION

To our knowledge, this study describes the largest series of patients to receive a Freestyle stentless bioprosthesis for IE with local destruction of surrounding tissues. The prosthesis is a valuable option and its use should be considered in LVOT reconstruction after extensive debridement. Clinical outcomes in patients receiving this prosthesis are as good as those of patients receiving homografts, even in patients with IE. Haemodynamic performance is excellent, and the risk of recurrent aortic valve endocarditis is very low. Early mortality, however, remains relatively high in this group of patients.

FUNDING

This study was supported by an unrestricted research grant from Medtronic, Inc., Minneapolis, MN, USA.

Conflict of interest: none declared.

REFERENCES

1. Habib G, Lancellotti P, Antunes MJ, Bongiorni MG, Casalta J-P, Del Zotti F, et al. 2015 ESC Guidelines for the management of infective endocarditis: The Task Force for the Management of Infective Endocarditis of the European Society of Cardiology (ESC) Endorsed by: European Association for Cardio-Thoracic Surgery (EACTS), the European Association of Nuclear Medicine (EANM). European Heart Journal 2015:ehv319. doi:10.1093/eurheartj/ehv319.

2. Nishimura RA, Otto CM, Bonow RO, Carabello BA, Erwin JP, Guyton RA, et al. 2014 AHA/ACC guideline for the management of patients with valvular heart disease: a report of the American College of Cardiology/American Heart Association Task Force on Practice Guidelines. Journal of the American College of Cardiology 2014;63:e57–185. doi:10.1016/j.jacc.2014.02.536.

3. Byrne JG, Rezai K, Sanchez JA, Bernstein RA, Okum E, Leacche M, et al. Surgical Management of Endocarditis: The Society of Thoracic Surgeons Clinical Practice Guideline. The Annals of Thoracic Surgery 2011;91:2012–9. doi:10.1016/j.athoracsur.2011.01.106.

4. El-Hamamsy I, Clark L, Stevens LM, Sarang Z, Melina G, Takkenberg JJM, et al. Late outcomes following freestyle versus homograft aortic root replacement: results from a prospective randomized trial. Journal of the American College of Cardiology 2010;55:368–76. doi:10.1016/j.jacc.2009.09.030.

5. Bach DS, Kon ND. Long-Term Clinical Outcomes 15 Years After Aortic Valve Replacement With the Freestyle Stentless Aortic Bioprosthesis. The Annals of Thoracic Surgery 2014;97:544–51. doi:10.1016/j.athoracsur.2013.08.047.

6. Mohammadi S, Kalavrouziotis D, Voisine P, Dumont E, Doyle D, Perron J, et al. Bioprosthetic valve durability after stentless aortic valve replacement: the effect of implantation technique. The Annals of Thoracic Surgery 2014;97:2011–8. doi:10.1016/j.athoracsur.2014.02.040.

7. Li JS, Sexton DJ, Mick N, Nettles R, Fowler VG, Ryan T, et al. Proposed modifications to the Duke criteria for the diagnosis of infective endocarditis. Clin Infect Dis 2000;30:633–8. doi:10.1086/313753.

8. Akins CW, Miller DC, Turina MI, Kouchoukos NT, Blackstone EH, Grunkemeier GL, et al. Guidelines for reporting mortality and morbidity after cardiac valve interventions. The Journal of Thoracic and Cardiovascular Surgery 2008;135:732–8. doi:10.1016/j.jtcvs.2007.12.002.

9. Musci M, Weng Y, Hübler M, Amiri A, Pasic M, Kosky S, et al. Homograft aortic root replacement in native or prosthetic active infective endocarditis: twenty-year single-center experience. The Journal of Thoracic and Cardiovascular Surgery 2010;139:665–73. doi:10.1016/j.jtcvs.2009.07.026.

10. Flameng W, Daenen W, Jashari R, Herijgers P, Meuris B. Durability of homografts used to treat complex aortic valve endocarditis. The Annals of Thoracic Surgery 2015;99:1234–8. doi:10.1016/j.athoracsur.2014.11.002.

11. Mohammadi S, Tchana-Sato V, Kalavrouziotis D, Voisine P, Doyle D, Baillot R, et al. Long-Term Clinical and Echocardiographic Follow-Up of the Freestyle Stentless Aortic Bioprosthesis. Circulation 2012;126:S198–S204. doi:10.1161/CIRCULATIONAHA.111.084806.

12. Heinz A, Dumfarth J, Ruttmann-Ulmer E, Grimm M, Müller LC. Freestyle root replacement for complex destructive aortic valve endocarditis. The Journal of Thoracic and Cardiovascular Surgery 2014;147:1265-70. doi:10.1016/j.jtcvs.2013.05.014.

13. Miceli A, Croccia M, Simeoni S, Varone E, Murzi M, Farneti PA, et al. Root replacement with stentless Freestyle bioprostheses for active endocarditis: a single centre experience. Interactive CardioVascular and Thoracic Surgery 2012;16:27–30. doi:10.1093/icvts/ivs438.

14. El-Hamamsy I, Zaki M, Stevens LM, Clark LA, Rubens M, Melina G, et al. Rate of progression and functional significance of aortic root calcification after homograft versus freestyle aortic root replacement. Circulation 2009;120:S269–75. doi:10.1161/CIRCULATIONAHA.108.843748.

15. Thuny F, Beurtheret S, Mancini J, Gariboldi V, Casalta J-P, Riberi A, et al. The timing of surgery influences mortality and morbidity in adults with severe complicated infective endocarditis: a propensity analysis. European Heart Journal 2011;32:2027–33. doi:10.1093/eurheartj/ehp089.

16. Dickerman SA, Abrutyn E, Barsic B, Bouza E, Cecchi E, Moreno A, et al. The relationship between the initiation of antimicrobial therapy and the incidence of stroke in infective endocarditis: an analysis from the ICE Prospective Cohort Study (ICE-PCS). American Heart Journal 2007;154:1086–94. doi:10.1016/j.ahj.2007.07.023.

17. Hill EE, Herijgers P, Claus P, Vanderschueren S, Peetermans WE, Herregods M-C. Abscess in infective endocarditis: The value of transesophageal echocardiography and outcome. American Heart Journal 2007;154:923–8. doi:10.1016/j.ahj.2007.06.028.

18. Habets J, Tanis W, Reitsma JB, van den Brink RBA, Mali WPTM, Chamuleau SAJ, et al. Are novel non-invasive imaging techniques needed in patients with suspected prosthetic heart valve endocarditis? A systematic review and meta-analysis. Eur Radiol 2015;25:2125–33. doi:10.1007/s00330-015-3605-7.

19. Saby L, Laas O, Habib G, Cammilleri S, Mancini J, Tessonnier L, et al. Positron emission tomography/computed tomography for diagnosis of prosthetic valve endocarditis: increased valvular 18F-fluorodeoxyglucose uptake as a novel major criterion. Journal of the American College of Cardiology 2013;61:2374–82. doi:10.1016/j.jacc.2013.01.092.



A MULTI-CENTER, PROPENSITY SCORE MATCHED COMPARISON BETWEEN STENTLESS BIOLOGICAL AND MECHANICAL COMPOSITE GRAFT AORTIC ROOT REPLACEMENT.

Adriaan W. Schneider, Bardia Arabkhani, Wiebe Knol, Mark G. Hazekamp, Robert J.M. Klautz, Johanna J.M. Takkenberg, Jerry Braun, Jos A. Bekkers

CHAPTER 7

ABSTRACT

Objective

Comparison of clinical outcome after mechanical versus biological aortic root replacement (ARR) in a propensity score matched cohort.

Methods

Propensity score matching was applied in 117 patients after mechanical ARR and 260 after biological ARR between 2004 and 2014 in 2 centers and resulted in 101 matched pairs. Primary endpoint was freedom from the composite endpoint of thromboembolic event, bleeding, reintervention and valve related mortality. Secondary endpoints were freedom all-cause mortality and the primary endpoints separately.

Results

After matching, patient characteristics were comparable between both groups, with a median age of 65-years. The median follow-up time was 4 years. Besides more reinterventions for bleeding in the mechanical prosthesis (MP) group, there were no differences in perioperative complication rates. At 8 years, freedom from thromboembolic event, bleeding, reintervention and valve related death (primary endpoint) was 60.9% (48.9 – 75.7%) in the MP group and 66.7% (49.8 – 89.1%) in the bioprosthesis (BP) group (P = 0.030). Overall survival was higher in the BP group (P = 0.032). The competing risks analysis showed a higher event-free survival probability during follow-up in the BP group (90.1% at 4 years) compared to the MP group (77.9% at 4 years).

Conclusions

Aortic root replacement with a bioprosthesis had better overall survival compared to a mechanical prosthesis in patients over 60 years of age, with a higher valve related mortality after mechanical valve replacement. Event-free survival during the first years of follow-up was higher after biological root replacement.

INTRODUCTION

Several options are available to replace a diseased aortic valve and root. Mechanical composite grafts have been the “gold standard” for several decades. The most important benefit is an excellent durability of mechanical prostheses. This comes, however, at the cost of lifelong anticoagulant therapy to prevent thromboembolism, which is related with higher hemorrhagic event risk. Bioprostheses do not need anticoagulant treatment, but structural degeneration, especially in young patients, limit their durability with the risk of a reintervention in time. In recent years, the use of bioprostheses has increased[1]. This increase might be explained by improved durability of modern bioprostheses and the advances in less invasive transcatheter valve-in-valve reinterventions to replace a degenerated bioprosthesis.

Regarding aortic valve prosthesis choice, recent American and European guidelines state that bioprostheses should be considered in older patients (aged >70[2] and >65[3]), and mechanical prostheses should be considered in younger patients (aged <50[2] and <60[3]). However, the lack of scientific support for these class IIa recommendations is demonstrated by the level of evidence C (expert opinion). Furthermore, these recommendations create a gray area in which prosthetic valve selection is less straightforward, and patient preferences, considering risks of reoperation and risks of anticoagulant treatment, play a more important role. Moreover, in case of aortic root disease there might be additional risks due to the more extensive surgery, especially in the perioperative period. In this light there is even less evidence on outcomes related to the type of prosthesis.

In this light we conducted a propensity score matched cohort study after aortic valve and root replacement with either a mechanical composite graft or a stentless aortic root bioprosthesis, to search for differences in clinical outcome between both types of prostheses.

METHODS

Patients

Between 2004 and 2014, 352 patients underwent aortic valve and root replacement (ARR) with a mechanical composite graft (MP) at the Erasmus Medical Center, and 366 patients underwent ARR with a Freestyle stentless bioprosthesis (BP) (Medtronic Inc., Minneapolis, MN, USA) at the Leiden University Medical Center. Since some etiologies of aortic valve and root disease are relatively rare and there were differences between the 2 groups (i.e. congenital cardiac anomalies like hypoplastic left heart, atrioventricular septal defect, and tetralogy of Fallot were overrepresented in the biological valve group), these patients were excluded from the study. Additionally, all patients with emergent surgery were excluded, resulting in 117 patients with a MP and 260 with a BP in the study population.

Anticoagulant treatment

Patients with mechanical AVR postoperatively received lifelong vitamin K antagonists (VKA) with a target International Normalized Ration of 2.0 – 3.0. Patients who received a biological AVR were treated with aspirin for 3 months (unless VKA treatment was warranted for other indications).

Data collection

Data were collected retrospectively from the departments' databases. Follow-up data was obtained using outpatient clinic visits, questionnaires, or through direct telephone contact. Data on death causes were obtained from hospital records or patients general practitioners. Valve related events were defined according to current guidelines[4]. The ethical committees of the centers approved of this study and waived the need of patients informed consent.

Study endpoints

The primary endpoint was freedom from the composite endpoint of thromboembolic (TE) event, bleeding, reintervention and valve related mortality. Secondary endpoints were freedom all-cause mortality, and the primary endpoints separately. Study endpoints are reported for both the unmatched, and the matched study cohorts.

Statistical analysis

The cohort was matched using propensity score matching, considering 15 variables (Table 1). Matching was performed 1:1 without replacement, with a caliper width of 0.05 and priority to exact matches, resulting in 103 matched pairs. Continuous data are expressed as means ± standard deviation (SD) and compared using the Students T-test or as medians (interquartile range [IQR]) and compared with the Mann-Whitney U-test where appropriate. Categorical data are expressed as counts (%) and compared using the Chi-squared test or Fishers exact test. Freedom from events were calculated using the Kaplan-Meier estimator and compared using the log-rank test. To provide insights in the time related occurrence of valve related events, a competing risks analysis was performed using the mstate package[5] in R (version 3.5.0, R foundation for statistical computing, Vienna, Austria). Analyzed competing risks were death, reoperation and thromboembolic/bleeding event. All other analyses were performed with IBM SPSS Statistics version 24 (IBM Inc., Armonk, NY, USA).

RESULTS

Baseline characteristics

Baseline characteristics of the total group before matching, and the matched cohort are shown in Table 1. After matching, there were no preoperative differences between both groups, indicating an adequate performance of the matching process. Median follow-up in the MP group was 4.2 (2.3 – 6.3) years in the unmatched and 4.3 (2.3 – 6.7) years in the matched cohort, and in the BP group 4.3 (2.5 – 5.7) years in the unmatched and 4.6 (2.8 – 6.2) in the matched cohort, and was 100% complete.

Table 1. Patient characteristics

	Entire cohort			Matched cohort		
	Bentall	**Freestyle**	**P-value**	**Bentall**	**Freestyle**	**P-value**
Number of patients	117	260		103	103	
Male sex	86 (73.5)	180 (69.2)	0.400	74 (71.8)	79 (76.7)	0.425
Age at operation (y) (median [IQR])	65.5 (61.1 – 70.1)	64.1 (58.9 – 71.4)	0.355	65.6 (61.3 – 70.0)	65.2 (61.8 – 72.1)	0.577
Redo surgery	31 (26.5)	67 (25.8)	0.882	25 (24.3)	28 (27.2)	0.633
LVEF			0.006			0.836
>50	82 (70.1)	197 (75.8)		79 (76.7)	77 (74.8)	
30 – 50	19 (16.2)	53 (20.4)		19 (18.4)	19 (18.4)	
21 – 30	12 (10.3)	8 (3.1)		5 (4.9)	7 (6.8)	
20 or less	4 (3.4)	2 (0.8)		...	...	
Prior myocardial infarction	5 (4.3)	13 (5.0)	0.760	4 (3.9)	4 (3.9)	1
Urgent timing	30 (25.6)	66 (25.4)	0.958	22 (21.4)	28 (27.2)	0.330
Diabetes mellitus	3 (2.6)	34 (13.1)	0.002	3 (2.9)	4 (3.9)	0.701
Creatinine (median [IQR])	89 (75 – 104)	81 (72 – 96)	0.007	87 (73 – 101)	82 (74 – 99)	0.329
Prior CVA	3 (2.6)	37 (14.3)	0.001	3 (2.9)	6 (5.8)	0.307
Coronary artery disease	18 (15.4)	56 (21.5)	0.164	18 (17.5)	16 (15.5)	0.707
Aortic valve stenosis	61 (52.1)	142 (54.6)	0.655	49 (47.6)	56 (54.4)	0.780
Aortic valve insufficiency	87 (74.4)	192 (73.8)	0.916	73 (70.9)	74 (71.8)	0.878
COPD	13 (11.1)	26 (10.0)	0.743	12 (11.7)	13 (12.6)	0.831
Hypertension	55 (47.0)	169 (65.3)	0.001	53 (51.5)	55 (53.4)	0.780
NYHA functional class			0.337			0.944
I	48 (41.7)	97 (37.3)		45 (43.7)	43 (41.7)	
II	29 (25.2)	87 (33.5)		29 (28.2)	33 (32.0)	
III	33 (28.7)	68 (26.2)		22 (26.2)	25 (24.3)	
IV	5 (4.4)	8 (3.1)		2 (1.9)	2 (1.9)	

Values depict count (%) unless stated otherwise
COPD: chronic obstructive pulmonary disease, CVA: cerebrovascular accident, IQR: interquartile range, LVEF: left ventricular ejection fraction

Perioperative details

Perioperative details are shown in Table 2. There were more reinterventions for bleeding in the MP group. Early mortality, postoperative conduction block requiring a pacemaker, postoperative stroke, and postoperative myocardial infarction were not statistically significantly different between both groups.

Table 2. (Peri)operative details

	Entire cohort			**Matched cohort**		
	Bentall	**Freestyle**	**P-value**	**Bentall**	**Freestyle**	**P-value**
Bypass time (median [IQR])	189 (153 – 231)	206 (171 – 271)	0.011	183 (146 – 224)	207 (171 – 260)	0.010
Crossclamp time (median [IQR])	128 (100 – 157)	166 (132 – 213)	<0.001	125 (100 – 156)	167 (136 – 211)	0.010
Concomitant CABG	14 (12.0)	49 (18.8)	0.098	13 (12.6)	18 (17.5)	0.330
Concomitant mitral valve surgery	8 (6.8)	46 (17.7)	0.005	7 (6.8)	15 (14.6)	0.071
Reintervention for bleeding	24 (20.5)	17 (6.5)	<0.001	22 (21.4)	8 (7.8)	0.006
Perioperative myocardial infarction	1 (0.9)	5 (1.0)	0.444	1 (1.0)	1 (1.0)	1
Permanent pacemaker	5 (4.3)	21 (8,1)	0.175	3 (2.9)	8 (7.8)	0.134
Perioperative stroke	-	5 (1.9)	0.132	-	2 (1.9)	0.498
Early mortality	5 (4.3)	11 (4.2)	0.985	4 (3.9)	0	0.121

Values depict count (%) unless stated otherwise

CABG: coronary artery bypass grafting

Primary endpoint

The 8 year freedom from combined TE event, bleeding, reintervention and valve related death (primary endpoint) was 60.9% (48.9 – 75.7%) in the MP group and 66.7% (49.8 – 89.1%) in the BP group, respectively (P = 0.030) in the matched

population. Figure 1 shows the freedom from the primary endpoint in both the matched and the unmatched group.

Secondary endpoints

There was a survival benefit in favor of the BP group, with an 8 year estimated overall survival of 79.8% (68.5 – 92.9%) vs. 66.3% (55.1 – 79.8%) in the MP group (P = 0.032).

Freedom from TE events and bleeding combined, and freedom from reintervention did not differ significantly between both groups. Figure 1 shows a detailed freedom from the secondary endpoints in the matched and unmatched group.

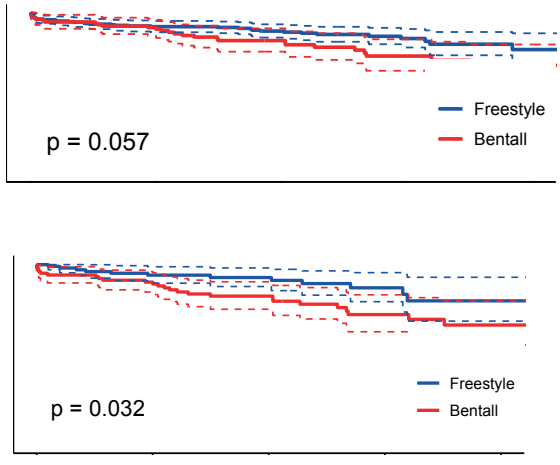

Figure 1. Kaplan-meier of overall survival (A), freedom from thromboembolic (TE) events and bleeding (B), freedom from reintervention (C) and freedom from the composite endpoint of TE events, bleeding, explant and valve related mortality in the unmatched (top) and matched (bottom) cohorts.

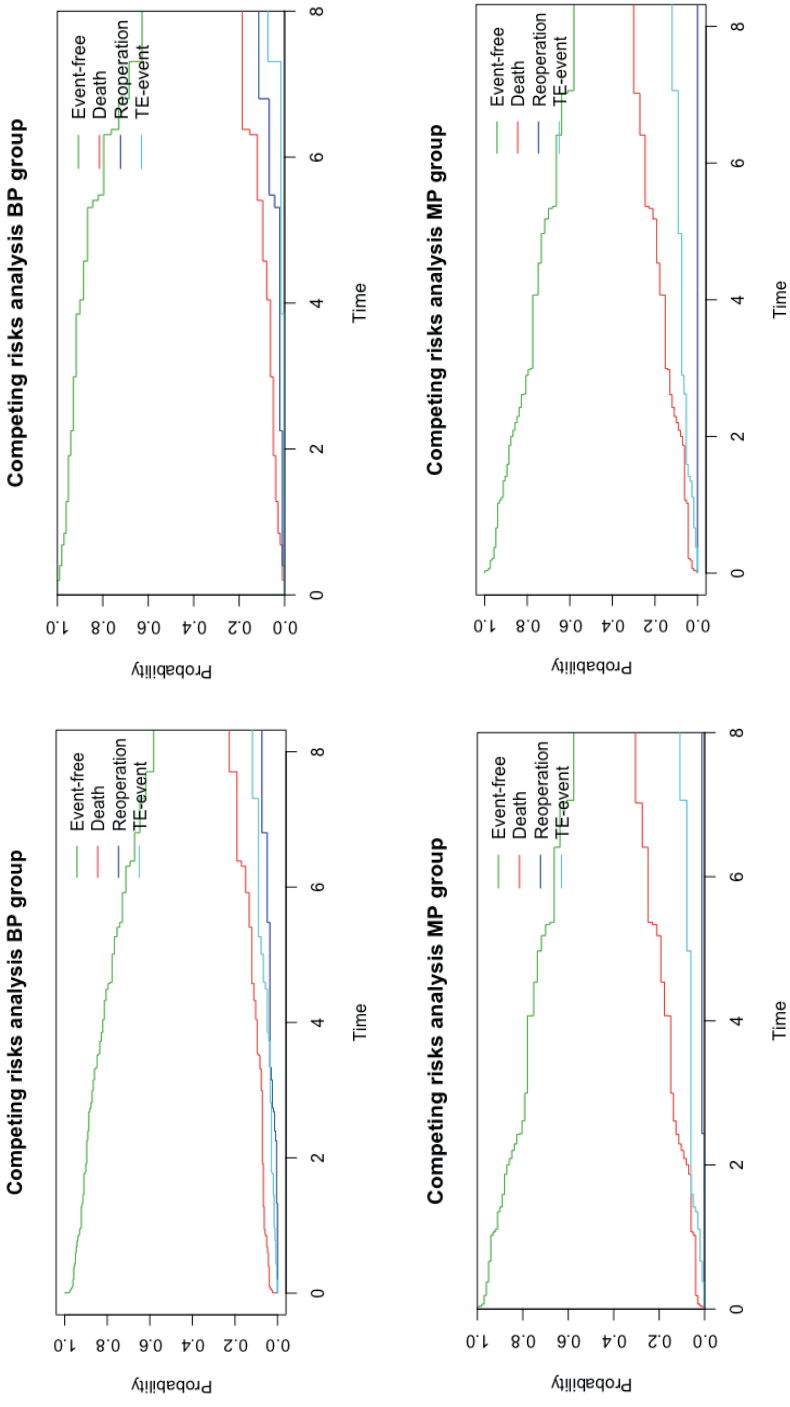

Figure 2. Competing risks analysis in the unmatched (left 2)) and matched (right 2) patient cohorts in the bioprosthesis group and mechanical prosthesis group. The increased probability of being event-free in the BP group decreases during follow-up.

Competing risks analysis

The competing risks analysis showed a higher event-free survival probability during at 4 years: 94% in the BP group (90.1% at 4 years) compared to 78% in the MP group. During the first years after surgery, a higher death rate and incidence of TE events in the MP group is responsible for this difference (Figure 2). At 8 years, however, the event-free rates of both groups converge (62.7% vs. 57.6% in the BP vs. MP groups in the matched cohort, respectively), mostly due to increased probability of death, and to a lesser extent reoperation, in the BP group (Figure 2).

DISCUSSION

This study reports on valve related outcomes after mechanical and biological aortic root replacement. Both prosthesis types seem to be safe and durable during the first decade after implantation. Mechanical valve replacement is associated with a higher valve related mortality, possibly due to more fatal bleeding events.

Early mortality and postoperative complications did not differ between both groups. This is in line with previously reported data.[6]These results emphasize that both treatment options can be performed safely, and that the choice between biological or mechanical aortic root replacement is a choice between the long-term risks accompanying both types of prostheses, and that preoperative informing of patients should focus on these aspects.

However, freedom from TE, bleeding, reintervention and valve related mortality was in favor of BP. This difference was already present in the unmatched group, but became more evident after propensity score matching. The most important separate endpoint contributing to this difference was the high rate of valve related mortality during follow-up in the MP group.

Freedom from the individual endpoints only differed significantly in terms of all-cause mortality. This difference is remarkable, considering the higher number of concomitant bypass and mitral valve surgery in the BP group. Several previous studies comparing biological versus mechanical AVR found either no difference, or higher survival rates in the mechanical prosthesis group, however, patients in most of these series were younger.[7-13] A possible explanation for this survival benefit in the BP group might be more concealed bleeding events in the sudden unexplained deaths.

Freedom from reinterventions did not differ significantly between both groups in the first postoperative decade. However, the rate of structural deterioration of bioprostheses increases after approximately 10 years in patients aged > 60 yrs. Longer follow-up of this series is needed to assess this event, as increased reoperation rates after biological AVR are expected.[8,12,14]

The incidence of TE- and bleeding events were comparable. Fatal bleeding events not diagnosed as such in the MP group, however, might be disguised as sudden valve related deaths, which leads to the significant difference in the primary outcome of this study. Although we cannot be completely certain, it is less likely that these sudden deaths were cardiac deaths, since there was no sign of progressive (ventricular or valvular) dysfunction in the outpatient clinic. Unfortunately, only few pathology reports were available as autopsy, especially after deaths outside of the hospital, are not performed routinely due to objection from the patients family.

The median age of 65 years in this study population is relatively old for mechanical prostheses. Higher age is associated with more bleeding complications of anticoagulant treatment with vitamin K antagonists[15,16]. In this study, the increased mortality in the MP group was attributable to the high number of sudden, unexplained deaths. These deaths might be explained due to undiagnosed fatal bleeding events due to anticoagulant treatment. The higher bleeding risk in older patients is one of the considerations of the recent guidelines on valvular heart disease, which state that bioprostheses should be considered in older patients.[2,3] Although this is still a level of evidence C recommendation, the results of this study provide data to support this recommendation. In a meta-analysis by Mookhoek et al., the reported linearized occurrence rate of hemorrhage and thromboembolism after the Bentall procedure was estimated at 1.2% per patient-year[17]. A recent study on long-term outcomes after aortic valve and root replacement using the Freestyle prosthesis in a large cohort reports a combined linearized occurrence rate of 1% per patient-year for hemorrhage and thromboembolism (including transient ischemic attacks)[14].

The competing risks analysis showed an increased event-free survival probability in the first 5 years after surgery in the BP group. This difference was mainly attributable to higher mortality rates and increased incidence of TE events during

the first years after surgery in the MP group. At 8 years, however, event-free probabilities were similar between both groups, with increasing death rates in the BP group. Reoperations will further lower event-free rates, probably more so in the BP group than the MP group due to increasing structural degeneration of bioprostheses during longer follow-up.

Limitations

This is a retrospective study comparing 2 treatment options with possible different patient populations, however, propensity score matching provided 2 comparable groups and minimized bias. The follow-up time of the BP might be relatively short, as most SVD of bioprostheses occurs after 10 years, so more reinterventions in the BP group can be expected with longer follow-up. Although both centers act according to the guidelines, local preferences in peri-operative care may have influences outcomes.

CONCLUSIONS

Both mechanical and biological aortic root replacement can be performed safely. Mid-term freedom from TE events, bleeding and reintervention is similar between both types of prostheses. The results of this study show better survival after root replacement using a bioprosthesis compared to a mechanical prosthesis in patients over 60 years of age, with a higher valve related mortality after mechanical valve replacement, probably due to sudden death from hemorrhagic CVA. Event-free survival during the first years of follow-up seems to be higher after biological root replacement.

FUNDING

None

CONFLICT OF INTEREST

None.

REFERENCES

1. Isaacs AJ, Shuhaiber J, Salemi A, Isom OW, Sedrakyan A. National trends in utilization and in-hospital outcomes of mechanical versus bioprosthetic aortic valve replacements. The Journal of Thoracic and Cardiovascular Surgery 2015;149:1262–3. doi:10.1016/j.jtcvs.2015.01.052.

2. Nishimura RA, Otto CM, Bonow RO, Carabello BA, Erwin JP, Fleisher LA, et al. 2017 AHA/ACC Focused Update of the 2014 AHA/ACC Guideline for the Management of Patients With Valvular Heart Disease: A Report of the American College of Cardiology/American Heart Association Task Force on Clinical Practice Guidelines. Circulation 2017;135:e1159–95. doi:10.1161/CIR.0000000000000503.

3. Baumgartner H, Falk V, Bax JJ, De Bonis M, Hamm C, Holm PJ, et al. 2017 ESC/EACTS Guidelines for the management of valvular heart disease: The Task Force for the Management of Valvular Heart Disease of the European Society of Cardiology (ESC) and the European Association for Cardio-Thoracic Surgery (EACTS). European Heart Journal 2017. doi:10.1093/eurheartj/ehx391.

4. Akins CW, Miller DC, Turina MI, Kouchoukos NT, Blackstone EH, Grunkemeier GL, et al. Guidelines for reporting mortality and morbidity after cardiac valve interventions. The Journal of Thoracic and Cardiovascular Surgery 2008;135:732–8. doi:10.1016/j.jtcvs.2007.12.002.

5. de Wreede LC, Fiocco M, Putter H. The mstate package for estimation and prediction in non- and semi-parametric multi-state and competing risks models. Comput Methods Programs Biomed 2010;99:261–74. doi:10.1016/j.cmpb.2010.01.001.

6. Pantaleo A, Murana G, Di Marco L, Jafrancesco G, Barberio G, Berretta P, et al. Biological versus mechanical Bentall procedure for aortic root replacement: a propensity score analysis of a consecutive series of 1112 patients†. European Journal of Cardio-Thoracic Surgery 2017:1–7. doi:10.1093/ejcts/ezx070.

7. Hammermeister K, Sethi GK, Henderson WG, Grover FL, Oprian C, Rahimtoola SH. Outcomes 15 years after valve replacement with a mechanical versus a bioprosthetic valve: final report of the Veterans Affairs randomized trial. Journal of the American College of Cardiology 2000;36:1152–8.

8. Glaser N, Jackson V, Holzmann MJ, Franco-Cereceda A, Sartipy U. Aortic valve replacement with mechanical vs. biological prostheses in patients aged 50-69 years. European Heart Journal 2016;37:2658–67. doi:10.1093/eurheartj/ehv580.

9. Stassano P, Di Tommaso L, Monaco M, Iorio F, Pepino P, Spampinato N, et al. Aortic valve replacement: a prospective randomized evaluation of mechanical versus biological valves in patients ages 55 to 70 years. Journal of the American College of Cardiology 2009;54:1862–8. doi:10.1016/j.jacc.2009.07.032.

10. Byrne JG, Gudbjartsson T, Karavas AN, Mihaljevic T, Phillips BJ, Aranki SF, et al. Biological vs. mechanical aortic root replacement. European Journal of Cardio-Thoracic Surgery 2003;23:305–10.

11. Zhao DF, Seco M, Wu JJ, Edelman JB, Wilson MK, Vallely MP, et al. Mechanical Versus Bioprosthetic Aortic Valve Replacement in Middle-Aged Adults: A Systematic Review and Meta-Analysis. The Annals of Thoracic Surgery 2016;102:315–27. doi:10.1016/j.athoracsur.2015.10.092.

12. Chiang YP, Chikwe J, Moskowitz AJ, Itagaki S, Adams DH, Egorova NN. Survival and long-term outcomes following bioprosthetic vs mechanical aortic valve replacement in patients aged 50 to 69 years. Jama 2014;312:1323–9. doi:10.1001/jama.2014.12679.

13. van Geldorp MWA, Eric Jamieson WR, Kappetein AP, Ye J, Fradet GJ, Eijkemans MJC, et al. Patient outcome after aortic valve replacement with a mechanical or biological prosthesis: weighing lifetime anticoagulant-related event risk against reoperation risk. The Journal of Thoracic and Cardiovascular Surgery 2009;137:881–6–886e1–5. doi:10.1016/j.jtcvs.2008.09.028.

14. Schneider AW, Putter H, Hazekamp MG, Holman ER, Bruggemans EF, Versteegh MIM, et al. Twenty-year experience with stentless biological aortic valve and root replacement: informing patients of risks and benefits. Eur J Cardiothorac Surg 2018;53:1272–8. doi:10.1093/ejcts/ezx478.

15. Launbjerg J, Egeblad H, Heaf J, Nielsen NH, Fugleholm AM, Ladefoged K. Bleeding complications to oral anticoagulant therapy: multivariate analysis of 1010 treatment years in 551 outpatients. J Intern Med 1991;229:351–5.

16. Torn M, Bollen WLEM, van der Meer FJM, van der Wall EE, Rosendaal FR. Risks of oral anticoagulant therapy with increasing age. Arch Intern Med 2005;165:1527–32. doi:10.1001/archinte.165.13.1527.

17. Mookhoek A, Korteland NM, Arabkhani B, Di Centa I, Lansac E, Bekkers JA, et al. Bentall Procedure: A Systematic Review and Meta-Analysis. The Annals of Thoracic Surgery 2016;101:1684–9. doi:10.1016/j.athoracsur.2015.10.090.



REINTERVENTIONS AFTER FREESTYLE STENTLESS AORTIC VALVE REPLACEMENT:

An assessment of procedural risks

Adriaan W. Schneider, Mark G. Hazekamp, Michel I.M. Versteegh,
Arend de Weger, Eduard R. Holman, Robert J.M. Klautz,
Eline F. Bruggemans, Jerry Braun

Eur J Cardiothorac Surg 2019;56(6):1117-1123

CHAPTER 8

ABSTRACT

OBJECTIVES

Repeat aortic valve interventions after previous stentless aortic valve replacement (AVR) are considered technically challenging with an increased perioperative risk, especially after full-root replacement. We analysed our experience with reinterventions after stentless AVR.

METHODS

A total of 75 patients with previous AVR using a Freestyle stentless bioprosthesis (31 subcoronary, 15 root-inclusion and 29 full-root replacement) underwent reintervention in our centre from 1993 until December 2018. Periprocedural data were retrospectively collected from the department database and follow-up data were prospectively collected.

RESULTS

Median age was 62 years (interquartile range 47–72 years). Indications for reintervention were structural valve deterioration (SVD) in 47, non-SVD in 13 and endocarditis in 15 patients. Urgent surgery was required in 24 (32%) patients. Reinterventions were surgical AVR in 16 (21%), root replacement in 51 (68%) and transcatheter AVR in 8 (11%) patients. Early mortality was 9.3% ($n = 7$), but decreased to zero in the past decade in 28 patients undergoing elective reoperation. Per indication, early mortality was 9% for SVD, 8% for non-SVD and 13% for endocarditis. Aortic root replacement had the lowest early mortality rate (6%), followed by surgical AVR (13%) and transcatheter AVR (25%, 2 patients with coronary artery obstruction). Pacemaker implantation rate was 7%. Overall survival rate at 10 years was 69% (95% confidence interval 53–81%).

CONCLUSIONS

Repeat aortic valve interventions after stentless AVR carry an increased, but acceptable, early mortality risk. Transcatheter valve-in-valve procedures after stentless AVR require careful consideration of prosthesis leaflet position to prevent obstruction of the coronary arteries.

INTRODUCTION

The Freestyle stentless bioprosthesis (Medtronic Inc., Minneapolis, MN, USA) offers excellent haemodynamics in patients who require an aortic valve replacement (AVR) [1, 2]. However, as with all biological prostheses, structural valve deterioration (SVD) limits its durability, eventually necessitating reintervention. The growing use of bioprostheses for AVR in younger patients over the past decades, together with the increasing life expectancy, will result in an increased number of reinterventions in patients with bioprostheses [3]. The periprocedural risks associated with reinterventions may vary between different types of prostheses and could, therefore, influence the prosthesis choice during primary AVR.

Reinterventions after implantation of a stentless aortic bioprosthesis are potentially technically more demanding compared with reinterventions after implantation of a stented bioprosthesis or mechanical valve and, therefore, carry a supposedly higher perioperative complication risk. After stentless full-root (FR) implantation, reoperations may be more difficult because of dense adhesions around the aortic root, and care should be taken during re-excision of the coronary buttons. Resection of a calcified stentless prosthesis after subcoronary (SC) implantation may lead to laceration of the aortic annulus and thus require root replacement instead of valve replacement alone. Experience with transcatheter reintervention in this specific setting is limited [4].

Regarding the actual periprocedural risks associated with reinterventions after AVR with stentless bioprostheses, limited data are available. From 1993 until December 2018, the Freestyle stentless bioprosthesis has been used for AVR or root replacement in 818 patients at our institution. In this study, we describe our experience with different types of reinterventions after stentless AVR to quantify the risks accompanying these procedures, examining the different primary implantation techniques, the different aetiologies determining the indication for reintervention and the different reintervention techniques.

METHODS

All patients with a Freestyle stentless bioprosthesis in the aortic position who underwent a reintervention in our institution from 1993 until December 2018 were included in this study. Patients' preoperative and operative data regarding the reintervention were retrospectively collected from the department database.

Postoperative events were assessed according to current guidelines [5]. Early mortality was defined as death within 30 days after surgery or during index hospital admission. Patients' vital status was last checked on 12 December 2018 and was 100% complete. The local ethics committee approved the study design and waived the need for patient informed consent.

Decision on type of reintervention

The Freestyle prosthesis was implanted during primary AVR using one of the techniques previously described [6]. Patients with prosthesis dysfunction were discussed in the local heart team to decide on the indication for and type of reintervention. Redo-AVR or root replacement was the preferred reintervention. In selected high-risk patients, percutaneous valve-in-valve (ViV) techniques were deemed appropriate from 2008 onwards. Patients were categorized as high risk by the local heart team after considering patient-related factors (e.g. frailty, comorbidities) and procedural factors (e.g. porcelain aorta, position of coronary arteries). Final valve prosthesis selection (biological versus mechanical) was the result of a shared decision-making process involving patient and surgeon. Homografts were not routinely used for aortic valve or root replacement in our institution.

Statistical analysis

Continuous data are expressed as mean ± standard deviation when normally distributed or as median [interquartile range (IQR)] when non-normally distributed. Categorical data are expressed as *n* (%). Comparisons between subgroups were performed using the Mann–Whitney *U*-test or Kruskal–Wallis test for continuous data and Fisher's exact test for categorical data. Survival was estimated using the Kaplan–Meier method. Analyses were performed using IBM SPSS Statistics 23 for Windows (IBM Corp., Armonk, NY, USA).

RESULTS

A total of 75 patients underwent reintervention after previous stentless AVR or root replacement (Table 1). Median age at reintervention was 62.0 years (IQR 47.1–71.8 years) and 23 (31%) patients had undergone 2 or more previous surgeries. Median EuroSCORE II was 8.3 (IQR 5.3–14.6). During the initial stentless AVR, 31 (41%) prostheses were implanted using the SC technique, 15 (20%) using the root-

inclusion (RI) technique and 29 (39%) prostheses were used for FR replacement. Over time, there was an increased use of FR replacement, while the RI technique was abandoned in 1998.

Table 1: Patient characteristics per reintervention type

Characteristics	SAVR	SARR	TAVR	Total
Number of patients	16 (21.3)	51 (68.0)	8 (10.7)	75 (100)
Male gender	14 (87.5)	33 (64.7)	5 (62.5)	52 (69.3)
Age at reintervention (years), median (IQR)	61.5 (51.9–76.3)	55.0 (45.4–67.2)	82.2 (79.7–84.3)	62.0 (47.1–71.8)
Preoperative NYHA functional class				
I	4 (25.0)	10 (19.6)		14 (18.7)
II	3 (18.8)	22 (43.1)	4 (50.0)	29 (38.7)
III	4 (25.0)	13 (25.5)	1 (12.5)	18 (24.0)
IV	5 (31.3)	6 (11.8)	3 (37.5)	14 (18.7)
Preoperative atrial fibrillation	1 (6.3)	4 (7.8)	1 (12.5)	6 (8.0)
Number of previous surgeries				
1	12 (75.0)	34 (66.7)	6 (75.0)	52 (69.3)
2	1 (6.3)	12 (23.5)	1 (12.5)	14 (18.7)
3	3 (18.8)	3 (5.9)	1 (12.5)	7 (9.3)
4		1 (2.0)		1 (1.3)
5		1 (2.0)		1 (1.3)
Previous cerebrovascular accident		7 (13.7)	1 (12.5)	8 (10.7)
Previous myocardial infarction			2 (25.0)	2 (2.6)
Insulin-dependent diabetes mellitus	1 (6.3)			1 (1.3)
Hypertension	6 (37.5)	16 (31.4)	3 (37.5)	25 (33.3)
Chronic obstructive pulmonary disease		3 (6.0)		3 (3.9)
Renal dialysis		1 (2.0)	1 (12.5)	2 (2.7)
Implantation technique during primary AVR				
Subcoronary	9 (56.3)	15 (29.4)	7 (87.5)	31 (41.3)
Root-inclusion	6 (37.5)	8 (15.7)	1 (12.5)	15 (20.0)
Full-root replacement	1 (6.3)	28 (54.9)		29 (38.7)
EuroSCORE II, median (IQR)	5.2 (2.6–11.6)	8.9 (6.4–14.7)	10.6 (8.4–14.7)	8.3 (5.3–14.6)
Preoperative echocardiography				
AR ≥ grade 3	13 (81.3)	31 (60.8)		52 (69.3)
MR ≥ grade 3	3 (7.0)	4 (7.8)	2 (25.0)	6 (8.0)
LVEF ≤ 30%	1 (6.3)	2 (3.9)	2 (25.0)	5 (6.7)
Pulmonary hypertension (echocardiographic) (mmHg)				
30–55	3 (18.8)	10 (19.6)	2 (25.0)	15 (20.0)
>55	1 (6.3)	2 (3.9)		3 (4.1)

Data are presented as counts (%) unless stated otherwise.

AR: aortic regurgitation; AVR: aortic valve replacement; eGFR: estimated glomerular filtration rate; IQR: interquartile range; LVEF: left ventricular ejection fraction; MR: mitral regurgitation; NYHA: New York Heart Association; SARR: surgical aortic root replacement; SAVR: surgical AVR; TAVR: transcatheter aortic valve replacement.

Modes of failure of the stentless valve

In 47 (63%) patients, SVD was the failure mode of the stentless prosthesis. These patients typically presented with (sub-)acute dyspnoea due to sudden increase of aortic regurgitation caused by leaflet tear or perforation. Non-SVD was the failure mode in 13 (17%) patients and prosthesis endocarditis in 15 (20%). Median interval from implantation to reintervention was 7.8 years (IQR 3.5–12.6 years), with a significant difference between indications for reintervention (SVD versus non-SVD versus endocarditis 11.2 vs 3.5 vs 2.7 years; $P < 0.001$).

Operative details

Reinterventions were surgical AVR in 16 (21%; 8 mechanical, 7 biological, 1 sutureless), aortic root replacement in 51 (68%; 34 biological, 15 mechanical, 2 pulmonary autograft) and ViV transcatheter AVR (ViV-TAVR) in 8 (11%; 6 balloon expandable, 2 self-expanding) patients. Urgent surgery was required in 24 (32%) patients, mainly because of haemodynamic compromise or endocarditis. In patients undergoing surgical reintervention, 43 (64%) underwent a total of 50 concomitant procedures, mostly replacement of the ascending aorta (Table 2). Aortic root replacement with or without replacement of the ascending aorta was performed in case of dilatation of the root and ascending aorta, prosthesis endocarditis with perivalvular extension, and extensive calcification of the native aortic root (mostly at the suture lines of the stentless prosthesis) or a calcified prosthetic root.

Table 2: Procedural details and complications per reintervention type

	SAVR	SARR	TAVR	Total
Number of patients	16 (21.3)	51 (68.0)	8 (10.7)	75 (100)
Time between implantation and reintervention (years), median (IQR)	3.2 (0.9–6.4)	8.2 (4.6–12.8)	15.2 (11.4–18.1)	7.8 (3.5–12.6)
Timing				
Elective	11 (68.8)	34 (66.7)	6 (75.0)	51 (68.0)
Urgent	5 (31.3)	17 (33.3)	2 (25.0)	24 (32.0)
Indication				
SVD	6 (37.5)	33 (64.7)	8 (100)	47 (62.7)
NSVD	9 (56.3)	4 (7.8)		13 (17.3)
Endocarditis	1 (6.3)	14 (27.5)		15 (20.0)
Patients with concomitant surgery	4 (25.0)	39 (76.5)		43 (64.2)
Ascending aorta replacement	1 (6.3)	29 (56.9)		30 (44.8)
Mitral valve repair	1 (6.3)	8 (15.7)		9 (13.4)
Mitral valve replacement	1 (6.3)	2 (3.9)		3 (4.5)
Tricuspid valve repair		2 (3.9)		2 (2.9)
Coronary artery bypass grafting	1 (6.3)	5 (9.8)		6 (8.9)
Cross-clamping time (min), median (IQR)	123 (85–152)	171 (141–211)		168 (134–209)
Complications				
Left ventricular failure	2 (12.5)		2 (25.0)	4 (5.3)
Right ventricular failure		3 (5.9)	1 (12.5)	4 (5.3)
Postoperative intra-aortic balloon pump	1 (6.3)	2 (3.9)	1 (12.5)	4 (5.3)
Postoperative extracorporeal membrane oxygenation		2 (3.9)		2 (2.7)
New onset atrial fibrillation at discharge	1 (6.3)	2 (3.9)		3 (4.0)
Permanent pacemaker implantation		4 (7.8)	1 (12.5)	5 (6.7)
Postoperative myocardial infarction			2 (25.0)	2 (2.7)
Re-exploration for bleeding	2 (12.5)	5 (9.8)		7 (9.3)
Early mortality	2 (12.5)	3 (5.9)	2 (25.0)	7 (9.3)

Data are presented as counts (%) unless stated otherwise.

IQR: interquartile range; SARR: surgical aortic root replacement; SAVR: surgical AVR; TAVR: transcatheter aortic valve replacement.

Median cross-clamping time was 168 min (IQR 134–209 min) and was significantly longer in patients after primary FR implantation (FR versus other: 190 vs 151 min; $P = 0.002$).

Postoperative course and late survival

In total, there were 7 (9.3%) early deaths (Table 3). In 28 consecutive patients reoperated on for SVD since the last mortality in 2007, early mortality rate was zero. Early mortality was not significantly different in patients after primary FR implantation [FR versus other: 10% (3/29) vs 9% (4/46), $P = 1.0$]. Early mortality per indication was 8.5% (4/47) for SVD, 7.7% (1/13) for non-SVD and 13.3% (2/15) for endocarditis. Per reintervention type, early mortality was 12.5% (2/16) for surgical AVR, 5.9% (3/51) for aortic root replacement and 25% (2/8) for ViV-TAVR.

Table 3: Causes of early mortality

Patient	Age at reinter-vention (years)	Number of previous surgeries	Year of reoper-ation	Primary implantation technique of stentless valve	Reoperative procedure	Indication for reinter-vention	Cause of death
1	78	1	1996	Root-inclusion	Stentless bioprosthesis (subcoronary)	NSVD	Multi organ failure
2	54	1	1996	Subcoronary	Mechanical valve	SVD	Preop-erative critical state (ino-tropics). Postop-erative cardiac failure
3	20	4	2007	Full root	Annular extension (Konno incision), mechanical valve implantation, pulmonary valve replacement and CABG	SVD	Cardiac failure

Patient	Age at reinter-vention (years)	Number of previous surgeries	Year of reoper-ation	Primary implantation technique of stentless valve	Reoperative procedure	Indication for reinter-vention	Cause of death
4	81	1	2009	Subcoronary	ViV-TAVR	SVD	MI due to obstruc-tion of left coronary artery
5	75	1	2012	Full root	Stentless bio-prosthesis (full root), ascending aorta replace-ment and CABG	Endocar-ditis	RV failure due to obstruc-tion of the RCA despite emergen-cy con-comitant CABG
6	64	3	2012	Full root	Reconstruction of aortic-mitral continuity and left atrium, stentless bioprosthesis (full root) and ascending aorta replacement	Endocar-ditis	Multi organ failure
7	83	1	2013	Subcoronary	ViV-TAVR	SVD	MI due to obstruc-tion of left coronary artery

CABG: coronary artery bypass grafting; MI: myocardial infarction; NSVD: non-structural valve deterioration; RCA: right coronary artery; RV: right ventricle; SVD: structural valve deterioration; ViV-TAVR: valve-in-valve transcatheter aortic valve replacement.

In both ViV-TAVR patients who died, a SAPIEN balloon-expandable valve (Edwards Lifesciences, Irvine, CA, USA) was used, and in both patients, obstruction of the left coronary artery (LCA) resulted in periprocedural death. Although a wire was placed in the LCA prior to valve deployment to facilitate possible emergency intervention

in one of these patients, LCA obstruction occurred and emergency stenting could not prevent fatal myocardial infarction.

Five patients (6.7%) required postoperative circulatory support for cardiac failure with an intra-aortic balloon pump (*n* = 3), extracorporeal membrane oxygenation (*n* = 1) or both (*n* = 1). The latter 2 patients survived. Five patients required permanent pacemaker implantation due to a new conduction block, 4 after redo root replacement and 1 after ViV-TAVR.

Median follow-up time was 5.0 years (IQR 1.4–10.2 years). Overall survival rates at 1, 5 and 10 years were 90.7% [95% confidence interval (CI) 84.3–97.5%], 76.2% (95% CI 66.2–87.8%) and 69.2% (95% CI 53.2–80.5%), respectively (Fig. 1). Late death (*n* = 13) was valve-related in 2 (1 endocarditis, 1 prosthesis dehiscence), sudden unexplained in 2 and non-cardiac related in 7 patients. For 2 patients, no data on the cause of death could be retrieved.

Figure 1:

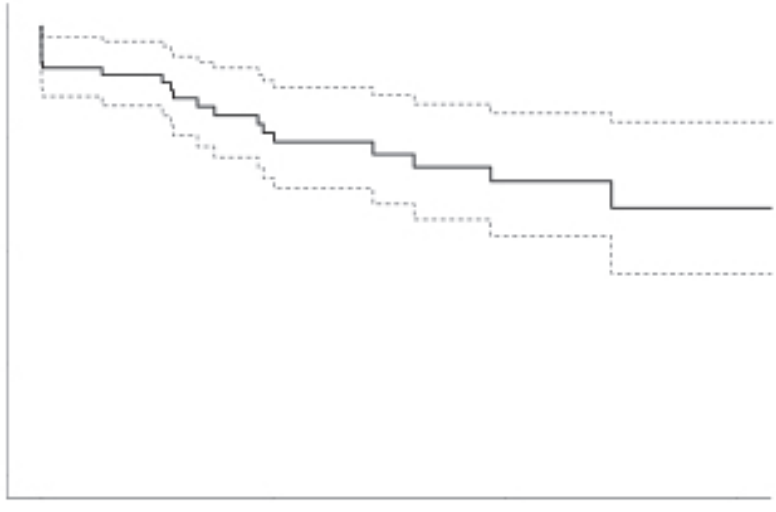

Kaplan–Meier curve of overall survival with 95% confidence interval.

DISCUSSION

The decision on valve prosthesis is complex, especially in younger patients, but essentially comes down to a bioprosthesis versus a mechanical prosthesis. However, within bioprostheses, there still are several options. Stented valves with or without vascular graft, stentless valves or stentless roots, homografts and the Ross procedure all offer a biological, but still very different, solution to treat aortic valve and root disease. This makes the choice between a biological and mechanical prosthesis not as straightforward as it would seem.

Our centre was one of the first to use the currently discussed Freestyle prosthesis. Based on our experience over the past 25 years, the haemodynamic and structural advantages of this prosthesis have led to its use in younger patients. This study describes the perioperative risks of the main disadvantage of this prosthesis: reinterventions.

All bioprostheses have the disadvantage of limited durability, especially in younger patients. Patients aged 50 years who undergo a stentless bioprosthetic aortic root replacement have ~23% probability of requiring reintervention at 15 years [7], compared to ~8% after mechanical-valved prostheses [8]. The longer durability of mechanical prostheses, however, comes at the cost of a higher life-time risk of thromboembolism and bleeding events (33% for mechanical prostheses vs 17% for bioprostheses) [8, 9]. Whether the benefits of mechanical prostheses outweigh those of bioprostheses therefore largely depends on the risks of reintervention after bioprosthetic AVR. If these can be performed with minimal mortality and morbidity, the use of bioprostheses in younger patients may be justified. Earlier series on reoperations after stentless AVR report high mortality rates of 10–20%, thus perhaps not justifying stentless AVR in young patients [4, 10, 11]. However, the more recent experience in this series with zero mortality in the latest 28 consecutive patients reoperated on for SVD may change this perspective. Another recent paper by Yang *et al.* [12] in 143 consecutive patients reported an reoperative early mortality rate of 2% after primary Freestyle AVR. It seems that in valve centres with a vast experience in reoperative aortic root replacement, these procedures can be performed safely. Therefore, young patients with a strong preference for a bioprosthesis should not be declined this option. It has been suggested by a previous studies that the higher risk of reintervention compared

with primary surgery may not be related to the procedure itself, but rather to patient characteristics [13, 14]. In our series, 2 of 7 early deaths were reoperated on for prosthetic valve endocarditis and 2 patients were among the first to undergo ViV-TAVR. Another patient died after a fifth operation with double valve replacement and coronary artery bypass surgery.

Although not mentioned in the most recent European guidelines on valvular interventions [15], the Ross procedure offers a good alternative for patients who want a biological solution for their aortic valve disease, with long event-free survival [16]. However, this procedure is restricted to experienced centres and, therefore, not available to a large population of patients.

Considerations in surgical reinterventions

FR replacement is often required in redo-AVR after previous Freestyle implantation, even in patients with SC implanted prostheses. As SC and RI implanted prostheses have grown into the native aortic root wall and annulus at the time of reintervention, complete resection of the prosthesis without damaging the native wall or annulus is often impossible. This results in either a lacerated annulus or an inadequate remaining diameter at the level of the annulus, necessitating root replacement. However, in these patients, root replacement often is straightforward as adhesions around the native root are generally mild. True redo root replacements (i.e. after previous root replacement), on the other hand, are more challenging. The prosthetic stentless root is almost always calcified. Calcifications around the coronary artery buttons can be problematic, as the remaining rim of supple tissue can be very small after excision from the calcified prosthetic wall. Therefore, during primary root replacement with a Freestyle prosthesis, a sufficiently large rim of native aortic wall should be left on the coronary artery buttons to facilitate re-excision and reimplantation during redo surgery. This is especially important in younger patients, as they have a higher lifetime probability of requiring redo surgery.

An alternative for reintervention after root replacement is a sutureless valve-in-root procedure, provided that an adequately large annulus remains after resection of the prosthetic valve leaflets. This procedure reduces cross-clamping times considerably. In this series, only 1 patient underwent a sutureless valve-in-root procedure in a calcified RI implanted Freestyle prosthesis.

All but 2 patients who were reoperated on for endocarditis received a stentless bioprosthesis in this series. Surgical considerations in this group of patients have been reported previously [17].

Considerations in valve-in-valve transcatheter aortic valve replacement

The mode of failure in degenerated Freestyle prostheses is predominantly leaflet tear, especially in FR implanted prostheses [7]. Although the prosthetic root is often calcified, providing an anchoring point for TAVR prostheses, they often lose their sinus shape and become a straight tube, increasing the chance of coronary obstruction by prosthetic valve leaflets during ViV-TAVR. Partly because of this, we have refrained from ViV-TAVR in the Freestyle prosthesis after FR replacement. In SC implanted Freestyle prostheses, the prosthetic leaflets calcify more often and provide anchoring points for TAVR prostheses. However, coronary obstruction may still occur due to the position of the implanted Freestyle prosthesis (which might be closer to the coronary ostia than the native leaflets) and the absence of prosthesis struts that limit lateral displacement of the prosthetic leaflets [18]. The absence of radio-opaque markers in the Freestyle prosthesis makes it especially difficult to determine the correct position of the transcatheter valve. In our practice, we inject contrast dye into the aortic root during rapid pacing in order to identify the location of the prosthesis leaflets to guide valve deployment on fluoroscopy, adding 3-dimensional transoesophageal echocardiographic imaging.

Coronary obstruction, a severe complication often associated with a fatal outcome, occurred in 2 of 8 patients who underwent ViV-TAVR, both after primary SC implantation. The European Society of Cardiology/European Association of Cardiovascular Surgery guidelines state that a low coronary height favours surgical AVR over TAVR [15]. Although no minimum height is defined, a minimal distance of 10–14 mm has been suggested for TAVR in native valves [19, 20]. Conzelmann *et al*. [21] reported on TAVR in patients with a low coronary height of <7 mm. Out of the 10 patients after ViV-TAVR in their study, 2 had coronary obstruction, and the early mortality rate was 30%. Sang *et al*. [22] reported their experience with ViV-TAVR in 22 degenerated Freestyle prostheses, with no early mortality. One patient required stenting of the LCA because of obstruction. In our series, both cases of coronary obstruction occurred with a balloon-expandable valve. The

resulting high early mortality rate after ViV-TAVR in this series, however, should be interpreted in relation to the low number of ViV procedures in this particular patient population and the limited early experience at that time. Periprocedural management has been adapted to decrease the risk of coronary obstruction. Preprocedural computed tomography scanning is performed to assess the height of the coronary ostia relative to the aortic prosthesis annulus, the height of the stentless valve leaflets and the sinus wall shape. In patients considered at increased risk for coronary obstruction, a valvuloplasty balloon is inflated prior to valve implantation to detect possible coronary obstruction. In that case, the ViV procedure is aborted and the patient is scheduled for conventional reoperation if eligible. Periprocedural extracorporeal membrane oxygenation support during ViV-TAVR is not routinely used in our institution. The risk of coronary obstruction may also be decreased by using transcatheter prostheses that anchor the prosthetic valve leaflets to the transcatheter valve [23].

Limitations

Different primary implantation techniques of the stentless valve and different indications for reoperation make this a heterogeneous series. The low number of patients and events limit the possibility for risk factor analysis.

CONCLUSION

The incidence of repeat aortic valve interventions, both surgical and transcatheter in nature, after stentless AVR will increase because of the growing use of bioprostheses to replace the aortic valve or root in younger patients together with an increase in life expectancy in general. Although reinterventions have an increased early mortality rate, especially in more severe pathology, this study shows that elective redo surgery after primary stentless AVR can be performed with acceptable risks and complication rates. While aortic root replacement is often required, also in patients who did not undergo initial root replacement, this more extensive surgery did not lead to an increased mortality rate compared to surgical and transcatheter AVR. Transcatheter ViV procedures after stentless AVR require careful consideration of prosthesis leaflet position relative to coronary ostia position to prevent obstruction of coronary arteries. Although bioprostheses are not optimal in young patients due to the higher lifetime probability of

reinterventions, the risks of these reinterventions do not preclude their use in young patients with a strong preference for a biological solution to treat their aortic valve disease.

FUNDING

This work was supported by an unrestricted research grant from Medtronic Inc., Minneapolis, MN, USA.

Conflict of interest: Robert J.M. Klautz is consultant for Medtronic Inc. All other authors declared no conflict of interest.

REFERENCES

1. Bach DS, Kon ND. Long-Term Clinical Outcomes 15 Years After Aortic Valve Replacement With the Freestyle Stentless Aortic Bioprosthesis. The Annals of Thoracic Surgery 2014;97:544–51. doi:10.1016/j.athoracsur.2013.08.047.

2. Mohammadi S, Tchana-Sato V, Kalavrouziotis D, Voisine P, Doyle D, Baillot R, et al. Long-term clinical and echocardiographic follow-up of the Freestyle stentless aortic bioprosthesis. Circulation 2012;126:S198–204. doi:10.1161/CIRCULATIONAHA.111.084806.

3. Isaacs AJ, Shuhaiber J, Salemi A, Isom OW, Sedrakyan A. National trends in utilization and in-hospital outcomes of mechanical versus bioprosthetic aortic valve replacements. The Journal of Thoracic and Cardiovascular Surgery 2015;149:1262–3. doi:10.1016/j.jtcvs.2015.01.052.

4. Grubitzsch H, Zobel S, Christ T, Holinski S, Stangl K, Treskatsch S, et al. Redo procedures for degenerated stentless aortic xenografts and the role of valve-in-valve transcatheter techniques. Eur J Cardiothorac Surg 2017;51:653–9. doi:10.1093/ejcts/ezw397.

5. Akins CW, Miller DC, Turina MI, Kouchoukos NT, Blackstone EH, Grunkemeier GL, et al. Guidelines for reporting mortality and morbidity after cardiac valve interventions. The Journal of Thoracic and Cardiovascular Surgery 2008;135:732–8. doi:10.1016/j.jtcvs.2007.12.002.

6. Doty DB, Cafferty A, Kon ND, Huysmans HA, Krause AH, Westaby S. Medtronic Freestyle aortic root bioprosthesis: Implant techniques. Journal of Cardiac Surgery 1998;13:369–75.

7. Schneider AW, Putter H, Hazekamp MG, Holman ER, Bruggemans EF, Versteegh MIM, et al. Twenty-year experience with stentless biological aortic valve and root replacement: informing patients of risks and benefits. Eur J Cardiothorac Surg 2018;53:1272–8. doi:10.1093/ejcts/ezx478.

8. Korteland NM, Etnel JRG, Arabkhani B, Mokhles MM, Mohamad A, Roos-Hesselink JW, et al. Mechanical aortic valve replacement in non-elderly adults: meta-analysis and microsimulation. European Heart Journal 2017;38:3370–7. doi:10.1093/eurheartj/ehx199.

9. Etnel JRG, Huygens SA, Grashuis P, Pekbay B, Papageorgiou G, Roos-Hesselink JW, et al. Bioprosthetic Aortic Valve Replacement in Nonelderly Adults: A Systematic Review, Meta-Analysis, Microsimulation. Circulation: Cardiovascular Quality and Outcomes 2019;12:e005481. doi:10.1161/CIRCOUTCOMES.118.005481.

10. Borger MA, Prasongsukarn K, Armstrong S, Feindel CM, David TE. Stentless aortic valve reoperations: a surgical challenge. The Annals of Thoracic Surgery 2007;84:737–43–discussion743–4. doi:10.1016/j.athoracsur.2007.04.061.

11. Böning A, Niemann B, Ennker I, Richter M, Roth P, Ennker J. Are aortic valve reoperations after primary replacement with stentless heart valve prostheses more demanding than after stented biological prostheses? Thorac Cardiovasc Surg 2014;62:475–81. doi:10.1055/s-0034-1371697.

12. Yang B, Patel HJ, Norton EL, Debenedictus C, Farhat L, Wu X, et al. Aortic Valve Reoperation After Stentless Bioprosthesis: Short- and Long-Term Outcomes. The Annals of Thoracic Surgery 2018;106:521–5. doi:10.1016/j.athoracsur.2018.02.073.

13. Berretta P, Di Marco L, Pacini D, Cefarelli M, Alfonsi J, Castrovinci S, et al. Reoperations versus primary operation on the aortic root: a propensity score analysis. Eur J Cardiothorac Surg 2017;51:322–8. doi:10.1093/ejcts/ezw250.

14. Jassar AS, Desai ND, Kobrin D, Pochettino A, Vallabhajosyula P, Milewski RK, et al. Outcomes of aortic root replacement after previous aortic root replacement: the "true" redo root. The Annals of Thoracic Surgery 2015;99:1601–8–discussion1608–9. doi:10.1016/j.athoracsur.2014.12.038.

15. Baumgartner H, Falk V, Bax JJ, De Bonis M, Hamm C, Holm PJ, et al. 2017 ESC/EACTS Guidelines for the management of valvular heart disease: The Task Force for the Management of Valvular Heart Disease of the European Society of Cardiology (ESC) and the European Association for Cardio-Thoracic Surgery (EACTS). European Heart Journal 2017. doi:10.1093/eurheartj/ehx391.

16. Schneider AW, Putter H, Klautz RJM, Bruggemans EF, Holman ER, Bökenkamp R, et al. Long-Term Follow-Up After the Ross Procedure: A Single Center 22-Year Experience. The Annals of Thoracic Surgery 2017;103:1976–83. doi:10.1016/j.athoracsur.2016.11.064.

17. Schneider AW, Hazekamp MG, Versteegh MIM, Bruggemans EF, Holman ER, Klautz RJM, et al. Stentless bioprostheses: a versatile and durable solution in extensive aortic valve endocarditis. Eur J Cardiothorac Surg 2016;49:1699–704. doi:10.1093/ejcts/ezv463.

18. Dvir D, Leipsic J, Blanke P, Ribeiro HB, Kornowski R, Pichard A, et al. Coronary obstruction in transcatheter aortic valve-in-valve implantation: preprocedural evaluation, device selection, protection, and treatment. Circ Cardiovasc Interv 2015;8:e002079–9. doi:10.1161/CIRCINTERVENTIONS.114.002079.

19. Masson J-B, Kovac J, Schuler G, Ye J, Cheung A, Kapadia S, et al. Transcatheter aortic valve implantation: review of the nature, management, and avoidance of procedural complications. JACC Cardiovasc Interv 2009;2:811–20. doi:10.1016/j.jcin.2009.07.005.

20. Holmes DR, Mack MJ, Kaul S, Agnihotri A, Alexander KP, Bailey SR, et al. 2012 ACCF/AATS/SCAI/STS expert consensus document on transcatheter aortic valve replacement. Journal of the American College of Cardiology 2012;59:1200–54. doi:10.1016/j.jacc.2012.01.001.

21. Conzelmann LO, Würth A, Schymik G, Schröfel H, Anusic T, Temme S, et al. Feasibility of transcatheter aortic valve implantation in patients with coronary heights ≤7 mm: insights from the transcatheter aortic valve implantation Karlsruhe (TAVIK) registry. Eur J Cardiothorac Surg 2018;54:752–61. doi:10.1093/ejcts/ezy130.

22. Sang SLW, Beute T, Heiser J, Berkompas D, Fanning J, Merhi W. Early Outcomes for Valve-in-valve Transcatheter Aortic Valve Replacement in Degenerative Freestyle Bioprostheses. Semin Thorac Cardiovasc Surg 2018;30:262–8. doi:10.1053/j.semtcvs.2017.11.001.

23. Silaschi M, Treede H, Rastan AJ, Baumbach H, Beyersdorf F, Kappert U, et al. The JUPITER registry: 1-year results of transapical aortic valve implantation using a second-generation transcatheter heart valve in patients with aortic stenosis. Eur J Cardiothorac Surg 2016;50:874–81. doi:10.1093/ejcts/ezw170.



SUMMARY AND FUTURE PERSPECTIVES

CHAPTER 9

This thesis addresses long-term clinical outcomes after biological aortic root replacement focusing on stentless prostheses. Stentless prostheses have the advantage of a large effective orifice area, providing optimal hemodynamics. Which type of prosthesis is ideal for which patient, however, depends on several factors, such as age and comorbidities. In this thesis, outcomes after aortic root replacement with the use the pulmonary autograft and the Freestyle stentless bioprosthesis are presented. The data presented in this thesis can be used to guide prosthesis choice.

In ***Chapter 1,*** the spectrum of aortic valve and root pathology is introduced, and surgical treatments are described. The development, anatomy, morphology and dynamics of the aortic valve and root are discussed in detail. The complex relationship between the different parts which form the aortic valve apparatus is illustrated. Proper function of the valve relies on each of these parts are functioning optimally. Diastolic stress on the valve leaflets in a normal aortic root is shared with the aortic root wall. This may implicate increased valvular stress on prostheses that do not replace the complete root, or composite prostheses consisting of a (stented) valve prosthesis inside a vascular tube graft. The etiology and natural history of aortic valve disease in children and adults are discussed, as well as the several treatment options currently available.

Aortic valve disease in young children is mostly congenital. Severe congenital aortic stenosis can be accompanied by left ventricular outflow tract obstruction (LVOTO) due to underdevelopment of the outflow tract and myocardial hypertrophy. Often, these patients have other cardiac anomalies. The amount of hypoplasia of the left ventricle determines whether a biventricular correction is possible, or if there is need for a univentricular palliation. In case biventricular correction is feasible, the LVOTO needs to be relieved and the underdeveloped aortic valve and root need to be replaced. As prosthetic valves have fixed sizes, they are incapable of growing with the child. In these patients, the patients' own pulmonary valve can be used to replace the aortic valve, as this is capable of somatic growth. Furthermore, the LVOTO can be relieved by incising the interventricular septum. Outcomes after this so-called 'Ross-Konno' procedure in 48 patients are discussed in ***Chapter 2.***

The median age of the study population was 12.8 months, with 46% of patients under 1 year of age. The vast majority of patients (92%) had undergone 1 or more previous cardiac interventions. The high risk of the Ross-Konno procedure

was demonstrated by an early mortality rate of 12.5%. A poor LV function, as an expression of severity of hypoplasia, was an independent risk factor for early mortality. Median follow-up time of the patient cohort was 4.3 years (range, 0 to 20 years). Reoperation for autograft failure was necessary in 5 patients at a median age of 14 years after the Ross-Konno procedure, mostly for autograft dilatation and concurrent regurgitation. Freedom from all-cause reoperation at 10- and 15 years was 55% and 33%, respectively. Most reoperations were necessary for degeneration or size mismatch of the right-sided conduit.

The results described in Chapter 2 show that the Ross-Konno procedure is a durable solution for multilevel LVOTO in a highly complex patient population. The high early mortality rates in patients with impaired left ventricular function, however, emphasize the importance of patient selection. Reoperation for autograft failure may occur late after the Ross-Konno procedure.

In young patients with aortic valve disease without underdevelopment of the left ventricle, surgery can often be postponed to later in life, for example by dilating a stenotic valve using balloon valvuloplasty. Furthermore, congenital aortic valve disease may first present itself during (young) adulthood. In these patients, the pulmonary autograft can be used to replace the aortic valve, without the need for left ventricular outflow tract augmentation, i.e. the Ross procedure. As shown in Chapter 2, autograft dilatation may necessitate reintervention on the pulmonary autograft in time. In ***Chapter 3*** outcomes after both the Ross, and the Ross-Konno procedure are reported, focusing on autograft function during long-term follow-up, analyzed using a competing risks model.

Data on 154 patients who underwent the Ross (n=105) and Ross-Konno (n=49) procedure was analyzed. There were 8 (5%) early deaths, 6 of whom underwent the Ross-Konno procedure, and 10 (7%) late deaths. Survival rates at 15 years were 86% in the total cohort and 91% in the isolated Ross subgroup. Cumulative incidences of all cause reoperation at 15 and 20 years were 35.2% and 45.3%, respectively. Twenty-six patients needed autograft reoperation, 20 due to dilatation. Cumulative incidences of autograft reoperation at 15 and 20 years were 20.1% and 31.1%, respectively.

The data presented in Chapter 3 shows that the Ross procedure can be performed safely in young patients with low number of valve related events. Autograft

function remains stable in the first decade after surgery, but autograft dilatation in the second decade necessitates reintervention.

As shown in Chapters 2 and 3, dilatation of the pulmonary autograft may necessitate reintervention during (long-term) follow-up. In ***Chapter 4*** a surgical technique in which the autograft is reinforced in order to prevent late dilatation of the autograft wall is presented. After harvesting, the pulmonary autograft is reimplanted in a vascular tube graft, scalloping all three sinus walls. This technique makes autograft regurgitation due to dilatation of the sinus walls impossible, potentially lengthening the durability of the pulmonary autograft. This technique, however, is only possible in fully grown patients, as it deprives the capability of growth of the autograft with somatic growth of the patient.

Several stentless bioprostheses are currently available to replace the aortic valve and root. The Freestyle stentless bioprosthesis has been available since 1992. In ***Chapter 5*** long-term outcomes after the use of this prosthesis are described. Furthermore, a competing risks regression model was constructed to provide predictive data on the expected clinical trajectory after aortic valve and root replacement using this prosthesis

Data on 604 patients operated on between 1993 and 2014 were collected both retrospectively and prospectively. This chapter shows that the Freestyle prosthesis can be used safely to replace the aortic valve and root, demonstrated by the decline in early mortality rates over the years, with no early mortality in elective, isolated root replacement surgery during the last 5 years of the study period. Competing risks regression identified patients' age, renal function, and implantation technique of the bioprosthesis as significant risk factors for death (age, renal function) and the development of structural valve deterioration (age, implantation technique). Full root replacement and increasing age were protective for structural valve deterioration. The cumulative incidences of structural valve deterioration at 15 years ranged from 36% in patients with maximum risk factors (young, poor renal function, subcoronary implanted prostheses) to 4% in patients >70 years of age with a good renal function who underwent full-root replacement.

Chapter 5 shows that the Freestyle prosthesis is a valuable option in patients with an indication for aortic root replacement. The predictive data presented in this chapter can be used to fully inform patients on the expected (individualized)

clinical trajectory after implantation of this prosthesis, aiding the shared decision making process of prosthetic valve choice.

The previous chapter showed good performance of the Freestyle prosthesis in a wide variety of patients. In ***Chapter 6,*** the use of this prosthesis in the specific setting of extensive (prosthetic) aortic valve infective endocarditis is addressed. Severe infective endocarditis of the aortic valve often extends into perivalvular structures, such as the aortic-mitral continuity and the roof of the left atrium, and to a lesser extent the membranous septum towards the right atrium, and the pulmonary valve. The cornerstone of treatment in infective endocarditis is the radical resection of all infected tissues. This necessitates, often complex, reconstruction of all resected structures. The pliable suture ring of the Freestyle prosthesis facilitates optimal implantation of the prosthesis in the reconstructed 'annulus'.

Fifty-four consecutive patients were analyzed, 29 of whom had prosthetic valve endocarditis and 13 had septic emboli prior to surgery. The early mortality rate was 11%, and estimated 5 year survival was 70%. There was no survival difference between native and prosthetic valve endocarditis. One patient underwent reoperation for recurrent endocarditis at 2.3 years after index surgery. Prosthesis function was good after a median follow-up time of 3.5 years.

Infective endocarditis of the aortic valve, extending into perivalvular structures is a life threatening condition requiring aggressive surgical debridement of all infected tissues and subsequent reconstruction. Chapter 5 shows that the Freestyle prosthesis is a valuable option in this specific setting. Although early mortality rates are high, demonstrating the severity of this disease, surgery is the only curative treatment available for these patients. Low incidences of recurrent endocarditis were seen in the studied patient population.

Their remains controversy about the preferred type of prosthesis to replace the aortic valve and root. Both biological and mechanical prostheses have their advantages. In short, bioprosthesis degenerate in time, but mechanical prostheses require anticoagulant treatment with all of its accompanying risks. In ***Chapter 7,*** outcomes after the use of both type of prostheses are presented. To make both patient groups comparable, the two groups were matched using propensity score matching.

Data on 117 patients who received a mechanical valved conduit were compared to 260 patients who received a Freestyle stentless bioprosthesis. Propensity score matching resulted in 103 matched pairs. Median age after matching was 65 years in both groups. A trend towards less valve related complications (thromboembolic- and bleeding events, reintervention, and valve related death combined) in the bioprosthetic group before matching was confirmed by a significant difference after matching. Furthermore, overall mortality in the patient group receiving a bioprosthesis was significantly lower compared to the patients who received a mechanical conduit. This difference was mainly ascribed to more sudden, unexplained deaths, which are likely to be due to fatal (cerebral) bleeding events due to anticoagulation treatment. Although the difference in incidence of reintervention on the prosthesis was not significantly different in this cohort, more reinterventions in the bioprosthetic group are to be expected with longer follow-up.

Chapter 7 shows that both mechanical and bioprosthetic aortic root replacement are feasible options. In the mid-term, bioprosthetic aortic root replacement is associated with less valve-related complications.

As previously mentioned, bioprostheses are subject to structural degeneration in time, often necessitating reintervention. With an increased use of bioprostheses, also in younger patients, it can be expected that reinterventions will be necessary more often in the coming years. In Chapter 8, an extensive overview of the risks associated with reinterventions after previous aortic valve or root replacement using the Freestyle bioprosthesis is presented.

A series of 75 patients after previous aortic valve or root replacement using a stentless bioprosthesis were analyzed. Median age was 62 years, and most patients needed reintervention due to structural degeneration of their prosthesis. Redo root replacement was the most common intervention (51 patients), followed by surgical AVR (16 patients) and transcatheter AVR (8 patients). The early mortality rate was 9.3%, and lowest in redo root replacement. After a learning curve, mortality in elective reoperations for SVD had zero mortality. Transcatheter reinterventions carry the risk of (often fatal) coronary obstruction. Chapter 8 shows that patient' characteristics, rather than the type of reintervention, contribute most to the risk of early death. Considerations in redo surgery, as well as in transcatheter valve-in-valve interventions are extensively discussed in Chapter 8.

Reinterventions after stentless aortic valve or root replacement carry an acceptable risk in the current era. Periprocedural risks are mostly determined by patient' characteristics. Transcatheter reinterventions require careful consideration of anatomic factors to minimize the risk of coronary obstruction.

FUTURE PERSPECTIVES

To date, no perfect prosthesis exists to replace a diseased aortic valve and root. All currently available prostheses have their advantages, but also their shortcomings. However, there are several developments to improve valve prostheses.

Mechanical prostheses

For mechanical prosthesis, the burden of anticoagulant treatment is the main disadvantage. Current developments are aimed to lower this burden by lowering the target International Normalized Ratio (INR). Current guidelines advice an INR of 3.0 – 3.5 for most modern mechanical prostheses [1]. Changes in valve design (e.g. smoother hinges) or improved endothelization of the valve leaflets might lower the target INR, lowering the risk of thromboembolic and bleeding complications [2,3]. However, it has to be awaited whether the anticoagulant burden accompanying mechanical prostheses can be lowered enough to increase their use in valvular heart disease.

Biological prostheses

For biological prostheses, new treatment methods are being developed to treat the valve tissue, aimed at decreasing the immunologic response and preventing calcification. Furthermore, structural alterations are made to better facilitate possible future valve-in-valve therapies by creating an expansion zone in the prosthesis, enabling larger sized transcatheter prostheses [4]. This could minimize the burden of reintervention after bioprosthetic valve failure.

Tissue engineering

In theory, tissue engineered heart valves (TEHV) are the ideal valve prosthesis. The goal of tissue engineering, is providing a living, competent valve, capable of continuous remodeling. Ideally, the valve should be capable of growth, expanding their use in young children. A three-dimensional scaffold is needed to

accommodate repopulation with the patients' own cells. The use of decellularized aortic and pulmonary homografts is currently being explored in the ARISE [5] and ESPOIR [6] trials, respectively, with promising early results.

Alternatives to existing valves, scaffolds can be created by molding or suturing biomaterials to a stent, electrospinning, 3D bioprinting, or a combination of these techniques [7]. Regardless of the technique used, scaffolds need to be, amongst others, biodegradable, non-immuno- and thrombogenic, capable of repopulation and mechanically robust [7]. Although the possibilities of THEV are exciting, many challenges have to be overcome before they can be routinely used clinically in the treatment of diseased heart valves.

Patient involvement

As mentioned, the ideal valve prosthesis still does not exist. Therefore, involving patients in the decision on type of prosthesis is of paramount importance. Different patients have different lifestyles and lifegoals, influencing this decision. In order to choose a certain type of prosthesis, patients should be fully informed on the available options, and the accompanying advantages and disadvantages. Wishes and expectations of the patient should be taken into account, and final prosthesis selection should be a shared decision between the patient and surgeon. The data presented in this thesis aid this shared-decision making process.

REFERENCES

1. Baumgartner H, Falk V, Bax JJ, De Bonis M, Hamm C, Holm PJ, et al. 2017 ESC/EACTS Guidelines for the management of valvular heart disease: The Task Force for the Management of Valvular Heart Disease of the European Society of Cardiology (ESC) and the European Association for Cardio-Thoracic Surgery (EACTS). European Heart Journal 2017. doi:10.1093/eurheartj/ehx391.

2. Frendl CM, Tucker SM, Khan NA, Esch MB, Kanduru S, Cao TM, et al. Endothelial retention and phenotype on carbonized cardiovascular implant surfaces. Biomaterials 2014;35:7714–23. doi:10.1016/j.biomaterials.2014.05.075.

3. Fallon AM, Shah N, Marzec UM, Warnock JN, Yoganathan AP, Hanson SR. Flow and thrombosis at orifices simulating mechanical heart valve leakage regions. J Biomech Eng 2006;128:30–9.

4. Puskas JD, Bavaria JE, Svensson LG, Blackstone EH, Griffith B, Gammie JS, et al. The COMMENCE trial: 2-year outcomes with an aortic bioprosthesis with RESILIA tissue. Eur J Cardiothorac Surg 2017;52:432–9. doi:10.1093/ejcts/ezx158.

5. Tudorache I, Horke A, Cebotari S, Sarikouch S, Boethig D, Breymann T, et al. Decellularized aortic homografts for aortic valve and aorta ascendens replacement. Eur J Cardiothorac Surg 2016;50:89–97. doi:10.1093/ejcts/ezw013.

6. Boethig D, Horke A, Hazekamp M, Meyns B, Rega F, Van Puyvelde J, et al. A European study on decellularized homografts for pulmonary valve replacement: initial results from the prospective ESPOIR Trial and ESPOIR Registry data†. European Journal of Cardio-Thoracic Surgery 2019;6:184.–7. doi:10.1093/ejcts/ezz054.

7. Cheung DY, Duan B, Butcher JT. Current progress in tissue engineering of heart valves: multiscale problems, multiscale solutions. Expert Opin Biol Ther 2015;15:1155–72. doi: 10.1517/14712598.2015.1051527.



NEDERLANDSE SAMENVATTING

CHAPTER 10

Dit proefschrift richt zich op de lange termijn uitkomsten na biologische aortawortelvervanging met de focus op protheses zonder stent. Stentloze protheses hebben als voordeel dat ze een groter effectief openingsoppervlakte hebben, wat zorgt voor een optimale hemodynamiek. Welke prothese het meest geschikt is voor welke patiënt hangt echter van verscheidene factoren af, waaronder leeftijd en comorbiditeit. In dit proefschrift worden uitkomsten na aortawortelvervanging middels de pulmonalis homograft en de Freestyle stentless bioprothese besproken. De resultaten van dit proefschrift kunnen worden gebruikt in het beslisproces omtrent welke prothese het meest geschikt is voor welke patiënt.

In ***Hoofdstuk 1*** wordt het spectrum van aortaklep- en -wortelpathologie geïntroduceerd en chirurgische therapieën besproken. De ontwikkeling, anatomie, morfologie en dynamiek van de aortaklep en -wortel worden in detail besproken. De complexe relatie tussen de verschillende onderdelen die gezamenlijk het aortaklep apparaat vormen wordt toegelicht. Een goede klepfunctie hangt af van het optimaal functioneren van al deze onderdelen. De diastolische belasting van de klepblaadjes wordt in een normale aortawortel gedeeld met de aortawand. Dit impliceert dat de belasting van klepprotheses die niet de gehele aortawortel vervangen, en als gevolg de druk niet delen met de aortawand, onder grotere belasting staan. De etiologie en het natuurlijk beloop van aortaklep aandoeningen in kinderen en volwassenen wordt besproken, en verschillende behandelingen worden toegelicht.

Aortaklep aandoeningen in jonge kinderen is doorgaans aangeboren. Ernstige aangeboren aortaklepstenose kan worden vergezeld door obstructie van de linker kamer uitstroombaan (LVOTO) door onvoldoende ontwikkeling van de uitstroombaan en hypertrofie van het myocard. Vaak gaat dit gepaard met andere cardiale afwijkingen. De ernst van de onderontwikkeling van de linker ventrikel bepaalt of er kan worden toegewerkt naar een biventriculaire correctie, dan wel naar univentriculaire palliatie. In het geval dat biventriculaire correctie mogelijk is dient de uitstroombaanobstructie te worden opgeheven en de onderontwikkelde aortaklep en -wortel te worden vervangen. De vaste maat van klepprotheses maakt deze ongeschikt om met het kind mee te groeien. In deze patiënten kan de eigen pulmonalisklep – wel in staat mee te groeien met het kind- worden gebruikt om de aortaklep te vervangen. Daarnaast kan de uitstroombaan worden verwijd

door het interventriculaire septum te incideren. De uitkomsten na deze "Ross-Konno" operatie worden beschreven in ***Hoofdstuk 2.***

De mediane leeftijd van de studiepopulatie was 12.8 maanden, waarvan 46% minder dan een jaar oud was. De grote meerderheid (92%) had reeds 1 of meerdere cardiale interventies ondergaan. De 12.5% vroege sterfte in dit cohort toonde het hoge risico van de Ross-Konno procedure. Een slechte linkerkamerfunctie, als uiting van ernstige onderontwikkeling, was een onafhankelijke risicofactor voor vroege sterfte. De mediane follow-up tijd was 4.3 jaar (bereik, 0 tot 20 jaar). Reoperaties wegens falen van de autograft was nodig in 5 patiënten na een mediane duur van 14 jaar na de Ross-Konno procedure, met name wegens dilatatie van de autograft met bijkomende lekkage. Vrijheid van alle reoperaties na 10 en 15 jaar was respectievelijk 55% en 33%. De meeste reoperaties waren wegens degeneratie of niet meer passen van de rechtszijdige prothese.

De resultaten beschreven in Hoofdstuk 2 laten zien dat de Ross-Konno operatie een duurzame oplossing kan bieden voor uitgebreide uitstroombaanobstructie in een hoog-complexe patiëntengroep. De hoge vroege sterfte in patiënten met een verminderde kamerfunctie benadrukt het belang van goede patiëntenselectie. Reoperaties vanwege falen van de autograft kan op de lange termijn voorkomen.

In jonge patiënten met aortaklep aandoeningen met een normaal ontwikkelde linker ventrikel kan chirurgisch ingrijpen doorgaans worden uitgesteld tot later in het leven, bijvoorbeeld door ballondilatatie van een stenotische klep. Daarnaast presenteren aangeboren hartklepafwijkingen zich regelmatig pas in de adolescentie. In deze patiënten kan de pulmonalisklep worden gebruikt om de aortaklep te vervangen, zonder daarbij de uitstroombaan te hoeven verwijden. Zoals in hoofdstuk 2 beschreven, kan dilatatie van de autograft leiden tot reoperaties later in het leven. In ***Hoofdstuk 3*** worden uitkomsten na zowel de Ross als Ross-Konno operatie beschreven, met nadruk op autograftfunctie op de lange termijn, geanalyseerd middels concurrerend risico ("competing-risks") modellen.

Data van 154 patiënten die de Ross (n=105) dan wel Ross-Konno (n=49) operatie ondergingen werd geanalyseerd. Er waren 8 (5%) vroege sterftes, waarvan 6 de Ross-Konno procedure ondergingen, en 10 (7%) late sterftes. Na 15 jaar was 86% van het totale cohort en 91% van de Ross subgroep nog in leven. De cumulatieve incidentie van reoperatie na 15 en 20 jaar was respectievelijk 35.2% en 45.3%.

Zesentwintig patiënten moesten worden gereopereerd aan de autograft, waarvan 20 wegens dilatatie. De cumulatieve incidentie van autograft reoperatie na 15 en 20 jaar was respectievelijk 20.1% en 31.1%.

De data beschreven in Hoofdstuk 3 laat zien dat de Ross procedure veilig kan worden verricht in jonge patiënten met een laag aantal klepgerelateerde events. De functie van de pulmonalis autograft blijft het eerste decennium stabiel, echter maakt autograft dilatatie in het tweede decennium reoperatie noodzakelijk.

Zoals beschreven in Hoofdstukken 2 en 3 leidt dilatatie van de pulmonalis autograft tot reinterventie op de lange termijn. In ***Hoofdstuk 4*** wordt een chirurgische techniek beschreven waarbij de autograft wordt verstevigd om deze dilatatie op termijn te voorkomen. Na het vrijmaken van de autograft uit het hart wordt deze gereimplanteerd in een vaatprothese, waarbij de wanden van de sinussen worden getrimd. Deze techniek maakt lekkage van de autograft door dilatatie onmogelijk, waardoor het lange termijn functioneren van de autograft mogelijk wordt verbeterd. Door het fixeren van de autograft in een buisprothese wordt echter de mogelijkheid van de autograft om met een kind mee te groeien ontnomen, waardoor deze techniek alleen geschikt is voor volgroeide patiënten.

Momenteel zijn er verschillende stentloze bioprotheses beschikbaar die gebruikt kunnen worden om de aortaklep en -wortel te vervangen. De Freestyle stentloze bioprothese is beschikbaar sinds 1992. In ***Hoofdstuk 5*** worden lange-termijnuitkomsten na het gebruik van deze prothese beschreven. Daarnaast is er een concurrerende-risico regressie model gemaakt, waarmee voorspellende data omtrent het te verwachten beloop na gebruik van deze prothese kan worden geconstrueerd.

Data van 604 patiënten, geopereerd tussen 1993 en 2014 werd zowel retrospectief als prospectief verzameld. Dit hoofdstuk laat zien dat de Freestyle prothese veilig kan worden gebruikt om de aortaklep en -wortel te vervangen, met afname van de vroege sterfte in de laatste jaren van dit cohort. Het regressiemodel identificeerde leeftijd, nierfunctie en implantatietechniek als significante risicofactoren voor overlijden (leeftijd en nierfunctie) en voor het ontwikkelen van structureel klepfalen (leeftijd en implantatietechniek). De cumulatieve incidenties van structureel klepfalen 15 jaar na operatie reikten van 36% in patiënten met maximaal aantal risicofactoren (jong, slechte nierfunctie en subcoronaire

implantatietechniek) tot 4% in patiënten ouder dan 70 met een goede nierfunctie die een aortawortelvervanging ondergingen.

Hoofdstuk 5 laat zien dat de Freestyle prothese een waardevolle optie biedt voor patiënten die een aortawortelvervanging nodig hebben. De voorspellende data die in dit hoofdstuk gepresenteerd wordt kan bijdragen aan het volledig informeren van patiënten over het te verwachten (geindividualiseerde) klinische traject na implantatie van deze prothese. Dit draagt bij aan de gezamenlijke klepkeuze tussen patiënt en chirurg.

Het vorige hoofdstuk liet goede resultaten van de Freestyle prothese zien in een diverse patiëntenpopulatie. In ***Hoofdstuk 6*** wordt het gebruik van deze prothese in de context van uitgebreide aortaklep (-prothese) endocarditis geadresseerd. Ernstige aortaklependocarditis breidt zich regelmatig uit naar de perivalvulaire structuren, zoals de aorto-mitrale overgang en het dak van het linker atrium. Zeldzamer is uitbreiding naar het membraneuze septum richting het rechter atrium, en naar de pulmonalisklep. De hoeksteen van de behandeling van endocarditis is de resectie van ál het geïnfecteerde weefsel. Dit noodzaakt vaak complexe reconstructie van de verwijderde structuren. De flexibele hechtring van de Freestyle prothese maakt dat deze goed te implanteren is in een gereconstrueerde 'annulus'.

Vierenvijftig achtereenvolgende patiënten werden geanalyseerd, waarvan 29 patiënten een prothese-endocarditis hadden en 13 patiënten reeds septische embolieën voorafgaand aan chirurgie. Er was 11% vroege sterfte en de geschatte 5-jaarsoverleving was 70%. Er was geen verschil in overleving tussen natieve en prothese-endocarditis. Één patiënt onderging reoperatie voor opnieuw opgetreden endocarditis, 2.3 jaar na de eerdere operatie. De functie van de prothese was goed na een mediane follow-up van 3.5 jaar.

Endocarditis van de aortaklep die uitbreidt naar de omliggende weefsels is een levensbedreigende aandoening die agressieve chirurgische resectie van ál het geïnfecteerde weefsel, gevolgd door reconstructie vereist. Hoofdstuk 5 laat zien dat de Freestyle prothese een waardevolle optie is in deze specifieke context. Hoewel hoog risico, aangetoond door de vroege sterfte, is chirurgie de enige genezende optie in deze patiëntengroep. Recidief endocarditis trad in dit cohort nauwelijks op.

Er bestaat controverse over wat de beste prothese is om een aortaklep (en -wortel) te vervangen. Zowel biologische als mechanische protheses hebben hun voor- en nadelen. Samenvattend, bioprotheses slijten met de tijd, maar voor mechanische protheses is levenslange antistolling noodzakelijk, met alle risico's van dien. In ***Hoofdstuk 7*** worden de resultaten na gebruik van beide protheses besproken. Propensity-score matching is toegepast om beide groepen vergelijkbaar te maken.

Data over 117 patiënten die een mechanische prothese hebben ontvangen werd vergelijkt met data over 260 patiënten met Freestyle stenloze bioprothese. Propensity-score matching resulteerde in 103 gekoppelde paren. De mediane leeftijd na matchen was 65 jaar in beide groepen. Voor matchen leken er minder klepgerelateerde complicaties (trombo-embolie, bloeding, reinterventie en klepgerelateerde sterfte) voor te komen in de biologische groep, en dit verschil werd statistisch significant na matchen. Daarnaast was de algehele sterfte in de biologische groep significant lager ten opzichte van de sterfte in de mechanische groep. Dit verschil werd met name veroorzaakt door plotselinge, onverklaarde sterftes, welke mogelijk toe te schrijven zijn aan (cerebrale) bloedingscomplicaties van de antistolling in de mechanische groep. Hoewel de incidentie van reoperaties niet significant verschilde is te verwachten dat met langere follow-up het aantal reoperaties met name in de biologische groep zal toenemen.

Hoofdstuk 7 laat zien dat zowel biologische als mechanische prothese goede opties zijn om de aortawortel te vervangen. Op de middellange-termijn is het gebruik van biologische protheses geassocieerd met minder klepgerelateerde complicaties.

Zoals eerder genoemd zijn bioprotheses onderhevig aan structurele slijtage in de tijd, vaak leidend tot reinterventies. Met een toename van het gebruik van bioprotheses, ook in jongere patiënten, is de verwachting dat het aantal reinterventies zal toenemen in de komende jaren. In ***Hoofdstuk 8*** wordt een uitgebreid overzicht gepresenteerd van de risico's van reinterventies na aortaklep of -wortelvervanging met een Freestyle bioprothese.

Een serie van 75 patiënten werd geanalyseerd. De mediane leeftijd was 62 jaar en de meerderheid van de patiënten moest een reinterventie ondergaan wegens structureel klepfalen. Re-aortawortelvervanging was de meest uitgevoerde procedure (51 patiënten), gevolgd door chirurgische AVR (16 patiënten) en transcatheter AVR (8 patiënten). De vroege sterfte bedroeg 9.3% en was het laagst

na re-aortawortelvervanging. Na een leercurve bedroeg trad er geen vroege sterfte meer op in de electieve chirurgisch reoperaties. Transcatheter technieken hebben het risico van, vaak lethale, obstructie van de coronairarteriën. Hoofdstuk 8 laat zien dat patientkarakteristieken meer bijdrage aan het risico op sterfte dan het type reinterventie. Overwegingen voor zowel reoperaties als voor transcatheter klep-in-klep interventies worden uitgebreid besproken in hoofdstuk 8.

Reinterventies na aortaklep of -wortelvervanging met een stentloze bioprothese hebben in de huidige tijd een acceptabel risico. Het periprocedurele risico wordt met name bepaald door patientkarakteristieken. Om het risico op coronairobstructie tijdens transcathetertechnieken zo laag mogelijk te houden dienen anatomische factoren nauwkeurig in acht te worden genomen.

TOEKOMSTPERSPECTIEVEN

Tot op heden bestaat er geen perfecte prothese om een aangetaste aortaklep en -wortel te vervangen. Alle momenteel beschikbare protheses hebben zowel hun voordelen als tekortkomingen. Er zijn echter verschillende ontwikkelingen gaande om de protheses te verbeteren.

Mechanische protheses

Het grootste nadeel van mechanische protheses is de noodzaak van antistolling. Huidige ontwikkelingen zijn erop gericht de last van deze antistollingsbehandeling te verlagen door lagere waarde van het 'International Normalied Ratio' (INR) na te streven. Huidige richtlijnen adviseren een streef INR van 2.5 – 3.0 voor de meeste moderne mechanische protheses. [1] Veranderingen in ontwerp (bijvoorbeeld soepelere scharnieren) of endothelialisatie van de klepbladen zouden kunnen leiden tot een lager streef INR waarmee het risico op trombo-embolieën en bloedingscomplicaties zou kunnen verminderen. [2,3] Echter, het valt nog te bezien of het lukt om de antistollingslast van mechanische protheses voldoende te verminderen om toename van hun gebruik te rechtvaardigen.

Biologische protheses

Nieuwe methodes worden ontwikkeld om het klepweefsel van biologische protheses dusdanig te behandelen dat er minder immuunreactie optreedt en calcificering wordt verminderd. Daarnaast worden structurele aanpassingen

gemaakt om eventuele toekomstige transcatheter klep-in-klep interventies beter te kunnen faciliteren, bijvoorbeeld door het maken van een expansiering in de prothese. [4] Deze ontwikkelingen zouden de levensduur van biologische protheses mogelijk kunnen verlengen en, indien slijtage toch optreedt, de impact van eventuele reinterventies kunnen verminderen.

Tissue engineering

Theoretisch zijn 'tissue engineered' hartkleppen (TEHV) de ideale protheses. Het doel van tissue engineering is een levende, competente klep te ontwikkelen, die zichzelf, net als een natieve klep, continue kan vernieuwen. Idealiter is de klep in staat te groeien, waardoor deze ook in kinderen gebruikt kan worden. Een driedimensionale mal is nodig, die vervolgens wordt bekleed en vervangen door eigen cellen van patiënten. Het gebruik van gedecellulariseerde aorta en pulmonalis homografts wordt momenteel onderzocht in de respectievelijk ARISE[5] en ESPOIR[6] studies, met veelbelovende vroege resultaten.

Als alternatief voor bestaande kleppen kan een mal ook worden gecreëerd door biomateriaal te fixeren aan een stent, 'electrospinning', 3D bioprinten, of een combinatie van voorgaande technieken. [7] Onafhankelijk van welke techniek wordt toegepast moeten de mallen, onder andere, biologisch afbreekbaar, niet thrombogeen, geschikt voor repopulatie met humane cellen en mechanisch robuust zijn. Daarnaast moeten ze geen immuunreactie opwekken. Hoewel de theoretische mogelijkheden van TEHV veelbelovend zijn, moeten er nog vele uitdagingen worden overkomen voordat ze routinematig kunnen worden toegepast in patiënten met hartklepaandoeningen.

Betrokkenheid van de patiënt

Zoals eerder aangegeven bestaat de ideale klepprothese nog steeds niet. Daarom is het van groot belang patiënten te betrekken in de klepkeuze. Verschillende patiënten hebben verschillende levensstijlen en verschillende doelen in het leven die elk deze beslissing beïnvloeden. Om in staat te zijn weloverwogen een type prothese te kunnen kiezen dienen patiënten volledig te worden geïnformeerd over de beschikbare opties en de bijbehorende voor- en nadelen. Wensen en verwachtingen van de patiënt dienen mee te worden gewogen, en de uiteindelijke prothese keuze hoort een gezamenlijk besluit te zijn tussen de patiënt en de chirurg. De data gepresenteerd in dit proefschrift helpen dit proces van klepkeuze.

REFERENTIES

1. Baumgartner H, Falk V, Bax JJ, De Bonis M, Hamm C, Holm PJ, et al. 2017 ESC/EACTS Guidelines for the management of valvular heart disease: The Task Force for the Management of Valvular Heart Disease of the European Society of Cardiology (ESC) and the European Association for Cardio-Thoracic Surgery (EACTS). European Heart Journal 2017. doi:10.1093/eurheartj/ehx391.

2. Frendl CM, Tucker SM, Khan NA, Esch MB, Kanduru S, Cao TM, et al. Endothelial retention and phenotype on carbonized cardiovascular implant surfaces. Biomaterials 2014;35:7714–23. doi:10.1016/j.biomaterials.2014.05.075.

3. Fallon AM, Shah N, Marzec UM, Warnock JN, Yoganathan AP, Hanson SR. Flow and thrombosis at orifices simulating mechanical heart valve leakage regions. J Biomech Eng 2006;128:30–9.

4. Puskas JD, Bavaria JE, Svensson LG, Blackstone EH, Griffith B, Gammie JS, et al. The COMMENCE trial: 2-year outcomes with an aortic bioprosthesis with RESILIA tissue. Eur J Cardiothorac Surg 2017;52:432–9. doi:10.1093/ejcts/ezx158.

5. Tudorache I, Horke A, Cebotari S, Sarikouch S, Boethig D, Breymann T, et al. Decellularized aortic homografts for aortic valve and aorta ascendens replacement. Eur J Cardiothorac Surg 2016;50:89–97. doi:10.1093/ejcts/ezw013.

6. Boethig D, Horke A, Hazekamp M, Meyns B, Rega F, Van Puyvelde J, et al. A European study on decellularized homografts for pulmonary valve replacement: initial results from the prospective ESPOIR Trial and ESPOIR Registry data†. European Journal of Cardio-Thoracic Surgery 2019;6:184.–7. doi:10.1093/ejcts/ezz054.

7. Cheung DY, Duan B, Butcher JT. Current progress in tissue engineering of heart valves: multiscale problems, multiscale solutions. Expert Opin Biol Ther 2015;15:1155–72. doi:10.1517/14712598.2015.1051527.



LIST OF PUBLICATIONS

DANKWOORD

CURRICULUM VITAE

CHAPTER 11

LIST OF PUBLICATIONS

Hazekamp MG, Schneider AW, Blom NA. Pulmonary Atresia with Intact Ventricular Septum. In: Da Cruz EM, Ivy D, Jaggers J, editors. Pediatric and Congenital Cardiology, Cardiac Surgery and Intensive Care, London: Springer London; 2014, pp. 1543–55. doi:10.1007/978-1-4471-4619-3_20.

Schneider AW, Blom NA, Bruggemans EF, Hazekamp MG. More than 25 years of experience in managing pulmonary atresia with intact ventricular septum. Ann Thorac Surg. 2014 Nov;98(5):1680-6. doi: 10.1016/j.athoracsur.2014.05.085.

Schneider AW, Hazekamp MG, Versteegh MI, Bruggemans EF, Holman ER, Klautz RJ, Braun J. Stentless bioprostheses: a versatile and durable solution in extensive aortic valve endocarditis. Eur J Cardiothorac Surg. 2016 Jun;49(6):1699-704. doi: 10.1093/ejcts/ezv463.

Tomšic A, Schneider AW, Palmen M, van Brakel TJ, Versteegh MIM, Klautz RJM. Extensive infective endocarditis of the aortic root and the aortic-mitral continuity: a mitral valve sparing approach†. Eur J Cardiothorac Surg. 2017 Jun 1;51(6):1100-1107. doi: 10.1093/ejcts/ezw445.

Schneider AW, Putter H, Klautz RJM, Bruggemans EF, Holman ER, Bökenkamp R, Hazekamp MG. Long-Term Follow-Up After the Ross Procedure: A Single Center 22-Year Experience. Ann Thorac Surg. 2017 Jun;103(6):1976-1983. doi: 10.1016/j.athoracsur.2016.11.064.

Schneider A, Klautz RJM, Hazekamp M. The Ross reimplantation technique. Multimed Man Cardiothorac Surg 2017;2017. doi:10.1510/mmcts.2017.019.

Schneider AW, Putter H, Hazekamp MG, Holman ER, Bruggemans EF, Versteegh MIM, Schalij MJ, Varkevisser RRB, Klautz RJM, Braun J. Twenty-year experience with stentless biological aortic valve and root replacement: informing patients of risks and benefits. Eur J Cardiothorac Surg. 2018 Jun 1;53(6):1272-1278. doi: 10.1093/ejcts/ezx478.

Schneider AW, Bökenkamp R, Bruggemans EF, Hazekamp MG. Twenty-year experience with the Ross-Konno procedure. Eur J Cardiothorac Surg. 2016 Jun;49(6):1564-70. doi: 10.1093/ejcts/ezv434.

Schneider AW, Hazekamp MG, Versteegh MIM, de Weger A, Holman ER, Klautz RJM, Bruggemans EF, Braun J. Reinterventions after freestyle stentless aortic valve replacement: an assessment of procedural risks. Eur J Cardiothorac Surg. 2019 Dec 1;56(6):1117-1123. doi: 10.1093/ejcts/ezz222.

Sibilio S, Koziarz A, Belley-Côté EP, McClure GR, MacIsaac S, Reza SJ, Um KJ, Lengyel A, Mendoza P, Alsagheir A, Alraddadi H, Gupta S, Schneider AW, Patel PM, Brown JW, Chu MWA, Peterson MD, Ouzounian M, Paparella D, El-Hamamsy I, Whitlock RP. Outcomes after Ross procedure in adult patients: A meta-analysis and microsimulation. J Card Surg. 2019 May;34(5):285-292. doi: 10.1111/jocs.14020.

Schneider AW, Klautz RJM, Hazekamp MG, Braun J. Reply to Böning. Eur J Cardiothorac Surg. 2019 May 1;55(5):1019-1020. doi: 10.1093/ejcts/ezy316.

Sojak V, Bökenkamp R, Kuipers I, Schneider A, Hazekamp M. Biventricular repair after the hybrid Norwood procedure. Eur J Cardiothorac Surg 2019;56:110–6. doi:10.1093/ejcts/ezz028.

DANKWOORD

Prof. dr. Braun, beste Jerry. In de afgelopen jaren heb ik onwijs veel van je geleerd en dat hoop ik de komende jaren te blijven doen. Daarnaast bied je een luisterend oor voor zowel professionele als persoonlijke kwesties. Veel dank daarvoor!

Prof. dr. Hazekamp, beste Mark. Door jou geïntroduceerd in de thoraxchirurgie, wat een begin! Ik waardeer je no-nonsense instelling en heb veel bewondering voor hoe je de kinderhartchirurgie vorm hebt gegeven.

Prof. dr. Klautz, beste prof, dank voor de kritische blik en sturing tijdens mijn promotie. Daarnaast dank voor het vertrouwen dat u in mij stelt. Ik heb veel respect voor de manier waarop u de thoraxchirurgische zorg continu probeert te verbeteren.

De overige stafleden van de afdeling thoraxchirurgie, dank voor jullie vertrouwen en de stimulerende omgeving die jullie creëren.

Beste collega (oud)assistenten en PA's, door de jaren heen hebben we vele zowel mooie als zware momenten meegemaakt. Dank voor de steun wanneer nodig en vooral ook de gezellige tijden!

Collega's van de omringende specialismen wil ik danken voor de prettige samenwerking. Een kritische blik van buiten houdt je scherp.

Drs. Voigt en drs. Bihariesingh, beste Pieter en Rosita, mijn tijd in het mooie Suriname zal me altijd bijblijven! Ik heb onwijs veel respect voor hoe jullie je inzetten voor de zorg in het land, zowel binnen de thoraxchirurgie, als ver daarbuiten. Veel dank voor alle lessen en voor het me zo welkom laten voelen. Mijn deur zal ook altijd voor jullie open staan. Mi kon baka!

Alle vrienden, huis- en clubgenoten, BIS collega's en allen die ik niet persoonlijk kan bedanken, dankzij jullie heb ik enorm veel mooie herinneringen. Ik hoop er nog vele met jullie te maken!

Anton en Bardia, bedankt dat jullie mijn paranimf willen zijn. Ik hoop nog vaak samen op boevenpad te gaan!

Lieve Kees, Yvonne, Willem en Elise, Salut I Força al Canut!

Lieve familie, een band zoals wij die hebben is niet vanzelfsprekend.

Lieve Tatiana en Natalie, betere zussen kan ik me niet wensen.

Mijn lieve ouders wil ik bedanken voor hun niet aflatende en onvoorwaardelijke liefde en steun. Ik ben heel blij met jullie.

Lieve Michèle, ik kijk uit naar onze toekomst samen!

CURRICULUM VITAE

Adriaan Schneider was born on 18 May 1989 in Alkmaar, The Netherlands. After graduating secondary school (Murmellius Gymnasium, Alkmaar) in 2007, he started his studies in Medicine at the Leiden University. During his studies, he worked from 2008 until 2016 as a chief retrieval officer at BISLIFE foundation, performing, and being responsible for the surgical retrieval of humane heart valve, bone, tendon and ocular tissues meant for post mortal donation and transplantation.

He obtained his medical degree in 2014 and worked from then until July 2017 as clinical researcher at the department of Cardiothoracic Surgery at Leiden University Medical Center under the supervision of prof. dr. R.J.M. Klautz, prof. dr. M.G. Hazekamp and prof. dr. J. Braun. During these years, the fundament of this thesis was built. From July 2017 until July 2019, he resumed his clinical work and worked as resident at the same department. From July 2019 he went abroad and worked for half a year as resident at the department of Cardiothoracic Surgery at the Academic Hospital Paramaribo, Suriname. During these months, he started developing his surgical skills under the supervision of Dr. P.G. Voigt. After returning to The Netherlands, he started his training in cardiothoracic surgery in January 2020 at the Leiden University Medical Center.