



Universiteit
Leiden
The Netherlands

Cardiovascular compromise in monochorionic twins

Gijtenbeek, M.

Citation

Gijtenbeek, M. (2021, July 7). *Cardiovascular compromise in monochorionic twins*. Retrieved from <https://hdl.handle.net/1887/3195073>

Version: Publisher's Version

License: [Licence agreement concerning inclusion of doctoral thesis in the Institutional Repository of the University of Leiden](#)

Downloaded from: <https://hdl.handle.net/1887/3195073>

Note: To cite this publication please use the final published version (if applicable).

Cover Page



Universiteit Leiden



The handle <https://hdl.handle.net/1887/3195073> holds various files of this Leiden University dissertation.

Author: Gijtenbeek, M.

Title: Cardiovascular compromise in monozygotic twins

Issue Date: 2021-07-07



PART II

FETAL CIRCULATION



CHAPTER 2

MEASUREMENT OF CARDIAC FUNCTION BY
CARDIAC TIME INTERVALS, APPLICABILITY
IN NORMAL PREGNANCY AND TWIN-TWIN
TRANSFUSION SYNDROME



S.J. Eschbach
M. Gijtenbeek
N. van Geloven
D. Oepkes
M.C. Haak

ABSTRACT

Background: To detect early cardiac deterioration, a simple and stable tool is needed. Measurement of time intervals in a simple four-chamber view using color-coded Tissue Doppler Imaging (cTDI) is a relatively new approach to assess fetal cardiac function. The aim of this study was to evaluate the applicability of this modality and to construct reference ranges for cardiac time intervals.

Methods: We performed a prospective longitudinal cohort study in healthy fetuses. We used linear mixed models to construct age-adjusted reference ranges for shortening time (St) and lengthening time (Lt) in three cardiac regions: global heart and right and left ventricular wall. St and Lt were expressed as a percentage of the cardiac cycle. Feasibility and intra- and interobserver variabilities were evaluated. We applied the technique to twin-twin transfusion syndrome (TTTS) recipients before laser therapy to test the diagnostic performance.

Results: A total of 251 recordings were obtained from 54 healthy singletons. St decreased and Lt increased with gestational age in all regions. We found a high feasibility (99.6%) and excellent intra/interobserver variability for St (0.96/0.94) and Lt (0.99/0.96) of the global heart. Left and right ventricle performance parameters were good. In TTTS recipients, St was prolonged ($p < 0.01$) and Lt was shortened ($p < 0.01$) in all regions and the feasibility was excellent (96.6%).

Conclusions: The assessment of fetal cardiac function by measurement of cardiac time intervals is technically feasible with good reproducibility, even in difficult scanning circumstances such as TTTS. It is possible to discriminate between healthy and compromised fetuses with this technique.

INTRODUCTION

Assessment of fetal cardiac function gained much interest in the last decade. New ultrasound technologies like speckle tracking and Tissue Doppler seem promising. Conventional Doppler is increasingly used to assess cardiac function in the so-called modified myocardial performance index (MPI). However, this is mainly used in tertiary care centers in research settings. Implementation in general practice is hampered by the need for extensive training to ensure acceptable performance and reproducibility.^{1,2} Normal ranges of MPI vary widely, and despite a clear agreement about the landmarks of the time periods, interobserver agreement is often disappointing.³⁻⁶ A simple and stable quantitative measurement of cardiac function, which is suitable for daily assessment, is not yet available. There is however a need to predict early functional deterioration of fetuses that are at risk of cardiac failure.⁷

Tissue Doppler Imaging (TDI) has been used since the early 1990s in adult echocardiography,⁸ but is a relatively new technique in fetal echocardiography. Pulsed-wave TDI is similar to pulsed-wave Doppler, but focuses on lower frequency shifts, which enables measurement of lower velocities like myocardial wall motion. Color-coded recordings are easy to obtain in a simple four-chamber view. In color-coded Tissue Doppler Imaging (cTDI), the representation of myocardial velocities is superimposed on gray-scale two-dimensional or M-mode images, to indicate the direction and velocity of myocardial motion.⁹

In adults, cTDI is used as a prognostic tool in heart failure and for differentiation between constrictive pericarditis and restrictive cardiomyopathy.¹⁰⁻¹² In fetal echocardiography, cTDI was first described for the assessment of myocardial velocities by Paladini *et al.*,¹³ in pregnancies complicated by intrauterine growth restriction or gestational diabetes.¹⁴⁻¹⁸ cTDI does not differentiate between active motion and passive motion; thus, fetal or maternal movements may cause artefacts. Velocity measurements are furthermore influenced by angle of insonation and the size of the used region of interest (ROI).^{19, 20} The applicability of the use of velocities in fetuses is therefore limited. In contrast, time intervals are independent of the angle of insonation and ROI size, making the use of time intervals a promising new approach for the assessment of fetal cardiac function.^{15, 19} In cTDI images, change in the direction of the myocardial wall motion is visible as a nadir in the curve. We hypothesize that these nadirs can be used as transition markers to indicate the moment from shortening to lengthening of the myocardium. This might be an easy and reproducible technique to measure cardiac time intervals to express fetal cardiac function.

The aim of our study was to evaluate the applicability of cTDI in terms of feasibility and intra- and interobserver variability. We created reference curves of the shortening time and lengthening time of the myocardial wall, in specific areas in the fetal heart and the whole heart, visualized in the four-chamber view. In addition, we evaluated St and Lt in twin-twin transfusion syndrome (TTTS) recipients, who typically show compromised cardiac function, to investigate the ability to discriminate between normal and abnormal cardiac function.

METHODS

Uncomplicated singleton pregnancies were recruited in a primary care center and at our fertility department between November 2014 and December 2016. The pregnancies were dated by crown-to-rump length (CRL) measurement in the first trimester or date of conception in IVF pregnancies. Conditions that possibly influence fetal cardiac function were excluded, including maternal diabetes, pregnancy induced hypertension, pre-eclampsia, systemic lupus erythematosus, fetal heart malformations, and birth weight below the 5th percentile.

Color-coded Tissue Doppler clips were acquired using a Canon Aplio 500 with a PVT-674BT 6 MHz transducer in early second trimester and a PVT-375BT 3.5 MHz transducer in late second and third trimester. A measurement software package (Canon Medical Systems Corporation) was used for analysis. Ultrasonographic examinations were repeatedly performed between a gestational age of 16 and 36 with a monthly interval. Fetal biometry and standard 2D echocardiography were performed in each examination. In the absence of fetal movements, at least two cTDI recordings, containing five or more cardiac cycles, were stored in an apical or basal four-chamber view. Settings were optimized with the heart covering approximately 60% of the image, to obtain the highest frame rate.²⁰ The examinations were limited to a 15 min slot per fetus for the complete examination.

Time intervals in color-coded Tissue Doppler recordings

In images derived from cTDI, the change of direction in myocardial movement results in nadirs in the curve. Shortening time (St) was defined as the duration of myocardial motion when the ventricular wall shortens and is expressed as a percentage of the cardiac cycle. Lengthening time (Lt) was defined as the duration of myocardial motion when the ventricular wall extends and expressed as a percentage of the cardiac cycle. St and Lt are not the same as systole and diastole, which are defined by opening and closure of the semilunar valves and by not myocardial motion. Time intervals between St and Lt were noted as inter St-Lt and inter Lt-St times.

As demonstrated in Figure 1, the nadirs that delineate St and Lt were defined as the ones with the smallest angle towards the direction of shortening respectively lengthening movement. The cardiac cycle with the most appropriate delineation of the time intervals was selected and stored separately for analysis. Three ROIs were examined in each clip. A large ROI was used to evaluate global heart function. The large ROI was placed around the whole heart depicted in a four-chamber view, covering at least both ventricles. Two smaller ROI's were used to evaluate specific areas in the fetal heart: at the base of the

right ventricular wall (RV), just beneath the tricuspid valve, and at the base of the left ventricular wall, just beneath the mitral valve (LV). The smaller ROI's were placed just below the attachment of the atrioventricular valves (AV) valves at the free ventricular wall at the end of systole with the AV valves closed, to measure the base of the ventricle. The size of this ROI covered the width of myocardial wall but did not involve the AV valve.

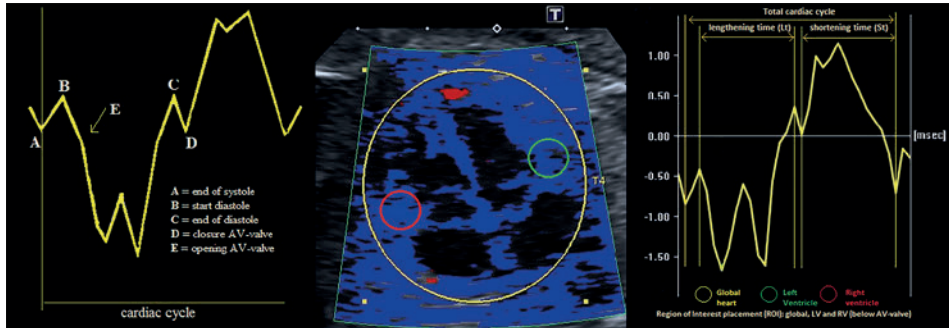


Figure 1. Schematic illustration of the cardiac cycle using cTDI, placement of regions of interest (ROI's) and demarcations of lengthening time (Lt) and shortening time (St) in the derived image

To investigate the ability to express abnormal cardiac function of this measurement, we performed cTDI measurements in all recipients with TTTS referred to our department between January 2015 and December 2016. We used the last ultrasound examination before laser therapy. Recipients may demonstrate cardiac dysfunction at time of TTTS diagnosis.²¹ We stored two cTDI recordings, containing five or more cardiac cycles for analysis of the St and Lt. Because TTTS occurs mainly between 14 to 28 weeks, we compared recipients with healthy singletons within this gestational age period. Thus, the TTTS recipients were matched at the level of gestational age. All examinations were performed and analyzed by one experienced operator (S.E.). For intraobserver agreement, 30 clips containing one raw cardiac cycle of the singleton group were stored and analyzed three times with a time interval of three months. For interobserver agreement, a second operator (M.G.) performed three analyses on the same 30 cardiac cycles. The mean of the three analyses of both operators was compared for interobserver agreement. Within-fetus variability was defined as agreement in three different cardiac cycles in different clips in one examination and analyzed by the same operator (S.E.). The study was approved by the medical ethical committee of the Leiden University Medical Center and all women signed informed consent.

Statistical analysis

Statistical analysis was performed with IBM SPSS 20.0 statistical package (Chicago, IL, USA). Feasibility was defined as the percentage of measurements which could be performed successfully. A measurement was noted as successful if the signal was clear enough to recognize all four nadirs. A measurement was unsuccessful in case of absent nadirs, or multiple nadirs in which the demarcation nadir could not be recognized. Baseline characteristics between healthy singletons and recipients were compared with the *t* test and Chi-square test. Intra- and interobserver agreement and within-fetus variability were quantified by the intraclass correlation coefficient (ICC). Because of the longitudinal character of this study, we used linear mixed models in which we included a random intercept per individual to account for the correlated measurements within each fetus. For each outcome variable, we evaluated whether the gestational age trend increased or decreased over time, using a mixed model with a fixed linear age effect. We used this same model to construct reference intervals for healthy singletons. To compare the means of TTTS recipients and healthy singletons, we constructed a second mixed model for each outcome including gestational age, group (healthy singleton or TTTS recipient) and the interaction between age and group as fixed effects. From this model, we estimated the mean difference between the groups at the mean observed gestational age.

RESULTS

The baseline characteristics of the healthy singletons and the TTTS recipients are depicted in Table 1. Sixty-one singletons were eligible for inclusion, but seven cases were excluded from analysis because gestational diabetes or intrauterine growth restriction developed during gestation.

Table 1. Demographic characteristics and pregnancy outcome of singletons and TTTS recipients

| Characteristics | Singletons (n = 54) | TTTS recipients (n = 86) | p-value |
|---|------------------------|-----------------------------|---------|
| Caucasian | 93.2 | 97.0 | 0.17 |
| Maternal body mass index (kg/m ²) | 23.3 ± 3.1 | 24.6 ± 4.6 | 0.05 |
| Gestational age at delivery (weeks) | 39.6 ± 1.4 | 31.5 ± 5.1 | |
| Birth weight (grams) | 3500 ± 496 | 1985 ± 630 | |
| 5-min Apgar score | 9 ± 1 | 8 ± 1 | |
| Quintero stage | n/a | | |
| I | | 16.3 | |
| II | | 24.4 | |
| III | | 55.8 | |
| IV | | 2.3 | |
| V | | 1.2 | |
| Frames per second | 124 ± 22 | 122 ± 30 | 0.91 |

Data are presented as % or mean (+-SD). TTTS, twin-twin transfusion syndrome.

A total of 251 examinations were performed in 54 healthy singletons. Performance parameters are summarized in Table 2. Feasibility in the global heart and the right ventricular wall was excellent (99.6%/93.6%) and good in the left ventricular wall (78.1%). The mean global shortening time was 45.8% of the cardiac cycle at 16 weeks of gestation and decreased significantly to 42.4% at 36 weeks of gestation, while mean global lengthening time was 42.8% of the cardiac cycle at 16 weeks of gestation and increased to 44.6% at 36 weeks of gestation. Normal reference curves were constructed and are shown in Figure 2. The inter St-Lt and inter Lt-St time frames were noted and analysed, as shown in Table 2. While inter St-Lt appeared to be stable during gestation, inter Lt-St increased in all ROI's.

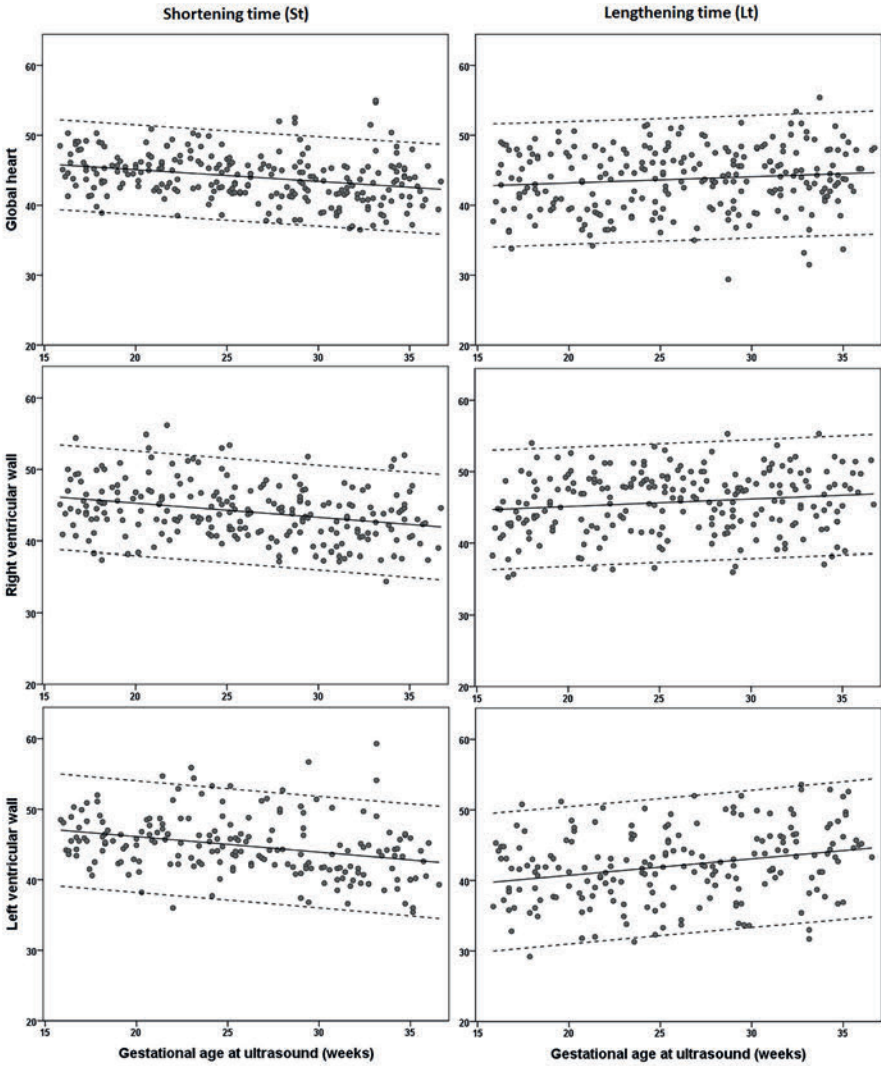


Figure 2. Reference charts for St and Lt in healthy singletons, in different ROI's of the fetal heart from 16 to 36 weeks of gestation

Table 2. Performance of cTDI in different ROI's of the fetal heart at 16 and 36 weeks of gestation

| | 16 weeks | 36 weeks | p-value |
|-------------|--------------------|--------------------|----------------|
| | Mean % (SD) | Mean % (SD) | |
| Global | | | |
| St | 45.8 (3.3) | 42.4 (3.3) | <0.01 |
| Lt | 42.8 (4.5) | 44.6 (4.5) | 0.049 |
| Inter St-Lt | 9.5 (3.8) | 10.2 (3.8) | 0.42 |
| Inter Lt-St | 3.1 (2.2) | 5.1 (2.2) | <0.01 |
| RV | | | |
| St | 46.1 (3.7) | 42.1 (3.7) | <0.01 |
| Lt | 44.7 (4.3) | 46.8 (4.3) | 0.02 |
| Inter St-Lt | 5.8 (3.0) | 6.0 (3.0) | 0.88 |
| Inter Lt-St | 3.7 (2.3) | 5.5 (2.3) | <0.01 |
| LV | | | |
| St | 47.0 (4.1) | 42.6 (4.1) | <0.01 |
| Lt | 39.8 (5.0) | 44.5 (5.0) | <0.01 |
| Inter St-Lt | 3.9 (2.6) | 5.6 (2.6) | 0.01 |
| Inter Lt-St | 4.0 (2.6) | 5.6 (2.6) | 0.01 |

cTDI, color-coded Tissue Doppler Imaging; ROI, region of interest; St, shortening time; Lt, lengthening time; RV, right ventricular wall; LV, left ventricular wall;

| Feasibility % | Intra-CC | Inter-CC | Within-fetus variability |
|--------------------------|-----------------|-----------------|---------------------------------|
| 99.6 | 0.98 | 0.94 | 0.60 |
| | 0.99 | 0.96 | 0.56 |
| | 0.99 | 0.95 | 0.27 |
| | 0.90 | 0.97 | 0.46 |
| 93.6 | 0.94 | 0.76 | 0.47 |
| | 0.94 | 0.72 | 0.38 |
| | 0.88 | 0.77 | 0.20 |
| | 0.88 | 0.78 | 0.17 |
| 78.1 | 0.91 | 0.82 | 0.29 |
| | 0.89 | 0.74 | 0.61 |
| | 0.92 | 0.60 | 0.29 |
| | 0.86 | 0.74 | 0.19 |

Intra-CC, intraclass correlation coefficient for intraobserver agreement; Inter-CC, intraclass correlation coefficient for interobserver agreement.

Intraobserver agreement within a cardiac cycle was good for the global heart and the RV and LV (St 0.98/0.94/0.91 and Lt 0.99/0.94/0.89). Interobserver agreement was excellent for the global heart (St 0.94 and Lt 0.96) and reasonable for the RV (St 0.76 and Lt 0.72) and LV (St 0.82 and Lt 0.74). The intraclass correlation coefficient for within-fetus variability varied between 0.17 and 0.61 in all ROIs, reflecting high variability of the heart cycle within the same fetus. Mean frame rate (frames per second) was 98, with a standard deviation of 35 frames per second. Lower frame rates were associated with advanced gestational age.

Baseline characteristics for TTTS recipients were comparable with healthy singletons (Table 1). In 86 recordings of recipients at time of TTTS diagnosis, feasibility was 96.6% for global ROI, 94.2% for RV and 70.0% for LV. Lengthening time was significantly shortened, and shortening time significantly prolonged, in all ROI's (Table 3 and Figure 3).

Table 3. Singletons versus recipients at time of TTTS diagnosis, in different ROI's of the fetal heart in the second trimester

| | Singletons | Recipients | Mean Difference^a (CI) | p-value |
|-------------|--------------------|--------------------|---|----------------|
| | Mean % (SD) | Mean % (SD) | | |
| Global | | | | |
| St | 44.9 (2.7) | 48.3 (4.7) | 3.0 (1.9 - 4.1) | <0.01 |
| Lt | 43.4 (4.5) | 37.6 (5.3) | 5.6 (4.1 - 7.0) | <0.01 |
| Inter St-Lt | 8.1 (4.0) | 9.7 (4.7) | 1.7 (0.4 - 2.8) | 0.01 |
| Inter Lt-St | 3.7 (2.3) | 4.3 (2.5) | 0.8 (0.0 - 1.5) | 0.04 |
| RV | | | | |
| St | 45.2 (2.7) | 49.0 (7.5) | 3.1 (1.2 - 5.0) | <0.01 |
| Lt | 45.6 (4.2) | 37.2 (7.1) | 8.1 (6.3 - 9.9) | <0.01 |
| Inter St-Lt | 5.3 (3.1) | 8.3 (2.5) | 2.8 (1.7 - 4.0) | <0.01 |
| Inter Lt-St | 3.7 (2.3) | 4.4 (3.0) | 0.4 (-1.2 - 0.4) | 0.30 |
| LV | | | | |
| St | 45.8 (3.6) | 48.9 (7.5) | 3.1 (1.8 - 4.4) | <0.01 |
| Lt | 41.2 (4.9) | 34.8 (5.7) | 6.1 (4.3 - 7.9) | <0.01 |
| Inter St-Lt | 4.3 (2.5) | 10.4 (3.7) | 6.0 (4.9 - 7.1) | <0.01 |
| Inter Lt-St | 4.3 (2.5) | 5.8 (4.1) | 1.5 (0.3 - 2.6) | 0.01 |

TTTS, twin-twin transfusion syndrome; ROI, region of interest; St, shortening time; Lt, lengthening time; RV, right ventricular wall; LV, left ventricular wall; CI, confidence interval.

^aMean difference between recipients and singletons at 21 weeks of gestation

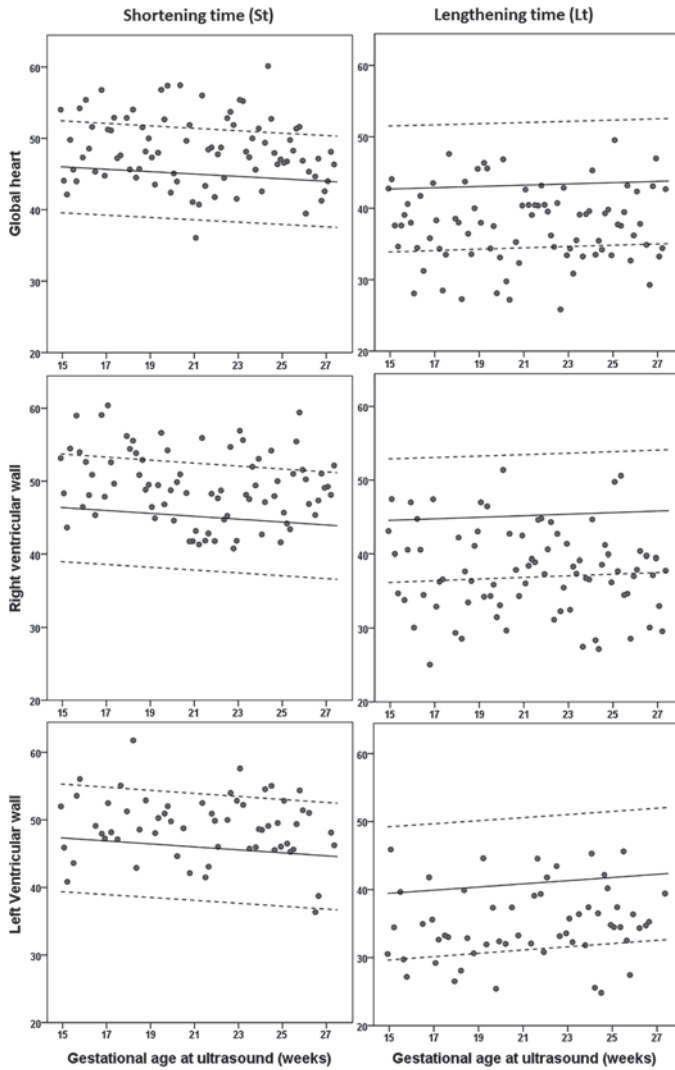


Figure 3. Scatterplots for recipients at time of TTTS diagnosis versus singletons reference curves in different ROI's of the fetal heart from 16 to 28 weeks of gestation

DISCUSSION

In this study, we introduce a new approach to assess fetal cardiac function through the measurement of time intervals of the myocardial wall motion in a simple four-chamber view using cTDI. Lengthening time and shortening time of the fetal heart show a slight increase, respectively decrease, with advancing gestation. Feasibility and intra- and interobserver agreement were shown to be excellent in the global heart ROI. The high feasibility (96.6%) in difficult circumstances like TTTS, with polyhydramnios and abundant fetal movements of the recipient, indicates that this approach is simple and robust. Lt was shortened and St prolonged in TTTS recipients compared to healthy singletons, reflecting the discriminative ability of this new parameter.

Currently, the MPI is the most used method to assess fetal cardiac function. MPI is considered a consistent cardiac marker which becomes altered in early stages of chronic hypoxia or cardiac overload.²² MPI implementation in routine assessment has several limitations. First, MPI is a pulsed-wave Doppler-derived index of isovolumetric time intervals (IRT/ICT) and ejection time (ET), and ventricular inflow and outflow are ideally measured in the same cardiac cycle. For left MPI measurement, a combined flow velocity waveform recording of mitral valve and aorta outflow can be obtained in the same sample volume, but these recordings require considerable expertise of the operator in image acquisition and correct recording of the Doppler tracing. The anatomy of the tricuspid valve and pulmonary artery, however, precludes recording of both valves within the same Doppler sample gate in the right ventricle, which is the dominant ventricle in fetal circulation. Therefore, right MPI can only be calculated from two separate recordings, which affects feasibility and reproducibility. As a result, normal ranges of both left and right MPI vary widely and interobserver agreement is disappointing.³⁻⁶ Another difficulty in MPI measurements is the caliper placement in the Doppler waveforms to calculate the time intervals. This seems to be resolved with the development of automated MPI systems which removes the subjectivity of manual caliper placement, but authors acknowledge that ultrasound image acquisition remains a potential source of variability, even for highly trained operators.^{23,24} Contrary, the cTDI recordings described in this study are easy to obtain because only a recording of the four-chamber view is needed. The four-chamber view is easy to acquire and is part of every routine obstetric ultrasound examination. The placement of the ROI is simple and fast, which makes this technique applicable in daily obstetrical care in the future.

The measurement of cardiac time intervals in cTDI is a relatively new approach in fetal echocardiography.¹⁵ Willruth *et al.*¹⁹ concluded that time intervals can be analyzed with a high accuracy, irrespective of what ROI size is used. They described IRT, ICT, and ET

retrieved by cTDI, comparable to these parameters in Doppler-derived MPI. Interobserver agreement in this study was low, probably because the closure and the opening of the cardiac valves are not easy to recognize in the signal. In our approach of the analysis of the same signal, cardiac time intervals are marked by myocardial wall motion and not by the movement of the blood. Instead of ET, which represents blood volume shift and is marked by cardiac valve clicks, we propose to evaluate St, which reflects the time the myocardium actually contracts. By definition St will be longer than ET because the myocardium first starts to contract, and with increased intraventricular pressure the semilunar valve opens, and the ejection of blood starts. Lt is prolonged in the same manner (Figure 1). Consequently, the inter St-Lt and inter Lt-St are shorter than the isovolumetric time intervals. As shown in Table 2, the inter-shortening-lengthening time as well as the inter-lengthening-shortening time show a large standard deviation in all ROIs which we attribute to measurement error caused by the current frame rates. Therefore, the value of inter St-Lt, respectively, and Lt-St in individual measurements is limited.

However, this approach of the analysis of cTDI signal results in an excellent feasibility and intra- and interobserver agreement for global heart function, which is better than currently used techniques to assess fetal cardiac function. This is explained by the simplicity of the large ROI placement and the easy recognition of the nadirs in the curve. We observed that wall motion in the smaller ROIs is less consistent and several smaller nadirs may be visible, which results in a larger interobserver variability. We observed that the LV shows lower feasibility scores compared to the RV. Previous studies show lower volume shifting and less ventricular wall displacement in the left ventricle compared to the right ventricle in fetal life,^{15, 25, 26} which might explain the nadirs to be less clear, which results in lower feasibility scores and reproducibility.

In contrast to intra- and interobserver agreement, within-fetus variability in our study was high in all areas of the fetal heart. We hypothesize that the high within-fetus variability can be attributed to beat-to-beat (BTB) variability, which is a physiological phenomenon mediated by the autonomic nervous system. This hypothesis is consistent with a recently published study by Maheshwari *et al.*,²⁷ which showed that MPI time intervals have a BTB variability which is comparable with the fetal heart rate variability. BTB variability is well established in various Doppler flow measurements, and the occurrence of physiological changes as possible contributors to measurement variation is mentioned before in studies assessing repeatability.^{28, 29}

Recipients in TTTS show abnormal cardiac function, and it is suggested earlier that cardiac profiling can be an aid in early management of TTTS.^{30, 31} Our study shows deviations in mean cardiac time intervals with a shortened Lt, prolonged St and prolonged inter St-Lt

in recipients, which confirms findings of abnormal MPI and prolonged isovolumetric contraction time.^{32, 33} The within-fetus variability in normal fetuses, together with the overlap of the results in TTTS recipients with the normal values, makes distinction in TTTS difficult. Care should be taken, and further research is needed to determine the diagnostic accuracy of cTDI. The feasibility rates in the TTTS recipients are, however, exceptionally high compared to the current techniques, as it is known that the retrieval of Doppler recordings in TTTS is difficult because of the polyhydramnios and the abundant fetal movements of the recipient. A feasibility rate of 96.6% proves that this method is simple and fast. Future studies are planned by our group to elucidate the possible role of cTDI in monitoring monochorionic twins.

To investigate the ability to discriminate between normal and abnormal cardiac function, recipient twins were matched for gestational age to healthy singletons. The lack of a control group of uncomplicated twins is a limitation of our study. It is, however, well accepted that reference charts of healthy singletons are compared to complicated monochorionic twins. In the previous studies in the field of fetal cardiology, speckle tracking-derived fetal cardiac function and modified MPI measurements in recipient twins were compared to normal singleton fetuses.^{24, 34, 35} Uncomplicated (monochorionic) twins are generally not used as a control group, since twin pregnancies cannot be considered normal because of their complexity and high risk of complications.

In conclusion, the proposed technique presents a promising new approach to assess fetal cardiac function. Recordings are easy to obtain and feasibility and inter- and intraobserver agreement are excellent for global heart function, even in difficult scanning circumstances as in TTTS recipients. Therefore, this technique is potentially useful in daily practice, because it can be applied in only a four-chamber view. Furthermore, this approach seems promising in the detection of abnormal heart function, but further research in pathological pregnancies is needed.

REFERENCES

1. Herberg U, Breuer J, Gembruch U, Willruth A. Imaging in fetal cardiology. *Minerva Pediatr* 2014;66(5):453-71.
2. Simpson JM, Cook A. Repeatability of echocardiographic measurements in the human fetus. *Ultrasound Obstet Gynecol* 2002;20(4):332-9.
3. Van Mieghem T, Gucciardo L, Lewi P, Lewi L, Van Schoubroeck D, Devlieger R, et al. Validation of the fetal myocardial performance index in the second and third trimesters of gestation. *Ultrasound Obstet Gynecol* 2009;33(1):58-63.
4. Cruz-Martinez R, Figueras F, Bennasar M, Garcia-Posadas R, Crispi F, Hernandez-Andrade E, et al. Normal reference ranges from 11 to 41 weeks' gestation of fetal left modified myocardial performance index by conventional Doppler with the use of stringent criteria for delimitation of the time periods. *Fetal Diagn Ther* 2012;32(1-2):79-86.
5. Hernandez-Andrade E, Lopez-Tenorio J, Figueroa-Diesel H, Sanin-Blair J, Carreras E, Cabero L, et al. A modified myocardial performance (Tei) index based on the use of valve clicks improves reproducibility of fetal left cardiac function assessment. *Ultrasound Obstet Gynecol* 2005;26(3) 227-32.
6. Meriki N, Welsh AW. Development of Australian reference ranges for the left fetal modified myocardial performance index and the influence of caliper location on time interval measurement. *Fetal Diagn Ther* 2012;32(1-2):87-95.
7. Gardiner HM. Foetal cardiac function: assessing new technologies. *Cardiol Young* 2014;24 Suppl 2 26-35.
8. Miyatake K, Yamagishi M, Tanaka N, Uematsu M, Yamazaki N, Mine Y, et al. New method for evaluating left ventricular wall motion by color-coded tissue Doppler imaging: in vitro and in vivo studies. *J Am Coll Cardiol* 1995;25(3):717-24.
9. Ho CY, Solomon SD. A clinician's guide to tissue Doppler imaging. *Circulation* 2006;113(10):e396-8.
10. Wang M, Yip G, Yu CM, Zhang Q, Zhang Y, Tse D, et al. Independent and incremental prognostic value of early mitral annulus velocity in patients with impaired left ventricular systolic function. *J Am Coll Cardiol* 2005;45(2):272-7.
11. Hillis GS, Moller JE, Pellikka PA, Gersh BJ, Wright RS, Ommen SR, et al. Noninvasive estimation of left ventricular filling pressure by E/e' is a powerful predictor of survival after acute myocardial infarction. *J Am Coll Cardiol* 2004;43(3):360-7.
12. Garcia MJ, Rodriguez L, Ares M, Griffin BP, Thomas JD, Klein AL. Differentiation of constrictive pericarditis from restrictive cardiomyopathy: assessment of left ventricular diastolic velocities in longitudinal axis by Doppler tissue imaging. *J Am Coll Cardiol* 1996;27(1):108-14.
13. Paladini D, Lamberti A, Teodoro A, Arienzo M, Tartaglione A, Martinelli P. Tissue Doppler imaging of the fetal heart. *Ultrasound Obstet. Gynecol* 2000;16(6):530-535.
14. Comas M, Crispi F, Gomez O, Puerto B, Figueras F, Gratacos E. Gestational age- and estimated fetal weight-adjusted reference ranges for myocardial tissue Doppler indices at 24-41 weeks' gestation. *Ultrasound Obstet. Gynecol* 2011;37(1):57-64.
15. Elmstedt NN, Johnson JJ, Lind BB, Ferm-Widlund KK, Herling LL, Westgren MM, et al. Reference values for fetal tissue velocity imaging and a new approach to evaluate fetal myocardial function. *Cardiovasc. Ultrasound* 2013;11:29.

16. Herling L, Johnson J, Ferm-Widlund K, Lindgren P, Acharya G, Westgren M. Automated analysis of color tissue Doppler velocity recordings of the fetal myocardium using a new algorithm. *Cardiovasc. Ultrasound* 2015;13:39.
17. Larsen LU, Sloth E, Petersen OB, Pedersen TF, Sorensen K, Ulbjerg N. Systolic myocardial velocity alterations in the growth-restricted fetus with cerebroplacental redistribution. *Ultrasound Obstet. Gynecol* 2009;34(1):62-67.
18. Saini AP, Ural S, Pauliks LB. Quantitation of fetal heart function with tissue Doppler velocity imaging-reference values for color tissue Doppler velocities and comparison with pulsed wave tissue Doppler velocities. *Artif. Organs* 2014;38(1):87-91.
19. Willruth AM, Steinhard J, Enzensberger C, Axt-Fliedner R, Gembruch U, Doelle A, et al. Color Tissue Doppler to Analyze Fetal Cardiac Time Intervals: Normal Values and Influence of Sample Gate Size. *Ultraschall Med* 2016.
20. Comas M, Crispi F. Assessment of fetal cardiac function using tissue Doppler techniques. *Fetal Diagn. Ther* 2012;32(1-2):30-38.
21. Van Mieghem T, Klaritsch P, Done E, Gucciardo L, Lewi P, Verhaeghe J, et al. Assessment of fetal cardiac function before and after therapy for twin-to-twin transfusion syndrome. *Am J Obstet Gynecol* 2009;200(4):400 e1-7.
22. Hernandez-Andrade E, Benavides-Serralde JA, Cruz-Martinez R, Welsh A, Mancilla-Ramirez J. Evaluation of conventional Doppler fetal cardiac function parameters: E/A ratios, outflow tracts, and myocardial performance index. *Fetal Diagn Ther* 2012;32(1-2) 22-9.
23. Welsh AW, Maheshwari P, Wang J, Henry A, Chang D, Crispi F, et al. Evaluation of an automated fetal myocardial performance index. *Ultrasound Obstet Gynecol* 2016;48(4):496-503.
24. Lee MY, Won HS, Park JE, Shim JY, Lee PR, Kim A, et al. Fetal left modified myocardial performance index measured by the Auto Mod-MPI system: development of reference values and application to recipients of twin-to-twin transfusion syndrome. *Prenat Diagn* 2016;36(5):424-31.
25. Kim SH, Miyakoshi K, Kadohira I, Tanaka M, Minegishi K, Matsumoto T, et al. Comparison of the right and left ventricular performance during the fetal development using velocity vector imaging. *Early Hum Dev* 2013;89(9):675-81.
26. Uittenbogaard LB, Haak MC, Spreeuwenberg MD, van Vugt JM. Fetal cardiac function assessed with four-dimensional ultrasound imaging using spatiotemporal image correlation. *Ultrasound Obstet Gynecol* 2009;33(3) 272-81.
27. Maheshwari P, Alphonse J, Henry A, Wang J, Redmond SJ, Welsh A. Beat-to-beat variability of the fetal myocardial performance index (MPI). *Ultrasound Obstet Gynecol* 2016.
28. Hollis B, Mavrides E, Campbell S, Tekay A, Thilaganathan B. Reproducibility and repeatability of transabdominal uterine artery Doppler velocimetry between 10 and 14 weeks of gestation. *Ultrasound Obstet Gynecol* 2001;18(6):593-7.
29. Papageorghiou AT, To MS, Yu CK, Nicolaidis KH. Repeatability of measurement of uterine artery pulsatility index using transvaginal color Doppler. *Ultrasound Obstet Gynecol* 2001;18(5):456-9.
30. Wohlmuth C, Gardiner HM, Diehl W, Hecher K. Fetal cardiovascular hemodynamics in twin-twin transfusion syndrome. *Acta Obstet Gynecol Scand* 2016;95(6):664-71.
31. Moon-Grady AJ. Fetal echocardiography in twin-twin transfusion syndrome. *Am J Perinatol* 2014;31 Suppl 1:S31-8.
32. Stirnemann JJ, Mougeot M, Proulx F, Nasr B, Essaoui M, Fouron JC, et al. Profiling fetal cardiac function in twin-twin transfusion syndrome. *Ultrasound Obstet Gynecol* 2010;35(1):19-27.

33. Raboisson MJ, Fouron JC, Lamoureux J, Leduc L, Grignon A, Proulx F, et al. Early intertwin differences in myocardial performance during the twin-to-twin transfusion syndrome. *Circulation* 2004;110(19):3043-8.
34. Rychik J, Zeng S, Bebbington M, Szwasz A, Quartermain M, Natarajan S, et al. Speckle tracking-derived myocardial tissue deformation imaging in twin-twin transfusion syndrome: differences in strain and strain rate between donor and recipient twins. *Fetal Diagn Ther* 2012;32(1-2):131-7.
35. Van Mieghem T, Giusca S, DeKoninck P, Gucciardo L, Done E, Hindryckx A, et al. Prospective assessment of fetal cardiac function with speckle tracking in healthy fetuses and recipient fetuses of twin-to-twin transfusion syndrome. *J Am Soc Echocardiogr* 2010;23(3):301-8.