



Universiteit  
Leiden  
The Netherlands

## **Assessment of the Clinical Benefit of Imaging in Children With Unilateral Sensorineural Hearing Loss: A Systematic Review and Meta-analysis**

Ropers, F.G.; Pham, E.N.B.; Kant, S.G.; Rotteveel, L.J.C.; Rings, E.H.H.M.; Verbist, B.M.; Dekkers, O.M.

### **Citation**

Ropers, F. G., Pham, E. N. B., Kant, S. G., Rotteveel, L. J. C., Rings, E. H. H. M., Verbist, B. M., & Dekkers, O. M. (2019). Assessment of the Clinical Benefit of Imaging in Children With Unilateral Sensorineural Hearing Loss: A Systematic Review and Meta-analysis. *Jama Otolaryngology-Head And Neck Surgery*. doi:10.1001/jamaoto.2019.0121

Version: Not Applicable (or Unknown)

License: [Leiden University Non-exclusive license](#)

Downloaded from: <https://hdl.handle.net/1887/3195446>

**Note:** To cite this publication please use the final published version (if applicable).

# Assessment of the Clinical Benefit of Imaging in Children With Unilateral Sensorineural Hearing Loss

## A Systematic Review and Meta-analysis

Fabienne G. Ropers, MD, Dr Med; Eveline N. B. Pham, BSc; Sarina G. Kant, MD, PhD; Liselotte J. C. Rotteveel, MD, PhD; Edmond H. H. M. Rings, MD, PhD; Berit M. Verbist, MD, PhD; Olaf M. Dekkers, MD, PhD

**IMPORTANCE** Imaging used to determine the cause of unilateral sensorineural hearing loss (USNHL) in children is often justified by the high likelihood of detecting abnormalities, which implies that these abnormalities are associated with hearing loss and that imaging has a positive contribution to patient outcome or well-being by providing information on the prognosis, hereditary factors, or cause of hearing loss.

**OBJECTIVES** To evaluate the diagnostic yield of computed tomography (CT) and magnetic resonance imaging (MRI) in children with isolated unexplained USNHL and investigate the clinical relevance of these findings.

**EVIDENCE REVIEW** Cochrane Library, Embase, PubMed, and Web of Science databases were searched for articles published from 1978 to 2017 on studies of children with USNHL who underwent CT and/or MRI of the temporal bone. Two authors (F.G.R. and E.N.B.P.) independently extracted information on population characteristics, imaging modality, and the prevalence of abnormalities and assessed the studies for risk of bias. Eligibility criteria included studies with 20 or more patients with USNHL who had CT and/or MRI scans, a population younger than 18 years, and those published in English.

**MAIN OUTCOMES AND MEASURES** The pooled prevalence with 95% CI of inner ear abnormalities grouped according to finding and imaging modality.

**FINDINGS** Of 1562 studies, 18 were included with a total of 1504 participants included in the analysis. Fifteen studies were consecutive case studies and 3 were retrospective cohort studies. The pooled diagnostic yield for pathophysiologic relevant findings in patients with unexplained USNHL was 37% for CT (95% CI, 25%-48%) and 35% for MRI (95% CI, 22%-49%). Cochleovestibular abnormalities were found with a pooled frequency of 19% for CT (95% CI, 14%-25%) and 16% for MRI (95% CI, 7%-25%). Cochlear nerve deficiency and associated cochlear aperture stenosis had a pooled frequency of 16% for MRI (95% CI, 3%-29%) and 44% for CT (95% CI, 36%-53%), respectively. Enlarged vestibular aqueduct (EVA) was detected with a pooled frequency of 7% for CT and 12% for MRI in children with USNHL.

**CONCLUSIONS AND RELEVANCE** Imaging provided insight into the cause of hearing loss in a pooled frequency of about 35% to 37% in children with isolated unexplained USNHL. However, none of these findings had therapeutic consequences, and imaging provided information on prognosis and hereditary factors only in a small proportion of children, namely those with EVA. Thus, there is currently no convincing evidence supporting a strong recommendation for imaging in children who present with USNHL. The advantages of imaging should be carefully balanced against the drawbacks during shared decision making.

JAMA Otolaryngol Head Neck Surg. doi:10.1001/jamaoto.2019.0121  
Published online April 4, 2019.

[+ Invited Commentary](#)

[+ Supplemental content](#)

**Author Affiliations:** Department of Pediatrics, Leiden University Medical Center, Leiden, Netherlands (Ropers, Pham, Rings); Department of Human Genetics, Leiden University Medical Center, Leiden, Netherlands (Kant); Department of Otorhinolaryngology, Leiden University Medical Center, Leiden, Netherlands (Rotteveel); Department of Pediatrics, Erasmus Medical Center, Rotterdam, Netherlands (Rings); Department of Radiology, Leiden University Medical Center, Leiden, Netherlands (Verbist); Department of Clinical Epidemiology, Leiden University Medical Center, Leiden, Netherlands (Dekkers); Department of Medicine, Section Endocrinology, Leiden University Medical Center, Leiden, Netherlands (Dekkers).

**Corresponding Author:** Fabienne G. Ropers, MD, Dr Med, Department of Pediatrics, Leiden University Medical Center, Albinusdreef 2, 2333 ZA Leiden, The Netherlands (f.g.ropers@lumc.nl).

Children with unilateral sensorineural hearing loss (USNHL) are at risk for behavioral problems and delayed speech, language, social, and mathematical skill development compared with normal-hearing peers.<sup>1-4</sup> With a prevalence of 1.7 per 1000 live births, which rises up to 3% at school age, USNHL is not uncommon among children.<sup>5,6</sup> The severity of USNHL can range from mild to profound, and in approximately 30% of patients, progression occurs.<sup>7</sup>

There is no evidence-based protocol for diagnostic testing to identify the cause of USNHL. However, the usual approach is that diagnostic tests are guided by clinical information if it points to a specific diagnosis. If history taking and physical examination offer no clue, the first diagnostic step is testing for congenital cytomegalovirus (CMV) infection, the most common nongenetic cause of hearing loss.<sup>8,9</sup> If results are negative for infection, imaging of the temporal bone is recommended because of the high frequency of abnormalities (25%-49%).<sup>10-12</sup> Laboratory testing and genetic screening are not routinely performed.<sup>11-13</sup>

Computed tomography (CT) and magnetic resonance imaging (MRI) are used for evaluation of sensorineural hearing loss (SNHL). Computed tomography is an excellent modality to identify abnormalities of the bony labyrinth and middle ear. Magnetic resonance imaging has a higher soft-tissue resolution that displays the internal cochlear structures in detail, outperforming CT for evaluation of the cochleovestibular and facial nerve in the internal auditory canal, the cerebellopontine angle cistern, and abnormalities along the auditory pathway. No consensus exists regarding the preferred imaging modality for SNHL; some authors recommend CT as the first choice,<sup>10,12,14</sup> whereas others have advocated for an increased role for MRI<sup>15,16</sup> or even dual-modality screening.<sup>17</sup>

Imaging is often advocated for patients with USNHL given the high detection rate of inner ear abnormalities.<sup>12</sup> However, advantages and disadvantages of diagnostic testing should be balanced carefully, and testing should be initiated only if it may result in net patient benefit. Tests may benefit the patient if the results improve outcomes through a change in management or if valuable information about prognosis or hereditary factors is provided. Also, parents and patients may benefit from knowing the exact anatomic cause of hearing loss, despite the fact that this information does not change the disease course through altered management. However, imaging for this sole purpose is a preference-sensitive decision; the net benefit depends on how benefits and harms (and cost) of imaging are weighed by patients and their families. Because no curative treatment exists for almost all causes of USNHL, the benefits of imaging on prognosis could be associated with effective preventive measures, if available. Radiation exposure is a disadvantage of CT, particularly in very young children; however, owing to changes in screening policies, the typical age at diagnosis of USNHL has decreased from 4 to 5 years to 2 to 3 months.<sup>18</sup> Sedation is necessary for MRI in young children.

Herein, we assessed the diagnostic yield and consequences of imaging in children with isolated USNHL in whom medical history and physical examination is not suggestive for a specific diagnosis; imaging is often recom-

## Key Points

**Question** What is the clinical benefit of diagnostic imaging (computed tomography [CT] or magnetic resonance imaging [MRI]) in children with isolated unexplained unilateral sensorineural hearing loss (USNHL)?

**Findings** In this systematic review and meta-analysis, imaging revealed relevant pathophysiologic findings in one-third of 1504 children with USNHL, but these findings did not alter treatment for USNHL. Only detection of enlarged vestibular aqueduct with a pooled frequency of 7% for CT and 12% for MRI yielded information on hereditary factors and higher risk of progressive hearing loss in participants. Harms of imaging include radiation exposure in CT and sedation for MRI if MRI is performed in young children.

**Meaning** Imaging performed as part of the routine workup for patients with USNHL does not provide information that alters treatment or give insight into prognosis or hereditary factors of hearing loss in most cases; the benefits of imaging should be carefully balanced against the drawbacks during shared decision making.

mended for these patients.<sup>13</sup> We performed a meta-analysis to evaluate the diagnostic yield of imaging, focusing on findings associated with hearing loss. Subsequently, we aimed to provide an overview, combining information on expected findings and the potential benefits of these findings, to facilitate shared decision making.

## Methods

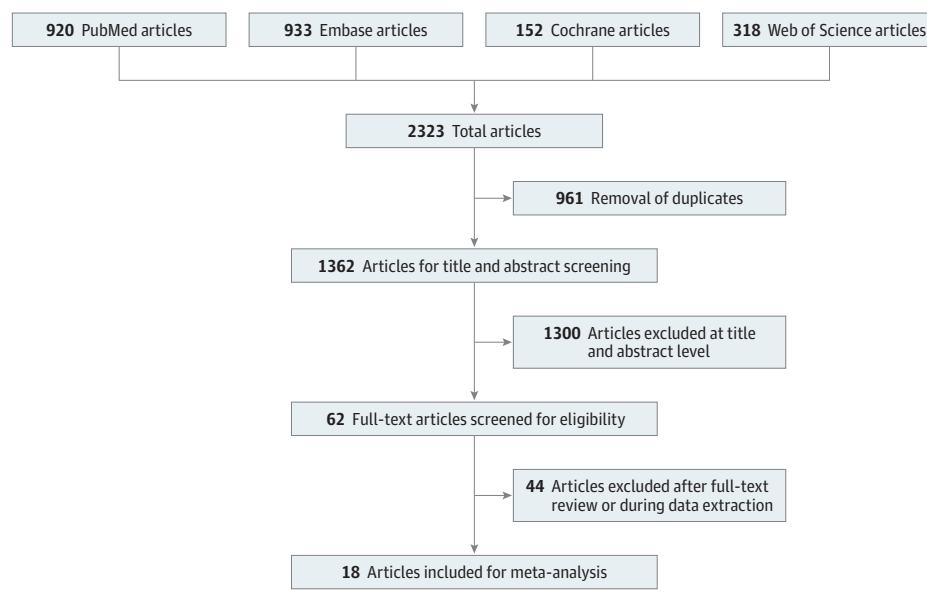
### Data Sources and Study Selection

We included original studies on the prevalence of inner ear abnormalities in children with USNHL that used CT or MRI of the temporal bone. A systematic literature search was conducted in PubMed, Cochrane Library, Web of Science, and Embase databases in December 2017. The detailed search strategy is outlined in eTable 1 in the [Supplement](#). Reference lists of the included articles were reviewed for relevant studies. Studies published before 1978 were not considered because prior to 1978 enlarged vestibular aqueduct (EVA) was not recognized as being associated with hearing loss.<sup>19</sup>

The following eligibility criteria were applied: (1) studies with 20 or more patients with USNHL who underwent CT or MRI, (2) studies with a patient population with a mean age younger than 18 years, and (3) studies published in English.

Studies were excluded if (1) mixed categories of hearing loss were included, but separate data for USNHL were not provided, (2) only the total number of abnormal scans was given, without further specification of the abnormalities, or (3) studies included more than 10% of children with a dysmorphological syndrome or more than 10% of children with acquired causes of USNHL (mumps, CMV, or meningitis) without sufficient information to separate data for the nonsyndromic/acquired cohort. Two authors (F.G.R. and E.N.B.P.) independently evaluated eligibility and extracted data.

Figure 1. PRISMA Flowchart



Articles excluded at the title and abstract level were studies performed before 1978, a study population with a mean/median age older than 18 years, reviews, and studies published in languages other than English. Articles excluded after full-text review or during data extraction included those with mixed categories of hearing loss that had no separate data for unilateral sensorineural hearing loss, articles that listed only the total number of abnormal imaging scans without specification of the abnormalities found, and articles without sufficient information to separate data for the entire nonsyndromic and/or acquired hearing loss cohort.

### Data Extraction and Endpoint Definition

The following data were extracted using a piloted and standardized data extraction form: (1) bibliographic details, (2) study period, (3) patient characteristics, (4) hearing loss characteristics, (5) number of patients with CT and/or MRI, (6) imaging modality, and (7) frequency and type of findings on CT and/or MRI. To standardize outcomes, cochleovestibular abnormalities were categorized according to the classification described by Sennaroglu and Bajin<sup>20</sup> (eTable 2 in the Supplement). In addition to the description of the CT and/or MRI findings, the findings were classified as having a likely or unlikely association with USNHL. The association was assessed using the Bradford Hill criteria<sup>21,22</sup> and is based on current literature as outlined in eTable 3 in the Supplement. Because the goal of imaging is to detect abnormalities associated with hearing loss, we excluded findings without a likely association with hearing loss to determine the corrected yield.

### Definition of Patient Benefit and Harm

The potential patient benefit was defined as all information acquired by imaging that contributes to an improved outcome either by altering management or providing information on prognosis or hereditary factors. Potential harms of imaging were radiation exposure for CT and sedation for MRI. In our definition of benefit, we chose to exclude “potential benefit of receiving information on the etiology of hearing loss without further consequence for the mentioned aspects treatment, heredity, or prognosis.”<sup>23</sup> We also focused on individual harms associated with CT and MRI rather than on the societal burden of resource use.

### Risk of Bias

Each selected study was assessed for risk of bias according to 3 domains. The first domain was patient selection. We considered studies to have a low risk of bias if the authors clearly described the proportion of patients with USNHL who underwent imaging

and the reasons for imaging. All other studies were considered to have an intermediate risk of bias. The second domain was the blinding of outcome assessment. We considered studies to have low risk of bias if reviewers of imaging data were blinded to the side and degree of the hearing loss. All other studies were considered to have an intermediate risk of bias. The last domain was classification of inner ear abnormalities. We considered studies to have a low risk of bias if a broadly accepted classification system, such as the system proposed by Sennaroglu and Bajin,<sup>20</sup> was used.

### Data Analysis

The primary outcome was the prevalence (expressed as proportion) of inner ear abnormalities. We grouped outcomes according to finding and imaging modality (CT, MRI, and CT and/or MRI). For the latter category, patients had CT and/or MRI, but the detected abnormalities and/or the total number of patients with USNHL with imaging were not specified per imaging modality. In studies describing the results of both CT and MRI, findings were excluded if less than 20 patients were evaluated with a specific modality.

We pooled proportions using a random effects model; a fixed effect model was used when there were fewer than 4 studies per subgroup because the between-study variability cannot be estimated reliably in this case. To evaluate the heterogeneity among studies,  $I^2$  statistics were used. All statistical analysis was performed using Stata version 14 (StataCorp).

## Results

### Study Characteristics

The search yielded 1562 articles; 18 studies were included (Figure 1).<sup>10,11,14,18,24-37</sup> Studies were published between 1991 and 2017. Study details are described in Table 1 and more comprehensively in eTable 4 in the Supplement. Indications for

Table 1. Study Characteristics of Included Studies<sup>a</sup>

Source	Eligibility Criteria	Mean/Median Age at Study Enrollment/ Diagnosis, y	Extent of Hearing Loss	No. of Patients With USNHL Imaging/ Total USNHL Study Population (%)	Diagnostic Yield Study, % (No. of Abnormal Scans/Total Patients With Imaging)	Identified Abnormalities <sup>b</sup>
<b>CT Studies</b>						
Bamiou et al, <sup>24</sup> 1999	Inclusion: Presence of USNHL	11.1 (Mean, population)	Mild: 2, moderate: 6, severe: 5, profound: 22	35/35 (100)	31 (11/35)	1 Absent cochlea, 1 Mondini, 4 EVA (2 bilateral), 1 narrow internal acoustic meatus, 3 labyrinthitis ossificans, 1 dysplasia of petrous bones, large bulbous internal auditory meatus and dilatation of left lateral SCC in syndromic case
Brookhouser et al, <sup>25</sup> 1991	Inclusion: Children with USNHL Exclusion: Asymmetric, conductive, and mixed hearing loss	8.8 (Mean, diagnosis), 7.8 (median, diagnosis)	Borderline: 43, mild: 51, moderate: 40, severe: 19, profound: 81, anacusis: 50, high frequency: 90	57/324 (18)	18 (10/57)	2 Malformation of cochlea and SCC, 2 EVA, 3 widening and shortening of IAC, 2 fractures of temporal bone
Cama et al, <sup>26</sup> 2012	Inclusion: Children with UHL not attributable to external ear malformation and/or otitis media with effusion Exclusion: Physical examination suggestive of a syndromic condition	4.6 (Mean, diagnosis)	Mild: 0, moderate: 3, severe: 1, profound: 16	20/20 (100)	45 (9/20)	1 Cochleovestibular hypoplasia, 1 common cavity, 5 EVA, 2 labyrinthitis ossificans, 4 jugular bulb variants (high riding, diverticulum, dehiscence)
Ghogomu et al, <sup>18</sup> 2014	Inclusion: Children with USNHL or unilateral mixed hearing loss	Pre-USNHS: 4.4 and Post-USNHS: 2.6 (mean, diagnosis)	Mild: 10, moderate: 34, severe: 22, profound: 68	95/134 (70)	28 (27/95)	16 EVA, 8 cochlear/labyrinthine dysplasia, 5 small IAC, 4 enlarged cochlear aqueduct, 2 temporal bone fracture, 4 other, 9 patients with multiple findings
Haffey et al, <sup>30</sup> 2013	Inclusion: Children <18 y with USNHL Exclusion: Conductive component in hearing loss or bilateral involvement	5.6 (Mean, diagnosis)	Unknown	61/89 (69)	33 (20/61)	15 EVA (1 bilateral), 8 Mondini, 3 SCC dehiscence, 5 mastoiditis/chronic otitis media, 1 high jugular bulb, 1 cholesteatoma, 1 bony deformation of incus
Kono et al, <sup>31</sup> 2008	Inclusion: Children between 0-15 y who underwent CT of the temporal bone Exclusion: Underlying trauma, illness (meningitis, systemic disease), or poor quality images	5.0 (Mean, age at enrollment)	Unknown	160/160 (100)	71 (114/160)	5 Common cavity, 2 cochlear aplasia/hypoplasia, 19 IP, 13 vestibular and/or SCC dysplasia without cochlear malformation, 3 EVA, 72 BCNC stenosis
Lin et al, <sup>11</sup> 2017	Inclusion: Patients with pediatric-onset unilateral or asymmetric SNHL Exclusion: Patients >50 y, with conductive or mixed hearing loss, and without complete history in medical records	9.1 (Mean, age at enrollment)	Residual hearing: 40, scaled out levels: 50	55/92 (60)	31 (17/55)	3 IP1, 1 IP2, 5 Dilated vestibule, 3 SCC dysplasia, 0 EVA, 0 common cavity, 15 cochlear aperture stenosis
Masuda et al, <sup>32</sup> 2013	Inclusion: USNHL patients with temporal bone CT aged 0-15 y Exclusion: Patients with middle ear diseases and abnormalities, conductive and combined hearing loss, and obviously acquired hearing loss	4.3 (Mean, diagnosis)	Mild: 6, moderate: 13, severe: 7, profound: 43	69/69 (100)	67 (46/69)	0 Cochlear aplasia, 2 common cavity deformity, 1 cochlear hypoplasia, 11 IP, 5 vestibular/SCC malformations, 20 narrow IAC, 1 enlarged IAC, 1 absent IAC, 2 EVA, 32 CNC stenosis
Nakano et al, <sup>33</sup> 2013	Inclusion: Children with congenital hearing loss with temporal bone CT scans	4.0 (Median, age at enrollment)	Unknown	56/56 (100)	63 (35/56)	28 Small or absent BCNC, 9 small IAC (all in combination with small or absent BCNC), 10 inner ear abnormality, 3 EVA

(continued)

Table 1. Study Characteristics of Included Studies<sup>a</sup> (continued)

Source	Eligibility Criteria	Mean/Median Age at Study Enrollment/ Diagnosis, y	Extent of Hearing Loss	No. of Patients With USNHL Imaging/ Total USNHL Study Population (%)	Diagnostic Yield Study, % (No. of Abnormal Scans/Total Patients With Imaging)	Identified Abnormalities <sup>b</sup>
Shusterman et al, <sup>35</sup> 1992	Inclusion: Children with SNHL	6.8 (Mean, age at enrollment)	Unknown	38/38 (100)	8 (3/38)	1 Left temporal arachnoid cyst, 1 asymmetry of posterior wall of IAC (with negative MRI), 1 enlarged left endolymphatic duct
Simons et al, <sup>14</sup> 2006	Inclusion: All children with unilateral or bilateral asymmetric SNHL Exclusion: Conductive component was not included in the risk analysis in children with mixed hearing loss	5.9 (Mean, diagnosis)	Unknown	83/147 (57)	35 (29/83)	17 EVA (at least 1 bilateral), 8 IEA, 2 CPA arachnoid cyst, 2 small IAC, 1 noncommunicating hydrocephalus, 1 enlarged fourth ventricle
Song et al, <sup>36</sup> 2009	Inclusion: Children <15 y with USNHL Exclusion: Conductive component in hearing loss, previous temporal bone trauma, or otologic surgical intervention	7.9 (Mean, age at enrollment)	Mild: 10, moderate: 39, severe: 29, profound: 244	322/322 (100)	29 (93/322)	1 Complete labyrinth aplasia, 1 cochlear aplasia, 6 common cavity, 10 IPI, 2 cochlear hypoplasia, 28 IP2 (9 bilateral), 22 narrow IAC, 1 bilateral wide IAC, 4 SCC dysplasia (1 bilateral), 17 EVA (7 bilateral)
Van Beeck Calkoen et al, <sup>10</sup> 2017	Inclusion: Children with USNHL who underwent imaging to gain insight into the cause of the hearing loss Exclusion: Children with pure conductive hearing loss and those who did not undergo imaging at parental request or because imaging had no additional value	3.7 (Mean, diagnosis)	Mild: 9, moderate: 16, severe: 14, profound: 62	70/102 (69)	36 (25/70)	1 Ossification oval window, 4 obliteration/ossification, 1 common cavity, 1 IPI, 6 IP2, 1 cochlear aplasia, 2 cochlear hypoplasia, 4 isolated EVA, 2 isolated SCC (1 in combination with IAC/cochlear nerve abnormality), 2 vestibular hypoplasia, 2 narrow IAC, 0 cochlear hematoma, 0 brain abnormalities
Yi et al, <sup>37</sup> 2013	Inclusion: Children with nonsyndromic USNHL Exclusion: Patients with history of underlying illnesses or inadequate imaging	11.0 (Mean, age at enrollment)	Unknown	51/51 (100)	63 (32/51)	29 BCNC stenosis, 12 IAC stenosis (all in combination with BCNC), 4 hypoplasia of the cochlea basal turn, 9 hypoplasia of the cochlear middle turn, 3 EVA
<b>MRI Studies</b>						
Clemmens et al, <sup>27</sup> 2013	Inclusion: All children with USNHL who underwent MRI Exclusion: Insufficient quality of MRI scan	5.6 (Mean, diagnosis)	Unknown	128/128 (100)	50 (64/128)	33 CND, of them 6 had other inner ear anomalies (3 with bilateral SCC dysplasia, 2 ipsilateral EVA and 1 ipsilateral common cavity), 32 EVA, of them 3 bilateral, and 2 with CND, 3 bilateral SCC dysplasia (in combination with CND), 1 common cavity (with CND), 1 vestibule/SCC dysplasia alone
Haffey et al, <sup>30</sup> 2013	See CT section	See CT section	See CT section	30/89 (34)	30 (9/30)	1 EVA, 1 Mondini, 1 asymmetric IAC, 2 mastoiditis/chronic otitis media, 1 Chiari malformation, 1 Large jugular bulb, 1 brain cyst, 1 leukomalacia, 1 subdural hematoma
Simons et al, <sup>14</sup> 2006	See CT section	See CT section	See CT section	40/147 (27)	25 (10/40)	4 EVA, 1 IEA, 2 Hypoplastic nerve, 1 CPA arachnoid cyst, 1 glioma in pons, 1 Chiari malformation
Van Beeck Calkoen et al, <sup>10</sup> 2017	See CT section	See CT section	See CT section	52/102 (51)	58 (30/52)	1 Cochlear hematoma, 1 IP2, 2 cochlear hypoplasia, 6 isolated EVA, 1 isolated SCC, 2 vestibular hypoplasia (1 in combination with IAC/cochlear nerve abnormality), 9 cochlear nerve hypoplasia, 0 ossification oval window, 0 obliteration/ossification, 0 common cavity, 0 IPI, 0 cochlear aplasia

(continued)

Table 1. Study Characteristics of Included Studies<sup>a</sup> (continued)

Source	Eligibility Criteria	Mean/Median Age at Study Enrollment/ Diagnosis, y	Extent of Hearing Loss	No. of Patients With USNHL Imaging/ Total USNHL Study Population (%)	Diagnostic Yield Study, % (No. of Abnormal Scans/Total Patients With Imaging)	Identified Abnormalities <sup>b</sup>
CT/MRI Studies						
Friedman et al, <sup>28</sup> 2013	Inclusion: Children with >70 dB hearing loss at 500, 1000, and 2000 Hz Exclusion: Presence of conductive component	Unknown	Only cases with severe to profound hearing loss	49/84 (58)	41 (20/49)	7 EVA, of them 4 bilateral, 5 malformed SCC of them 3 bilateral, 4 hypoplastic cochlea of them 1 bilateral, 2 IP1, 2 fractures, 1 IP2, 1 bilateral malformed IAC
Gruber et al, <sup>29</sup> 2017	Inclusion: Children from 0-15 y with newly diagnosed USNHL Exclusion: Any diagnosed syndrome, mixed SNHL, conductive hearing loss, asymmetrical bilateral SNHL and inconsistent audiometry results	4.3 (Mean, diagnosis)	Mild: 17, moderate: 15, severe: 7, profound: 15	43/60 (72)	37 (16/43)	10 Absent or abnormal cochlear nerve on MRI or CT (6 cases on MRI, 4 small cochlear aperture or narrow IAC), 4 cochlear dysplasia (1 on MRI, 3 on CT), 3 with EVA on CT (1 Ipsilateral, 1 bilateral, 1 contralateral)
Paul et al, <sup>34</sup> 2017	Inclusion: All children with USNHL Exclusion: Children with conductive hearing loss	4.4 (Mean, diagnosis)	Mild: 1, moderate: 10, severe: 15, profound: 54	76/80 (95)	41 (29/71)	6 IAC stenosis, 2 vestibular malformations, 6 cochleovestibular malformation, 4 cochlear malformations, 24 cochlear nerve deficiency, 6 EVA

Abbreviations: BCNC, bony cochlear nerve canal; CPA, cerebellopontine angle; CT, computed tomography; dB, decibel; EVA, enlarged vestibular aqueduct; IAC, inner auditory canal; IEA, inner ear abnormality; MRI, magnetic resonance imaging; SCC, semicircular canal; SNHL, sensorineural hearing loss; UHL, unilateral hearing loss; UNHS, universal newborn hearing screening; USNHL, unilateral sensorineural hearing loss.

<sup>a</sup> See eTable 4 in the Supplement.

<sup>b</sup> See eTable 3 in the Supplement for assessment of association with hearing loss.

imaging were not specified in most studies. If mentioned, establishing the cause of USNHL was the most common reason for imaging. Four studies<sup>26,29,31,37</sup> excluded children with a dysmorphological syndrome, and 4 studies<sup>24,33-35</sup> allowed for exclusion of imaging results of children with a dysmorphological syndrome or infectious causes. In the remaining 10 studies,<sup>10,11,14,18,25,27,28,30,32,36</sup> less than 10% of the included study population were syndromic, or diagnosed with meningitis, CMV, or mumps, but the presented data were insufficient to exclude those participants. With the exception of 1 study<sup>28</sup> including only children with severe-to-profound USNHL, all studies included all grades of hearing impairment. Children not part of our target population were excluded from the study, including 1045 children who only had a CT, 188 children who only had an MRI, 108 children who were assessed with both modalities, and 163 children with a nonspecified imaging modality.

Most studies presented findings irrespective of their association with SNHL. Because the goal of imaging in SNHL is detection of abnormalities that are associated with hearing loss, we assessed the abnormalities' association with hearing loss as described in the Methods section. The resulting classification is presented in Figure 2.

Most studies reported on inner ear abnormalities in detail. Five studies reported on "inner ear abnormality" or "cochleovestibular malformations" without further specifications.<sup>14,18,25,33,35</sup>

### Pooled Yield of Imaging

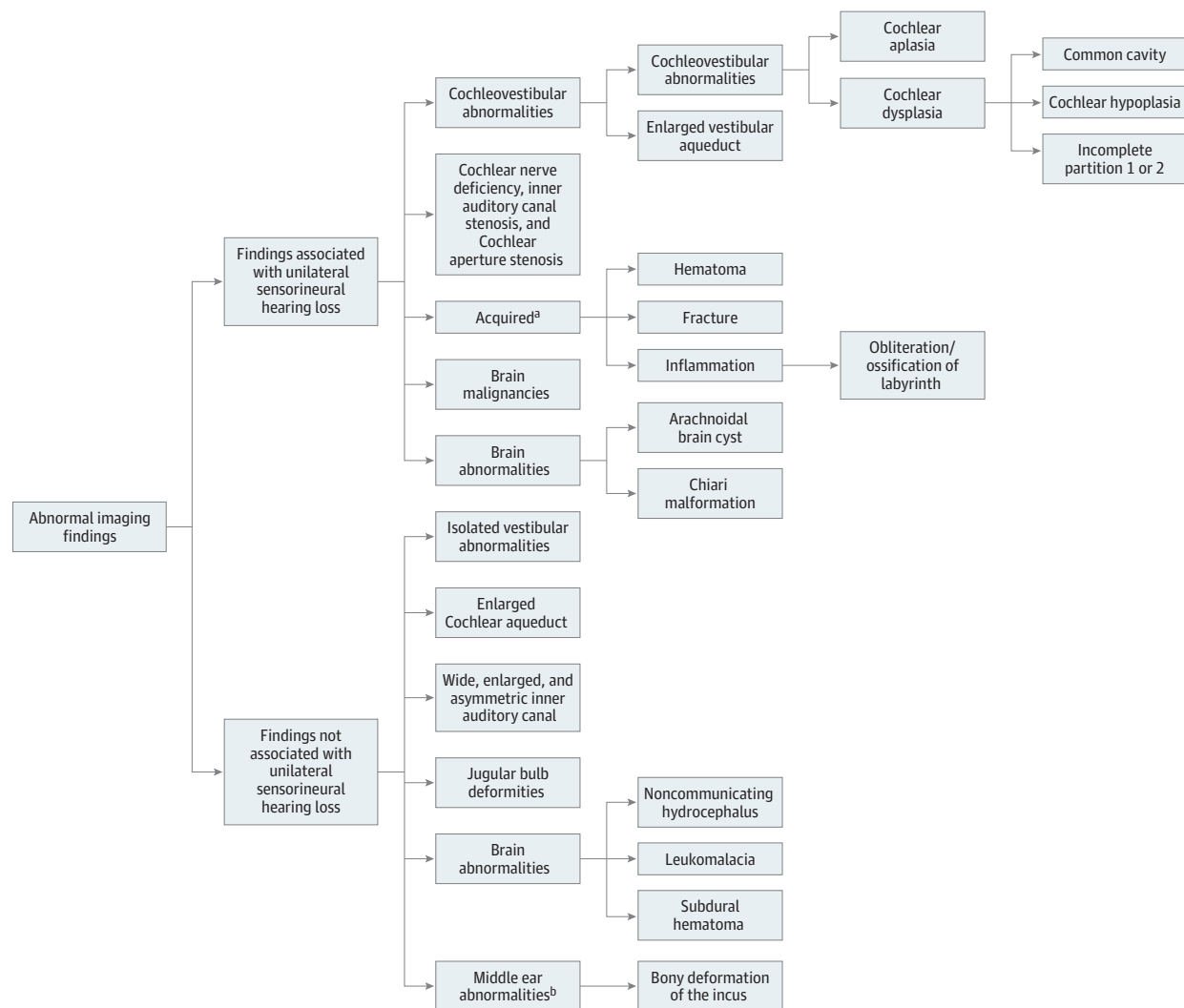
Figure 3 shows the abnormalities detected with imaging, excluding findings not associated with the cause of USNHL and those findings in children with a dysmorphological syndrome, CMV, mumps, or meningitis, when possible. The pooled yield was 37% (95% CI, 25%-48%) for CT (14 studies<sup>10,11,14,18,24-26,30-33,35-37</sup>;  $I^2 = 95%$ ) and 35% (95% CI, 22%-49%) for MRI (4 studies<sup>10,14,27,30</sup>;  $I^2 = 77%$ ).

### Frequently Detected Abnormalities (Pooled Frequencies)

Cochlear nerve deficiency (CND) was the most common abnormality found by MRI, with a frequency of 16% (95% CI, 3%-29%; 3 studies<sup>10,14,27</sup>). Cochlear nerve deficiency was the term used to describe both the complete absence of the cochlear nerve and different grades of cochlear nerve hypoplasia. The frequency of a cochlear aperture (CA), also known as cochlear nerve canal (CNC) stenosis, was 44% (95% CI, 36%-53%) (5 studies<sup>11,31-33,37</sup>;  $I^2$ , 66%). Cochlear aperture is the most common abnormality detected by CT. This percentage is higher than the overall yield because it was calculated over 5 studies<sup>11,31-33,37</sup> describing CA stenosis in detail. A stenotic or absent internal auditory canal (IAC) was detected with a pooled frequency of 9% (95% CI, 5%-14%) (CT, 8 studies<sup>10,14,18,24,32,33,36,37</sup>).

Pooled frequencies of cochleovestibular abnormalities (including EVA) were 19% for CT (95% CI, 14%-25%) and 16% for MRI (95% CI, 7%-25%) (MRI). The frequency of detection of cochlear abnormalities with CT and MRI was 14% (95% CI, 11%-18%) and 2% (95% CI, 0%-5%), respectively. Enlarged vestibular aqueducts were found with a frequency of 7% for CT (95% CI, 4%-11%) and 12% for MRI (95% CI, 3%-12%). The EVA

Figure 2. Classification of Abnormalities Detected on Imaging



The association between specific abnormalities and hearing loss was assessed using the literature and the Bradford Hill criteria.<sup>21,22</sup> For background and references, see eTable 3 in the Supplement.

<sup>a</sup> Outside our target population.

<sup>b</sup> Associated with conductive hearing loss.

was found bilaterally with a frequency of 21%. Various definitions for EVA were used in the studies, with a vestibular aqueduct larger than 1.5 mm at midpoint being the most applied definition. Two studies used a more stringent definition of a vestibular aqueduct larger than 2.0 mm at midpoint and found 0 of 55 (0%)<sup>10</sup> and 3 of 160 (2%)<sup>31</sup> EVAs with CT and MRI, respectively. One study applied a definition of vestibular aqueduct size greater than 0.9 mm at midpoint and found 32 EVAs in 128 cases (25%).<sup>27</sup>

The frequency of acquired causes of hearing loss (cochlear inflammation, temporal bone fractures and cochlear hematoma) was 5% with CT and 3% with MRI. In these cases, medical history and physical examination can be indicative of an acquired cause of the hearing loss. Proportions of other observed abnormalities, as well as their association with hearing loss and the clinical consequences of these abnormalities are presented in Table 2 and eTable 5 in the Supplement.

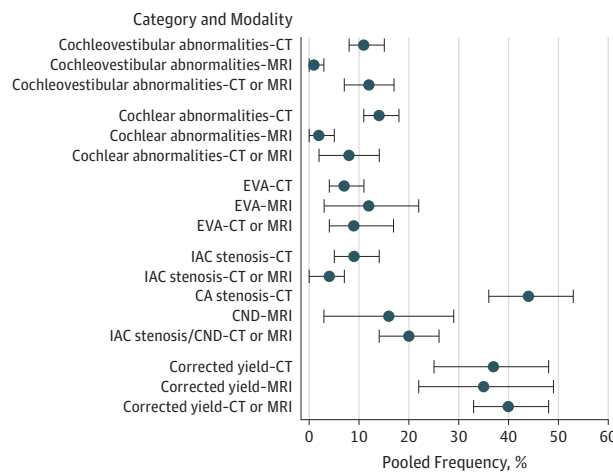
## Discussion

To our knowledge, this is the first meta-analysis that critically reviews the diagnostic yield of imaging of the temporal bone in children with USNHL, with an emphasis on the clinical relevance of imaging findings. By focusing on unexplained isolated hearing loss in children and on abnormalities with an association with hearing loss we aimed to provide a better estimation of the prevalence of relevant inner ear abnormalities in patients with USNHL in whom medical history and physical examination did not contribute to the diagnosis. The pooled data show an overall diagnostic yield of 37% for CT and 35% for MRI.

### Limitations

There was a wide range in the reported diagnostic yield and heterogeneity among the studies. None of the studies

**Figure 3. Abnormalities Detected by Imaging of the Temporal Bone**



The Figure shows the pooled frequencies for the main classification groups, frequently detected abnormalities, and yield based on imaging modality. The circles represent the pooled frequencies, and the 95% CIs are represented by the error bars. The number of studies included to calculate specific frequencies depends on the detail in which abnormalities were presented in the respective studies. See eTable 4 in the Supplement for the details of all the included studies<sup>10,11,14,18,24-37</sup> and eTable 5 in the Supplement for frequency calculations. CA indicates cochlear aperture; CND, cochlear nerve deficiency; CT, computed tomography; EVA, enlarged vestibular aqueduct; IAC, inner auditory canal; MRI, magnetic resonance imaging.

provided a clear description of the selection process for performing imaging in patients with USNHL. Because the studies reflect clinical practice, imaging decisions likely depend on physicians' and parents' preference. Given that none of the studies in this meta-analysis described the clinical decision process for imaging, the generalizability of our findings could be limited, especially for patients with severe hearing loss who undergo imaging. Furthermore, improved imaging techniques and the description of new entities seemingly related to hearing loss through the years, such as CA stenosis and CND, will have introduced heterogeneity. Finally, measurement errors and the use of different inner ear classifications and definitions can contribute to the heterogeneity. In accordance with previous authors,<sup>20</sup> this limitation underlines the importance of universally accepted and correct classification of inner ear abnormalities.

**Detected Abnormalities and Association With Hearing Loss**

Historically, EVA has been the most commonly reported inner ear abnormality in early onset hearing loss.<sup>14</sup> However, our meta-analysis showed that the prevalence of CND and CA stenosis is higher (16% and 44%, respectively) in this selected group with USNHL. Both CA stenosis and IAC stenosis detected by CT are suggestive for CND because the cochlear nerve passes through these bony structures. Jang et al<sup>67</sup> analyzed the correlation between CNC and hearing status and found that the width of the CNC was smaller in the affected ears of children with USNHL compared with the nonaffected ears. In addition, no cutoff value exists for CNC size to discriminate affected ears from nonaffected ears. In 2 separate studies,

Adunka and colleagues have assessed the status of the IAC<sup>68</sup> and the CA<sup>69</sup> in children with USNHL with a likely CND. The authors concluded that both IAC stenosis (<3 mm) and CA stenosis (<1.4 mm) are unreliable surrogate markers for the cochlear nerve integrity and therefore recommended MRI as the primary imaging modality in children with severe to profound hearing loss. The term CND has been used to describe both an absent as well as a hypoplastic cochlear nerve, which is detected on MRI. There is no uniform definition for cochlear nerve hypoplasia,<sup>70</sup> and discriminatory power varies depending on the definition used.

Although there is an association between hearing loss and stenotic bony structures (IAC and CA) found on CT and hearing loss and CN hypoplasia and aplasia found on MRI, the proposed cutoffs or definitions do not provide high discriminatory power.<sup>27,71-73</sup> Ambiguous terminology, such as CND, should be avoided. Research determining the diagnostic accuracy of different cutoff values for CN hypoplasia, IAC stenosis, and CA stenosis by performing imaging in participants with normal hearing vs those with USNHL could facilitate correct interpretation of imaging findings. Taking this into consideration, the relevance of the high frequency of CA stenosis (44%) must be interpreted with care. Similarly, a universal definition for EVA with concomitant diagnostic accuracy for hearing loss would be helpful.

The association between semicircular canal (SCC) abnormalities and hearing loss is controversial. Yamashita et al<sup>49</sup> have concluded that there is no correlation between an isolated small lateral SCC and SNHL. However, in the setting of Waardenburg syndrome, the SNHL is associated with SCC dysplasia.<sup>74</sup> Given this controversy and the fact that we focused on children without dysmorphological syndrome, we classified SCC dysplasia as an abnormality without a likely association with hearing loss.

**Clinical Implications: Benefit-Harm Balance**

Several studies have briefly mentioned that imaging acquisition barely has clinical implications,<sup>24,28</sup> but imaging is still justified because of its high diagnostic yield. However, clinical benefit should be the foremost consideration when performing diagnostic tests. There is no consensus on the exact definition of the benefit of diagnostics. Diagnostic information is beneficial if it positively influences patient outcome through altered management. However, prognostic and genetic information can confer benefit as well.<sup>23</sup> Also, knowing the exact anatomical cause of hearing loss might be valued positively by patients and parents. It is crucial to emphasize that no curative treatment is available for any of the abnormalities detected with imaging of the temporal bone (Table 2). Specific anatomical information only provides additional value if cochlear implantation is considered for USNHL because the outcomes of cochlear implantation are less favorable in patients with CND and cochlear aplasia.<sup>75-78</sup> Given that cochlear implantation is currently not standard treatment for USNHL, imaging in children with USNHL is performed to provide information about prognosis, hereditary factors, and the specific cause of hearing loss. With regard to inner ear abnormalities found on imaging, only

Table 2. Frequencies and Clinical Consequences of Abnormalities Detected by Temporal Bone Imaging in Children With USNHL

Imaging Findings	Frequency, % (95% CI)			Association With Hearing Loss <sup>a</sup>	Available Treatment	Additional Risk of Progression of Hearing Loss	Information About Heredity	Reference No.
	CT	MRI	CT/MRI					
Corrected yield	37 (25-48)	35 (22-49)	40 (33-48)					
Cochleovestibular abnormalities (including EVA)	19 (14-25)	16 (7-25)	20 (13-28)	Likely	No	Only for isolated EVA and IP2	No	20
Cochlear abnormalities	12 (8-17)	2 (1-5)	8 (2-14)	Likely	No	No	No	20
Cochlear aplasia	0 (0-1)	0 (0-7)	NA	Likely	No	No	No	20
Cochlear dysplasia	12 (8-17)	1 (0-3)	12 (5-18)	Likely	No	No	No	20
Common cavity	2 (1-3)	0 (0-2)	NA	Likely	No	No	No	20
Cochlear hypoplasia	3 (0-7)	4 (1-13)	8 (3-13)	Likely	No	No	No	20
IP type 1 or 2	10 (7-13)	2 (0-6)	6 (2-17)	Likely	No	No	No	20
IP type 1 <sup>b</sup>	3 (1-4)	0 (0-7)	4 (1-14)	Likely	No	No	No	20
IP type 2 <sup>c</sup>	6 (2-10)	2 (0-6)	2 (0-11)	Likely	No	Progression occurs. Association with head trauma and common cold has been suggested, in absence of substantial evidence.	No	20,38
EVA <sup>c,d</sup>	7 (4-11)	12 (3-22)	9 (4-14)	Likely	No	Progression occurs. Association with head trauma and common cold has been suggested, in absence of substantial evidence.	SLC26A4 mutation: in unilateral EVA 10%-13% monoallelic, if bilateral EVA 30% monoallelic, 15%-30% biallelic	7,8,38-48
Vestibular abnormalities (isolated)	6 (2-10)	4 (1-6)	4 (1-8)	Unlikely	NA	NA	No	49
Stenosis or absence of IAC <sup>e</sup>	9 (5-14)	NA	4 (0-7)	Likely, depending on cut-off	No	No	No	20
Enlarged, asymmetric, wide and malformed IAC	1 (0-2)	3 (1-17)	NA	Unlikely	NA	NA	No	50
Cochlear aperture stenosis <sup>f</sup>	44 (36-53)	NA	NA	Likely, depending on cut-off	No	No	No	20
Cochlear nerve deficiency	NA	16 (3-29)	20 (14-26)	Likely, depending on definition	No	No	No	20
Jugular bulb deformities	2 (0-5)	3 (1-17)	NA	Unlikely	NA	NA	No	51,52
Brain malignancies	NA	0 (0-3)	NA	Likely, if affecting auditory pathway	Possibly	Yes	Possibly	14,53
Brain abnormalities	0 (0-3)	9 (4-14)	5 (1-16)	Depends on exact abnormality <sup>a</sup>	NA	NA	NA	54-64
Middle ear malformations	2 (0-4)	0 (0-7)	2 (0-12)	Associated with conductive hearing loss	NA	NA	NA	20
Acquired causes	5 (2-7)	3 (0-6)	4 (1-14)	Likely, but outside scope	Yes	Yes	No	65,66

Abbreviations: CT, computed tomography; EVA, enlarged vestibular aqueduct; IAC, inner auditory canal; IP, incomplete partition; MRI, magnetic resonance imaging; NA, not applicable; USNHL, unilateral sensorineural hearing loss.

<sup>a</sup> See eTable 3 in the Supplement for details.

<sup>b</sup> Chance of recurrent meningitis, during attack of otitis media.<sup>20</sup>

<sup>c</sup> No evidence supporting advice to wear helmets when playing sports or to

avoid contact sports to prevent progression.

<sup>d</sup> Various definitions of EVA were used: >0.9 mm, >1.5 mm and >2.0 mm.

<sup>e</sup> Different definitions of stenosis were applied: <2.0 mm, <3.0 mm and <3.8 mm. The most applied definition was <3.0 mm.

<sup>f</sup> Different definitions of stenosis were applied: <1.4 mm, <1.5 mm and <1.7 mm. The most frequently used definition was <1.5 mm.

detection of EVA, which occurs in approximately 10% of USNHL, provides prognostic and hereditary information. Patients with EVA show more progression and fluctuation of hearing loss than those without EVA,<sup>7</sup> bilateral EVA and/or fluctuating hearing loss is particularly associated with a risk of progression.<sup>7,39</sup> Furthermore, progression has been associated with minor head trauma.<sup>40</sup> However, there is no convincing evidence substantiating this association, and a recent meta-analysis demonstrated no correlation between

hearing loss and head trauma in EVA.<sup>38</sup> Importantly, current literature does not provide evidence for effective preventive measures for progression of hearing loss in children with EVA. Consequently, there is no evidence that the detection of EVA could contribute to improved hearing outcome.

Enlarged vestibular aqueduct has been associated with pathogenic mutations in *SLC26A4* and appears to be inherited as a recessive trait.<sup>41,42</sup> However, in patients with unilateral EVA, biallelic mutations have only been found

sporadically,<sup>41-45</sup> whereas monoallelic mutations have been reported in 10% to 13% of patients.<sup>7,41</sup> The fact that only 1 mutation can be found could be explained by a second undetected mutation in *SLC26A4*, a mutation in another gene related to deafness, or mutations in multiple genes related to deafness combined with environmental factors (multifactorial inheritance).<sup>42,46,47</sup> Biallelic mutations in *SLC26A4* are detected in at least 15% of patients with bilateral EVA,<sup>7</sup> although this might be a conservative estimate given that data combining laterality of EVA, laterality of hearing loss, and genotype are rare. Monoallelic mutations are detected in about 25% of patients with bilateral EVA.<sup>7</sup> Percentages are based on predominantly Caucasian populations. Several children with biallelic mutations are likely to develop Pendred syndrome, which is characterized by EVA, hearing loss, and euthyroid goiter, with euthyroid goiter usually manifesting in the second or third decade of life.<sup>7,43,48</sup> Considering that (1) approximately 10% of the patients with USNHL have EVA, (2) approximately 20% of these patients have bilateral EVA, and (3) at least 15% of patients with bilateral EVA carry biallelic *SLC26A4* mutations, an estimated 0.3% (10% × 20% × 15%) of the total population of children with USNHL carry biallelic *SLC26A4* mutations and are at risk for Pendred syndrome.

Compared with other inner ear abnormalities, incomplete partition type 2 also carries an increased risk of progression of hearing loss, similar to isolated EVA.<sup>20</sup> In incomplete partition 2, the middle and apical turns of the cochlea coalesce to form a cystic apex accompanied by EVA and possibly a dilated vestibule.<sup>20</sup>

An important question is how often imaging reveals rare malignant tumors. In one study<sup>14</sup> a pons glioma was reported, without further data on symptoms or physical examination. However, in general, the probability of an intracranial tumor is very low.<sup>79</sup> It is even more unlikely that USNHL is the sole manifestation in the setting of rare malignant tumors. This may explain why none of the studies included in the meta-analysis mentioned detection of malignant tumors as a reason for imaging. In conclusion, with the exception of EVA, abnormalities found on temporal bone imaging do not provide additional information on prognosis or heredity.

The harms of imaging involve radiation exposure for CT and the need for sedation in young children who undergo MRI. An increased risk of developing cancer has been attributed to radiation exposure through CT. The radiation effect decreases with increasing age.<sup>80,81</sup> In our experience, contem-

porary CT scans use a radiation dose of 0.4 mSv in children younger than 12 months compared with 4.5 mSv in the original publication,<sup>82</sup> which will likely translate to a lower cancer risk. Sedation for MRI is usually not necessary when a child is old enough to lie still during the MRI. One single anesthetic procedure before the age of 4 years does not lead to an increased risk of learning or behavioral problems, but multiple exposures are reported to do so.<sup>83-87</sup>

Thus, to mitigate the risks, imaging can be postponed. The potential consequences of postponing imaging to an older age or refraining from imaging include a delayed and/or missed diagnosis of EVA in approximately 10% of patients with USNHL and therefore no additional prognostic information and a delayed or missed diagnosis of Pendred syndrome in less than 1%. Regarding information on recurrence risk, the potential consequence would be delayed and/or missed information in about 2% of children with USNHL and unilateral EVA ( $0.8 \times 0.10$  [frequency of unilateral EVA in USNHL] ×  $0.10$  [10% detected mutation in *SLC26A4*] = 1%) or bilateral EVA ( $0.2 \times 0.10$  [frequency of bilateral EVA in USNHL] ×  $0.4$  [40% detected mutation in *SLC26A4*] = 1%) under the assumption of a recessive mode of inheritance and in patients with monoallelic mutations.<sup>41,42</sup>

## Conclusions

With this study, we want to spark the discussion about patient outcomes associated with imaging findings in children with USNHL. Evaluating the diagnostic yield and consequences of imaging has demonstrated that imaging performed as part of the routine workup for patients with USNHL does not provide information that alters management or gives insight into prognosis or hereditary causes in most cases and therefore does not warrant strong recommendations. Physicians may assume that parents and patients are reassured by knowing the exact anatomical cause of hearing loss, despite the fact that this information does not change the natural course of the condition. However, imaging with this sole purpose is a preference-sensitive decision. Therefore, we suggest a shared decision-making approach to help elucidate these preferences after providing the relevant information of advantages and disadvantages of imaging, as opposed to presenting imaging as a part of routine care in the diagnostic assessment of children with USNHL.

### ARTICLE INFORMATION

**Accepted for Publication:** January 21, 2019.

**Published Online:** April 4, 2019.  
doi:10.1001/jamaoto.2019.0121

**Author Contributions:** Dr Ropers and Ms Pham had full access to all of the data in the study and take responsibility for the integrity of the data and the accuracy of the data analysis. Dr Ropers and Ms Pham contributed equally as co-first authors.  
**Study concept and design:** All authors.  
**Acquisition, analysis, or interpretation of data:** Ropers, Pham, Kant, Rotteveel, Verbist, Dekkers.  
**Drafting of the manuscript:** Ropers, Pham,

Rotteveel, Verbist, Dekkers.

**Critical revision of the manuscript for important intellectual content:** All authors.

**Statistical analysis:** Ropers, Pham, Dekkers.  
**Obtained funding:** Rings.

**Administrative, technical, or material support:** Ropers.

**Study supervision:** Ropers, Kant, Rotteveel, Rings, Verbist, Dekkers.

**Conflict of Interest Disclosures:** Dr Verbist reported other financial support from Advanced Bionics and Cochlear outside the submitted work. No other disclosures were reported.

### REFERENCES

- Lieu JE. Unilateral hearing loss in children: speech-language and school performance. *B-ENT*. 2013;(suppl 21):107-115.
- White KR. Early hearing detection and intervention programs: opportunities for genetic services. *Am J Med Genet A*. 2004;130A(1):29-36. doi:10.1002/ajmg.a.30048
- Lieu JE, Tye-Murray N, Fu Q. Longitudinal study of children with unilateral hearing loss. *Laryngoscope*. 2012;122(9):2088-2095. doi:10.1002/lary.23454

4. Bess FH, Tharpe AM. Unilateral hearing impairment in children. *Pediatrics*. 1984;74(2):206-216.
5. Bess FH, Dodd-Murphy J, Parker RA. Children with minimal sensorineural hearing loss: prevalence, educational performance, and functional status. *Ear Hear*. 1998;19(5):339-354. doi:10.1097/00003446-199810000-00001
6. Schmitz J, West KP Jr, Khatri SK, et al. Vitamin A supplementation in preschool children and risk of hearing loss as adolescents and young adults in rural Nepal: randomised trial cohort follow-up study. *BMJ*. 2012;344(7841):d7962. doi:10.1136/bmj.d7962
7. Greinwald J, DeAlarcon A, Cohen A, et al. Significance of unilateral enlarged vestibular aqueduct. *Laryngoscope*. 2013;123(6):1537-1546. doi:10.1002/lary.23889
8. Goderis J, Keymeulen A, Smets K, et al. Hearing in children with congenital cytomegalovirus infection: results of a longitudinal study. *J Pediatr*. 2016;172:110-115.e2. doi:10.1016/j.jpeds.2016.01.024
9. Fowler KB, Boppana SB. Congenital cytomegalovirus (CMV) infection and hearing deficit. *J Clin Virol*. 2006;35(2):226-231. doi:10.1016/j.jcv.2005.09.016
10. van Beeck Calkoen EA, Sanchez Aliaga E, Merkus P, et al. High prevalence of abnormalities on CT and MR imaging in children with unilateral sensorineural hearing loss irrespective of age or degree of hearing loss. *Int J Pediatr Otorhinolaryngol*. 2017;97:185-191. doi:10.1016/j.ijporl.2017.04.002
11. Lin PH, Hsu CJ, Lin YH, et al. Etiologic and audiologic characteristics of patients with pediatric-onset unilateral and asymmetric sensorineural hearing loss. *JAMA Otolaryngol Head Neck Surg*. 2017;143(9):912-919. doi:10.1001/jamaoto.2017.0945
12. Preciado DA, Lim LH, Cohen AP, et al. A diagnostic paradigm for childhood idiopathic sensorineural hearing loss. *Otolaryngol Head Neck Surg*. 2004;131(6):804-809. doi:10.1016/j.otohns.2004.06.707
13. Preciado DA, Lawson L, Madden C, et al. Improved diagnostic effectiveness with a sequential diagnostic paradigm in idiopathic pediatric sensorineural hearing loss. *Otol Neurotol*. 2005;26(4):610-615. doi:10.1097/01.mao.0000178133.89353.1d
14. Simons JP, Mandell DL, Arjmand EM. Computed tomography and magnetic resonance imaging in pediatric unilateral and asymmetric sensorineural hearing loss. *Arch Otolaryngol Head Neck Surg*. 2006;132(2):186-192. doi:10.1001/archotol.132.2.186
15. Parry DA, Booth T, Roland PS. Advantages of magnetic resonance imaging over computed tomography in preoperative evaluation of pediatric cochlear implant candidates. *Otol Neurotol*. 2005;26(5):976-982. doi:10.1097/01.mao.0000185049.61770.da
16. McClay JE, Booth TN, Parry DA, Johnson R, Roland P. Evaluation of pediatric sensorineural hearing loss with magnetic resonance imaging. *Arch Otolaryngol Head Neck Surg*. 2008;134(9):945-952. doi:10.1001/archotol.134.9.945
17. Lin JW, Chowdhury N, Mody A, et al. Comprehensive diagnostic battery for evaluating sensorineural hearing loss in children. *Otol Neurotol*. 2011;32(2):259-264. doi:10.1097/MAO.0b013e31820160fa
18. Ghogomu N, Umansky A, Lieu JE. Epidemiology of unilateral sensorineural hearing loss with universal newborn hearing screening. *Laryngoscope*. 2014;124(1):295-300. doi:10.1002/lary.24059
19. Valvassori GE, Clemis JD. The large vestibular aqueduct syndrome. *Laryngoscope*. 1978;88(5):723-728. doi:10.1002/lary.1978.88.5.723
20. Sennaroglu L, Bajin MD. Classification and current management of inner ear malformations. *Balkan Med J*. 2017;34(5):397-411. doi:10.4274/balkanmedj.2017.0367
21. Fedak KM, Bernal A, Capshaw ZA, Gross S. Applying the Bradford Hill criteria in the 21st century: how data integration has changed causal inference in molecular epidemiology. *Emerg Themes Epidemiol*. 2015;12:14. doi:10.1186/s12982-015-0037-4
22. Hill AB. The environment and disease: association or causation? *Proc R Soc Med*. 1965;58:295-300.
23. Kole A, Faurisson F. *The Voice of 12,000 Patients: Experiences and Expectations of Rare Disease Patients on Diagnosis and Care in Europe: A Report Based on the EurodisCare3 Surveys*. Paris, France: EuroDis; 2009.
24. Bamiou DE, Savy L, O'Mahoney C, Phelps P, Sirimanna T. Unilateral sensorineural hearing loss and its aetiology in childhood: the contribution of computerised tomography in aetiological diagnosis and management. *Int J Pediatr Otorhinolaryngol*. 1999;51(2):91-99. doi:10.1016/S0165-5876(99)00261-X
25. Brookhouser PE, Worthington DW, Kelly WJ. Unilateral hearing loss in children. *Laryngoscope*. 1991;101(12 Pt 1):1264-1272. doi:10.1002/lary.5541011202
26. Cama E, Inches I, Muzzi E, et al. Temporal bone high-resolution computed tomography in non-syndromic unilateral hearing loss in children. *ORL J Otorhinolaryngol Relat Spec*. 2012;74(2):70-77. doi:10.1159/000335586
27. Clemmens CS, Guidi J, Caroff A, et al. Unilateral cochlear nerve deficiency in children. *Otolaryngol Head Neck Surg*. 2013;149(2):318-325. doi:10.1177/0194599813487681
28. Friedman AB, Guillory R, Ramakrishnaiah RH, et al. Risk analysis of unilateral severe-to-profound sensorineural hearing loss in children. *Int J Pediatr Otorhinolaryngol*. 2013;77(7):1128-1131. doi:10.1016/j.ijporl.2013.04.016
29. Gruber M, Brown C, Mahadevan M, Neeff M. Concomitant imaging and genetic findings in children with unilateral sensorineural hearing loss. *J Laryngol Otol*. 2017;131(8):688-695. doi:10.1017/S002225117001219
30. Haffey T, Fowler N, Anne S. Evaluation of unilateral sensorineural hearing loss in the pediatric patient. *Int J Pediatr Otorhinolaryngol*. 2013;77(6):955-958. doi:10.1016/j.ijporl.2013.03.015
31. Kono T. Computed tomographic features of the bony canal of the cochlear nerve in pediatric patients with unilateral sensorineural hearing loss. *Radiat Med*. 2008;26(3):115-119. doi:10.1007/s11604-007-0204-9
32. Masuda S, Usui S, Matsunaga T. High prevalence of inner-ear and/or internal auditory canal malformations in children with unilateral sensorineural hearing loss. *Int J Pediatr Otorhinolaryngol*. 2013;77(2):228-232. doi:10.1016/j.ijporl.2012.11.001
33. Nakano A, Arimoto Y, Matsunaga T. Cochlear nerve deficiency and associated clinical features in patients with bilateral and unilateral hearing loss. *Otol Neurotol*. 2013;34(3):554-558. doi:10.1097/MAO.0b013e3182804b31
34. Paul A, Marlin S, Parodi M, et al. Unilateral sensorineural hearing loss: medical context and etiology. *Audiol Neurootol*. 2017;22(2):83-88. doi:10.1159/000474928
35. Shusterman D, Handler SD, Marsh RR, Bilaniuk L, Tom LW. Usefulness of computed tomographic scan in the evaluation of sensorineural hearing loss in children. *Arch Otolaryngol Head Neck Surg*. 1992;118(5):501-503. doi:10.1001/archotol.1992.01880050047012
36. Song JJ, Choi HG, Oh SH, Chang SO, Kim CS, Lee JH. Unilateral sensorineural hearing loss in children: the importance of temporal bone computed tomography and audiometric follow-up. *Otol Neurotol*. 2009;30(5):604-608. doi:10.1097/MAO.0b013e3181ab9185
37. Yi JS, Lim HW, Kang BC, Park SY, Park HJ, Lee KS. Proportion of bony cochlear nerve canal anomalies in unilateral sensorineural hearing loss in children. *Int J Pediatr Otorhinolaryngol*. 2013;77(4):530-533. doi:10.1016/j.ijporl.2012.12.031
38. Alemi AS, Chan DK. Progressive hearing loss and head trauma in enlarged vestibular aqueduct: a systematic review and meta-analysis. *Otolaryngol Head Neck Surg*. 2015;153(4):512-517. doi:10.1177/0194599815596343
39. Noordman BJ, van Beeck Calkoen E, Witte B, Govertts T, Hensen E, Merkus P. Prognostic factors for sudden drops in hearing level after minor head injury in patients with an enlarged vestibular aqueduct: a meta-analysis. *Otol Neurotol*. 2015;36(1):4-11.
40. Jackler RK, De La Cruz A. The large vestibular aqueduct syndrome. *Laryngoscope*. 1989;99(12):1238-1242. doi:10.1288/00005537-198912000-00006
41. Chattaraj P, Reimold FR, Muskett JA, et al. Use of *SLC26A4* mutation testing for unilateral enlargement of the vestibular aqueduct. *JAMA Otolaryngol Head Neck Surg*. 2013;139(9):907-913. doi:10.1001/jamaoto.2013.4185
42. Choi BY, Stewart AK, Madeo AC, et al. Hypo-functional *SLC26A4* variants associated with nonsyndromic hearing loss and enlargement of the vestibular aqueduct: genotype-phenotype correlation or coincidental polymorphisms? *Hum Mutat*. 2009;30(4):599-608. doi:10.1002/humu.20884
43. Pryor SP, Madeo AC, Reynolds JC, et al. *SLC26A4*/PDS genotype-phenotype correlation in hearing loss with enlargement of the vestibular aqueduct (EVA): evidence that Pendred syndrome and non-syndromic EVA are distinct clinical and genetic entities. *J Med Genet*. 2005;42(2):159-165. doi:10.1136/jmg.2004.024208
44. Jonard L, Niasme-Grare M, Bonnet C, et al. Screening of *SLC26A4*, *FOX11* and *KCNJ10* genes in unilateral hearing impairment with ipsilateral enlarged vestibular aqueduct. *Int J Pediatr*

- Otolaryngol.* 2010;74(9):1049-1053. doi:10.1016/j.ijporl.2010.06.002
45. Madden C, Halsted M, Meinzen-Derr J, et al. The influence of mutations in the *SLC26A4* gene on the temporal bone in a population with enlarged vestibular aqueduct. *Arch Otolaryngol Head Neck Surg.* 2007;133(2):162-168. doi:10.1001/archotol.133.2.162
46. Pique LM, Brennan ML, Davidson CJ, Schaefer F, Greinwald J Jr, Schrijver I. Mutation analysis of the *SLC26A4*, *FOX11* and *KCNJ10* genes in individuals with congenital hearing loss. *PeerJ.* 2014;2:e384. doi:10.7717/peerj.384
47. Nonose RW, Lezrovitz K, de Mello Auricchio MTB, Batisso AC, Yamamoto GL, Mingroni-Netto RC. Mutation analysis of *SLC26A4* (Pendrin) gene in a Brazilian sample of hearing-impaired subjects. *BMC Med Genet.* 2018;19(1):73. doi:10.1186/s12881-018-0585-x
48. Sugiura M, Sato E, Nakashima T, et al. Long-term follow-up in patients with Pendred syndrome: vestibular, auditory and other phenotypes. *Eur Arch Otorhinolaryngol.* 2005;262(9):737-743. doi:10.1007/s00405-004-0884-z
49. Yamashita K, Yoshiura T, Hiwatashi A, et al. Sensorineural hearing loss: there is no correlation with isolated dysplasia of the lateral semi-circular canal on temporal bone CT. *Acta Radiol.* 2011;52(2):229-233. doi:10.1258/ar.2010.100324
50. McClay JE, Tandy R, Grundfast K, et al. Major and minor temporal bone abnormalities in children with and without congenital sensorineural hearing loss. *Arch Otolaryngol Head Neck Surg.* 2002;128(6):664-671. doi:10.1001/archotol.128.6.664
51. Hourani R, Carey J, Yousem DM. Dehiscence of the jugular bulb and vestibular aqueduct: findings on 200 consecutive temporal bone computed tomography scans. *J Comput Assist Tomogr.* 2005;29(5):657-662. doi:10.1097/01.rct.0000175499.34213.5d
52. Kupfer RA, Hoesli RC, Green GE, Thorne MC. The relationship between jugular bulb-vestibular aqueduct dehiscence and hearing loss in pediatric patients. *Otolaryngol Head Neck Surg.* 2012;146(3):473-477. doi:10.1177/0194599811430045
53. Usami SI, Kitoh R, Moteki H, et al. Etiology of single-sided deafness and asymmetrical hearing loss. *Acta Otolaryngol.* 2017;137(sup565):S2-S7. doi:10.1080/00016489.2017.1300321
54. Simons JP, Ruscetta MN, Chi DH. Sensorineural hearing impairment in children with Chiari I malformation. *Ann Otol Rhinol Laryngol.* 2008;117(6):443-447. doi:10.1177/000348940811700607
55. Haktanir A, Yücedağ F, Kaçar E, et al. Association of Chiari I malformation and cerebellar ectopia with sensorineural hearing loss. *J Craniofac Surg.* 2013;24(4):1153-1155. doi:10.1097/SCS.0b013e318293f840
56. Sperling NM, Franco RA Jr, Milhorat TH. Otolgic manifestations of Chiari I malformation. *Otol Neurotol.* 2001;22(5):678-681. doi:10.1097/00129492-200109000-00020
57. Chao TK. Middle cranial fossa arachnoid cysts causing sensorineural hearing loss. *Eur Arch Otorhinolaryngol.* 2005;262(11):925-927. doi:10.1007/s00405-005-0921-6
58. Pollice PA, Bhatti NI, Niparko JK. Imaging quiz case 1. Posterior fossa arachnoid cyst. *Arch Otolaryngol Head Neck Surg.* 1997;123(7):764-765.
59. Haberkamp TJ, Monsell EM, House WF, Levine SC, Piazza L. Diagnosis and treatment of arachnoid cysts of the posterior fossa. *Otolaryngol Head Neck Surg.* 1990;103(4):610-614. doi:10.1177/019459989010300414
60. Jallo GI, Woo HH, Meshki C, Epstein FJ, Wisoff JH. Arachnoid cysts of the cerebellopontine angle: diagnosis and surgery. *Neurosurgery.* 1997;40(1):31-37.
61. Ottaviani F, Neglia CB, Scotti A, Capaccio P. Arachnoid cyst of the cranial posterior fossa causing sensorineural hearing loss and tinnitus: a case report. *Eur Arch Otorhinolaryngol.* 2002;259(6):306-308.
62. Bohrer PS, Chole RA. Unusual lesions of the internal auditory canal. *Am J Otol.* 1996;17(1):143-149.
63. Hadley MN, Graham TW, Daspi CP, Spetzler RF. Otolaryngologic manifestations of posterior fossa arachnoid cysts. *Laryngoscope.* 1985;95(6):678-681. doi:10.1288/00005537-198506000-00009
64. Boudewyns AN, Declau F, De Ridder D, Parizel PM, van den Ende J, Van de Heyning PH. Case report: "auditory neuropathy" in a newborn caused by a cerebellopontine angle arachnoid cyst. *Int J Pediatr Otorhinolaryngol.* 2008;72(6):905-909. doi:10.1016/j.ijporl.2008.02.003
65. Bhandi A, Carpineta L, Al Qassabi B, et al. Hearing loss in pediatric temporal bone fractures: Evaluating two radiographic classification systems as prognosticators. *Int J Pediatr Otorhinolaryngol.* 2018;109:158-163. doi:10.1016/j.ijporl.2018.04.005
66. Douglas SA, Sanli H, Gibson WP. Meningitis resulting in hearing loss and labyrinthitis ossificans - does the causative organism matter? *Cochlear Implants Int.* 2008;9(2):90-96.
67. Jang JH, Kim JH, Yoo JC, et al. Implication of bony cochlear nerve canal on hearing in patients with congenital unilateral sensorineural hearing loss. *Audiol Neurootol.* 2012;17(5):282-289. doi:10.1159/000338821
68. Adunka OF, Roush PA, Teagle HF, et al. Internal auditory canal morphology in children with cochlear nerve deficiency. *Otol Neurotol.* 2006;27(6):793-801. doi:10.1097/01.mao.0000227895.34915.94
69. Adunka OF, Jewells V, Buchman CA. Value of computed tomography in the evaluation of children with cochlear nerve deficiency. *Otol Neurotol.* 2007;28(5):597-604. doi:10.1097/01.mao.0000281804.36574.72
70. Freeman SR, Sennaroglu L. Management of cochlear nerve hypoplasia and aplasia. *Adv Otorhinolaryngol.* 2018;81:81-92.
71. Stjernholm C, Muren C. Dimensions of the cochlear nerve canal: a radioanatomic investigation. *Acta Otolaryngol.* 2002;122(1):43-48. doi:10.1080/00016480252775724
72. Lim CH, Lim JH, Kim D, Choi HS, Lee DH, Kim DK. Bony cochlear nerve canal stenosis in pediatric unilateral sensorineural hearing loss. *Int J Pediatr Otorhinolaryngol.* 2018;106:72-74. doi:10.1016/j.ijporl.2018.01.015
73. Pagarkar W, Gunny R, Saunders DE, Yung W, Rajput K. The bony cochlear nerve canal in children with absent or hypoplastic cochlear nerves. *Int J Pediatr Otorhinolaryngol.* 2011;75(6):764-773. doi:10.1016/j.ijporl.2011.02.017
74. Oysu C, Oysu A, Aslan I, Tinaz M. Temporal bone imaging findings in Waardenburg's syndrome. *Int J Pediatr Otorhinolaryngol.* 2001;58(3):215-221. doi:10.1016/S0165-5876(01)00443-8
75. Kutz JW Jr, Lee KH, Isaacson B, Booth TN, Sweeney MH, Roland PS. Cochlear implantation in children with cochlear nerve absence or deficiency. *Otol Neurotol.* 2011;32(6):956-961. doi:10.1097/MAO.0b013e31821f473b
76. Witte RJ, Lane JJ, Driscoll CL, et al. Pediatric and adult cochlear implantation. *Radiographics.* 2003;23(5):1185-1200. doi:10.1148/rg.235025046
77. Valero J, Blaser S, Papsin BC, James AL, Gordon KA. Electrophysiologic and behavioral outcomes of cochlear implantation in children with auditory nerve hypoplasia. *Ear Hear.* 2012;33(1):3-18. doi:10.1097/AUD.0b013e3182263460
78. Buchman CA, Teagle HF, Roush PA, et al. Cochlear implantation in children with labyrinthine anomalies and cochlear nerve deficiency: implications for auditory brainstem implantation. *Laryngoscope.* 2011;121(9):1979-1988.
79. Arora RS, Alston RD, Eden TO, Estlin EJ, Moran A, Birch JM. Age-incidence patterns of primary CNS tumors in children, adolescents, and adults in England. *Neuro Oncol.* 2009;11(4):403-413. doi:10.1215/15228517-2008-097
80. Mathews JD, Forsythe AV, Brady Z, et al. Cancer risk in 680,000 people exposed to computed tomography scans in childhood or adolescence: data linkage study of 11 million Australians. *BMJ.* 2013;346:f2360. doi:10.1136/bmj.f2360
81. Pearce MS, Salotti JA, Little MP, et al. Radiation exposure from CT scans in childhood and subsequent risk of leukaemia and brain tumours: a retrospective cohort study. *Lancet.* 2012;380(9840):499-505. doi:10.1016/S0140-6736(12)60815-0
82. National Research Council Staff. *Health Risks from Exposure to Low Levels of Ionizing Radiation.* Washington, DC: The National Academies Press; 2006.
83. Wilder RT, Flick RP, Sprung J, et al. Early exposure to anesthesia and learning disabilities in a population-based birth cohort. *Anesthesiology.* 2009;110(4):796-804. doi:10.1097/01.anes.0000344728.34332.5d
84. Flick RP, Katusic SK, Colligan RC, et al. Cognitive and behavioral outcomes after early exposure to anesthesia and surgery. *Pediatrics.* 2011;128(5):e1053-e1061. doi:10.1542/peds.2011-0351
85. Sprung J, Flick RP, Wilder RT, et al. Anesthesia for cesarean delivery and learning disabilities in a population-based birth cohort. *Anesthesiology.* 2009;111(2):302-310. doi:10.1097/ALN.0b013e3181ad4f41
86. Sprung J, Flick RP, Katusic SK, et al. Attention-deficit/hyperactivity disorder after early exposure to procedures requiring general anesthesia. *Mayo Clin Proc.* 2012;87(2):120-129. doi:10.1016/j.mayocp.2011.11.008
87. Yu CK, Yuen VM, Wong GT, Irwin MG. The effects of anaesthesia on the developing brain: a summary of the clinical evidence. *F1000 Res.* 2013;2:166. doi:10.12688/f1000research.2-166.v1