

Universiteit
Leiden
The Netherlands

Hemodynamic adaptation in complicated monochorionic twin pregnancies

Eschbach, S.J.

Citation
Eschbach, S. J. (2021, June 15). *Hemodynamic adaptation in complicated monochorionic twin pregnancies*. Retrieved from https://hdl.handle.net/1887/3188565

Version:	Publisher's Version
License:	Licence agreement concerning inclusion of doctoral thesis in the Institutional Repository of the University of Leiden
Downloaded from:	https://hdl.handle.net/1887/3188565

Note: To cite this publication please use the final published version (if applicable).

Cover Page

Universiteit Leiden



The handle https://hdl.handle.net/1887/3188565 holds various files of this Leiden University dissertation.

Author: Eschbach, S.J.
Title: Hemodynamic adaptation in complicated monochorionic twin pregnancies
Issue Date: 2021-06-15

Hemodynamic adaptation in complicated monochorionic twin pregnancies

S.J. Eschbach

Hemodynamic adaptation in complicated monochorionic twin pregnancies.
Phd thesis, University of Leiden, the Netherlands

ISBN: 978-94-6416-558-6
Illustrations: Linda van Soolingen / lindavansoolingen.nl
Layout and printing: Ridderprint /www.ridderprint.nl

© 2021 S.J. Eschbach
All rights reserved. No part of this publication may be reproduced or transmitted in any form or by any means, electronic or mechanical, including photocopy, recording, or any information storage or retrieval system, without permission in writing by the author.

The research prescribed in this thesis was performed at the Department of Obstetrics and Prenatal Diagnosis of the Leiden University Medical Center, the Netherlands.

Financial support by the Dutch Heart Foundation for the publication of this thesis is gratefully acknowledged.

The printing of this thesis was financially supported by the department of Obstetrics of the Leiden University Medical Center, Walaeus University Library, Reinier de Graaf Gasthuis, Chipsoft and Canon Medical Systems.

Hemodynamic adaptation in complicated monochorionic twin pregnancies

Proefschrit

ter verkrijging van

de graad van doctor aan de Universiteit Leiden,

op gezag van rector magnificus prof. dr. ir. H. Bijl,

volgens besluit van het college voor promoties

te verdedigen op dinsdag 15 juni 2021

klokke 16:15 uur

door

Sientje Johanna Eschbach

Geboren te Zwolle

In 1983

Promotor:	Prof. Dr. D. Oepkes
Co-promotor:	Mw. Dr. M.C. Haak
Leden promotiecommissie:	Prof. Dr. N.A. Blom
	Prof. Dr. L. Lewi, University Hospitals, KU Leuven, België
	Dr. L. Herling, Karolinska Institutet, Stockholm, Zweden

Financial support by the Dutch Heart Foundation for the publication of this thesis is gratefully acknowledged.

Onderzoek alles en houd het goede vast

Voor Noëlle en Mirthe

TABLE OF CONTENTS

Chapter I	General Introduction	9
Part 1 Fetal demise		
Chapter II	The value of echocardiography and Doppler in the prediction of fetal demise after laser coagulation for TTTS: a systematic review and meta-analysis *(Prenat Diagn, 2019;39(10):838-847).*	27
Chapter III	Prediction of single fetal demise after laser therapy for twin-twin transfusion syndrome *(Ultrasound Obstet and Gynecol, 2016;47(3):356-62).*	49
Chapter IV	Abnormal umbilical artery flows in uncomplicated monochorionic diamniotic twins in relation to proximate cord insertion; a possible harmful combination? *(Prenat Diagn, 2020;40(10):1284-1289).*	67
Part 2 Cardiac compromise		
Chapter V	Right Ventricular Outflow Tract Obstruction in complicated monochorionic twin pregnancy *(Ultrasound Obstet and Gynecol, 2017;49(6):737-753)*	83
Chapter VI	Acquired right ventricular outflow tract obstruction in twin-to-twin transfusion; a prospective longitudinal study *(Prenat Diagn, 2018;38(13):1013-1019).*	101
Chapter VII	Measurement of cardiac function by cardiac time intervals, applicability in normal pregnancy and twin-to-twin transfusion syndrome *(Journal of Echocardiogr, 2019;17(3):129-137).*	117
Chapter VIII	General discussion	135
Chapter IX	Summary	150
	Nederlandse samenvatting	156
APPENDICES	List of publications	166
	List of abbreviations	168
	Dankwoord	170
	Curriculum Vitae	173



CHAPTER I

General introduction



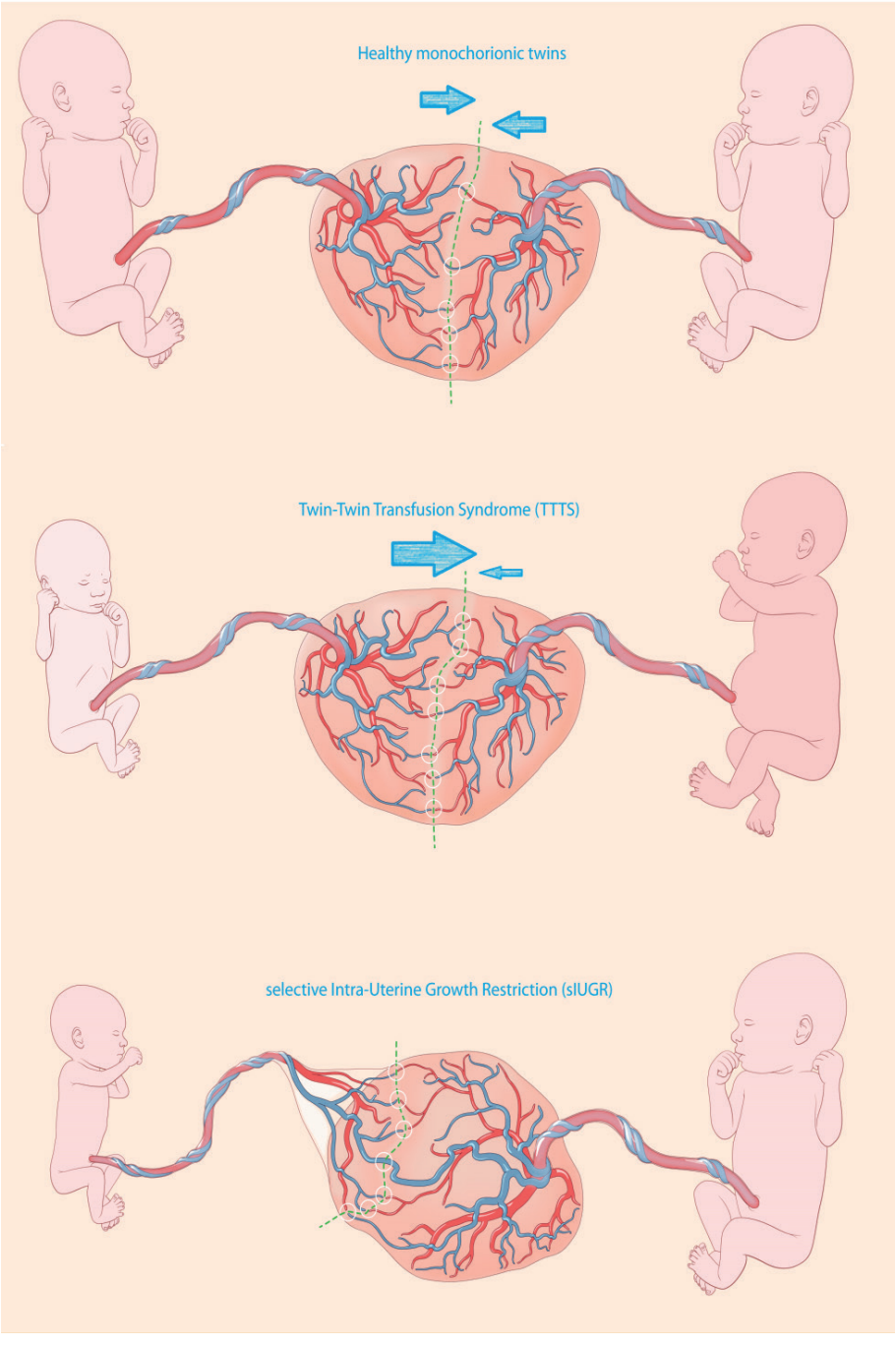
Healthy monochorionic twins
Twin-Twin Transfusion Syndrome (TTTS)
selective Intra-Uterine Growth Restriction (sIUGR)

Monochorionic pregnancies

Approximately 2% of all pregnancies in the Netherlands are multiple gestations, of which 0.3% of all pregnancies are monochorionic (MC) twin pregnancies.[1,2] MC twins have a perinatal mortality twice as high as dichorionic twins, and four times higher than singletons.[3,4] The increased risk for adverse pregnancy outcome derives mainly from the communicating vessels on the placental surface, that connect the fetal blood circulations to each other. These vascular anastomoses are present in nearly all monochorionic twin placentas.[5] Three types of anastomoses are identified (Figure 2). The arterio-venous (AV) anastomosis is most frequently present, which has unidirectional flow from one fetus to the other. The arterio-arterial (AA) anastomosis and veno-venous (VV) anastomosis have the possibility of bidirectional flow, and the direction of blood flow is dependent on the (blood) pressure gradient.[6,7]

Fetal cardio-placental circulation

The fetal circulation differs from the postnatal circulation, mainly because the lungs are not yet in use. For oxygenation, the fetus is dependant of a organ outside the body; the placenta. Once the blood is oxygenated, it is transported to the fetus via the umbilical vein and ductus venosus to enter the right atrium of the fetal heart. To bypass the pulmonary circulation of the fetal body, most of the oxygenated blood that enters the heart passes the foramen ovale or the ductus venosus directly into the left ventricle or the aorta. From there, it is transported the fetal body to oxygenate the end organs.

Because the fetal blood circulation contains a fetal and a placental part, abnormal placental resistance consequently influences fetal blood circulation and well-being.[8] In MC twins, a third component is added to the cardio-placental circulation: the shared blood circulation of the co-twin. The unique placental angioarchitecture with different types and sizes of anastomoses from one twin to the other, carry extraordinary hemodynamic challenges for the fetal heart, and causes specific complications in MC twins.

◂Figure 1. Possible complications of monochorionic pregnancies
Equal placental sharing and a balanced exchange of blood through the communicating vessels (anastomoses) are required for an uncomplicated course of the pregnancy (above). In case of unbalanced exchange of blood through the anastomosis, twin-to-twin transfusion syndrome (TTTS, middle) occurs. In case of unequal placental sharing, selective intrauterine growth restriction (sIUGR, below) takes place

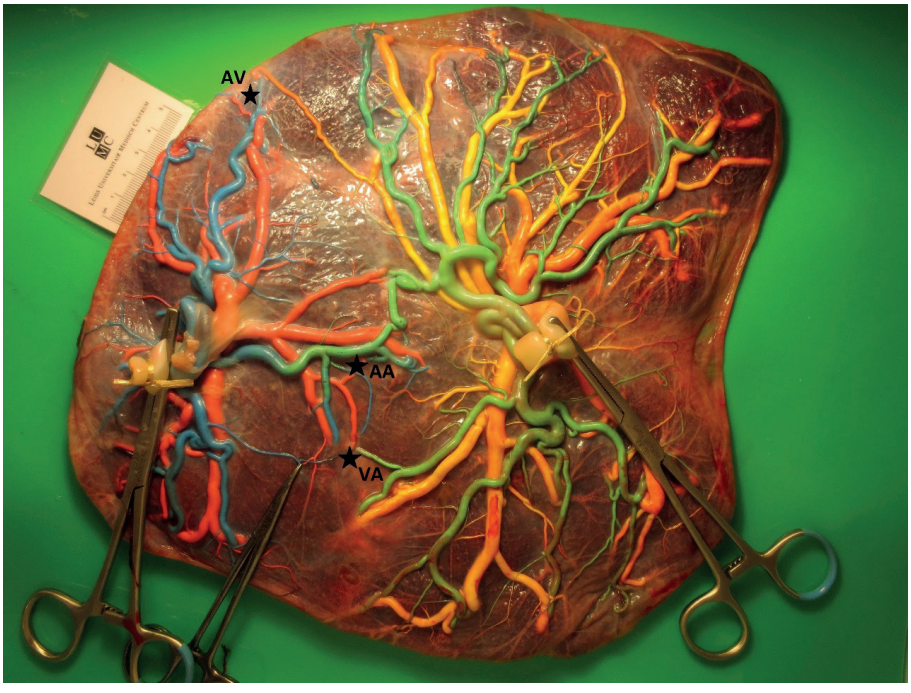

▲**Figure 2. Picture of a monochorionic twin placenta** injected with coloured dye. This placenta illustrates different types of anastomosis. AA = arterio-arterial anastomosis, AV = arterio-venous anastomosis

Complications in MC pregnancies

Common placenta related complications of MC pregnancies are twin-to-twin transfusion syndrome (TTTS) and selective intrauterine growth restriction (sIUGR). More seldom, spontaneous twin anaemia polycythemia sequence (TAPS), twin reversed arterial perfusion (TRAP) and conjoined twins are seen. This thesis focusses mainly on the hemodynamic challenges in TTTS and sIUGR.

Twin-to-twin transfusion syndrome

In about 10-15% of MC pregnancies, imbalanced blood flow over one or more AV-anastomosis leads to twin-to-twin transfusion syndrome. The staging of TTTS is currently based on ultrasonographic features, described by Quintero *et al*.[7] The overall mortality and morbidity rate is up to 90% if left untreated.[9] The current treatment is laser coagulation of the placental vascular anastomoses. The results of laser surgery for TTTS show >80% survival rate for at least one fetus.[10,11]

Selective intrauterine growth restriction

A disproportionate distribution of placental mass between the twins is the cause of sIUGR (Figure 2). sIUGR affects approximately 10% of MC twins, severe cases of sIUGR can result in spontaneous fetal demise of the smallest twin with subsequent hypoxia with cerebral damage or even secondary fetal demise of the larger twin.[12-14] Severity of disease is classified in the Gratacos staging system, according to umbilical artery Doppler flow in the smaller twin (Figure 6). Currently there is no treatment for sIUGR.

Cardiovascular adaptation in complicated MC twins

Prevalence of cardiac compromise

The current Quintero staging system only includes indirect signs of cardiac dysfunction, namely absent end-diastolic flow in the umbilical artery (Figure 3), abnormal a-wave in ductus venosus (Figure 4) and hydrops.[13] Up to 70% of TTTS recipients, however show direct signs of cardiac compromise at the time of diagnosis.[15-17] Even in early Quintero stages, myocardial hypertrophy, atrioventricular valve regurgitation and elevated myocardial performance index (Figure 5) is observed.[15,16,18,19] In studies that were performed in advanced stages of TTTS, more severe cardiomyopathy was found, such as prominent cardiomegaly (Figure 6) and massive atrioventricular regurgitation (Figure 7). Another finding is the absence of forward flow across the pulmonary valve, in some cases with excusive reversed direction of flow in the ductus arteriosus (Figure 8), reflecting right ventricular outflow tract obstruction (RVOTO). This can be attributed to either anatomical changes of the valve (anatomical stenosis or atresia), either the lack of pressure in the right ventricle during systole which prevents forward flow across the valve (functional atresia). RVOTO is leading to hydrops in 10-15% of cases.[17-20] RVOTO may be progressive during pregnancy and may require urgent pulmonary balloon valvuloplasty or surgery after birth.[20] The prevalence of severe postnatal RVOTO varies between 3 to 7% of all surviving TTTS recipients, which is significantly increased compared to only 0.6% of singletons.[20-22]

Pathophysiology of RVOTO

Several factors leading to right ventricular outflow tract obstruction in the recipient of TTTS have been suggested. An increase in cardiac preload leads to right ventricular hypertrophy and impaired cardiac function. Severe myocardial hypertrophy and cardiac dysfunction can cause decreased or absent flow across the pulmonary valve (functional atresia), which might lead to underdevelopment of the valve. [15,16,19,21,23,24] Besides that, endothelial damage caused by shear stress might eventually result in valve dysplasia, causing pulmonary valve stenosis. At the same time, the donor has inadequate placental return of blood volume which activates vasoactive mediators such as endothelin-1, renin, and angiotensin II.[25-28] Those vasoactive mediators are transfused to the recipients circulation, in which they have an adverse effect due to vasoconstriction in an already overloaded circulation.

Myocardial hypertrophy and the development of RVOTO is also described in the larger twin in MC pregnancies complicated with sIUGR.[29-31] It is suggested that cardiac abnormalities in the larger twin are caused by a hyperdynamic state due to the disproportion of the placental territory, and amplified by hemodynamic imbalances related to the presence of a large AA anastomosis and possible exchange of vasoactive mediators from the donor.[32]

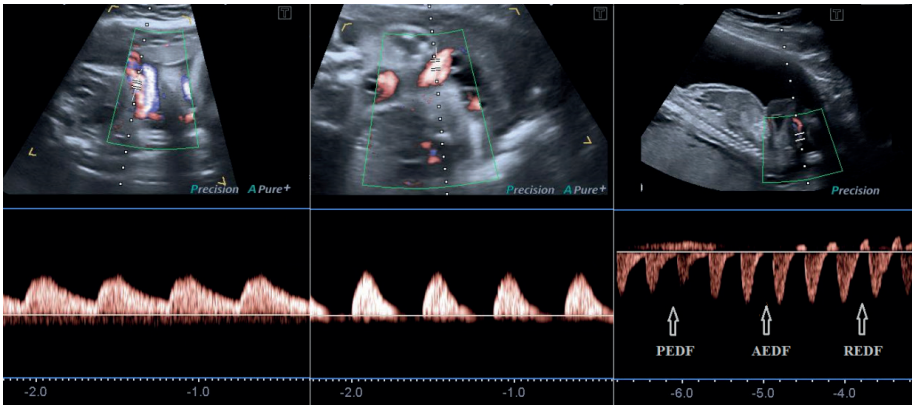

▲**Figure 3.** Different types of end diastolic flows over the umbilical artery; positive flow (Gratacos stage I, left), continuous absent flow (Gratacos stage II, middle) and intermittent positive, absent or reversed end diastolic flow (Gratacos stage III, right)

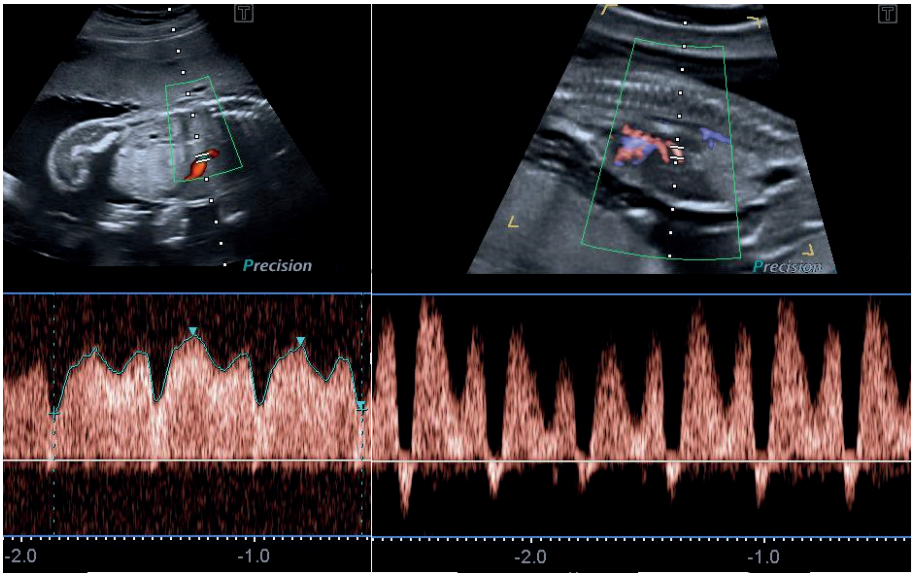

▲**Figure 4.** Normal flow (left) and reversed A-wave (right) in the ductus venosus

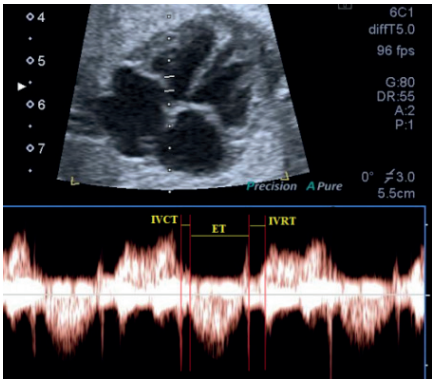

◄**Figure 5**. Myocardial Performance Index (MPI = [IVCT+IVRT]/ET) using conventional pulsed wave Doppler technique

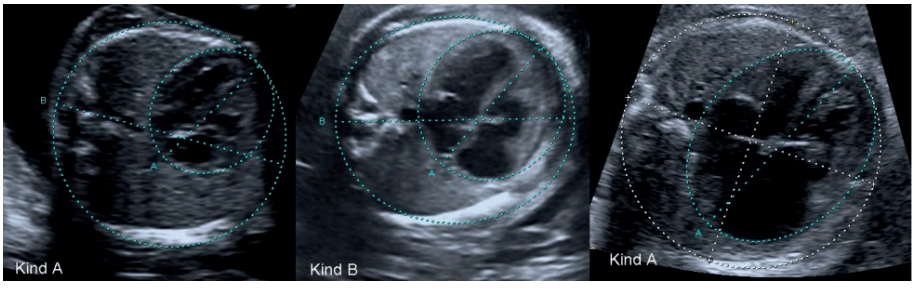

▲**Figure 6.** Normal cardiac size (right), cardiomegaly in a recipient (middle) and severe cardiomegaly with right atrial dilatation (right) due to severe tricuspid regurgitation in a recipient with RVOTO

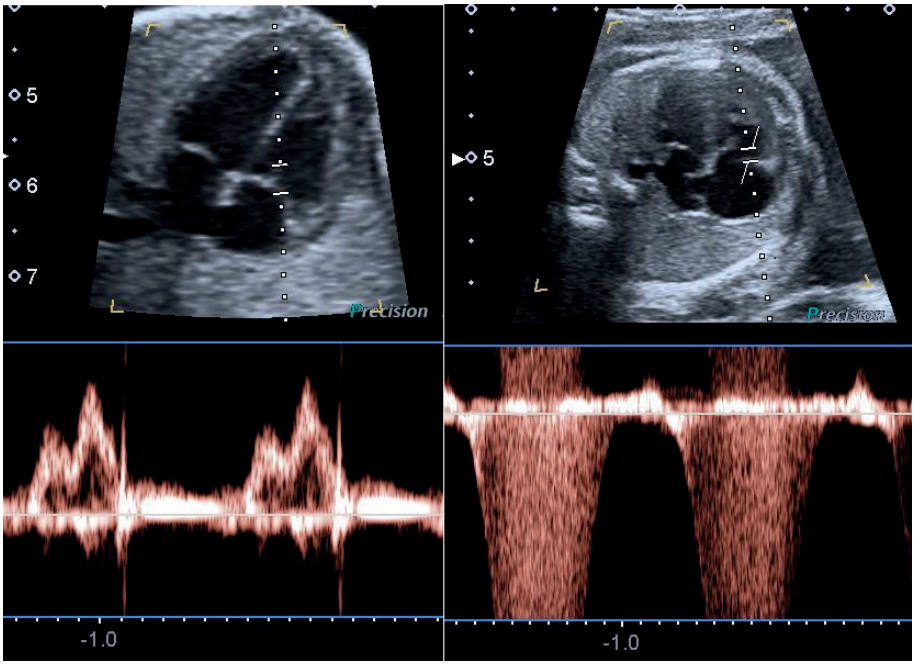

▲**Figure 7.** Normal Doppler flow over the tricuspid valve (right and severe tricuspid insufficiency with holosystolic regurgitation

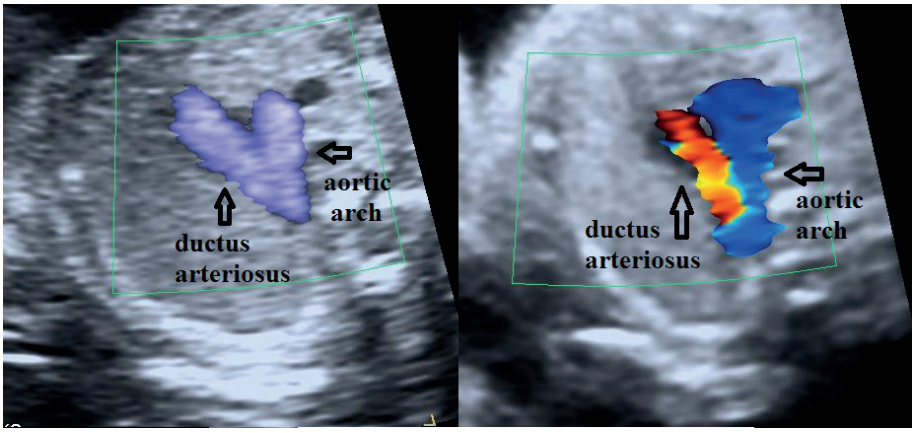

▲**Figure 8.** Normal V-sign (right) with antegrade flow over the ductus arteriosus, and right ventricular outflow tract obstruction (right) with retrograde flow over the ductus arteriosus.

Echocardiographic assessment in MC twins

The challenge of fetal echocardiography

Assessment of cardiac function is more challenging in the fetus than in adults. Firstly, the cardio-placental circulation is different than the cardio-respiratory circulation, and the fetal heart is smaller with an higher heart rate compared to postnatal life. Secondary, fetal position and fetal movements influences cardiac imaging highly. Finally, maternal factors such as high body mass index or maternal (breathing) movements may affect optimal scanning circumstances, and accompanying fetal electrocardiogram currently unable to establish. In TTTS pregnancies, fetal echocardiography is even more challenging due to polyhydramnios/anhydramnios, and often abundant fetal movements of the recipient.

Echocardiographic assessment techniques in monochorionic twins

In complicated MC twins, conventional pulsed-wave Doppler (PW) techniques are widely used to determine disease severity. PW-Doppler imaging of the umbilical artery and ductus venosus, as indirect signs of cardiac dysfunction, are included in staging of TTTS and sIUGR.[13,35] PW-Doppler is used as well to detect direct signs of cardiac deterioration such as atrioventricular valve regurgitation and increased myocardial performance index.

New ultrasonographic techniques such as speckle tracking technique, strain rate and color-coded Tissue Doppler Imaging are explored in fetal echocardiography.[34] Since the last decades these techniques have been used in adult echocardiography increasingly, but the clinical use in fetal echocardiography is still under investigation.[36,37] In TTTS, several studies have been done to evaluate speckle tracking and strain rate in recipient twins.[38-41] Right ventricular failure could be identified in recipients in all studies, but the feasibility was only 61%,[40] which prevents from implementation in daily clinical use.

In conclusion, fetuses in complicated monochorionic twins suffer serious hemodynamic challenges due to imbalanced blood flow through the communicating vessels in their shared placenta. They are at increased risk of developing cardiac dysfunction, followed by acquired heart diseases or eventually fetal demise. Fetoscopic laser

coagulation, which is the curative treatment for TTTS, reduces fetal demise drastically and is associated with a significant improvement of cardiac function. However, it does not prevent fetal demise or development of subsequent cardiac defects in all cases.[42] Echocardiographic assessment in complicated twin pregnancies is challenging, and new modalities to detect early cardiac dysfunction and predict fetal demise or development of severe RVOTO are still under investigation.

Aim and outline of this thesis

The general aim of the studies presented in this thesis was to gain more knowledge about hemodynamic adaptation of the fetal heart in complicated monochorionic twin pregnancies, in order to understand more of the pathways of abnormal cardiac development and fetal demise under these circumstances, which eventually could lead to better future care. In part one, we aimed to investigate possible risk factors for fetal demise after laser therapy for TTTS. Besides that, we investigated the consequence of proximate cord insertion on the fetal condition in otherwise uncomplicated MC pregnancies. In part two, we aimed to investigate the spectrum of RVOTO and aim to develop an prediction model for development of postnatal RVOTO. Lastly, we aimed to develop a new echocardiographic modality to identify fetal cardiac deterioriation. ***Chapter 1*** provides a general introduction that led to this thesis.

Part one – fetal demise

In ***Chapter 2*** we performed a systematic review and meta-analysis to compare preoperative ultrasonographic parameters between fetuses with and without fetal demise after laser surgery, in order to identify parameters predictive of demise. In ***Chapter 3*** we studied fetal demise in recipients as well as in donors after laser therapy for TTTS. We performed a retrospective cohort study, to determine independent factors associated with single fetal demise. ***Chapter 4*** describes the phenomenon of abnormal flows in pregnancies with proximate cord insertions. We performed a case control study in which we compared the presence of abnormal flows in pregnancies with and without proximate cord insertions, and evaluated pregnancy outcomes.

Part two – cardiac compromise

Chapter 5 focusses on the hemodynamic adaptation of the right ventricle outflow tract in complicated monochorionic twin pregnancies. In this retrospective cohort prenatal ultrasonographic data of all neonates with postnatal RVOTO after TTTS were compared with those without postnatal RVOTO. We describe four additional cases with postnatal RVOTO that were not TTTS recipients. In ***Chapter 6*** we perform a prospective longitudinal study to investigate the development and spectrum of RVOTO in TTTS recipients during pregnancy until the neonatal period. In ***Chapter 7*** we introduce a new ultrasonographic tool to detect cardiac deterioration, based on color-coded tissue Doppler imaging. We constructed reference ranges for cardiac time intervals in healthy singleton pregnancies and evaluated the applicability of this modality. We applied this technique to TTTS recipients before laser therapy, to test the diagnostic performance in fetuses with cardiac compromise.

In ***Chapter 8*** we discuss the results of this thesis and we evaluate their implications of clinical practice and future perspectives. ***Chapter 9*** gives a general summary of this thesis.

REFERENCES

1. Dutch Perinatal ***Registry*** (***Perined***).
2. Cordero L, Franco A, Joy SD, O'Shaughnessy R W. Monochorionic diamniotic infants without twin-to-twin transfusion syndrome. *J Perinatol.* 2005;25(12):753-758.
3. Dube J, Dodds L, Armson BA. Does chorionicity or zygosity predict adverse perinatal outcomes in twins? *Am J Obstet Gynecol.* 2002;186(3):579-583.
4. Lewi L, Van Schoubroeck D, Gratacos E, Witters I, Timmerman D, Deprest J. Monochorionic diamniotic twins: complications and management options. *Curr Opin Obstet Gynecol.* 2003;15(2):177-194.
5. Zhao DP, de Villiers SF, Slaghekke F, et al. Prevalence, size, number and localization of vascular anastomoses in monochorionic placentas. *Placenta.* 2013;34(7):589-593.
6. Denbow ML, Cox P, Taylor M, Hammal DM, Fisk NM. Placental angioarchitecture in monochorionic twin pregnancies: relationship to fetal growth, fetofetal transfusion syndrome, and pregnancy outcome. *Am J Obstet Gynecol.* 2000;182(2):417-426.
7. Umur A, van Gemert MJ, Nikkels PG, Ross MG. Monochorionic twins and twin-twin transfusion syndrome: the protective role of arterio-arterial anastomoses. *Placenta.* 2002;23(2-3):201-209.
8. Camm EJ, Botting KJ, Sferruzzi-Perri AN. Near to One's Heart: The Intimate Relationship Between the Placenta and Fetal Heart. *Front Physiol.* 2018;9:629.
9. Berghella V, Kaufmann M. Natural history of twin-twin transfusion syndrome. *J Reprod Med.* 2001;46(5):480-484.
10. Rossi AC, D'addario V. Comparison of donor and recipient outcomes following laser therapy performed for twin-twin transfusion syndrome: a meta-analysis and review of literature. *Am J Perinatol.* 2009;26(1):27-32.
11. Middeldorp JM, Sueters M, Lopriore E, et al. Fetoscopic laser surgery in 100 pregnancies with severe twin-to-twin transfusion syndrome in the Netherlands. *Fetal Diagn Ther.* 2007;22(3):190-194.
12. Bennasar M, Eixarch E, Martinez JM, Gratacos E. Selective intrauterine growth restriction in monochorionic diamniotic twin pregnancies. *Semin Fetal Neonatal Med.* 2017;22(6):376-382.
13. Quintero RA, Morales WJ, Allen MH, Bornick PW, Johnson PK, Kruger M. Staging of twin-twin transfusion syndrome. *J Perinatol.* 1999;19(8 Pt 1):550-555.
14. Sukhwani M, Antolin E, Herrero B, et al. Management and perinatal outcome of selective intrauterine growth restriction in monochorionic pregnancies. *J Matern Fetal Neonatal Med.* 2019:1-6.
15. Habli M, Michelfelder E, Livingston J, et al. Acute effects of selective fetoscopic laser photocoagulation on recipient cardiac function in twin-twin transfusion syndrome. *Am J Obstet Gynecol.* 2008;199(4):412 e411-416.
16. Karatza AA, Wolfenden JL, Taylor MJ, Wee L, Fisk NM, Gardiner HM. Influence of twin-twin transfusion syndrome on fetal cardiovascular structure and function: prospective case-control study of 136 monochorionic twin pregnancies. *Heart.* 2002;88(3):271-277.
17. Stirnemann JJ, Mougeot M, Proulx F, et al. Profiling fetal cardiac function in twin-twin transfusion syndrome. *Ultrasound Obstet Gynecol.* 2010;35(1):19-27.
18. Villa CR, Habli M, Votava-Smith JK, et al. Assessment of fetal cardiomyopathy in early-stage twin-twin transfusion syndrome: comparison between commonly reported cardiovascular assessment scores. *Ultrasound Obstet Gynecol.* 2014;43(6):646-651.

19. Michelfelder E, Gottliebson W, Border W, et al. Early manifestations and spectrum of recipient twin cardiomyopathy in twin-twin transfusion syndrome: relation to Quintero stage. *Ultrasound Obstet Gynecol.* 2007;30(7):965-971.
20. Lopriore E, Bokenkamp R, Rijlaarsdam M, Sueters M, Vandenbussche FP, Walther FJ. Congenital heart disease in twin-to-twin transfusion syndrome treated with fetoscopic laser surgery. *Congenit Heart Dis.* 2007;2(1):38-43.
21. Herberg U, Gross W, Bartmann P, Banek CS, Hecher K, Breuer J. Long term cardiac follow up of severe twin to twin transfusion syndrome after intrauterine laser coagulation. *Heart.* 2006;92(1):95-100.
22. Lougheed J, Sinclair BG, Fung Kee Fung K, et al. Acquired right ventricular outflow tract obstruction in the recipient twin in twin-twin transfusion syndrome. *J Am Coll Cardiol.* 2001;38(5):1533-1538.
23. Sueters M, Middeldorp JM, Vandenbussche FP, et al. The effect of fetoscopic laser therapy on fetal cardiac size in twin-twin transfusion syndrome. *Ultrasound Obstet Gynecol.* 2008;31(2):158-163.
24. Barrea C, Hornberger LK, Alkazaleh F, et al. Impact of selective laser ablation of placental anastomoses on the cardiovascular pathology of the recipient twin in severe twin-twin transfusion syndrome. *Am J Obstet Gynecol.* 2006;195(5):1388-1395.
25. Bajoria R, Ward S, Chatterjee R. Brain natriuretic peptide and endothelin-1 in the pathogenesis of polyhydramnios-oligohydramnios in monochorionic twins. *Am J Obstet Gynecol.* 2003;189(1):189-194.
26. Mahieu-Caputo D, Salomon LJ, Le Bidois J, et al. Fetal hypertension: an insight into the pathogenesis of the twin-twin transfusion syndrome. *Prenat Diagn.* 2003;23(8):640-645.
27. Manning N, Archer N. Cardiac Manifestations of Twin-to-Twin Transfusion Syndrome. *Twin Res Hum Genet.* 2016;19(3):246-254.
28. Van Mieghem T, Done E, Gucciardo L, et al. Amniotic fluid markers of fetal cardiac dysfunction in twin-to-twin transfusion syndrome. *Am J Obstet Gynecol.* 2010;202(1):48 e41-47.
29. de Haseth SB, Haak MC, Roest AA, Rijlaarsdam ME, Oepkes D, Lopriore E. Right ventricular outflow tract obstruction in monochorionic twins with selective intrauterine growth restriction. *Case Rep Pediatr.* 2012;2012:426825.
30. Eckmann-Scholz C, Diehl W, Kanzow M, Hecher K. Monochorionic twin pregnancy complicated by right ventricular outflow tract obstruction (RVOTO) of one fetus without proof of a twin-twin transfusion syndrome. *Ultraschall Med.* 2014;35(6):573-574.
31. Herberg U, Bolay J, Graeve P, Hecher K, Bartmann P, Breuer J. Intertwin cardiac status at 10-year follow-up after intrauterine laser coagulation therapy of severe twin-twin transfusion syndrome: comparison of donor, recipient and normal values. *Arch Dis Child Fetal Neonatal Ed.* 2014;99(5):F380-385.
32. Munoz-Abellana B, Hernandez-Andrade E, Figueroa-Diesel H, et al. Hypertrophic cardiomyopathy-like changes in monochorionic twin pregnancies with selective intrauterine growth restriction and intermittent absent/reversed end-diastolic flow in the umbilical artery. *Ultrasound Obstet Gynecol.* 2007;30(7):977-982.
33. Van MT, DeKoninck P, Steenhaut P, Deprest J. Methods for prenatal assessment of fetal cardiac function. *Prenat Diagn.* 2009;29(13):1193-1203.
34. Gardiner HM. Foetal cardiac function: assessing new technologies. *Cardiol Young.* 2014;24 Suppl 2:26-35.

35. Gratacos E, Lewi L, Munoz B, et al. A classification system for selective intrauterine growth restriction in monochorionic pregnancies according to umbilical artery Doppler flow in the smaller twin. *Ultrasound Obstet Gynecol.* 2007;30(1):28-34.

36. Larsen LU, Petersen OB, Norrild K, Sorensen K, Uldbjerg N, Sloth E. Strain rate derived from color Doppler myocardial imaging for assessment of fetal cardiac function. *Ultrasound Obstet Gynecol.* 2006;27(2):210-213.

37. Paladini D, Lamberti A, Teodoro A, Arienzo M, Tartaglione A, Martinelli P. Tissue Doppler imaging of the fetal heart. *Ultrasound Obstet Gynecol.* 2000;16(6):530-535.

38. Willruth A, Geipel A, Berg C, Fimmers R, Gembruch U. Assessment of cardiac function in monochorionic diamniotic twin pregnancies with twin-to-twin transfusion syndrome before and after fetoscopic laser photocoagulation using Speckle tracking. *Ultraschall Med.* 2013;34(2):162-168.

39. Zhao S, Deng YB, Chen XL, Liu R. Assessment of right ventricular function in recipient twin of twin to twin transfusion syndrome with speckle tracking echocardiography. *Ultrasound Med Biol.* 2012;38(9):1502-1507.

40. Van MT, Giusca S, DeKoninck P, et al. Prospective assessment of fetal cardiac function with speckle tracking in healthy fetuses and recipient fetuses of twin-to-twin transfusion syndrome. *J Am Soc Echocardiogr.* 2010;23(3):301-308.

41. Rychik J, Zeng S, Bebbington M, et al. Speckle tracking-derived myocardial tissue deformation imaging in twin-twin transfusion syndrome: differences in strain and strain rate between donor and recipient twins. *Fetal Diagn Ther.* 2012;32(1-2):131-137.

42. Gardiner HM, Taylor MJ, Karatza A, et al. Twin-twin transfusion syndrome: the influence of intrauterine laser photocoagulation on arterial distensibility in childhood. *Circulation.* 2003;107(14):1906-1911.

PART I

Fetal demise



C.M. Gijtenbeek
S.J. Eschbach
J.M. Middeldorp
F. J.C.M. Klumper
F. Slaghekke
D. Oepkes
M.C. Haak

Published in: Prenatal Diagnosis, 2019; 39(10): 838-847

CHAPTER II

The value of echocardiography and Doppler in the prediction of fetal demise after laser coagulation for TTTS: a systematic review and meta-analysis



Abstract

Objective

This study aimed to investigate the value of echocardiography and Doppler before fetoscopic laser coagulation for twin-twin transfusion syndrome (TTTS) in the prediction of intrauterine fetal demise (IUFD).

Methods

We performed a systematic review and meta-analysis to compare preoperative parameters between fetuses with and without demise after laser surgery. Eighteen studies were included.

Results

Recipient twins have an increased risk of demise in case of preoperative absent/reversed flow (A/REDF) in the umbilical artery (odds ratio [OR] 2.76, 95% confidence interval [CI]: 1.78-4.28), absent or reversed a-wave in the ductus venosus (OR 2.32, 95% CI: 1.70-3.16) or a middle cerebral artery peak systolic velocity >1.5MoM (OR 7.59, 95% CI: 2.56-22.46). In donors, only A/REDF in the umbilical artery (OR 3.40, 95% CI: 2.68-4.32) and absent or reversed a-wave in the ductus venosus (OR 1.66, 95% CI:1.12-2.47) were associated with IUFD. No association was found between donor-IUFD and preoperative myocardial performance index (MPI). Two studies found an association between abnormal MPI and recipient demise.

Conclusion

With this study we have identified a set of preoperative Doppler parameters predictive of fetal demise after laser surgery. More research is needed to assess the utility of preoperative echocardiographic parameters such as the MPI in predicting IUFD.

Introduction

Twin-twin transfusion syndrome (TTTS) complicates approximately 10-15% of monochorionic twin pregnancies and results from unbalanced intertwin transfusion through placental vascular anastomoses which impacts cardiovascular loading conditions.[1,2] If left untreated, the overall perinatal mortality can be as high as 90-100%.[3,4] Fetoscopic laser coagulation of placental anastomoses significantly improves the dual twin survival rate to 64%-70% and the survival rate of at least one survivor to 85%-92%.[5,6] Survival after surgery is determined by a combination of post-laser intrauterine fetal demise (IUFD) and non-viable delivery. Compromised cardiac function is thought to contribute significantly to the mortality rates after TTTS.[7] Cardiac (functional) abnormalities, most commonly observed in recipients[8-10] are, however, not taken into account in the disease severity classification by Quintero.[11] The diagnosis of TTTS is made by ultrasound and encompasses the presence of concurrent polyhydramnios in the recipient and oligohydramnios in the donor twin.[12] Since fetuses with cardiac compromise are more likely to die in utero, assessment of fetal cardiac function prior to laser surgery might help in staging disease severity.

Several studies have focused on fetal circulation and cardiac involvement in TTTS and the prognostic value of these measurements. The objective of this systematic review and meta-analysis was to determine the capability to predict IUFD after fetoscopic laser coagulation with echocardiography and Doppler before surgery.

Methods

Search strategy

This systematic review was performed using the PRISMA methodology.[13] Relevant articles were identified using electronic databases (Pubmed, Embase, Web of Science and Cochrane). Publications from January 1990 to July 2018, written in English and containing the search terms related to twin-twin transfusion syndrome, fetoscopic laser coagulation, prediction of fetal demise and ultrasonography were included. The complete search string is available in Supplement 1. The final search was performed on 10/01/2018. Two reviewers (MG and SE) screened titles and abstracts independently for relevance. If a title or abstract seemed relevant, full text was retrieved and assessed for inclusion. Selected articles were cross-referenced. Disagreement was resolved by consensus between the two reviewers. Studies were excluded from the analysis if no

ultrasound had been performed prior to laser surgery or IUFD was not an endpoint of the study. IUFD was defined as fetal demise at any time after laser surgery and before onset of labor.

Quality assessment

Study quality and risk of bias was assessed by the two reviewers using the Hayden bias rating tool,[14] as suggested by the Cochrane Collaboration. With this tool the risk of bias was assessed in 6 domains (study participation, study attrition, prognostic factor measurement, outcome measurement, study confounding, and statistical analysis and reporting). Each of the 6 potential bias domains was rated as having high, moderate, or low risk of bias. Low methodological quality was not an exclusion criterion.

Data extraction

One reviewer (MG) extracted relevant information from the selected articles. The following data were extracted from the selected articles and tabulated: first author, year of publication, study design, country of origin, number of patients, type of fetoscopic laser surgery (selective laser photocoagulation of communicating vessels [SLPCV] or the Solomon technique[5]), operationalization of primary outcome and outcome measurement and the incidence of IUFD in cases and controls (2 x 2 tables). If possible, deaths attributable to pregnancy loss before 24 weeks gestation or termination of pregnancy were excluded from the analyses.

Statistical analysis

Statistical analysis was performed using Review Manager 5.3 (Copenhagen: The Nordic Cochrane Center, The Cochrane Collaboration, 2014). Odds ratios (OR) and their 95% confidence intervals (CI) were used as effect sizes for meta-analysis of dichotomous data. Heterogeneity between studies was examined with the inconsistency square (I2) statistics, with between-study heterogeneity at $I2 \geq 50\%$ and $p \geq 0.05$.[15] In case of heterogeneity, a random effects model was used.[16] Otherwise, or in case of limited studies to reliably estimate between study variability, a fixed effect model was used. We performed meta-analyses and constructed forest plots to examine the effect of abnormal Doppler flow velocity waveforms (FVW) on IUFD with separate analyses for recipients and donors. Absent and reversed end diastolic flow (A/REDF) in the umbilical

artery (UA) were combined in one group. Likewise, absent or reversed a-wave in the ductus venosus (DV) were combined in one group. Parameters measured in the same twin were used for the analyses (i.e. umbilical artery Doppler in the recipient twin in relation to recipient IUFD).

Results

The search resulted in 473 articles, of which 18 were included in this study (Figure 1). The study characteristics are summarized in Table 1. Quality assessment is summarized in Table 2.

Overall IUFD

Five studies report on fetal demise in the first 24h after surgery. An IUFD rate of 12% for donors and 8% for recipients was reported.[17-21] If the period is extended to the first week after laser surgery the mortality rates increase to 17% and 15% respectively.[19,20,22] In studies including all fetal deaths before onset of labor 23% of donor twins and 17% of recipient

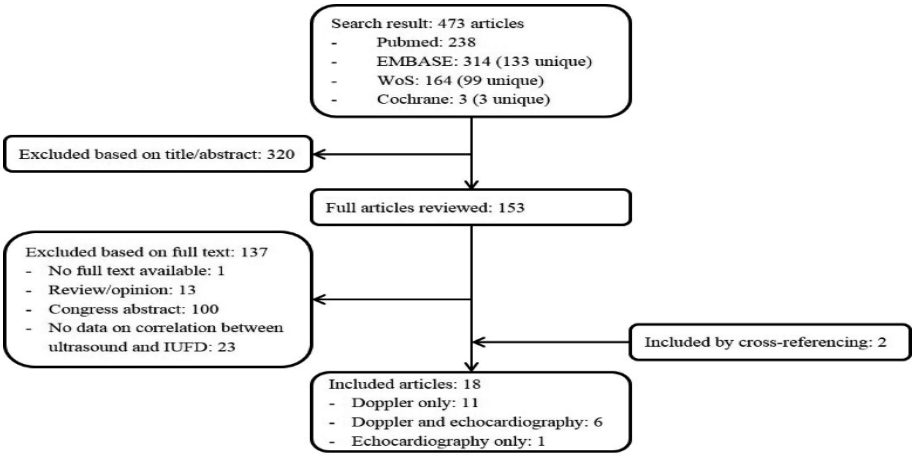

▲**Figure 1.** Flow chart demonstrating results of systematic review

twins died in utero.[19,21,23-33] In the early years of fetoscopic laser coagulation (1998-2008) these rates were 29% and 21%. These rates improved to 19% and 13% respectively in the following decade (2008-2018).

Doppler ultrasonography

Three studies were excluded from the meta-analysis[19,33,34] because abnormal Doppler FVWs were not analyzed in relation to IUFD[19,33] or only time-interval variables of the DV FVW were analyzed.[34] Since the number of included studies was too small for reliable assessment of between-study variance, a fixed effect model was used throughout.

We estimated the prevalence of abnormal Doppler FVWs in both donors and recipients prior to laser surgery. Of all fetuses, both alive and demised, 25.3% of donors and 6.2% of recipients had A/REDF in the UA prior to laser surgery. Abnormal DV FVW was found in 9.7% of donors and 28.3% of recipients. In 6.9% of donors and 35.6% of recipients pulsations in the umbilical vein were present. An elevated middle cerebral artery peak systolic velocity (MCA-PSV) prior to surgery was reported in 7.9% of donor twins and 2.4% in recipient twins.

Variables associated with fetal demise in recipient twins were: A/REDF in the UA, absent or reversed a-wave in the DV and MCA-PSV >1.5MoM (Multiples of the Median, Figure 2). Pulsatile flow in the umbilical vein was seen in over one-third of recipients but this did not increase the risk of recipient IUFD (OR 1.50, 95% CI: 0.98-2.29). In donors, only A/REDF in the umbilical artery and absent or reversed a-wave in the DV were associated with IUFD (Figure 3). An elevated MCA-PSV in the donor almost doubled the risk of demise, but this finding did not reach significance (OR 1.91, 95% CI: 0.97-3.76). Three studies reported the odds of donor demise for AEDF and REDF in the UA separately.[28-30] All three studies concluded that REDF in the UA was the strongest predictor of donor demise. Many studies included in this review were underpowered to detect a difference in IUFD rate of donors and recipients with abnormal DV FVW. No study except for the study by Ishii *et al*[26] found a significant association between preoperative abnormal DV FVW and donor demise. By pooling the data in this meta-analysis, we were able to find an association between abnormal DV FVW and an increased risk of IUFD of both donors and recipients.

In the included studies, additional variables were also investigated. Kontopoulos *et al*.[27] showed that the proportion of time in the cardiac cycle spent in AEDF (%AEDF) was significantly higher in patients with IUFD of the donor as compared to surviving donors (36.5% vs. 29.6%, p = 0.01). In a recent study by Delabaere *et al*.[20] with 111 patients, donors with early fetal demise (<7 days after laser surgery) had a lower MCA-pulsatility index (PI) (1.43 vs. 1.65, p = 0.02), a higher UA-PI (2.03 vs. 1.59, p = 0.05)

and a lower cerebroplacental ratio (0.81 vs. 1.11, p = 0.01) as compared to donors who survived the first week after surgery. Two other studies were not able to confirm these findings.[21,29]

Results of individual studies on echocardiography in relation to IUFD

In seven studies echocardiographic findings were analyzed in relation to IUFD.[19-21,28,29,32,33] We could only perform a meta-analysis on atrioventricular regurgitation. The presence of this finding was not associated with a higher risk of either donor (OR 1.34, 95% CI, 0.39-4.62) or recipient demise (OR 1.20, 95% CI, 0.79-1.83).[20,21,28]

The substantial methodical heterogeneity prevented the construction of other forest plots, we therefore present a summary of outcomes for other echocardiographic parameters. Five studies assessed the preoperative myocardial performance index (MPI) as a separate parameter [19,20,29,32,33], of which two report an increased risk of recipient demise.[20,33] In a study of 105 recipients[33] the risk of recipient demise was 4 times higher if the MPI z-score was above a cut-off z-score of 1.645, which corresponds to the 95th percentile (p < 0.01). After adjustment for gestational age and placental localization, there was no increased risk (OR 3.09, 95% CI: 0.94 - 9.30, p = 0.06). In the most recent study by Delabaere *et al*.[20] demised recipients had a higher mean MPI of the right ventricle (RV-MPI) as compared to survivors after adjustment for gestational age at laser surgery (unadjusted p = 0.07, adjusted p = 0.02). The three remaining studies did not find an association between preoperative MPI and postoperative recipient demise.[19,29,32] The results are therefore conflicting. An association between preoperative MPI and donor-IUFD was absent in all studies.

Table 1. Article characteristics

	Journal name (year) country	Design	Multi-/ single center	Patients	Type of FLC	Time of IUFD	Doppler measurements	Echo-cardiography	Included in meta-analysis
1	Ville (1998), UK	P	M	132	SLPCV	Before onset of labor	UA	No	UA
2	Zilulnig (1999) Germany	P	S	121	SLPCV	Before onset of labor	UA, DV	No	UA
3	Martinez (2003) USA	P	S	110	SLPCV	Unspecified	UA, DV, UV, MCA	Yes	UA, DV, UV
4	Cavicchioni (2006),	R	S	120	SLPCV	Before onset of labor	UA, DV	No	UA, DV
5	Ishii (2007) Japan	P	M	55	SLPCV	Before onset of labor	UA, DV, UV	No	UA, DV, UV
6	Kontopoulos (2007) USA	P	S	401	SLPCV	Unspecified (donor)	UA, %UA	No	UA
7	Kontopoulos (2009) USA	P	S	189	SLPCV	<24h after FLC	MCA	No	MCA-PSV
8	Skupski (2010) USA	R	M	466	SLPCV	Before onset of labor	UA, DV, UV	Yes	UA, DV, UV
9	Trieu (2012) France	R	S	86	N/A	<7d after FLC	MCA	No	MCA-PSV
10	Eixarch (2013) Spain	P	S	215	SLPCV	<7d after FLC	UA, DV, MCA	Yes	UA, MCA-PSV, DV
11	Gapp-Born (2014) France	P	S	105	Both	Unspecified (recipient)	-	Yes	-
12	Tachibana (2015) Germany	R	S	107	SLPCV	<2d after FLC	DV (time inter-vals)	No	-
13	Snowise (2015) USA	P	S	166	Solomon	Before onset of labor (donor)	UA, DV, MCA	No	UA, DV

	Journal name (year) country	Design	Multi-/ single center	Patients	Type of FLC	Time of IUFD	Doppler measurements	Echo-cardiography	Included in meta-analysis
14	Patel (2015) USA	R	S	369	SLPCV	<24h after FLC (recipient)	UA	No	UA
15	Eschbach (2016) Netherlands	R	S	288	Both	SFD before onset of labor	UA, DV, UV	No	UA, DV, VU
16	Finneran (2016) USA	**R**	**S**	53	SLPCV	<7d after FLC	-	Yes	-
17	Leduc (2017) Canada	**R**	**S**	105	Both	Unspecified	UA	**Yes**	UA
18	Delabaere (2018) Canada	**R**	**S**	111	Both	<7d after FLC	UA, DV, MCA	**yes**	UA, DV, MCA-PSV

P, prospective; R, retrospective; S, single center; M, multicenter; FLC, fetoscopic laser coagulation; SLPCV, selective laser photocoagulation of communicating vessels; IUFD, intra-uterine fetal demise; SFD, single fetal demise

Table 2. Risk of bias in 6 domains based on the Hayden bias rating tool

	Variable	Study participation	Study attrition	Prognostic factor measurement	Outcome measurement	Study confounding	Statistical analysis and reporting
1	Ville (1998)	Moderate	Low	Low	Moderate	Moderate	Low
2	Zilulnig (1999)	Moderate	Low	Low	Moderate	Moderate	Low
3	Martinez (2003)	Low	Low	Low	Moderate	High	Low
4	Cavicchioni (2006)	Moderate	Low	Moderate	Low	Low	Low
5	Ishii (2007)	High	Low	Low	Low	Moderate	Low
6	Kontopoulos (2007)	Moderate	Low	Low	Moderate	High	Moderate
7	Kontopoulos (2009)	Moderate	Low	Low	Low	Low	Low
8	Skupski (2010)	Low	Low	Moderate	Low	Low	Low
9	Trieu (2012)	Low	Low	Low	Moderate	Low	Low
10	Eixarch (2013)	Low	Low	Low	Low	Low	Low
11	Gapp-Born (2014)	Low	Low	Low	Low	Low	Low
12	Tachibana (2015)	Low	Low	Low	Low	High	Low
13	Snowise (2015)	Low	Low	Low	Low	Low	Low
14	Patel (2015)	Moderate	Low	Low	Low	High	Low
15	Eschbach (2016)	Low	Low	Low	Low	Low	Low
16	Finneran (2016)	Moderate	Low	Moderate	Low	Low	Low
17	Leduc (2017)	Moderate	Low	Moderate	Low	High	Low
18	Delabaere (2018)	Low	Low	Low	Low	Moderate	Low

In three studies the CHOP (Children's Hospital of Philadelphia) score[35] (a sum of 12 cardiovascular parameters, including the MPI) was analyzed in relation to IUFD.[20,28,33] A CHOP score above 5 is generally considered as abnormal. Interestingly, only a CHOP score ≥ 3 was associated with recipient demise (40% with a score ≥ 3 vs 13% with a score < 3, $p < 0.01$)[33] and a score > 5 was not.[20] In the study of 466 TTTS cases, 'global cardiac dysfunction' was included in the analysis, a factor defined as an abnormal MPI, ventricular dyskinesia, abnormal ejection fraction, abnormal CHOP score (or other measure of cardiac dysfunction; exact cut-off values for separate parameters were not stated). The presence of "global cardiac dysfunction" prior to surgery did not increase the risk of either donor or recipient demise.[28] In a small study by Leduc *et al*.[32] of 55 treated pregnancies the aortic isthmus flow velocity patterns were assessed. The isthmic systolic index[36], which reflects the relative performances of the right and left ventricle, measured in recipients before laser was associated with recipient IUFD ($p = 0.04$).

Discussion

In this systematic review and meta-analysis we found an association between preoperative Doppler FVWs and IUFD after fetoscopic laser coagulation. Fetal echocardiographic parameters such as the MPI appear not to be associated with fetal demise after laser coagulation. Results from studies investigating echocardiographic parameters do almost reach significance however, possibly indicating lack of power in these studies. The conflicting results regarding the use of echocardiography in the prediction of demise prevented us from building a prediction model including both Doppler and echocardiographic parameters.

We have shown an IUFD rate of 19% for donors and 13% for recipients in the last decade. Improved survival after laser surgery may reflect a learning-curve effect of the operators,[6,37] who gain more experience with this procedure globally. Furthermore, evolution of the technique[38] and developments and improvements in ultrasonographic monitoring may play a role. The investigation of these factors on fetal survival rates fell outside of the scope of this article.

We found that A/REDF in the UA, absent or reversed a-wave in the DV and MCA-PSV >1.5MoM increases the risk of recipient IUFD. Abnormal UA FVW, present in only 6% of recipients, may result from placental compression by increased intra-amniotic pressure due to massive polyhydramnios or, alternatively from poor cardiac function.

▼**Figure 2.** Doppler flows in the recipient twin

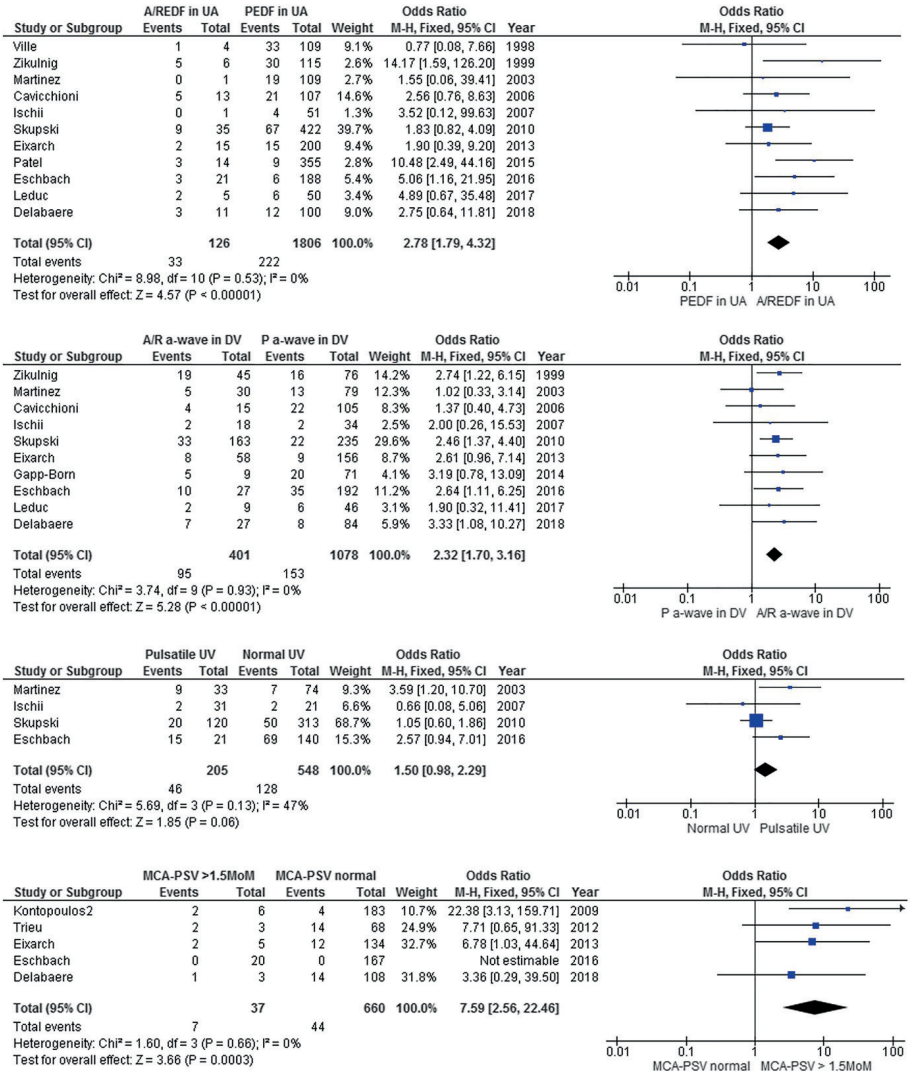

PEDF or A/REDF in UA, positive or absent/reversed end diastolic flow in the umbilical artery; P or A/E a-wave in DV, positive or absent/reversed a-wave in the ductus venosus; UV, umbilical vein; MCA-PSV, middle cerebral artery-peak systolic velocity

▼**Figure 3.** Doppler flows in the donor twin

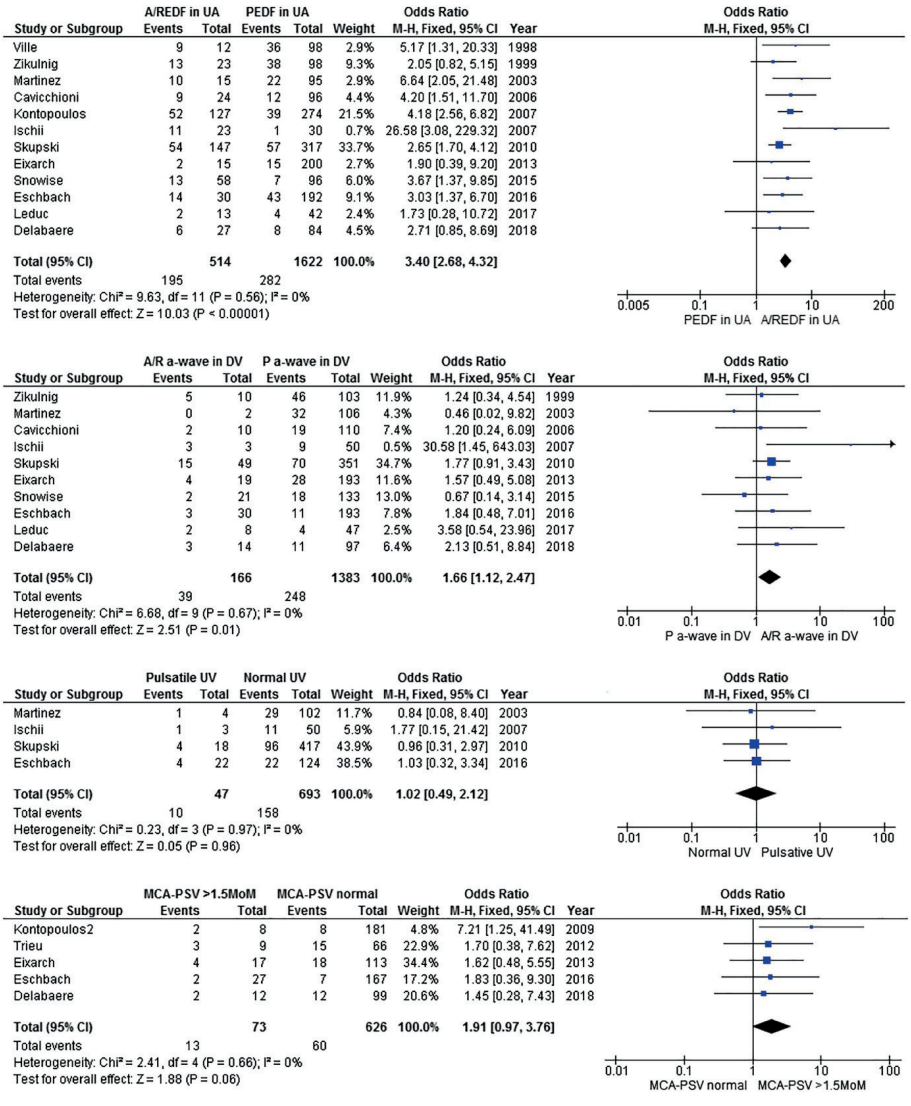

PEDF or A/REDF in UA, positive or absent/reversed end diastolic flow in the umbilical artery; P or A/E a-wave in DV, positive or absent/reversed a-wave in the ductus venosus; UV, umbilical vein; MCA-PSV, middle cerebral artery-peak systolic velocity

A suggested theory is that poor myocardial contractility as a result of recipient hypervolemia and cardiac overload, result in an insufficient generated blood pressure to propel the blood forward in the UA throughout diastole.[20] The theory that poor cardiac function causes A/REDF flow in the umbilical artery in recipient twins is further supported by the finding that recipient twins with abnormal UA FVW always have abnormal venous FVW of the umbilical vein, ductus venosus, or both.[18] More than one-third of recipients had a pulsatile umbilical vein preoperative, which could also indicate cardiac overload. This parameter was however not statistically significant associated with recipient demise. The mechanism underlying the association between increased MCA-PSV and IUFD in recipients is not entirely clear. Increased cardiac output resulting from the hypervolemic status of these fetuses, which is responsible for cardiomegaly and hypertrophy in some TTTS cases, could also elevate the blood velocity in the cerebral arteries. These changes have also been shown in fetuses with congenital heart disease[39] or intrauterine growth restriction.[40] Another suggested explanation is decreased fetal oxygenation due to placental interstitial edema which increases MCA blood velocity through autoregulation in the absence of low hemoglobin.[29,41]

In donors, only A/REDF in the UA and absent or reversed a-wave in the DV were found to be associated with donor-IUFD. In these twins, the mechanism leading to hemodynamic changes appears to differ from the pathophysiology in recipient twins. Abnormal UA FVW occurs in a quarter of donors prior to laser surgery. If present, the odds of demise are 3.4 times higher as compared to fetuses who have a normal UA FVW. It reflects both placental insufficiency (maldevelopment and unequal sharing) and fetal hypotension secondary to the hemodynamic imbalance in TTTS. Three studies showed that REDF in the UA is a stronger predictor of donor IUFD than AEDF.[28-30] It is suggested that reversed UA flow reflects placental insufficiency in a greater degree and that it is not amenable to improvement following restoration of volume status.[29] Abnormal venous FVW in donor twins may be explained by either cardiac decompensation due to severe placental insufficiency or hypovolemia as a result of the TTTS. The relative hypervolemia after occlusion of vascular anastomoses may increase the afterload and cause acute transient impaired cardiac function which attributes to a higher chance of donor demise after surgery. Elevated MCA-PSV prior to surgery is reported in 8% of donor twins. In monochorionic twins, unbalanced net intertwin blood transfusion may lead to TTTS, but also to twin anemia polycythemia sequence (TAPS). In TAPS, there is a chronic and slow transfusion of blood from the

donor to the recipient twin through extremely small anastomoses.[42] This process leads to an anemic donor and polycythemia in the recipient. 2-8% of TTTS cases may have preoperative signs of TAPS,[43] which may explain the increased MCA-PSV in donors prior to laser surgery. Although there was a tendency for donor twins with an elevated MCA-PSV to die more frequently in utero after surgery this finding did not reach statistical significance.

The question whether echocardiographic parameters should be included in the TTTS staging system remains unanswered. Most studies investigating the association between assessment of cardiac function and IUFD include neonatal demise instead of fetal demise as their endpoint.[44-49] A large amount of data reflecting cardiac function had therefore been excluded from this systematic review. Furthermore, the limited amount of available reports on the value of a detailed cardiovascular assessment in the prediction of fetal survival provide discordant results. Three out of five studies did not find any genuine correlation with IUFD.[19,29,32] The lack of correlation between severity of cardiac disease and intrauterine demise is not explained so far. The low reproducibility and repeatability indices of the MPI and a high degree of expertise needed to perform MPI or CHOP score measurements may be important factors. Very precise recordings and manual placement of calipers are needed for MPI calculations. For the left ventricle, the Doppler cursor is placed between the mitral valve and aortic valve and both mitral inflow and aortic outflow can be visualized on the same trace. Measurement of the RV-MPI is further complicated because the right ventricular inflow and outflow cannot be visualized in one plane and thus not in the same trace. Published normal ranges for different gestational ages demonstrate a wide variation,[50-54] probably because a standardized method has not been established. While automation of these measurements will remove the human factor on measurement error, experience is still required to be able to acquire the correct Doppler waveform successfully.[55,56] The lack of correlation may also be explained by the effectiveness of laser surgery for improving recipient cardiac function. Other variables associated with laser surgery such as premature rupture of membranes, unequal placental share and preterm delivery become the predominant determinants of fetal mortality after correction of the hemodynamic imbalance.

To our knowledge, this is the first review and meta-analysis of pre-operative echocardiography and Doppler in the prediction of IUFD after fetoscopic laser surgery. To maximize our sample size, we included all studies which investigated fetal demise

before birth, not only early-IUFD (<7 days). Other causes of demise such as placental insufficiency or IUGR could therefore have influenced our results, even though the majority of IUFD after laser occurs in the first week after laser surgery.[7,21,26] There are also other limitations to this study. Most studies are single center reports. Half of the reports are retrospective studies. In all but one study[30] selective coagulation was used for all or for a proportion of cases. It is known that incomplete laser coagulation is a risk factor for recurrent TTTS or post-laser TAPS and therewith for possible subsequent fetal demise.[57] Finally, we did not include fetal growth discordance, selective intra-uterine growth restriction (sIUGR) or TAPS prior to laser surgery in this study. Future large-scale prospective studies could allow for multivariate analysis into the interference of sIUGR and TAPS on fetal echocardiography and Doppler parameters for IUFD. Incorporating signs of sIUGR and TAPS, but also factors such as Quintero stage, hydrops and gestational age at TTTS diagnosis, into a prediction model together with the before mentioned Doppler parameters could be useful in daily clinical care in cases where the risk of fetal demise turns out to be high, to spend additional counseling time on cord occlusion as a back-up plan if laser surgery seems technically challenging. A prediction model could also be useful in future clinical trials investigating innovations in treatment of TTTS.

Conclusion

In conclusion, we have identified a set of preoperative Doppler parameters predictive of fetal demise after fetoscopic laser coagulation. Recipient twins have an increased risk of demise in case of preoperative abnormal FWV of the UA, DV and MCA. In donor twins, only abnormal FVW of the UA and DV are associated with IUFD after surgery. The utility of preoperative parameters that reflect cardiac function such as the MPI in predicting IUFD remains unclear.

REFERENCES

1. Lopriore E, Vandenbussche FP, Tiersma ES, et al. Twin-to-twin transfusion syndrome: new perspectives. J Pediatr 1995;127:675-680.
2. Huber A, Hecher K. How can we diagnose and manage twin-twin transfusion syndrome? Best practice & research Clinical obstetrics & gynaecology 2004;18:543-556.
3. El Kateb A, Ville Y. Update on twin-to-twin transfusion syndrome. Best practice & research Clinical obstetrics & gynaecology 2008;22:63-75.
4. Fisk NM, Duncombe GJ, Sullivan MH. The basic and clinical science of twin-twin transfusion syndrome. Placenta 2009;30:379-390.
5. Slaghekke F, Lopriore E, Lewi L, et al. Fetoscopic laser coagulation of the vascular equator versus selective coagulation for twin-to-twin transfusion syndrome: an open-label randomised controlled trial. Lancet 2014;383:2144-2151.
6. Diehl W, Diemert A, Grasso D, et al. Fetoscopic laser coagulation in 1020 pregnancies with twin-twin transfusion syndrome demonstrates improvement in double-twin survival rate. Ultrasound Obstet Gynecol 2017;50:728-735.
7. Shah AD, Border WL, Crombleholme TM, Michelfelder EC. Initial fetal cardiovascular profile score predicts recipient twin outcome in twin-twin transfusion syndrome. J Am Soc Echocardiogr 2008;21:1105-1108.
8. Eschbach SJ, Boons LS, van Zwet E, et al. Right ventricular outflow tract obstruction in complicated monochorionic twin pregnancies. Ultrasound Obstet Gynecol 2016;
9. Rychik J, Zeng S, Bebbington M, et al. Speckle tracking-derived myocardial tissue deformation imaging in twin-twin transfusion syndrome: differences in strain and strain rate between donor and recipient twins. Fetal Diagn Ther 2012;32:131-137.
10. Zosmer N, Bajoria R, Weiner E, et al. Clinical and echographic features of in utero cardiac dysfunction in the recipient twin in twin-twin transfusion syndrome. Br Heart J 1994;72:74-79.
11. Quintero RA, Morales WJ, Allen MH, et al. Staging of twin-twin transfusion syndrome. J Perinatol 1999;19:550-555.
12. Johnson A. Diagnosis and Management of Twin-Twin Transfusion Syndrome. Clinical obstetrics and gynecology 2015;58:611-631.
13. Moher D, Liberati A, Tetzlaff J, et al. Preferred reporting items for systematic reviews and meta-analyses: the PRISMA statement. J Clin Epidemiol 2009;62:1006-1012.
14. Hayden JA, van der Windt DA, Cartwright JL, et al. Assessing bias in studies of prognostic factors. Ann Intern Med 2013;158:280-286.
15. Higgins JP, Thompson SG, Deeks JJ, Altman DG. Measuring inconsistency in meta-analyses. BMJ 2003;327:557-560.
16. DerSimonian R, Laird N. Meta-analysis in clinical trials. Control Clin Trials 1986;7:177-188.
17. Kontopoulos EV, Quintero RA. Assessment of the peak systolic velocity of the middle cerebral artery in twin-twin transfusion syndrome. Part I: preoperative assessment. Am J Obstet Gynecol 2009;200:61.e61-65.
18. Patel S, Quintero RA, Kontopoulos EV, et al. Abnormal umbilical artery Doppler findings in the recipient twin before laser surgery for twin-twin transfusion syndrome. J Ultrasound Med 2015;34:843-846.

19. Finneran MM, Pickens R, Templin M, Stephenson CD. Impact of recipient twin preoperative myocardial performance index in twin-twin transfusion syndrome treated with laser. J Matern Fetal Neonatal Med 2016;1-5.
20. Delabaere A, Leduc F, Reboul Q, et al. Factors associated to early intrauterine fetal demise after laser for TTTS by preoperative fetal heart and Doppler ultrasound. Prenat Diagn 2018;38:523-530.
21. Martinez JM, Bermudez C, Becerra C, et al. The role of Doppler studies in predicting individual intrauterine fetal demise after laser therapy for twin-twin transfusion syndrome. Ultrasound Obstet Gynecol 2003;22:246-251.
22. Trieu NT, Weingertner AS, Guerra F, et al. Evaluation of the measurement of the middle cerebral artery peak systolic velocity before and after placental laser coagulation in twin-to-twin transfusion syndrome. Prenat Diagn 2012;32:127-130.
23. Ville Y, Hecher K, Gagnon A, et al. Endoscopic laser coagulation in the management of severe twin-to-twin transfusion syndrome. Br J Obstet Gynaecol 1998;105:446-453.
24. Zikulnig L, Hecher K, Bregenzer T, et al. Prognostic factors in severe twin-twin transfusion syndrome treated by endoscopic laser surgery. Ultrasound Obstet Gynecol 1999;14:380-387.
25. Cavicchioni O, Yamamoto M, Robyr R, et al. Intrauterine fetal demise following laser treatment in twin-to-twin transfusion syndrome. BJOG : an international journal of obstetrics and gynaecology 2006;113:590-594.
26. Ishii K, Hayashi S, Nakata M, et al. Ultrasound assessment prior to laser photocoagulation for twin-twin transfusion syndrome for predicting intrauterine fetal demise after surgery in Japanese patients. Fetal Diagn Ther 2007;22:149-154.
27. Kontopoulos EV, Quintero RA, Chmait RH, et al. Percent absent end-diastolic velocity in the umbilical artery waveform as a predictor of intrauterine fetal demise of the donor twin after selective laser photocoagulation of communicating vessels in twin-twin transfusion syndrome. Ultrasound Obstet Gynecol 2007;30:35-39.
28. Skupski DW, Luks FI, Walker M, et al. Preoperative predictors of death in twin-to-twin transfusion syndrome treated with laser ablation of placental anastomoses. Am J Obstet Gynecol 2010;203:388.e381-388.e311.
29. Eixarch E, Valsky D, Deprest J, et al. Preoperative prediction of the individualized risk of early fetal death after laser therapy in twin-to-twin transfusion syndrome. Prenat Diagn 2013;33:1033-1038.
30. Snowise S, Moise KJ, Johnson A, et al. Donor Death After Selective Fetoscopic Laser Surgery for Twin-Twin Transfusion Syndrome. Obstet Gynecol 2015;126:74-80.
31. Eschbach SJ, Boons LS, Wolterbeek R, et al. Prediction of single fetal demise after laser therapy for twin-twin transfusion syndrome. Ultrasound Obstet Gynecol 2016;47:356-362.
32. Leduc F, Delabaere A, Gendron R, et al. Aortic Isthmus Flow Recording Predicts the Outcome of the Recipient Twin after Laser Coagulation in Twin-Twin Transfusion Syndrome. Fetal Diagn Ther 2017;
33. Gapp-Born E, Sananes N, Weingertner AS, et al. Predictive value of cardiovascular parameters in twin-to-twin transfusion syndrome. Ultrasound Obstet Gynecol 2014;44:427-433.
34. Tachibana D, Glosemeyer P, Diehl W, et al. Time-interval analysis of ductus venosus flow velocity waveforms in twin-to-twin transfusion syndrome treated with laser surgery. Ultrasound Obstet Gynecol 2015;45:544-550.

35. Rychik J, Tian Z, Bebbington M, et al. The twin-twin transfusion syndrome: spectrum of cardiovascular abnormality and development of a cardiovascular score to assess severity of disease. Am J Obstet Gynecol 2007;197:392 e391-398.
36. Chabaneix J, Fouron JC, Sosa-Olavarria A, et al. Profiling left and right ventricular proportional output during fetal life with a novel systolic index in the aortic isthmus. Ultrasound Obstet Gynecol 2014;44:176-181.
37. Peeters SH, Van Zwet EW, Oepkes D, et al. Learning curve for fetoscopic laser surgery using cumulative sum analysis. Acta Obstet Gynecol Scand 2014;93:705-711.
38. Akkermans J, Peeters SH, Klumper FJ, et al. Twenty-Five Years of Fetoscopic Laser Coagulation in Twin-Twin Transfusion Syndrome: A Systematic Review. Fetal Diagn Ther 2015;38:241-253.
39. Berg C, Gembruch O, Gembruch U, Geipel A. Doppler indices of the middle cerebral artery in fetuses with cardiac defects theoretically associated with impaired cerebral oxygen delivery in utero: is there a brain-sparing effect? Ultrasound Obstet Gynecol 2009;34:666-672.
40. Makh DS, Harman CR, Baschat AA. Is Doppler prediction of anemia effective in the growth-restricted fetus? Ultrasound Obstet Gynecol 2003;22:489-492.
41. Picklesimer AH, Oepkes D, Moise KJ, Jr., et al. Determinants of the middle cerebral artery peak systolic velocity in the human fetus. Am J Obstet Gynecol 2007;197:526 e521-524.
42. Tollenaar LS, Slaghekke F, Middeldorp JM, et al. Twin Anemia Polycythemia Sequence: Current Views on Pathogenesis, Diagnostic Criteria, Perinatal Management, and Outcome. Twin research and human genetics : the official journal of the International Society for Twin Studies 2016;19:222-233.
43. Van Winden KR, Quintero RA, Kontopoulos EV, et al. Pre-Operative Twin Anemia/Polycythemia in the Setting of Twin-Twin Transfusion Syndrome (TTTS). Fetal Diagn Ther 2015;37:274-280.
44. Delabaere A, Leduc F, Reboul Q, et al. Prediction of neonatal outcome of TTTS by fetal heart and Doppler ultrasound parameters before and after laser treatment. Prenat Diagn 2016;36:1199-1205.
45. Gil Guevara E, Pazos A, Gonzalez O, et al. Doppler assessment of patients with twin-to-twin transfusion syndrome and survival following fetoscopic laser surgery. International journal of gynaecology and obstetrics: the official organ of the International Federation of Gynaecology and Obstetrics 2017;137:241-245.
46. Stirnemann JJ, Nasr B, Proulx F, et al. Evaluation of the CHOP cardiovascular score as a prognostic predictor of outcome in twin-twin transfusion syndrome after laser coagulation of placental vessels in a prospective cohort. Ultrasound Obstet Gynecol 2010;36:52-57.
47. Van Mieghem T, Martin AM, Weber R, et al. Fetal cardiac function in recipient twins undergoing fetoscopic laser ablation of placental anastomoses for Stage IV twin-twin transfusion syndrome. Ultrasound Obstet Gynecol 2013;42:64-69.
48. Maskatia SA, Ruano R, Shamshirsaz AA, et al. Estimated combined cardiac output and laser therapy for twin-twin transfusion syndrome. Echocardiography 2016;33:1563-1570.
49. Ortiz JU, Masoller N, Gomez O, et al. Rate and Outcomes of Pulmonary Stenosis and Functional Pulmonary Atresia in Recipient Twins with Twin-Twin Transfusion Syndrome. Fetal Diagn Ther 2017;41:191-196.

50. Cruz-Martinez R, Figueras F, Bennasar M, et al. Normal reference ranges from 11 to 41 weeks' gestation of fetal left modified myocardial performance index by conventional Doppler with the use of stringent criteria for delimitation of the time periods. Fetal Diagn Ther 2012;32:79-86.
51. Hernandez-Andrade E, Figueroa-Diesel H, Kottman C, et al. Gestational-age-adjusted reference values for the modified myocardial performance index for evaluation of fetal left cardiac function. Ultrasound Obstet Gynecol 2007;29:321-325.
52. Mahajan A, Henry A, Meriki N, et al. The (Pulsed-Wave) Doppler Fetal Myocardial Performance Index: Technical Challenges, Clinical Applications and Future Research. Fetal Diagn Ther 2015;38:1-13.
53. Meriki N, Izurieta A, Welsh A. Reproducibility of constituent time intervals of right and left fetal modified myocardial performance indices on pulsed Doppler echocardiography: a short report. Ultrasound Obstet Gynecol 2012;39:654-658.
54. Meriki N, Welsh AW. Development of Australian reference ranges for the left fetal modified myocardial performance index and the influence of caliper location on time interval measurement. Fetal Diagn Ther 2012;32:87-95.
55. Lee MY, Won HS, Jeon EJ, et al. Feasibility of using auto Mod-MPI system, a novel technique for automated measurement of fetal modified myocardial performance index. Ultrasound Obstet Gynecol 2014;43:640-645.
56. Leung V, Avnet H, Henry A, et al. Automation of the Fetal Right Myocardial Performance Index to Optimise Repeatability. Fetal Diagn Ther 2018;44:28-35.
57. Lopriore E, Slaghekke F, Middeldorp JM, et al. Residual anastomoses in twin-to-twin transfusion syndrome treated with selective fetoscopic laser surgery: localization, size, and consequences. Am J Obstet Gynecol 2009;201:66 e61-64.

S.J. Eschbach
L.S. Boons
R. Wolterbeek
J.M. Middeldorp
F.J. Klumper
E. Lopriore
D. Oepkes
M.C. Haak

Published in: Ultrasound in Obstetrics & Gynecology, 2016; 47 (3): 356-362

CHAPTER III

Prediction of single fetal demise after laser therapy for twin-twin transfusion syndrome

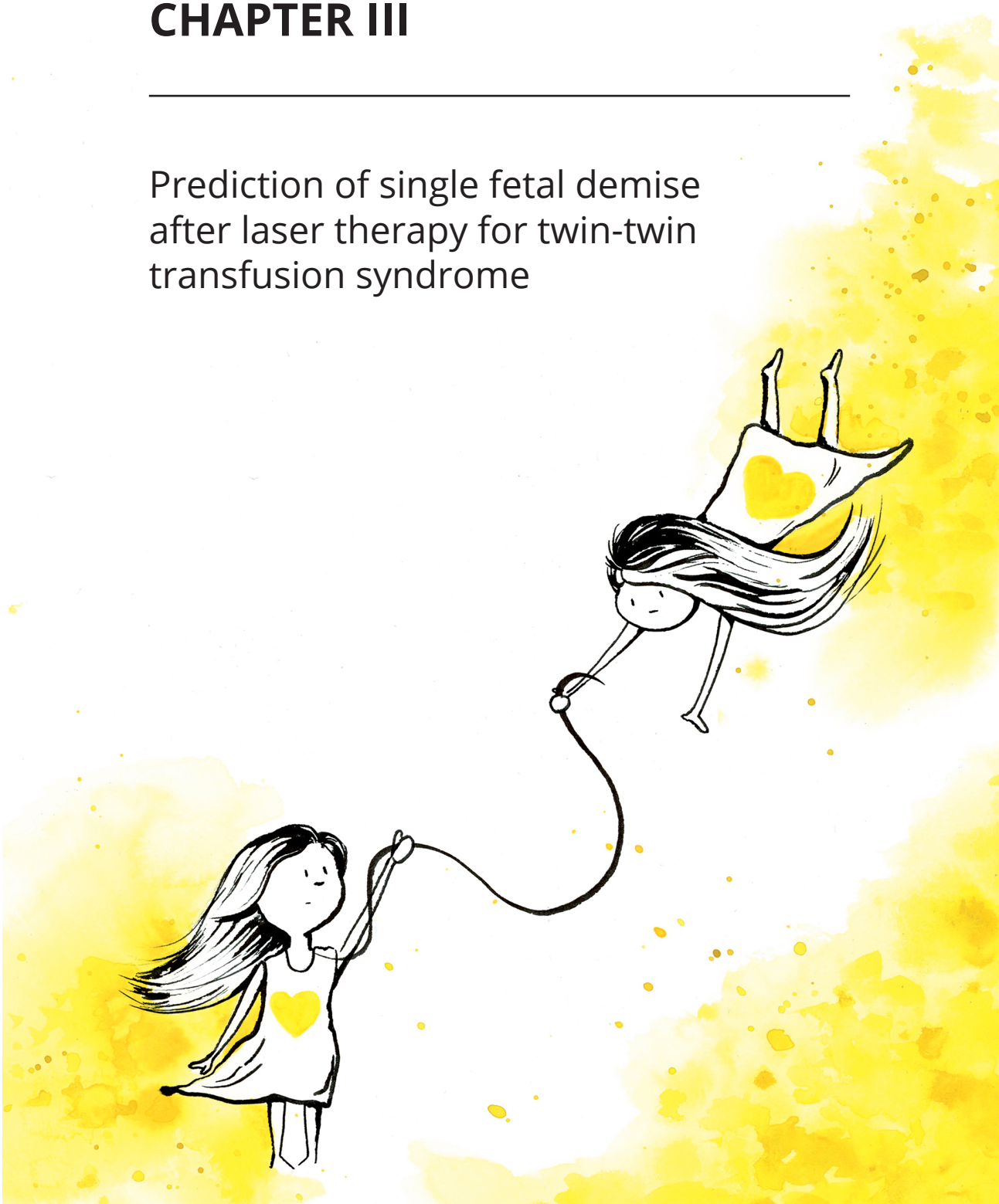

Abstract

Objective

Single fetal demise (SFD) occurs in up to 20% of monochorionic pregnancies treated with laser coagulation for twin-twin transfusion syndrome (TTTS). We aimed to determine the independent factors associated with SFD to improve outcome in the care of TTTS pregnancies in the future.

Methods

This was a case-control study on twin pregnancies treated for TTTS between 2007 and 2013. Data on ultrasound, laser surgery and outcome were retrieved from our monochorionic twin database. We analyzed separately cases of SFD in donor and recipient twins, and compared them with treated pregnancies that resulted in two live births.

Results

Of the 273 TTTS pregnancies treated with laser coagulation, SFD occurred in 30 donors (11.0%) and 27 recipients (9.9%). In 67% of pregnancies with SFD, the death occurred within 1 week after laser treatment. For SFD in donors, absent/reversed end-diastolic flow in the umbilical artery was the strongest predictor (odds ratio (OR), 3.0 (95% CI, 1.1-8.0); P = 0.01), followed by the presence of an arterioarterial anastomosis (OR, 4.2 (95% CI, 1.4-13.1); P = 0.03) and discordance in estimated fetal weight (OR, 1.0 (95% CI, 1.0-1.1); P = 0.04). For SFD in recipients, independent predictors were absent/reversed A-wave in the ductus venosus (OR, 3.6 (95% CI, 1.2-10.5); P = 0.02) and the absence of recipient-to-donor arteriovenous anastomoses (OR, 10.6 (95% CI, 1.8-62.0); P < 0.01).

Conclusion

Our findings confirm earlier reports that suggest that abnormal blood flow is associated with SFD after laser treatment for TTTS. The association of SFD with the type of anastomoses is a new finding. We speculate that the type of anastomoses present determines the degree of hemodynamic change during laser therapy. Future strategies should aim at stabilizing fetal circulation before laser therapy to decrease the vulnerability to acute preload and afterload changes.

Introduction

Monochorionic–diamniotic (MCDA) pregnancy has a higher risk of adverse fetal or neonatal outcome than does twin pregnancy in general, owing to a higher incidence of congenital malformations and pregnancy complications as a result of placental angioarchitecture. In 10–15% of MCDA twin pregnancies, imbalanced blood flow through the communicating vessels in the shared placenta causes a net transfusion from one twin (donor) to the other twin (recipient), known as twin–twin transfusion syndrome (TTTS). Overall mortality rate in fetuses with TTTS has been reported to be as high as 90% if left untreated.[1,2] Laser coagulation of the anastomoses that develop in TTTS decreases the mortality rate to approximately 40% in donors and 30% in recipients.[3]

Double, often simultaneous, fetal demise after laser surgery occurs in up to 20% of treated pregnancies,[4,5] caused by a variety of complications. Many of these causes are well understood, such as intrauterine bleeding, rupture of membranes, infection, miscarriage, technical complications and incomplete procedures.

Single fetal demise (SFD), however, often occurs unexpectedly after otherwise uneventful surgery. The identification of factors that are associated with unexplained SFD could help to explain the pathophysiological processes that play a role in this event. Several ultrasonographic findings, such as abnormal flow in the ductus venosus (DV) or the umbilical artery, have been associated with SFD.[4] This reflects a hemodynamic challenge for fetuses with TTTS. TTTS is treated by laser coagulation of the vascular anastomoses to restore hemodynamic balance. Placental angioarchitecture is different in all monochorionic placentae, and different types of anastomosis might cause different hemodynamic challenges, which could be a factor in fetal demise after laser therapy. The aim of this study was to determine the independent risk factors concerning ultrasonographic and angioarchitectural findings in unexplained SFD after laser surgery for TTTS. Further insight into the hemodynamics of TTTS could initiate the start of the development of interventions with the aim of improved fetal outcome after laser therapy.

Methods

The Leiden University Medical Center is the national referral center for invasive fetal therapy in The Netherlands. Data on all consecutive pregnancies diagnosed with TTTS and treated by laser surgery between January 2007 and July 2013 were reviewed. Data concerning ultrasonographic findings, operative characteristics, postpartum placental examination and neonatal follow-up were entered prospectively into the monochorionic twin database. SFD was defined as demise of one twin at any time after laser therapy and before the onset of labor. Case–control analysis was performed separately for donors and recipients. TTTS cases treated with laser coagulation and resulting in the live birth of both twins were used as controls.

In all pregnancies, gestational age was calculated on the basis of crown–rump length at first-trimester ultrasound. TTTS was diagnosed according to the Eurofetus criteria and defined as polyuric polyhydramnios in the recipient twin with a deepest vertical pocket of 8 cm before 20 weeks' gestation and 10 cm after 20 weeks, and simultaneously, oliguric oligohydramnios in the donor twin with a deepest vertical pocket of less than 2 cm.[6] Severity of the disease was classified according to the Quintero staging system.[7] Indications for performing laser surgery were Quintero Stage II–IV or Stage I with symptomatic polyhydramnios. Exclusion criteria for analysis were chromosomal abnormalities or major congenital malformations, intrauterine fetal demise (IUFD) of both twins or IUFD attributable to labor. Cases of selective feticide were also excluded.

A comprehensive preoperative ultrasound examination was always performed before laser treatment in our unit to confirm and stage the TTTS. Signs of fetal cardiac adaptation or compromise were evaluated. Discordance in estimated fetal weight (EFW) was calculated as (recipient EFW – donor EFW)/(recipient EFW) × 100%.

The placenta was examined after birth by injecting colored dye, as described previously.[8,9] Under local anesthesia with adjuvant intravenous analgesia and mild sedation with fentanyl and midazolam, fetoscopic laser surgery was performed by one of five experienced fetal surgeons. Patients were treated with sequential selective laser coagulation of all communicating vessels, with coagulation of the whole vascular equator (the Solomon technique)[9] or without this additional coagulation. During laser therapy, the number and type of coagulated anastomoses were recorded and used for analysis. After laser therapy, patients remained in hospital for about 24 h. Ultrasound

examination was performed the following morning and approximately 1 week after laser therapy. Biweekly follow-up scans were scheduled after the first week until birth for all patients, and the placenta was examined postnatally to determine the site of cord insertion. In the majority of SFD cases, dye injection was not feasible owing to maceration of the placental share of the deceased fetus.[8,10]

Neonatal cerebral ultrasound of the surviving twin after SFD was performed routinely after birth. Severe cerebral injury was defined as the presence of at least one of the following findings on cranial imaging: intraventricular hemorrhage ≥ Grade III,[11] periventricular leukomalacia ≥ Grade II,[12] (progressive and non-progressive) ventricular dilatation ≥ 97th percentile[13] and arterial or venous infarct or other cerebral anomalies associated with adverse neurological outcome.[14]

Data were stored and statistical analysis was carried out with the IBM SPSS 20.0 statistical package (IBM, Chicago, IL, USA). Using univariable logistic regression analysis, preselection of variables for the prediction of SFD was performed to select those for inclusion in the subsequent multivariable analysis. Logistic regression analysis was performed separately for SFD of donors and recipients. Variables with $P \leq 0.10$ were considered for inclusion in the multivariable analysis. For analysis, absent and reversed end-diastolic flow (A/REDF) in the umbilical artery was clustered as one variable because of the low prevalence of REDF in the cohort. Absent and reversed A-wave in the DV were clustered as one variable because of low prevalence of absent A-wave in the cohort. Variables with a very low prevalence or too many missing values were omitted from the analysis.

A multivariable model was constructed to identify independent predictors of SFD in donors and in recipients, using backward stepwise elimination. Variables with $P < 0.05$ remained in the final model. For all associations in the model the odds ratios (OR) and their 95% CIs were computed.

Results

In the study period, a total of 288 pregnancies were referred to our hospital for TTTS. An overview of the total cohort is shown in Figure 1. Four cases were excluded because of chromosomal or major congenital abnormalities. Laser coagulation was not performed in two cases owing to impaired visualization. These pregnancies were managed expectantly.

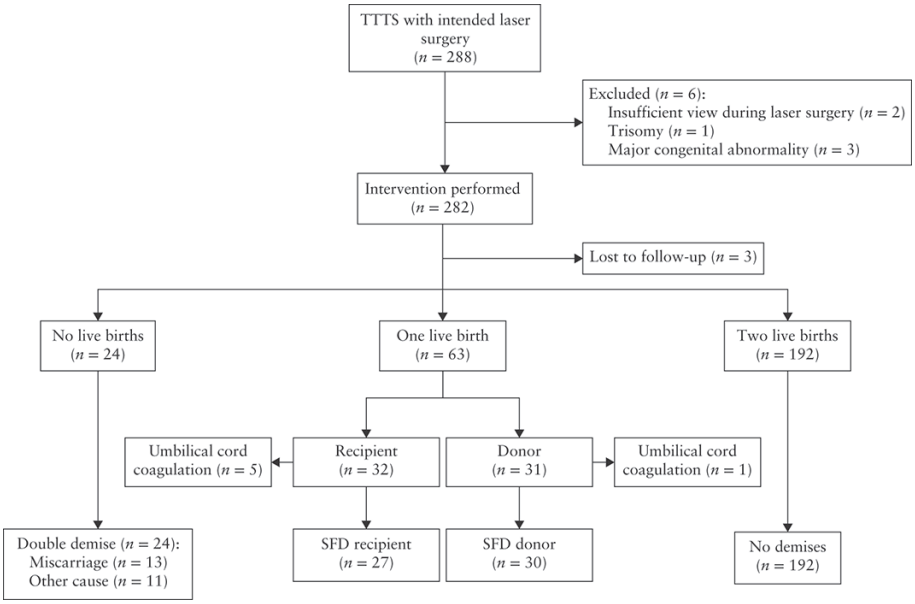

Figure 1. Flowchart of monochorionic-diamniotic twin pregnancies that underwent laser therapy for twin-twin tranfusion syndrome (TTTS)

In 282 pregnancies laser coagulation of the communicating vessels was attempted. Three cases were lost to follow-up and excluded from the analysis. In six cases that appeared suitable for laser therapy, umbilical cord coagulation was performed instead owing to technical complications (Table 1).

A total of 273 pregnancies received laser therapy for TTTS. Of these, 138 (50.5%) also participated in the Solomon trial.[9] A total of 120 (48%) pregnancies were treated with the Solomon technique. Table 2 shows the characteristics of the cohort treated with laser therapy according to their outcome. The mean ± SD gestational age at the time of laser procedure was 20.0 weeks ± 3.0 days. SFD occurred in 11.0% (30/273) of donors and in 9.9% (27/273) of recipient twins. The majority of SFD was detected within 1 week after laser surgery in 60.0% (18/30) of donor SFD and in 74.1% (20/27) of recipient SFD. Double fetal demise occurred in 4.0% (11/273) and the pregnancy ended in miscarriage with no survivors in 4.8% (13/273). Live birth of both twins occurred in 70.3% (192/273) of pregnancies, providing 249 pregnancies for inclusion in the analysis.

Table 1. Technical complications that resulted in umbilical cord coagulation instead of the intended laser therapy in six fetuses with twin-twin transfusion syndrome

Case	Type	Quintero stage	GA (wk+day)	Complication
1	R	II	17+0	Uterus subseptus, hemorrhage at trocar insertion, donor blocking vascular equator
2	R	III	15+4	Insufficient visualization owing to amnion dehiscence in early pregnancy
3	R	IV	22+0	Hemorrhage on trocar insertion, insufficient visualization
4	R	III	18+0	Donor blocking vascular equator
5	D	III	16+0	Difficult visualization in early pregnancy and obese patient; laser therapy difficult to maintain due to major velamentous anastomoses
6	R	II	19+2	Donor blocking vascular equator

R, recipient; D, donor; Q, Quintero stage; GA, gestation age at procedure

Table 2. Baseline characteristics of 273 pregnancies with twin–twin transfusion syndrome (TTTS) treated with laser therapy, according to survival outcome

	No IUFD	sIUFD donor	sIUFD recipient	IUFD double	All
	(n = 192)	(n = 30)	(n = 27)	(n = 24)	(n = 273)
GA at laser therapy (weeks)	20.0 (18.3-22.8)	18.7 (16.4-20.4)	20.1 (16.7-22.4)	18.8 (16.2-20.6)	19.7 (17.9-22.2)
Maternal age (years)	30.3 ± 4.8	31.2 ± 4.9	32.4 ± 4.7	31.3 ± 6.2	30.6 ± 5.0
Stage of TTTS					
I	19 (9.9)	3 (10)	2 (7.4)	-	24 (8.8)
II	63 (32.8)	8 (26.7)	5 (18.5)	5 (20.8)	81 (29.7)
III	102 (53.1)	19 (63.3)	19 (70.3)	19 (79.2)	159 (58.2)
IV	8 (4.2)	-	1 (3.7)	-	9 (2.5)
Laser-to-IUFD interval					
<24hrs	-	13 (43.3)	15 (55.5)	6 (25.0)*	
24 h to7days	-	5 (16.7)	5 (18.5)	4 (16.7)	
>7 days	-	12 (40.0)	7 (25.9)	11 (45.8)	
GA at delivery (weeks)	33.0 (30.1-35.3)	34.7 (31.0-36.3)	36.0 (32.3-37.8)	20.7 (18.8-22.4)	33.0 (29.6-35.6)

Data are presented as median (interquartile range), mean ± SD or n (%).
** In 3 cases of double demise there was unequal time of demise of both twins*

Table 3 summarizes the incidence of potential risk factors for SFD in donors and recipients, and values are compared with those in controls (live birth of both twins). The results of multivariable analysis for the identification of predictors of SFD in donor and recipient twins are shown in Tables 4 and 5, respectively. Variables associated with SFD of donor twins after univariable analysis were: EFW discordance, A/REDF in the umbilical artery, presence of arterioarterial (AA) anastomoses detected during fetoscopy and lower gestational age at the procedure.

Table 3. Characteristics of controls versus SFD donor or recipient twin

Variable	Controls (n = 192)	SFD donor (n = 30)	p-value*	SFD recipient (n = 27)	p-value*
Basic parameters					
GA at procedure (weeks)	20.0 (18.3–22.8)	18.7 (16.4–20.4)	0.01	20.1 (16.7–22.4)	0.18
Anterior placenta	63 (32.8)	10 (33.3)	0.96	12 (44.4)	0.24
EFW discordance (%)	18.0 ± 13.2	27.1 ± 10.8	< 0.01	19.7	
Ultrasound parameters in recipient					
Deepest vertical pocket (mm)	98.4 ± 33.4	93.7 ±22.7	0.46	102.6 ±34.6	0.55
A/REDF UA	6 (3.1)	1 (3.4)	0.98	3 (12.5)	0.06
MCAPSV >1.5 MoM	0	0	-	0	-
Pulsatile UV	69 (49.3)	11 (44.0)	0.63	15 (71.4)	0.07
A/R atrial flow DV	35 (18.2)	3 (10.0)	0.22	10 (37.0)	0.02
Cardiomegaly	43 (22.5)	8 (26.7)	0.62	5 (18.5)	0.64
Ascites	8 (4.2)	-	-	1 (3.7)	0.90
Pericardial effusion	7 (3.7)	3 (6.7)	0.44		
Pleural effusion	2 (1.0)	-	-	1 (3.7)	0.30
Subcutaneous oedema	3 (1.6)	-	-	-	-
Ultrasound parameters in donor					
Bladder not visible	37 (20.3)	9 (31.0)	0.20	1 (4.2)	0.09
A/REDF UA	43 (22.4)	14 (46.7)	<0.01	8 (32.0)	0.02
MCAPSV >1.5 MoM	7 (4.2)	2 (7.4)	0.47	3 (12.5)	0.11
Pulsatile UV	22 (17.7)	4 (18.3)	0.96	3 (15.0)	0.76
A/R atrial flow DV	11 (5.7)	3 (10)	0.44	1 (4.5)	0.69
Cardiomegaly	9 (4.7)	3 (10.0)	0.24	-	-
Ascites	1 (0.5)	-	-	-	-
Pericardial effusion	4 (2.1)	1 (3.3)	0.65	-	-
Placental angioarchitecture					
Velamentous cord insertion (recipient)	22 (11.8)	1 (4.0)	0.25	6 (25)	0.05

Variable	Controls (n = 192)	SFD donor (n = 30)	p-value*	SFD recipient (n = 27)	p-value*
Velamentous cord insertion (donor)	41 (21.8)	5 (22.7)	0.24	2 (9.5)	0.16
Presence of AA anastomoses	15 (8.1)	9 (33.3)	<0.01	2 (8)	0.99
Absence of AVRD	5 (2.7)	2 (7.4)	0.22	4 (15)	<0.01
Laser therapy characteristics					
Solomon technique	93 (48.4)	17 (56.7)	0.40	10 (37.0)	0.11
PPROM < 14 days after procedure	10 (5.2)	3 (10.0)	0.31	2 (7.4)	0.64
Intrauterine bleeding during procedure	3 (1.6)	2 (6.7)	0.11	1 (3.7)	0.45

*Values are given as median (interquartile range), mean ± SD or n (%). Data were not available in all cases; percentages reflect this. *Compared to controls. AA, arterioarterial; A/R, absent or reversed; A/REDF, absent or reversed end-diastolic flow; AVRD, arteriovenous anastomoses from recipient to donor; DV, ductus venosus; EFW, estimated fetal weight; GA, gestational age; MCA-PSV, middle cerebral artery peak systolic velocity; MoM, multiples of the median; PPROM, preterm prelabor rupture of membranes; UA, umbilical artery; UV, umbilical vein.*

Lower gestational age at the procedure was excluded from analysis because it showed correlation with abnormal flow in the umbilical artery, and priority was given to the clinically relevant variable of blood flow over gestational age. After multivariable analysis, independent risk factors for SFD in donor twins were: A/REDF in the umbilical artery (OR, 3.0 (95% CI, 1.1–8.0); ***P*** = 0.01), presence of AA anastomoses (OR, 4.2 (95% CI, 1.4–13.1); ***P*** = 0.03) and discordance in EFW (OR, 1.0 (95% CI, 1.0–1.1); ***P*** = 0.04).

Variables associated with SFD in recipient twins were: A/REDF in the umbilical artery in one or both twins, absent or reversed A-wave in the DV and pulsatile flow in the umbilical vein of the recipient twin, velamentous cord insertion for the recipient and absence of recipient-to-donor arteriovenous (AVRD) anastomoses. Pulsatile flow in the umbilical vein was excluded from the analysis as there were too many missing values, which impedes multivariable analysis. After multivariable analysis, absent or reversed A-wave in the DV (OR, 3.6 (95% CI, 1.2–10.5); *P* = 0.02) and absence of AVRD anastomoses (OR, 10.6 (95% CI, 1.8–62.0); *P* < 0.01) remained independent factors for SFD of the recipient twin.

Table 4. Univariable and multivariable logistic regression model analysis to identify predictors of single fetal demise in donor twin after laser therapy for twin-twin transfusion syndrome

Variable	Univariable		Multivariable	
	OR (95% CI)	P-value	OR (95% CI)	P-value
GA at procedure	0.97 (0.95-0.99)	0.01		
EFWD	1.06 (1.02-1.10)	<0.01	1.04 (1.00-1.09)	0.04
AREDF UA	5.19 (2.31-11.78)	<0.01	2.95 (1.08-8.03)	0.01
Presence AA anastomoses	5.59 (2.23-13.98)	<0.01	4.21 (1.36-13.06)	0.03

SFD, single fetal demise; GA, gestational age; EFWD, estimated fetal weight discordance; AREDF, absent or reverse end diastolic flow; UA, umbilical artery; AA, arterio-arterial anastomoses.

Complications of laser treatment, such as intrauterine bleeding or ruptured membranes within 2 weeks after treatment, did not differ significantly between controls and SFD groups. Neonatal death occurred in 2/30 (6.7%) recipients. Both were delivered before 26 weeks' gestation; one had severe cerebral injury, but no cerebral imaging was performed in the other. One case was lost to neonatal follow-up. Severe cerebral injury in surviving recipients was found in 1/27 (3.7%); gestational age at delivery was 25 weeks. One recipient had no abnormalities on neonatal cerebral ultrasound but showed neurodevelopmental impairment at the follow-up visit at 2 years of age. Neonatal death occurred before cerebral imaging was performed in 2/27 (7.4%) donors; both were delivered before 26 weeks' gestation. Severe cerebral injury was not found in any of the surviving donors. One case was lost to follow-up.

Table 5. Univariable and multivariable logistic regression model – recipient

Variable	Univariable		Multivariable	
	OR (95% CI)	P-value	OR (95% CI)	P-value
Velamentous cord insertion (recipient)	3.03 (1.00–9.19)	0.05		
A/REDF in UA (recipient)	4.10 (0.95–17.60)	0.06		NS
A/REDF in UA (donor)	2.61 (1.03–6.61)	0.04		NS
A/R A-wave in DV	3.06 (1.24–7.54)	0.02	3.59 (1.23–10.51)	0.02
Pulsatile UV (recipient)	2.57 (0.94–7.01)	0.07		NS
Absence of AVRD	6.86 (1.71–27.56)	< 0.01	10.59 (1.81–62.02)	< 0.01

A/R, absent or reversed; A/REDF, absent or reversed end-diastolic flow; AVRD, arteriovenous recipient-to-donor anastomoses; DV, ductus venosus; OR, odds ratio; UA, umbilical artery; UV, umbilical vein.

Discussion

In this study, predictors of SFD following laser surgery for TTTS were abnormal Doppler flow profiles and the type of anastomoses present at the time of treatment. Our results for overall survival rate are consistent with those of previous reports.[3-5,15,16] Rates of severe cerebral injury of the surviving twin following SFD were comparable with those of overall cerebral injury in TTTS laser therapy.[17-19]

Abnormal Doppler flow

A/REDF in the umbilical artery for donors and abnormal A-wave in the DV for recipients were found to be independent risk factors for SFD, both reflecting Quintero-Stage-III TTTS. A/REDF is a known predictor of demise of the donor and is thought to reflect hypotension secondary to TTTS.[4,16,20,21] Acute hemodynamic changes take place when the communicating vessels are coagulated. Gratacós *et al*.[22] evaluated the impact of fetoscopic laser coagulation within the first days after the procedure, and found that up to 50% of donors with abnormal flow in the umbilical artery showed reappearance of positive EDF in the umbilical artery within 1 week. However, up to 25% of donors developed transient tricuspid valve insufficiency or hydropic signs owing to relative hypervolemia after laser treatment.[22] We speculate that in more severely compromised donor fetuses, sudden restoration of volume status can cause fetal demise. This hypothesis is supported by the studies of Eixarch *et al*.[15] and Skupski *et al*,[5] who found only REDF in the umbilical artery as a risk factor for fetal demise and not AEDF. They considered that REDF reflects a more severe degree of compromise in TTTS.

In recipient twins, an absent/reversed A-wave in the DV was an independent risk factor for fetal demise. This is in agreement with studies of Skupski *et al*.[5] and Zikulnig *et al*.[23] An abnormal A-wave in the DV is suggestive of increased central venous/right atrial pressure, thus cardiac compromise, probably due to hypervolemia with increased end-diastolic ventricular pressure. In more advanced stages this may result in cardiac dysfunction and fetal hydrops. It has been postulated that acute restoration of volume status causes acute altered preload, resulting in the demise of these fetuses.

Type of anastomoses

We identified the presence of AA anastomoses as a risk factor for SFD in donors and the absence of AVRD anastomoses for SFD in recipients. This association has not been described previously. AA anastomoses are thought to equalize blood flow between fetuses and protect against TTTS. They are accompanied by branching vessels that enter the cotyledon

of the recipient or donor twin. The function of the AA anastomosis depends on where the hemodynamic equator lies. Depending on whether the AA anastomosis is located on the donor or recipient side, it serves as a functional AVRD or donor-to-recipient arteriovenous (AVDR) anastomosis. AA anastomoses occur in 19–37% of TTTS cases, compared with 91% of uncomplicated MC twin pregnancies.[24-26] Umur *et al*.[27] claimed that AA anastomoses protect against TTTS more frequently than do AVRD anastomoses of similar size because of a smaller resistance. We hypothesize that if AA anastomoses are unable to prevent TTTS, they might make an important contribution to causing the disease by behaving as a strong functional arteriovenous anastomosis. This is in agreement with the findings of a small study by Murakoshi *et al*,[25] who showed unidirectional flow in 93% of AA anastomoses in a cohort of 14 TTTS cases. Interestingly, unidirectional flow could be from donor to recipient or vice versa, suggesting that AA anastomoses can play either a causal role or a compensating role in TTTS. In our study we could not investigate flow in AA anastomoses, therefore the function of the coagulated AA anastomoses in these cases is unknown. SFD in the presence of an AA anastomosis can be explained by the hypothesis that acute hemodynamic changes at the time of laser surgery are more profound in these cases.

AVRD anastomoses establish blood flow from recipient to donor and therefore compensate for AVDR anastomoses in TTTS. In our study, absence of these vessels was found in 14.8% (4/27) of dead recipients and was associated with SFD in recipients. The pathogenesis of this phenomenon is not well understood. Hypothetically, recipients, in the absence of AVRD anastomoses, face more hypervolemic challenges during TTTS than when the vessels are present, resulting in more profound volume changes after laser therapy, which might result in fetal demise. On the other hand, sample size was limited and more research is needed to confirm this finding.

Abnormal Doppler flow, as defined in Quintero Stage III, is a strong predictor of SFD, reflecting more profound hemodynamic challenges in pregnancies with TTTS. Fetal

survival might improve through the training of referral-center personnel, to achieve timely referral and treatment. Furthermore, the type of anastomoses present at the time of TTTS appears to play an important role in SFD. We speculate that the type of anastomoses determines the degree of hemodynamic change that occurs during laser therapy. Although the exact pathogenesis is not fully understood, this knowledge provides us with the opportunity to investigate the options available to adapt our fetoscopic laser procedure in the future. Crombleholme *et al*.[28] and Zaretsky *et al*.[29] state that adjunctive medical therapy might improve the survival of recipient twins with signs of cardiomyopathy, and suggest further research on this topic. We speculate that vasoactive medication could prevent SFD through stabilization of the hemodynamics in both fetuses. This should be the subject of future research to improve survival after laser therapy for TTTS.

Strengths and limitations of the study

We believe that the strengths of our study are the separate evaluation of unexplained SFD in donors and recipients, as they face different challenges in TTTS, and the relatively large size of our consecutive cohort, which enabled analysis by logistic regression to assess the value of most variables as prognostic factors. Nevertheless, some potential predictors were limited in number, preventing robust conclusions to be made on their importance.

It can be difficult to recognize the type of anastomosis, but where possible this parameter was recorded during laser therapy. This constitutes a limitation of our study, especially as regards smaller arteriovenous anastomoses, while AA anastomoses are more easily recognized. The incidence of AA anastomoses in our study was 10.4%, which is low compared with previously reported values of up to 37% in postpartum placenta dye-injection examinations. Although these studies did not state whether laser therapy was performed and if fetal demise occurred, this could indicate an underestimation of AA anastomoses in our study.

Conclusion

Abnormal blood flow patterns and the type of anastomoses present between twins are associated with SFD after laser treatment. Both parameters are a reflection of the hemodynamic challenges fetuses face in TTTS. Fetuses in more advanced stages of TTTS carry a higher risk of fetal demise, so early detection and well-timed therapy might improve fetal outcome. In addition, future studies should, on the one hand, focus on the role of different types of anastomoses in hemodynamic changes during laser therapy, and, on the other hand, focus on stabilization of the fetal circulation before and during laser treatment. This would provide opportunities to adapt our management of TTTS in order to decrease vulnerability to acute pre- and afterload changes and improve outcome.

References

1. Fisk NM, Duncombe GJ, Sullivan MH. The basic and clinical science of twin–twin transfusion syndrome. *Placenta*2009; 30: 379–390.
2. Berghella V, Kaufmann M. Natural history of twin–twin transfusion syndrome. *J Reprod Med* 2001; 46: 480–484.
3. Rossi AC, D'Addario V. Comparison of donor and recipient outcomes following laser therapy performed for twin–twin transfusion syndrome: a meta-analysis and review of literature. *Am J Perinatol* 2009; 26: 27–32.
4. Martinez JM, Bermudez C, Becerra C, Lopez J, Morales WJ, Quintero RA. The role of Doppler studies in predicting individual intrauterine fetal demise after laser therapy for twin–twin transfusion syndrome. *Ultrasound Obstet Gynecol* 2003; 22: 246–251.
5. Skupski DW, Luks FI, Walker M, Papanna R, Bebbington M, Ryan G, O'Shaughnessy R, Moldenhauer J, Bahtiyar O; North American Fetal Therapy Network (NAFTNet). Preoperative predictors of death in twin-to-twin transfusion syndrome treated with laser ablation of placental anastomoses. *Am J Obstet Gynecol* 2010; 203: 388.e1–388.e11.
6. Senat MV, Deprest J, Boulvain M, Paupe A, Winer N, Ville Y. Endoscopic laser surgery versus serial amnioreduction for severe twin-to-twin transfusion syndrome. *N Engl J Med* 2004; 351: 136–144.
7. Quintero RA, Morales WJ, Allen MH, Bornick PW, Johnson PK, Kruger M. Staging of twin–twin transfusion syndrome. *J Perinatol* 1999; 19: 550–555.
8. Lopriore E, Slaghekke F, Middeldorp JM, Klumper FJ, van Lith JM, Walther FJ, Oepkes D. Accurate and simple evaluation of vascular anastomoses in monochorionic placenta using colored dye. *J Vis Exp* 2011; e3208.
9. Slaghekke F, Lopriore E, Lewi L, van Zwet EW, Weingertner AS, Klumper FJ, Dekoninck P, Devlieger R, Kilby MD, Rustico MA, Deprest J, Favre R, Oepkes D. Fetoscopic laser coagulation of the vascular equator versus selective coagulation for twin-to-twin transfusion syndrome: an open-label randomised controlled trial. *Lancet* 2014; 383: 2144–2151.
10. Lewi L, Jani J, Cannie M, Robyr R, Ville Y, Hecher K, Gratacos E, Vandecruys H, Vandecaveye V, Dymarkowsky S, Deprest J. Intertwin anastomoses in monochorionic placentas after fetoscopic laser coagulation for twin-to-twin transfusion syndrome: is there more than meets the eye? *Am J Obstet Gynecol* 2006; 194: 790–795.
11. Papile LA, Burstein J, Burstein R, Koffler H. Incidence and evolution of subependymal and intraventricular hemorrhage: a study of infants with birth weights less than 1,500 gm. *J Pediatr* 1978; 92: 529–534.
12. de Vries LS, Eken P, Dubowitz LM. The spectrum of leukomalacia using cranial ultrasound. *Behav Brain Res* 1992; 49: 1–6.
13. Levene MI. Measurement of the growth of the lateral ventricles in preterm infants with real-time ultrasound. *Arch Dis Child* 1981; 56: 900–904.
14. Lopriore E, Sueters M, Middeldorp JM, Oepkes D, Vandenbussche FP, Walther FJ. Neonatal outcome in twin-to-twin transfusion syndrome treated with fetoscopic laser occlusion of vascular anastomoses. *J Pediatr* 2005; 147: 597–602.
15. Eixarch E, Valsky D, Deprest J, Basschat AA, Lewi L, Ortiz JU, Martinez-Crespo JM, Gratacos E. Preoperative prediction of the individualized risk of early fetal death after laser therapy in twin-to-twin transfusion syndrome. *Prenat Diagn* 2013; 33: 1033–1038.

16. Ishii K, Hayashi S, Nakata M, Murakoshi T, Sago H, Tanaka K. Ultrasound assessment prior to laser photocoagulation for twin–twin transfusion syndrome for predicting intrauterine fetal demise after surgery in Japanese patients. *Fetal Diagn Ther* 2007; 22: 149–154.
17. Crombleholme T. Central nervous system injury in twin–twin transfusion syndrome: opportunity for improvement? *Obstet Gynecol* 2012; 120: 7–8.
18. Spruijt M, Steggerda S, Rath M, van Zwet E, Oepkes D, Walther F, Lopriore E. Cerebral injury in twin–twin transfusion syndrome treated with fetoscopic laser surgery. *Obstet Gynecol* 2012; 120: 15–20.
19. van Klink JM, Koopman HM, van Zwet EW, Middeldorp JM, Walther FJ, Oepkes D, Lopriore E. Improvement in neurodevelopmental outcome in survivors of twin–twin transfusion syndrome treated with laser surgery. *Am J Obstet Gynecol* 2014; 210: 540.e1–7.
20. Yamamoto M, Robyr R, Takahashi Y, Ville Y. Intrauterine fetal demise following laser treatment in twin-to-twin transfusion syndrome. *BJOG* 2006; 113: 590–594.
21. Stirnemann JJ, Nasr B, Essaoui M, Bussieres L, Ville Y. A nomogram for perioperative prognostic risk-assessment in twin–twin transfusion syndrome. *Prenat Diagn* 2013; 33: 103–108.
22. Gratacós E, Van Schoubroeck D, Carreras E, Devlieger R, Roma E, Cabero L, Deprest J. Impact of laser coagulation in severe twin–twin transfusion syndrome on fetal Doppler indices and venous blood flow volume. *Ultrasound Obstet Gynecol* 2002; 20: 125–130.
23. Zikulnig L, Hecher K, Bregenzer T, Baz E, Hackeloer BJ. Prognostic factors in severe twin–twin transfusion syndrome treated by endoscopic laser surgery. *Ultrasound Obstet Gynecol* 1999; 14: 380–387.
24. de Villiers SF, Slaghekke F, Middeldorp JM, Walther FJ, Oepkes D, Lopriore E. Arterio-arterial vascular anastomoses in monochorionic placentas with and without twin–twin transfusion syndrome. *Placenta* 2012; 33: 652–654.
25. Murakoshi T, Quintero RA, Bornick PW, Allen MH. In vivo endoscopic assessment of arterioarterial anastomoses: insight into their hemodynamic function. *J Matern Fetal Neonatal Med* 2003; 14: 247–255.
26. Zhao DP, de Villiers SF, Slaghekke F, Walther FJ, Middeldorp JM, Oepkes D, Lopriore E. Prevalence, size, number and localization of vascular anastomoses in monochorionic placentas. *Placenta* 2013; 34: 589–593.
27. Umur A, van Gemert MJ, Nikkels PG, Ross MG. Monochorionic twins and twin–twin transfusion syndrome: the protective role of arterio-arterial anastomoses. *Placenta* 2002; 23: 201–209.
28. Crombleholme TM, Lim FY, Habli M, Polzin W, Jaekle R, Michelfelder E, Cnota J, Liu C, Kim MO. Improved recipient survival with maternal nifedipine in twin–twin transfusion syndrome complicated by TTTS cardiomyopathy undergoing selective fetoscopic laser photocoagulation. *Am J Obstet Gynecol* 2010; 203: 397–399.
29. Zaretsky MV, Somme S, Crombleholme TM. Role of adjunctive medical therapy in the fetoscopic surgical treatment of twin–twin transfusion syndrome. *Am J Perinatol* 2014; 31 (Suppl 1): S39–S46.

S.J. Eschbach
L.S.A. Tollenaar
E. Lopriore
D. Oepkes
M.C. Haak

Published in: Prenatal Diagnosis, 2020; 40(10): 1284-1289

CHAPTER IV

Abnormal umbilical artery flows in appropriately grown monochorionic twins in relation to proximate cord insertion: A harmful combination?



Abstract

Objective

To compare the prevalence of intermittent absent or reversed end-diastolic flow (iAREDF) in the umbilical artery in appropriately grown monochorionic diamniotic (MCDA) pregnancies with and without proximate cord insertion (PCI), and to evaluate pregnancy outcome

Methods

The prevalence of iAREDF in MCDA pregnancies with PCI (n=11) was compared with a control group without PCI (n=33). PCI was defined as a distance between the cord insertions below the fifth percentile. Placental sharing, number, and diameter of anastomoses were assessed by placental examination. Pregnancy outcome was evaluated.

Results

iAREDF was present in 7/11 PCI pregnancies, compared with 0/33 in the control group (p=<0.01). All PCI pregnancies and 94% of controls had arterio-arterial (AA)-anastomoses (p=0.56), the diameter was larger in the PCI group, respectively 3.3 versus 2.1 mm (p=0.03). Three cases with iAREDF had adverse outcome, two resulted in fetal death of which one with brain damage in the co-twin, another underwent early premature emergency section for fetal distress

Conclusion

iAREDF occurs in a large proportion of MCDA pregnancies with PCI and is related to the diameter of the AA anastomosis. We hypothesize that iAREDF in appropriately grown MCDA twin pregnancies reflects an unstable hemodynamic balance with an increased risk for fetal deterioration. Whether outcome in these pregnancies can be improved by altered management requires further investigation.

Introduction

Monochorionic diamniotic (MCDA) twins carry a high risk for specific pregnancy complications due to their shared placental circulation.[1] Type, number and size of the vascular anastomoses on the placental surface influence the risk for twin-twin transfusion syndrome (TTTS), twin anemia polycythemia sequence (TAPS) and, when combined with an unequally shared placenta, selective intra-uterine growth restriction (sIUGR). A combination of a central and velamentous insertion is known to increase the risk for complications as well, especially in sIUGR pregnancies.[2,3]

The assessment of Doppler waveforms in the umbilical artery is used to estimate the risk of adverse outcome in complicated monochorionic twins. A specific flow pattern, first described in 1994, is intermittent absent or reversed end-diastolic flow (iAREDF) in the smaller twin of sIUGR.[4] This is attributed to a large arterio-arterial (AA) anastomosis that facilitates transmission of the systolic waveforms of one twin into the umbilical cord of the co-twin.[5] The iAREDF reflects an unstable hemodynamic balance between the two fetuses,[6,7] and the presence of iAREDF is associated with unexpected fetal death in cases with sIUGR.[7,8] If single fetal death occurs in monochorionic twin pregnancies, this can result in severe cerebral injury or even fetal death in the co-twin.[9-11]

We observed several cases with iAREDF in MCDA twins in absence of TTTS, TAPS of sIUGR. In these pregnancies, cord insertions lied very close to each other on the placental surface, which is known as 'proximate cord insertion' (PCI). PCI occurs in 3% of monochorionic diamniotic (MCDA) pregnancies and a large AA anastomosis is always present.[9,12] Currently, it is unknown whether this specific subgroup is at increased risk of adverse pregnancy outcome such as known in sIUGR. The aim of our study was to assess the presence of iAREDF in appropriately grown MCDA pregnancies with and without PCI, in absence of TTTS, TAPS or sIUGR and evaluate a possible relation to pregnancy outcome.

Methods

The Leiden University Medical Center is the national referral center for complicated monochorionic twin pregnancies. Data on prenatal ultrasound, placental characteristics and neonatal outcome of all monochorionic twins born in our unit are prospectively entered in fetal and neonatal databases. Placentas of all monochorionic

twins are routinely injected with colored dye. Pictures of the placenta are taken with a measuring tape to allow measurements on the digital picture.[13] To assess the relationship between PCI and iAREDF in MCDA pregnancies, we extracted all PCI cases based on placental examination after birth. We selected all pregnancies that received prenatal care, including ultrasonographic follow-up, in our unit, born between January 2004 and June 2017. PCI was defined as a distance between the cord insertions below the 5th percentile, ranging from 3.3 to 4.0 cm across gestation.[12] We excluded cases with TTTS, TAPS and sIUGR, as the aim of this study was to assess the prevalence of iAREDF in appropriately grown, uncomplicated monochorionic twin pregnancies. TTTS was defined using the Eurofoetus criteria and the Quintero staging system.[14,15] sIUGR was defined as an estimated fetal weight below the 10th percentile in one twin and an inter-twin difference of estimated fetal weight at ultrasound of >25%.[7] When manifestation of sIUGR took place weeks after the initial finding of iAREDF, the case remained in the study in order to evaluate pregnancy outcome in cases with iAREDF in appropriately grown fetuses at time of examination. As control cases, we included all consecutive uncomplicated MCDA pregnancies between January 2013 and June 2017 without PCI. The size of AA anastomosis and placental share discordance were measured on the placenta pictures. Placental share discordance was calculated as (larger placental area – smaller placental area)/(larger placental area)x100%.

All monochorionic pregnancies attending our clinic receive ultrasonographic examinations biweekly from 14 weeks gestational age onwards. In uncomplicated monochorionic twins, labor is induced at 36 weeks of gestation. We reviewed all ultrasound examinations of PCI cases and controls, including biometry and flow velocity waveforms of the umbilical artery in both twins. iAREDF in the umbilical artery was defined as the clear observation of absent and reversed end diastolic flow, alternating with positive diastolic flow over a short period of time, in the absence of fetal and maternal breathing.[7] Ductus venosus flow was defined as normal when a positive a□wave was present, and abnormal when absent or reversed a□wave in the ductus venosus was seen. We assessed fetal survival, gestational age of delivery and birthweight (BW) discordance, the latter was calculated as (BW larger twin- BW smaller twin)/(BW larger twin) x100%.

Statistical analysis was performed with IBM SPSS 25.0 statistical package. Categorical variables were analyzed using the independent-samples t-test, and a chi-square test was performed to analyze continuous variables. A p-value of <0.05 was considered statistically significant.

▼**Figure 1.** Overview of umbilical artery flow in MCDA pregnancies with PCI

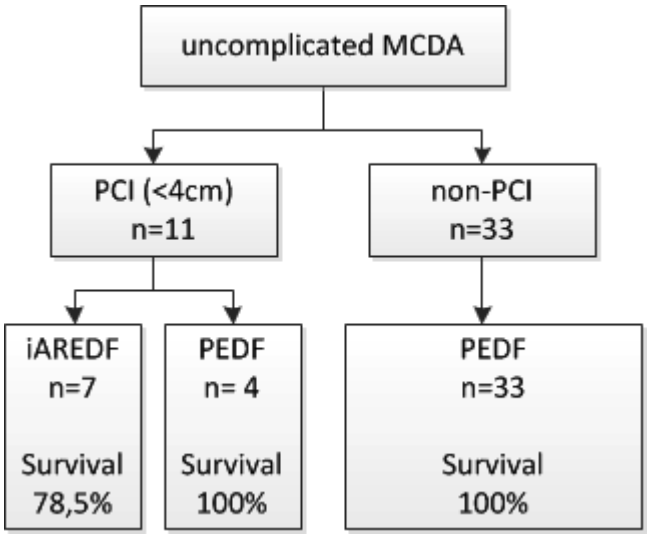

iAREDF, intermittent absent or reversed end-diastolic flow in the umbilical artery; MCDA, monochorionic diamniotic; PCI, proximate cord insertion; PEDF, positive end diastolic flow in the umbilical artery; TTTS, twin to twin transfusion syndrome

Results

We extracted 23 cases with an MCDA placenta with PCI in our placenta database. Twelve were excluded because of TTTS or sIUGR , thus 11 cases remained eligible for analysis. Thirty-three consecutive uncomplicated MCDA pregnancies without PCI were included as controls (see Figure 1).

In 64% (7/11) of PCI cases iAREDF was present, in the 33 control cases iAREDF was never encountered ($p<0.01$). Ductus venosus flows were normal in all cases. As shown in Table 1, the presence of AA anastomoses was comparable in both groups ($p=0.56$), but the diameter of the AA anastomosis in the PCI group was significantly larger than in controls ($p=0.03$). The majority of placentas showed only 1 AA-anastomosis. In the control group, 3 placentas were found with 2 AA-anastomoses, while 2 placentas showed no AA-anastomosis. There were no other differences in placental characteristics between both groups.

Table 2 summarizes the seven cases with iAREDF. In 4 cases the finding of iAREDF was transient and resolved in the third trimester. These cases resulted in a live birth of both twins after 34 weeks of gestation. In 3 of the 7 cases with iAREDF, fetal

deterioration occurred in the twin showing iAREDF. In the first case, unexpected fetal demise of this twin occurred at 20 weeks of gestation, despite absence of any sign of TTTS or sIUGR. Severe cerebral damage of the co-twin was found on follow-up scans, which was confirmed by fetal MRI. The parents chose to terminate the pregnancy at 23 weeks of gestation. Figure 2 shows the iAREDF in the umbilical artery at 18 weeks of gestation in this case, Figure 3 shows the placenta with proximate cord insertion. The second case was referred for iAREDF in MCDA twins with concordant growth at 20 weeks of gestation. Follow-up in the following weeks showed deteriorating fetal condition with frequent episodes of bradycardia. The estimated fetal weight of the iAREDF twin dropped from 30th percentile to below the 10th percentile within three weeks. Selective reduction of the iAREDF twin was chosen by the parents at 23 weeks gestation. The surviving twin was born healthy at 37 weeks of gestation. In this case, placental color dye injection could not be performed due to maceration of the placental share of the demised twin. The third case was referred to our center at 27 weeks with iAREDF of gestation of twin A, but concordant growth of the twins. The patient was admitted for fetal monitoring. After five days, caesarean section was performed because of non-reassuring fetal tracings, resulting in two live born twins of 1070 and 910 grams, respectively. Postnatal placental examination showed a large AA anastomosis between the umbilical cord insertions.

Table 1. Clinical and placental characteristics in MCDA pregnancies with and without PCI

	PCI (n=11)	**Controls (n=33)**	**p-value**
iAREDF in the umbilical artery of one twin, n (%)	7 (64)	0 (0)	<0.01
Gestational age at delivery in weeks^{+days}, median (IQR)	36^{+2} (34^{+2}-36^{+6})	36^{+0} (35^{+4}-36^{+3})	0.35
Fetal demise, n (%)	2 (18)	0 (0)	0.06
Birth-weight discordance in %, median (IQR)	7.4 (5.5-13.1)	10.7 (8.6-15.1)	0.28
Placental characteristics			
Placental-share discordance in %, median (IQR)	17.7 (0-17.7)	29.5 (12.8-40.8)	0.56
Total number of anastomoses, median (IQR)	6 (4-11))	11 (7-19)	0.20
Presence of AA anastomoses, n (%)†	11 (100)	31 (93.4)	0.56
Diameter of AA anastomoses in mm, median (IQR)	3.3 (2.9-5.9)	2.1 (1.1-2.8)	0.03

PCI, proximate cord insertion; iAREDF, intermittent absent and reversed diastolic flow; AA anastomosis, arterio-arterial anastomosis; IQR, interquartile range † In this small study, median interobserver difference was 0.1 mm (IQR 0.0-0.1) and median intraobserver difference was 0.1 mm (IQR 0.0-0.125).

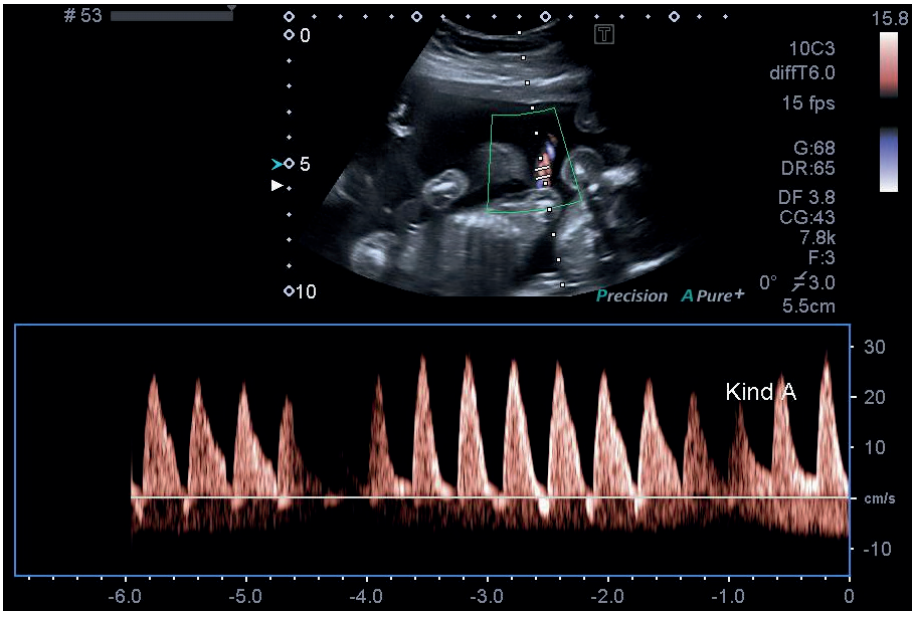

▲**Figure 2.** iAREDF at 18 weeks of gestation in an equal size MCDA pregnancy

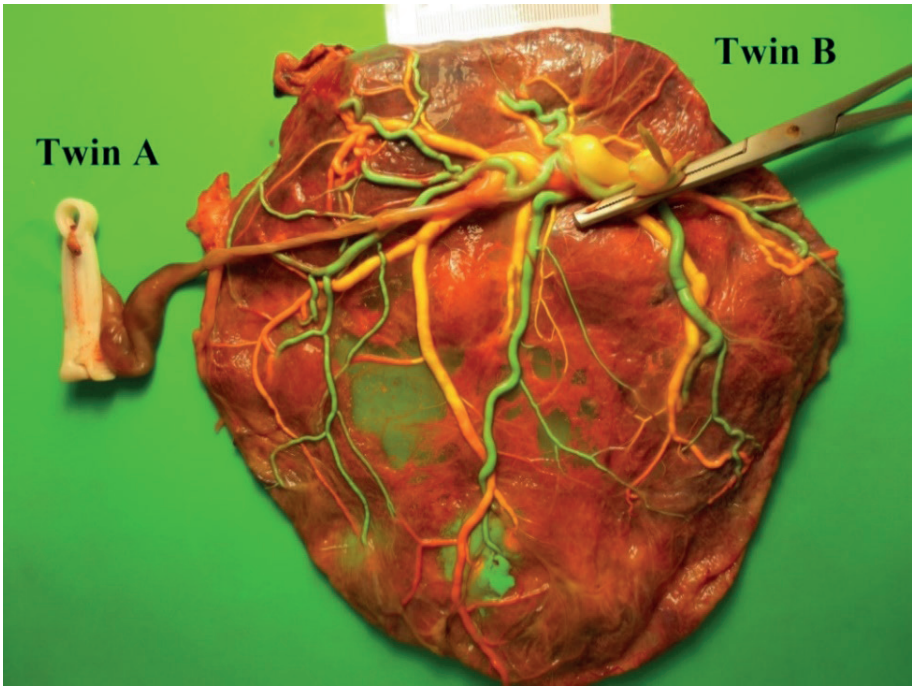

▲**Figure 3.** placenta of MCDA-pregnancy with PCI and fetal demise of iAREDF twin (case 1)

Table 2. Pregnancy outcome for PCI pregnancies with iAREDF

	iAREDF (GA in weeks)	Follow-up	GA delivery (weeks+days)	Birth weights twin1/ twin2 (grams)	Birth-weight discordance (%)
1	18	Fetal demise 20 weeks, TOP 23 weeks †	23^{+5}		
2	20	UCC for fetal deterioration at 23 weeks ‡	37^{+3}	2950	
3	27 §	Caesarean section at 28 weeks ¶	27^{+5}	1070/910	15.0
4	16	iAREDF resolved after 31 weeks	36^{+3}	2670/2160	18.8
5	16	iAREDF resolved after 24 weeks	36^{+1}	2350/2220	5.5
6	18	iAREDF resolved after 26 weeks	36^{+2}	2645/2350	11.2
7	22	iAREDF resolved after 26 weeks	34^{+2}	1810/1765	2.5

MCDA, monochorionic diamniotic; EFWD, estimated fetal weight discordance; GA, gestational age;; TOP, termination of pregnancy; UCC, umbilical cord coagulation; † intracerebral injury following fetal demise of cotwin (case 1); ‡ selective reduction because of hemodynamic deterioration of fetus with iAREDF (case 2); § no ultrasound data before 27 weeks; ¶ Caesarean section because non-reassuring cardiotocography of fetus with iAREDF (case 3).

Comments

The flow pattern of iAREDF in monochorionic twins is best known from the classification system described by Gratacos *et al*. for selective sIUGR.[7] iAREDF is caused by a large AA anastomosis and represents instable blood flow between both fetuses, with increased risk for sudden fetal demise in the smaller twin and subsequent brain damage in the larger twin.

This study shows that iAREDF can also been found in MCDA pregnancies with appropriately grown fetuses. Only a few cases have been described in literature so far. We found five cases with favorable pregnancy outcome after 34 weeks of gestation in the literature. One is a case report[16] and four were part of a larger cohort. [8] A large AA-anastomosis was found in all these cases, but the distance between the cord insertions was not reported. Another case with iAREDF with appropriately grown fetuses is described in a cohort study on iAREDF in MCDA pregnancies. In this case, delivery took place at 29 weeks of gestation with a birth weight difference of only 2%, but no other details were given.[17]

In our study, iAREDF was only found in cases with PCI. In the majority of PCI cases, iAREDF was absent or transient and pregnancy outcome was favorable. In case of transient abnormal flows, we hypothesize that the growth of an AA-anastomosis is not proportional with gestational age. The diameter of the AA-anastomoses might

increase less compared to the placental volume with gestational age, and the hemodynamic influence on the pregnancy might diminish in time.

Sudden fetal deterioration occurred in three of the seven pregnancies with iAREDF in this study, suggesting a possible correlation between iAREDF, PCI and fetal deterioration. Although cord insertion patterns such as velamentous insertion are known to increase the risk of complications[2,3] not much is known about the risk of proximate cord insertion. In monochorionic monoamniotic (MCMA) pregnancies, however, PCI is frequently seen.[9] Unexpected fetal demise in one or both twins is a known risk in these pregnancies[18] and is mostly attributed to cord entanglement. However, entanglement is not always found postnatally. Lewi *et al* [19] hypothesized that other causes such as acute exsanguination across the often present large caliber anastomoses between cord insertions may be an important co-factor in unexpected demise as well. This hypothesis could be in concordance with our findings in MCDA pregnancies. We did not find reports on iAREDF in appropriately grown MCMA twins. In PCI, monoamniotic or diamniotic, diameters of the AA anastomoses are larger and distance to the other twin is shorter compared to monochorionic placenta's without PCI. The vascular resistance in the AA anastomosis is lower when the diameter is larger and the distance between the cord insertions is shorter. Therefore, systolic hemodynamic forces increase when distance between the cord insertions is shorter and the diameter of the vessel is larger. Consequently, these hemodynamic changes are magnified in case of unbalance, and might be responsible for sudden deterioration and may even result in fetal demise. In addition, when demise of the iAREDF twin occurs, the short anastomosis with a large diameter, with therefore a lower resistance, may allow a more rapid and massive exsanguination in reverse direction which can result in severe cerebral injury in the surviving twin as represented in case 1.

Strengths and limitations

Our study evaluates the occurrence of iAREDF in appropriately grown MCDA pregnancies with PCI in a center with a high volume of MCDA pregnancies and a standardized follow-up, including placenta examination. A limitation of this study is the limited sample size, due to the low frequency of PCI in MCDA pregnancies. In addition, selection bias could play a role since our center is the referral center for monochorionic twin pregnancies in our country. MCDA with persistent abnormal flows are referred to our clinic for a second opinion (case 2 and 3) more often than MCDA pregnancies with normal flows.

Recommendations

Regarding management of MCDA pregnancies with PCI and iAREDF, strong conclusions cannot be made based on this small case series. We, however, recommend heightened awareness in the presence of the combination of iAREDF and PCI irrespective of fetal growth. We realize that such an as yet unproven concern may lead to increased anxiety by both parents and doctors, with the risk of (too) early interventions and possibly unnecessary harm of iatrogenic preterm birth. However, it is known that sudden fetal death occurs in up to 3.6% of appropriately grown, uncomplicated MCDA pregnancies after 24 weeks of gestation, and in up to 1.2% after 32 weeks of gestation.[20-22] Some of these cases may be associated with (unrecognized) PCI cases with iAREDF. A large observational multicenter study is needed to evaluate the prevalence and pregnancy outcome of iAREDF in PCI in monochorionic pregnancies, before we can suggest specific management for such cases.

Conclusion

MCDA pregnancies with PCI show a higher incidence of iAREDF in the umbilical artery. As in sIUGR, iAREDF might be a reflection of an unstable hemodynamic balance which might result in adverse pregnancy outcome. Prospective studies with a larger sample size should be performed to evaluate this phenomenon.

References

. Lewi L, Van Schoubroeck D, Gratacos E, et al. Monochorionic diamniotic twins: complications and management options. *Curr Opin Obstet Gynecol.* 2003;15(2):177-194.

2. Kalafat E, Thilaganathan B, Papageorghiou A, et al. Significance of placental cord insertion site in twin pregnancy. *Ultrasound Obstet Gynecol.* 2018;52(3):378-384.

3. Couck I, Mourad Tawfic N, et al. Does site of cord insertion increase risk of adverse outcome, twin-to-twin transfusion syndrome and discordant growth in monochorionic twin pregnancy? *Ultrasound Obstet Gynecol.* 2018;52(3):385-389.

4. Hecher K, Jauniaux E, Campbell S, et al. Artery-to-artery anastomosis in monochorionic twins. *Am J Obstet Gynecol.* 1994;171(2):570-572.

5. Valsky DV, Eixarch E, Martinez JM, et al. Selective intrauterine growth restriction in monochorionic twins: pathophysiology, diagnostic approach and management dilemmas. *Semin Fetal Neonatal Med.* 2010;15(6):342-348.

6. Wee LY, Taylor MJ, Vanderheyden T, et al. Transmitted arterio-arterial anastomosis waveforms causing cyclically intermittent absent/reversed end-diastolic umbilical artery flow in monochorionic twins. *Placenta.* 2003;24(7):772-778.

7. Gratacos E, Lewi L, Munoz B, et al. A classification system for selective intrauterine growth restriction in monochorionic pregnancies according to umbilical artery Doppler flow in the smaller twin. *Ultrasound Obstet Gynecol.* 2007;30(1):28-34.

8. Gratacos E, Lewi L, Carreras E, et al. Incidence and characteristics of umbilical artery intermittent absent and/or reversed end-diastolic flow in complicated and uncomplicated monochorionic twin pregnancies. *Ultrasound Obstet Gynecol.* 2004;23(5):456-460.

9. Hack KE, van Gemert MJ, Lopriore E, et al. Placental characteristics of monoamniotic twin pregnancies in relation to perinatal outcome. *Placenta.* 2009;30(1):62-65.

10. Hillman SC, Morris RK, Kilby MD. Co-twin prognosis after single fetal death: a systematic review and meta-analysis. *Obstet Gynecol.* 2011;118(4):928-940.

11. van Klink JM, van Steenis A, Steggerda SJ, et al. Single fetal demise in monochorionic pregnancies: incidence and patterns of cerebral injury. *Ultrasound Obstet Gynecol.* 2015;45(3):294-300.

12. Zhao DP, Peeters SH, Middeldorp JM, et al. Monochorionic placentas with proximate umbilical cord insertions: definition, prevalence and angio-architecture. *Placenta.* 2015;36(2):221-225.

13. Lopriore E, Slaghekke F, Middeldorp JM, et al. Accurate and simple evaluation of vascular anastomoses in monochorionic placenta using colored dye. *J Vis Exp.* 2011(55):e3208.

14. Quintero RA, Morales WJ, Allen MH, et al. Staging of twin-twin transfusion syndrome. *J Perinatol.* 1999;19(8 Pt 1):550-555.

15. Senat MV, Deprest J, Boulvain M, et al. Endoscopic laser surgery versus serial amnioreduction for severe twin-to-twin transfusion syndrome. *N Engl J Med.* 2004;351(2):136-144.

16. Lin TH, Lin CH, Shih JC, et al. Effect of arterioarterial anastomosis on early-onset umbilical artery flow abnormality in a monochorionic-diamniotic twin. *Ultrasound Obstet Gynecol.* 2012;40-(3):371-372.
17. Nakai Y, Ishiko O, Nishio J, et al. Cyclic changes in the umbilical arterial flow in mono-chorionic, di-amniotic twin pregnancy. *Eur J Obstet Gynecol Reprod Biol.* 2002;101(2):135-138.
18. Van Mieghem T, De Heus R, Lewi L, et al. Prenatal management of monoamniotic twin pregnancies. *Obstet Gynecol.* 2014;124(3):498-506.
19. Lewi L. Cord entanglement in monoamniotic twins: does it really matter? *Ultrasound Obstet Gynecol.* 2010;35(2):139-141.
20. Lee YM, Wylie BJ, Simpson LL, et al. Twin chorionicity and the risk of stillbirth. *Obstet Gynecol.* 2008;111(2 Pt 1):301-308.
21. Newman RB, Unal ER. Multiple gestations: timing of indicated late preterm and early-term births in uncomplicated dichorionic, monochorionic, and monoamniotic twins. *Semin Perinatol.* 2011;35(5):277-285.
22. Simoes T, Queiros A, Marujo AT, et al. Prospective risk of intrauterine death of monochorionic twins: update. *J Perinat Med.* 2016;44(8):871-874.



PART II

Cardiac compromise





S.J. Eschbach
L.S. Boons
E. van Zwet
J.M. Middeldorp
F.J. Klumper
E. Lopriore
A.K.K Teunissen
M.E. Rijlaarsdam
D. Oepkes
A.D.J. ten Harkel
M.C. Haak

Published in: Ultrasound in Obstetrics & Gynecology, 2017; 39(10): 838-347

CHAPTER V

Right ventricular outflow tract obstruction in complicated monochorionic twin pregnancy



Abstract

Objective

Severe right ventricular outflow tract obstruction (RVOTO) is a potential complications in recipients of twin-to-twin transfusion syndrome (TTTS) that requires postnatal treatment. We aimed to evaluate pregnancy characteristics of neo-nates with RVOTO from complicated monochorionic twin pregnancies, determine the incidence of RVOTO in TTTS cases and construct a prediction model for its development.

Methods

This was an observational cohort study of all complicated monochorionic twin pregnancies with a postnatal diagnosis of RVOTO at our center. Cases were referred for evaluation for evaluation because of TTTS, selective intrauterine growth restriction (sIUGR) or multiple congenital malformations in one of the twins. Ultrasound data were retrieved from our monochorionic twin database. Among liveborn TTTS recipients treated prenatally with laser therapy, those with RVOTO were compared with those without RVOTO. We describe four additional cases with RVOTO that were not TTTS recipients.

Results

A total of 485 twin pregnancies received laser therapy for TTTS. RVOTO was diagnosed in 3% (11/368) of liveborn TTTS recipients, of whom two showed mild Ebstein's anomaly. Before laser therapy, pericardial effusion was seen in 45% (5/11) of RVOTO cases ($P < 0.01$) and abnormal A-wave in the ductus venosus (DV) in 73% (8/11) ($P = 0.03$), significantly higher proportions than in controls. Mean gestational age at laser therapy was 17 + 3 weeks in RVOTO cases compared with 20 + 3 weeks in controls ($P = 0.03$). A prediction model for RVOTO was constructed incorporating these three significant variables. One TTTS donor had RVOTO after transient hydrops following laser therapy. Three larger twins in sIUGR pregnancies developed RVOTO, the onset of which was detectable early in the second trimester.

Conclusion

RVOTO occurs in TTTS recipient twins but can also develop in TTTS donors and larger twins of pregnancies complicated by sIUGR. Abnormal flow in the DV, pericardial effusion and early gestational age at onset of TTTS are predictors of RVOTO in TTTS recipients, which suggests increased vulnerability to hemodynamic imbalances in the fetal heart in early pregnancy. These findings could guide diagnostic follow-up protocols after TTTS treatment.

Introduction

Severe right ventricular outflow tract obstruction (RVOTO) is a heart anomaly that requires surgery or catheter intervention in the newborn period or early infancy.[1,2] Fetal RVOTO is being diagnosed increasingly in complicated monochorionic twin pregnancies, and usually starts with right ventricular hypertrophy leading to valvular, subvalvular or supravalvular outflow tract obstruction, including pulmonary valve stenosis and pulmonary atresia. Severe postnatal RVOTO is reported mainly in recipients of twin-to-twin transfusion syndrome (TTTS),[3,4] although it has been reported sporadically in TTTS donors and in the larger twin of a monochorionic pair with selective intrauterine growth restriction (sIUGR).[2,5-7]

Right ventricular hypertrophy and RVOTO may be present in recipients at the time of diagnosis of TTTS or can develop later in pregnancy. RVOTO can be transient, progressive or persistent, even beyond the neonatal period.[8] The reported incidence of severe RVOTO in liveborn recipients varies between 2% and 8%, but the true incidence is difficult to estimate.[2,4,5,9] Laser intervention at an early stage of TTTS is associated with a significant reduction in the incidence of RVOTO.[4,10,11] Risk factors for the development of RVOTO are unknown.

The objective of this study was to evaluate pregnancy characteristics of neonates from a complicated monochorionic twin pregnancy with clinical signs of RVOTO. We aimed to determine the incidence of RVOTO in TTTS cases and construct a prediction model for its development. Identification of these risk factors may guide further follow-up examinations in affected pregnancies and may indicate the appropriate diagnostic protocol after birth.

Methods

The Leiden University Medical Center is the national referral center for fetal therapy in The Netherlands. Twin pregnancies complicated by TTTS are referred to our center for fetoscopic laser coagulation of placental anastomoses. Monochorionic twin pregnancies with sIUGR or with discordance for multiple congenital abnormalities (MCA) are referred if selective feticide of the affected twin is considered by the parents. All data on sonographic findings, operative characteristics and neonatal outcomes in complicated monochorionic twin pregnancies are entered prospectively in a database. All monochorionic twin pregnancies referred to or treated in our center between January 2004 and July 2015 were reviewed for a postpartum diagnosis of RVOTO.

The diagnosis of RVOTO was made by postnatal echocardiography. The scan was indicated by clinical signs of RVOTO or because prenatal scans showed cardiac abnormalities. All twins were seen at our follow-up clinic at the age of 2 years, at which time hospital admissions and interventions were noted. In this cohort of monochorionic twins there is a 3% lost-to-follow-up rate at this visit.

RVOTO was defined as subvalvular, valvular or supravalvular pulmonary stenosis (PS) or pulmonary atresia on postnatal echocardiography, with or without the presence of tricuspid regurgitation. PS was defined as an elevated peak velocity over the pulmonary valve, classified as mild (2–3 m/s), moderate (3–4 m/s) or severe (> 4 m/s).[12]

TTTS was diagnosed using the Eurofoetus criteria,[13] i.e. polyuric polyhydramnios in the recipient twin with a deepest vertical pocket (DVP) of 8 cm before 20 weeks' gestation and 10 cm after 20 weeks, and oliguric oligohydramnios in the donor twin with a DVP of < 2 cm. The Quintero staging system was used to classify the severity of TTTS.[14] Pericardial effusion was defined as the accumulation of pericardial fluid of > 2 mm at the level of the atrioventricular valves.[15] Hydrops was defined as the accumulation of fluid in two or more compartments (skin, ascites, pleural effusion or pericardial effusion) of the fetal body. All TTTS cases were treated by laser coagulopathy.

Laser surgery was offered to cases with Quintero Stage II or higher, or Stage I with symptomatic polyhydramnios. A preoperative ultrasound examination was performed in all cases to diagnose and stage TTTS. The findings of this examination were used to identify parameters as predictors for postnatal RVOTO in TTTS recipients. All

fetuses underwent a full echocardiographic examination, but extended assessment of fetal cardiac function was not routinely performed in the earlier years of this study. The size of the aorta and pulmonary artery were measured if they appeared to be abnormal. Signs of fetal cardiac adaptation or compromise were evaluated. Intertwin discordance in estimated fetal weight (EFW) was calculated as ((recipient EFW – donor EFW)/ recipient EFW) × 100. Abnormal flow in the ductus venosus (DV) was defined as an absent or reversed A-wave. Cardiomegaly was defined as a cardiothoracic ratio greater than the 95th percentile for gestational age, measured in a transverse plane of the fetal thorax at the level of the four-chamber view of the fetal heart and in diastole.[16,17] Tricuspid regurgitation was defined as visualization of a clear jet across the tricuspid valve in systole, using color Doppler ultrasound in an apical four-chamber view. Laser coagulation of the vascular anastomoses was performed as described previously.[18] The first ultrasound examination after laser coagulation was performed from 24 h to approximately 1 week after the procedure. Further follow-up scans were scheduled at least biweekly for all patients until birth.

sIUGR was defined as an EFW < 10th percentile in one twin and an intertwin difference of > 25% in the absence of TTTS. sIUGR was classified into three types according to Gratacós *et al*.[19] In Type I, the smaller twin has positive end-diastolic flow in the umbilical artery, in Type II it has persistently absent or reversed end-diastolic flow and in Type III it has intermittently absent or reversed end-diastolic flow.

Statistical analysis

Statistical analysis was performed with IBM SPSS 20.0 statistical package (IBM Corp., Chicago, IL, USA). TTTS recipients with clinical symptoms of RVOTO were compared with recipients without RVOTO, which were used as controls. A multivariable logistic regression model was constructed using stepwise backward elimination to identify independent predictors for the development of RVOTO in TTTS recipients to include in a final prediction model. All variables with $P < 0.05$ were considered risk factors and odds ratios (ORs) including 95% CIs were computed. The area under the receiver–operating characteristics (ROC) curve was calculated to assess the ability of the model to discriminate between fetuses that will develop RVOTO and those that will have normal cardiac development.

Results

Fifteen neonates from monochorionic twin pregnancies diagnosed postnatally with RVOTO were identified in our database. Two cases were cotwins in a single pregnancy, thus 14 pregnancies were analyzed. Ultrasound findings at the time of laser therapy and postnatal diagnosis and interventions are summarized in Tables 1 and 2, respectively.

TTTS recipients

During the study period, 485 twin pregnancies received laser therapy for TTTS. RVOTO was diagnosed in 11 (3%) of the 368 liveborn recipients available for follow up. Pregnancy and ultrasound characteristics of this group at the time of laser therapy are shown in Table 3 and compared with all liveborn recipients without RVOTO (controls). The mean gestational age at diagnosis and treatment of TTTS in RVOTO cases was 17 + 3 weeks, significantly lower than in the control group (20 + 3 weeks; $P = 0.004$). Abnormal flow in the DV ($P < 0.01$), pericardial effusion ($P < 0.01$) and ascites ($P = 0.03$) at the time of diagnosis of TTTS occurred significantly more frequently in the RVOTO cases than in controls.

Variables found to be independent predictors for RVOTO were gestational age at diagnosis (OR, 0.96 (95% CI, 0.92–0.996)), abnormal flow in the DV (OR, 5.13 (95% CI, 1.15–22.96)) and pericardial effusion (OR, 26.1 (95% CI, 4.9–139)). A prediction model for the risk of RVOTO at birth in TTTS recipients was constructed, incorporating gestational age, presence of abnormal flow in the DV and presence of pericardial effusion (Table 4). In cases with TTTS diagnosed at 15 weeks' gestation, the risk for RVOTO was > 80% when both pericardial effusion and abnormal DV flow were present. The risk decreased to 11% if these signs were present but TTTS was diagnosed after 26 weeks. With normal flow in the DV and an absence of pericardial effusion, the risk for RVOTO was 4% in cases with TTTS diagnosed at 15 weeks and 0% in cases diagnosed at or after 22 weeks. The area under the ROC curve of the prediction model was 0.92 (95% CI, 0.88–0.98) (Figure 1).

Table 1. Ultrasound findings at time of fetal intervention in 14 complicated monochorionic twin pregnancies with a postnatal diagnosis of right ventricular outflow tract obstruction (RVOTO)

Case	Diagnosis	Twin	Intervention	GA at intervention (weeks+days)	Intertwin EFW discordance (%)	DV in A-wave	Cardiomegaly	Tricuspid insufficiency	Pericardial effusion
1	TTTS Q II	recipient	FLC	15+6	22.1	positive	no	no	no
2-a	TTTS Q III	donor	FLC	19+6	30.5	-	-	-	-
2-b	TTTS QIII	recipient	FLC	19+6	30.5	reversed	yes	no	yes
3	TTTS QIII	recipient	FLC	16+0	37.7	absent	no	no	no
4	TTTS Q III	recipient	FLC	20+0	33.4	reversed	no	no	yes
5	TTTS QIII	recipient	FLC	17+2	26.3	positive	no	no	no
6	TTTS Q III	recipient	FLC	14+3	4.0	positive	no	no	no
7	TTTS Q IV	recipient	FLC	22+3	6.1	reversed	no	no	yes
8	TTTS Q III	recipient	FLC	19+5	29.3	reversed	yes	no	no
9	TTTS Q III	recipient	FLC	14+4	23.5	reversed	yes	-	yes
10	TTTS Q III	recipient	FLC	16+1	32.1	reversed	no	yes	no
11	TTTS Q IV	recipient	FLC	15+5	5.8	reversed	yes	yes	yes
12	sIUGR	larger	none	-	-	-	-	-	-
13	sIUGR*	larger	UCC	18+5	45.6	positive	yes	-	yes
14	sIUGR†	larger	UCC	18+0	36.8	positive	no	-	yes

**sIUGR twin with abnormal cerebellum and hydrocephalus*
†sIUGR twin with omphalocele and hydrocephalus
DV, ductus venosus; EFW, estimated fetal weight; FLC, fetoscopic laser coagulation of anastomoses; GA, gestational age; NK, not known (missing data); QS, Quintero Stage; sIUGR, selective intrauterine growth restriction; TTTS, twin-to-twin transfusion syndrome; UCC, selective feticide by umbilical cord coagulation

Table 2. Characteristics of monochorionic twin pregnancies with neonatal diagnosis of RVOTO

Case	GA at birth (weeks)	Birthweight (grams)	Prenatal diagnosis of RVOTO	Postnatal diagnosis of RVOTO	Intervention	Age (wk) at intervention	Follow up
1	29+3	1135	yes	Severe valvular PS	Balloon valvuloplasty	4	A&W
2a	26+3	720	yes	Valvular PS	Balloon valvuloplasty	42	A&W
2b	26+3	865	yes	Severe valvular PS, hypoplastic RV	None[a]		NND at 1 wk
3	27+0	955	no	Severe valvular PS	Balloon valvuloplasty	18	A&W
4	38+3	3420	yes	Severe valvular PS hypoplastic RV	Balloon valvuloplasty second BV[b]	<1 10	Tay Sachs disease
5	31+0	1400	yes	Severe valvular PS, small RV	Rashkind Balloon valvuloplasty	4	A&W
6	26+5	960	yes	Mild PS	none		A&W
7	36+5	2250	yes	Mild PS	none		A&W
8	32+2	1845	yes	Severe PS, mild Ebstein anomaly	Balloon valvuloplasty	19	A&W
9	39+0	3260	yes	Severe PS, mild Ebstein anomaly	Balloon valvuloplasty	<1	A&W
10	29+0	1205	yes	Pulmonary atresia	Balloon valvuloplasty	3	A&W
11	34+3	2160	yes	Severe PS, massive TI	None[c]		NND at 5
12	34+4	2630	yes	Severe PS , RV hypertrophy	Balloon valvuloplasty	<1	A&W
13	37+3	2565	yes	Severe PS, RV hypertrophy	Balloon valvuloplasty BT shunt 1.5 ventricle repair[d]	<1 6 2,5yr	A&W
14	37+6	3155	yes	Severe valvular PS dysplastic bicuspid valve	Balloon valvuloplasty	10	A&W

Pulmonary stenosis (PS): mild, peak gradient 2–3 m/s; moderate, 3–4 m/s; severe, > 4 m/s)
aNeonatal death (NND) due to prematurity, cardiac failure with cerebral abnormalities and infant respiratory distress syndrome
bSuccessful balloon valvuloplasty on day 1 with redilatation after 10 weeks because of increasing PS
cNND due to cardiac failure combined with Escherichia coli sepsis.d Glenn procedure (bidirectional cavopulmonary shunt)
A&W, alive and well; BT shunt, Blalock–Taussig shunt; GA, gestational age; RV, right ventricle; TI, tricuspid insufficiency

Table 3. Characteristics at time of laser therapy for twin-to-twin transfusion syndrome (TTTS) in recipients with postnatal diagnosis of right ventricular outflow tract obstruction (RVOTO) and recipients without RVOTO

Characteristic	RVOTO (n = 11)	RVOTO absent (n = 357)	P-value	Multivariate analysis OR (95% CI)	P-value
GA at laser therapy (weeks)	(17 + 3) ± (2 + 4)	(20 + 3) ± (3 + 2)	0.004	0.96 (0.92–0.996)	0.03
Intertwin EFW discordance (%)	24.3 ± 11.3	19.2 ± 12.6	0.20		
TTTS Quintero Stage > III	9 (81.8)	153 (42.9)	0.07		
Abnormal DV flow	8 (72.7)	66 (19.7)‡	< 0.01	5.13 (1.15–22.96)	0.03
Ascites	2 (18.2)	7 (2.0)	0.03		0.33
Skin edema	1 (9.1)	3 (0.8)	0.11		
Pleural effusion	0 (0)	2 (0.6)	0.94		
Cardiac compromise					
Cardiomegaly	4 (36.4)	102 (29.7)‡	0.22		
Tricuspid insufficiency	2 (18.2)	42 (14.2)‡	0.27		
Pericardial effusion*	5 (45.5)	8 (2.2)	< 0.01	26.1 (4.9–139)	< 0.01

Data are given as n (%) or mean ± SD.
**Isolated pericardial effusion found in 3/5 RVOTO cases and 4/8 controls.*
†Missing data: abnormal DV flow (6%), cardiomegaly (3.8%), tricuspid insufficiency (17%).
DV, ductus venosus; EFW, estimated fetal weight; GA, gestational age; OR, odds

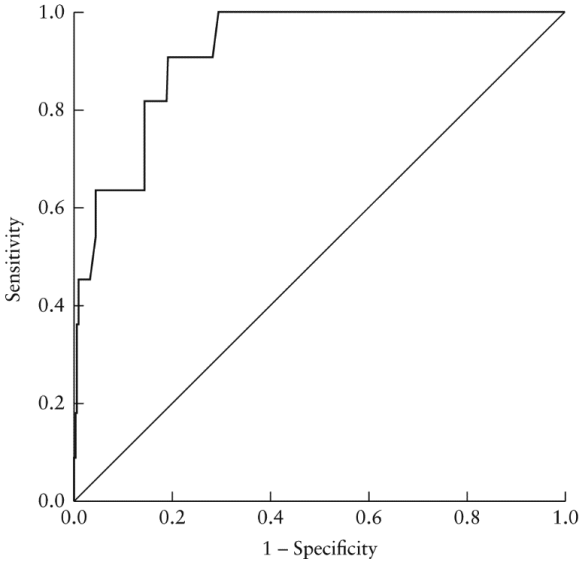

◄**Figure 1.** Receiver–operating characteristics (ROC) curve for prediction of right ventricular outflow tract obstruction at birth in recipient twin of twin-to-twin transfusion syndrome (TTTS) using model incorporating gestational age at diagnosis of TTTS and presence of pericardial effusion and abnormal flow in the ductus venosus. Area under ROC curve, 0.92.

Table 4 shows a risk estimation for RVOTO for each week of gestation at which TTTS is diagnosed. This risk is stratified according to the presence or absence of abnormal flow in ductus venosus or the presence of pericardial effusion. Example: if TTTS is diagnosed at 15 weeks with normal DV and absent PE, risk for neonatal PS is 4%.

Table 4. Prediction model: predicted risk for RVOTO at birth for recipients

GA diagnosis of TTTS (weeks)	PE absent		PE present	
	Normal DV	Abnormal DV	Normal DV	Abnormal DV
15	4	20	43	82
16	3	16	35	77
17	2	12	28	70
18	2	9	22	63
19	1	6	17	55
20	1	5	13	47
21	1	3	10	39
22	0	3	7	31
23	0	2	5	25
24	0	1	4	19
25	0	1	3	14
26	0	1	2	11

Data are given as percentage risk

TTTS donors and sIUGR

Four fetuses diagnosed with RVOTO were not TTTS recipients; one was the donor twin in a TTTS pregnancy and three were the larger twins in sIUGR pregnancies. Because pregnancies with sIUGR are referred to our center only if selective feticide is considered, the incidence of RVOTO in this group could not be deduced. Because of the limited sample size, statistical analysis of risk factors was not performed.

The TTTS donor with RVOTO and the recipient cotwin were concordant for RVOTO. At the time of diagnosis of TTTS (19 + 6 weeks), the recipient twin showed signs of RVOTO, while signs of cardiac compromise were absent in the donor twin. After the laser procedure, the donor twin developed transient hydrops with massive skin edema, pleural effusion and mild ascites. The hydrops resolved, but the donor twin showed progressive RVOTO up to birth.

In the sIUGR pregnancies with RVOTO in the larger twin, two were complicated by MCA in the smaller twin, and umbilical cord coagulation was performed in both cases

(Table 1). Both larger twins showed pericardial effusion at the time of the intervention; one case had elevated peak systolic velocity in the pulmonary artery and in the other case cardiomegaly was present. Both fetuses developed progressive RVOTO in the subsequent weeks following the intervention. In the third sIUGR case, no abnormality was seen in the smaller twin and umbilical cord coagulation was not performed. Intermittent absent/reversed end-diastolic flow in the umbilical artery was present in the smaller twin, staged as sIUGR Type III according to Gratacós *et al*.[19] Pericardial effusion was seen from 17 weeks onwards in the larger twin, which developed severe pulmonary stenosis. This case has been reported previously by our group.[20]

Neonatal outcome

Details of postnatal diagnosis and treatment of all 15 cases with RVOTO are summarized in Table 2. Two (13%) of the neonates died within 1 week owing to prematurity and sepsis combined with cardiac failure before cardiac intervention could be performed. Eleven (73%) cases received surgical or catheter-based intervention within the first postnatal months. In two cases, Ebstein's anomaly was diagnosed, with true inferior displacement of the valve. In both cases the anomaly was mild, with normal right ventricular function. In one (7%) case, pulmonary stenosis was not detected prenatally (Case 3). This case was referred early in the study period and only absent A-wave in the DV was present at the time of laser therapy. At follow-up, cardiomegaly was noted, but detailed echocardiography was hampered by blurred imaging because of maternal obesity and preterm rupture of membranes.

Discussion

This study shows that an early gestational age at diagnosis of TTTS, abnormal flow in the DV and pericardial effusion are predictors of the development of RVOTO. Our prediction model shows that the risk of development of RVOTO is highest in the presence of abnormal DV flow and pericardial effusion when TTTS is diagnosed early in the second trimester; the risk decreases with increasing gestational age at the diagnosis of TTTS.

The association of RVOTO with an early gestational age at TTTS diagnosis was suggested previously in a case report[20] and is confirmed in this regional cohort of consecutive cases. The cascade of cardiac adaptations in TTTS, in which volume loading and ventricular hypertrophy with tricuspid regurgitation occur in the recipient, is well

known.[3,21,22] The hypertrophy leads to a stiff, non-compliant ventricle with impaired diastolic function. The cardiovascular score of TTTS described by Rychik *et al*.[22] incorporates cardiovascular parameters as a reflection of the severity of the disease. In this study, decreased size of the pulmonary artery was found in TTTS recipients. This finding was attributed to diminished forward flow across the valve. Intracardiac circulation is necessary for cardiac morphogenesis and vasculogenesis.[23,24] In the absence of sufficient forward flow due to abnormal right ventricular function in TTTS, the pulmonary valve might fail to grow. If the TTTS remains untreated, this process could lead to the development of PS or pulmonary atresia.

Early in the second trimester semilunar valve maturation is not complete,[25] and we hypothesize that, in this period, the fetal heart is therefore more susceptible to hemodynamic imbalances leading to RVOTO. This explains our finding that postnatal, and thus persistent, RVOTO is associated with an early gestational age at diagnosis of TTTS. It is plausible that temporary RVOTO, more often seen later in pregnancy, may represent obstruction due to myocardial hypertrophy in TTTS that disappears with normalization of the myocardium after laser treatment, without anatomical stenosis of the pulmonary valve.

The finding that abnormal tricuspid valve development can occur in TTTS is new. A recent study in zebrafish showed that prolonged disturbance in intracardiac flow during the period of embryogenesis resulted in abnormal development of the atrioventricular valve.[26] Abnormal intracardiac flow, as seen in TTTS, might result in malformation of the tricuspid valve and right ventricle, as seen in Ebstein's anomaly.[22,27]

The other two parameters in the prediction model for RVOTO are a reflection of the severity of cardiac compromise in the late stages of TTTS. These parameters confirm the presence of altered hemodynamics, as in the above-described cascade of events. Laser therapy often improves cardiac function through restoration of the hemodynamic imbalance,[10,11,17,20,28] and the majority of fetuses will recover without developing RVOTO.[11,29] If hydrops is present, up to one third of fetuses develop cardiac abnormalities such as RVOTO.[30] Timely diagnosis and laser treatment might contribute to a better cardiac outcome in TTTS.

Although our prediction model needs further validation, it could be an aid to antenatal and postnatal follow-up. When pericardial effusion or abnormal DV flow is present, especially when TTTS occurs early in pregnancy, we recommend echocardiographic

follow-up in a specialized center, and additional postnatal follow-up is necessary to detect cases with mild RVOTO. In our opinion, it is too early to recommend refraining from echocardiographic follow-up examinations in low-risk pregnancies. The possibility of delivering in centers with pediatric cardiology services in TTTS cases without prenatal signs of RVOTO depends on healthcare systems and travel distances, and individual cases should be treated according to local circumstances.

For the larger twin in sIUGR pregnancies, risk factors for RVOTO could not be evaluated because our cohort was influenced by referral bias. However, in all three pregnancies with RVOTO and one previously described case,[6,7] sIUGR was already evident early in the second trimester, which is in accordance with our findings in TTTS cases. All cases had signs of cardiac compromise in the second trimester, thus suggesting a developmental pathway similar to that seen in TTTS cases. The pattern of vascular anastomoses in sIUGR is usually different from that in TTTS. In up to 98% of sIUGR cases, a large arterioarterial anastomosis is present.[31] These anastomoses are thought to cause an unstable hemodynamic balance, especially if flow recordings show sIUGR Stage III according to Gratacós *et al*.[19,32] We speculate that large arterioarterial anastomoses in the early stages of pregnancy also cause disturbances in intracardiac flow. The hypertrophic cardiomyopathy-like changes that have been found in cases with large arterioarterial anastomoses support the theory of altered intracardiac hemodynamics.[33]

Finally, this large, consecutive cohort of TTTS cases has established an incidence of RVOTO of 3% in recipient twins.[4,9] Higher incidences have been reported previously, but may be explained by a limited number of cases[5,10] or by the studies being performed prior to routine laser therapy and therefore representing untreated TTTS.[21]

The strength of this study is the large consecutive cohort of TTTS cases, which allowed us to analyse the incidence and risk factors for RVOTO and enabled us to develop a prediction model. Prospective validation should be performed to assess the value of the prediction model, especially because the sample size was limited. Another limitation is the retrospective approach of prospectively collected data. We used items of the TTTS Quintero staging system to identify clinically relevant predictors of RVOTO. Extended prenatal and postnatal echocardiographic follow-up was not performed systematically in all survivors in the early years of the study period, and it is therefore possible that cases with mild RVOTO were missed.

In the prediction model, one recipient was concordant with the donor for pulmonary stenosis. Although a genetic component could be suggested in this case, we included this recipient in the statistical analysis. We believe that hemodynamic disturbances were a probable cause of RVOTO in both fetuses, as RVOTO was already present in the recipient at the time of diagnosis of TTTS and the donor developed RVOTO after a transient period of hydrops directly following laser therapy.

Conclusion

RVOTO in monochorionic twins occurs not only in recipients but also in donors and larger twins of pregnancies with sIUGR. In cases with TTTS, the fetal heart is more vulnerable to the development of RVOTO in early pregnancy. When abnormal flow in the DV and pericardial effusion are present, accurate prenatal and postnatal sonographic follow-up is mandatory.

References

1. Lopriore E, Bökenkamp R, Rijlaarsdam M, Sueters M, Vandenbussche FP, Walther FJ. Congenital heart disease in twin-to-twin transfusion syndrome treated with fetoscopic laser surgery. *Congenit Heart Dis* 2007; 2: 38–43.
2. Pruetz JD, Sklansky M, Detterich J, Korst LM, Llanes A, Chmait RH. Twin–twin transfusion syndrome treated with laser surgery: postnatal prevalence of congenital heart disease in surviving recipients and donors. *Prenatal Diagn* 2011; 31: 973–977.
3. Marton T, Hajdu J, Papp C, Patkos P, Hruby E, Papp Z. Pulmonary stenosis and reactive right ventricular hypertrophy in the recipient fetus as a consequence of twin-to-twin transfusion. *Prenat Diagn* 2001; 21: 452–456.
4. Michelfelder E, Tan X, Cnota J, Divanovic A, Statile C, Lim FY, Crombleholme T. Prevalence, spectrum, and outcome of right ventricular outflow tract abnormalities in twin–twin transfusion syndrome: a large, single-center experience. *Congenit Heart Dis* 2015; 10: 209–218.
5. Herberg U, Bolay J, Graeve P, Hecher K, Bartmann P, Breuer J. Intertwin cardiac status at 10-year follow-up after intrauterine laser coagulation therapy of severe twin–twin transfusion syndrome: comparison of donor, recipient and normal values. *Arch Dis Child Fetal Neonatal Ed* 2014; 99: 380–385.
6. Eckmann-Scholz C, Diehl W, Kanzow M, Hecher K. Monochorionic twin pregnancy complicated by right ventricular outflow tract obstruction (RVOTO) of one fetus without proof of a twin–twin transfusion syndrome. *Ultraschall Med* 2014; 35: 373–374.
7. Kondo Y, Hidaka N, Yumoto Y, Fukushima K, Tsukimori K, Wake N. Cardiac hypertrophy of one fetus and selective growth restriction of the other fetus in a monochorionic twin pregnancy. *J Obstet Gynaecol Res* 2010; 36: 401–404.
8. Simpson LL, Marx GR, Elkadry EA, D'Alton ME. Cardiac dysfunction in twin–twin transfusion syndrome: a prospective, longitudinal study. *Obstet Gynecol* 1998; 92: 557–562.
9. Springer S, Mlczoch E, Krampl-Bettelheim E, Mailáth-Pokorny M, Ulm B, Worda C, Worda K. Congenital heart disease in monochorionic twins with and without twin-to-twin transfusion syndrome. *Prenat Diagn* 2014; 34: 994–999.
10. Barrea C, Hornberger LK, Alkazaleh F, McCrindle BW, Roberts A, Berezovska O, Windrim R, Seaward PG, Smallhorn JF, Ryan G. Impact of selective laser ablation of placental anastomoses on the cardiovascular pathology of the recipient twin in severe twin–twin transfusion syndrome. *Am J Obstet Gynecol* 2006; 195: 1388–1395.
11. Herberg U, Gross W, Bartmann P, Banek CS, Hecher K, Breuer J. Long term cardiac follow up of severe twin to twin transfusion syndrome after intrauterine laser coagulation. *Heart* 2006; 92: 95–100.
12. Baumgartner H, Hung J, Bermejo J, Chambers JB, Evangelista A, Griffin BP, Iung B, Otto CM, Pellikka PA, Quiñones M; EAE/ASE. Echocardiographic assessment of valve stenosis: EAE/ASE recommendations for clinical practice. *Eur J Echocardiogr* 2009; 10: 1–25.

13. Senat MV, Deprest J, Boulvain M, Paupe A, Winer N, Ville Y. Endoscopic laser surgery versus serial amnioreduction for severe twin-to-twin transfusion syndrome. *N Engl J Med* 2004; 351: 136–144.
14. Quintero RA, Morales WJ, Allen MH, Bornick PW, Johnson PK, Kruger M. Staging of twin–twin transfusion syndrome. *J Perinatol* 1999; 19: 550–555.
15. Dizon-Townson DS, Dildy GA, Clark SL. A prospective evaluation of fetal pericardial fluid in 506 second-trimester low-risk pregnancies. *Obstet Gynecol* 1997; 90: 958–961.
16. Paladini D, Chita SK, Allan LD. Prenatal measurement of cardiothoracic ratio in evaluation of heart disease. *Arch Dis Child* 1990; 65: 20–23.
17. Sueters M, Middeldorp JM, Vandenbussche FP, Teunissen KA, Lopriore E, Kanhai HH, Le Cessie S, Oepkes D. The effect of fetoscopic laser therapy on fetal cardiac size in twin–twin transfusion syndrome. *Ultrasound Obstet Gynecol* 2008; 31: 158–163.
18. Slaghekke F, Lopriore E, Lewi L, Middeldorp JM, van Zwet EW, Weingertner AS, Klumper FJ, Dekoninck P, Devlieger R, Kilby MD, Rustico MA, Deprest J, Favre R, Oepkes D. Fetoscopic laser coagulation of the vascular equator versus selective coagulation for twin-to-twin transfusion syndrome: an open-label randomised controlled trial. *Lancet* 2014; 383: 2144–2151.
19. Gratacós E, Lewi L, Muñoz B, Acosta-Rojas R, Hernandez-Andrade E, Martinez JM, Carreras E, Deprest J. A classification system for selective intrauterine growth restriction in monochorionic pregnancies according to umbilical artery Doppler flow in the smaller twin. *Ultrasound Obstet Gynecol* 2007; 30: 28–34.
20. de Haseth SB, Haak MC, Roest AA, Rijlaarsdam ME, Oepkes D, Lopriore E. Right ventricular outflow tract obstruction in monochorionic twins with selective intrauterine growth restriction. *Case Rep Pediatr* 2012; 2012: 426825.
21. Lougheed J, Sinclair BG, Fung Kee Fung K, Bigras JL, Ryan G, Smallhorn JF, Hornberger LK. Acquired right ventricular outflow tract obstruction in the recipient twin in twin–twin transfusion syndrome. *J Am Coll Cardiol*2001; 38: 1533–1538.
22. Rychik J, Tian Z, Bebbington M, Xu F, McCann M, Mann S, Wilson RD, Johnson MP. The twin–twin transfusion syndrome: spectrum of cardiovascular abnormality and development of a cardiovascular score to assess severity of disease. *Am J Obstet Gynecol* 2007; 197: 392–398.
23. Berdougo E, Coleman H, Lee DH, Stainier DY, Yelon D. Mutation of weak atrium/atrial myosin heavy chain disrupts atrial function and influences ventricular morphogenesis in ebrafish. *Development* 2003; 130: 6121–6129.
24. Huang C, Sheikh F, Hollander M, Cai C, Becker D, Chu PH, Evans S, Chen J. Embryonic atrial function is essential for mouse embryo-genesis, cardiac morphogenesis and angiog-enesis. *Development* 2003; 130: 6111–6119.
25. Monaghan MG, Linneweh M, Liebscher S, Van Handel B, Layland SL, Schenke-Layland K. Endocardial-to-mesenchymal transformation and mesenchymal cell colonization at the onset of human cardiac valve develop-ment. *Development* 2016; 143: 473–482.

26. Kalogirou S, Malissovas N, Moro E, Argenton F, Stainier DY, Beis D. Intracardiac flow dynamics regulate atrioventricular valve morphogenesis. *Cardiovasc Res* 2014; 104: 49–60.
27. Raboisson MJ, Fouron JC, Lamoureux J, Leduc L, Grignon A, Proulx F, Gamache S. Early intertwin differences in myocardial performance during the twin-to-twin transfusion syndrome. *Circulation* 2004; 110: 3043–3048.
28. Moon-Grady AJ, Rand L, Lemley B, Gosnell K, Hornberger LK, Lee H. Effect of selective fetoscopic laser photocoagulation therapy for twin–twin transfusion syndrome on pulmonary valve pathology in recipient twins. *Ultrasound Obstet Gynecol* 2011; 37: 27–33.
29. Khalek N, Villa A, Johnson M, Moldenhauer J, Martinez-Poyer J, Rychik J. Echocardiography follow up performed at two years in monochorionic pairs affected by twin twin transfusion syndrome who underwent selective laser photocoagulation. *Am J Obstet Gynecol* 2014; S86.
30. Gray PH, Ward C, Chan FY. Cardiac outcomes of hydrops as a result of twin–twin transfusion syndrome treated with laser surgery. *J Paediatr Child Health* 2009; 45: 48–52.
31. Zhao DP, de Villiers SF, Slaghekke F, Walther FJ, Middeldrop JM, Oepkes D, Lopriore E. Prevalence, size, number and localization of vascular anastomoses in monochorionic placentas. *Placenta* 2013; 34: 589–593.
32. Wee LY, Taylor MJ, Vanderheyden T, Talbert D, Fisk NM. Transmitted arterio-arterial anastomosis waveforms causing cyclically intermittent absent/reversed end-diastolic umbilical artery flow in monochorionic twins. *Placenta* 2003; 24: 772–778.
33. Muñoz-Abellana B, Hernandez-Andrade E, Figueroa-Diesel H, Ferrer Q, Acosta-Rojas R, Cabero L, Gratacos E. Hypertrophic cardiomyopathy-like changes in monochorionic twin pregnancies with selective intrauterine growth restriction and intermittent absent/reversed end-diastolic flow in the umbilical artery. *Ultrasound Obstet Gynecol* 2007; 30: 977–98



S.J. Eschbach
A.D.J. ten Harkel
J.M. Middeldorp
F.J. Klumper
D. Oepkes
E. Lopriore
M.C. Haak

Published in: Prenatal Diagnosis, 2018; 49(6): 737-743

CHAPTER VI

Acquired right ventricular outflow tract obstruction in twin-to-twin transfusion syndrome; a prospective longitudinal study



Abstract

Objective

The pathophysiology of right ventricular outflow tract obstruction (RVOTO) in twin-to-twin transfusion syndrome (TTTS) recipients is incompletely understood. We aimed to investigate the development and spectrum of RVOTO in TTTS recipients.

Methods

A prospective longitudinal cohort study was conducted between 2015 and 2017. Echocardiographic assessment was performed in recipients from TTTS diagnosis until the neonatal period.

Results

Prenatal RVOTO, defined as abnormal flow velocity waveforms across the pulmonary valve (PV), was diagnosed in 12.9% (16/124) of recipients at TTTS diagnosis. Postnatal RVOTO was found in 6.7% (7/105) of surviving recipients. All recipients with severe postnatal RVOTO showed prenatal RVOTO at TTTS diagnosis. In 5.6% (6/108) of cases, prenatal RVOTO appeared only after laser therapy, and in 1.9% (2/108), this progressed to mild postnatal pulmonary stenosis. Elevated peak systolic PV velocities were more frequently associated with postnatal RVOTO compared with prenatal finding of functional pulmonary atresia. Postnatal RVOTO was associated with early manifestation of TTTS but was equally found in all Quintero stages.

Conclusion

In the spectrum of postnatal RVOTO, severe cases show prenatal RVOTO at TTTS diagnosis. However, RVOTO can develop after laser or even in the neonatal period and in all Quintero stages. A potential risk factor for postnatal RVOTO is early TTTS manifestation.

Introduction

Right ventricular outflow tract obstruction (RVOTO) is a relatively common finding in recipients in twin-to-twin transfusion syndrome (TTTS). In untreated TTTS, approximately 10% to 12% of recipients will develop congenital heart disease, including RVOTO.[1, 2] Fetoscopic laser therapy is known to improve cardiac function, and the reported incidence of postnatal RVOTO in surviving recipients after laser therapy is 2% to 3% in larger series.[3-7]

The pathophysiology of RVOTO in TTTS is not fully understood, and risk factors for progression to postnatal RVOTO are still difficult to determine. Most studies focus on preintervention assessment of RVOTO, because systematic longitudinal echocardiographic follow-up of all recipients after laser therapy is difficult to establish in fetal therapy centers.[4, 5, 8-11] This impedes knowledge on the complete spectrum of RVOTO.[12] Furthermore, the true incidence of RVOTO might be underestimated, because of undetected late-onset or mild cases.

The aim of this study was to investigate the incidence and the spectrum of RVOTO in all recipients from the onset of TTTS. We followed all cases throughout pregnancy until delivery and performed a systematic assessment in the neonatal period, to contribute to the understanding of pathophysiology of RVOTO development.

Methods

A prospective cohort study was performed between January 2015 and March 2017. All consecutive monochorionic pregnancies referred to our center for TTTS in this period were included in this study. The Leiden University Medical Center is the national referral center for fetal therapy in the Netherlands. A comprehensive preoperative ultrasound examination was performed in all cases to stage TTTS. The severity of TTTS was classified according to the Quintero staging system.[13] Laser therapy was performed in stage 2 or higher or in stage 1 if severe maternal discomfort or cervical shortening was present. Reasons not to perform laser therapy were advanced cervical dilatation or a gestational age greater than 28 weeks.

Following laser therapy, patients remained in hospital for 12 to 24 hours. An ultrasound examination was performed within 24 hours and approximately 1 to 2 weeks after laser therapy. After that, at least monthly follow-up scans were performed until birth

at our department. In case of the absence of other complications, induction of labor was initiated at 36 weeks of gestation.

Extended fetal echocardiography was performed in all examinations, using an Aplio 500 (Toshiba Medical System Corporation, Otawara-Shi, Tochigi, Japan). We assessed the right ventricular outflow tract with a recording of the flow velocity waveform across the pulmonary valve (FVW-PV). The sample volume was placed distal to the valve, with an insonation angle of less than 20°. Measurements were made in absence of fetal breathing movements. Normal FVW-PV was defined as forward flow across the valve with a peak systolic velocity less than 1 m/s. Prenatal RVOTO was defined as abnormal FVW-PV, and three subgroups were identified as described before.[4] Functional pulmonary atresia was defined as the absence of forward flow across the pulmonary valve with an exclusive reverse direction of flow in the ductus arteriosus. Pulmonary stenosis was defined as turbulent flow with a peak systolic velocity of greater than 1 m/s, whether or not across a thickened or echogenic pulmonary valve and whether or not combined with insufficiency across the pulmonary valve. Isolated pulmonary insufficiency was defined as pulmonary insufficiency with reversed flow from main pulmonary artery entering the right ventricle, with either forward or bidirectional flow in the ductus arteriosus, in the absence of other signs of RVOTO.[4] The flow across the atrioventricular valves was assessed with color Doppler and categorized according to duration of the jet during the cardiac cycle.[14] Atrioventricular valvular insufficiency was categorized as mild if the jet appeared only early systolic, moderate if it appeared early to midsystolic and severe if the jet appeared throughout the complete systole. Diastolic function was assessed by analysis of the pulsed wave Doppler tracings of ductus venosus and umbilical vein. Abnormal ductus venosus FVW was defined as an absent or reversed A-wave. Pulsatile flow across the umbilical vein was defined as abnormal.

Postnatal assessment composed of a transthoracic echocardiogram in the first week of life and a second echocardiogram 1 month after the estimated date of delivery. A Vivid E9 or S6 (GE Healthcare, Wauwatosa, Wisconsin) echo machine was used for postnatal echocardiography. Peak velocity across the pulmonary valve was measured by continuous wave Doppler in the short axis view. Postnatal pulmonary stenosis and pulmonary atresia were both categorized as postnatal RVOTO. Pulmonary stenosis in neonates was defined as mild when the peak gradient was 2 to 3 m/s, moderate when the peak gradient was 3 to 4 m/s, and severe when the peak gradient was greater than

4 m/s. Clinical data were requested if cases were delivered in referring hospitals. To retrieve optimal follow-up, we contacted mothers that were not able to attend follow-up visits about 2 months after the estimated date of delivery and asked for hospital admission or treatment for RVOTO in their infant(s) in other centers. The study was approved by the medical ethical committee of the Leiden University Medical Center. All mothers signed informed consent.

Statistical analysis

Statistical analysis was performed with IBM SPSS 20.0 statistical package (Chicago, Illinois). Categorical variables were analysed by mixed model analysis and continuous variables with independent samples t-test. A p-value of less than 0.05 was considered statistical significant.

Results

In the study period, 124 pregnancies were referred for TTTS to our center, 119 were monochorionic diamniotic (MCDA) twins and five were monochorionic triamnionic or dichorionic triamniotic triplets. Laser therapy was performed in 115 cases, nine cases were managed expectantly because of Quintero stage 1 (n = 5), stage 5 (n = 2), or advanced gestational age (n = 2). Figure 1 summarizes the incidence of prenatal and postnatal RVOTO from TTTS diagnosis until the neonatal period, and Table 1 shows the baseline characteristics of prenatal and postnatal RVOTO cases.

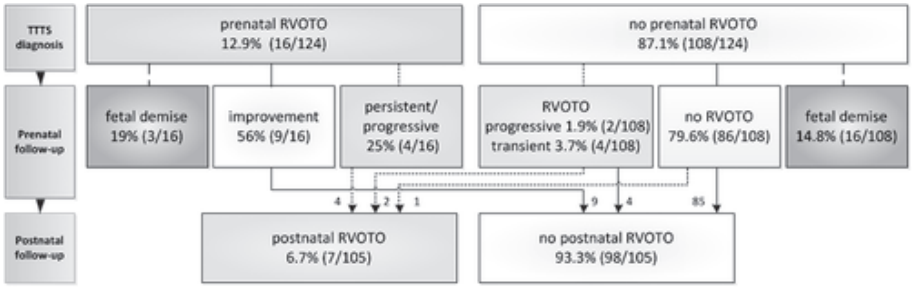

▲**Figure 1** Incidence of RVOTO of the total cohort at time of diagnosis and at prenatal and postnatal follow-up

Table 1. Baseline characteristics of recipients with abnormal FVW□PV at TTTS and postnatal RVOTO

	TTTS diagnosis		Neonatal follow-up	
	Normal FVW n=108	**Abnormal FVW n = 16**	**No RVOTO n = 98**	**RVOTO n = 7**
GA at TTTS diagnosis †	18+6 (4+5)	18+4 (7+0) *	19+1 (3+6)	17+4 (3+5) **
Quintero ‡				
stage I	17 (15.7%)	3 (18.8%)	14 (14.3%)	2 (28,6%)
stage II	37 (34.3%)	1 (6.3%)	31 (31.6%)	2 (28,6%)
stage III	50 (46.3%)	11(68.8%)	49 (50%)	2 (28,6%)
stage IV	2 (1.9%)	1(6.3%)	2 (2%)	1 (14.3%)
stage V	2 (1.9%)	0 (0%)	2 (2%)	0 (0%)
Laser performed	96 (88.9%)	13 (81.3%)	91 (92.9%)	5 (71.4%)
Fetal demise	16 (14.8%)	3 (18.8%)		
GA at delivery‡			33+2 (6+1)	34+3 (3+2)

*Values given as †median (IQR), or ‡number (%). *p-value 0.19, ** p-value is 0.03 FVW-PV, flow velocity waveforms of the pulmonary valve; TTTS, twin-to-twin transfusion syndrome; RVOTO, right ventricular outflow tract obstruction; GA, gestational age*

All 124 pregnancies received extended echocardiography at time of TTTS diagnosis. In 12.9% (16/124) of the recipients, prenatal RVOTO was present at the time of the TTTS diagnosis. Isolated pulmonary insufficiency was seen in seven cases (Table 2), pulmonary atresia (PA) in four cases (Table 3), and pulmonary stenosis in five cases (Table 4).

Table 2. Echocardiographic findings in recipients with isolated pulmonary insufficiency at time of TTTS diagnosis

	Q-stage	GA	Laser therapy	TI	MI	A-wave DV	UV	birth	Postnatal findings
1	III	19+3	yes	mild	no	reverse	pulsatile	37+2	normal
2	III	15+6	yes	mild	no	reverse	pulsatile		†
3	III	17+2	Yes	no	no	reverse	pulsatile	29+3	normal
4§	III	22+4	yes	severe	no	reverse	pulsatile	35+6	normal
5	II	16+5	yes	mild	no	normal	pulsatile	28+0	normal
6§	III	21+2	yes	severe	no	reverse	pulsatile		‡
7	III	16+3	yes	no	no	normal	pulsatile		†

TTTS, twin-to-twin transfusion syndrome; Q, Quintero stage; GA, gestational age; TI, tricuspid insufficiency; MI, mitral insufficiency; DV, ductus venosus A-wave; VU, umbilical vene; CTR, cor-thorax ratio § cases with circular shunt physiology; †immature birth; ‡fetal demise

Table 3. Echocardiographic findings in recipients with pulmonary atresia at time of TTTS diagnosis

	Q-stage	GA	Laser	TI	MI	A-wave DV	UV	birth	Postnatal Diagnosis and follow up
8	IV	16+5	yes	severe	no	reverse	pulsatile	34+3	Severe PS, severe TI with right ventricle dilatation, NND <1wk (cardiac failure combined with sepsis)
9	III	25+1	yes	no inflow/ outflow	no	reverse	pulsatile	30+5	Normal, A&W
10	III	23+6	yes	severe	no	reverse	Pulsatile	26+6	Normal, A&W
11	III	24+1	yes	severe	no	reverse	-	28+1	Mild PS, A&W

TTTS, twin-to-twin transfusion syndrome; Q, Quintero stage; GA, gestational age; TI, tricuspid insufficiency; MI, mitral insufficiency; DV, ductus venosus; UV, umbilical vene; PS, pulmonary stenosis; NND, neonatal death; A&W, alive and well

Prenatal RVOTO improved in nine out of 16 cases after laser therapy. In four cases, prenatal RVOTO was persistent or progressive until the neonatal period, of which three were in the pulmonary stenosis group. Two of these cases were in Quintero stage 1 and were managed expectantly. None of the cases with isolated pulmonary insufficiency developed postnatal RVOTO. Fetal demise in the prenatal RVOTO group occurred in three out of 16 cases, two because of birth before 24 weeks of gestation and one intrauterine demise occurred 2 weeks after laser therapy in a fetus with isolated pulmonary insufficiency and persistent severe TI.

Table 4. Echocardiographic findings in recipients with pulmonary stenosis at time of TTTS diagnosis

	Q-stage	velocity PV	GA	Laser	TI	MI	A-wave DV	UV	birth	Postnatal diagnosis and follow up
12	III	2.4 m/s	16+2	yes	mild	no	normal	-	29+1	Severe PA, balloon valvuloplasty after 3 wk
13	III	1.2 m/s	16+4	yes	mild	no	reverse	Normal	35+3	Normal, A&W
14	I	1.1 m/s	17+6	no	mild	no	normal	Normal	34+3	Severe PS, balloon valvuloplasty after 3 wk
15	I	1.5m/s	21+3	no	no	no	normal	Normal	36+1	Mild PS, expectant management A&W
16	I	1.5m/s	28+5	no	severe	no	normal	Normal	34+1	Normal, A&W

TTTS, twin-to-twin transfusion syndrome; Q, Quintero stage; PV, pulmonary valve; GA, gestational age at TTTS diagnosis; TI, tricuspid insufficiency; MI, mitral insufficiency; DV, ductus venosus; UV, umbilical vene; PS, pulmonary stenosis; PA, pulmonary atresia; A&W, alive and well

All cases received longitudinal follow-up during pregnancy. In 87% (108/124) of recipients, signs of prenatal RVOTO were absent at TTTS diagnosis. In 4.8% (6/124), prenatal RVOTO was observed only after laser therapy; these cases are summarized in Figure 2. In three cases, prenatal RVOTO was observed in the first examination within 24 hours after uncomplicated laser therapy. These three cases showed completely normal FVW-PV in the subsequent ultrasound examination 1 week after laser therapy. In three other cases, prenatal RVOTO appeared several weeks after laser therapy. Two of these cases were diagnosed with pulmonary stenosis in the neonatal period; the other developed primary pulmonary hypertension (PPHN).

▼**Figure 2.** Echocardiographic findings of cases with signs of prenatal RVOTO, apparent only after laser therapy

	Post laser RVOT abnormalities					
pre-laser	normal FVW-PV no TI	normal FVW-PV severe TI	normal FVW-PV severe TI	normal FVW-PV moderate TI	normal FVW-PV moderate TI	normal FVW-PV mild TI
	Laser 16w3d	**Laser 20w3d**	**Laser 25w1d**	**Laser 17w5d**	**Laser 27w1d**	**Laser 20w0d**
post laser	< 24 hrs abnormal FVW-PV (PI, no TI) Resolved completely within 1 week	<24 hrs abnormal FVW-PV (PI, severe TI) Resolved completely within 1 week IUD donor	< 24 hrs abnormal FVW-PV (PA, severe TI) IUD donor Resolved completely within 1 week	<24hrs normal FVW-PV moderate TI 19-25 weeks: mild PS with elevated flow 1.3 m/s over thickened valve without TI >27 weeks normal FVW-PV	<24 hrs normal FVW-PV no TI 30-33 weeks: mild PS and PI with elevated flow 1.4 m/s, severe TI, RVH > 33 weeks normal FVW-PV	<24 hrs normal FVW-PV no TI from 23 weeks progressive pulmonary valve calcification with normal FVW-PV
	Birth 36w0d		**Birth 38w0d**	**Birth 36w1d**	**Birth 36w3d**	**Birth 36w3d**
<1 week	No abnormalities	No clinical signs of RVOTO	No clinical signs of RVOTO	turbulence PV no PS	RVH, PPHN, no RVOTO	PV calcification, no PS
2 months	No abnormalities			mild valvular PS	no abnormalities	PV calcification, mild valvular PS

FVW-PV, flow velocity waveforms across the pulmonary valve; TI, tricuspid insufficiency; PI, pulmonary insufficiency; PA, pulmonary atresia; IUD, intrauterine demise; RVH, right ventricle hypertrophy; PPHN, persistent pulmonary hypertension of the neonate; RVOTO, right ventricular outflow tract obstruction

Postnatal echocardiographic follow-up was performed in 67.6% (71/105) of surviving recipients. In 43% (45/105), follow-up was performed within the first week of life, and in 61% (64/105), follow-up was performed 1 month after estimated date of delivery. In cases without a postnatal scan, cancellation of the appointment was requested by the parents due to logistic reasons. The majority of these cases were pregnancies with uncomplicated recovery after TTTS. In these cases, delivery took place in the referral centers with long travel distance. In all the cases, mothers were interviewed about the details of the hospital admissions and possible cardiac examinations of the infants. In none of them cardiac anomalies were diagnosed.

Postnatal RVOTO was diagnosed in 6.7% (7/105) of the surviving recipients, of which 2.9% (3/105) were severe. Of the three severe cases, one was born at 34 weeks of gestation and died within the first week of life due to cardiac failure combined with sepsis. Two other neonates needed balloon valvuloplasty within the first month of life.

All severe cases showed RVOTO prenatally; the first case showed pulmonary atresia at TTTS diagnosis; the two others showed pulmonary stenosis. In one case (0.9%), mild pulmonary stenosis was observed at the second scan at the age of 2 months, whereas no signs of RVOTO were seen prenatally or at the first postnatal scan after delivery at 36 weeks of gestation.

The mean gestational age at TTTS diagnosis was 17 + 4 weeks in surviving recipients with postnatal RVOTO compared with 19 + 1 weeks in those without postnatal RVOTO, which is significantly lower (P = 0.03). Of 115 lasers, 43 were performed less than 18 weeks of gestation, of which five developed postnatal RVOTO (11.6%), 65 were performed between 18 and 24 weeks of gestation of which two developed postnatal RVOTO (3.1%), and 17 were performed after 24 weeks in which none developed postnatal RVOTO. The gestational age at TTTS diagnosis did not differ between recipients with and without prenatal RVOTO (P = 0.19). Quintero stages were equally distributed in cases with postnatal RVOTO, while prenatal RVOTO at TTTS diagnosis seem to occur more in the advanced Quintero stages (Table 1).

Comments

The incidence of prenatal RVOTO in this prospective, consecutive cohort is 12.9% in recipients at TTTS diagnosis, of which 4/16 (25%) showed PA, 5/16 (31%) showed PS, and 7/16 (44%) showed isolated PI. Postnatal RVOTO was diagnosed in 6.7% of surviving recipients. All severe postnatal cases (2.9%) showed prenatal RVOTO at the time of TTTS diagnosis, while the majority of the mild postnatal RVOTO cases became apparent weeks after laser therapy or even in the neonatal period. A new finding is the occurrence of postnatal RVOTO in TTTS Quintero stage 1 cases, with expectant management.

Our results correspond well to previous prevalence estimates of prenatal RVOTO before laser therapy. Michelfelder *et al*[4] reported a prevalence of 8.7% in a retrospective cohort, of which 45% showed PA, 30% PS, and 25% isolated PI. Moon-Grady *et al*[9] reported 21% of abnormal pulmonary valve function before laser therapy in a retrospective cohort, of which 25% showed PA, 62% PS, and 17% showed pulmonary insufficiency (PI). In a retrospective study of cardiac function in stage 4 TTTS by van Mieghem *et al*,[15] preoperative PA was found in 36% of recipients.

In the current study, pulmonary stenosis or atresia at the time of TTTS diagnosis resulted in severe postnatal valvular stenosis in 33% of cases (3/9) and in mild stenosis in 11% (1/9).[4, 8-10] In addition, 2% of cases with initial normal FVW-PV at TTTS diagnosis developed abnormal FVW-PV in the weeks after laser therapy, which progressed to mild valvular stenosis in the neonatal period.

Because most studies on this topic focus on recipients with preintervention RVOTO and lack longitudinal prospective follow-up on all recipients, detection of these late-onset cases is rarely described before.[1] Initial mild RVOTO after birth is however important, as it may progress to severe RVOTO with need for intervention in infancy.[1, 16] The total incidence of postnatal RVOTO found in this study is slightly higher than in prior large cohort studies, which found an incidence of 2.1% to 4%.[3-5, 17] This can be explained by the systematic longitudinal follow-up of all recipients in pregnancy, which allowed us to detect mild and late-onset cases. However, the total incidence in this study is possibly underestimated because postnatal echocardiographic assessment was performed in only 67.6% (71/105) of surviving recipients, and for that, mild cases could have been missed, because cases without a postnatal scan were regarded as no postnatal RVOTO, because of the absence of clinical signs of RVOTO.

Several pathways of RVOTO development have been suggested, such as the underdevelopment of the pulmonary valve due to decreased forward flow across the PV, caused by right ventricular hypertrophy, the effect of endothelial damage caused by shear stress, which eventually results in valve dysplasia and damage of the valve due to exposure to abnormal concentrations of vasoactive mediators such as endothelin-1, renin, and angiotensin II.[16, 18-22] The decreased flow across the PV may be explained by impaired cardiac function at the time of TTTS.[2, 6, 7, 23-25] Myocardial hypertrophy combined with increased systemic afterload can result in insufficient closure of the valve, which ultimately causes pulmonary insufficiency and eventually bidirectional flow in the ductus arteriosus, which was categorized as isolated pulmonary insufficiency.[4] With progression of the TTTS, cardiac function worsens, and the FVWs across the PV develop to functional pulmonary atresia with no right ventricular outflow. After laser therapy, volume overload and cardiac function are restored, and the FVW-PV will normalize, in the absence of irreversible anatomical changes to the pulmonary valve. Accordingly, isolated pulmonary insufficiency may be considered as a relatively mild finding in TTTS, which is presumably reversible after laser therapy. This hypothesis is supported by the observation that none of

these cases in our series did develop postnatal RVOTO, confirming the finding in a retrospective cohort study by Michelfelder *et al*.[4]

In contrast to this, cases with pulmonary insufficiency with reversed circular shunt physiology were included in the isolated PI in our cohort (cases 4 and 6, Table 2). Circular shunt physiology is a circular shunt in which blood originating in one cardiac chamber is shunted through the heart to return to the original chamber without ever crossing a capillary bed and described in recipients in a recent study of Pruetz *et al*.[11] In one case, fetal demise occurred, while the other case improved without echocardiographic abnormalities postnatally in this recipient. Pruetz *et al* stated that recipients with preoperative circular shunt physiology are at increased risk for postnatal right ventricular outflow tract obstruction. Our sample size is, however, too small to conclude this.

All prenatal pulmonary atresia cases in our study showed severe tricuspid insufficiency. The FVW-PV normalized when the right ventricle function was restored after laser therapy,[8, 10] proving the concept that the pulmonary atresia at time of TTTS diagnosis is a functional. Only one prenatal pulmonary atresia case resulted in postnatal severe valvular pulmonary stenosis. In this case, right ventricular dysfunction persisted with ventricular dilatation and severe tricuspid insufficiency. The TTTS was diagnosed early in the second trimester, when semilunar valve formation is not fully completed.[26] Overall, we found that early TTTS was associated with postnatal RVOTO, confirming the findings in a retrospective cohort previously published by our group.[5] We hypothesize that the fetal heart at early gestation might be more vulnerable to hemodynamic changes and endothelial damage, caused by hypertension and accelerated by circulating vasoactive mediators, which eventually leads to valve dysplasia.

Anatomical changes at valve level result in an elevated peak systolic velocity across the PV, and this series shows that these FVWs are less favorable to be reversible after cardiac function is restored. Thus, elevated peak systolic velocity across the pulmonary valve carries a higher risk of postnatal valve pathology, with the need of intervention, compared with isolated pulmonary insufficiency or functional pulmonary atresia. Counselling and ultrasonographic follow-up could be adjusted to this finding.

It has been suggested previously that recipients in higher Quintero stages of TTTS are more likely to develop postnatal RVOTO.[10, 11] In this prospective cohort, prenatal

RVOTO at TTTS diagnosis seem to occur more frequently in the advanced stages of TTTS, but postnatal RVOTO was equally found in all Quintero stages. We hypothesize that severe cardiac dysfunction with subsequent prenatal RVOTO is more frequently present in advanced stages of TTTS, while pulmonary valve dysplasia might occur equally in all stages. Development to postnatal RVOTO is possibly facilitated by a longer period of volume overload, shear stress, and transfusion of vasoactive mediators. This vascular programming effect in the setting of intertwin differences, altered by different treatment strategies of TTTS, has been reported previously.[27-29] In our cohort, this is illustrated by three cases with expectant management in Quintero 1 that showed pulmonary stenosis. TTTS improved completely, but pulmonary stenosis was progressive in two cases, with the need of balloon valvuloplasty in the third week of life in one case. For detection of postnatal RVOTO in recipients, we propose extended fetal echocardiographic follow-up 1 to 2 months after laser therapy or TTTS diagnosis and routine postnatal echocardiographic follow-up at the corrected age of 1 months.

It should be noted that the sample size is still limited, although relatively large compared with other studies on this subject. In addition, routine postnatal echocardiographic assessment could not be performed in all neonates, mainly because patients preferred delivery at their referral hospitals. This means that the prevalence of mild RVOTO could be underestimated.

Conclusion

Recipients with severe postnatal RVOTO all show abnormal FVW-PV at the time of TTTS diagnosis. Recipients with a pattern of elevated peak systolic velocities across the PV seem to be more likely to develop postnatal RVOTO than patterns showing isolated pulmonary insufficiency or functional pulmonary atresia. Early gestational age and duration of hemodynamic adaptation to TTTS might be a stronger predictor than Quintero stage for postnatal RVOTO. Importantly, mild RVOTO can develop weeks after laser therapy or even in the neonatal period, and routine prenatal and postnatal cardiac evaluation is recommended in all surviving recipients of TTTS.

References

1. Lougheed J, Sinclair BG, Fung Kee Fung K, et al. Acquired right ventricular outflow tract obstruction in the recipient twin in twin-twin transfusion syndrome. *J Am Coll Cardiol.* 2001;38(5):1533-1538.
2. Karatza AA, Wolfenden JL, Taylor MJ, Wee L, Fisk NM, Gardiner HM. Influence of twin-twin transfusion syndrome on fetal cardiovascular structure and function: prospective case-control study of 136 monochorionic twin pregnancies. *Heart.* 2002;88(3):271-277.
3. Springer S, Mlczoch E, Krampl-Bettelheim E, et al. Congenital heart disease in monochorionic twins with and without twin-to-twin transfusion syndrome. *Prenat Diagn.* 2014;34(10):994-999.
4. Michelfelder E, Tan X, Cnota J, et al. Prevalence, Spectrum, and Outcome of Right Ventricular Outflow Tract Abnormalities in Twin-twin Transfusion Syndrome: A Large, Single-center Experience. *Congenit Heart Dis.* 2015;10(3):209-218.
5. Eschbach SJ, Boons L, Van Zwet E, et al. Right ventricular outflow tract obstruction in complicated monochorionic twin pregnancy. *Ultrasound Obstet Gynecol.* 2017;49(6):737-743.
6. Sueters M, Middeldorp JM, Vandenbussche FP, et al. The effect of fetoscopic laser therapy on fetal cardiac size in twin-twin transfusion syndrome. *Ultrasound Obstet Gynecol.* 2008;31(2):158-163.
7. Herberg U, Gross W, Bartmann P, Banek CS, Hecher K, Breuer J. Long term cardiac follow up of severe twin to twin transfusion syndrome after intrauterine laser coagulation. *Heart.* 2006;92(1):95-100.
8. Gray PH, Ward C, Chan FY. Cardiac outcomes of hydrops as a result of twin-twin transfusion syndrome treated with laser surgery. *J Paediatr Child Health.* 2009;45(1-2):48-52.
9. Moon-Grady AJ, Rand L, Lemley B, Gosnell K, Hornberger LK, Lee H. Effect of selective fetoscopic laser photocoagulation therapy for twin-twin transfusion syndrome on pulmonary valve pathology in recipient twins. *Ultrasound Obstet Gynecol.* 2011;37(1):27-33.
10. Ortiz JU, Masoller N, Gomez O, et al. Rate and Outcomes of Pulmonary Stenosis and Functional Pulmonary Atresia in Recipient Twins with Twin-Twin Transfusion Syndrome. *Fetal Diagn Ther.* 2017;41(3):191-196.
11. Pruetz JD, Votava-Smith JK, Chmait HR, Korst LM, Llanes A, Chmait RH. Recipient Twin Circular Shunt Physiology Before Fetal Laser Surgery: Survival and Risks for Postnatal Right Ventricular Outflow Tract Obstruction. *J Ultrasound Med.* 2017.
12. Hornberger LK. Re: Right ventricular outflow tract obstruction in complicated monochorionic twin pregnancy. S. J. Eschbach, L. S. T. M. Boons, E. Van Zwet, J. M. Middeldorp, F. J. C. M. Klumper, E. Lopriore, A. K. K. Teunissen, M. E. Rijlaarsdam, D. Oepkes, A. D. J. Ten Harkel, M. C. Haak. Ultrasound Obstet Gynecol 2017; 49: 737-743. *Ultrasound Obstet Gynecol.* 2017;49(6):693-694.
13. Quintero RA, Morales WJ, Allen MH, Bornick PW, Johnson PK, Kruger M. Staging of twin-twin transfusion syndrome. *J Perinatol.* 1999;19(8 Pt 1):550-555.
14. Messing B, Porat S, Imbar T, Valsky DV, Anteby EY, Yagel S. Mild tricuspid regurgitation: a benign fetal finding at various stages of pregnancy. *Ultrasound Obstet Gynecol.* 2005;26(6):606-609; discussion 610.
15. Van Mieghem T, Martin AM, Weber R, et al. Fetal cardiac function in recipient twins undergoing fetoscopic laser ablation of placental anastomoses for Stage IV twin-twin transfusion syndrome. *Ultrasound Obstet Gynecol.* 2013;42(1):64-69.

16. Manning N, Archer N. Cardiac Manifestations of Twin-to-Twin Transfusion Syndrome. *Twin Res Hum Genet.* 2016;19(3):246-254.
17. Lopriore E, Bokenkamp R, Rijlaarsdam M, Sueters M, Vandenbussche FP, Walther FJ. Congenital heart disease in twin-to-twin transfusion syndrome treated with fetoscopic laser surgery. *Congenit Heart Dis.* 2007;2(1):38-43.
18. Bajoria R, Ward S, Chatterjee R. Brain natriuretic peptide and endothelin-1 in the pathogenesis of polyhydramnios-oligohydramnios in monochorionic twins. *Am J Obstet Gynecol.* 2003;189(1):189-194.
19. Mahieu-Caputo D, Muller F, Joly D, et al. Pathogenesis of twin-twin transfusion syndrome: the renin-angiotensin system hypothesis. *Fetal Diagn Ther.* 2001;16(4):241-244.
20. Mahieu-Caputo D, Salomon LJ, Le Bidois J, et al. Fetal hypertension: an insight into the pathogenesis of the twin-twin transfusion syndrome. *Prenat Diagn.* 2003;23(8):640-645.
21. Van Mieghem T, Done E, Gucciardo L, et al. Amniotic fluid markers of fetal cardiac dysfunction in twin-to-twin transfusion syndrome. *Am J Obstet Gynecol.* 2010;202(1):48 e41-47.
22. Herberg U, Bolay J, Graeve P, Hecher K, Bartmann P, Breuer J. Intertwin cardiac status at 10-year follow-up after intrauterine laser coagulation therapy of severe twin-twin transfusion syndrome: comparison of donor, recipient and normal values. *Arch Dis Child Fetal Neonatal Ed.* 2014;99(5):F380-385.
23. Barrea C, Hornberger LK, Alkazaleh F, et al. Impact of selective laser ablation of placental anastomoses on the cardiovascular pathology of the recipient twin in severe twin-twin transfusion syndrome. *Am J Obstet Gynecol.* 2006;195(5):1388-1395.
24. Habli M, Michelfelder E, Livingston J, et al. Acute effects of selective fetoscopic laser photocoagulation on recipient cardiac function in twin-twin transfusion syndrome. *Am J Obstet Gynecol.* 2008;199(4):412 e411-416.
25. Michelfelder E, Gottliebson W, Border W, et al. Early manifestations and spectrum of recipient twin cardiomyopathy in twin-twin transfusion syndrome: relation to Quintero stage. *Ultrasound Obstet Gynecol.* 2007;30(7):965-971.
26. Monaghan MG, Linneweh M, Liebscher S, Van Handel B, Layland SL, Schenke-Layland K. Endocardial-to-mesenchymal transformation and mesenchymal cell colonization at the onset of human cardiac valve development. *Development.* 2016;143(3):473-482.
27. Gardiner HM, Taylor MJ, Karatza A, et al. Twin-twin transfusion syndrome: the influence of intrauterine laser photocoagulation on arterial distensibility in childhood. *Circulation.* 2003;107(14):1906-1911.
28. Gardiner HM, Barlas A, Matsui H, et al. Vascular programming in twins: the effects of chorionicity and fetal therapy for twin-to-twin transfusion syndrome. *J Dev Orig Health Dis.* 2012;3(3):182-189.
29. Cheung YF, Taylor MJ, Fisk NM, Redington AN, Gardiner HM. Fetal origins of reduced arterial distensibility in the donor twin in twin-twin transfusion syndrome. *Lancet.* 2000;355(9210):1157-1158.



S.J. Eschbach
M. Gijtenbeek
N. van Geloven
D. Oepkes
M.C. Haak

Published in: Journal of Echocardiography, 2018; 38(13): 1013-1019

CHAPTER VII

Measurement of cardiac function by cardiac time intervals, applicability in normal pregnancy and twin-to-twin transfusion syndrome

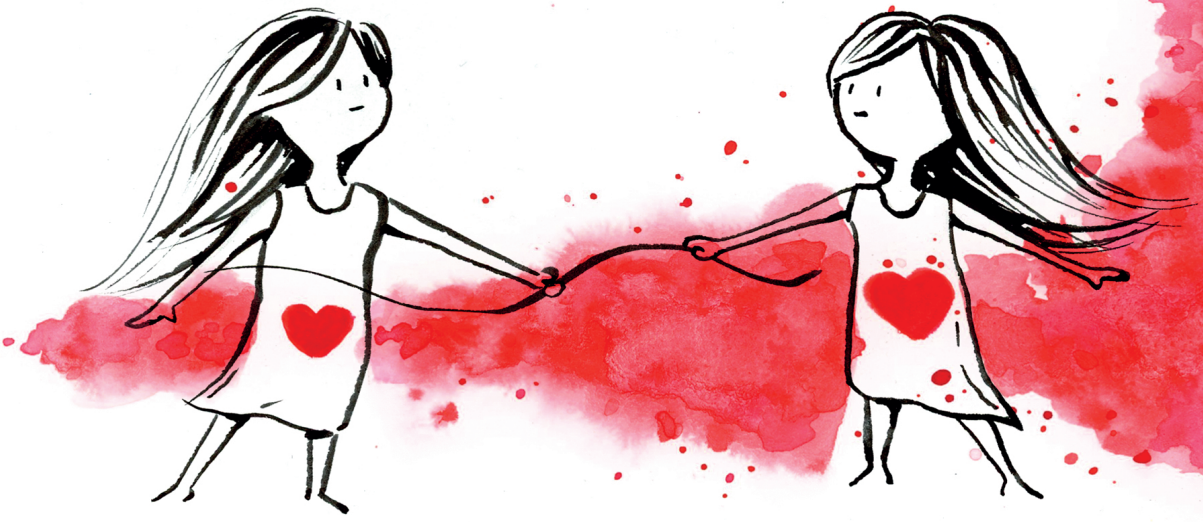

Abstract

Objective

To detect early cardiac deterioration, a simple and stable tool is needed. Measurement of time intervals in a simple 4-chamber view using color-coded tissue Doppler imaging is a relatively new approach to assess fetal cardiac function. The aim of this study was to evaluate the applicability of this modality and to construct reference ranges for cardiac time intervals.

Methods

We performed a prospective longitudinal cohort study in healthy fetuses. We used linear mixed models to construct age-adjusted reference ranges for shortening time (St) and lengthening time (Lt) in three cardiac regions: global heart and right and left ventricular wall. St and Lt were expressed as percentage of the cardiac cycle. Feasibility and intra- and interobserver variabilities were evaluated. We applied the technique to twin–twin transfusion syndrome (TTTS) recipients before laser therapy to test the diagnostic performance.

Results

A total of 251 recordings were obtained from 54 healthy singletons. St decreased and Lt increased with gestational age in all regions. We found a high feasibility (99.6%) and excellent intra-/interobserver variability for St (0.96/0.94) and Lt (0.99/0.96) of the global heart. Left and right ventricle performance parameters were good. In TTTS recipients, St was prolonged ($p < 0.01$) and Lt was shortened ($p < 0.01$) in all regions and the feasibility was excellent (96.6%).

Conclusion

The assessment of fetal cardiac function by measurement of cardiac time intervals is technically feasible with good reproducibility, even in difficult scanning circumstances such as TTTS. It is possible to discriminate between healthy and compromised fetuses with this technique.

Introduction

Assessment of fetal cardiac function gained much interest in the last decade. New ultrasound technologies like speckle tracking and tissue Doppler seem promising. Conventional Doppler is increasingly used to assess cardiac function in the so-called modified myocardial performance index (MPI). However, this is mainly used in tertiary care centers in research settings. Implementation in general practice is hampered by the need for extensive training to ensure acceptable performance and reproducibility.[1, 2] Normal ranges of MPI vary widely, and despite a clear agreement about the landmarks of the time periods, interobserver agreement is often disappointing.[3-6] A simple, stable quantitative measurement of cardiac function, which is suitable for daily assessment, is not yet available. There is, however, a need to predict early functional deterioration of fetuses that are at risk of cardiac failure.[7]

Tissue Doppler imaging (TDI) has been used since the early 1990s in adult echocardiography,[8] but is a relatively new technique in fetal echocardiography. Pulsed-wave TDI technique is similar to pulsed-wave Doppler, but focuses on lower frequency shifts, which enables measurement of lower velocities like myocardial wall motion. Color-coded recordings are easy to obtain in a simple four-chamber view. In color-coded tissue Doppler imaging (cTDI), the representation of myocardial velocities is superimposed on gray-scale two-dimensional or M-mode images, to indicate the direction and velocity of myocardial motion.[9]

In adults, cTDI is used as prognostic tool in heart failure and differentiation between constrictive pericarditis and restrictive cardiomyopathy.[10-12] In fetal echocardiography, cTDI was first described for the assessment of myocardial velocities by Paladini *et al*.,[13] in pregnancies complicated by intrauterine growth restriction or gestational diabetes.[14- 18] cTDI does not differentiate between active motion and passive motion; thus, fetal or maternal movements may cause artefacts. Velocity measurements are, furthermore, influenced by angle of insonation and the size of the used region-of-interest (ROI).[19, 20] The applicability of the use of velocities in fetuses is, therefore, limited. In contrast, time intervals are independent of the angle of insonation and ROI size, making the use of time intervals a promising new approach for the assessment of fetal cardiac function. [15, 19]

In cTDI images, change in the direction of the myocardial wall motion is visible as a nadir in the curve. We hypothesize that these nadirs can be used as transition

markers to indicate the moment from shortening to lengthening of the myocardium. This might be an easy and reproducible technique to measure cardiac time intervals to express fetal cardiac function.

The aim of our study was to evaluate the applicability of cTDI in terms of feasibility, intra- and interobserver variability. We created reference curves of the shortening time (St) and lengthening time (Lt) of the myocardial wall, in specific areas in the fetal heart and the whole heart, visualized in the four-chamber view. In addition, we evaluated St and Lt in twin–twin transfusion syndrome (TTTS) recipients, who typically show compromised cardiac function, to investigate the ability to discriminate between normal and abnormal cardiac function.

Methods

Uncomplicated singleton pregnancies were recruited in a primary care center and at our fertility department between November 2014 and December 2016. The pregnancies were dated by crown to rump (CRL) measurement in the first trimester or date of conception in IVF pregnancies. Conditions that possibly influence fetal cardiac function were excluded, including maternal diabetes, pregnancy induced hypertension, pre-eclampsia, systemic lupus erythematosus, fetal heart malformations, and birth weight below the 5th percentile.

Color-coded Doppler clips were acquired using a Toshiba Aplio 500 with a PVT-674BT 6 MHz transducer in early second trimester and a PVT-375BT 3.5 MHz transducer in late second and third trimester. A measurement software package (Toshiba Medical Systems Corporation) was used for analysis. Ultrasonographic examinations were repeatedly performed between a gestational age (GA) of 16 and 36 with a monthly interval. Fetal biometry and standard 2D echocardiography were performed in each examination. In the absence of fetal movements, at least two color-coded tissue Doppler recordings, containing 5 or more cardiac cycles, were stored in an apical or basal four-chamber view. Settings were optimized with the heart covering approximately 60% of the image, to obtain the highest frame rates per second.[20] The examinations were limited to a 15 min slot per fetus for the complete examination.

Time intervals in color-coded tissue Doppler recordings

In images derived from cTDI, the change of direction in myocardial movement results in nadirs in the curve. Shortening time (St) was defined as the duration of myocardial motion when the ventricular wall shortens, and is expressed as percentage of the cardiac cycle. Lengthening time (Lt) was defined as the duration of myocardial motion when the ventricular wall extends, and expressed as percentage of the cardiac cycle. St and Lt are not the same as systole and diastole, which are defined by opening and closure of the semilunar valves and by not myocardial motion. Time intervals between St and Lt were noted as inter St-Lt and inter Lt-St times.

As demonstrated in Figure 1, the nadirs that delineate St and Lt were defined as the ones with the smallest angle towards the direction of shortening, respectively lengthening movement. The cardiac cycle with the most appropriate delineation of the time intervals was selected and stored separately for analysis. Three regions of interest (ROI) were examined in each clip. A large ROI was used to evaluate global heart function. The large ROI was placed around the total heart depicted as four-chamber view, covering at least both ventricles. Two smaller ROI's were used to evaluate specific areas in the fetal heart (Figure 1): at the base of the right ventricular wall (RV), just beneath the tricuspid valve, and at the base of the left ventricular wall, just beneath the mitral valve (LV). The smaller ROI's were placed just below the attachment of the AV valves at the free ventricular wall at the end of systole with the AV valves closed, to measure the base of the ventricle, as shown in Figure 1. The size of this ROI covered the width of myocardial wall, but did not involve the AV valve.

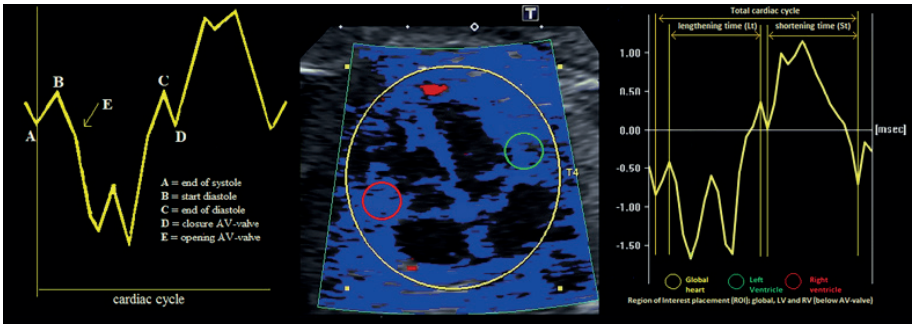

▲**Figure 1.** Schematic illustration of the cardiac cycle using cTDI, placement of regions of interest (ROI) and demarcations of lengthening time (Lt) and shortening time (St) in the derived image

To investigate the ability to express abnormal cardiac function of this measurement, we performed cTDI measurements on all recipients with TTTS referred to our department between January 2015 and December 2016. We used the last ultrasound examination before laser therapy. Recipients may demonstrate cardiac dysfunction at time of TTTS diagnosis.[21] We stored 2 color-coded tissue Doppler recordings, containing 5 or more cardiac cycles for analysis of the St and Lt. Because TTTS occurs mainly between 14 to 28 weeks, we compared recipients with healthy singletons within this gestational age period. Thus, the TTTS recipients were matched at the level of gestational age. All examinations were performed and analyzed by one experienced operator (S.E.). For intraobserver agreement, 30 clips containing one raw cardiac cycle of the singleton group were stored, and analyzed three times with a time interval of 3 months. For interobserver agreement, a second operator (M.G.) performed three analyses on the same 30 cardiac cycles. The mean of the three analyses of both operators was compared for interobserver agreement. Within-fetus variability was defined as agreement in three different cardiac cycles in different clips in one examination, and analyzed by the same operator (S.E.). The study was approved by the medical ethical committee of the Leiden University Medical Center and all women signed informed consent.

Statistical analysis

Statistical analysis was performed with IBM SPSS 20.0 statistical package (Chicago, IL, USA). Feasibility was defined as the percentage of measurements, which could be performed successfully. A measurement was noted as successful if the signal was clear enough to recognize all 4 nadirs. A measurement was unsuccessful in case of absent nadirs, or multiple nadirs in which the demarcation nadir could not be recognized. Baseline characteristics between healthy singletons and recipients were compared with the ***t*** test and Chi-square test.

Intra- and interobserver agreement and within-fetus variability were quantified by the intraclass correlation coefficient. Because of the longitudinal character of this study, we used linear mixed models in which we included a random intercept per individual to account for the correlated measurements within each fetus. For each outcome variable, we evaluated whether the gestational age trend increased or decreased over time, using a mixed model with a fixed linear age effect. We used this same model to construct reference intervals for healthy singletons. To compare means of TTTS recipients and healthy singletons, we constructed a second mixed model for

each outcome including gestational age, group (healthy singleton or TTTS recipient) and the interaction between age and group as fixed effects. From this model, we estimated the mean difference between the groups at the mean observed gestational age.

Results

The baseline characteristics of the healthy singletons and the TTTS recipients are depicted in Table 1. Sixty-one singletons were eligible for inclusion, but seven cases were excluded from analysis, because gestational diabetes or intrauterine growth restriction developed during gestation.

A total of 251 examinations were performed in 54 healthy singletons. Performance parameters are summarized in Table 2. Feasibility in the global heart and the right ventricular wall was excellent (99.6%/93.6%), and good in the left ventricular wall (78.1%). The mean global shortening time was 45.8% of the cardiac cycle at 16 weeks of gestation, and decreased significantly to 42.4% at 36 weeks of gestation, while mean global lengthening time was 42.8% of the cardiac cycle at 16 weeks of gestation, and increases to 44.6% at 36 weeks of gestation. Normal reference curves are constructed and are shown in Figure 2. The inter St-Lt and inter Lt-St time frames were noted and analysed, as shown in Table 2. While inter St-Lt appears to be stable during gestation, inter Lt-St increases in all ROI's.

Intraobserver agreement within a cardiac cycle was good for the global heart, the right and the left ventricular wall (St 0.98/0.94/0.91 and Lt 0.99/0.94/0.89). Interobserver agreement was excellent for the global heart (St 0.94 and Lt 0.96), and reasonable in the right ventricular wall (St 0.76 and Lt 0.72) and left ventricular wall (St 0.82 and Lt 0.74). The intraclass correlation coefficient for within-fetus variability varied between 0.17 and 0.61 in all ROIs, reflecting high variability of the heart cycle within the same fetus. Mean frame rate per second (fps) was 98, and standard deviation was 35 fps. Lower frame rates were associated with advanced gestational age.

Baseline characteristics for TTTS recipients are comparable with healthy singletons (Table 1). In 86 recordings of recipients at time of TTTS diagnosis, feasibility was 96.6% for global ROI, 94.2% for RV, and 70.0% for LV. Lengthening time was significantly shortened, and shortening time was significantly prolonged in all ROI's (Table 3 and Fig. 3).

Table 1. Demographic characteristics and pregnancy outcome of singletons and recipients

	Singletons ***% or mean (+- SD)*** **N=54**	**Recipients** ***% or mean (+- SD)*** **N=86**	**p-value**
Caucasian	93.2	97.0	0.17
Maternal body mass index (kg/m^2)	23.3 ± 3.1	24.6 ± 4.6	0.05
Gestational age at delivery (weeks)	39.6 ± 1.4	31.5 ± 5.1	
Birth weight (grams)	3500 ± 496	1985 ± 630	
5-min Apgar score	9 ± 1	8 ±1	
Quintero stage n (%)	n/a		
I		14 (16.3)	
II		21(24.4)	
III		48 (55.8)	
IV		2 (2.3)	
V		1 (1.2)	
Mean frame rate per second in 2nd trimester	124 ± 22	122 ± 30	0.91

Table 2. Performance of CTDI in different ROI's of the fetal heart in second and third trimester

	Mean % 16 wks (SD)	**Mean % 36 wks (SD)**	**p-value**	**Feasibility (%)**	**Intra-CC**	**Inter-CC**	**Within-fetus variability**
Global							
St	45.8 (3.3)	42.4 (3.3)	<0.01	99.6	0.98	0.94	0.60
Lt	42.8 (4.5)	44.6 (4.5)	0.049		0.99	0.96	0.56
Inter St-Lt	9.5 (3.8)	10.2 (3.8)	0.42		0.99	0.95	0.27
Inter Lt-St	3.1 (2.2)	5.1 (2.2)	<0.01		0.90	0.97	0.46
RV							
St	46.1(3.7)	42.1(3.7)	<0.01	93.6	0.94	0.76	0.47
Lt	44.7 (4.3)	46.8 (4.3)	0.02		0.94	0.72	0.38
Inter St-Lt	5.8 (3.0)	6.0 (3.0)	0.88		0.88	0.77	0.20
Inter Lt-St	3.7 (2.3)	5.5 (2.3)	<0.01		0.88	0.78	0.17
LV							
St	47.0 (4.1)	42.6 (4.1)	<0.01	78.1	0.91	0.82	0.29
Lt	39.8 (5.0)	44.5 (5.0)	<0.01		0.89	0.74	0.61
Inter St-Lt	3.9 (2.6)	5.6 (2.6)	0.01		0.92	0.60	0.29
Inter Lt-St	4.0 (2.6)	5.6 (2.6)	0.01		0.86	0.74	0.19

CTDI, Color Tissue Doppler Imaging; SD, standard deviation; ROI, region of interest; St, Shortening time; Lt, Lengthening time; RV, right ventricular wall; LV, left ventricular wall; Intra-CC, intraclass correlation coefficient for intraobserver agreement; inter-CC, intraclass correlation coefficient for interobserver agreement

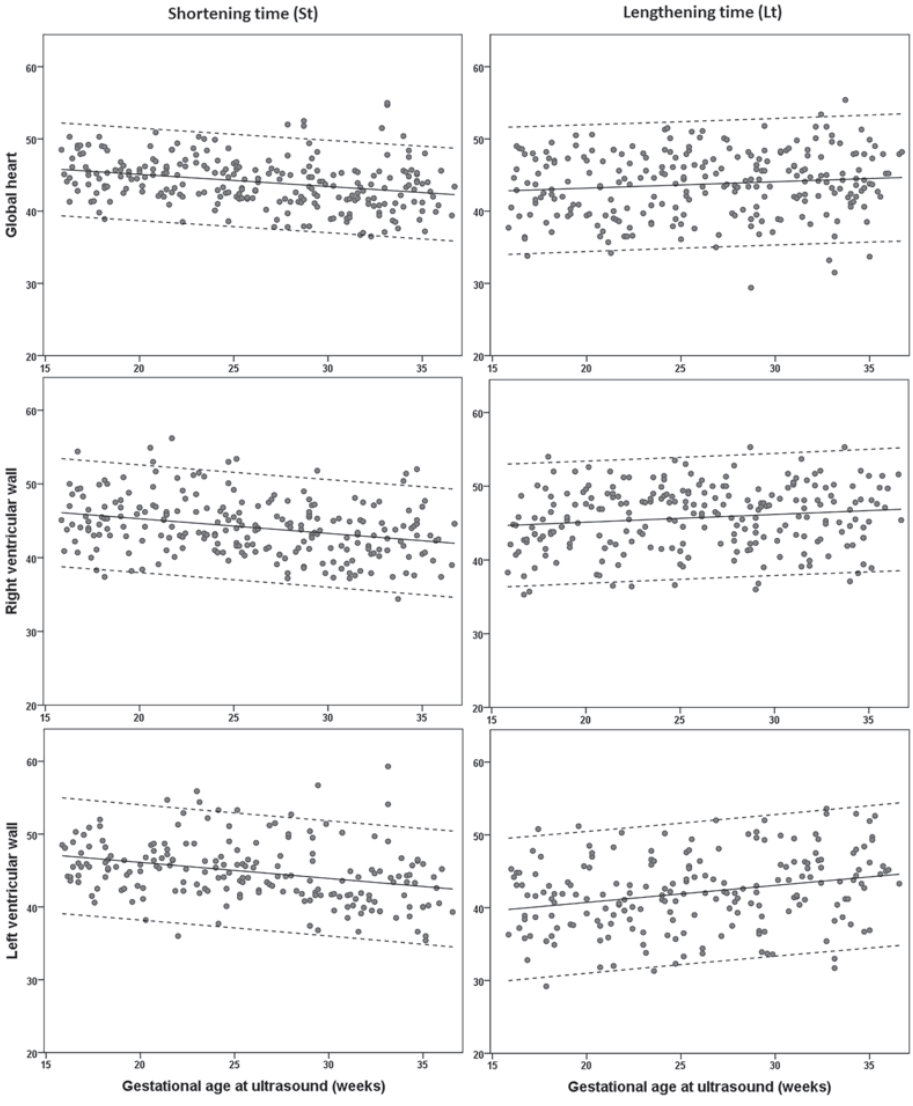

▲**Figure 2.** Reference charts for Lt and St in healthy singletons, in different regions of interest in the fetal heart from 16 to 36 weeks of gestation

Table 3. Mean (SD) St and Lt for singletons versus recipients at time of TTTS diagnosis, in different ROI's of the fetal heart in the second trimester

	Recipients mean % (SD)	Singletons mean% (SD)	Mean Difference* (CI)	p-value
Global				
St	48.3 (4.7)	44.9 (2.7)	3.0 (1.9-4.1)	<0.01
Lt	37.6 (5.3)	43.4(4.5)	5.6 (4.1-7.0)	<0.01
Inter St-Lt	9.7 (4.7)	8.1 (4.0)	1.7 (0.4-2.8)	0.01
Inter Lt-St	4.3 (2.5)	3.7 (2.3)	0.8 (0.0-1.5)	0.04
RV				
St	49.0 (7.5)	45.2 (2.7)	3.1 (1.2-5.0)	<0.01
Lt	37.2 (7.1)	45.6 (4.2)	8.1 (6.3-9.9)	<0.01
Inter St-Lt	8.3 (2.5)	5.3 (3.1)	2.8 (1.7-4.0)	<0.01
Inter Lt-St	4.4 (3.0)	3.7 (2.3)	0.4 (-1.2-0.4)	0.30
LV				
St	48.9 (7.5)	45.8 (3.6)	3.1 (1.8-4.4)	<0.01
Lt	34.8(5.7)	41.2 (4.9)	6.1 (4.3-7.9)	<0.01
Inter St-Lt	10.4 (3.7)	4.3 (2.5)	6.0 (4.9-7.1)	<0.01
Inter Lt-St	5.8 (4.1)	4.3 (2.5)	1.5 (0.3-2.6)	0.01

*ROI, region of interest; St, Shortening time; Lt, Lengthening time; RV, right ventricular wall; LV, left ventricular wall; *the difference is tested based on the mean difference between recipients and singletons at 21 weeks using the linear mixed model; CI, confidence interval*

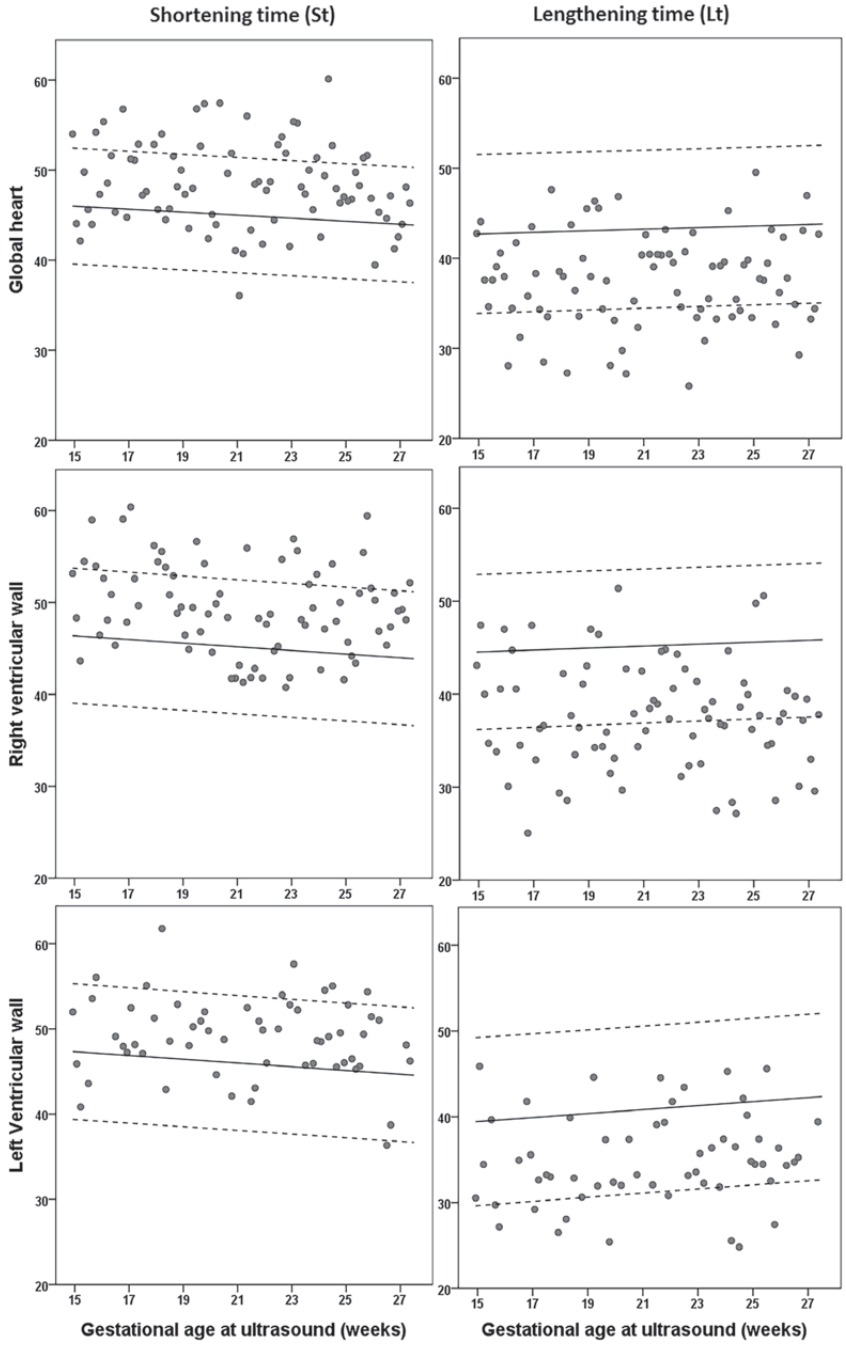

▲**Figure 3.** Scatterplots for recipients at time of TTTS diagnosis versus singletons reference curves in different ROI of the heart from 16 to 28 weeks of gestation

Discussion

In this study, we introduce a new approach to assess fetal cardiac function through the measurement of time intervals of the myocardial wall motion, in a simple four-chamber view using cTDI. Lengthening time and shortening time of the fetal heart show a slight increase, respectively, decrease with advancing gestation. Feasibility and intra- and interobserver agreement were shown to be excellent in the global heart ROI. The high feasibility (96.6%) in difficult circumstances like TTTS, with polyhydramnios and abundant fetal movements of the recipient, indicates that this approach is simple and robust. Lt was shortened and St prolonged in TTTS recipients compared to healthy singletons, reflecting the discriminative ability of this new parameter.

Currently, the myocardial performance index (MPI) is the most used method to assess fetal cardiac function. MPI is considered a consistent cardiac marker which becomes altered in early stages of chronic hypoxia or cardiac overload.[22] MPI implementation in routine assessment has several limitations. First, MPI is a pulsed-wave Doppler-derived index of isovolumetric time intervals (IRT/ICT) and ejection time (ET) and ventricular inflow and outflow are ideally measured in the same cardiac cycle. For left MPI measurement, a combined flow velocity waveform recording of mitral valve and aorta outflow can be obtained in the same sample volume, but these recordings require considerable expertise of the operator in image acquisition and correct recording of the Doppler tracing. The anatomy of the tricuspid valve and pulmonary artery, however, precludes recording of both valves within the same Doppler sample gate in the right ventricle, which is the dominant ventricle in fetal circulation. Therefore, right MPI can only be calculated from two separate recordings, which affects feasibility and reproducibility. As a result, normal ranges of both left and right MPI vary widely and interobserver agreement is disappointing.[3-6] Another difficulty in MPI measurements is the caliper placement in the Doppler waveforms to calculate the time intervals. This seems to be resolved with the development of automated MPI systems which removes the subjectivity of manual caliper placement, but authors acknowledge that ultrasound image acquisition remains a potential source of variability, even for highly trained operators.[23, 24] Contrary, the cTDI recordings described in this study are easy to obtain because only a recording of the four-chamber view is needed. The four-chamber view is easy to acquire and is part of every routine obstetric ultrasound examination. The placement of the ROI is simple and fast, which makes this technique applicable in daily obstetrical care in the future.

The measurement of cardiac time intervals in cTDI is a relatively new approach in fetal echocardiography.[15] Willruth *et al*.[19] concluded that time intervals can be analyzed with a high accuracy, irrespective of which ROI size is used. They described IRT, ICT, and ET retrieved by cTDI, comparable to these parameters in Doppler-derived MPI. Interobserver agreement in this study was low, probably because the closure and the opening of the cardiac valves are not easy to recognize in the signal. In our approach of the analysis of the same signal, cardiac time intervals are marked by myocardial wall motion and not by the movement of the blood. Instead of ET, which represents blood volume shift and is marked by cardiac valve clicks, we propose to evaluate St, which reflects the time the myocardium actually contracts. By definition, St will be longer than ET, because the myocardium first starts to contract, and with increased intraventricular pressure, the semilunar valve opens and the ejection of blood starts. Lt is prolonged in the same manner (Figure 1). Consequently, the inter St–Lt and inter Lt–St are shorter than the isovolumetric time intervals. As shown in Table 2, the inter-shortening–lengthening time as well as the inter-lengthening–shortening time show a large standard deviation in all ROIs which we attribute to measurement error caused by the current frame rates. Therefore, the value of inter St–Lt, respectively, and Lt–St in individual measurements is limited.

However, this approach of the analysis of cTDI signal results in an excellent feasibility and intra- and interobserver agreement for global heart function, which is better than current used techniques to assess fetal cardiac function. This is explained by the simplicity of the large ROI placement and the easy recognition of the nadirs in the curve. We observed that wall motion in the smaller ROIs is less consistent and several smaller nadirs may be visible, which results in a larger interobserver variability. We observed that the LV shows lower feasibility scores compared to the RV. The previous studies show lower volume shifting and less ventricular wall displacement in the left ventricle compared to the right ventricle in fetal life,[15, 25-26] which might explain the nadirs to be less clear, which results in lower feasibility scores and reproducibility.

In contrast to intra- and interobserver agreement, within-fetus variability in our study was high in all areas of the fetal heart. We hypothesize that the high within-fetus variability can be attributed to beat-to-beat (BTB) variability, which is a physiological phenomenon mediated by the autonomic nervous system. This hypothesis is consistent with a recently published study by Maheshwari *et al*.,[27]

who showed that MPI time intervals have a BTB variability which is comparable with the fetal heart rate variability. BTB variability is well established in various Doppler flow measurements, and the occurrence of physiological changes as possible contributors to measurement variation is mentioned before in studies assessing repeatability.[28, 29]

Recipients in TTTS show abnormal cardiac function, and it is earlier suggested that cardiac profiling can be an aid in early management of TTTS.[30, 31] Our study shows deviations in mean cardiac time intervals with a shortened Lt, prolonged St, and prolonged inter St-Lt in recipients, which confirms findings of abnormal MPI and prolonged isovolumetric contraction time.[32, 33] The within-fetus variability in normal fetuses, together with the overlap of the results in TTTS recipients with the normal values, makes distinction in TTTS difficult. Care should be taken, and further research is needed to determine the diagnostic accuracy of cTDI. The feasibility rates we found in the TTTS recipients are, however, exceptional high compared to the current techniques, as it is known that the retrieval of Doppler recordings in TTTS is difficult because of the polyhydramnios and the abundant fetal movements of the recipient. A feasibility rate of 96.6% proves that this method is simple and fast. Future studies are planned by our group to elucidate the possible role of cTDI in monitoring monochorionic twins.

To investigate the ability to discriminate between normal and abnormal cardiac function, recipient twins were matched for gestational age to healthy singletons. The lack of a control group of uncomplicated twins is a limitation of our study. It is, however, well accepted that reference charts of healthy singletons are compared to complicated monochorionic twins. In the previous studies in the field of fetal cardiology, speckle tracking-derived fetal cardiac function and modified MPI measurements in recipient twins were compared to normal singleton fetuses.[24, 34, 35] Uncomplicated (monochorionic) twins are generally not used as a control group, since twin pregnancies cannot be considered normal because of their complexity and high risk of complications.

Conclusion

In conclusion, the proposed technique presents a promising new approach to assess fetal cardiac function. Recordings are easy to obtain and feasibility and inter- and intraobserver agreement are excellent for global heart function, even in difficult scanning circumstances as TTTS recipients. Therefore, this technique is potentially useful in daily practice, because it can be applied in only a four-chamber view. Furthermore, this approach seems promising in the detection of abnormal heart function, but further research in pathological pregnancies is needed.

References

1. Herberg U, Breuer J, et al. Imaging in fetal cardiology. Minerva Pediatr. 2014;66:453–7
2. Simpson JM, Cook A. Repeatability of echocardiographic measurements in the human fetus. Ultrasound Obstet Gynecol. 2002;20:332–9.
3. Van Mieghem T, Gucciardo L, Lewi P, et al. Validation of the fetal myocardial performance index in the second and third trimesters of gestation. Ultrasound Obstet Gynecol. 2009;33:58–63.
4. Cruz-Martinez R, Figueras F, Bennasar M, et al. Normal reference ranges from 11 to 41 weeks' gestation of fetal left modified myocardial performance index by conventional Doppler with the use of stringent criteria for delimitation of the time periods. Fetal Diagn Ther. 2012;32:79–86.
5. Hernandez-Andrade E, Lopez-Tenorio J, Figueroa-Diesel H, et al. A modified myocardial performance (Tei) index based on the use of valve clicks improves reproducibility of fetal left cardiac function assessment. Ultrasound Obstet Gynecol. 2005;26:227–32.
6. Meriki N, Welsh AW. Development of Australian reference ranges for the left fetal modified myocardial performance index and the influence of caliper location on time interval measurement. Fetal Diagn Ther. 2012;32:87–95.
7. Gardiner HM. Foetal cardiac function: assessing new technologies. Cardiol Young. 2014;24(Suppl 2):26–35.
8. Miyatake K, Yamagishi M, Tanaka N, et al. New method for evaluating left ventricular wall motion by color-coded tissue Doppler imaging: in vitro and in vivo studies. J Am Coll Cardiol. 1995;25:717–24.
9. Ho CY, Solomon SD. A clinician's guide to tissue Doppler imaging. Circulation. 2006;113:e396–8.
10. Wang M, Yip G, Yu CM, et al. Independent and incremental prognostic value of early mitral annulus velocity in patients with impaired left ventricular systolic function. J Am Coll Cardiol. 2005;45:272–7.
11. Hillis GS, Moller JE, Pellikka PA, et al. Noninvasive estimation of left ventricular filling pressure by E/e' is a powerful predictor of survival after acute myocardial infarction. J Am Coll Cardiol. 2004;43:360–7.
12. Garcia MJ, Rodriguez L, Ares M, et al. Differentiation of constrictive pericarditis from restrictive cardiomyopathy: assessment of left ventricular diastolic velocities in longitudinal axis by Doppler tissue imaging. J Am Coll Cardiol. 1996;27:108–14.
13. Paladini D, Lamberti A, Teodoro A, et al. Tissue Doppler imaging of the fetal heart. Ultrasound Obstet Gynecol. 2000;16:530–5.
14. Comas M, Crispi F, Gomez O, et al. Gestational age- and estimated fetal weight-adjusted reference ranges for myocardial tissue Doppler indices at 24-41 weeks' gestation. Ultrasound Obstet Gynecol. 2011;37:57–64.
15. Elmstedt NN, Johnson JJ, Lind BB, et al. Reference values for fetal tissue velocity imaging and a new approach to evaluate fetal myocardial function. Cardiovasc. Ultrasound. 2013;11:29.
16. Herling L, Johnson J, Ferm-Widlund K, et al. Automated analysis of color tissue Doppler velocity recordings of the fetal myocardium using a new algorithm. Cardiovasc. Ultrasound. 2015;13:39.
17. Larsen LU, Sloth E, Petersen OB, et al. Systolic myocardial velocity alterations in the growth-restricted fetus with cerebroplacental redistribution. Ultrasound Obstet Gynecol. 2009;34:62–7.
18. Saini AP, Ural S, Pauliks LB. Quantitation of fetal heart function with tissue Doppler velocity imaging-reference

values for color tissue Doppler velocities and comparison with pulsed wave tissue Doppler velocities. Artif Organs. 2014;38:87–91.

19. Willruth, A.M., J. Steinhard, C. Enzensberger, et al. Color Tissue Doppler to Analyze Fetal Cardiac Time Intervals: Normal Values and Influence of Sample Gate Size. Ultraschall Med. 2016.
20. Comas M, Crispi F. Assessment of fetal cardiac function using tissue Doppler techniques. Fetal Diagn Ther. 2012;32:30–8.
21. Van Mieghem T, Klaritsch P, Done E, et al. Assessment of fetal cardiac function before and after therapy for twin-to-twin transfusion syndrome. Am J Obstet Gynecol. 2009;200(400):e1–7.
22. Hernandez-Andrade E, Benavides-Serralde JA, Cruz-Martinez R, et al. Evaluation of conventional Doppler fetal cardiac function parameters: E/A ratios, outflow tracts, and myocardial performance index. Fetal Diagn Ther. 2012;32:22–9.
23. Welsh AW, Maheshwari P, Wang J, et al. Evaluation of an automated fetal myocardial performance index. Ultrasound Obstet Gynecol. 2016;48:496–503.
24. Lee MY, Won HS, Park JE, et al. Fetal left modified myocardial performance index measured by the Auto Mod-MPI system: development of reference values and application to recipients of twin-to-twin transfusion syndrome. Prenat Diagn. 2016;36:424–31.
25. Kim SH, Miyakoshi K, Kadohira I, et al. Comparison of the right and left ventricular performance during the fetal development using velocity vector imaging. Early Hum. Dev. 2013;89:675–81.
26. Uittenbogaard LB, Haak MC, Spreeuwenberg MD, et al. Fetal cardiac function assessed with four-dimensional ultrasound imaging using spatiotemporal image correlation. Ultrasound Obstet Gynecol. 2009;33:272–81.
27. Maheshwari, P., J. Alphonse, A. Henry, et al. Beat-to-beat variability of the fetal myocardial performance index (MPI). Ultrasound Obstet Gynecol. 2016.
28. Hollis B, Mavrides E, Campbell S, et al. Reproducibility and repeatability of transabdominal uterine artery Doppler velocimetry between 10 and 14 weeks of gestation. Ultrasound Obstet Gynecol. 2001;18:593–7.
29. Papageorghiou AT, To MS, Yu CK, et al. Repeatability of measurement of uterine artery pulsatility index using transvaginal color Doppler. Ultrasound Obstet Gynecol. 2001;18:456–9.
30. Wohlmuth C, Gardiner HM, Diehl W, et al. Fetal cardiovascular hemodynamics in twin–twin transfusion syndrome. Acta Obstet Gynecol Scand. 2016;95:664–71.
31. Moon-Grady AJ. Fetal echocardiography in twin–twin transfusion syndrome. Am J Perinatol. 2014;31(Suppl 1):S31–8.
32. Stirnemann JJ, Mougeot M, Proulx F, et al. Profiling fetal cardiac function in twin–twin transfusion syndrome. Ultrasound Obstet Gynecol. 2010;35:19–27.
33. Raboisson MJ, Fouron JC, Lamoureux J, et al. Early intertwin differences in myocardial performance during the twin-to-twin transfusion syndrome. Circulation. 2004;110:3043–8.
34. Rychik J, Zeng S, Bebbington M, et al. Speckle tracking-derived myocardial tissue deformation imaging in twin–twin transfusion syndrome: differences in strain and strain rate between donor and recipient twins. Fetal Diagn Ther. 2012;32:131–7.
35. Van Mieghem T, Giusca S, DeKoninck P, et al. Prospective assessment of fetal cardiac function with speckle tracking in healthy fetuses and recipient fetuses of twin-to-twin transfusion syndrome. J Am Soc Echocardiogr. 2010;23:301–8.



CHAPTER VIII

General discussion



Introduction

The unique placental angioarchitecture in monochorionic twin pregnancies carries a high risk for adverse pregnancy outcome. Disproportionate distribution of placental mass may result in selective intrauterine growth restriction (sIUGR), and unbalanced intertwin transfusion across the intertwin anastomoses causes twin to twin transfusion syndrome (TTTS). These conditions are known to result in unique changes in the hemodynamic balance in these fetuses, compared to singletons. Important complications which contribute significantly to the unfavorable outcome of the pregnancies are fetal demise and right ventricular outflow tract obstruction (RVOTO).

The prediction of fetal demise and the development of postnatal RVOTO is still challenging, but would be helpful in counseling, the planning of follow-up visits and the development of innovative treatment options of TTTS and sIUGR. The general aim of the studies presented in this thesis was to gain more knowledge about hemodynamic adaptation of the fetal heart in complicated monochorionic twin pregnancies, in order to understand the pathways of abnormal cardiac development and fetal demise under these circumstances, which eventually could lead to better future care.

Part one – fetal demise

Twin-to-twin transfusion syndrome

A seemingly straightforward laser surgery ending in fetal demise of one or both twins is a frustrating matter for both parents and fetal surgeons. Earlier reports showed that abnormal flows in the ductus venosus and umbilical artery in TTTS are associated with this complication of laser therapy and our data confirm these findings (***chapter 2 and 3***). Besides that, the data in our retrospective cohort show that the presence of an AA anastomosis for donors, and the absence of a compensating recipient-to-donor anastomosis for the recipient, increase the risk for unexpected fetal demise after laser therapy ***(chapter 3)***. Our study is the first attempt to investigate the type of anastomoses in relation to fetal demise in TTTS.

The question raises how anastomoses influence mortality rates in TTTS. It has been hypothesized before that the combination of type and size of anastomoses determine the grade of acute hemodynamic changes during and directly after laser therapy. The

coagulation of placental anastomoses causes acute volume changes in the intertwin circulation, which has an immediate impact on cardiac preload in the recipient and afterload in the donor, which demands an instant cardiac adaptation of in both fetusses. A suggested way to minimize this acute change is reducing the immediate hemodynamic challenge by sequential selective laser therapy, whereby anastomoses are coagulated in a specific order, by starting with the coagulation of the largest donor-to-recipient arteriovenous anastomoses followed by the smaller ones and after these the occlusion of the recipient-to-donor arteriovenous anastomoses. Finally, if present, the arterioarterial and the venovenous anastomoses will be coagulated. It is hypothesized that intraoperative correction of the hypoperfusion of the donor and hyperperfusion of the recipient is achieved in the time interval between the sites of coagulation and will reduce mortality. A meta-analysis of three small non-randomized studies suggests an improved fetal survival from 88% to 92% using this technique, but a large randomised trial is lacking.[1-4] On one hand, the data in our study support the approach of sequential laser therapy, because it could be hypothesized that occlusion of a AA-anastomosis early in surgery magnifies the hemodynamic forces in the other anastomoses and for that, increase the risk for fetal demise. On the other hand, it is questionable if sudden hemodynamic changes during laser therapy can be avoided at a sufficient magnitude by a different order of occlusion because all anastomoses are usually coagulated within a short time period.

Another suggested way to improve fetal survival after laser therapy is medical stabilization of fetal circulation before laser coagulation, to decrease the vulnerability to acute preload and afterload changes when the intertwin anastomoses are coagulated. A matched case control study in 141 cases explored transplacental treatment with nifedipine 24-48 hours prior to laser therapy and showed an increased survival of the recipient twin, but the donor survival showed no difference.[5] Nifedipine is a type 2 calcium channel blocker of which the primarily effect is vasodilatation and is widely used for treatment of hypertension in pregnant woman. It crosses the placenta and achieves serum levels in the fetus.[6] The hypothesis is that the vasodilatation decreases the hemodynamic forces (increased cardiac preload) on forehand and lowers the impact of sudden hemodynamic changes during laser coagulation. In this way, the pre-laser impact of the absence of a compensating recipient-to-donor anastomosis for the recipient is less prominent, which makes the acute hemodynamic change less challenging during and after intervention. For donors, the potential effect of pre-laser

vasodilatation is debated and could have the opposite effect because of the decrease in preload in an already hypovolemic fetus. The above-mentioned study did not show that, and we hypothesize a possible protective effect in cases of the presences of an AA anastomosis. If TTTS develops in the presence of an AA anastomosis it may act as a strong unidirectional shunt.[7] Vasodilatation may reduce the flow across this shunt before the laser surgery. In this way it may lower the risk for the donor, as our study found an increased risk for demises in donors in case of the presence of an AA anastomosis in TTTS. A multi-center randomised controlled trial is the next step to confirm the case control study[5] and explore out hypothesis that it might even be beneficial for donors.

Alternatively to calcium channel blockers, positive inotropic medical treatment could be considered to optimize fetal myocardial contraction around laser therapy, for example with digoxin. Pre-laser the hypovolemic donor will benefit from increased cardiac contractility. The recipient faces sudden decreased preload after laser surgery and those that show cardiomyopathy might benefit from increased contractile force achieved by medical treatment. The long loading time of digoxine, however, makes this experiment difficult to explore.

Proximate cord insertion

A second topic addressed in this thesis is the presence of intermittent absent and reversed end-diastolic flow in the umbilical artery (iAREDF) in ***uncomplicated*** monochorionic pregnancies with proximate cord insertion (PCI) (***chapter 4***). We are the first to describe the pathophysiological mechanism behind this phenomenon and the possible association with fetal deterioration. Our data show that iAREDF occurs in 64% of cases with PCI and is related to the diameter of the AA-anastomosis. Our data suggest that iAREDF in PCI pregnancies is a possible risk factor for fetal deterioration and demise. No other reports studying the relationship of iAREDF and PCI are available. PCI is, however, seen in 53% of monochorionic mono***amniotic*** pregnancies,[8] and pathophysiology of fetal demise in PCI in monoamniotic and diamniotic twin pregnancies might be partly comparable. In monoamniotic pregnancies, unexpected fetal demise is a well-known risk and is mostly attributed to cord entanglement. Cord entanglement is, however, not always found in these cases after birth. It was hypothesized by Lewi[9] that other causes, such as acute exsanguination across large caliber anastomoses, which are often present between the cord insertions, may be

an explanation for unexpected demise as well. The findings in our study in cases with proximate cord insertions with large anastomoses might be explained in a similar way.

It is currently unknown whether fetal outcome in PCI-diamniotic pregnancies can be improved by altered management. Our study raises the question if, and (if so) at which gestational age intensified fetal monitoring should be pursued in PCI pregnancies. Firstly, the findings in this study suggest that awareness of the combination of iAREDF and PCI could be relevant in daily clinical practice. PCI is currently not considered as a risk factor for sudden demise and is therefore not investigated and documented in (uncomplicated) MCDA pregnancies. The still existing unexpected fetal death in MCDA pregnancies could possibly be explained by the presence of PCI. We therefore suggest to record PCI in all MCDA pregnancies. Secondly, this study suggests that increased fetal surveillance might be helpful in known PCI cases. The effect of intensified ultrasound examination, whether or not in combination with intensified fetal monitoring using fetal cardiotocography, is still unclear. Hypothetically these monitoring interventions might detect fetal distress timely, and therewith prevent further deterioration. On the other hand, the only available treatment is delivery, which will occur preterm in most of these cases. Whether or not the benefit of preterm delivery outweighs the possible complications of prematurity is unknown. Besides that, intensive monitoring will increase fear in patients or might lead to long hospital admissions which brings additional costs. Better understanding of the magnitude of this clinical finding should be achieved by a multicenter registry study, followed eventually by a randomized controlled trial that compares different approaches of fetal monitoring and intervention options in PCI cases.

Part two – cardiac compromise

Part two of this thesis determines the incidence of postnatal right ventricular outflow tract obstruction (RVOTO) to be 6.7% in recipient twins, of which 2.9% need balloon valvuloplasty in the neonatal period ***(chapter 6)***. Our large cohort enabled us to describe the spectrum of prenatal RVOTO and following development to postnatal RVOTO, which can be an aid in future care and counseling.

Prediction and follow-up of RVOTO in complicated monochorionic pregnancies

Firstly, we constructed a prediction model for development of postnatal RVOTO in TTTS recipients. As predictors we found pericardial effusion, abnormal flow in ductus venosus and early gestational age at TTTS onset ***(chapter 5)***. Although it is important to realize that mild RVOTO can develop weeks after laser therapy or even in de neonatal period, neonates with severe postnatal RVOTO (defined as the need for neonatal surgical intervention) all showed prenatal RVOTO at TTTS diagnosis ***(chapter 6)***.

Pericardial effusion and abnormal flow in the ductus venosus are well known alterations in severe TTTS cases (Quintero stage III and IV). Both are reflections of cardiac compromise in TTTS. Pericardial effusion is included in the criteria for hydrops, and an earlier report showed that up to one third of hydropic recipients develop postnatal cardiac abnormalities including RVOTO.[10] Laser therapy often improves cardiac function, and is recommended in severe TTTS.[11-13]

The association of postnatal RVOTO with an early gestational age at TTTS diagnosis is a new and important finding. We propose that this is related to the fact that early in the second trimester semilunar valve maturation is not complete.[14] Therefore these cardiac valves might be more susceptible to hemodynamic imbalances leading to RVOTO. In these circumstances endothelial damage, caused by hypertension and accelerated by circulating vasoactive mediators, eventually leads to valve dysplasia and pulmonary stenosis.

A longer period of exposure to the hemodynamic challenges in TTTS could facilitate the development of valve dysplasia and could increase the risk for postnatal RVOTO, especially in early gestational age. This hypothesis is supported by the new finding that postnatal RVOTO occurs equally in all Quintero stages and was also found in cases with Quintero stage I with expectant management ***(chapter 6***). This finding raises the question if abnormal flows in the right ventricular outflow tract could be a reason to initiate laser treatment to prevent postnatal RVOTO in prolonged Q1 TTTS. However, the current risk of complications for laser surgery, such as fetal demise of donor (17%) or recipient (13%) ***(chapter 2),*** immature birth (4,5%) ***(chapter 3)***, premature preterm rupture of membranes (40%)[15,16] and following preterm birth[15] are still much higher than the risk for severe postnatal RVOTO. Besides that, treatment of postnatal RVOTO is more difficult in small, premature infants than in term infants, which makes

iatrogenic preterm birth by laser intervention even more unfavorable in these cases.[17] For these reasons, we do not recommend laser treatment in these cases solely to prevent postnatal RVOTO.

Awareness of development of postnatal RVOTO is, however, recommended. As mentioned above, neonates with postnatal RVOTO might need balloon valvuloplasty in the newborn period and will benefit by a delivery in a center with pediatric cardiology services to ensure timely cardiac intervention. Laser treatment is worldwide centered in specialized centers for fetal therapy, and after treatment, patients are often referred back to their local hospitals with sometimes large travel distances to centers with specialized cardiac neonatal care.

We recommend that fetuses with a combination of pericardial effusion, early gestational age at TTTS diagnosis, abnormal flow in DV and even expectant management in Q1-TTTS, should receive echocardiographic follow-up in a specialized center to estimate the risk for postnatal RVOTO. In the spectrum of antenatal RVOTO, we found that cases with elevated peak systolic velocity across the pulmonary valve have a higher risk for developing postnatal RVOTO than cases with isolated pulmonary insufficiency or functional pulmonary atresia ***(chapter 6)***. This might be explained by the hypothesis that pulmonary insufficiency and atresia is mostly a functional expression of cardiac dysfunction due to the volume overload in TTTS-recipients, which restores after successful laser treatment. On the opposite, elevated peak systolic velocity across the valve occurs when dysplasia results in valvular stenosis. In that way, elevated peak systolic flow reflects anatomical changes of the valve, which is less likely to fully recover after laser treatment.

These findings could be an aid in clinical decision making concerning TTTS treatment, as well as counseling and the planning of follow-up visits of patients with high risk for development of postnatal RVOTO. Firstly, functional pulmonary atresia is a very impressive ultrasonographic finding which might lead to the suspicion of long-term cardiac disease or the end-stage of cardiac failure. Consequently this might steer clinical decision making towards the consideration of selective cord coagulation of the RVOTO twin, instead of the usual laser treatment. Our study shows that this ultrasonographic finding is often reversible after successful laser therapy, and for that, common treatment with laser coagulation of the intertwin anastomosis is highly recommended.

Secondly, elevated peak systolic velocity across the PV is a more subtle ultrasonographic finding, but carries a higher risk for development of postnatal RVOTO. For that, cases with elevate peak systolic velocity across the PV should be advised to deliver in a center with pediatric cardiology services to ensure proper neonatal care and the availability of cardiac intervention in severe cases. Cases with isolated pulmonary insufficiency or functional pulmonary atresia eventually could deliver in their local centers, if improvement of cardiac function is confirmed with prenatal follow-up scans.

An additional new finding is that RVOTO may develop in TTTS donors and the large twins of sIUGR-cases (chapter 5)**.** As described above, donors face an acute cardiac challenge after laser therapy as well. When intertwin anastomoses are coagulated, a transition from pre-laser hypovolemia to sudden increased afterload has to be endured. Although pre-laser recipients face an increased preload and post-laser donors an increased afterload, the ultrasonographic (transient) cardiac findings are comparable. Earlier reports describe an abnormal ductus venosus, tricuspid valve insufficiency and even hydrops in up to 25% of donors after lasercoagulation.[18-20] In addition to this, the donors in our study did not show any signs of cardiac dysfunction pre-laser, and developed RVOTO after a transient period of hydrops directly following laser treatment ***(chapter 5)***. We postulate that a period of acute shear stress after laser treatment could lead to endothelial damage and eventually valvular dysplasia in these circumstances, and in that way increase the risk for postnatal RVOT, comparable to recipients.

The large twin in sIUGR-cases do not face such event of sudden hemodynamic challenge and exact pathophysiology of development of RVOTO remains unknown. We speculate that large arterioarterial anastomoses, present in 98% of sIUGR cases, combined with a large placental mass in the early stages of pregnancy may cause disturbances in intracardiac flow, which might cause cardiac dysfunction. The hypertrophic cardiomyopathy-like changes that have been found in the larger twin of sIUGR cases with large arterioarterial anastomoses support this hypothesis.[21] Again the pathophysiology might find its origin in the endothelial damage caused by disturbed flows, which causes stenosis in the pulmonary valve. A longer duration of abnormal flow exposure might facilitate the development of postnatal RVOTO, as described above in Q1 cases TTTS with expectant management. Since there is no treatment for sIUGR, fetuses are exposed to these factors for a significant period. Due

to a low number of cases factors associated with development of postnatal RVOTO could not be investigated. We recommend awareness of cardiac changes such as pericardial effusion and RVOTO in the larger twin in case of severe sIUGR, especially when sIUGR was present from early second trimester.

Color-coded tissue Doppler imaging (cTDI) in fetal echocardiography

Innovative cardiac function measurements such a cTDI are increasingly used and proven valuable in the prediction of outcome in adult cardiac disease. In fetal echocardiography, a simple quantitative measurement of cardiac function that predicts cardiac compromise in high-risk fetuses, is needed. In current practice, MPI is considered a consistent cardiac marker to detect early chronic hypoxia or cardiac overload.[22] Pulsed-wave Doppler derived MPI recordings are, however, difficult to obtain and right MPI can only be calculated from two separate recordings which affects feasibility and reproducibility. This makes it less suitable for usage in daily practice.

In ***chapter 7*** we investigate cTDi in fetal echocardiography, and introduce a new modality to assess fetal cardiac function by the measurement of cardiac time intervals using this technique. Measurement of shortening time and lengthening time of the myocardial wall are applied in a four-chamber view. The recordings are therefor easy to obtain and potentially useful for daily practice. In a study in healthy singletons and TTTS recipients we demonstrated that this modality is technically feasible with good reproducibility, even in difficult scanning circumstances such as TTTS. It discriminates between healthy and compromised fetuses. One other study confirms that measurement of time intervals using cTDI can be analyzed with a high accuracy.[23] However, since our study is the first to evaluate shortening and lengthening time intervals with this modality, larger studies are needed to confirm our findings. Even more important, the predictive value of this new approach to assess fetal cardiac function should be investigated in different study populations of fetuses in challenging circumstances. Although future use of this new modality seems promising, implementation will be dependent on a wider range of pregnancy complications and the development of automatic analysis of the retrieved signal.

Future perspective and conclusion

The studies presented in this thesis show that the hemodynamic challenges of the placental angioarchitecture in monochorionic twin pregnancies play a crucial role in the mortality rate and cardiac outcome of these twins. Although diagnostic tools and fetal interventions have improved the outcome of these pregnancies tremendously in the past decades, there is room for improvement.

Future perspective

To increase survival rates in TTTS, future research should focus on the possible benefit of individualized treatment for these fetuses, such as specific sequential laser therapy whether or not in combination with presurgical medical stabilization of hemodynamic forces. Ideally, the number and size of intertwin anastomoses should be visualized before surgery with innovative techniques such as 3D-mapping, in order to detect high-risk placental angioarchitecture. In this way, not only the introduction site for the fetoscope can be optimized, but the sequential laser order can be determined on beforehand. This will shorten the operation time which reduces rate of rupture of membranes. Besides that, different types of medication could be considered to achieve medical stabilization around laser therapy. The challenge herein is that medication that might be beneficial to the recipient might not be beneficial to the donor and the other way around. Additionally, hemodynamic forces change directly after laser therapy for both fetuses, which will result in different needs for each fetus.

Conclusion

The overall conclusion of the studies presented in this thesis is that individualized care could further improve fetal outcome in monochorionic pregnancies. New insights into risk factors for fetal deterioration, such as the presence of PCI or the presence/absence of certain anastomosis in TTTS, identifies relatively small groups of vulnerable fetuses. This gives the opportunity to develop a more individual approach in follow-up or treatment in these cases, which might lower the risk for fetal demise or development of RVOTO even further.

References

1. Akkermans J, Peeters SH, Klumper FJ, Middeldorp JM, Lopriore E, Oepkes D. Is the Sequential Laser Technique for Twin-to-Twin Transfusion Syndrome Truly Superior to the Standard Selective Technique? A Meta-Analysis. *Fetal Diagn Ther.* 2015;37(4):251-258.
2. Chmait RH, Khan A, Benirschke K, Miller D, Korst LM, Goodwin TM. Perinatal survival following preferential sequential selective laser surgery for twin-twin transfusion syndrome. *J Matern Fetal Neonatal Med.* 2010;23(1):10-16.
3. Nakata M, Murakoshi T, Sago H, et al. Modified sequential laser photocoagulation of placental communicating vessels for twin-twin transfusion syndrome to prevent fetal demise of the donor twin. *J Obstet Gynaecol Res.* 2009;35(4):640-647.
4. Quintero RA, Ishii K, Chmait RH, Bornick PW, Allen MH, Kontopoulos EV. Sequential selective laser photocoagulation of communicating vessels in twin-twin transfusion syndrome. *J Matern Fetal Neonatal Med.* 2007;20(10):763-768.
5. Crombleholme TM, Lim FY, Habli M, et al. Improved recipient survival with maternal nifedipine in twin-twin transfusion syndrome complicated by TTTS cardiomyopathy undergoing selective fetoscopic laser photocoagulation. *Am J Obstet Gynecol.* 2010;203(4):397 e391-399.
6. King JF, Flenady V, Papatsonis D, Dekker G, Carbonne B. Calcium channel blockers for inhibiting preterm labour; a systematic review of the evidence and a protocol for administration of nifedipine. *Aust N Z J Obstet Gynaecol.* 2003;43(3):192-198.
7. Murakoshi T, Quintero RA, Bornick PW, Allen MH. In vivo endoscopic assessment of arterioarterial anastomoses: insight into their hemodynamic function. *J Matern Fetal Neonatal Med.* 2003;14(4):247-255.
8. Zhao DP, Peeters SH, Middeldorp JM, et al. Monochorionic placentas with proximate umbilical cord insertions: definition, prevalence and angio-architecture. *Placenta.* 2015;36(2):221-225.
9. Lewi L. Cord entanglement in monoamniotic twins: does it really matter? *Ultrasound Obstet Gynecol.* 2010;35(2):139-141.
10. Gray PH, Ward C, Chan FY. Cardiac outcomes of hydrops as a result of twin-twin transfusion syndrome treated with laser surgery. *J Paediatr Child Health.* 2009;45(1-2):48-52.
11. Barrea C, Hornberger LK, Alkazaleh F, et al. Impact of selective laser ablation of placental anastomoses on the cardiovascular pathology of the recipient twin in severe twin-twin transfusion syndrome. *Am J Obstet Gynecol.* 2006;195(5):1388-1395.
12. Herberg U, Gross W, Bartmann P, Banek CS, Hecher K, Breuer J. Long term cardiac follow up of severe twin to twin transfusion syndrome after intrauterine laser coagulation. *Heart.* 2006;92(1):95-100.
13. Sueters M, Middeldorp JM, Vandenbussche FP, et al. The effect of fetoscopic laser therapy on fetal cardiac size in twin-twin transfusion syndrome. *Ultrasound Obstet Gynecol.* 2008;31(2):158-163.
14. Monaghan MG, Linneweh M, Liebscher S, Van Handel B, Layland SL, Schenke-Layland K. Endocardial-to-mesenchymal transformation and mesenchymal cell colonization at the onset of human cardiac valve development. *Development.* 2016;143(3):473-482.

15. Snowise S, Mann LK, Moise KJ, Jr., Johnson A, Bebbington MW, Papanna R. Preterm prelabor rupture of membranes after fetoscopic laser surgery for twin-twin transfusion syndrome. *Ultrasound Obstet Gynecol.* 2017;49(5):607-611.
16. Stirnemann J, Djaafri F, Kim A, et al. Preterm premature rupture of membranes is a collateral effect of improvement in perinatal outcomes following fetoscopic coagulation of chorionic vessels for twin-twin transfusion syndrome: a retrospective observational study of 1092 cases. *BJOG.* 2018;125(9):1154-1162.
17. Rigby ML. Severe aortic or pulmonary valve stenosis in premature infants. *Early Hum Dev.* 2012;88(5):291-294.
18. Degenhardt J, Reinold M, Enzensberger C, et al. Short-Time Impact of Laser Ablation of Placental Anastomoses on Myocardial Function in Monochorionic Twins with Twin-to-Twin Transfusion Syndrome. *Ultraschall Med.* 2017;38(4):403-410.
19. Gratacos E, Van Schoubroeck D, Carreras E, et al. Impact of laser coagulation in severe twin-twin transfusion syndrome on fetal Doppler indices and venous blood flow volume. *Ultrasound Obstet Gynecol.* 2002;20(2):125-130.
20. Mineo E, Honda T, Ishii M. Right ventricular failure with high echoic ventricular wall change after foetoscopic laser photocoagulation: a case report of a donor in twin-to-twin transfusion syndrome. *Cardiol Young.* 2016;26(1):155-157.
21. Munoz-Abellana B, Hernandez-Andrade E, Figueroa-Diesel H, et al. Hypertrophic cardiomyopathy-like changes in monochorionic twin pregnancies with selective intrauterine growth restriction and intermittent absent/reversed end-diastolic flow in the umbilical artery. *Ultrasound Obstet Gynecol.* 2007;30(7):977-982.
22. Willruth AM, Steinhard J, Enzensberger C, et al. Color Tissue Doppler to Analyze Fetal Cardiac Time Intervals: Normal Values and Influence of Sample Gate Size. *Ultraschall Med.* 2018;39(1):56-68.
23. Hernandez-Andrade E, Benavides-Serralde JA, Cruz-Martinez R, Welsh A, Mancilla-Ramirez J. Evaluation of conventional Doppler fetal cardiac function parameters: E/A ratios, outflow tracts, and myocardial performance index. *Fetal Diagn Ther.* 2012;32(1-2):22-29.



CHAPTER IX

Summary

Nederlands Samenvatting



Summary

Monochorionic twin pregnancies carry a high risk for adverse pregnancy outcome. The unique placenta angioarchitecture with the shared blood circulation might cause specific complications such as twin tot twin transfusion syndrome (TTTS) or selective intrauterine growth restriction (sIUGR). The hemodynamic challenges in these complications require specific adaptation of the fetal heart. Subsequently, a higher risk for fetal demise and acquired cardiac abnormalities is present in these cases.

The general aim of the studies presented in this thesis was to gain more knowledge about hemodynamic adaptation of the fetal heart in complicated monochorionic twin pregnancies, in order to understand more of the pathways of abnormal cardiac development and fetal demise under these circumstances, which eventually could lead to better future care.

Part one - Fetal demise

In the first part of this thesis, we focused on the risk for fetal demise in complicated MCDA pregnancies. If left untreated, the perinatal mortality in TTTS is over 90%. Fetoscopic laser therapy of placental anastomoses significantly improves the overall survival rate to ≈ 70% and to > 85% for at least one surviving fetus.

Several studies have been performed in order to predict fetal demise after fetoscopic laser treatment for TTTS. In **chapter 2** we performed a systematic review and meta-analysis to compare pre-operative ultrasonographic parameters between fetuses with and without fetal demise after laser surgery. After assessment of study quality, a total of eighteen studies were included. Donors were at higher risk for fetal demise (23%) than recipients (17%). The risk for fetal demise was highest within 24 hours after laser therapy (52% and 42% of the total demises respectively), and the majority of fetal demise occurred within one week after laser therapy (74% and 88% of the total demises respectively). Mortality rates declined from 29% for donors and 21% for recipients in the early years of fetoscopic laser coagulation, to 19% and 13% in the last decade.

For both donor and recipient, preoperative absent/reversed end diastolic flow in the umbilical artery and an absent or reversed a-wave in the ductus venosus were associated with fetal demise. These flows are classified as Quintero stage 3. Additionally, increased velocity in the median cerebral artery (MCA) is associated with

fetal demise in recipients as well. The mechanisms leading to abnormal flow velocity waveforms are different in donors and recipients. For donors, we speculated that the abnormal flows reflect both placental insufficiency and fetal hypotension secondary to the TTTS. For recipients, the mechanism leading to abnormal flows is different. It is suggested that poor myocardial contractility as a result of hypervolemia and cardiac overload causes abnormal flows in the umbilical artery and ductus venosus. The increased velocity in the MCA might be the reflection of the hypervolemic status of the recipient. Another suggested explanation for the MCA flows in recipients is that decreased fetal oxygenation due to placental interstitial edema causes this elevated velocity in the MCA. In conclusion, abnormal Dopplers reflect an unstable circulation which increase the risk for fetal demise for both donors and recipients.

Data on myocardial function were only available in seven studies. Meta-analysis could only be performed for atrioventricular regurgitation, and turned out to be not associated with a higher risk for fetal demise. An association between preoperative MPI and fetal demise of the donor was not found. For recipients data were conflicting: 2 studies found a possible correlation between elevated MPI and recipient demise, 3 did not. We concluded that the utility of preoperative parameters that reflect cardiac function in predicting IUFD remains unclear.

In **chapter 3** we investigated possible predictors of single fetal demise after laser treatment in our national referral center for TTTS in a retrospective cohort of 273 pregnancies. Overall fetal survival was 84%. Single fetal demise occurred in 11% of donors and 10% of recipients, of which 67% occurred within 7 days after laser therapy. For donors, absent/reversed end-diastolic flow in the umbilical artery was the strongest predictor, followed by the presence of an AA anastomoses and discordance in estimated fetal weight. In recipients, independent predictors were absent/reversed a-wave in the ductus venosus and the absence of recipient-to-donor arteriovenous anastomoses. In previous literature, the association between these abnormal blood flows and fetal demise is described several times before (see **chapter 2**). The classification of these FVWs are incorporated in the current staging system for TTTS (Quintero stage III).

The association of specific types of anastomosis and fetal demise is not studied before. We speculate that the type and size of anastomoses that are present, determines the degree of hemodynamic change during and directly after laser therapy. Although AA anastomoses are thought to equalize blood flow between fetuses and have a protective

effect against TTTS, we hypothesized that if this anastomosis is unable to prevent TTTS, it functions as a strong AV anastomosis. For that, it has a strong influence on the acute peri-and postoperative hemodynamic changes, which eventually increase the risk for fetal demise. However, currently there is no method to investigate the flow across the anastomoses. We recommend that future studies should focus on the role of different types and sizes of the placental anastomoses.

In general, monochorionic twin pregnancies carry a risk of fetal demise of 1%, even in the absence of complications such as TTTS or sIUGR. Still, the placental architecture is thought to play a role in these unexpected demises. In **chapter 4**, we studied the possible risk for fetal demise in case of otherwise uncomplicated MCDA pregnancies with proximate cord insertion (PCI). MCDA pregnancies with PCI often have a large AA anastomosis between the cord insertions. Large AA anastomosis are known to attribute to unstable haemodynamics between the two fetuses in MCDA twins with sIUGR, with the risk of sudden fetal demise of the smaller twin. In pregnancies with PCI, the risk for fetal deterioration is unknown. In our study we studied 11 pregnancies with PCI and 33 uncomplicated MCDA pregnancies without PCI. We confirmed that the diameter of the AA anastomosis was significantly larger in the PCI group. In the PCI group, 7 cases showed intermittent absent and reversed end diastolic flow in the umbilical artery, compared to none in the control group. In 4 cases, iAREDF was transient and pregnancy outcome was favorable. In 3 cases fetal deterioration occurred, followed by fetal demise in 2 cases and iatrogenic early preterm birth in the third case. We hypothesize that the vascular resistance in the AA diameter is lower in case of PCI, because of the larger diameter and shorter distance compared to cases without PCI. This could magnify a sudden exsanguination between fetuses and may increase the risk for fetal demise. Although strong conclusions cannot be made based on this small cohort, we recommend awareness for iAREDF in the presence of PCI. A large observational multicenter study is needed to evaluate the prevalence and pregnancy outcome of iAREDF in PCI, before specific management in these cases can be suggested.

Part two – Cardiac compromise

In part two, we investigated the cardiac consequences of complicated MCDA pregnancies. In the last decades, prenatal right ventricular outflow tract obstruction (RVOTO) is increasingly recognized in TTTS cases. Preoperative RVOTO often may disappear after laser treatment, however, in some cases it might worsen during

pregnancy and require surgery or catheter intervention in the newborn period or in early infancy. We focused on the understanding of the process leading to postnatal RVOTO, and investigated possible associated factors of the development of RVOTO.

No prediction model for development of postnatal RVOTO is available in current literature. In **chapter 5** we describe a retrospective observational cohort study of all monochorionic twins with postnatal diagnosis of RVOTO in our center (2004-2015). We aimed to evaluate pregnancy characteristics in order to determine factors that are associated with the development of postnatal RVOTO. We found a total of 485 pregnancies treated for TTTS, and postnatal RVOTO was diagnosed in 3% of recipients. We encountered postnatal RVOTO in one donor as well. Associated factors for RVOTO were early gestational age at TTTS diagnosis, absent or reversed a-wave in the ductus venosus and the presence of pericardial effusion. TTTS in these cases occurred at a mean of 17+3 weeks of gestation, compared to 20+3 weeks of gestation in controls. This finding suggests an increased vulnerability to hemodynamic imbalances in the young developing fetal heart. Absent or reversed a-wave in the ductus venosus and the presence of pericardial effusion are both a reflection of compromised cardiac function in the late stages of TTTS. We constructed a prediction model for postnatal RVOTO, incorporating these three variables and suggest to perform accurate follow-up in TTTS cases in case of presence of these variables.

Beside TTTS survivors, three larger twins in pregnancies complicated with selective intrauterine growth restriction developed postnatal RVOTO. In these cases the onset of RVOTO was detectable early in second trimester, confirming the finding in TTTS survivors that the young fetal heart is more vulnerable for development of postnatal RVOTO. In sIUGR, large AA anastomoses are typically present. We speculated that a large AA anastomosis, mainly in early stages of pregnancy, may cause disturbances in intracardiac flows leading to postnatal RVOTO. The prevalence of postnatal RVOTO in the large twin in sIUGR is a new finding, and awareness of cardiac changes in early and severe cases of sIUGR is recommended.

To assess the development and spectrum of RVOTO in recipients, we performed a prospective longitudinal study in 124 consecutive TTTS cases (2015-2017). The results are described in **chapter 6**. Three subgroups of ***prenatal*** RVOTO were identified. In the first group forward flow across the pulmonary valve was absent, with exclusive reverse direction of flow in the ductus arteriosus. This was classified as pulmonary atresia, which is often a functional pulmonary atresia. The second group showed

elevated peak systolic velocity of the pulmonary valve classified as pulmonary stenosis, and the third group showed isolated pulmonary insufficiency. Prenatal RVOTO was diagnosed in 12.9% of recipients at TTTS diagnosis. In another 5.6% of cases, prenatal RVOTO appeared only after laser therapy.

Postnatal RVOTO was found in 6.7% of surviving recipients, of which 70% showed prenatal RVOTO before laser therapy and 30% only after laser therapy. Notably, all recipients with severe postnatal RVOTO showed prenatal RVOTO at the time of TTTS diagnosis. The incidence of postnatal RVOTO found in this study is slightly higher than in prior large cohort studies, which can be explained by the systematic longitudinal follow-up of all recipients, which allowed us to detect mild and late-onset cases.

We evaluated the three subgroups of prenatal RVOTO. Cases with elevated peak systolic velocities across the pulmonary valve were more frequently associated with postnatal RVOTO compared to cases with prenatal 'pulmonary atresia'. We suggested that elevated peak systolic velocity is a result of valve dysplasia, which is an anatomical change of the valve and may be less favorable to be reversible after laser therapy. In contrast, pulmonary atresia is more often the result of impaired right ventricle function, which is likely to normalize when cardiac function is restored after laser therapy. Lastly, none of the cases with isolated pulmonary insufficiency developed postnatal RVOTO. We suggested that this may be a relatively mild functional finding in TTTS which is presumably reversible after laser therapy.

In this study, postnatal RVOTO was associated with early manifestation of TTTS, which confirms the finding in **chapter 5**. Although prenatal RVOTO was more frequently observed in advanced Quintero stages, postnatal RVOTO was equally found in all Quintero stages. We hypothesize that severe cardiac dysfunction leading to prenatal RVOTO is more frequently present in advanced stages of TTTS, while pulmonary valve dysplasia might occur equally in all Quintero stages. We suggested that valve dysplasia is facilitated by an early gestational age combined with a longer period of volume overload, shear stress and inter-twin transfusion of vasoactive mediators. The latter is illustrated by three cases in our cohort with expectant management in Quintero 1 that showed pulmonary stenosis. While TTTS improved completely in all cases, pulmonary stenosis was progressive in two cases with the need of balloon valvuloplasty in the neonatal period in one case.

To detect early cardiac compromise that might lead to RVOTO or fetal demise in TTTS,

a simple, stable quantitative measurement of cardiac function is needed. Currently, the myocardial performance index (MPI) is the most used method to assess fetal cardiac function. MPI is the ratio of isovolumetric cardiac time intervals to ejection cardiac time interval, and represents myocardial function. MPI recordings are, however, difficult to obtain and require considerable expertise of the operator, which hampers usage in daily practice. In **chapter 7** we introduce a new modality to detect fetal cardiac dysfunction. We measured the shortening time (St) and lengthening time (Lt) of the myocardial wall in three cardiac regions, using color-coded tissue Doppler imaging in the four chamber view of the fetal heart. We performed a prospective longitudinal cohort study in 54 healthy fetuses, performing a total of 251 recordings.

Firstly, we aimed to evaluate the applicability of this modality. We found a high feasibility (99.6%) and excellent intra-/interobserver variability for St and Lt of the global heart. Left and right ventricle test performance parameters were good. Therefore we considered this technique is easy to obtain in only an four chamber view with good reproducibility, and so potentially useful in daily practice in the future.

Secondly, we constructed age-adjusted reference ranges for the time intervals. St decreased and Lt increased with gestational age in all regions. We applied this technique to recipients in TTTS before laser therapy, to test the diagnostic performance in fetuses with cardiac compromise. The feasibility was excellent (96.6%). St was prolonged and Lt was shortened in all regions. These altered time intervals are comparable to the altered time intervals in abnormal MPI in recipients.

Based on the findings in this study, we concluded that the assessment of fetal cardiac function by measurement of cardiac time intervals is technically feasible with good reproducibility, even in difficult scanning circumstances such as TTTS. It is possible to discriminate between healthy and compromised fetuses with this technique. Further studies should, however, be performed to analyze the usage of this modality in treatment or prediction of fetal outcome in pathological pregnancies.

This thesis is finalized by **chapter 8**, which provides a general discussion and interpretation of the chapters described in this thesis. Secondly, a scope for future research in this research field is suggested.

In conclusion, this thesis provides studies that could be an aid in fetal clinical management and neonatal follow-up of twins in monochorionic pregnancies, and secondly, our data serve as a guide in prenatal counseling of the parents.

Samenvatting

Monochoriale tweelingzwangerschappen hebben een verhoogd risico op een ongunstige zwangerschapsuitkomst. De unieke samenstelling van de placentaire anastomosen en de (ongelijke) verdeling van het placentavolume over beide foetus kan complicaties zoals Tweeling Transfusie Syndroom (TTS) en selectieve intra-uteriene groeirestrictie (sIUGR) veroorzaken. De veranderde hemodynamica in deze complicaties vraagt een groot aanpassingsvermogen van het foetale hart, waardoor er een hoger risico bestaat op intra-uterien overlijden en het ontwikkelen van foetale hartafwijkingen.

Het doel van de studies beschreven in dit proefschrift was om meer kennis te verkrijgen over de hemodynamische aanpassingen van het foetale hart in gecompliceerde monochoriale diamniotische (MCDA) tweelingzwangerschappen. Op deze manier hopen we meer inzicht te verkrijgen over de verschillende manieren waarop hartafwijkingen ontstaan en bij welke foetussen een verhoogde kans is op intra-uteriene sterfte, waardoor de zorg voor MCDA zwangerschappen in de toekomst verbeterd kan worden.

Deel I – intra-uteriene vruchtdood

In het eerste deel van dit proefschrift ligt de focus op het onderzoeken van het risico op intra-uteriene vruchtdood (IUVD) in MCDA zwangerschappen. In onbehandelde TTS is de perinatale sterfte meer dan 90%. Door foetale lasertherapie, waarbij de placentaire anastomosen tussen beide foetus worden dicht gelaserd, verbetert de totale foetale overleving naar ongeveer 70% en de overleving van in elk geval één van beide foetus naar >85%.

Er zijn meerdere studies verricht naar de voorspellende factoren van IUVD na lasertherapie. In **hoofdstuk 2** beschreven wij een systematische review en meta-analyse waarin wij preoperatieve echografische parameters in foetussen met en zonder IUVD vergelijken. Na beoordeling van de kwaliteit van de studies werden 18 studies geïncludeerd. Donoren bleken een hoger risico te hebben op IUVD (23%) dan recipiënten (17%). Het risico op IUVD was het hoogst in de 24 uur na de lasertherapie (52% respectievelijk 42%) en de meerderheid vond plaats binnen een week na de lasertherapie (74% respectievelijk 88%). De foetale sterfte daalde van 29% voor donoren en 21% voor recipiënten in de beginjaren van deze behandeling, naar 19% respectievelijk 13% in het afgelopen decennium.

Voor zowel de donor als de recipiënt zijn een preoperatief afwezige of reversed eind diastolische flow over de arteria umbilicalis en een abnormale a-wave in de ductus venosus geassocieerd met IUVD. Deze afwijkende flows zijn geïncorporeerd in het huidige stadiëring systeem, en geclassificeerd als Quintero stadium 3. Daarnaast is een verhoogde snelheid in de arteria cerebri media (ACM) ook geassocieerd met IUVD in de recipiënt. De mechanismen die leiden tot abnormale flows verschillen in donoren in vergelijking tot recipiënten. Wij speculeerden dat de abnormale flows in donoren de placentaire insufficiëntie en hypotensie reflecteren, die op hun beurt het gevolg zijn van TTS. In recipiënten is dit mechanisme anders en wordt er gedacht dat een verminderde contractiliteit van het myocard, als gevolg van de hypovolemie en cardiale overbelasting in TTS, resulteert in abnormale flows in de arteria umbilicalis en ductus venosus. De verhoogde snelheid in de ACM zou een reflectie kunnen zijn van de hypervolemische status van de recipiënt. Een andere hypothese zou kunnen zijn dat de verminderde foetale oxygenatie, ontstaan door interstitieel oedeem van de placenta, deze verhoogde snelheid veroorzaakt. Concluderend reflecteren abnormale Doppler flows een instabiele circulatie die het risico op IUVD voor zowel donoren als recipiënten verhoogd.

Data over myocardfunctie waren slechts in zeven studies beschikbaar. Meta-analyse kon alleen verricht worden over atrioventriculaire insufficiëntie en dat was niet geassocieerd met een hoger risico op IUVD. Ook werd er geen relatie gevonden tussen myocardial performance index (MPI) en IUVD van de donor. Voor recipiënten was de data niet eenduidig: 2 studies beschrijven een mogelijke correlatie tussen een verhoogd MPI en IUVD, 3 studies vonden deze correlatie niet. Wij concludeerden dat de bruikbaarheid van preoperatieve hartfunctie parameters in de voorspelling van IUVD in TTS vooralsnog onduidelijk is.

In **hoofdstuk 3** beschreven wij een retrospectief cohortonderzoek van 273 zwangerschappen, welke werd verricht in ons nationale verwijscentrum voor foetale therapie. Wij onderzochten mogelijke voorspellende factoren voor IUVD van één van beide foetus. De totale foetale overleving in deze studie was 84%. IUVD vond plaats in 11% van de donoren en 10% van de recipiënten, waarvan 67% in de eerste 7 dagen na lasertherapie. In de groep donoren was afwezige of reversed eind diastolische flow in de arteria umbilicalis de sterkste voorspellende factor voor IUVD, gevolgd door de aanwezigheid van een arterio-arteriële anastomose (AA-anastomose) en het verschil in geschat foetaal gewicht van beide foetussen. In de groep recipiënten waren

onafhankelijke voorspellende factoren voor IUVD een abnormale a-wave in de ductus venosus en de afwezigheid van een arterioveneuze anastomose van recipiënt naar donor. De associatie tussen abnormale flows en IUVD is meerdere keren beschreven in eerdere literatuur (zie **hoofdstuk 2**).

De associatie tussen IUVD en de aan- of afwezigheid van specifieke anastomosen is niet eerder in de literatuur beschreven. Het is aannemelijk dat het type en de grootte van de aanwezige anastomosen op de placenta de mate van hemodynamische verandering tijdens en direct na de lasertherapie bepalen. Van AA-anastomosen wordt gedacht dat ze de bloedstromen tussen de foetussen stabiliseren en op die manier beschermen tegen de ontwikkeling van TTS. Wij hypothetiseren dat, als een AA-anastomose toch voorkomt in TTS, het zich gedraagt als een sterke arterioveneuze anastomose. Daardoor heeft het een sterke invloed op de acute peri- en postoperatieve hemodynamische schommelingen, wat het risico op IUVD kan verhogen. Op dit moment is er echter nog geen valide methode ontwikkeld om deze hypothese te onderzoeken. Toekomstig onderzoek zou zich meer kunnen richten op de rol van verschillende types en de grootte van de placentaire anastomosen in relatie tot IUVD.

Monochoriale tweelingzwangerschappen hebben een verhoogd risico van 1% op IUVD in afwezigheid van TTS of sIUGR. De unieke placentaire angioarchitectuur speelt waarschijnlijk een rol in deze onverwachte IUVD's maar de pathofysiologie is onbekend. In **hoofdstuk 4** hebben we het mogelijke risico op onverwachte vruchtdood onderzocht in monochoriale tweelingzwangerschappen waarbij de navelstrenginserties dicht naast elkaar op de placenta liggen, zogenoemd 'proximate cord insertion' (PCI). In monochoriale tweeling-zwangerschappen met PCI is bijna altijd een grote AA-anastomose aanwezig tussen de navelstrenginserties. Het is bekend dat grote AA-anastomosen bijdragen aan een instabiele hemodynamica tussen foetussen in zwangerschappen gecompliceerd met sIUGR, waardoor het risico op plotseling overlijden van de kleinste foetus is verhoogd. In zwangerschappen met PCI is het risico hierop niet bekend. In deze studie onderzochten we 11 PCI zwangerschappen en 33 ongecompliceerde zwangerschappen zonder PCI. Zoals bekend uit voorgaand onderzoek bevestigden wij dat de diameter van de AA-anastomose groter was in de PCI groep dan de controle groep. In de PCI groep vonden wij in 7 gevallen een intermitterend afwezige en/of reversed eind diastolische flow over de arteria umbilicalis, in de controle groep werd dit niet gevonden. In 4 van deze gevallen was deze

afwijkende flow van voorbijgaande aard en verliep de zwangerschap ongecompliceerd. In 3 van de gevallen ging de foetale conditie achteruit bij de foetus waar de afwijkende flow werd geconstateerd. In 2 gevallen trad IUVD op, en in het 3e geval werd er een vroeggeboorte geïnduceerd om dit te voorkomen. Onze hypothese is dat, gezien de grotere diameter en de kortere afstand tussen de navelstrenginserties, de weerstand in de AA-anastomose lager is in PCI zwangerschappen in vergelijking tot de controle zwangerschappen. Dit zou eventuele plotselinge veranderingen van hemodynamica tussen de foetussen kunnen versterken en daardoor het risico op IUVD vergroten. Gezien dit een klein cohortonderzoek betreft kunnen er geen absolute conclusies getrokken worden, danwel specifieke management opties aanbevolen worden. Wel raden wij aan om in gevallen van PCI bewust te zijn van de ontwikkeling van afwijkende flows in de arteria umbilicalis. Wij adviseren een groot observationeel multicenter onderzoek om de prevalentie en zwangerschapsuitkomsten in PCI zwangerschappen te evalueren.

Deel twee – cardiale aanpassing

In het tweede deel van dit proefschrift onderzochten we cardiale aanpassingen in gecompliceerde monochoriale tweelingzwangerschappen. In de laatste decennia wordt 'right ventricular outflow tract obstruction' (RVOTO) als gevolg van TTS steeds vaker prenataal ontdekt. Preoperatieve RVOTO kan voorbijgaan na lasertherapie, maar kan ook verergeren gedurende de zwangerschap waarbij dit operatief gecorrigeerd moet worden in de neonatale periode of in de jonge kindertijd. In dit proefschrift hebben we ons gericht op het leren begrijpen van de processen die leiden tot postnatale RVOTO, en we hebben mogelijk geassocieerde factoren voor het ontwikkelen hiervan onderzocht.

In de huidige literatuur was er geen predictiemodel beschikbaar voor de ontwikkeling van postnatale RVOTO. In **hoofdstuk 5** beschreven wij een retrospectief cohort van alle monochoriale tweelingzwangerschappen in ons centrum (2004-2015). Het doel was om de zwangerschapskarakteristieken van de casus met postnatale RVOTO te evalueren, om zo geassocieerde factoren voor de ontwikkeling hiervan te detecteren. In totaal vonden wij 485 zwangerschappen welke gecompliceerd waren met TTS, waarbij in 3% van de gevallen postnatale RVOTO werd gediagnosticeerd bij de recipiënt. Ook werd postnatale RVOTO vastgesteld in één van de donoren. Geassocieerde factoren met de ontwikkeling van RVOTO waren een vroege zwangerschapsduur bij

het ontstaan van TTS, een afwezige of reversed a-wave van de ductus venosus en de aanwezigheid van toegenomen pericardvocht. De gemiddelde zwangerschapsduur van vaststellen en behandeling van TTS in casus met RVOTO was 17 weken en 3 dagen, ten opzichte van 20 weken en 3 dagen van de groep zonder ontwikkeling van postnatale RVOTO. Deze bevinding suggereert een grotere kwetsbaarheid van het jonge foetale hart voor hemodynamische instabiliteit. Afwezige of reversed a-wave in de ductus venosus en de aanwezigheid van toegenomen pericardvocht reflecteren beiden cardiale aanpassingen in de latere stadia van TTS. We construeerden een predictiemodel voor postnatale RVOTO met deze drie factoren en stellen een accurate follow-up voor in zwangerschappen met TTS waarbij deze variabelen aanwezig zijn.

Naast de recipiënten en donoren in TTS, ontwikkelden ook drie foetus uit zwangerschappen gecompliceerd met sIUGR postnatale RVOTO. In deze drie casus werd de sIUGR en de RVOTO bij de grootste foetus al gezien vroeg in het tweede trimester. Dit bevestigt de hypothese dat het jonge foetale hart kwetsbaarder is en een hogere kans heeft op ontwikkeling van postnatale RVOTO bij hemodynamische veranderingen, in vergelijking tot het foetale hart later in de zwangerschap.

In sIUGR zijn vaak grote AA-anastomosen aanwezig. Wij speculeerden dat deze grote AA-anastomosen verantwoordelijk zijn voor verstoorde flowpatronen intracardiaal, die met name vroeg in de zwangerschap kunnen leiden tot blijvende schade en ontwikkeling van postnatale RVOTO. Het voorkomen van postnatale RVOTO in de grotere foetus van sIUGR zwangerschappen is een relatief nieuwe bevinding en oplettendheid op de ontwikkeling hiervan bij vroege en ernstige gevallen van sIUGR wordt aanbevolen in de dagelijkse kliniek.

Om het spectrum en de ontwikkeling van RVOTO in recipiënten te onderzoeken hebben wij een prospectief longitudinaal cohortonderzoek verricht in 124 opeenvolgende TTS casus in onze kliniek (2015-2017). De resultaten staan beschreven in **hoofdstuk 6**. Wij onderscheidden drie subgroepen van ***prenataal*** RVOTO. De eerste groep werd geclassificeerd als pulmonale atresie, waarbij er geen voorwaartse stroming over de pulmonaal arterie meer te detecteren was en er over de ductus arteriosus omgekeerde flow te zien is. Dit is vaak een uiting van functionele atresie. In de tweede groep werd een verhoogde flow over de pulmonaalklep gevonden en werd geclassificeerd als pulmonaalstenose. In de derde groep was sprake van geïsoleerde pulmonaalklep insufficiëntie en deze werd als zodanig geclassificeerd. Prenataal

RVOTO werd in 12,9% van de recipiënten gediagnosticeerd op het moment van het vaststellen van TTS. In 5,6% van de recipiënten werd er juist prenataal RVOTO gezien na de lasertherapie terwijl dit daarvoor niet was vastgesteld.

Postnatale RVOTO werd vastgesteld in 6,7% van de overlevende recipiënten, waarvan 70% dit al voor de lasertherapie lieten zien en 30% alleen daarna. Alle recipiënten met ernstige postnatale RVOTO (waarvoor chirurgische behandeling noodzakelijk was) lieten de RVOTO al zien voor de lasertherapie. De incidentie van postnatale RVOTO in deze studie is iets hoger dan in voorgaande grote cohortonderzoeken bekend in de literatuur. Dit is te verklaren door het prospectieve karakter van deze studie met systematische longitudinale follow-up van alle recipiënten, waardoor wij enkele milde, late-onset gevallen konden vaststellen.

We evalueerden de drie subgroepen van prenatale RVOTO. De groep met prenatale pulmonaalstenose ontwikkelden vaker postnatale RVOTO dan de groep waarbij pulmonale atresie werd gezien. Onze hypothese is dat een verhoogde snelheid over de pulmonaalklep een uiting is van dysplasie van de pulmonaalklep. Dit is een anatomische verandering van de klep en daardoor is het minder waarschijnlijk dat deze reversibel is na lasertherapie. Pulmonale atresie is daarentegen vaak een resultaat van verminderde rechter ventrikel functie en dus een functionele verandering, die normaliseert als de hartfunctie hersteld is na lasertherapie. Als laatste vonden wij in de groep met geïsoleerde pulmonaalklep insufficiëntie geen kinderen met ontwikkeling van postnatale RVOTO. Dit suggereert dat dit een relatief milde bevinding is in TTS, welke reversibel is na behandeling.

In deze studie werd postnatale RVOTO geassocieerd met ontwikkeling van TTS vroeg in de zwangerschap, wat de bevindingen in **hoofdstuk 5** bevestigd. Hoewel prenatale RVOTO vaker voorkwam in de latere stadia van TTS (Quintero stadium 3 en 4), kwam postnatale RVOTO in alle Quintero stadia gelijk voor. Onze hypothese is dat de ernstige cardiale dysfunctie in de latere stadia van TTS een functionele RVOTO veroorzaakt, terwijl pulmonaalklep dysplasie gelijk voorkomt in alle stadia. Dysplasie zou dan vaker optreden bij een vroege zwangerschapsduur en een langere blootstelling aan volume overbelasting, 'shear stress' en uitwisseling van vasoactieve mediatoren tussen de foetussen. Gezien dysplasie minder reversibel is na behandeling resulteert dit vaker in postnatale RVOTO. Dit wordt geïllustreerd door de drie casus in ons cohort waarbij expectatief management werd gevoerd in TTS Quintero stadium I en waarbij

pulmonaalstenose werd vastgesteld in de recipiënt. Terwijl de TTS in alle drie de casus verbeterde, was de pulmonaalstenose progressief in twee van de drie casus, waarbij in één van de casus chirurgische correctie middels ballon-valvuloplastiek nodig was in de neonatale periode.

Het is wenselijk om in een vroeg stadium foetaal cardiaal dysfunctioneren, dat op termijn zou kunnen leiden tot RVOTO of IUVD, te kunnen detecteren met een simpele stabiele en kwantitatieve meting. Op dit moment is de MPI de meest gebruikte methode om de foetale hartfunctie te beoordelen. MPI is de ratio tussen de isovolumetrische tijdsintervallen en de ejectietijd van het foetale hart en geeft de myocardfunctie weer. Het verkrijgen van de juiste echografische beelden voor het berekenen van de MPI is echter niet makkelijk en vereist een hoge mate van deskundigheid, waardoor de toepassing in de dagelijkse praktijk beperkt is. In **hoofdstuk 7** introduceerden wij een nieuwe techniek om foetale hartfunctie te beoordelen. We bepaalden de tijd die het myocard nodig heeft om te verkorten, de 'shortening time' (St) en de tijd die het myocard nodig heeft om weer te ontspannen, de 'lengthening time' (Lt). We bepaalden deze tijdsintervallen in drie cardiale regio's, namelijk het gehele hart, het linker- en het rechter ventrikel. De benodigde beelden worden verkregen met gebruik van color-coded tissue Doppler imaging en gemaakt in het vierkamerbeeld van het foetale hart. We verrichtten een prospectief longitudinaal cohortonderzoek in 54 gezonde eenlingzwangerschappen met een totaal van 251 opnamen.

Allereerst hebben wij de toepassing van deze techniek geëvalueerd. We vonden een hoge haalbaarheid (99,6%) en een excellente intra- en interobserver variabiliteit voor de St en Lt van het globale hart. De prestatie parameters voor het linker en rechter ventrikel waren goed. Op basis hiervan concludeerden we dat deze techniek goed reproduceerbaar is. Het vierkamerbeeld van het foetale hart is makkelijk te verkrijgen, deze techniek is dan ook potentieel bruikbaar in de dagelijkse kliniek.

Ten tweede hebben wij referentiewaarden gecreëerd voor deze tijdsintervallen. Lt nam toe St nam af met het toenemen van de zwangerschapsduur in alle regios. We pasten deze techniek toe op recipiënten om te testen of deze techniek verschillen zou meten in foetussen met een afwijkende hartfunctie. De uitvoerbaarheid was hoog (96,6%). St was verlengd en Lt was verkort in alle regio's van het hart. Deze veranderingen in de tijdsintervallen zijn vergelijkbaar met de bekende veranderingen in MPI bij recipiënten.

De bevindingen in deze studie laten zien dat het meten van de foetale hartfunctie met deze tijdsintervallen goed uitvoerbaar en goed reproduceerbaar is, zelfs in lastige echografische omstandigheden zoals TTS. Het is mogelijk om met deze techniek gezonde en cardiaal aangedane foetussen te onderscheiden. In de toekomst zullen meer studies verricht moeten worden om de bruikbaarheid van deze techniek te toetsen in de behandeling of voorspelling van foetale uitkomst in gecompliceerde zwangerschappen.

Dit proefschrift werd afgerond met **hoofdstuk 8**, waarin een algemene discussie en interpretatie van de uitkomsten van de studies werd beschreven. Daarnaast werd een suggestie gedaan voor toekomstig onderzoek in dit werkveld.

Concluderend kunnen de bevindingen beschreven in dit proefschrift bijdragen aan verbetering van klinische zorg, en foetale en neonatale follow-up van kinderen geboren uit monochoriale zwangerschappen. Daarnaast kunnen onze data gebruikt worden voor adequate counseling van de zwangere en haar partner.



APPENDICES

List of publications
List of abbreviations
Dankwoord
Curriculum Vitae



LIST OF PUBLICATIONS

Eschbach SJ, Tollenaar LSA, Oepkes D, Lopriore E, Haak MC. Intermittent absent and reversed umbilical artery flows in appropriately grown monochorionic diamniotic twins in relation to proximate cord insertion: A harmful combination? Prenat Diagn 2020;40(10):1284-1289.

Gijtenbeek M, Haak MC, Eschbach SJ, Buijnsters ZA, Middeldorp JM, Klumper FJCM, Oepkes D, Ten Harkel ADJ. Early postnatal cardiac follow-up of survivors of twin-twin transfusion syndrome treated with fetoscopic laser coagulation. J. Perinatol. 2020 Sep; 40(9):1375-1382.

Eschbach SJ, Gijtenbeek M, van Geloven N, Oepkes D, Haak MC. Measurement of cardiac function by cardiac time intervals, applicability in normal pregnancy and twin-to-twin transfusion syndrome. J Echocardiogr 2019;17(3):129-137.

Gijtenbeek M, Eschbach SJ, Middeldorp JM, Klumper FJCM, Slaghekke F, Oepkes D, Haak MC. The value of echocardiography and Doppler in the prediction of fetal demise after laser coagulation for TTTS: A systematic review and meta-analysis. Prenat Diagn 2019;39(10):838-847.

Eschbach SJ, Ten Harkel ADJ, Middeldorp JM, Klumper FJCM, Oepkes D, Lopriore E, Haak MC. Acquired right ventricular outflow tract obstruction in twin-to-twin transfusion syndrome; a prospective longitudinal study. Prenat Diagn 2018;38(13):1013-1019.

Eschbach SJ, Boons LSTM, Van Zwet E, Middeldorp JM, Klumper FJCM, Lopriore E,Teunissen AKK, Rijlaarsdam ME, Oepkes D, Ten Harkel ADJ, Haak MC. Right ventricular outflow tract obstruction in complicated monochorionic twin pregnancy. Ultrasound Obstet Gynecol 2017;49(6):737-743.

Eschbach SJ, Boons LS, Wolterbeek R, Middeldorp JM, Klumper FJ, Lopriore E, Oepkes D, Haak MC. Prediction of single fetal demise after laser therapy for twin-twin transfusion syndrome. Ultrasound Obstet Gynecol 2016;47(3):356-62.

Ruiter L, Eschbach SJ, Burgers M, Oude Rengerink K, van Pampus MG, van der Goes BY, Pajkrt E, Mol BWJ, de Graaf IM. A prediction model for emergency caesarean section in women with placenta previa. Am J of Perinatology 2016 Dec;33(14):1407-1414.

Burgers M, Oude Rengerink K, Eschbach SJ, Muller MM, van Pampus MG, Mol BWJ. Predictors for Massive Haemorrhage during Caesarean Delivery Due to Placenta Previa. Int J of Clin Med 01/2015; 2006(02):96-104.

Rheenen van PF, de Moor LT, Eschbach SJ, Brabin BJ. A cohort study of haemoglobin and zinc protoporphyrin levels in term Zambian infants: effects of Iron stores at birth, complementary food and placental malaria. Eur J Clin Nutr 2008;62:1379-1387.

Rheenen van PF, de Moor LT, Eschbach SJ, de Groot H, Brabin B. Delayed cord clamping and haemoglobin levels in infancy: a randomised controlled trial in term babies. Trop Med Int Health 2007;12:603-616.

LIST OF ABBREVIATIONS

AA-anastomosis	Arterio-Arterial anastomosis
A/REDF	Absent/Reversed End Diastolic Flow
AVDR-anastomosis	Arterio-Venous anastomosis from Donor to Recipiënt
AVRD-anastomosis	Arterio-Venous anastomosis from Recipiënt to Donor
cTDI	color-coded Tissue-Doppler-Imaging
DV	Ductus Venosus
EFW	Estimated Fetal Weight
ET	Ejection Time
GA	Gestational Age
FLS	Fetoscopic Laser Surgery
FVW	Flow Velocity Waveforms
iAREDF	intermittend Absent or Reversed End-Diastolic Flow
IUFD	Intrauterine Fetal Demise
Lt	Lengthening time of the myocard
LUMC	Leiden University Medical Center
MCA	Middle Cerebral Artery
MCDA	Monochorionic-Diamniotic
MCMA	Monochorial-Monoamniotic
MI	Mitral Insufficiency
MPI	Myocardial Performance Index
NND	Neonatal Death

PA	Pulmonary Atresia
PCI	Proximate Cord Insertion
PE	Pericardial Effusion
PI	Pulmonary Insufficiency
PPHN	Persistent Pulmonary Hypertension of the Neonate
PPROM	Preterm Prelabor Rupture of Membranes
PS	Pulmonary Stenosis
PSV	Peak Systolic Velocity
ROI	Region of Interest
RVOTO	Right Ventricular Outflow Tract Obstruction
SFD	Single Fetal Demise
St	Shortening time of the myocard
sIUGR	selective Intra Uterine Growth Restriction
SLPCV	Selective Laser Photocoagulation of Communicating Vessels
TAPS	Twin Anemia Polycythemia Sequence
TI	Tricuspid Insufficiency
TTTS	Twin-Twin Transfusion Syndrome
UA	Umbilical Artery
UCC	Umbilical cord coagulation
UV	Umbilical Vene

DANKWOORD

Een proefschrift schrijven is een avontuur, en dat beleef je niet alleen. Van meedenkende professionals tot het luisterend oor van vrienden in de avonduren, alles draagt bij aan het eindresultaat. In 2013 begon ik als arts prenatale diagnostiek in het LUMC en startte ik de HEARTTS studie, waarvan de resultaten beschreven staan in dit proefschrift. Hoewel ik niet iedereen bij name kan noemen, bedank ik graag iedereen die op welke manier dan ook aandeel heeft gehad in de totstandkoming hiervan, onderstaand genoemde personen in het bijzonder.

Mijn grootste dank gaat uit naar alle ouders en hun (ongeboren) kinderen wiens data ik mocht gebruiken voor mijn studie. In de echokamers op de B3 hebben jullie niet alleen deelgenomen aan mijn onderzoek, ik heb ook deelgenomen aan jullie vreugdevolle, emotionele en kwetsbare momenten. Achter elk getal schuilt een verhaal.

Ik dank alle collega's en professionals zonder wiens inbreng ik hier niet had kunnen staan. Ik ben dankbaar voor al jullie wetenschappelijke lessen en jullie steun in de praktische uitvoering van mijn onderzoek.

Dick, de laatste loodjes wegen het zwaarst. Bedankt door je steun en vertrouwen.

Monique, het was een lange weg maar hier staan we dan toch! Ik heb respect voor je gedrevenheid in de wetenschap en je kunde in de echokamers. Bedankt voor alles wat ik van je geleerd heb.

Derk Jan, bedankt voor al je goede inbreng en begeleiding, en natuurlijk voor het organiseren en beoordelen van alle neonatale echo's. Ik dank ook Gwen en Francisca voor de vele extra echo's die zij verricht hebben.

Manon, harde werker! Met jou aan boord op de 'tweelingen-lijn' bleek delen vooral vermenigvuldigen te zijn. Bedankt voor de fijne samenwerking en natuurlijk ook voor het lief en leed dat we deelden op dat kleine kamertje in de hoek.

Katinka en Phebe, jullie wijze lessen gingen verder dan mijn onderzoek. Naast de kunst van de echografie brachten jullie mij ook een stuk levenskunst bij.

Wijlen RJ, "waar gaat het om in dit leven"? Dank je wel voor alle existentiële gesprekken op kamer 089, ik had je graag gezien bij mijn verdediging.

Alle mede-auteurs, met name Annemieke, Frans en Enrico. Zonder jullie bijdrage en steun stond ik hier nu niet. Hartelijk dank.

Studenten Lidwien, Stephan en Roanne: bedankt voor alle uren dataverzameling en de samenwerking daarna. Het ga jullie goed.

Collega-onderzoekers Tess, Fenna, Sheila, Lisanne en Amber, dank voor alle gezelligheid en het samen sparren en ontdekken.

Collega's van het Reinier de Graaf Gasthuis, met name Kitty. Wat een heerlijke werkplek heb ik bij jullie gevonden! Bedankt voor jullie steun en de motiverende woorden en gesprekken in de afgelopen jaren.

Dit proefschrift kan ik niet los zien van 'mijn thuisfront'. Lieve familie en vrienden, jullie zagen op deze reis altijd het hele plaatje, ook als ik het zelf soms niet meer zag. Ik ben dankbaar voor het relativerende effect van alle momenten die ik met jullie mocht delen.

Lianne, op reis leert men zijn vrienden kennen. In Twente kruisten onze levens elkaar en na enkele woestijnachtige omzwervingen zijn we nu collega's in 'het Reinier'. Je hebt altijd voor mij klaargestaan, natuurlijk sta je vandaag weer naast me.

Tineke, nog één rivier te gaan. Onze spraakberichtjes zijn me dierbaar, dank voor je wijze en inspirerende woorden die mij altijd een duwtje in de rug zijn. Ik hoop nog lang met je op te lopen.

"Stoere meisjes" Emily en Janneke, ik voel me ozo heppie, zo heppie deze dag! Bedankt voor jullie altijd luisterend oor sinds de collegebanken. Al slaan we nooit een toetje over, ik kom altijd 10 kg lichter terug van onze etentjes.

"Fröhliche Mädchen", Elise en Trijnie. Echte vrienden lopen nooit in de weg, behalve als je de verkeerde kant op gaat. Die dienst hebben jullie mij meermaals bewezen en daarom ben ik nu waar ik ben. Need I say more? Mijn dank is groot.

"VWO-vriendinnetjes", Annalies, Christina en Laura. De beste spiegel is een oude vriend. Al die keren dat jullie mijn bedenkingen aan mochten horen kwamen er mooie adviezen terug. Bedankt voor jullie nuance in al onze discussies, het maakt mij een wijzer mens.

Lieve papa en mama, jullie onvoorwaardelijke steun en het onuitputtelijke vertrouwen in mijn kunnen zijn mijn fundament geworden. Maar belangrijker nog, jullie hebben mij geleerd waar het leven over gaat en daarin zijn jullie mijn grote voorbeeld. Tienduizend redenen tot dankbaarheid.

Lieve Alex, jij gaf mijn toekomst richting. Bedankt voor jouw stabiliteit, geduld en liefde op momenten dat mijn hoofd overliep. Jouw passie voor de maatschappij is inspirerend, ik ben blij dat ik naast jou mag staan.

Lieve Noëlle en Mirthe, het avontuur lacht jullie tegemoet en ik kan niet wachten het samen met jullie te beleven. Mooie meiden van ons: onderzoek alles, en houd het goede vast!

CURRICULUM VITAE

Sanne Eschbach was born on October 20th 1983 in Zwolle. After graduating at the Greijdanus college (Atheneum) in 2001, she moved to Amsterdam to study Medicine at the University of Amsterdam.

As a student, she was an active member of students' association 'GSVA Petrus Plancius'. From a young age, she carried a special interest in health care in developing countries. In 2003 she initiated an extracurricular internship Tropical Medicine at Lakhnadon Christian Hospital in India, where she participated in prevention and vaccination programs in the rural area of Madhya Pradesh. In 2005 she left to Zambia for her scientific research internship at Mpongwe Mission Hospital, investigating the influence of delayed cord clamping on hemoglobin levels of neonates and infants. In 2008, her final internship took place at the maternity and children's ward at Turiani Mission Hospital in Tanzania, where her enthusiasm for mother and childcare was born. After graduating in February 2009, she started working as a physician (ANIOS) in pediatrics and neonatology at the Kennemer Gasthuis, followed by a job in an HIV clinic in rural South Africa as a non-profit physician for seven months.

In 2010 she started to work as a physician (ANIOS) in Obstetrics and Gynecology in the Medisch Spectrum Twente, and continued this in the Academic Medical Center in Amsterdam where she participated in research evaluating complications in patients with placenta previa. In 2013 she was given the opportunity to start as ultrasonographer at the department of fetal medicine in the Leiden University Medical Center (LUMC). She specialized in the complications of monochorionic twin pregnancies, and started to research the consequences of hemodynamic adaptation of the fetal hearts in complicated monochorionic pregnancies, of which the result led to this thesis.

In 2016 she married Alex Haas. They live in Rijswijk with their two daughters, Noëlle (2018) and Mirthe (2021). Currently, she works at the Reinier de Graaf Gasthuis in Delft as physician (kliniek-arts) in obstetrics and gynecology with special interest in twin pregnancies.