



Universiteit
Leiden
The Netherlands

Brachytherapy for rectal cancer

Rijkmans, E.C.

Citation

Rijkmans, E. C. (2021, June 8). *Brachytherapy for rectal cancer*. Retrieved from <https://hdl.handle.net/1887/3176520>

Version: Publisher's Version

License: [Licence agreement concerning inclusion of doctoral thesis in the Institutional Repository of the University of Leiden](#)

Downloaded from: <https://hdl.handle.net/1887/3176520>

Note: To cite this publication please use the final published version (if applicable).

Cover Page



Universiteit Leiden




The handle <http://hdl.handle.net/1887/3176520> holds various files of this Leiden University dissertation.

Author: Rijkmans, E.C.

Title: Brachytherapy for rectal cancer

Issue date: 2021-06-08



Chapter 9

General discussion

9. GENERAL DISCUSSION

In this thesis, radical radiotherapy for frail or elderly patients with rectal cancer is evaluated in the HERBERT study. The results demonstrate that a combination of external beam radiotherapy and high-dose-rate endorectal brachytherapy (HDREBT) is both feasible and effective in rectal cancer patients unfit to undergo surgery. The results show promising tumour responses with almost 90% overall response and 61% complete response. Severe late toxicity, however, was observed in 40% of evaluable patients, which is unacceptable. As the HERBERT study represents the initial experience with HDREBT in the Netherlands, the high rate of toxicity can partly be explained by a learning curve. As was shown by the results of the repeat CT side study, there is much room for improvement of the technique. With developments in both external beam radiotherapy techniques and brachytherapy techniques, toxicity can be substantially reduced. Optimising the HDREBT technique and development of image-guided adaptive brachytherapy (IGABT) concepts for rectal cancer will allow for increased target coverage while minimising dose to normal tissue. As there is increasing interest in organ preservation for rectal cancer, HDREBT could have great potential, not only in elderly, but also fit patients who wish to avoid surgery. In this general discussion, the HERBERT trial is compared to current literature on radical radiotherapy in elderly patients and a follow-up trial, the HERBERT II, is introduced. Furthermore, suggestions are made to improve the HDREBT technique for rectal cancer and a target concept for image-guided adaptive brachytherapy for rectal cancer is introduced. Finally, the potential role of HDREBT in neoadjuvant and definitive radiotherapy is described and the current status of primary organ preservation and several options for treatment intensification including HDREBT are discussed.

9.1 Radical radiotherapy in elderly patients

The results of the HERBERT study are compared to three recently published cohort studies on radical radiotherapy in elderly patients with rectal cancer in Table 1.¹⁻⁴ The studies by Gerard et al. and Myint et al. describe the use of contact X-ray (CXB) as a boost to chemoradiotherapy and the study by Garant et al. uses HDREBT after external beam radiotherapy alone. These studies show that dose escalation up to 90-100 Gy EQD2 _{$\alpha\beta$ 10} is possible when using an intraluminal radiotherapy boost and is associated with a complete response rate between 61% and 86% in cT2-3 tumours.

Compared to the other studies in Table 1, the complete response rate in the HERBERT study is relatively low and the regrowth rate high. More importantly, the toxicity was unacceptably high. These differences can be explained by differences in patient selection and technique. In the contact X-ray cohorts young patients refusing standard surgery were also included and concurrent chemotherapy was prescribed, which might increase the chance of a complete response. Possibly, elderly or frail patients could have increased risk of toxicity due to reduced regenerative

Table 1. Comparison of the HERBERT study with recent publications of combined EBRT with intraluminal radiotherapy in elderly patients

Study	n	age median (range)	TNM-stage	Treatment				Outcome				
				EBRT	Chemo-therapy	CXB	HDREBT	EQD2*	cCR	Regrowth [^]	Late tox.	Definition of toxicity
HERBERT	38	83 (57-94)	cT2-3	13x3 Gy no	no		3x5-8 Gy	61-78.2	61%	30%	40%	Proctitis grade 3
Garant 2019	94	81 (60-97)	cT1-4	16x2.5 Gy no	no		3x10 Gy	91.7	86.2%	13.6%	19%	Grade not specified
Gerard 2019	74	74 (39-93)	cT2-3 < 5 cm	25x2 Gy	CAP	3x30 Gy		100	86%	10%	11%	Grade 3 bleeding/ incontinence
Myint 2018 [§]	83	72 (36-87)	cT2-3 (RV < 3 cm)	25x1.8 Gy	CAP/SFU (n=71)	3x30 Gy		94.2	63.8%	13.2%	6%	gr 2; APC for rectal bleeding, no gr 3
Myint 2017 [§]	200	74 (32-94)	cT1-4 (RV < 3 cm)	25x1.8 Gy	CAP/SFU (n=144)	3x30 Gy		94.2	72%	11%	11%	gr 2; APC for rectal bleeding, no gr 3

* Total EQD2 was calculated at 1 cm depth for contact X-ray (≈3x10 Gy).

[^] regrowth is calculated as proportion of complete responders.

[§] Myint 2018 is a selection of Myint 2017: cT1, small T2, T4, CXB< 4wks after EBRT, missing data were excluded.

Abbreviations: EQD2, equivalent dose in fractions of 2 Gy, α/β=10; RV, residual volume after EBRT; CAP, capecitabine; SFU, 5-fluorouracil.

ability. Moreover, CXB requires a small residual tumour volume (< 5 cc) and only patients with a tumour < 5 cm (Gerard et al.) or a residual tumour volume < 3 cm (Myint et al.) were included.¹⁻³ Furthermore, the contralateral wall is spared during CXB by the rigid proctoscope resulting in a very small irradiated volume. In the HERBERT trial, tumours were larger with a median residual diameter of 3 cm and median brachytherapy clinical target volume (CTV) of 7 cc.

The cohort described by Garant et al. is more comparable to the HERBERT study with a median age of 81 and no use of chemotherapy.⁴ The prescribed HDREBT boost dose was higher with 3×10 Gy instead of 3×7 Gy resulting in a total EQD2 of 91.7 Gy. The clinical complete response rate of 86% is very promising and superior to the 61% observed in the HERBERT study. While the prescribed dose was higher, the long-term complication rates were lower: 12.8% rectal bleeding, 3.2% symptomatic ulceration, 2% proctitis and 1% perforation. Further, major low anterior resection syndrome (LARS) was seen in only 1 of 14 evaluable patients after two years.⁴ These differences might be explained by the extensive experience with the technique at the McGill University Health Centre and further developments in the HDREBT technique compared to the technique used in the HERBERT study. These include use of central shielding, an ipsilateral balloon to reduce the surface dose to < 200% (i.e. 20 Gy) and adaptive CT-based image-guided brachytherapy.⁵

Overall, these studies show very promising complete response rates and prove the concept of radical radiotherapy for rectal cancer. While the studies using contact X-ray show minimal toxicity of very high doses to a small volume (3×30 Gy surface dose to < 3 cm), the toxicity analyses described in Chapter 4 and 5 show the risk of a HDREBT boost to larger volumes. In the dose-toxicity analyses described in Chapter 5, CTV D2cc and CTV volume were both strongly correlated with deep ulceration after brachytherapy. Improvements in brachytherapy technique, focussing on better target coverage in large tumours and reduction of very high dose regions, will likely result in improved tolerability. Further research on the risks and benefits of a brachytherapy boost is however warranted before implementing the use of a HDREBT boost as a standard treatment option for elderly patients.

Rationale for the HERBERT II study

In frail elderly patients with rectal cancer, unfit for standard surgery, the main aim of treatment should be to maximise tumour control while maintaining quality of life. While definitive radiotherapy is a possible curative option in cT2-3 tumours as illustrated by the cohort studies in Table 1, it is still associated with moderate to severe toxicity reducing quality of life in patients with a limited life expectancy. Palliative radiotherapy focussed on durable symptom control is currently still considered the standard of care in inoperable patients and the value of an endoluminal brachytherapy boost should be further evaluated in a randomised phase III trial.

The HERBERT II study will be performed to evaluate the added value of an intraluminal brachytherapy boost after external beam radiotherapy in cT2-3N0-1 rectal cancer patients, who are unfit for surgery.⁶ An important part of the study is a geriatric assessment which is aimed at

selection of patients who are deemed medically inoperable but in whom radical treatment is desirable. Initial screening on functional and cognitive status will be done using the Geriatric-8⁷ and the six-item cognitive impairment test.⁸ In case of abnormalities, patients will be referred for a comprehensive geriatric assessment. Treatment options, including the HERBERT II study, will then be discussed in a shared decision-making process.

The treatment schedule of the HERBERT II study is illustrated in Figure 1. Patients will receive 13×3 Gy external beam radiotherapy and, after response assessment, patients will be randomised to either a brachytherapy boost or further follow-up. The primary endpoint will be clinical complete response at six months after brachytherapy. Secondary endpoints include health-related quality of life, acute and late patient- and physician-reported toxicity and freedom from regrowth and overall survival at two years.

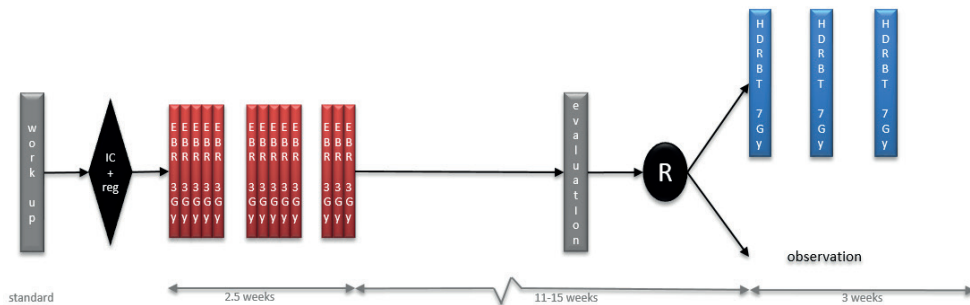


Figure 1. HERBERT II trial schedule.

9.2 Optimising HDR endorectal brachytherapy

To improve the outcome of HDREBT, further optimisation of the technique is needed, with the aim of improving target coverage while minimising dose to normal tissue. In Chapter 6, the benefit of CT-based adaptive brachytherapy was shown and this is now considered standard of care.^{9,10} Several aspects of HDREBT can however be further improved, working towards an image-guided adaptive brachytherapy workflow:

1. Imaging
2. Target definition
3. Dose prescription
4. Shielding of normal tissue
5. Position verification

9.2.1 Imaging

Soft tissue contrast on CT is poor and although a diagnostic MRI, endoscopy images and clips were used to aid in CTV delineation in the HERBERT study, there was still a high level of uncertainty. The residual tumour volume is best evaluated using a combination of digital rectal examination (DRE), endoscopy and MRI.¹¹⁻¹³ Information of DRE and endoscopy at time of diagnosis and at time of brachytherapy is essential and can be summarised in a clinical drawing (see Figure 2).¹⁰ Additional use of MRI has the potential to reduce interobserver variability and target volume compared to CT-based delineation.^{14,15} T2-weighted MRI is currently considered the standard in evaluation of rectal cancer.¹¹ Functional imaging such as diffusion-weighted MRI and FDG-PET are helpful in identifying pathologic areas but might result in smaller volumes and are less reliable in geometric accuracy.^{16,17}

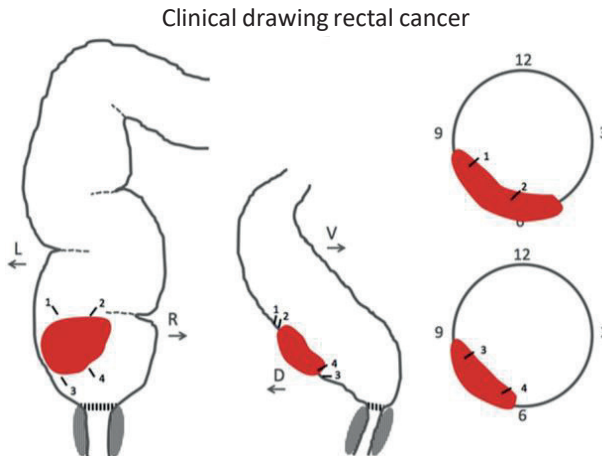


Figure 2. Clinical drawing for IGABT in rectal cancer.*

To allow for MRI evaluation after EBRT and MRI-guided brachytherapy, MRI compatible markers are needed. The clips used in the HERBERT study are not MRI compatible and gold fiducials were therefore tested as an alternative in the REMARK study. Visibility analyses selected the T1 3D GRE MRI sequence as the best sequence for marker detection and the Gold Anchor as the preferred marker because of superior visibility.¹⁸ The use of MRI for HDR endorectal brachytherapy was evaluated in the OPPER-BT trial. Intermediate risk rectal cancer patients were treated with neoadjuvant HDREBT (4×6.5 Gy on four consecutive days), followed by total mesorectal excision. The benefit of MRI-guided delineation is clearly illustrated in Figure 3. Better discrimination

* Reprint with permission of Elsevier from: Nout RA, Devic S, Niazi T, Wyse J, Boutros M, Pelsler V, et al.

“CT-based adaptive high-dose-rate endorectal brachytherapy in the preoperative treatment of locally advanced rectal cancer: Technical and practical aspects.”*Brachytherapy*. 2016;15(4):477-84, Copyright Elsevier (2016).

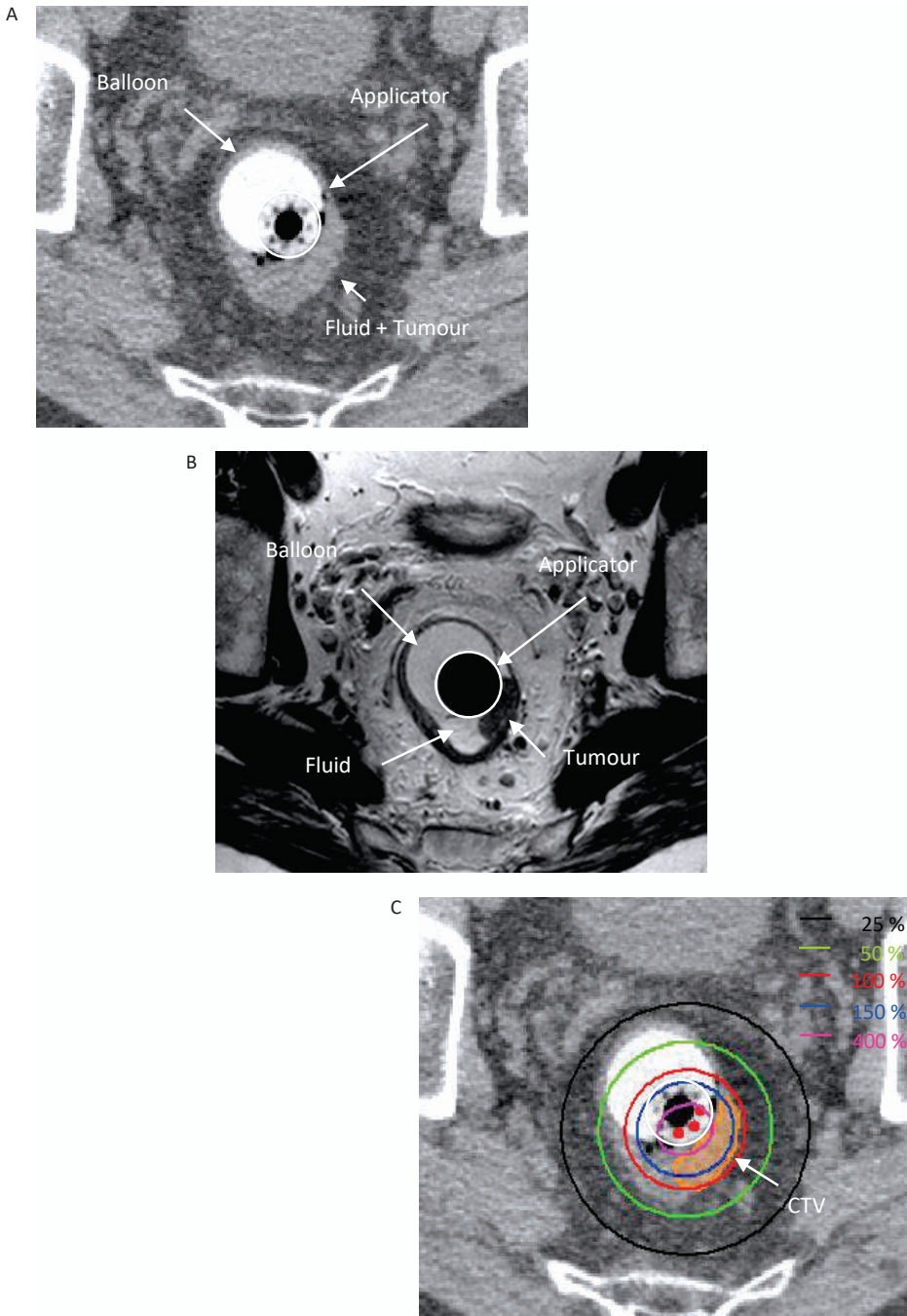


Figure 3. Example of MRI and planning CT of a patient in the OPPE-BT trial.
 (A) Planning CT. (B) Planning MRI. (C) Planning CT with CTV delineation and dose distribution. The fluid could be excluded from the CTV due to superior soft tissue contrast of MRI.

between fluid, faeces and tumour will allow for increased accuracy in delineation and therefore reduction in the total irradiated volume, increasing conformity and limiting toxicity. The trial has been closed prematurely because of poor inclusion, most likely due to organ-sparing alternative treatment options in these patients. However, the MR-guided brachytherapy workflow is very promising and will be further developed in the HERBERT II trial.

9.2.2 Target definition

The target definition for external beam radiotherapy in rectal cancer is mainly related to the risk of lymphatic spread based on the initial tumour stage. A consensus paper published in 2016 provides recommendations for elective lymph node areas to be included in the external beam radiotherapy fields of intermediate and high risk rectal cancer.¹⁹ With the introduction of radiotherapy in low risk tumours in organ-preservation studies, the size of the radiotherapy fields have been adjusted accordingly and include only the mesorectum.^{20,21}

The target definition for a brachytherapy boost is related to the primary tumour and requires differentiation between macroscopic and microscopic spread around the macroscopic tumour. Currently, widespread accepted definitions and terminology for target volumes in brachytherapy for rectal cancer are lacking. In order to understand and compare results obtained and to perform future multicentre research, this is of utmost importance.

Differences between rectal brachytherapy modalities challenge the development of robust target definitions. In CXB, usually no imaging is performed and most HDR-brachytherapy applications are still CT-based which, as stated above, provides poor soft tissue contrast.

With the implementation of MRI, the tumour can be better visualised, which allows for development of image-guided adaptive brachytherapy (IGABT). This concept has been developed by the Gynaecological GEC-ESTRO group in cervical and recently also vaginal cancer, and has been adopted in ICRU-89.²²⁻²⁵ These adaptive target concepts differentiate between target volumes at time of diagnosis (initial) and following response assessment during treatment (residual). Based on the expected cancer cell densities (decreasing with distance from the gross tumour volume (GTV)) and routes of microscopic tumour extension, different target volumes can be defined. In this paragraph, suggestions are made for a target concept for IGABT for rectal cancer (see Table 2).

Suggested target concept for IGABT in rectal cancer

Gross tumour volume for the primary tumour (GTV-T) is defined as macroscopic disease assessed through digital rectal examination, endoscopy and available imaging modalities. The initial GTV at diagnosis (GTV-T_{init}) will change during treatment and at every brachytherapy application a residual GTV (GTV-T_{res}) is defined. The clinical target volume is divided into CTV-T for direct spread of the primary tumour and CTV-N for potential lymph node spread. In IGABT, the CTV-T is further divided into three risk categories: high risk CTV-T, intermediate risk CTV-T and low risk CTV-T.

Table 2. Suggested target volumes for image-guided adaptive brachytherapy in rectal cancer

Target	Definition	Description
GTV-T _{init}	The initial gross macroscopic tumour volume at time of diagnosis.	The volume should be assessed using the information of DRE and endoscopy (clinical drawing) and the T2 weighted MRI. Areas with diffusion restriction should always be included in the GTV-T _{init} .
GTV-T _{res}	The gross macroscopic tumour volume at time of diagnosis as described by DRE, endoscopy and MRI.	The volume should be assessed using the information of DRE and endoscopy (clinical drawing) and the T2 weighted MRI. Areas with diffusion restriction should always be included in the GTV-T _{res} .
CTV-T _{HR}	The high risk CTV includes the GTV-T _{res} and if present the fibrotic scar	This includes the GTV-T _{res} and surrounding areas with hypointense signal intensity on T2-weighted MRI (fibrotic scarring) occurring within the initial tumour extension in the rectal wall, and possible 'grey zones' in the mesorectum within the initial tumour extension.
CTV-T _{IR}	The intermediate risk CTV should include all areas with significant microscopic tumour extension.	This should minimally include a 0.5 cm lateral safety margin around the CTV-T _{HR} , and in addition should include the original tumour extension at diagnosis (GTV-T _{init}), taking previous unaffected anatomical borders into account.

The high risk CTV (CTV-T_{HR}) is the area at highest risk of recurrence and the highest tumour cell density. It is suggested to include the GTV-T_{res} and all areas with residual mucosal abnormalities on endoscopy and abnormal signal intensity on MRI. In rectal cancer, usually a hypointense scar is seen on the T2 weighted image.¹¹ If brachytherapy is the first treatment modality, CTV-T_{HR} resembles the GTV-T_{init} at the first fraction.

The intermediate risk (CTV-T_{IR}) includes the CTV-T_{HR} with margins to include areas with significant potential for direct microscopic extension. This area is dependant of initial tumour extension (stage) and regression to EBRT. Lateral margins should include the submucosal microscopic spread within the rectal wall, and deep margins the microscopic spread into the mesorectum. Currently there is insufficient evidence to support an exact evidence-based margin for mesorectal spread, but it is advised to minimally include the initial tumour extension (GTV-T_{init}) into the CTV-T_{IR}, taking previous unaffected anatomical boundaries into account.

Several surgical studies do provide some evidence for the lateral microscopic extension. A study by Smith et al. showed that the lateral microscopic extension within the rectal wall was largely dependent on ypT-stage. They observed microscopic tumour spread lateral to the residual mucosal abnormalities in 32 of 45 (71%) patients. In ypT1 tumours the median spread was 0 mm and maximally 4 mm, in ypT2 tumours median spread was 2.5 mm and maximally 9 mm and in ypT3 tumours the median spread was 4 and maximally 9 mm. All ypT2/3 tumours were originally staged as cT3.²⁶ A meta-analysis including four studies evaluating microscopic intramural extension after neoadjuvant chemoradiotherapy also confirmed the relation between ypT-stage and lateral microscopic extension. Interestingly, there was a large group with no microscopic tumour extension (80%). The remaining 20% showed lateral extension between 1-10 mm, with one outlier to 20 mm. The authors conclude that a GTV to CTV margin of 5.5 mm would be sufficient to encompass all microscopic tumour extension in 95% of patients after neoadjuvant treatment.²⁷

These large differences in lateral microscopic extension can be explained by different patterns of tumour response: shrinkage, fragmentation and mucin pool formation (see Figure 4).²⁸ Inclusion of the $GTV-T_{init}$ will account for microscopic spread in both fragmentation and mucin pool formation patterns, but might not be necessary in tumours that show a shrinkage regression pattern. Further research is necessary to assess if these regression patterns can be identified on MRI or endoscopy.

A clear translation from these data into exact margin prescriptions for $CTV-T_{IR}$ is difficult, but a safety margin from $CTV-T_{HR}$ to $CTV-T_{IR}$ of 5 mm seems reasonable.

Areas at low risk of microscopic spread are referred to as the low risk CTV ($CTV-T_{LR}$). Areas at risk of lymph node spread are referred to as $CTV-N$. These CTVs can either be treated with (chemo)radiotherapy or surgery or both. A mesorectal excision after neoadjuvant brachytherapy is an example of surgical treatment of the $CTV-T_{LR}$ and $CTV-N$.

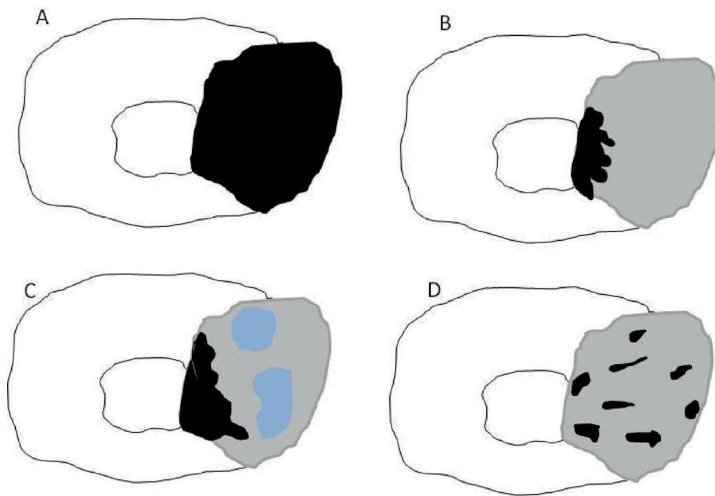


Figure 4. Schematic representation of response patterns. Adapted from Nagtegaal et al. 2020.^{28,29}

A shows the tumour at diagnosis (initial GTV). B-D show different regression patterns. Residual GTV is shown in black and initial GTV in grey.

(A) Tumour at diagnosis (initial GTV).

(B) Tumour shrinkage scenario.

(C) Mucin pool formation (blue).

(D) Tumour fragmentation scenario in which scattered groups of tumour cells spread throughout the whole fibrotic area.

Target definitions for brachytherapy alone in cT1 tumours

The target definition as described above can be used in patients with cT1-4 rectal cancer in combination with EBRT. In low risk cT1 rectal cancer, the risk of lymph node metastasis is very low and standard treatment is local excision. Alternatively, these patients could be treated with brachytherapy alone. Extensive experience is described with contact X-ray by professor Papillon and professor Gerard in the era prior to local excision.^{30,31} Because the risk of distant microscopic spread and lymph node spread is very low in these patients, the CTV-T_{LR} and CTV-N are disregarded and the tumour is treated locally (as with local excision). The CTV-T_{HR} is equal to the GTV-T_{init} at the first fraction, and resembles the definition in Table 2 in the following fractions. The CTV-T_{IR} should resemble the lateral microscopic tumour spread. A Japanese study showed that in stage I tumours, distal intramural spread is very rare and occurs only in 2.7%.³² A review on microscopic spread in pT2 tumours showed no microscopic spread in 90.2% of patients and a spread of > 5 mm in only 4.7% of patients. It can be assumed that the risk in cT1 tumours is very low and probably no margin is needed in the majority of patients, but for now a safety margin of 5 mm is suggested to avoid potential undertreatment (see Table 2).

Finally, this is a suggested target concept, which should be discussed in a broader context allowing adoption by a larger number of centres to allow prospective clinical validation in such a setting.

9.2.3 Dose prescription

Currently, a wide variety of treatment schedules are used for an intraluminal boost after (chemo)radiotherapy. Dose prescription for the boost is usually performed at a fixed distance from the applicator surface (0 cm, 0.5 cm or 1.0 cm) or the radial margin of the delineated CTV (see Figure 3).^{1,4,33-37} As dose prescription at a fixed distance will lead to overtreatment in superficial tumours and undertreatment in large tumours, prescription to the delineated CTV volume is preferred. However, prescribing to a delineated volume will also result in large differences in total irradiated volumes between patients with large and small tumours. Use of uniform terminology and reporting of the volumes of CTVs will allow for comparison between studies. In addition, registration of DVH parameters such as D98 and D90 and equivalent cumulative doses (EQD2 _{$\alpha/\beta 10$}) rather than physical doses will allow for dose-response analyses. Based on the results of the studies presented in Table 1 and a study on dose-response in patients with locally advanced tumours, an EQD2 _{$\alpha/\beta 10$} of at least 90 Gy for the CTV-T_{HR} is suggested, but needs confirmation in larger prospective trials.^{1-4,38} For microscopic tumour included in the CTV-T_{IR}, an EQD2 _{$\alpha/\beta 10$} of 60 Gy is usually assumed to be sufficient.^{25,39}

Planning aims for organs at risk

There are no reliable data to suggest evidence-based constraints in CXB or HDREBT treatment planning for rectal cancer.⁴⁰ In rectal cancer brachytherapy, the main organ at risk is the rectal wall, which overlaps with the clinical target volume. The CTV is therefore a target, but also an organ at risk. In contact X-ray, a surface dose of 3×30 Gy on the tumour after different schedules

of (chemo)radiotherapy (13×3 Gy/ 5×5 Gy/ 25×1.8-2 Gy) appears safe.⁴¹ Series on contact therapy after local excision however have used a lower dose of 3×20 Gy or 2×15 Gy combined with CRT. Both schedules appear safe and it can therefore be assumed that 3×20 Gy surface dose is well tolerated in a small area < 3 cm.⁴² In HDREBT, a constraint of 3×20 Gy on the surface is used in the study by Garant et al. and is associated with acceptable toxicity. From the HERBERT study, a CTV D2cc < 14 Gy/fraction is advised to minimise the risk of deep ulceration.

Organs at risk outside of the clinical target volume are the rectal wall surrounding the CTV (normal rectal wall), anal canal, the vagina and low-lying bowel loops. In the HERBERT study, no hotspots were allowed in the surrounding organs (D0.1cc < 100%) and no toxicity of the anal canal, vagina or small bowel was observed. The observed toxicity of the normal rectal wall illustrates the need for shielding, and reducing the dose as much as possible without compromising target coverage is currently advised. For the anal canal, dose constraints are needed to avoid painful ulceration in very low tumours. From experience in anal brachytherapy, a boost dose of 4×4 Gy interstitial brachytherapy seems safe after a dose of 45 Gy (EBRT+BT EQD2_{α/β3} = 65.6 Gy).⁴³ In the HERBERT I study, the EQD2_{α/β3} did not exceed 66 Gy and no anal toxicity was observed. From these data it can be assumed that a cumulative EQD2_{α/β3} D2cc of < 66 Gy for the anal canal will be safe in IGABT for rectal cancer. For all other organs at risk, constraints from experience in gynaecological cancer can be applied.^{39,44} However, registration of DVH parameters is advised to allow for dose-response analyses specifically for rectal cancer.

9.2.4 Shielding of normal tissue

In the HERBERT study, deep ulceration was seen in patients with very high surface dose at the tumour site. Due to the inverse-square law, dose reduction can be achieved by increasing the distance from the source to the organ at risk. This has led to the introduction of an ipsilateral semi-circular balloon. The surface dose and D2cc of the CTV can thereby be reduced while maintaining adequate tumour coverage. A volume of 20-30 cc is usually sufficient. Figure 5 illustrates reduction of the surface dose by use of an ipsilateral balloon.

Filling of the contralateral balloon will reduce the risk of telangiectasia and erythema of the normal rectal wall. Filling is limited by the comfort of the patient and a volume of 40-80 cc can usually be achieved.⁵

In addition, reduction of dose to the contralateral rectal wall can be achieved by shielding. Several studies performed at the medical physics unit of McGill University have evaluated the dosimetric effect of a lead or tungsten rod in the central canal. Unfortunately, such shielding effects cannot be calculated in the most commonly used TG-43 planning systems. However, when only three channels are used, the dose at the side of the tumour is unaffected while the dose to the contralateral wall is reduced by an average of 24% (see Figure 6).^{5,45,46}

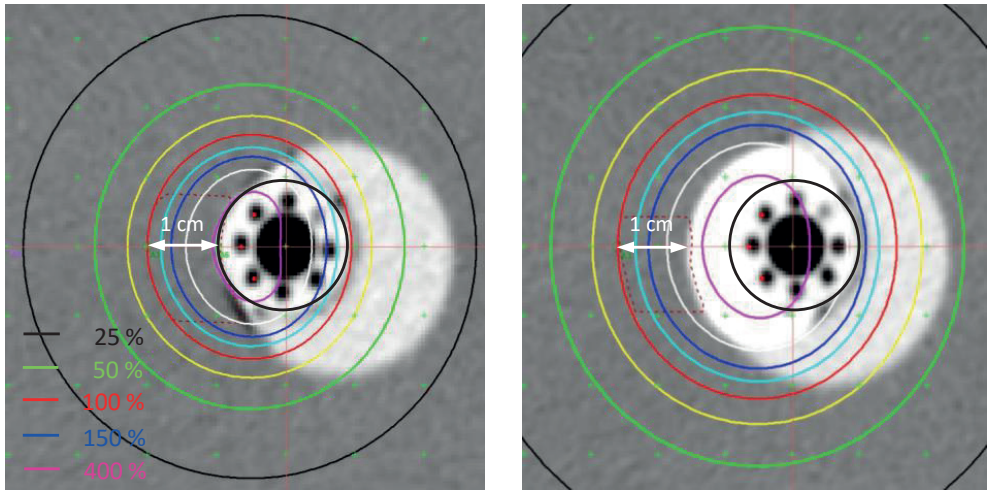


Figure 5. Simulation of the effect of an ipsilateral balloon on surface dose. 100% isodose is prescribed at 1 cm from the applicator/balloon surface. Surface dose is 450% without filling of the ipsilateral balloon and 275% after filling of the ipsilateral balloon with 20 cc contrast enhanced NaCl. The contralateral balloon is filled with 40 cc.

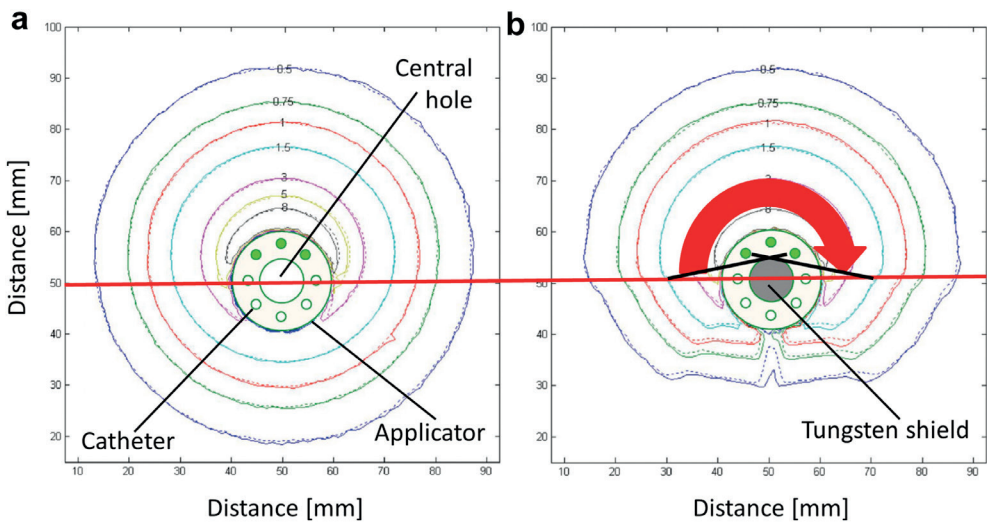


Figure 6. Absolute isodose distributions around the flexible multichannel applicator with sources loaded into three channels without (a) and with (b) tungsten shielding.*

* Reprint with permission of Elsevier from: Devic S, Bekerat H, Garant A, Vuong T. "Optimization of HDRBT boost dose delivery for patients with rectal cancer." *Brachytherapy*. 2019;18(4):559-63. Copyright Elsevier (2019).

Shielding possibilities of alternative applicators.

Several alternative applicators can be considered for HDREBT. Rigid cylinders and balloon-type applicators are currently in use and provide specific advantages and disadvantages compared to the flexible multichannel applicator.⁴⁷ Rigid cylinders with a central canal have a lower surface dose due to the increased distance from the source to the mucosa and shielding of 25-75% of the circumference allows for increased sparing of the contralateral rectal wall. Optimisation with one channel is however very limited and use of shielding induces a risk of shielding a part of the tumour in case of rotation of the rectal wall. Without shielding, the dose to the contralateral wall will be unacceptably high and a multichannel applicator is therefore preferred.

Balloon-type applicators use the concept of increasing the distance to the normal tissue by use of a balloon.^{33,48} When both contralateral and ipsilateral balloons are used with a multichannel applicator this will have a similar effect. The advantage of the multichannel applicator is that the reconstruction of the source channels is more straightforward.

Two other applicator types are under development: The Flower applicator and a shielded dynamic/grooved applicator. The Flower applicator is an initiation of the MAASTRO clinic in the Netherlands.⁴⁹ It aims to mimic the dose distribution of contact X-ray therapy with an HDR iridium afterloader. The advantages and disadvantages of CXB compared with HDREBT therefore apply. The difference with CXB is the increased treatment time (13 min vs. 3 min), which introduces possible issues with intrafraction movement of the rectal wall. However, if online position verification can be achieved, this method will be a good alternative to CXB or HDREBT with a multichannel applicator in small tumours.

The shielded dynamic/grooved applicator is being developed by the physics group of the McGill University in Canada.^{50,51} Two prototypes evaluate the use of a robot which steers the source to the correct positions in a fully shielded applicator and a fully shielded rigid applicator with multiple grooves for the sources. In theory, both applicators show increased sparing of normal tissue, but no reports on clinical testing have been published so far. Possible clinical limitations are the rigidity of the applicator, position verification and substantial increase in treatment time.

9.2.5 Position verification

Displacement of the applicator in between CT scanning and irradiation is a realistic risk in patients who will be transferred between imaging modalities and the treatment couch. This is currently overcome by correcting for depth and rotation, based on orthogonal X-rays in the brachytherapy suite.^{10,52} An in-room 3D imaging modality will prevent transfers, whereas rapid replanning based on the latest image will be possible. Ideally, the imaging modality would be an MRI, given the superior soft tissue characteristics as compared to CT scanning. However, given the logistical challenges of an MRI-based brachytherapy procedure and current need for a CT for applicator reconstruction, most institutes opt for CT-based. At present, an MRI-compatible afterloader is

being developed in UMCU.⁵³ In addition, in our group MRI-based applicator reconstruction is being investigated. Given these developments, an MRI-only workflow will probably be available within 3-5 years from now.

9.3 The role of HDREBT in curative treatment of rectal cancer

HDREBT can also be used as an alternative to neoadjuvant CRT, as has been demonstrated at the McGill University Hospital in Canada over the last two decades.⁵⁴ The obvious advantage of neoadjuvant HDREBT compared to neoadjuvant CRT is the reduction in irradiated volume and, as a consequence, in associated toxicity. Concerns of inferior oncological outcome due to insufficient dose to the elective lymph nodes are contradicted by the excellent local control. In a cohort of 483 patients with cT3/lowT2 tumours, only 4.8% local recurrences occurred after 4×6.5 Gy (daily) HDREBT with delayed surgery.⁵⁵ A comparison of patients with cT3 tumours treated with neoadjuvant HDREBT in Canada and patients with cT3 tumours treated with neoadjuvant (C)RT in the Netherlands showed no significant differences in oncological outcome.⁵⁶

The Correct trial is currently investigating both modalities in a randomised fashion and results are expected in 2021.⁵⁷ Comparable to the RAPIDO trial, this trial also implements the concept of total neoadjuvant treatment and prescribes full dose chemotherapy prior to TME surgery. In the RAPIDO trial, 5×5 Gy (SCRT) followed by 6-9 cycles of CAPOX/FOLFOX4 resulted in a higher compliance to chemotherapy and a reduced risk of locoregional and distant failure at three years.^{58,59} Acute preoperative toxicity ≥ grade 3 was however increased from 25% with standard chemoradiotherapy to 48% in the experimental arm.⁵⁸ Replacing neoadjuvant SCRT (5×5 Gy) with HDREBT (4×6.5 Gy) might improve tolerability of total neoadjuvant treatment.

HDREBT has also been evaluated as a boost strategy in addition to standard neoadjuvant chemoradiotherapy in locally advanced rectal cancer. A randomised trial reported by Jakobsen et al, showed an increase in major pathologic response from 29% to 44% after addition of 2×5 Gy HDREBT in patients with a cT3/4 tumour, but this did not translate into increased progression free or overall survival. It was therefore concluded that a HDREBT boost currently is not advised in neoadjuvant treatment of locally advanced rectal cancer.^{35,60}

However, if the aim of intensifying neoadjuvant treatment is to increase the chance of a watch-and-wait strategy, a HDREBT boost has been shown to be very effective in a phase II study by Appelt et al.³⁴ Fit patients with a cT2/3N0 tumour received a HDREBT boost of 5 Gy after high dose chemoradiotherapy (60 Gy). This resulted in a complete response rate of 78% and after a median follow-up of 23 months, 60% had successful organ preservation. Long-term follow-up showed excellent quality of life and local symptom scores.⁶¹

9.4 Organ preservation for rectal cancer

Shared decision making is the new standard in oncological care. In rectal cancer, a large group of patients have a clear desire for alternative treatment strategies to avoid a permanent stoma. In addition, the improved functional outcomes after a successful organ-preservation approach compared to neoadjuvant chemoradiotherapy followed by surgery further increases the interest in organ preservation.⁶¹⁻⁶⁴ Several options, such as intensifying radiotherapy or chemotherapy and selection of patients with earlier stages, are being explored to increase the chance of achieving a complete response. The downside of treatment intensification is the increased risk of toxicity in patients who do not achieve a complete response and require a completion TME. The GRECCAR-2 study clearly demonstrated that salvage TME after CRT and local excision is associated with increased morbidity compared to TME alone.⁶⁵ Moreover, the CARTS study reminded us that, although rare, chemoradiotherapy can even cause mortality itself.⁶⁶ While some patients therefore still prefer standard surgery, approximately 50% of patients are willing to risk extra toxicity in order to have a chance of organ preservation.^{63,64,67} Careful discussions of the advantages and disadvantages of organ preservation strategies should therefore be standard practice.

9.4.1 Challenges in organ preservation

Selection of patients is one of the most important challenges in organ preservation. Although volume and stage are important factors, large tumours may be very radiosensitive, whereas small tumours might exhibit intrinsic radioresistance. Many studies are currently investigating the potential use of biomarkers and radiomics in prediction of good responders.⁶⁸⁻⁷⁰ Clinical implementation of these markers will help in patient selection for organ preservation. Another important challenge is response assessment. The current gold standard for response assessment is based on three diagnostic modalities: Digital Rectal Examination (DRE), white light endoscopy and multiparametric MRI.^{12,13}

Criteria for a clinical complete response (cCR) are:

1. DRE: absence of any palpable tumour or irregularity.
2. Endoscopy: flat scar, whitening of the mucosa with or without telangiectasia.
3. MRI: normalised rectal wall or homogeneous fibrosis without diffusion restriction.

A combination of these three factors is associated with a chance of a true complete response of 98%.^{12,13} Very few patients however present with the perfect complete response, but still might have a pathologic complete response.^{12,71,72} From surgical studies it is clear that a longer waiting period increases the pCR rate and that response can be ongoing for several weeks and maybe months. In patients with minor residual abnormalities (near complete response), a watch-and-wait strategy can be discussed and reassessment every 6-8 weeks is advised to evaluate if there is an ongoing response.^{11,73,74} In case of residual abnormalities after several

evaluations, a completion TME is advised. Data from salvage surgery however show that still approximately 20% of salvage resections show a pCR.^{3,12,71,72,75-77} Response assessment after an intraluminal radiotherapy boost is possibly even more difficult than after EBRT alone because ulceration will be observed more frequently.⁷⁸ Techniques to diagnose a complete response therefore have to be improved to avoid unnecessary TME surgery with possible long-term morbidity. Use of big-data and radiomics could reduce the variability between radiologists and increase the positive predictive value of multiparametric MRI.⁶⁹ Another promising technique is the use of fluorescence during endoscopy. A novel EpCAM-targeting agent seems promising for the detection of rectal cancer, and could potentially be combined with white light endoscopy during response assessment.^{79,80}

9.4.2 Treatment intensification

Early stages, currently treated with surgery alone, might be treated with (chemo)radiotherapy with standard doses, but to increase the chance of a complete response in more advanced stages, intensification of treatment is required in the majority of patients. Moderate radiotherapy dose escalation to the tumour and lymph nodes can be achieved with a simultaneous integrated boost using intensity modulated or volumetric arc radiotherapy.^{34,61,81} While approximately 20% will achieve a complete response after moderate dose escalation, additional treatment of the residual tumour will be necessary in most patients.⁸¹ Local excision, CXB, HDREBT and stereotactic radiotherapy are all possible options.

Local excision

Developments in endoscopic and transanal surgical techniques for early rectal cancer have made local excision very attractive and a widely available option. Several phase 2 studies evaluated the use of local excision after (chemo)radiotherapy in cT2-3 tumours.⁸²⁻⁸⁵ The main advantage compared to other strategies is that response is confirmed by pathology. Further, in tumours which respond poorly to radiotherapy, a change in treatment modality may be logical and, in these patients, local excision could be preferred to HDREBT. The main disadvantages, however, are the need for general anaesthesia, a very high rate of severe acute toxicity including pain, and the risk of an incomplete resection or ypT2-3 stage requiring a completion TME.^{66,82}

Contact X-ray

Contact X-ray, delivers a very high dose to the rectal mucosa by use of an X-ray tube with 50kV which is guided through a rigid rectoscope. Its use is limited by the availability of the contact X-ray machine, size of the tumour (< 3 cm) and accessibility of the tumour with rigid proctoscopy.⁸⁶ When all these requirements are met, contact X-ray is preferred to local excision, HDREBT or EBRT because of a favourable toxicity profile due to the small irradiated volume.

HDREBT

As described in this thesis, high-dose-rate endorectal brachytherapy can achieve a very high dose without the limitations of CXB. In small tumours, however, it does result in a larger irradiated volume than CXB. Patients with a large residual tumour are therefore good candidates for a HDREBT boost. The use of image-guided HDREBT will enable adjustment of the dose distribution on the residual tumour volume, preventing over or under treatment. No anaesthesia is required and treatment is well tolerated.

Stereotactic radiotherapy

Developments in precision in external beam radiotherapy with the use of MR-guided radiotherapy allows for dose escalation to the tumour with external beam radiotherapy.^{87,88} The rectal boost trial evaluated dose escalation up to 65 Gy and showed that toxicity was acceptable.⁸⁹ To be able to achieve doses as high as 90 Gy EQD2, however, stereotactic radiotherapy techniques are required, which are currently not available for rectal cancer. Online MR-guided radiotherapy with an MRI-linac may facilitate the development of these techniques.⁸⁸ The main challenges will be sparing of the contralateral wall and compensation for intrafraction mobility. It remains to be determined whether similar high dose distributions can be achieved as in HDREBT or CXB.

9.4.3 Ongoing studies for primary organ preservation

Primary organ preservation is associated with possible increased toxicity and is therefore only advised within clinical trials. Table 3 shows a list of ongoing studies on primary organ preservation.⁹⁰⁻⁹⁹

Most trials focus on early stage rectal cancer. Use of chemotherapy is mainly seen in studies from the US, Canada, Germany, China and France, whereas intensification of radiotherapy is more common in the UK, France, Denmark and the Netherlands. Almost all studies opt for local excision for small residual disease. Only one study currently uses an intraluminal radiotherapy boost (the OPERA trial). Local excision, HDREBT, CXB or an external beam radiotherapy boost are however all possible treatment options for residual disease and have specific advantages and disadvantages. Therefore, all these methods should be evaluated in future organ-preservation studies.

Table 3. Ongoing primary organ preservation-studies

Study	Country	Stage	Treatment arms		Primary outcome	Accrual
			Standard	Experimental		
<i>Single arm trials</i>						
GI-116 ⁹⁰	US	cT1-3N0 (cT1 high risk/T3 low risk)	NA	FOLFOX 6x + LE + CRT	Successful Local excision (R0)	2018-2022
NEO ⁹¹	US/ Canada	cT1-T3bN0 (high risk excl.)	NA	FOLFOX 6x / CAPOX 4x + LE	3 yr. Organ preservation	2017-2020
NOM low risk rectal cancer ⁹²	China	cT2-3bN0-1	NA	CRT (concurrent CAPOX) ± LE	3 yr. Organ preservation	2016-2019
CAO/ARO/AIO-16 ⁹³	Germany	cT1-2N+/ cT3N0	NA	CRT (3x 5FU/OX) + CT (3x FOLFOX)	cCR rate	2018-2020
NO-CUT ⁹⁴	Italy	cT3-4 N0/ cT1-4, N1-3	NA	CAPOX + CRT	Distant Relapse-Free Survival	2018-2022
<i>Randomised trials</i>						
TESAR ⁹⁵	NL	ypT1,2, intermediate risk after LE	TME	CRT (45 Gy) ± LE	3 yr. Local recurrence	2015-2022
STAR-TREC Phase II ⁹⁶	NL/UK/ Denmark	cT2-3N0	TME	CRT (45 Gy) / SCRT ± LE	Accrual rate	2017-?
STAR-TREC Phase III ⁹⁶	NL/UK/ Denmark	cT2-3N0	TME	CRT (45 Gy) / SCRT ± LE	Organ preservation	2020-?
OPERA ⁹⁷	UK/ France/ Denmark	cT2-3bN0-1 (< 8 mm)	CRT (45 Gy) EBRT(9 Gy) ± LE	CRT (45 Gy) XCB (90 Gy) ± LE	3 yr. Organ preservation	2015-?
GRECCAR12 ⁹⁸	France	cT2-3bN0-1 (< 8 mm)	CRT (50 Gy) + LE	Folfinirox 4x + CRT (50 Gy) + LE	1 yr. Organ preservation + absence of stoma	2016-2023
Watchful Waiting 3 Trial ⁹⁹	Denmark	cT1-3	CRT (50.4 Gy)	CRT (50.4 Gy + SIB 62 Gy)	2 yr. Organ preservation	2020-?

Studies published online at clinicaltrials.gov in April 2020. Search terms: “organ preservation” and “rectal cancer”. Abbreviations: NA, not applicable; cCR, clinical complete response; CRT, standard 5FU/capecitabin based chemoradiotherapy; yr., year; TME, total mesorectal excision; LE, Local excision; FOLFOX, 5FU+Folnic acid+Oxaliplatin; CAPOX, Capecitabin + oxaliplatin; Folfinirox, 5Fu + Folnic acid + Irinotecan + Oxaliplatin.

CONCLUSION

In conclusion, HDREBT is a very promising technique for treatment in rectal cancer. Neoadjuvant HDREBT will likely improve quality of life without compromising oncological outcome in patients who prefer or are in need of surgical treatment. In organ preservation, a HDREBT boost can be applied in both fit and frail patients and allows for dose escalation to 90 Gy EQD2. Technical developments in image (MRI) guided adaptive brachytherapy provide the opportunity to increase treatment efficacy and limit the risk of toxicity. International consensus on image-guided adaptive brachytherapy concepts and training programs for brachytherapy teams are needed to facilitate a more widespread implementation of HDREBT for rectal cancer.

REFERENCES

1. Gerard JP, Barbet N, Gal J, et al. Planned organ preservation for early T2-3 rectal adenocarcinoma: A French, multicentre study. *European journal of cancer (Oxford, England : 1990)*. 2019;108:1-16.
2. Sun Myint A, Smith FM, Gollins S, et al. Dose Escalation Using Contact X-ray Brachytherapy After External Beam Radiotherapy as Nonsurgical Treatment Option for Rectal Cancer: Outcomes From a Single-Center Experience. *International journal of radiation oncology, biology, physics*. 2018;100(3):565-573.
3. Sun Myint A, Smith FM, Gollins SW, et al. Dose escalation using contact X-ray brachytherapy (Papillon) for rectal cancer: does it improve the chance of organ preservation? *The British journal of radiology*. 2017;90(1080):20170175.
4. Garant A, Magnan S, Devic S, et al. Image Guided Adaptive Endorectal Brachytherapy in the Nonoperative Management of Patients With Rectal Cancer. *International journal of radiation oncology, biology, physics*. 2019;105(5):1005-1011.
5. Devic S, Bekerat H, Garant A, Vuong T. Optimization of HDRBT boost dose delivery for patients with rectal cancer. *Brachytherapy*. 2019;18(4):559-563.
6. Trial register HERBERT II study. <https://www.trialregister.nl/trial/7795>.
7. Decoster L, Van Puyvelde K, Mohile S, et al. Screening tools for multidimensional health problems warranting a geriatric assessment in older cancer patients: an update on SIOG recommendationsdagger. *Ann Oncol*. 2015;26(2):288-300.
8. Tuijl JP, Scholte EM, de Craen AJ, van der Mast RC. Screening for cognitive impairment in older general hospital patients: comparison of the Six-Item Cognitive Impairment Test with the Mini-Mental State Examination. *Int J Geriatr Psychiatry*. 2012;27(7):755-762.
9. van den Ende RPJ, Rijkmans EC, Kerkhof EM, et al. Benefit of adaptive CT-based treatment planning in high-dose-rate endorectal brachytherapy for rectal cancer. *Brachytherapy*. 2018;17(1):78-85.
10. Nout RA, Devic S, Niazi T, et al. CT-based adaptive high-dose-rate endorectal brachytherapy in the preoperative treatment of locally advanced rectal cancer: Technical and practical aspects. *Brachytherapy*. 2016;15(4):477-484.
11. Beets-Tan RGH, Lambregts DMJ, Maas M, et al. Magnetic resonance imaging for clinical management of rectal cancer: Updated recommendations from the 2016 European Society of Gastrointestinal and Abdominal Radiology (ESGAR) consensus meeting. *European radiology*. 2018;28(4):1465-1475.
12. Maas M, Lambregts DM, Nelemans PJ, et al. Assessment of Clinical Complete Response After Chemoradiation for Rectal Cancer with Digital Rectal Examination, Endoscopy, and MRI: Selection for Organ-Saving Treatment. *Annals of surgical oncology*. 2015;22(12):3873-3880.
13. Habr-Gama A, Perez RO, Wynn G, Marks J, Kessler H, Gama-Rodrigues J. Complete clinical response after neoadjuvant chemoradiation therapy for distal rectal cancer: characterization of clinical and endoscopic findings for standardization. *Diseases of the colon and rectum*. 2010;53(12):1692-1698.
14. O'Neill BD, Salerno G, Thomas K, Tait DM, Brown G. MR vs CT imaging: low rectal cancer tumour delineation for three-dimensional conformal radiotherapy. *The British journal of radiology*. 2009;82(978):509-513.
15. Gwynne S, Mukherjee S, Webster R, et al. Imaging for target volume delineation in rectal cancer radiotherapy--a systematic review. *Clinical oncology (Royal College of Radiologists (Great Britain))*. 2012;24(1):52-63.

16. Zhang Q, van Houdt PJ, Lambregts DMJ, et al. Locally advanced rectal cancer: 3D diffusion-prepared stimulated-echo turbo spin-echo versus 2D diffusion-weighted echo-planar imaging. *European radiology experimental*. 2020;4(1):9.
17. Burbach JP, Kleijnen JP, Reerink O, et al. Inter-observer agreement of MRI-based tumor delineation for preoperative radiotherapy boost in locally advanced rectal cancer. *Radiotherapy and oncology : journal of the European Society for Therapeutic Radiology and Oncology*. 2016;118(2):399-407.
18. van den Ende RPJ, Rigter LS, Kerkhof EM, et al. MRI visibility of gold fiducial markers for image-guided radiotherapy of rectal cancer. *Radiotherapy and Oncology*. 2019;132:93-99.
19. Valentini V, Gambacorta MA, Barbaro B, et al. International consensus guidelines on Clinical Target Volume delineation in rectal cancer. *Radiotherapy and oncology : journal of the European Society for Therapeutic Radiology and Oncology*. 2016;120(2):195-201.
20. Socha J, Pietrzak L, Zawadzka A, Paciorkiewicz A, Krupa A, Bujko K. A systematic review and meta-analysis of pT2 rectal cancer spread and recurrence pattern: Implications for target design in radiation therapy for organ preservation. *Radiotherapy and oncology : journal of the European Society for Therapeutic Radiology and Oncology*. 2019;133:20-27.
21. Peters FP, Teo MTW, Appelt AL, et al. Mesorectal radiotherapy for early stage rectal cancer: A novel target volume. *Clin Transl Radiat Oncol*. 2020;21:104-111.
22. Schmid MP, Fokdal L, Westerveld H, et al. Recommendations from gynaecological (GYN) GEC-ESTRO working group - ACROP: Target concept for image guided adaptive brachytherapy in primary vaginal cancer. *Radiotherapy and oncology : journal of the European Society for Therapeutic Radiology and Oncology*. 2019;145:36-44.
23. Potter R, Haie-Meder C, Van Limbergen E, et al. Recommendations from gynaecological (GYN) GEC ESTRO working group (II): concepts and terms in 3D image-based treatment planning in cervix cancer brachytherapy-3D dose volume parameters and aspects of 3D image-based anatomy, radiation physics, radiobiology. *Radiotherapy and oncology : journal of the European Society for Therapeutic Radiology and Oncology*. 2006;78(1):67-77.
24. Haie-Meder C, Potter R, Van Limbergen E, et al. Recommendations from Gynaecological (GYN) GEC-ESTRO Working Group (I): concepts and terms in 3D image based 3D treatment planning in cervix cancer brachytherapy with emphasis on MRI assessment of GTV and CTV. *Radiotherapy and oncology : journal of the European Society for Therapeutic Radiology and Oncology*. 2005;74(3):235-245.
25. *ICRU Report 89, Prescribing, Recording, and Reporting Brachytherapy for Cancer of the Cervix*. International Commission on Radiation Units & Measurements.
26. Smith FM, Wiland H, Mace A, Pai RK, Kalady MF. Depth and lateral spread of microscopic residual rectal cancer after neoadjuvant chemoradiation: implications for treatment decisions. *Colorectal disease : the official journal of the Association of Coloproctology of Great Britain and Ireland*. 2014;16(8):610-615.
27. Verrijssen AS, Guillem J, Perez R, et al. Microscopic intramural extension of rectal cancer after neoadjuvant chemoradiation: A meta-analysis based on individual patient data. *Radiotherapy and oncology : journal of the European Society for Therapeutic Radiology and Oncology*. 2020;144:37-45.
28. Nagtegaal ID, Glynne-Jones R. How to measure tumour response in rectal cancer? An explanation of discrepancies and suggestions for improvement. *Cancer treatment reviews*. 2020;84:101964.
29. CC rights links Nagtegaal et al, 2020. <https://s100.copyright.com/AppDispatchServlet>.
30. Papillon J. Intracavitary irradiation of early rectal cancer for cure. A series of 186 cases. *Cancer*. 1975;36(2):696-701.

31. Gerard JP, Ayzac L, Coquard R, et al. Endocavitary irradiation for early rectal carcinomas T1 (T2). A series of 101 patients treated with the Papillon's technique. *International journal of radiation oncology, biology, physics*. 1996;34(4):775-783.
32. Shimada Y, Takii Y, Maruyama S, Ohta T. Intramural and mesorectal distal spread detected by whole-mount sections in the determination of optimal distal resection margin in patients undergoing surgery for rectosigmoid or rectal cancer without preoperative therapy. *Diseases of the colon and rectum*. 2011;54(12):1510-1520.
33. Schmid MP, Berger D, Heilmann M, et al. Inflatable multichannel rectal applicator for adaptive image-guided endoluminal high-dose-rate rectal brachytherapy: design, dosimetric characteristics, and first clinical experiences. *Journal of contemporary brachytherapy*. 2017;9(4):359-363.
34. Appelt AL, Ploen J, Harling H, et al. High-dose chemoradiotherapy and watchful waiting for distal rectal cancer: a prospective observational study. *The Lancet Oncology*. 2015;16(8):919-927.
35. Appelt AL, Vogelius IR, Ploen J, et al. Long-term results of a randomized trial in locally advanced rectal cancer: no benefit from adding a brachytherapy boost. *International journal of radiation oncology, biology, physics*. 2014;90(1):110-118.
36. Myint AS, Gerard JP. Role of radiotherapy in the treatment of rectal cancer in older patients. *European journal of surgical oncology : the journal of the European Society of Surgical Oncology and the British Association of Surgical Oncology*. 2020;46(3):349-357.
37. Corner C, Bryant L, Chapman C, Glynne-Jones R, Hoskin PJ. High-dose-rate afterloading intraluminal brachytherapy for advanced inoperable rectal carcinoma. *Brachytherapy*. 2010;9(1):66-70.
38. Appelt AL, Ploen J, Vogelius IR, Bentzen SM, Jakobsen A. Radiation dose-response model for locally advanced rectal cancer after preoperative chemoradiation therapy. *International journal of radiation oncology, biology, physics*. 2013;85(1):74-80.
39. Pötter R, Tanderup K, Kirisits C, et al. The EMBRACE II study: The outcome and prospect of two decades of evolution within the GEC-ESTRO GYN working group and the EMBRACE studies. *Clinical and Translational Radiation Oncology*. 2018;9:48-60.
40. Verrijssen AS, Opbroek T, Bellezzo M, et al. A systematic review comparing radiation toxicity after various endorectal techniques. *Brachytherapy*. 2018.
41. Dhadda AS, Martin A, Killeen S, Hunter IA. Organ Preservation Using Contact Radiotherapy for Early Rectal Cancer: Outcomes of Patients Treated at a Single Centre in the UK. *Clinical oncology (Royal College of Radiologists (Great Britain))*. 2017;29(3):198-204.
42. Gerard JP, Chapet O, Ortholan C, Benezery K, Barbet N, Romestaing P. French experience with contact X-ray endocavitary radiation for early rectal cancer. *Clinical oncology (Royal College of Radiologists (Great Britain))*. 2007;19(9):661-673.
43. Varela Cagetti L, Zemmour C, Salem N, et al. High-dose-rate vs. low-dose-rate interstitial brachytherapy boost for anal canal cancers. *Brachytherapy*. 2019;18(6):814-822.
44. Kirchheiner K, Nout RA, Lindegaard JC, et al. Dose-effect relationship and risk factors for vaginal stenosis after definitive radio(chemo)therapy with image-guided brachytherapy for locally advanced cervical cancer in the EMBRACE study. *Radiotherapy and oncology : journal of the European Society for Therapeutic Radiology and Oncology*. 2016;118(1):160-166.
45. Poon E, Williamson JF, Vuong T, Verhaegen F. Patient-specific Monte Carlo dose calculations for high-dose-rate endorectal brachytherapy with shielded intracavitary applicator. *International journal of radiation oncology, biology, physics*. 2008;72(4):1259-1266.

46. Poon E, Reniers B, Devic S, Vuong T, Verhaegen F. Dosimetric characterization of a novel intracavitary mold applicator for 192Ir high dose rate endorectal brachytherapy treatment. *Medical physics*. 2006;33(12):4515-4526.
47. Hansen JW, Jakobsen A. The importance of applicator design for intraluminal brachytherapy of rectal cancer. *Medical physics*. 2006;33(9):3220-3224.
48. Kuo HC, Mehta KJ, Yaparpalvi R, et al. Dosimetric Evaluation of a Flexible Dual Balloon-Constructed Applicator in Treating Anorectal Cancer. *Technology in cancer research & treatment*. 2017;1533034617707433.
49. Bellezzo M, Fonseca GP, Verrijssen AS, et al. A novel rectal applicator for contact radiotherapy with HDR (192)Ir sources. *Brachytherapy*. 2018;17(6):1037-1044.
50. Webster MJ, Devic S, Vuong T, et al. Dynamic modulated brachytherapy (DMBT) for rectal cancer. *Medical physics*. 2013;40(1):011718.
51. Webster MJ, Devic S, Vuong T, et al. HDR brachytherapy of rectal cancer using a novel grooved-shielding applicator design. *Medical physics*. 2013;40(9):091704.
52. Devic S, Vuong T, Moftah B, et al. Image-guided high dose rate endorectal brachytherapy. *Medical physics*. 2007;34(11):4451-4458.
53. Beld E, Seevinck PR, Schuurman J, Viergever MA, Lagendijk JJW, Moerland MA. Development and Testing of a Magnetic Resonance (MR) Conditional Afterloader for Source Tracking in Magnetic Resonance Imaging-Guided High-Dose-Rate (HDR) Brachytherapy. *International journal of radiation oncology, biology, physics*. 2018;102(4):960-968.
54. Vuong T, Belliveau PJ, Michel RP, et al. Conformal preoperative endorectal brachytherapy treatment for locally advanced rectal cancer: early results of a phase I/II study. *Diseases of the colon and rectum*. 2002;45(11):1486-1493; discussion 1493-1485.
55. Vuong T, Devic S. High-dose-rate pre-operative endorectal brachytherapy for patients with rectal cancer. *Journal of contemporary brachytherapy*. 2015;7(2):183-188.
56. Breugom AJ, Vermeer TA, van den Broek CB, et al. Effect of preoperative treatment strategies on the outcome of patients with clinical T3, non-metastasized rectal cancer: A comparison between Dutch and Canadian expert centers. *European journal of surgical oncology : the journal of the European Society of Surgical Oncology and the British Association of Surgical Oncology*. 2015;41(8):1039-1044.
57. Chemoradiation or Brachytherapy for Rectal Cancer (CORRECT); Principal Investigator: Dr. Amol Narang, ClinicalTrials.gov Identifier: NCT02017704. <https://clinicaltrials.gov/ct2/show/NCT02017704?term=correct&cond=Rectal+Cancer&draw=2&rank=1>. Accessed 23-4-2020.
58. van der Valk MJM, Marijnen CAM, van Etten B, et al. Compliance and tolerability of short-course radiotherapy followed by preoperative chemotherapy and surgery for high-risk rectal cancer – Results of the international randomized RAPIDO-trial. *Radiotherapy and Oncology*. 2020;147:75-83.
59. Hospers G, Bahadoer RR, Dijkstra EA, et al. Short-course radiotherapy followed by chemotherapy before TME in locally advanced rectal cancer: The randomized RAPIDO trial. 2020; ASCO Virtual Scientific Program.
60. Jakobsen A, Ploen J, Vuong T, Appelt A, Lindebjerg J, Rafaelsen SR. Dose-effect relationship in chemoradiotherapy for locally advanced rectal cancer: a randomized trial comparing two radiation doses. *International journal of radiation oncology, biology, physics*. 2012;84(4):949-954.
61. Dizdarevic E, Frostrup Hansen T, Ploen J, et al. Long-Term Patient-Reported Outcomes After High-Dose Chemoradiation Therapy for Nonsurgical Management of Distal Rectal Cancer. *International journal of radiation oncology, biology, physics*. 2020;106(3):556-563.

62. Hupkens BJP, Martens MH, Stoot JH, et al. Quality of Life in Rectal Cancer Patients After Chemoradiation: Watch-and-Wait Policy Versus Standard Resection - A Matched-Controlled Study. *Diseases of the colon and rectum*. 2017;60(10):1032-1040.
63. Gani C, Gani N, Zschaek S, et al. Organ Preservation in Rectal Cancer: The Patients' Perspective. *Frontiers in oncology*. 2019;9:318.
64. van der Valk MJM, van der Sande ME, Toebes RE, et al. Importance of patient reported and clinical outcomes for patients with locally advanced rectal cancer and their treating physicians. Do clinicians know what patients want? *European journal of surgical oncology : the journal of the European Society of Surgical Oncology and the British Association of Surgical Oncology*. 2020.
65. Rullier E, Rouanet P, Tuech JJ, et al. Organ preservation for rectal cancer (GRECCAR 2): a prospective, randomised, open-label, multicentre, phase 3 trial. *Lancet (London, England)*. 2017;390(10093):469-479.
66. Verseveld M, de Graaf EJ, Verhoef C, et al. Chemoradiation therapy for rectal cancer in the distal rectum followed by organ-sparing transanal endoscopic microsurgery (CARTS study). *The British journal of surgery*. 2015;102(7):853-860.
67. Couwenberg AM, Intven MPW, Burbach JPM, Emaus MJ, van Grevenstein WMU, Verkooijen HM. Utility Scores and Preferences for Surgical and Organ-Sparing Approaches for Treatment of Intermediate and High-Risk Rectal Cancer. *Diseases of the colon and rectum*. 2018;61(8):911-919.
68. Dayde D, Tanaka I, Jain R, Tai MC, Taguchi A. Predictive and Prognostic Molecular Biomarkers for Response to Neoadjuvant Chemoradiation in Rectal Cancer. *International journal of molecular sciences*. 2017;18(3).
69. Horvat N, Veeraraghavan H, Khan M, et al. MR Imaging of Rectal Cancer: Radiomics Analysis to Assess Treatment Response after Neoadjuvant Therapy. *Radiology*. 2018;287(3):833-843.
70. Schurink NW, Min LA, Berbee M, et al. Value of combined multiparametric MRI and FDG-PET/CT to identify well-responding rectal cancer patients before the start of neoadjuvant chemoradiation. *European radiology*. 2020;30(5):2945-2954.
71. Garant A, Florianova L, Gologan A, et al. Do clinical criteria reflect pathologic complete response in rectal cancer following neoadjuvant therapy? *International journal of colorectal disease*. 2018;33(6):727-733.
72. Smith FM, Wiland H, Mace A, Pai RK, Kalady MF. Clinical criteria underestimate complete pathological response in rectal cancer treated with neoadjuvant chemoradiotherapy. *Diseases of the colon and rectum*. 2014;57(3):311-315.
73. Habr-Gama A, Sao Juliao GP, Fernandez LM, et al. Achieving a Complete Clinical Response After Neoadjuvant Chemoradiation That Does Not Require Surgical Resection: It May Take Longer Than You Think! *Diseases of the colon and rectum*. 2019;62(7):802-808.
74. van der Valk MJM, Hilling DE, Bastiaannet E, et al. Long-term outcomes of clinical complete responders after neoadjuvant treatment for rectal cancer in the International Watch & Wait Database (IWWD): an international multicentre registry study. *Lancet (London, England)*. 2018;391(10139):2537-2545.
75. van der Sande ME, Beets GL, Hupkens BJ, et al. Response assessment after (chemo)radiotherapy for rectal cancer: Why are we missing complete responses with MRI and endoscopy? *European journal of surgical oncology : the journal of the European Society of Surgical Oncology and the British Association of Surgical Oncology*. 2019;45(6):1011-1017.
76. Marijnen CA. Organ preservation in rectal cancer: have all questions been answered? *The Lancet Oncology*. 2015;16(1):e13-22.

77. Frin AC, Evesque L, Gal J, et al. Organ or sphincter preservation for rectal cancer. The role of contact X-ray brachytherapy in a monocentric series of 112 patients. *European journal of cancer (Oxford, England : 1990)*. 2017;72:124-136.
78. Gerard JP, Frin AC, Doyen J, et al. Organ preservation in rectal adenocarcinoma (T1) T2-T3 Nx M0. Historical overview of the Lyon Sud - nice experience using contact x-ray brachytherapy and external beam radiotherapy for 120 patients. *Acta oncologica (Stockholm, Sweden)*. 2015;54(4):545-551.
79. Boogerd LSF, Boonstra MC, Prevoo H, et al. Fluorescence-guided tumor detection with a novel anti-EpCAM targeted antibody fragment: Preclinical validation. *Surgical oncology*. 2019;28:1-8.
80. Burggraaf J, Kamerling IM, Gordon PB, et al. Detection of colorectal polyps in humans using an intravenously administered fluorescent peptide targeted against c-Met. *Nature medicine*. 2015;21(8):955-961.
81. Burbach JP, den Harder AM, Intven M, van Vulpen M, Verkooijen HM, Reerink O. Impact of radiotherapy boost on pathological complete response in patients with locally advanced rectal cancer: a systematic review and meta-analysis. *Radiotherapy and oncology : journal of the European Society for Therapeutic Radiology and Oncology*. 2014;113(1):1-9.
82. Garcia-Aguilar J, Renfro LA, Chow OS, et al. Organ preservation for clinical T2N0 distal rectal cancer using neoadjuvant chemoradiotherapy and local excision (ACOSOG Z6041): results of an open-label, single-arm, multi-institutional, phase 2 trial. *The Lancet Oncology*. 2015;16(15):1537-1546.
83. Stijns RCH, de Graaf EJR, Punt CJA, et al. Long-term Oncological and Functional Outcomes of Chemoradiotherapy Followed by Organ-Sparing Transanal Endoscopic Microsurgery for Distal Rectal Cancer: The CARTS Study. *JAMA surgery*. 2019;154(1):47-54.
84. Peltrini R, Sacco M, Luglio G, Bucci L. Local excision following chemoradiotherapy in T2-T3 rectal cancer: current status and critical appraisal. *Updates in surgery*. 2020;72(1):29-37.
85. Rullier E, Vendrely V, Asselineau J, et al. Organ preservation with chemoradiotherapy plus local excision for rectal cancer: 5-year results of the GRECCAR 2 randomised trial. *The lancet Gastroenterology & hepatology*. 2020.
86. Gerard JP, Dejean C, Montagne L, Benezery K, Doyen J, Hannoun Levi JM. A brief history of contact X-ray brachytherapy 50 kVp. *Cancer radiotherapie : journal de la Societe francaise de radiotherapie oncologique*. 2020.
87. Van Wickle JD, Paulson ES, Landry JC, Erickson BA, Hall WA. Adaptive radiation dose escalation in rectal adenocarcinoma: a review. *Journal of gastrointestinal oncology*. 2017;8(5):902-914.
88. Gani C, Boldrini L, Valentini V. Online MR guided radiotherapy for rectal cancer. New opportunities. *Clin Transl Radiat Oncol*. 2019;18:66-67.
89. Alice M Couwenberg JPB, Maaik Berbee, Miangela M Lacle,, René Arensman MGR, Frank J Wessels, Joanne Verdult,, Jeanine Roodhart OR, Sieske Hoendervangers, Jeroen Buijsen,, Apollo Pronk ECC, Anke B Smits, Joost T Heikens, Ane L Appelt,, Wilhelmina MU van Grevenstein HVM, Martijn PW Intven*. Efficacy of dose-escalated chemoradiation on complete tumour response in patients with locally advanced rectal cancer (RECTAL-BOOST); a multicentre, non-blinded, phase II, randomised controlled trial within a prospective cohort. *TO BOOST OR NOT TO BOOST; Improving Quality of Life after Rectal Cancer*.
90. GI-116: Phase II Study of Organ Preservation in Early Rectal Cancer Patients: Namrata Vijayvergia, ClinicalTrials.gov Identifier: NCT03548961. <https://clinicaltrials.gov/ct2/show/NCT03548961?term=organ+preservation&cond=Rectal+Cancer&draw=2&rank=4>. Accessed 15-4-2020.

91. NEO: Neoadjuvant Chemotherapy, Excision and Observation for Early Rectal Cancer; Principle investigator: Chris O'Callaghan; ClinicalTrials.gov Identifier: NCT03259035. <https://clinicaltrials.gov/ct2/show/NCT03259035?term=organ+preservation&cond=Rectal+Cancer&draw=2&rank=7>. Accessed 15-04-2020.
92. Tailored Operative or Non-operative Management for Low-risk Rectal Cancer After Intensive Neoadjuvant Treatment; Principle investigator; Aiwen Wu, ClinicalTrials.gov Identifier: NCT02860234. *NOM low risk rectal cancer* <https://clinicaltrials.gov/ct2/show/NCT02860234?term=organ+preservation&cond=Rectal+Cancer&draw=2&rank=5>. Accessed 15-04-2020.
93. Organ Preservation in Locally Advanced Rectal Cancer by Radiochemotherapy Followed by Consolidation Chemotherapy. (CAO/ARO/AIO-16); Principle investigator; Dr. Cihan Gani, ClinicalTrials.gov Identifier: NCT03561142. <https://clinicaltrials.gov/ct2/show/NCT03561142?term=organ+preservation&cond=Rectal+Cancer&draw=2&rank=6>. Accessed 15-04-2020.
94. Total Neoadjuvant Treatment Without Surgery For Locally Advanced Rectal Cancer (NO-CUT); Principle investigator; Salvatore Siena, ClinicalTrials.gov Identifier: NCT03565029. <https://clinicaltrials.gov/ct2/show/NCT03565029?term=organ+preservation&cond=Rectal+Cancer&draw=2&rank=17>. Accessed 15-04-2020.
95. Rectal Preserving Treatment for Early Rectal Cancer. A Multi-centred Randomised Trial of Radical Surgery Versus Adjuvant Chemoradiotherapy After Local Excision for Early Rectal Cancers (TESAR); Principle investigator Jurriaan B. Tuynman; VU University Medical Center; ClinicalTrials.gov Identifier: NCT02371304. <https://clinicaltrials.gov/ct2/show/record/NCT02371304?term=tesar&cond=Rectal+Cancer&draw=2&rank=1>. Accessed 28-03-2020.
96. Can the Rectum be Saved by Watchful Waiting or TransAnal Surgery Following (Chemo)Radiotherapy Versus Total Mesorectal Excision for Early REctal Cancer? (STAR-TREC); Principal Investigator: Simon Bach, MD, University Hospitals Birmingham; ClinicalTrials.gov Identifier: NCT02945566.
97. Safety of a Boost (CXB or EBRT) in Combination With Neoadjuvant Chemoradiotherapy for Early Rectal Adenocarcinoma (OPERA); Centre Antoine Lacassagne; ClinicalTrials.gov Identifier: NCT02505750. <https://clinicaltrials.gov/ct2/show/record/NCT02505750?term=opera&cond=Rectal+Cancer&draw=2&rank=2>.
98. Optimisation of Response for Organ Preservation in Rectal Cancer : Neoadjuvant Chemotherapy and Radiochemotherapy vs. Radiochemotherapy (GRECCAR12); Principle investigator; prof Eric Rullier, ClinicalTrials.gov Identifier: NCT02514278. <https://clinicaltrials.gov/ct2/show/NCT02514278?term=organ+preservation&cond=Rectal+Cancer&draw=2&rank=2>. Accessed 15-04-2020.
99. Standard Dose Versus High Dose of Radiotherapy in Rectal Preservation With Chemoradiotherapy in Rectal Cancer Patients (WW3); Principle investigator; Lars H Jensen; ClinicalTrials.gov Identifier: NCT04095299. <https://clinicaltrials.gov/ct2/show/NCT04095299?term=organ+preservation&cond=Rectal+Cancer&draw=2&rank=16>. Accessed 15-04-2020.