



Universiteit
Leiden
The Netherlands

Functional implications of structural “anomalies” in shoulder pain

Kolk, A.

Citation

Kolk, A. (2021, May 6). *Functional implications of structural “anomalies” in shoulder pain*. Retrieved from <https://hdl.handle.net/1887/3166012>

Version: Publisher's Version

License: [Licence agreement concerning inclusion of doctoral thesis in the Institutional Repository of the University of Leiden](#)

Downloaded from: <https://hdl.handle.net/1887/3166012>

Note: To cite this publication please use the final published version (if applicable).

Cover Page



Universiteit Leiden



The handle <http://hdl.handle.net/1887/3166012> holds various files of this Leiden University dissertation.

Author: Kolk, A.

Title: Functional implications of structural “anomalies” in shoulder pain

Issue date: 2021-05-06

8

Teres major tendon transfer in the treatment of irreparable posterolateral rotator cuff tears

A. Kolk

JF. Henseler

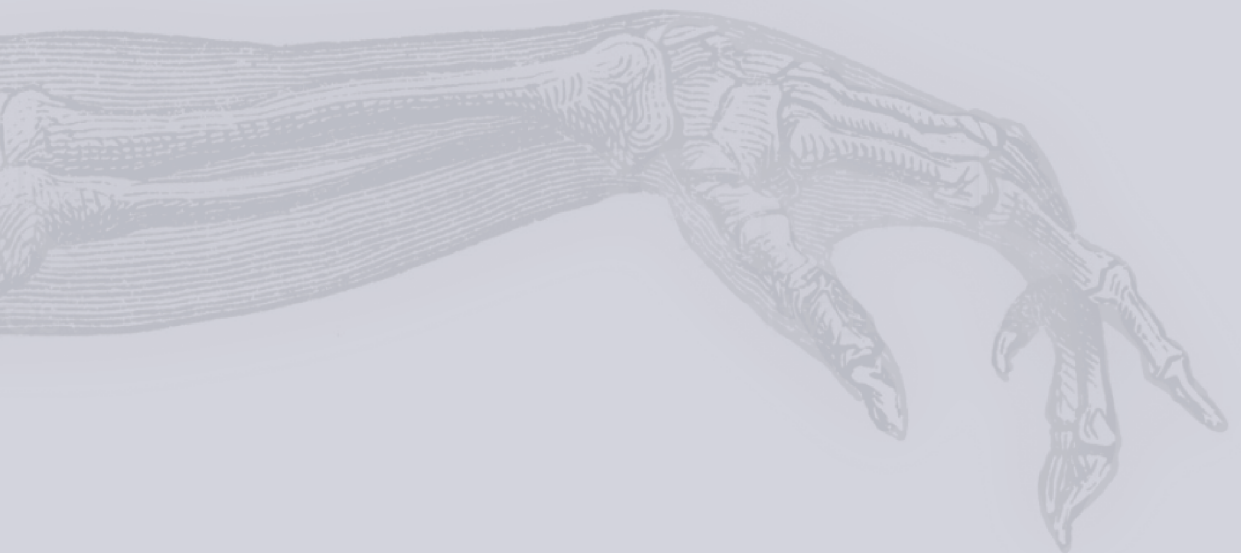E.J. Overes

J. Nagels

R.G.H.H. Nelissen

Bone Joint J. 2018; Mar 1; 100-B(3): 309-317

DOI: 10.1302/0301-620X.100B3.BJJ-2017-0920.R1



ABSTRACT

Background: Since long-term outcome of teres major tendon transfer surgery for irreparable posterosuperior rotator cuff (RC) tears is largely unknown, the primary aim of this study was to evaluate the long-term outcome of the teres major transfer. We also aimed to report on the results of a cohort of patients with a similar indication for surgery that underwent a latissimus dorsi tendon transfer.

Methods: In this prospective cohort study, we reported on the long-term results of 20 consecutive patients with a teres major for irreparable massive posterosuperior RC tears. Additionally, we reported on the results of the latissimus dorsi tendon transfer (n=19). Mean age was 60 (range 47 – 77) years. Outcomes included the Constant score (CS), pain at rest and during movement using Visual Analogue Scales (VAS).

Results: At a mean of ten years (range 8 – 12 years) following teres major transfer, the CS was still 23 points (95% confidence interval 14.6 – 30.9, $P < 0.001$) higher than preoperatively. VAS for pain at rest (21 mm; 95% confidence interval 4.0 – 38.9, $P = 0.016$) and movement (31mm; 95% confidence interval 16.0 – 45.1, $P < 0.001$) were lower than preoperative. We also found an increase in CS (32 points; 95% confidence interval 23.4 – 40.2, $P < 0.001$) and reduction of pain (26mm; 95% confidence interval 9.9 – 41.8, $P = 0.001$) six years after latissimus dorsi transfer.

Conclusions: Teres major tendon transfer is a treatment option to gain shoulder function and reduce pain in patients with an irreparable posterosuperior RC tear at a mean follow-up of ten years. The teres major tendon might be a valuable alternative to the commonly performed latissimus dorsi tendon transfer in the treatment of irreparable posterosuperior RC tears.

INTRODUCTION

The prevalence of rotator cuff (RC) tears in the general population increases substantially with age, from 0% to 3% in patients within their 30s to over half of the patients 70 years and older.³⁸ The majority of RC tears are asymptomatic and limited to the supraspinatus muscle, although the tear extends beyond the supraspinatus towards the infraspinatus muscle in 7% to 28%.^{15, 16} Those massive posterosuperior RC tears often severely restrict activities of daily living due to pain, and limitation of shoulder mobility.²⁷

Transfers of the latissimus dorsi or teres major tendon are viable treatment options to restore functional deficits and to reduce pain for the relatively young patient with a massive posterosuperior RC tear.^{14, 18, 19} For posterosuperior massive RC tears, transfer of the latissimus dorsi transfer has been the most frequently reported procedure in literature with satisfactory long-term functional outcomes.^{1, 11, 13, 14, 18, 21, 29, 31} As an alternative for transferring the latissimus dorsi, the teres major transfer has been advocated because of its potential favourable biomechanical orientation (i.e. better resembling the infraspinatus muscle).^{4, 19, 26, 28} So far, only short-term postoperative results of the teres major tendon transfer have been reported with a maximal follow-up of three years.^{3, 4, 19} Studies on long-term outcomes are warranted to provide information on the number of re-interventions (e.g. including conversions to reversed shoulder prosthesis after failed tendon transfer surgery and cuff tear arthropathy), to investigate durability of clinical improvements, and to examine whether the teres major can be used as a good alternative to the latissimus dorsi.

The purpose of this cohort study was to evaluate the long-term results of teres major tendon transfer surgery (mean 10 years, range 8 – 12 years) for patients with massive irreparable posterosuperior RC tears. Since shoulder surgery is primarily aimed at improving quality-of-life, this study will also provide a perspective on quality-of-life (i.e. SF-12 outcome measures) after tendon transfer surgery. Therefore, we also report on the results of a cohort of patients with a similar indication for surgery that underwent a latissimus dorsi tendon transfer at our institution with a mean follow-up of six years (range 5 – 8 years). We hypothesise that patients with an irreparable posterosuperior RC tear still have improved shoulder function and reduced pain 10 years after teres major tendon surgery.

MATERIALS AND METHODS

Participants

In this cohort study, we evaluated the outcomes of all consecutive patients who underwent teres major or latissimus dorsi tendon transfer for massive irreparable posterosuperior RC tears between April 2003 to April 2010 Leiden University Medical Centre, Leiden, the Netherlands. Initially from 2003 to 2007, the preferred muscle for tendon transfer surgery

was the teres major. From 2007 to 2010, the latissimus dorsi tendon transfer was favoured because of its reported success in the literature.¹³

The diagnosis massive irreparable posterosuperior RC tear was established after assessing patient history, physical examination, radiographs and Magnetic Resonance Imaging with Arthrography (MRA). At baseline, all subjects subjectively reported invalidating pain and/or lost shoulder functionality that hampered daily life activities. A tendon transfer was only indicated if the patients exhibited an external rotation deficit in abduction during physical examination, without passive restriction. A massive irreparable posterosuperior RC was defined as: 1) type 3 RC tear according to Davidson et al. with involvement of the infraspinatus muscle; 2) stage II or III retraction according to Patte et al.; and 3) at least grade 2 fatty infiltration according to the modified classification reported by Fuchs et al.^{8, 12, 32} Patients who suffered from a concurrent subscapularis muscle tear, axillary nerve injury, grade 3 or 4 glenohumeral osteoarthritis according to the Kelgren and Lawrence classification, symptomatic acromioclavicular osteoarthritis, and with restriction in passive shoulder mobility were not considered as eligible candidates for tendon transfer surgery²². Additionally, we excluded patients with a concomitant fracture, language barrier or in situ shoulder arthroplasty. The latter was considered an endpoint for this study. In total, 50 patients were eligible and received surgery between 2003 and 2010. Written informed consent was obtained from all participants.

Follow-up

Preoperative data and the evaluation approximately one year were obtained from a retrospective medical chart review. Short-term postoperative results of the teres major and latissimus dorsi transfer are previously reported.^{18, 19, 34} For the purpose of the current study, patients were re-examined by an independent physician (AK/JFH). Of the 26 eligible subjects with a teres major tendon transfer, 20 patients (77%) attended the follow-up visit with a mean follow-up of ten years (range 8 – 12). Of the 24 eligible subjects with a latissimus dorsi tendon transfer, 19 patients (79%) attended the follow-up visit with a mean follow-up of six years (range 5 – 8). Loss to follow-up is reported in Figure 1. Baseline characteristics of the 39 included patients are described in Table 1 and complications that occurred in all 50 eligible subjects are described in Table 2.

Clinical assessment

The primary outcome of this study was to assess shoulder function, described with the Constant Score (CS).⁶ Secondary outcomes were active range of motion, Visual Analogue Scale (VAS) for pain at rest, VAS for pain during movement of the arm and satisfaction with surgery. VAS for pain was reported by the patient on a 100mm bar, with 0mm indicating no pain, and 100mm indicating severe pain. Satisfaction was rated as either satisfied or unsatisfied with the outcome. Furthermore, we assessed health related general and disease-specific

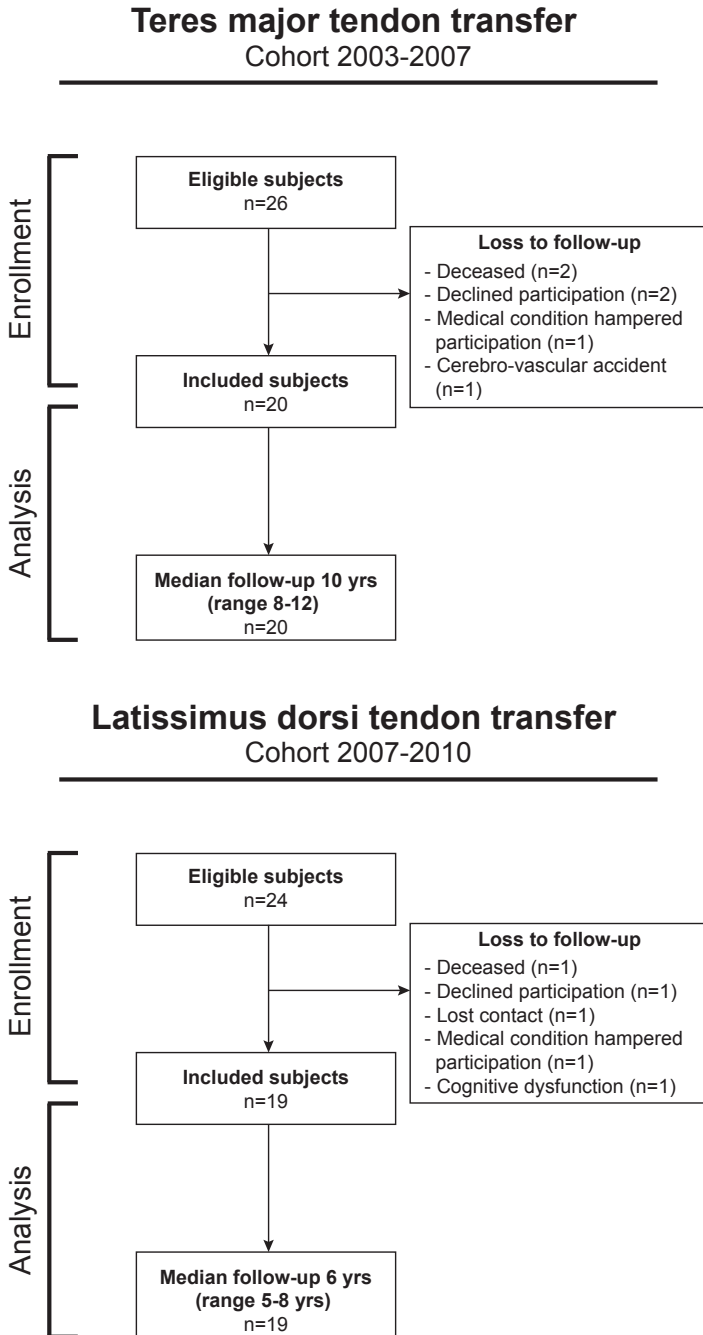


Figure 1. Flow-chart showing the number of included patients in the teres major tendon transfer cohort (left) and latissimus dorsi tendon transfer cohort (right).

quality-of-life at our final follow-up visit. The Short Form (SF)-12 was recorded to describe general health related quality-of-life after tendon transfer surgery.³⁶ The SF-12 expresses quality-of-life by means of a physical component summary (PCS) and mental component summary (MCS). To calculate the PCS and MCS, we used weights of indicator variables and constants that were obtained from a Dutch normative dataset and using the oblique rotation method.³⁰ Mean age- and sex-standardized scores (i.e. according to Dutch scores) were used to construct an age- and sex-corrected normative population.³⁰ This age- and sex-corrected normative population was created in order to investigate whether our patients did well when comparing patients with their counterparts in the general population. Disease-specific quality-of-life was recorded on the Western Ontario Rotator Cuff Index (WORC) with a score of 100% indicating an optimal shoulder-related quality-of-life.²³

Table 1. Baseline characteristics of included subjects

	<i>Teres major transfer</i> Cohort 2003 to 2007 n= 20	<i>Latissimus dorsi transfer</i> Cohort 2007 to 2010 n= 19
Age, yrs. †	60 (47 to 71)	59 (47 to 77)
Follow-up, mths. †	121 (94 to 144)	75 (58 to 92)
Male sex, n (%) ‡	9 (45%)	11 (58%)
Involved side (right) ‡	13 (65%)	16 (84%)
Dominant arm affected ‡	14 (70%)	14 (74%)
History of failed cuff repair ‡	7 (35%)	6 (32%)

Description of baseline characteristics of patients in both study cohorts. Data are described by the mean with range (†) and absolute numbers with a percentage (‡). Abbreviations: yrs, years; mths, months.

Table 2. Complications rate of the eligible patients

	<i>Teres major transfer</i> Cohort 2003 to 2007 n= 26	<i>Latissimus dorsi transfer</i> Cohort 2007 to 2010 n= 24
Postoperative re-interventions, n (%)		
<i>RSA for cuff tear arthroplasty</i>	1 (4%)	0
<i>Hemi-arthoplasty for cuff tear arthroplasty</i>	0	1 (4%)
<i>Subscapularis repair</i>	2 (8%)	2 (8%)
<i>Scar correction</i>	1 (4%)	0 (0%)
Complications, n (%)		
<i>Wound infection</i>	1 (4%)	0
<i>Hematoma</i>	1 (4%)	0
<i>Pulmonary embolism</i>	1 (4%)	0
<i>Atrial fibrillation</i>	1 (4%)	0

Abbreviations: RSA, reversed shoulder arthroplasty.

Surgical technique

All tendon transfers were performed by one out of three orthopaedic surgeons (JN, RG-GHN or PMR), using a two-incision surgical technique (Figure 2); surgical details have been described earlier.^{18, 19} In short, patients were positioned in the lateral decubitus position with the arm in approximately 60 degrees of abduction and in internal rotation with the elbow 90 degrees flexed. First, a curved incision was made just proximal to the posterior axillary fold. Dissection was continued to expose the teres major and latissimus dorsi, and the anatomical insertion sites. The teres major was carefully separated from the latissimus dorsi. Either the teres major or latissimus dorsi was detached from the periosteum of the humeral shaft once the quadrangular space and radial nerve in the triangular interval were clearly identified. The tendon (i.e. either teres major or latissimus dorsi tendon) was marked by absorbable sutures and the muscle belly was released from the axillary fat. Subsequently, a second deltoid split incision was made to expose the proximal humerus. The tendon was tunneled underneath the posterior part of the deltoid and over the long head of the triceps brachii muscle. The teres major or latissimus dorsi tendon was re-attached using RC anchors (DePuy Mitek Inc., Warsaw, Indiana, USA) with the arm in slight abduction and full external rotation onto the lateral side of the major tubercle, caudal to the supraspinatus footprint, and ventral to the infraspinatus footprint. We did not attempt to close RC defects. No additional procedures (e.g. acromioplasty) were conducted.

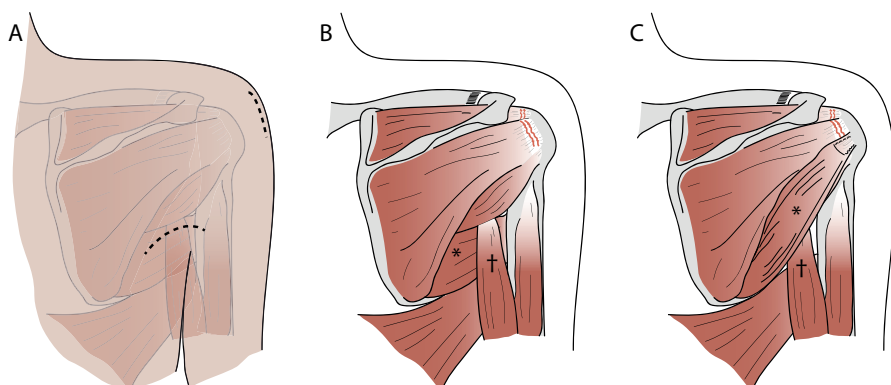


Figure 2. Surgical exposure and tendon insertion. A two-incision surgical technique was used: a curved incision was made just proximal to the posterior axillary fold and a deltoid split incision was made to expose the proximal humerus (Figure 2A). The preoperative anatomy is projected in Figure 2B. The deltoid muscle is removed from these illustrations. The teres major (*) runs underneath the long head of the triceps brachii muscle (†). In Figure 2C, the anatomy after transfer visualised. The teres major tendon (*) is tunneled underneath the posterior part of the deltoid and over the long head of the triceps brachii muscle (†). The teres major is inserted onto the lateral side of the major tubercle.

Following wound closure, the arm was immobilized in a shoulder brace with the arm in 0° of abduction and 0° of external rotation for six weeks. After six weeks, active movements were started under supervision of a physiotherapist. Strengthening exercises were allowed after three months.

Statistical analysis

Parametric data were described with means and range, nonparametric data were expressed with medians and interquartile range (IQR). Considering the repeated measurements and nonparametric distribution, generalized estimating equations were applied to assess changes in Constant Score (i.e. dependent variable) over time. Similar analyses were performed for VAS for pain. An autoregressive covariance structure of order one with heterogeneous variance was used to model correlated errors between consecutive assessment within a subject. The fixed factor was time (i.e. preoperative, at one years and at final follow-up). We expressed the change in outcome over time together with its 95% confidence interval (CI). These statistical analyses were performed using IBM SPSS statistics for Windows (version 20.0, IBM Corp, 2011, Armonk, New York, USA). A one-sample Student's t-test was performed to compare quality-of-life after a tendon transfer with quality-of-life of an age- and sex-corrected normalised population. These analyses were conducted using GraphPad Prism software for Windows (version 5.0, GraphPad software, La Jolla, California, USA). Significance level was set on a two-sided P value of 0.05.

RESULTS

Teres major tendon transfer

At a mean of 10 years (range 8 – 12 years) after teres major transfer, the median CS was 54 points, which was 23 points (95%CI 14.6 – 30.9, $P < 0.001$) higher than the preoperative score. The improvements in observed active forward elevation, abduction and external rotation in 90° of shoulder abduction were essentially preserved at ten years' follow-up (Table 3, Figure 3). We also observed a persistent reduction in pain. The CS at ten years' follow-up score was statistically significantly lower than at one year post-surgery (-8 points; 95%CI -14.5 – -0.4, $P = 0.037$), but no differences in VAS for pain at rest (5mm; 95%CI -5.3 – 15.5, $P = 0.337$) or during movement (10mm; 95%CI -7.5 – 28.0, $P = 0.259$) were observed. Of our 26 subjects eligible for participation, four (15%) patients were re-operated within ten years' follow-up (Table 2). Of 20 participants, 16 (80%) were satisfied with the results of the tendon transfer.

Table 3. Clinical outcomes after teres major tendon transfer

	Pre-operative	Follow-up at 1 yr.			
			Improvement (95% CI)	P value	
Forward flexion [†] , °	70 (91)	100 (70)	19 (-4.1 – 41.9)	0.107	
Abduction [†] , °	70 (91)	100 (100)	17 (0.7 – 32.9)	0.040 [*]	
External rotation in 90° abduction [†] , °	45 (60)	60 (28)	21 (3.5 – 39.4)	0.019 [*]	
Constant Score [†] , points	35 (25)	68 (19)	30 (21.9 – 38.5)	<0.001 [†]	
VAS pain at rest [†] , mm	45 (69)	5 (23)	-27 (-41.0 – -12.1)	<0.001 [†]	
VAS pain on movement [†] , mm	49 (43)	0 (21)	-41 (-52.5 – -29.0)	<0.001 [†]	
		Follow-up at 10 yrs.			
			Improvement (95% CI)	P value	
Forward flexion [†] , °		125 (54)	28 (3.8 – 52.2)	0.023 [*]	
Abduction [†] , °		123 (78)	26 (6.2 – 46.3)	0.010 [*]	
External rotation in 90° abduction [†] , °		43 (39)	6 (-8.3 – 20.9)	0.400	
Constant Score [†] , points		54 (29)	23 (14.6 – 30.9)	<0.001 [†]	
VAS pain at rest [†] , mm		4 (23)	-21 (-38.9 – -4.0)	0.016 [*]	
VAS pain on movement [†] , mm		14 (43)	-31 (-45.1 – -16.0)	<0.001 [†]	

Shoulder function and pain scores at baseline, at a mean follow-up of one year and at final follow-up assessed with generalized estimating equations. Abbreviations: CI, confidence interval; VAS, visual analogue scale; yrs, years, mm, millimetre.

^{*} Statistically significant difference at P < 0.05.

[†] Median and interquartile range (IQR).

Latissimus dorsi tendon transfer

The median CS at a mean of six years (range 5 – 8 years) after latissimus dorsi transfer was 75 points and was 32 points (95%CI 23.4 – 40.2, P < 0.001) higher than the preoperative score. The improvements in observed active forward elevation, abduction and external rotation during in 90° of shoulder abduction were preserved at six years' follow-up (Table 4, Figure 4). We also observed a lasting reduction in pain at rest and during movement of the arm. The final follow-up score was not statistically significantly different from the outcome at one year for the CS (1 point; 95%CI -6.3 – 7.4, P = 0.880), VAS for pain at rest (6mm; 95%CI -1.7 – 13.8, P = 0.125), but VAS during movement was significantly increased (15mm; 95%CI 0 – 30.4, P = 0.050). Of our 24 subjects eligible for participation, three (13%) patient received additional surgery within six years' follow-up (Table 2). The majority of the patients (89%, 17 out of 19 participants) was satisfied with their outcomes.

Quality-of-life after a tendon transfer

The mean PSC and MSC after teres major tendon transfer were 41.1 points and 46.9 points, respectively (Figure 5). The PCS and MSC were lower in the surgical group than in the age- and sex-corrected normative population with 6 points (95%CI -11.31 – -1.12, P = 0.019) and 2 points (95%CI -7.73 – 2.92, P = 0.356), respectively. The median postoperative WORC score at ten years was 54% (IQR 35).

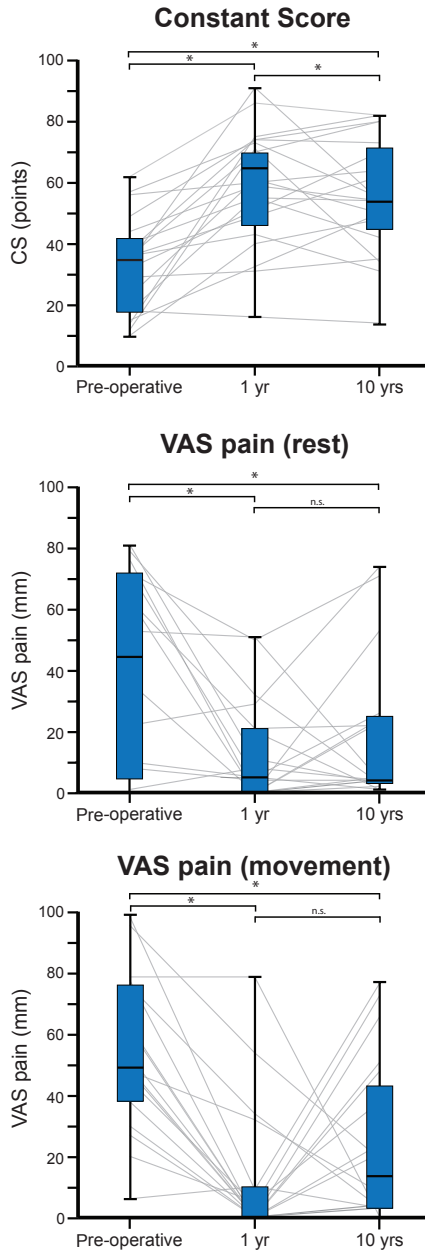


Figure 3. Results of the teres major tendon transfer. Plots show the course of shoulder pain and function after a teres major tendon transfer from preoperative, at a mean follow-up of two years and at a mean follow-up of ten years in individual patients (grey lines). Boxplots indicate the median, interquartile range and range of outcome measures.

* Statistically significant difference at $P < 0.05$.

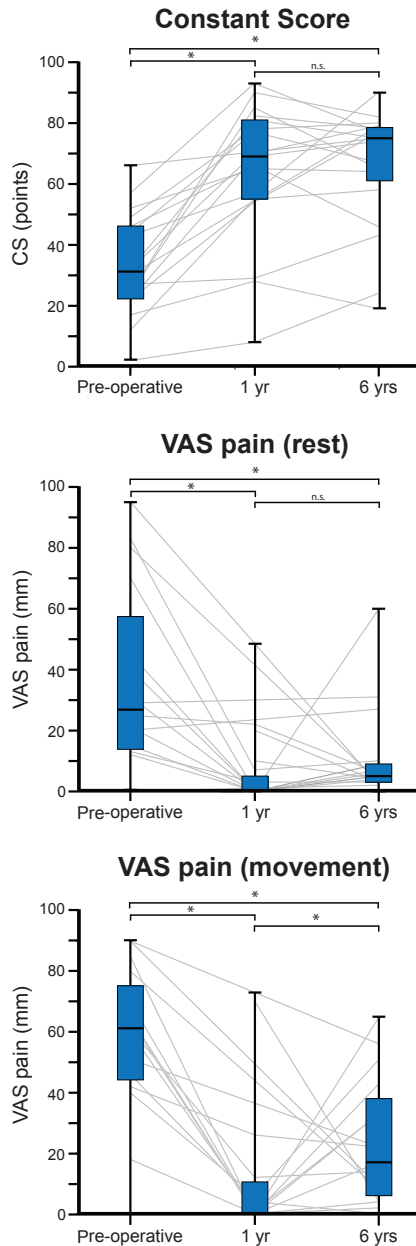


Figure 4. Results of the latissimus dorsi tendon transfer. Plots show the course of shoulder pain and function after a latissimus dorsi tendon transfer from preoperative, at a mean follow-up of two years and at a mean follow-up of six years in individual patients (grey lines). Boxplots indicate the median, interquartile range and range of outcome measures.

* Statistically significant difference at $P < 0.05$.

Table 4. Clinical outcomes after latissimus dorsi tendon transfer

	Pre-operative	Follow-up at 1 yr.			
		Improvement (95% CI)		P value	
Forward flexion [†] , °	90 (70)	130 (60)	37	(15.8 – 57.3)	0.001 [*]
Abduction [†] , °	80 (60)	120 (60)	43	(30.2 – 70.8)	<0.001 [*]
External rotation in 90° abduction [†] , °	20 (48)	65 (20)	42	(26.0 – 58.9)	0.008 [*]
Constant Score [‡] , points	31 (25)	69 (27)	31	(22.4 – 40.1)	<0.001 [*]
VAS pain at rest [‡] , mm	27 (50)	0 (7)	-32	(-46.4 – -17.5)	<0.001 [*]
VAS pain on movement [‡] , mm	61 (38)	0 (9)	-49	(-65.3 – -32.1)	<0.001 [*]

	Follow-up at 6 yrs.			
	Improvement (95% CI)		P value	
Forward flexion [†] , °	150 (35)	42	(21.8 – 61.8)	<0.001 [*]
Abduction [†] , °	160 (75)	51	(30.2 – 70.8)	<0.001 [*]
External rotation in 90° abduction [†] , °	70 (65)	28	(7.6 – 49.2)	0.008 [*]
Constant Score [‡] , points	75 (21)	32	(23.4 – 40.2)	<0.001 [*]
VAS pain at rest [‡] , mm	5 (6)	-26	(-41.8 – -9.9)	0.001 [*]
VAS pain on movement [‡] , mm	17 (39)	-33	(-48.5 – -18.4)	<0.001 [*]

Shoulder function and pain scores at baseline, at a mean follow-up of one year and at final follow-up assessed with generalized estimating equations. Abbreviations: CI, confidence interval; VAS, visual analogue scale; yrs, years, mm, millimetre.

^{*} Statistically significant difference at P < 0.05.

[†] Median and interquartile range (IQR).

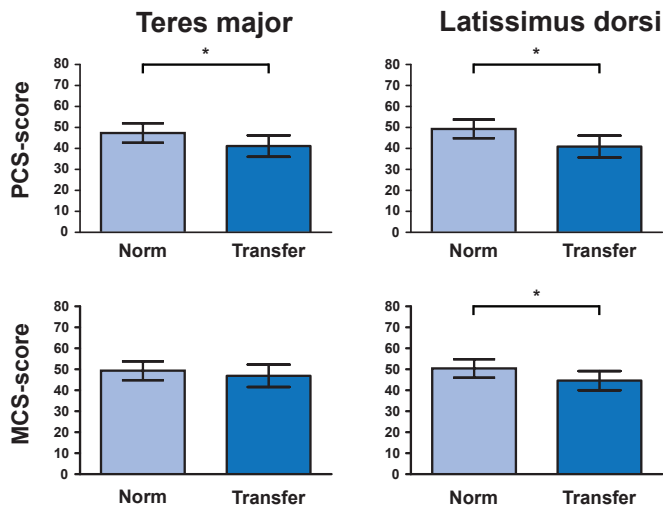


Figure 5. General quality-of-life after a tendon transfer. Comparison of mean (with 95% Confidence interval) general quality-of-life between the tendon transfer group and age- and sex-corrected normative population. Abbreviations: PCS, physical component summary; MCS, mental component summary; Norm, age- and sex-corrected normative population.

^{*} Statistically significant difference at P < 0.05.

After a latissimus dorsi transfer, mean PSC and MSC were 40.9 and 44.6 points, respectively. The difference in score was 8 points (95%CI -13.62 – -3.21, $P = 0.003$) and 6 points (95%CI -10.38 – -1.23, $P = 0.016$) lower after surgery for the PCS and MSC score, respectively. The median WORC after a latissimus dorsi tendon transfer was 61% (IQR 42).

DISCUSSION

Postoperative gain in shoulder function and relieve of pain after teres major tendon transfer at ten years were persistent through follow-up. We also showed an increase in shoulder function and reduction in pain at mid-term follow-up after latissimus dorsi tendon transfer. Quality-of-life was slightly decreased in patients who underwent tendon transfer surgery for massive irreparable posterosuperior RC tears when compared to a normalised control group.

Our results of the teres major tendon transfer at ten years' follow-up are comparable to the long-term follow-up reported outcomes of the latissimus dorsi transfer in literature. Both Gerber et al. (CS from 47 to 64 points) and El-Azab et al. (CS 36 from to 62 points) described an improvement in shoulder function with a follow-up of more than 9 years after latissimus dorsi transfer.^{11, 13} Likewise, our satisfaction rate of 80% and 4% conversion rate to a (reversed) shoulder arthroplasty after a teres major tendon transfer were comparable to these prior reports concerning latissimus dorsi tendon transfer.^{11, 13} While several other groups have reported on the postoperative outcomes of the latissimus dorsi tendon transfer^{11, 13, 14, 18, 21, 29, 31}, just Celli et al. described their mid-term experience with teres major tendon transfer in the treatment of an irreparable massive rotator cuff tear.^{3, 4} Celli et al. showed a postoperative functional gain on the mean CS of 22 point at 14 months, and 35 points at 3 years.^{3, 4} These mid-term results are comparable to our findings at 2 years.¹⁹ In this study, we are the first to show that the improvement in shoulder function and pain after a teres major tendon transfer is maintained over the course of ten years, and these data are equivalent to long-term results of the latissimus dorsi tendon transfer.

Teres major tendon transfer was initially described by L'Episcopo in obstetrical plexus injuries.²⁵ In the treatment of massive irreparable posterosuperior RC tears, Gerber et al. introduced the latissimus dorsi tendon transfer.¹⁴ The teres major transfer could be favourable as substitute for the infraspinatus muscle due to its scapulohumeral orientation.^{3, 4} A teres major transfer will result in a more functional augmentation in biomechanical alignment with the action of the infraspinatus. This idea was further propagated by model simulations that identified the teres major tendon transfer as the optimal procedure to restore external rotation leading to improved activities of daily living.²⁶ Following a teres major tendon transfer, large functional improvements were observed like washing the contralateral axilla and reaching. The transfer of the latissimus dorsi resulted in a lower number of success-

ful functional movement simulations (e.g. perineal care).²⁶ Theoretically, it may become more difficult to push on the arms of a chair to stand up after latissimus dorsi transfer. During surgical exposure, the teres major tendon is easily identified because it overlies the latissimus dorsi. Nevertheless, the length of the teres major tendon is limited, making it technically more demanding if the tendon is not cut flush from the bone.² The teres major has a reliable vascular supply, and has sufficient structural properties with respect to tension and excursion to reach the lateral site of the supraspinatus footprint at the greater tuberosity.^{2, 19, 20, 35} When attaching the tendon at this location, the transferred muscle has a biomechanically good position that allows the delivery of external rotation and elevation during arm abduction.^{26, 28}

The effectiveness of transfer surgery is frequently assigned to an active contribution of the transferred muscle in shoulder movement, ideally with synergistic muscle activity during abduction and external rotation.^{1, 9, 14, 18, 21, 34} Its effectiveness may also rely on reinstating humeral head position via increased caudally directed forces counteracting increased deltoid forces, and a potential tenodesis effect. Interestingly, inferior functional results were reported in the presence of insufficient torques produced by the subscapularis or teres minor muscle.^{1, 7, 14} Both muscles are assumed to have an important stabilizing function in the absence of forces generated by the infraspinatus.³⁷ In a cadaveric model that simulated the distribution of forces within the glenohumeral joint after a latissimus dorsi tendon transfer, activation of the subscapularis muscle has been found to counteract anterior translation of the humerus.³⁷ This finding suggests that a torn subscapularis muscle might be considered as a contraindication for tendon transfer.³⁷ Similarly, deficiency of the teres minor has been associated with inferior postoperative shoulder function because its activity may contribute to external rotation.³¹

In recent years the indication for reversed total shoulder arthroplasty has expanded and has become a therapeutic option for patients with a massive RC tear even in the absence of glenohumeral osteoarthritis.¹⁰ Revision rates of reversed total shoulder arthroplasty up to 38% at ten years' follow-up are a considerable cause for concerns, especially in a relatively young patient.¹⁰ Postoperative external rotation deficits may further increase the need for additional tendon transfers to recover activities of daily living.³³ A tendon transfer should be considered as an alternative to reversed total shoulder arthroplasty in posterosuperior RC tears, especially since a reversed total shoulder arthroplasty remains an option if function deteriorate over time.

There are several limitations concerning this study. Firstly, baseline Constant scores were obtained via a retrospective chart-review and follow-up evaluations were performed by a different examiner. The observed improvement in all outcomes are substantial and assumed to be beyond measurement error that might have been introduced by inter-observer variability (+/-18 points) and the change that is considered clinically relevant.^{5, 6, 17, 24} Secondly, not all eligible subjects were available for this follow-up study, which can be considered a

weakness. However, loss of follow-up was frequently related to death, cerebrovascular event or dementia, and thus we assume that loss of follow-up has not severely skewed our conclusions. Finally, we did not evaluate the progression of radiologic features in our subjects.

Future research may further elucidate the value and patient specific indication for tendon transfer surgery in patients with a massive posterosuperior RC tear. This study provided data regarding the number of re-interventions and long-term functional improvement after teres major tendon transfer. Since both tendons, the teres major and the latissimus dorsi, yield potential advantages, a randomised controlled trial is needed to compare the effectiveness of both tendon transfers. This trial is underway (Dutch Trial Register no. 4721).

CONCLUSION

Our long-term data indicate that the teres major transfer restores shoulder function and reduces pain in patients with a massive irreparable posterosuperior RC tear. We are the first to show that improvement in shoulder function after teres major tendon transfer lasts for over ten years. General health related quality-of-life after tendon transfer surgery was lower than in a normalised population. Since results at ten years' follow-up are comparable to the outcomes after a latissimus dorsi as reported in literature, the teres major might be an alternative to latissimus dorsi tendon transfer. For that matter, we consider both tendon transfers as a functional and long-term surgical option in the treatment of massive posterosuperior RC tears.

ACKNOWLEDGEMENTS

The authors gratefully acknowledge the work of P.M. Rozing MD, PhD for his initial efforts and contribution to the collection of data. This study is funded by the Dutch Arthritis Society (grant number 2013-1-303)

REFERENCES

- 1 Aoki M, Okamura K, Fukushima S, Takahashi T, Ogino T. Transfer of latissimus dorsi for irreparable rotator-cuff tears. *J Bone Joint Surg Br* 1996;78:761-766.
- 2 Buijze GA, Keereweer S, Jennings G, Vorster W, Debeer J. Musculotendinous transfer as a treatment option for irreparable posterosuperior rotator cuff tears: teres major or latissimus dorsi? *Clin Anat* 2007;20:919-923. DOI: 10.1002/ca.20547
- 3 Celli A, Marongiu MC, Rovesta C, Celli L. Transplant of the teres major in the treatment of irreparable injuries of the rotator cuff (long-term analysis of results). *Chir Organi Mov* 2005;90:121-132.
- 4 Celli L, Rovesta C, Marongiu MC, Manzieri S. Transplantation of teres major muscle for infraspinatus muscle in irreparable rotator cuff tears. *J Shoulder Elbow Surg* 1998;7:485-490. DOI: 10.1016/S1058-2746(98)90199-9
- 5 Conboy VB, Morris RW, Kiss J, Carr AJ. An evaluation of the Constant-Murley shoulder assessment. *J Bone Joint Surg Br* 1996;78:229-232.
- 6 Constant CR, Murley AH. A clinical method of functional assessment of the shoulder. *Clin Orthop Relat Res* 1987;160-164.
- 7 Costouros JG, Espinosa N, Schmid MR, Gerber C. Teres minor integrity predicts outcome of latissimus dorsi tendon transfer for irreparable rotator cuff tears. *J Shoulder Elbow Surg* 2007;16:727-734. DOI: 10.1016/j.jse.2007.02.128
- 8 Davidson JF, Burkhart SS, Richards DP, Campbell SE. Use of preoperative magnetic resonance imaging to predict rotator cuff tear pattern and method of repair. *Arthroscopy* 2005;21:1428. DOI: 10.1016/j.arthro.2005.09.015
- 9 de Groot JH, van de Sande MA, Meskers CG, Rozing PM. Pathological Teres Major activation in patients with massive rotator cuff tears alters with pain relief and/or salvage surgery transfer. *Clin Biomech (Bristol , Avon)* 2006;21 Suppl 1:S27-S32. DOI: 10.1016/j.clinbiomech.2005.09.011
- 10 Ek ET, Neukom L, Catanzaro S, Gerber C. Reverse total shoulder arthroplasty for massive irreparable rotator cuff tears in patients younger than 65 years old: results after five to fifteen years. *J Shoulder Elbow Surg* 2013;22:1199-1208. DOI: 10.1016/j.jse.2012.11.016
- 11 El-Azab HM, Rott O, Irlenbusch U. Long-term follow-up after latissimus dorsi transfer for irreparable posterosuperior rotator cuff tears. *J Bone Joint Surg Am* 2015;97:462-469. DOI: 10.2106/jbjs.m.00235
- 12 Fuchs B, Weishaupt D, Zanetti M, Hodler J, Gerber C. Fatty degeneration of the muscles of the rotator cuff: assessment by computed tomography versus magnetic resonance imaging. *J Shoulder Elbow Surg* 1999;8:599-605. DOI: 10.1016/S1058-2746(99)90097-6
- 13 Gerber C, Rahm SA, Catanzaro S, Farshad M, Moor BK. Latissimus dorsi tendon transfer for treatment of irreparable posterosuperior rotator cuff tears: long-term results at a minimum follow-up of ten years. *J Bone Joint Surg Am* 2013;95:1920-1926. DOI: 10.2106/JBJS.M.00122
- 14 Gerber C, Vinh TS, Hertel R, Hess CW. Latissimus dorsi transfer for the treatment of massive tears of the rotator cuff. A preliminary report. *Clin Orthop Relat Res* 1988;51-61.
- 15 Grimberg J, Kany J. Latissimus dorsi tendon transfer for irreparable postero-superior cuff tears: current concepts, indications, and recent advances. *Curr Rev Musculoskelet Med* 2014;7:22-32. DOI: 10.1007/s12178-013-9196-5
- 16 Harryman DT, 2nd, Hettrich CM, Smith KL, Campbell B, Sidles JA, Matsen FA, 3rd. A prospective multipractice investigation of patients with full-thickness rotator cuff tears: the importance of comorbidities, practice, and other covariables on self-assessed shoulder function and health status. *J Bone Joint Surg Am* 2003;85-a:690-696.
- 17 Henseler JF, Kolk A, van der Zwaal P, Nagels J, Vliet Vlieland TP, Nelissen RG. The minimal detectable change of the Constant score in impingement, full-thickness tears, and massive rotator cuff tears. *J Shoulder Elbow Surg* 2014. DOI: 10.1016/j.jse.2014.07.003
- 18 Henseler JF, Nagels J, Nelissen RG, de Groot JH. Does the latissimus dorsi tendon transfer for massive rotator cuff tears remain active postoperatively and restore active external rotation? *J Shoulder Elbow Surg* 2013. DOI: 10.1016/j.jse.2013.07.055

- 19 Henseler JF, Nagels J, van der Zwaal P, Nelissen RG. Teres major tendon transfer for patients with massive irreparable posterosuperior rotator cuff tears: Short-term clinical results. *Bone Joint J* 2013;95-B:523-529. DOI: 10.1302/0301-620X.95B4.30390
- 20 Herzberg G, Urien JP, Dimnet J. Potential excursion and relative tension of muscles in the shoulder girdle: relevance to tendon transfers. *J Shoulder Elbow Surg* 1999;8:430-437. DOI: 10.1016/S1058-2746(99)90072-1
- 21 Irlenbusch U, Bernsdorf M, Born S, Gansen HK, Lorenz U. Electromyographic analysis of muscle function after latissimus dorsi tendon transfer. *J Shoulder Elbow Surg* 2008;17:492-499. DOI: 10.1016/j.jse.2007.11.012
- 22 Kellgren JH, Lawrence JS. Radiological assessment of osteo-arthritis. *Ann Rheum Dis* 1957;16:494-502. DOI: 10.1136/ard.16.4.494
- 23 Kirkley A, Alvarez C, Griffin S. The development and evaluation of a disease-specific quality-of-life questionnaire for disorders of the rotator cuff: The Western Ontario Rotator Cuff Index. *Clin J Sport Med* 2003;13:84-92. DOI: 10.1097/00042752-200303000-00004
- 24 Kukkonen J, Kauko T, Vahlberg T, Joukainen A, Aarimaa V. Investigating minimal clinically important difference for Constant score in patients undergoing rotator cuff surgery. *J Shoulder Elbow Surg* 2013;22:1650-1655. DOI: 10.1016/j.jse.2013.05.002
- 25 L'Episcopo JB. Tendon transplantation in obstretical paralysis. *Am J Surg* 1934;25:122-125.
- 26 Magermans DJ, Chadwick EK, Veeger HE, Rozing PM, van der Helm FC. Effectiveness of tendon transfers for massive rotator cuff tears: a simulation study. *Clin Biomech* 2004;19:116-122. DOI: 10.1016/j.clinbiomech.2003.09.008
- 27 Magermans DJ, Chadwick EK, Veeger HE, van der Helm FC. Requirements for upper extremity motions during activities of daily living. *Clin Biomech* 2005;20:591-599. DOI: 10.1016/j.clinbiomech.2005.02.006
- 28 Magermans DJ, Chadwick EK, Veeger HE, van der Helm FC, Rozing PM. Biomechanical analysis of tendon transfers for massive rotator cuff tears. *Clin Biomech* 2004;19:350-357. DOI: 10.1016/j.clinbiomech.2003.11.013
- 29 Miniaci A, MacLeod M. Transfer of the latissimus dorsi muscle after failed repair of a massive tear of the rotator cuff. A two to five-year review. *J Bone Joint Surg Am* 1999;81:1120-1127. DOI: 10.2106/00004623-199908000-00007
- 30 Mols F, Pelle AJ, Kupper N. Normative data of the SF-12 health survey with validation using postmyocardial infarction patients in the Dutch population. *Qual Life Res* 2009;18:403-414. DOI: 10.1007/s1136-009-9455-5
- 31 Nove-Josserand L, Costa P, Liotard JP, Safar JF, Walch G, Zilber S. Results of latissimus dorsi tendon transfer for irreparable cuff tears. *Orthop Traumatol Surg Res* 2009;95:108-113. DOI: 10.1016/j.otsr.2008.10.002
- 32 Patte D. Classification of rotator cuff lesions. *Clin Orthop Relat Res* 1990:81-86.
- 33 Puskas GJ, Germann M, Catanzaro S, Gerber C. Secondary latissimus dorsi transfer after failed reverse total shoulder arthroplasty. *J Shoulder Elbow Surg* 2015;24:e337-344. DOI: 10.1016/j.jse.2015.05.033
- 34 Steenbrink F, Nelissen RG, Meskers CG, van de Sande MA, Rozing PM, de Groot JH. Teres major muscle activation relates to clinical outcome in tendon transfer surgery. *Clin Biomech* 2010;25:187-193. DOI: 10.1016/j.clinbiomech.2009.11.001
- 35 Wang AA, Strauch RJ, Flatow EL, Bigliani LU, Rosenwasser MP. The teres major muscle: an anatomic study of its use as a tendon transfer. *J Shoulder Elbow Surg* 1999;8:334-338. DOI: 10.1016/S1058-2746(99)90156-8
- 36 Ware J, Jr., Kosinski M, Keller SD. A 12-Item Short-Form Health Survey: construction of scales and preliminary tests of reliability and validity. *Med Care* 1996;34:220-233.
- 37 Werner CM, Zingg PO, Lie D, Jacob HA, Gerber C. The biomechanical role of the subscapularis in latissimus dorsi transfer for the treatment of irreparable rotator cuff tears. *J Shoulder Elbow Surg* 2006;15:736-742. DOI: 10.1016/j.jse.2005.11.002
- 38 Yamamoto A, Takagishi K, Osawa T, Yanagawa T, Nakajima D, Shitara H et al. Prevalence and risk factors of a rotator cuff tear in the general population. *J Shoulder Elbow Surg* 2010;19:116-120. DOI: 10.1016/j.jse.2009.04.006