



Universiteit
Leiden
The Netherlands

EXT-related pathways are not involved in the pathogenesis of dysplasia epiphysealis hemimelica and metachondromatosis

Bovée, J.V.M.G.; Hameetman, L.; Kroon, H.M.; Aigner, T.; Hogendoorn, P.C.W.

Citation

Bovée, J. V. M. G., Hameetman, L., Kroon, H. M., Aigner, T., & Hogendoorn, P. C. W. (2006). EXT-related pathways are not involved in the pathogenesis of dysplasia epiphysealis hemimelica and metachondromatosis. *Journal Of Pathology*, 209, 411-419. Retrieved from <https://hdl.handle.net/1887/8140>

Version: Not Applicable (or Unknown)

License:

Downloaded from: <https://hdl.handle.net/1887/8140>

Note: To cite this publication please use the final published version (if applicable).

Original Paper

EXT-related pathways are not involved in the pathogenesis of dysplasia epiphysealis hemimelica and metachondromatosis

JVMG Bovée,¹ L Hameetman,¹ HM Kroon,² T Aigner³ and PCW Hogendoorn^{1*}

¹Department of Pathology, Leiden University Medical Centre, The Netherlands

²Department of Radiology, Leiden University Medical Centre, The Netherlands

³Department of Pathology, University of Erlangen-Nürnberg, Germany

*Correspondence to:

Professor PCW Hogendoorn,
Department of Pathology, Leiden
University Medical Centre, PO
Box 9600, LI-Q, 2300 RC
Leiden, The Netherlands.
E-mail:
P.C.W.Hogendoorn@umc.nl

Abstract

Dysplasia epiphysealis hemimelica (DEH) and metachondromatosis (MC) are considered in the differential diagnosis of solitary and hereditary osteochondromas. Both are rare disorders with DEH demonstrating cartilaginous overgrowth of an epiphysis and MC exhibiting synchronous enchondromas and osteochondromas. Ten cases of DEH and two of MC were compared with osteochondromas at the histological and molecular level. Histologically, clumping of chondrocytes within a fibrillary chondroid matrix is characteristic of DEH, while osteochondromas and MC display the characteristic growth plate architecture. Using cDNA microarray analysis we demonstrate that DEH and MC cluster separately from osteochondromas and growth plates. The *EXT* genes, involved in the hereditary multiple osteochondromas syndrome, and downregulated in osteochondroma, were normally expressed in DEH and MC as shown by quantitative reverse transcriptase-polymerase chain reaction (qPCR). *EXT* is involved in heparan sulphate biosynthesis, important for Indian Hedgehog/ParaThyroid Hormone Like Hormone (IHH/PTHrP) growth plate signalling pathways. IHH/PTHrP signalling molecules were expressed in DEH and MC as shown by both qPCR and immunohistochemistry, suggesting that this pathway is active. This is in contrast to osteochondroma, in which PTHrP signalling is downregulated. Thus, lesions of DEH and MC are separate entities from osteochondroma as confirmed by their different cDNA and protein expression profiles. Downstream targets of *EXT*, which are downregulated in osteochondroma, are expressed in DEH and MC, suggesting that *EXT* signalling is not disturbed.

Copyright © 2006 Pathological Society of Great Britain and Ireland. Published by John Wiley & Sons, Ltd.

Keywords: chondrocytes; PTHrP and PTH1; growth factors; bone tumours; gene expression

Received: 17 November 2005

Revised: 17 January 2006

Accepted: 20 February 2006

Introduction

Dysplasia epiphysealis hemimelica (DEH, Trevor's disease, tarso-epiphyseal aclasis) and metachondromatosis (MC) are extremely rare disorders to be considered in the clinicoradiological and histological differential diagnosis of solitary or hereditary osteochondromas.

Osteochondromas are the most common benign bone tumours [1]. They are cartilage-capped bony outgrowths on the external surface of bone and contain a marrow cavity that is continuous with that of the underlying bone [1]. They develop in the first decade of life, increase in size into the second decade, and cease to grow when the growth plates close at or after puberty. About one in six osteochondromas arises within the context of Multiple Osteochondromas (MO, HME, *EXT*, diaphyseal aclasis) [2], an autosomal dominant orthopaedic disorder of multiple

osteochondromas, causing a variety of orthopaedic deformities [3] (reviewed by Hameetman *et al* [4]). The most important complication is malignant transformation, estimated to occur in <1% of solitary cases and 1–3% of cases of multiple osteochondromas [3].

DEH is a developmental disorder with cartilaginous overgrowth of a portion of one or more epiphyses or their equivalents, such as tarsal or carpal bones. The reported incidence is 1:1 000 000 [5]. It predominantly affects the lower extremity on one side of the body. It is usually restricted to either the medial (most frequent) or lateral side of the limb (hemimelic). Three different forms are recognized: localized (monostotic), classic (more than one area in a single extremity affected hemimelically), and generalized/severe (involving an entire single extremity) [6]. The classic form is most common. Similar to osteochondroma, DEH is usually diagnosed before the age of 15 years, more often in boys than in girls, and

growth of these lesions end at puberty as the growth plates close [5,7]. In contrast to MO, malignant transformation has not been reported so far [5] and there does not appear to be any genetic transmission [7–9]. Premature closure of the growth plate may lead to limb deformity and limb length discrepancy. Moreover, premature secondary osteoarthritis may occur. Histologically the lesion is alleged to be identical to osteochondroma [9,10]. Distinction from osteochondroma is made based on the characteristic radiological findings. Radiologically, DEH is characterized by a, usually irregular, bony outgrowth of an epiphysis of a tubular bone, a tarsal or carpal bone. Similar to osteochondroma, the cortex and bone marrow of the involved bone is continuous into (the basis of) this outgrowth (Figure 1). The localization in an epiphysis of a tubular bone, or in a tarsal or carpal bone is, however, in contrast with a common osteochondroma.

MC is a rare disorder exhibiting synchronously both multiple osteochondromas and enchondromas in children. It has an autosomal dominant mode of inheritance [11–13], but the disorder has not been mapped in the human genome so far. MC-related osteochondromas characteristically occur in the hands and feet, predominantly the digits and toes, and point towards the adjacent growth plate, while in MO the osteochondromas are mainly located in the long or other tubular bones and point away from the epiphysis [11]. The enchondromas, in contrast to enchondromas in patients with enchondromatosis (Ollier disease, Maffucci syndrome), mainly affect the iliac crests and the metaphyses of long bones [11]. Avascular necrosis is a frequent complication [14,15] and is hypothesized to be caused by interference with the integrity of the lateral epiphyseal vessels by the lesions [15]. Differentiation from MO is of great clinical significance

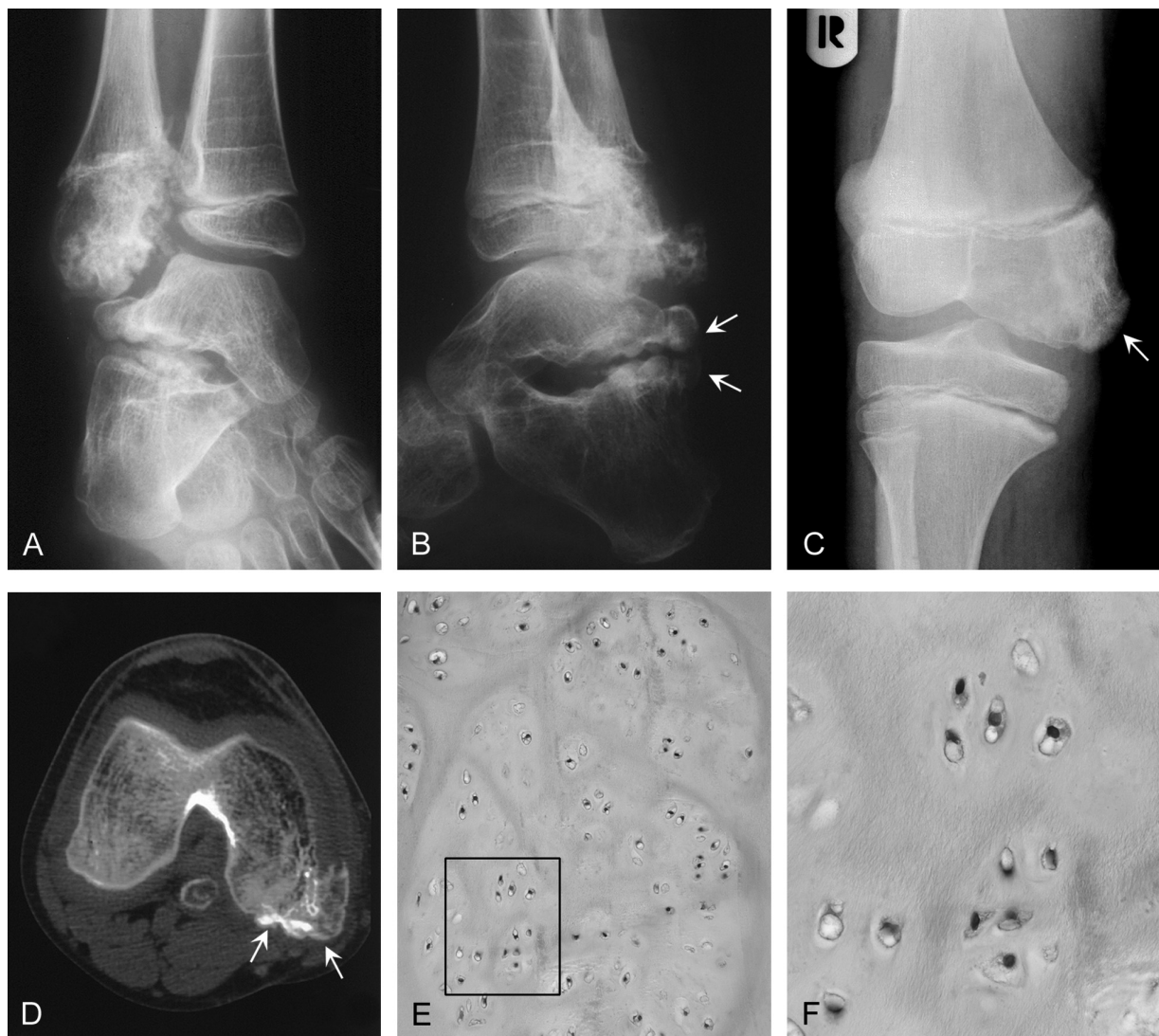

Figure 1. Dysplasia epiphysealis hemimelica. (A, B) Radiographs of DEH lesions of the right ankle of patient 1. The fibular lesion arises from the epiphysis and lies in close relation to the epiphyseal plate. The other lesions arise from the posterior and lateral aspect of the talus and the posterior aspect of the calcaneus (arrows); (C) DEH lesion of the right distal femur of patient 5 (arrow); (D) computed tomographic scan of the lesion shown in C, demonstrating all the radiological features of DEH; (E) micrograph of the lesion shown in A. In most DEH cases the chondrocytes lie in small clusters; (F) magnification of E, clearly demonstrating the fibrillary matrix around the chondrocyte clusters

because in patients with MC the lesions do not result in shortening or deformity of affected bones as in MO, and may spontaneously decrease in size or resolve completely, both clinically and radiologically [11,13].

The molecular defect in both DEH and MC is unknown and no molecular genetic studies have been reported. In contrast, two genes, *EXT1* and *EXT2*, located respectively on chromosomal bands 8q24 and 11p11–p12, have been identified for MO [16–18]. *EXT* displays its function in the biosynthesis of heparan sulphate (HS) proteoglycans, which are presumed to be important for diffusion of Indian Hedgehog (IHH), an important signalling molecule in the IHH/ParaThyroid Hormone Like Hormone (PTHrH) pathway that is responsible for chondrocyte proliferation and differentiation within the human growth plate. We have previously demonstrated that *EXT*-related signal transduction pathways are downregulated in hereditary and solitary osteochondromas [19]. In the present study, in addition to a histological and radiological evaluation, expression profiles of DEH and MC were compared with those of MO and the normal growth plate using cDNA microarray analysis as well as quantitative polymerase chain reaction (PCR) and immunohistochemistry specifically aimed at *EXT*-related pathways.

Materials and methods

Materials

Thirteen cases from 12 patients diagnosed with DEH or MC were retrieved from the files of the Netherlands Committee on Bone Tumours, containing >13 800 bone tumours or tumour-like lesions collected over the past 50 years. An additional case originated from the files of the Department of Pathology, University of Erlangen-Nurnberg, Germany. Radiological examination of all cases, including conventional X-rays for all patients and additional computed tomography

or magnetic resonance imaging scans for some of them, were reviewed by an expert bone tumour radiologist (HMK). Histological slides were reviewed by two specialist bone tumour pathologists (PCWH and JVMGB). The diagnosis was confirmed in 12 cases from 11 of the patients: two of MC and 10 of DEH. Two cases of supposed DEH were excluded since the diagnosis was changed to osteochondroma after radiological and histological review. Table 1 and Figures 1 and 2 show the patient data. Fresh frozen tissue was available in two cases for RNA isolation. All patient material was coded such that code breaking and correlation with clinical data were only possible for the physicians treating the patients. Research was conducted following the ethical guidelines of the national organization of scientific societies (FEDERA; "Code for Proper Secondary Use of Human Tissue in The Netherlands").

Histological evaluation

Histological criteria evaluated in DEH and MC cases are as follows: binucleated cells (absent, few, moderate, many), nuclear polymorphism (absent, moderate [open nuclei], severe), nucleoli (absent, present), distribution of cells (regular, irregular), clumping of chondrocytes (Figure 1) (absent, present), cellularity (low, intermediate, high), mitoses (absent, present), mucomyxoid matrix changes (absent, present), growth plate architecture (absent, partly present, complete), demarcation towards soft tissue (sharp, unsharp), fibrillary matrix (absent, present). A control group of osteochondromas was gender and age matched, including both actively growing, cellular lesions (in very young patients) and more mature and quiescent lesions, to avoid differences being due to different maturity of the lesions. DEH and osteochondromas were compared using the SPSS10.0 software package (SPSS Inc, Chicago, Illinois, USA) (Fisher's exact test).

Table 1. Patient data

Patient ID	Gender	Age at diagnosis (years)	Diagnosis	Location of resection	Other lesions	Family history
1	M	4	DEH	Distal fibula R	Talus R, calcaneus R	Unknown
2	M	5	DEH	Proximal tibia R	None	Unknown
3	M	7	DEH	Distal femur R	Talus R	Negative
4	F	41	DEH	Distal fibula L	1 st metatarsal L	Unknown
5	M	12	DEH	Distal femur R	None	Negative
6	F	3	DEH	Distal tibia R	None	Unknown
7	M	5	DEH	Talus R	None	Unknown
8	F	11	DEH	Talus R	Yes; see below	Unknown
9*	M	7	DEH	Navicular/cuboid/cuneiform bone R	None	Negative
10	F	5	MC	Metacarpals 2 and 5 L, 2 nd and 4 th digit R, metacarpal 1 R	Osteochondromas multiple digits, enchondroma 3 rd digit L	Negative†
11*	M	6	MC	3 rd and 4 th digit R, 2 nd metacarpal L	Enchondroma proximal femur R	Unknown

* Fresh frozen tissue available for RNA expression analysis.

† Mutation analysis for *EXT1* and *EXT2* was negative.

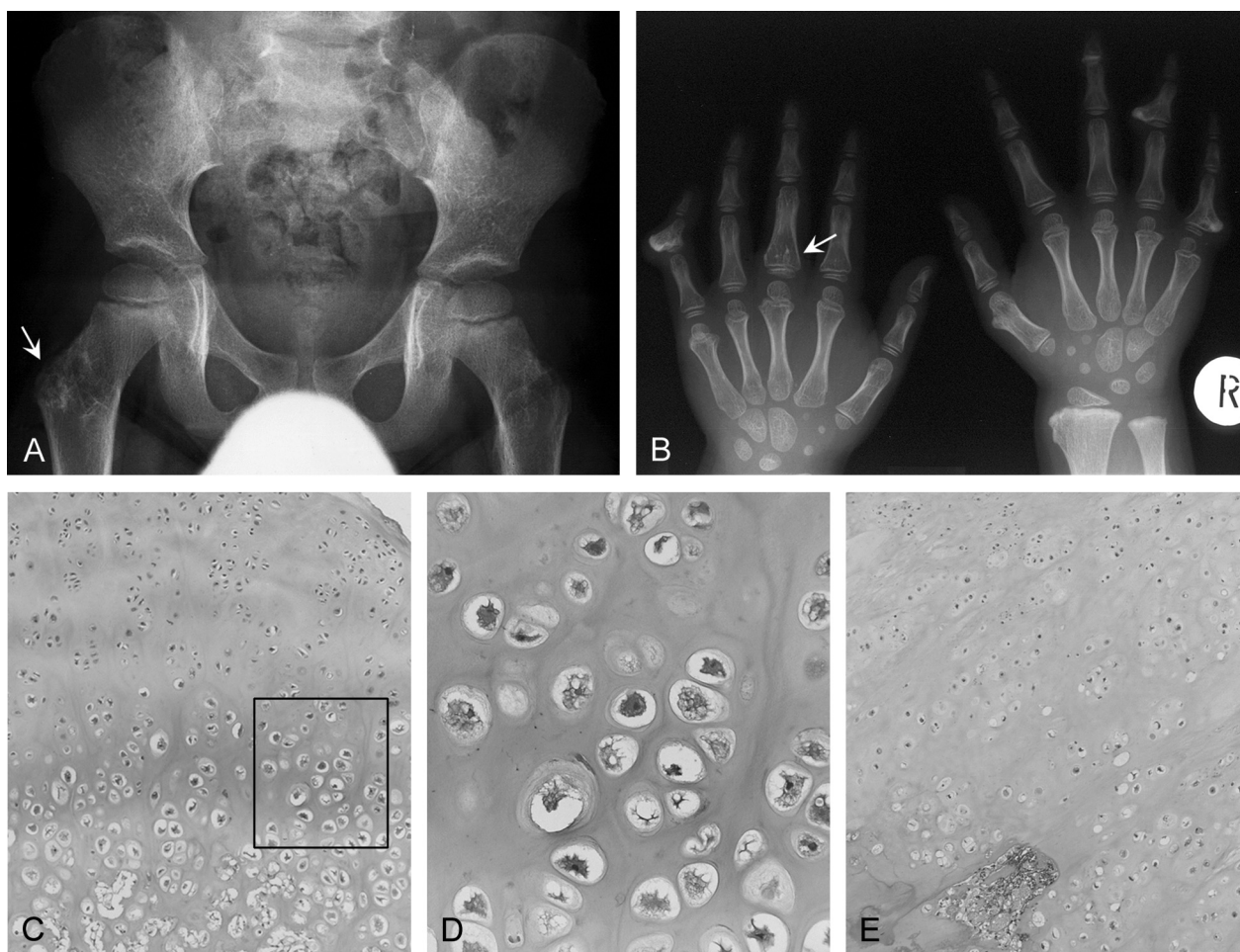


Figure 2. Metachondromatosis. (A) Radiograph of the pelvis of patient 11 with an enchondroma in the right proximal femur (arrow) adjacent to the apophysis of the greater trochanter; (B) radiograph of both hands of patient 10. Multiple osteochondromas pointing towards the epiphyses. Enchondroma in the proximal phalanx of the left third digit (arrow); (C, E) micrographs of osteochondroma-like lesions in metachondromatosis of patients 10 and 11, respectively; (D) magnification of C. These lesions are histologically indistinguishable from conventional osteochondroma recapitulating the normal growth plate architecture

Immunohistochemistry

Antibodies and controls

Formalin-fixed paraffin-embedded tissue was available for all 12 cases. Immunohistochemistry was performed as described previously [20]. Table 2 shows details of antibodies and controls. Commercially available antibodies against IHH and PTCH were not shown to work reliably in our hands and could therefore not be used to study IHH signalling. The 10E4 antibody reacts with an epitope that occurs in native HS chains [21]. The antibodies were tested for their susceptibility to formalin fixation using tissues fixed for 1–40 days to avoid false negative results. None of the antibodies showed diminished reactivity. For most antibodies, internal controls were available in the histological slides (Table 2) to exclude negativity of tumour cells caused by prolonged decalcification.

Scoring and evaluation

Slides were scored as described previously [19] by two observers independently (LH and JVMGB). Briefly,

staining intensity (0 = no staining; 1 = weak staining; 2 = moderate staining; 3 = strong staining) and the percentage of positive cells (0 = 0%; 1 = 1–24%; 2 = 25–49%; 3 = 50–74%; 4 = 75–100% positive tumour cells) were evaluated and the scores were added. As described previously, a score >3 was considered positive. Statistical analysis was performed with SPSS10.0 software. Immunohistochemical results for DEH were compared with those obtained previously for osteochondromas using Fisher's exact test. These data were partly published previously (PTHLH and BCL2 [22], p21 [19]). The median age of patients with osteochondromas was higher than that of patients with DEH and MC lesions (20.6 vs 6.5 years).

cDNA microarray analysis

mRNA was isolated as described [23] from frozen material from one DEH (patient No 9) and one MC case (No 11). cDNA microarray hybridization was performed as described previously [24]. Results were compared with those of six osteochondromas and four postnatal normal growth plates that were hybridized

Table 2. Details of antibodies

Antigen	Manufacturer	Mono-polyclonal	Staining	Positive control	Internal positive control	Dilution	Antigen retrieval
Syndecan-2 (10H4)	[36]	Mono (mouse IgG1)	Membrane, ECM	Normal growth plate	None	35 µg/ml	None
CD44 (7D8)	[37]	Mono (mouse IgG1)	Membrane, ECM	Normal skin	Osteocytes	10 µg/ml	None
CD44v3	Neomarkers	Mono (mouse IgG1)	Membrane, cytoplasm	Tonsil	None	1:15	Citrate
HS chains (10E4)	[21]	Mono (mouse IgM)	Membrane, ECM	Normal skin	Vessel walls, perichondrium	5 µg/ml	Citrate (120 min, 95 °C)
PTHrP	Oncogene	Poly (rabbit IgG)	Cytoplasm	Normal skin	None (occasionally osteoclasts)	1:25	Trypsin (30 min, 37 °C)
PTHrP	Upstate	Mono (mouse IgG1)	Nucleus	Normal skin	Osteoblasts, vessel walls	1:100	Citrate (120 min, 95 °C)
BCL2 (clone 124)	Roche	Mono (mouse IgG1)	Cytoplasm	Normal tonsil	Osteoclasts, lymphocytes	1:500	Citrate (120 min, 95 °C)
p21	Calbiochem	Mono (mouse IgG1)	Nucleus	Normal colon	None (occasionally vessels and osteoclasts)	1:400	Citrate (120 min, 95 °C)

ECM = extracellular matrix.

simultaneously [25]. The array data were clustered by unsupervised hierarchical clustering as described [26].

Quantitative PCR (qPCR)

Quantitative reverse transcriptase PCR experiments were performed on the same two DEH and MC cases as the microarray experiments. Total RNA (1 µg) was reverse transcribed to complementary DNA (cDNA) by using AMV Reverse Transcriptase (Roche Applied Science, Penzburg, Germany). qPCR was performed for *EXT1*, *EXT2*, *IHH*, *PTCH*, *SMO*, *GLI2*, *PTHLH*, and three normalization genes (*HNRPH1*, *CAPNS1*, and *SRPR*) (primers and qPCR conditions are available on request). We selected the normalization genes from the expression profiling experiments of six osteochondromas, 14 secondary peripheral chondrosarcomas, and four postnatal growth plates, with the least variation between all the samples [25]. Normalization was performed using the geNorm program [27]. qPCR reactions were performed with the qPCR Corekit for SybrGreen (Eurogentec, Seraing, Belgium) according to manufacturer's protocol and run on an iCycler (Bio-Rad, Hercules, CA, USA). For each gene, a standard curve, consisting of a mixture of eight samples, was included to calculate the relative starting quantity of each gene, used in normalization and statistical analysis. Results were compared with those of six osteochondromas and four postnatal normal growth plates [25].

Results

Histological evaluation

Osteochondromas tended to have partial or complete growth plate architecture, while in DEH chondrocytes were predominantly clumped in small clusters (Figure 1E). Moreover, fibrillary matrix was not seen in osteochondromas, while it was present in all DEH cases (Figure 1F). Histological features favouring the diagnosis of DEH over osteochondroma were absence or limited number of binucleated cells ($p = 0.000$), presence of nucleoli ($p = 0.040$), clumping of chondrocytes ($p = 0.002$), absence or only partial presence of a growth plate architecture ($p = 0.002$), and the presence of a fibrillary chondroid matrix ($p = 0.000$). Nuclear polymorphism ($p = 0.221$), the distribution of the cells ($p = 0.078$), cellularity ($p = 0.192$), mucomyxoid matrix degeneration ($p = 0.293$), and demarcation towards the soft tissue ($p = 0.095$) did not differ between the two lesions. Mitoses were absent in both lesions.

Meaningful statistical analysis on the two MC cases was not possible. They both showed absence of binucleated cells, some nuclear polymorphism, presence of nucleoli, high cellularity, some mucomyxoid matrix changes, absence of mitoses, complete growth plate architecture, and a sharp demarcation towards the soft

tissue, while a fibrillary chondroid matrix was absent (Figures 2C–E).

Radiological evaluation

Review of all radiological studies of the two cases of MC and 10 cases of DEH demonstrated classical radiographic criteria, eg bony outgrowths arising from the epiphyses of tubular bones and/or tarsal bones with continuity of both cortex and bone marrow from the underlying bone into the lesions in cases of DEH (Figure 1), and a synchronous combination of enchondromas and osteochondromas pointing towards the growth plate in cases of MC (Figure 2).

Immunohistochemistry

Table 3 summarizes the results. The protein expression of PTHLH, PTHR1, and BCL2 in DEH cases indicates that PTHLH signalling is active in DEH, while being downregulated in osteochondromas (Table 3). PTHLH and its downstream effector BCL2 expression were significantly different ($p = 0.011$ and 0.001 , respectively) between DEH and osteochondroma.

In MC, PTHLH is also expressed, while this does not lead to BCL2 expression. However, only one case of MC could be evaluated for BCL2. Figure 3 shows examples.

The expression of HS proteoglycans (syndecan-2 and HS-bearing variable exon 3 of CD44) and native HS side chains in DEH and MC was not significantly different from the expression in osteochondromas, with the proteoglycans being expressed in the majority of cases, while the native HS side chains were mostly absent. The expression of the different proteins did not correlate with gender or patient age.

cDNA microarray analysis

Unsupervised hierarchical clustering showed that DEH (case 9) and MC (case 11) clustered separately from solitary and MO and growth plates (Figure 4). Both lesions still expressed cartilage specific markers such as COL2A1, COL9A1, SOX9, and FGFR3 in a similar fashion as the growth plates (data available upon request).

qPCR

EXT1 mRNA was expressed in DEH (case 9) and MC (case 11), but was decreased in osteochondromas. Expression levels of *EXT2* were higher in the DEH and MC cases than in the three hereditary osteochondromas, but similar to expression levels found in three solitary osteochondromas. The expression levels of IHH signalling genes in DEH and MC were similar to those in osteochondromas, with the exception of PTHLH, which was expressed more highly in both DEH and MC. There were no differences in expression levels for all genes between DEH, MC and growth plates. Table 4 summarizes the expression levels.

Discussion

We present a histological and molecular evaluation of DEH and MC, two extremely rare disorders to be considered in the differential diagnosis of Multiple Osteochondromas. The distinction is made based on a clinicoradiological evaluation since, histologically, these lesions are often said to be identical. Osteochondromas recapitulate normal endochondral bone formation as the stratified zones of chondrocytes that are normally found in the growth plate can most often still be recognized histologically in osteochondroma, be it somewhat disorganized [1]. Although we could only evaluate two cases, the osteochondromas in MC seemed histologically indistinguishable from sporadic or hereditary osteochondromas, also recapitulating this growth plate architecture. In contrast, this was much less evident in DEH, in which clumping of chondrocytes, as previously described [8], surrounded by a fibrillary matrix was a prominent feature (Figure 1).

In addition to the different histological features, we demonstrate that DEH is also different from osteochondroma at the molecular level. Unfortunately, owing to its rarity, fresh frozen tissue to isolate high quality RNA was available for only one DEH case. DNA and RNA isolation from paraffin-embedded tissue is not possible owing to usually extensive decalcification. However, although only one sample could be evaluated, cDNA microarray analysis showed that

Table 3. Immunohistochemical results

Antigen	Osteochondroma*		DEH		Osteochondroma vs DEH (p value)	MC	
	Positive	%	Positive	%		Positive	%
Syndecan-2	15/21	71	8/8	100	0.15	2/2	100
CD44	3/23	13	0/8	0	0.55	0/2	0
CD44v3	19/20	95	8/9	89	0.53	2/2	100
HS chain	4/22	18	1/10	10	1	0/2	0
PTHLH	37/65	57	9/9	100	0.011	2/2	100
PTHR1	12/19	63	6/7	86	0.38	2/2	100
BCL2	3/59	5	4/6	67	0.001	0/1	0
p21	5/20	25	3/7	43	0.63	2/2	100

* Data published previously (PTHLH and BCL2 [22], p21 [19]) or unpublished (syndecan-2, CD44, CD44v3, HS chain, PTHR1).

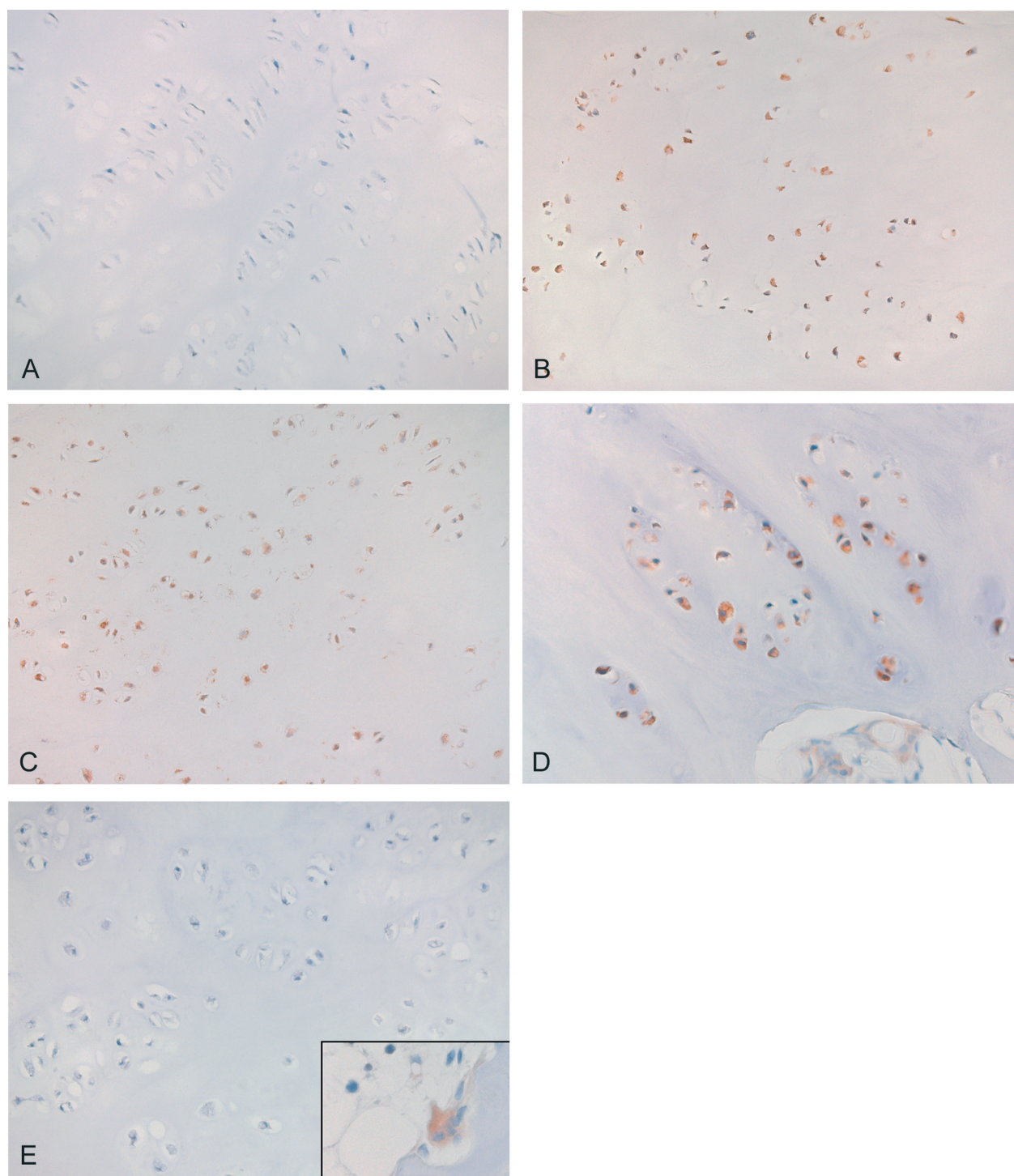


Figure 3. Immunohistochemical results. Light micrograph showing PTHLH immunohistochemical staining of (A) hereditary osteochondroma with very weak PTHLH staining in less than 25% of the cells, scored as negative; (B) DEH lesion scored as positive. The lesion clearly demonstrates strong PTHLH expression in 75–100% of the cells; (C) MC lesion expressing PTHLH in almost all cells. Light micrograph showing BCL2 immunohistochemical staining of (D) DEH lesion demonstrating strong BCL2 expression in 75–100% of the cells; (E) MC lesion demonstrating absent or very weak BCL2 expression, but positive internal controls were present (inset)

DEH clustered separately from osteochondromas as well as from growth plate samples. More specifically, in contrast to the generally low *EXT* expression in osteochondroma, due to *EXT* mutations, *EXT1* and *EXT2* expression levels in the DEH case were comparable to the normal growth plate. This is consistent with the one DEH patient reported with absent

EXT1 and *EXT2* mutations [28]. *EXT* mutations are hypothesized to result in aberrant HS biosynthesis, which in turn is expected to affect IHH/PTHLH signalling. We show that PTHLH signalling molecules are expressed in DEH at both mRNA (qPCR) and protein levels (immunohistochemistry). Thus, in contrast to osteochondroma, in which PTHLH signalling

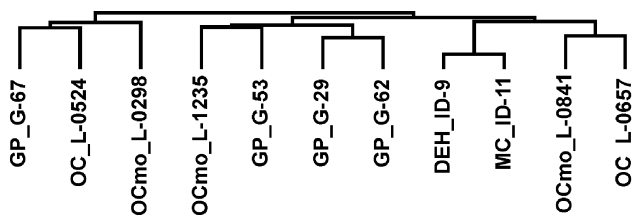


Figure 4. Unsupervised hierarchical cluster analysis of cDNA microarray. DEH and MC cluster together and separately from osteochondromas, both solitary and hereditary, and from the growth plates. The cluster represents 5271 spotted cDNA clones that were present in at least 55% of the samples. GP = growth plate; OC = solitary osteochondroma; OCmo = hereditary osteochondroma; DEH = dysplasia epiphysealis hemimelica; MC = metachondromatosis

Table 4. Normalized relative qPCR expression levels (log transformed) in DEH (case 9), MC (case 11), osteochondroma, and growth plate samples

	Growth plate (n = 4)	Osteochondroma (n = 6)	DEH (n = 1)	MC (n = 1)
Median age (years)	12	12	7	6
<i>EXT1</i>	3.37 ± 0.11	2.71 ± 0.48	3.39	3.17
<i>EXT2</i>	3.05 ± 0.10	2.68 ± 0.52	3.05	2.72
<i>IHH</i>	3.18 ± 0.72	2.92 ± 0.72	2.75	2.92
<i>PTCH</i>	3.34 ± 0.13	3.18 ± 0.31	3.30	2.77
<i>SMO</i>	3.17 ± 0.12	3.23 ± 0.17	3.68	2.74
<i>GLI1</i>	3.01 ± 0.08	2.99 ± 0.23	2.94	2.44
<i>GLI2</i>	3.43 ± 0.17	3.18 ± 0.17	3.22	3.14
<i>GLI3</i>	2.94 ± 0.06	2.90 ± 0.24	3.44	2.81
<i>PTHLH</i>	2.26 ± 0.21	1.89 ± 0.34	2.86	3.23

is downregulated, probably as a result of *EXT* mutations [19,22], this growth plate signalling pathway seems operative in DEH. Although patients with osteochondroma were older than those with DEH or MC lesions in our series, expression patterns did not correlate with patient age or gender, indicating that the observed differences in expression are independent of the maturity of the lesions. PTHLH signalling has also been shown to be active in other cartilaginous tumours, such as enchondroma and central chondrosarcoma [19,29], peripheral chondrosarcoma [19], chondroblastoma [30], and chondromyxoid fibroma [31], suggesting that is important not only for normal but also for neoplastic chondrocyte proliferation.

Little is known about the histogenesis of DEH and no molecular studies have been reported. Half a century ago it had already been suggested that an unknown aetiological factor affects the limb buds during early fetal life [32,33] and an early postzygotic mutation resulting in asymmetric involvement of skeletal structures can be expected, as has been shown, for instance, for polyostotic fibrous dysplasia (McCune–Albright syndrome) [34]. Silverman suggested that the lesions in DEH result from a defect in the periosteal ring around the growth cartilage [7]. Trevor suggested that they result from failure of the hypertrophic cells in the growth plate to undergo

apoptosis, retaining their power of division [32]. Our results may favour this hypothesis since we show that PTHLH signalling is active in DEH. Moreover, we show that BCL2, an anti-apoptotic protein downstream of PTHLH, is expressed in four of six DEH cases, while being mostly absent in osteochondroma [19,22].

In contrast to DEH, MC was histologically similar to osteochondroma, although only two cases were available. Clinically, however, MC-related osteochondromas and conventional osteochondromas behave differently since they have different predilection sites and point in different directions. Also, MC-related osteochondromas have the capacity to regress spontaneously, instead of the capacity to become malignant as is the case for conventional osteochondromas [3]. This difference is confirmed using cDNA microarray analysis since the MC case clustered together with the DEH case and demonstrated less resemblance to osteochondromas and growth plates.

EXT mutations were reported to be absent in one of our MC patients. The *EXT* genes were normally expressed, which also confirms that MC is different from MO. Nothing is known about the underlying gene defect or the histogenesis of MC-related osteochondromas. No genomic aberrations were found in case 11 (data not shown) using high resolution array comparative genomic hybridization experiments [35]. We show that the genes involved in IHH and PTHLH signalling are normally expressed in the two cases we had available, suggesting that, in contrast to the *EXT* genes in MO, the gene responsible for MC will probably not affect these pathways. Thus, despite the morphological similarities, MC-related and conventional osteochondromas are different entities.

In conclusion, in a comparative study between DEH, MC, and osteochondroma, we show that, at the histological level, clumping of chondrocytes in a fibrillary matrix are distinguishing features of DEH, while MC-related and conventional osteochondroma are histologically identical. At the molecular level, we show that, in contrast to osteochondroma, the *EXT* genes and the downstream PTHLH pathway are active in MC and DEH, confirming that these are different entities and suggesting that the so far unknown molecular defects in these lesions do not affect *EXT* signalling.

Acknowledgements

We thank Ayse Yavas and Pauline Wijers-Koster for expert technical assistance, Anne-Marie Cleton-Jansen for critically reading the manuscript, the Netherlands Committee on Bone Tumours for providing the cases studied, and Guido David for kindly providing the HS proteoglycans antibodies. This study was financially supported by the Dutch Cancer Society (grant RUL2002-2738). The departments of Pathology, LUMC and University of Erlangen-Nürnberg are partners of the EuroBoNet consortium, a European Commission granted Network of Excellence for studying the pathology and genetics of bone tumours. PCW Hogendoorn is on the advisory board of Novartis Inc, which is not relevant to the studies presented in this paper. The other authors have declared no conflicts of interest.

References

1. Khurana J, Abdul-Karim F, Bovée JVMG. Osteochondroma. In *World Health Organization Classification of Tumours. Pathology and Genetics of Tumours of Soft Tissue and Bone*, Fletcher CDM, Unni KK, Mertens F (eds). IARC Press: Lyon, 2002; 234–236.
2. Mulder JD, Schütte HE, Kroon HM, Taconis WK. *Radiologic Atlas of Bone Tumors* (2nd edn). Elsevier: Amsterdam, 1993.
3. Bovée JVMG, Hogendoorn PCW. Multiple osteochondromas. In *World Health Organization Classification of Tumours. Pathology and Genetics of Tumours of Soft Tissue and Bone*, Fletcher CDM, Unni KK, Mertens F (eds). IARC Press: Lyon, 2002; 360–362.
4. Hameetman L, Bovée JVMG, Taminiau AHM, Kroon HM, Hogendoorn PCW. Multiple osteochondromas: clinicopathological and genetic spectrum and suggestions for clinical management. *Hereditary Cancer in Clinical Practice* 2004;**2**:161–173.
5. Murphey MD, Choi JJ, Kransdorf MJ, Flemming DJ, Gannon FH. Imaging of osteochondroma: variants and complications with radiologic-pathologic correlation. *RadioGraphics* 2000;**20**:1407–1434.
6. Azouz EM, Slomic AM, Marton D, Rigault P, Finidori G. The variable manifestations of dysplasia epiphysealis hemimelica. *Pediatr Radiol* 1985;**15**:44–49.
7. Silverman FN. Dysplasia epiphysealis hemimelica. *Semin Roentgenol* 1989;**24**:246–258.
8. Ippolito E, Tudisco C. Dysplasia epiphysealis hemimelica. Clinical, histological and histochemical features. *Ital J Orthop Traumatol* 1983;**9**:101–107.
9. Kuo RS, Bellemore MC, Monsell FP, Frawley K, Kozlowski K. Dysplasia epiphysealis hemimelica: clinical features and management. *J Pediatr Orthop* 1998;**18**:543–548.
10. Brien EW, Mirra JM, Luck JV, Jr. Benign and malignant cartilage tumors of bone and joint: their anatomic and theoretical basis with an emphasis on radiology, pathology and clinical biology. II. Juxtacortical cartilage tumors. *Skeletal Radiol* 1999;**28**:1–20.
11. Bassett GS, Cowell HR. Metachondromatosis. Report of four cases. *J Bone Joint Surg Am* 1985;**67**:811–814.
12. Herman TE, Chines A, McAlister WH, Gottesman GS, Eddy MC, Whyte MP. Metachondromatosis: report of a family with facial features mildly resembling trichorhinophalangeal syndrome. *Pediatr Radiol* 1997;**27**:436–441.
13. Kennedy LA. Metachondromatosis. *Radiology* 1983;**148**:117–118.
14. Keret D, Bassett GS. Avascular necrosis of the capital femoral epiphysis in metachondromatosis. *J Pediatr Orthop* 1990;**10**:658–661.
15. Wenger DR, Birch J, Rathjen K, Tobin R, Billman G. Metachondromatosis and avascular necrosis of the femoral head: a radiographic and histologic correlation. *J Pediatr Orthop* 1991;**11**:294–300.
16. Ahn J, Ludecke H-J, Lindow S, Horton WA, Lee B, Wagner MJ, et al. Cloning of the putative tumour suppressor gene for hereditary multiple exostoses (EXT1). *Nature Genet* 1995;**11**:137–143.
17. Wuyts W, Van Hul W, Wauters J, Nemtsova M, Reyniers E, Van Hul E, et al. Positional cloning of a gene involved in hereditary multiple exostoses. *Hum Mol Genet* 1996;**5**:1547–1557.
18. Stickens D, Clines G, Burbee D, Ramos P, Thomas S, Hogue D, et al. The EXT2 multiple exostoses gene defines a family of putative tumour suppressor genes. *Nature Genet* 1996;**14**:25–32.
19. Bovée JVMG, Van den Broek LJCM, Cleton-Jansen AM, Hogendoorn PCW. Up-regulation of PTHrP and Bcl-2 expression characterizes the progression of osteochondroma towards peripheral chondrosarcoma and is a late event in central chondrosarcoma. *Lab Invest* 2000;**80**:1925–1933.
20. Bovée JVMG, Van den Broek LJCM, De Boer WI, Hogendoorn PCW. Expression of growth factors and their receptors in adamantinoma of long bones and the implications for its histogenesis. *J Pathol* 1998;**184**:24–30.
21. David G, Bai XM, Van der Schueren B, Cassiman JJ, Van den Berghe H. Developmental changes in heparan sulfate expression: in situ detection with mAbs. *J Cell Biol* 1992;**119**:961–975.
22. Hameetman L, Kok P, Eilers PHC, Cleton-Jansen AM, Hogendoorn PCW, Bovée JVMG. Distinguishing osteochondromas from grade I secondary peripheral chondrosarcomas: influence of patient gender and age on the use of Bcl-2 and PTHrP immunohistochemistry. *Virchows Arch* 2005;**446**:430–437.
23. Baelde HJ, Cleton-Jansen AM, van Beerendonk H, Namba M, Bovée JVMG, Hogendoorn PCW. High quality RNA isolation from tumours with low cellularity and high extracellular matrix component for cDNA microarrays: application to chondrosarcoma. *J Clin Pathol* 2001;**54**:778–782.
24. Rozeman LB, Hameetman L, van Wezel T, Taminiau AHM, Cleton-Jansen AM, Hogendoorn PCW, et al. cDNA expression profiling of central chondrosarcomas: Ollier disease resembles solitary tumors and alteration in genes coding for energy metabolism with increasing grade. *J Pathol* 2005;**207**:61–71.
25. Hameetman L, Rozeman LB, Lombaerts M, Dosting J, Taminiau AHM, Cleton-Jansen AM, et al. Peripheral chondrosarcoma progression is accompanied by decreased Indian Hedgehog (IHH) signalling. *J Pathol* 2006; in press.
26. Eisen MB, Spellman PT, Brown PO, Botstein D. Cluster analysis and display of genome-wide expression patterns. *Proc Natl Acad Sci USA* 1998;**95**:14863–14868.
27. Vandesompele J, De Preter K, Pattyn F, Poppe B, Van Roy N, De Paep A, et al. Accurate normalization of real-time quantitative RT-PCR data by geometric averaging of multiple internal control genes. *Genome Biol* 2002;**3**:research 0034.1–0034.11.
28. Bernard MA, Hall CE, Hogue DA, Cole WG, Scott A, Snuggs MB, et al. Diminished levels of the putative tumor suppressor proteins EXT1 and EXT2 in exostosis chondrocytes. *Cell Motil Cytoskeleton* 2001;**48**:149–162.
29. Rozeman LB, Hameetman L, Cleton-Jansen AM, Taminiau AHM, Hogendoorn PCW, Bovée JVMG. Absence of IHH and retention of PTHrP signalling in enchondromas and central chondrosarcomas. *J Pathol* 2005;**205**:476–482.
30. Romeo S, Bovée JVMG, Jadnanansing NAA, Taminiau AHM, Hogendoorn PCW. Expression of cartilage growth plate signalling molecules in chondroblastoma. *J Pathol* 2004;**202**:113–120.
31. Romeo S, Bovée JVMG, Grogan S, Taminiau AHM, Eilers PHC, Cleton-Jansen AM, et al. Chondromyxoid fibroma resembles *in vitro* chondrogenesis, though differs in expression of signalling molecules. *J Pathol* 2005;**206**:135–142.
32. Trevor D. Tarso-epiphyseal aclerosis; a congenital error of epiphyseal development. *J Bone Joint Surg Br* 1950;**32-B**:204–213.
33. Fairbank TJ. Dysplasia epiphysealis hemimelica (tarso-epiphyseal aclerosis). *J Bone Joint Surg Br* 1956;**38-B**:237–257.
34. Cohen MM Jr, Siegal GP. McCune-Albright syndrome. In *World Health Organization Classification of Tumours. Pathology and Genetics of Tumours of Soft Tissue and Bone*, Fletcher CDM, Unni KK, Mertens F (eds). IARC Press: Lyon, 2002; 357–359.
35. Rozeman LB, Szuhai K, Schrage YM, Rosenberg C, Tanke HJ, Taminiau AHM, et al. Array-CGH of central chondrosarcoma: identification of RPS6 and CDK4 as candidate target genes as target for genomic aberrations. *Cancer* 2006; in press.
36. David G, Bai XM, Van der Schueren B, Marynen P, Cassiman JJ, Van den Berghe H. Spatial and temporal changes in the expression of fibroglycan (syndecan-2) during mouse embryonic development. *Development* 1993;**119**:841–854.
37. Nackaerts K, Verbeken E, Deneffe G, Vanderschueren B, Demedts M, David G. Heparan sulfate proteoglycan expression in human lung-cancer cells. *Int J Cancer* 1997;**74**:335–345.