

hyperactive in psoriatic patients? There may be a defect in the immune system in psoriatic patients, whereby T helper 17 cells or innate lymphoid cell 3 systems become overactive to compensate, even though the defect cannot be detected clinically. The Koebner phenomenon may explain some of the distribution of the plaques as the increased expression of an antimicrobial peptide, cathelicidin, in psoriatic lesional epidermis is one of the provoking causes of inflammatory cascades.⁵

ACKNOWLEDGEMENTS

The Department of Dermatology, Fukuoka University has been supported by research grants from Kyowa Hakko Kirin Co Ltd and Mitsubishi Tanabe Pharma Corporation, AbbVie Pharmaceuticals, Japan, Torii Pharmaceutical Co Ltd and Novartis Pharma K.K. KY has been supported with grants for scientific research from the Ministry of Education, Culture, Sports, Science and Technology of Japan (17K10241, 26461690) and a grant from the Mie University Hospital Seed Grant program (2015).

Shinichi Imafuku¹ and Keiichi Yamanaka² 

¹Department of Dermatology, Fukuoka University Faculty of Medicine, Fukuoka, and ²Department of Dermatology, Graduate School of Medicine, Mie University, Tsu, Mie, Japan

REFERENCES

1. Saunte DM, Mrowietz U, Puig L *et al.* Candida infections in psoriasis and psoriatic arthritis patients treated with interleukin-17 inhibitors and their practical management. *Br. J. Dermatol.* 2017; **177**: 47–62.
2. Yamanaka K, Umezawa Y, Yamagiwa A *et al.* Biologic therapy improves psoriasis by decreasing the activity of monocytes and neutrophils. *J. Dermatol.* 2014; **41**: 679–85.
3. Guttman-Yassky E, Lowes MA, Fuentes-Duculan J *et al.* Low expression of the interleukin-25/T helper 17 pathway in atopic dermatitis compared to psoriasis. *J. Immunol.* 2008; **181**: 7420–7.

doi: 10.1111/ajd.12781

Case Letter

Dear Editor,

Agminated Spitz naevi or metastatic spitzoid melanoma?

An otherwise healthy 4-year old girl developed over several months a 1-cm erythematous papule on the dorsum of the left foot. The papule was excised elsewhere, under a clinical diagnosis of pyogenic granuloma and the defect was closed by a rhomboid flap. Ultrasound imaging

showed no enlarged lymph nodes in the inguinal region. Several weeks later, several papules similar to the first emerged within and close to the excision scar and a re-excision was performed. Histopathological examination of all excised papules showed a proliferation of spitzoid melanocytes, with compact and mitotically active dermal nests and a relatively high number of MIB-1-positive nuclei. HMB45 and p16 staining were negative (Fig. 1a,b). Lymph vessel invasion was noted. At that point the patient was referred to our hospital and the case was reviewed by an expert panel. Considering the clinical features of many monomorphic pink papules in a very young child, agminated Spitz naevi was thought to be the most likely diagnosis. However, some uncertainty was expressed with regard to the biological potential. Surgical excision of the entire lesion was recommended (Fig. 2) as well as a close clinical follow up, including ultrasound of the draining lymph basin. After 6 months there were no clinical signs of local recurrence, but an ultrasound revealed many enlarged ipsilateral inguinal lymph nodes, up to 2.7 cm in diameter. The largest lymph node was excised and showed an extensive deposit of the Spitz tumour (Fig. 1c, see Data S1). In view of the large size of the lymph node deposit, we concluded that it represented a metastasis, and the diagnosis was adjusted to most probably spitzoid melanoma. A positron emission tomography-computed tomography scan showed activity in another lymph node of the same lymph node basin. An inguinal lymph node dissection was performed, showing that one in six lymph nodes were tumour-positive. She additionally received temozolomide in monthly courses for 1 year. Two years after diagnosis, no distant metastases have become apparent.

DISCUSSION

Initially the diagnosis was agminated Spitz naevi.¹

Thus far, there have been no reports of malignant transformation occurring in patients with agminated or disseminated Spitz naevi. Unlike the previously published cases of agminated Spitz naevi, our patient demonstrated histopathological features of a Spitz tumour of uncertain malignant potential. Despite the clinical similarity with an earlier report of agminated Spitz naevi with a benign course² our case was histopathologically ambiguous with regional lymph node involvement. Nevertheless, the prognosis remains unclear. Immunohistochemistry, sentinel node biopsy and molecular analyses have thus far not been able to distinguish ambiguous cases accurately.^{3–5} Similarly, immunohistochemistry provided no concluding diagnosis in our case. A sentinel node biopsy was not performed because of the apparent lack of diagnostic and prognostic value.⁴ In our patient's hotspot mutation analysis or next generation sequencing showed no pathogenic variant and therefore provided no additional diagnostic or therapeutic value. The rapid development of major lymph node involvement, favors a diagnosis of spitzoid melanoma rather than a benign melanocytic lymph node aggregate. Fortunately, thus far no other metastases have been detected.

Conflict of interest: None.

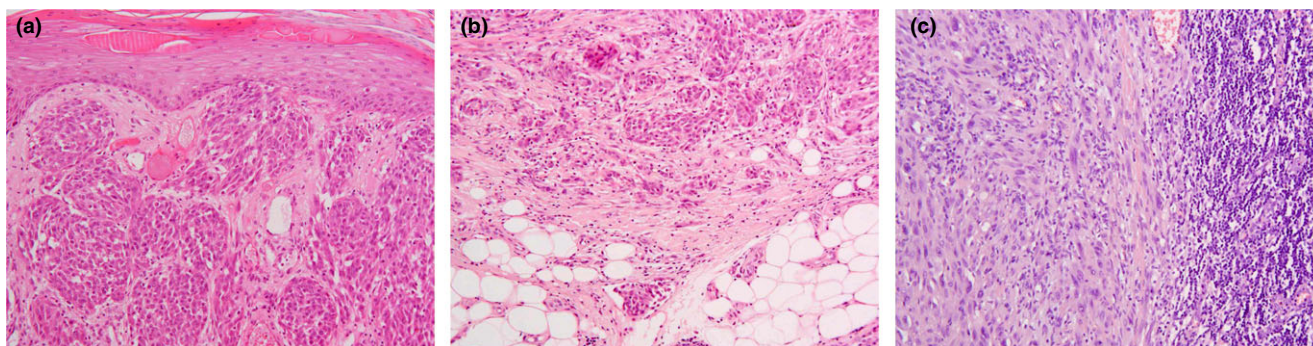


Figure 1 (a) The superficial part showed features compatible with Spitz naevus. Intra-dermal islands of enlarged, rather monomorphic spitzoid melanocytes, with increased, non-pigmented cytoplasm, with enlarged but monomorphous nuclei and few mitotic figures are seen (H&E, $\times 400$ magnification). (b) The deep dermal part of the lesion offers clues of the malignant potential of the disease: rather compact, nested architecture, lymphatic invasion and deep mitotic activity. Lymphatic invasion is not a formal proof of malignancy, since it may be occasionally encountered in benign Spitz naevi (H&E, $\times 400$ magnification). (c) Spread to the lymph node showed somewhat more spindled melanocytes, but they were otherwise identical to the ones of the skin lesion (H&E, $\times 400$ magnification).

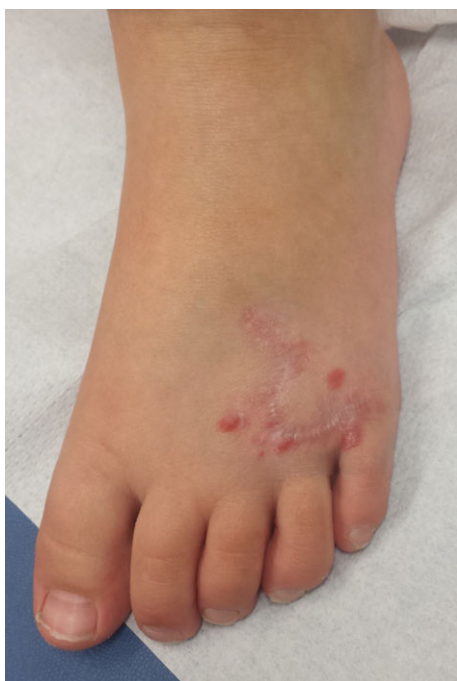

Figure 2 Recurrence of many papules in and close to the excision scar.

REFERENCES

1. Zeng MH, Kong QT, Sang H *et al.* Agminated spitz nevi: case report and review of the literature. *Pediatr. Dermatol.* 2015;**30**: e104–5.
2. Paties CT, Borroni G, Rosso R *et al.* Relapsing eruptive multiple Spitz nevi or metastatic spitzoid malignant melanoma? *Am. J. Dermatopathol.* 1987; **9**: 520–7.
3. Wiesner T, Kutzner H, Cerroni L *et al.* Genomic aberrations in spitzoid melanocytic tumours and their implications for diagnosis, prognosis and therapy. *Pathology.* 2016; **48**: 115–51.
4. Lallas A, Kyrgidis A, Ferrara G *et al.* Atypical Spitz tumours and sentinel lymph node biopsy: a systematic review. *Lancet Oncol.* 2014; **15**: e178–85.
5. Redon S, Guibourg B, Talagas M *et al.* A diagnostic algorithm combining immunohistochemistry and molecular cytogenetics to diagnose challenging melanocytic tumors. *Appl. Immunohistochem. Mol. Morphol.* 2017. <https://doi.org/10.1097/PAI.0000000000000511>

Supporting Information


Additional Supporting Information may be found online in Supporting Information:

Data S1. Molecular analyses.

doi: 10.1111/ajd.12804

ACKNOWLEDGEMENT

We thank W. J. Mooi for critically reviewing the manuscript and for providing the histopathology photographs.

Marloes Sophia van Kester,¹  Celine Eggen,²
Auke Beishuizen⁵ and Nicole Ariane Kukutsch¹

¹Department of Dermatology, Leiden University Medical Center, Leiden, ²Department of Dermatology, and

³Department of Paediatric Oncology and Haematology, Erasmus Medical Center, Sophia Children's Hospital, Rotterdam, The Netherlands

Correspondence Letter

Dear Editor,

Psoriasis and subclinical atherosclerosis in a Chinese population

We read with interest the article in this journal entitled 'Plaque psoriasis is associated with subclinical atherosclerosis in a Chinese population' by Xu and colleagues.¹ In