



**Universiteit
Leiden**
The Netherlands

Expert consensus recommendations on the cardiogenetic care for patients with thoracic aortic disease and their first-degree relatives

Verhagen, J.M.A.; Kempers, M.; Cozijnsen, L.; Bouma, B.J.; Duijnhouwer, A.L.; Post, J.G.; ...
; Natl Working Grp BAV TAA

Citation


Verhagen, J. M. A., Kempers, M., Cozijnsen, L., Bouma, B. J., Duijnhouwer, A. L., Post, J. G., ... Laar, I. M. B. H. van de. (2018). Expert consensus recommendations on the cardiogenetic care for patients with thoracic aortic disease and their first-degree relatives. *International Journal Of Cardiology*, 258, 243-248. doi:10.1016/j.ijcard.2018.01.145

Version: Not Applicable (or Unknown)

License: [Leiden University Non-exclusive license](#)

Downloaded from: <https://hdl.handle.net/1887/79887>

Note: To cite this publication please use the final published version (if applicable).



Expert consensus recommendations on the cardiogenetic care for patients with thoracic aortic disease and their first-degree relatives

Judith M.A. Verhagen^a, Marlies Kempers^b, Luc Cozijnsen^c, Berto J. Bouma^d, Anthonie L. Duijnhouwer^e, Jan G. Post^f, Yvonne Hillhorst-Hofstee^g, Sebastiaan C.A.M. Bekkers^h, Wilhelmina S. Kerstjens-Frederikseⁱ, Thomas J. van Brakel^j, Eric Lambermon^k, Marja W. Wessels^a, Bart L. Loeys^{b,1}, Jolien W. Roos-Hesselink^m, Ingrid M.B.H. van de Laar^{a,*}, on behalf of the National Working Group on BAV & TAA

^a Department of Clinical Genetics, Erasmus University Medical Center, Rotterdam, The Netherlands

^b Department of Clinical Genetics, Radboud University Medical Center, Nijmegen, The Netherlands

^c Department of Cardiology, Gelre Hospital, Apeldoorn, The Netherlands

^d Department of Cardiology, Academic Medical Center, Amsterdam, The Netherlands

^e Department of Cardiology, Radboud University Medical Center, The Netherlands

^f Department of Clinical Genetics, University Medical Center Utrecht, Utrecht, The Netherlands

^g Department of Clinical Genetics, Leiden University Medical Center, Leiden, The Netherlands

^h Department of Cardiology, Maastricht University Medical Center, Maastricht, The Netherlands

ⁱ Department of Genetics, University Medical Center Groningen, University of Groningen, Groningen, The Netherlands

^j Department of Cardiothoracic Surgery, Leiden University Medical Center, Leiden, The Netherlands

^k Dutch General Practitioners' Expert Group on Cardiovascular Diseases

^l Center of Medical Genetics, University of Antwerp and Antwerp University Hospital, Antwerp, Belgium

^m Department of Cardiology, Erasmus University Medical Center, Rotterdam, The Netherlands

ARTICLE INFO

Article history:

Received 20 June 2017

Received in revised form 16 January 2018

Accepted 31 January 2018

Available online 7 February 2018

Keywords:

Thoracic aortic aneurysm

Aortic disease

Dissection

Genetics

Family screening

ABSTRACT

Background: Thoracic aortic aneurysm (TAA) is a potentially life-threatening disorder with a strong genetic component. The number of genes implicated in TAA has increased exponentially over the last decade. Approximately 20% of patients with TAA have a positive family history. As most TAA remain asymptomatic for a long time, screening of at risk relatives is warranted to prevent complications. Existing international guidelines lack detailed instructions regarding genetic evaluation and family screening of TAA patients. We aimed to develop a consensus document to provide medical guidance for all health care professionals involved in the recognition, diagnosis and treatment of patients with thoracic aortic disease and their relatives.

Methods: A multidisciplinary panel of experts including cardiologists, cardiothoracic surgeons, clinical geneticists and general practitioners, convened to review and discuss the current literature, guidelines and clinical practice on genetic testing and family screening in TAA.

Results: There is a lack of high-quality evidence in the literature. This consensus statement, based on the available literature and expert opinions, summarizes our recommendations in order to standardize and optimize the cardiogenetic care for patients and families with thoracic aortic disease. In particular, we provide criteria to identify those patients most likely to have a genetic predisposition, and discuss the preferred modality and frequency of screening in their relatives.

Conclusions: Age, family history, aortic size and syndromic features determine who is advised to have genetic testing as well as screening of first-degree relatives. There is a need for more prospective multicenter studies to optimize current recommendations.

© 2018 The Authors. Published by Elsevier B.V. This is an open access article under the CC BY-NC-ND license (<http://creativecommons.org/licenses/by-nc-nd/4.0/>).

1. Introduction

Thoracic aortic aneurysm (TAA) is an abnormal, usually progressive widening of one or multiple segments of the aorta within the thoracic cavity. This consensus statement focuses on patients with aneurysms involving the aortic root and/or ascending aorta without concomitant aortic valve disease, and on thoracic aortic dissections (Stanford type

* Corresponding author at: Department of Clinical Genetics, Erasmus University Medical Center, P.O. Box 2040, 3000 CA Rotterdam, The Netherlands.
E-mail address: i.vandelaar@erasmusmc.nl (I.M.B.H. van de Laar).

A and B). This includes patients with thoracic aortic disease as part of a connective tissue disorder. Aortic dilatation in patients with repaired or unrepaired congenital heart disease, e.g. bicuspid aortic valve (BAV), tetralogy of Fallot, truncus arteriosus or after the Ross or arterial switch operation, is not included in this consensus document.

Most patients with TAA are asymptomatic. TAA is usually found accidentally during imaging studies for other purposes or upon screening of relatives. TAA can, if left untreated, lead to aortic dissection, rupture or sudden death. Approximately 20% of patients with TAA have a positive family history. Familial TAA is often inherited in an autosomal dominant pattern with incomplete penetrance and variable expressivity [1]. Despite advancing genetic knowledge and sequencing technologies, only one quarter of families with TAA receive a molecular diagnosis, suggesting further locus heterogeneity. Hence, a negative genetic test result does not exclude a genetic predisposition. Patients with TAA are more likely to develop aneurysms elsewhere in the arterial tree. However, the number of studies addressing this issue is limited. Approximately one quarter of patients with TAA have a concomitant abdominal aortic aneurysm (versus 5% in the general population) [2], and 10% a concomitant intracranial aneurysm (versus 1–2% in the general population) [3]. Relatives of patients with TAA also have an increased risk for aneurysms beyond the thoracic aorta [1].

The purpose of this document is to provide medical guidance for all health care professionals involved in the recognition, diagnosis and treatment of patients with thoracic aortic disease and their relatives. This consensus statement focuses on the cardiogenetic aspects of care in thoracic aortic disease including the indications for genetic testing and guidelines for the cardiovascular screening of relatives. For more information on the indications for treatment and the various treatment options, the authors refer to the latest guidelines of the European Society of Cardiology (ESC) and the American College of Cardiology/American Heart Association (ACC/AHA) [4,5].

2. Methods

The National Working Group on BAV & TAA was established in April 2015 at the 3rd Aortic Symposium in Rotterdam, The Netherlands, and gathers experts with a shared interest in improving the cardiogenetic care for patients with thoracic aortic disease. Members were actively recruited from various disciplines and health care institutions, in order to achieve a broad representation of the field. For a complete list of all members of the working group and their affiliations, please see the electronic supplement. The aim of this working group was to develop consensus recommendations in order to standardize and optimize care for patients and families with TAA.

We first discussed and agreed upon the definition of TAA. Following a national inventory of the major topics among cardiologists and clinical geneticists, three clinical questions were formulated: What factors are associated with an increased likelihood of a genetic predisposition for TAA? What genetic tests should be offered for efficient and cost-effective detection of mutations predisposing to TAA? What cardiovascular screening of relatives should be recommended? Relevant literature was evaluated to answer these questions and to formulate concept recommendations. These recommendations were then discussed at three plenary meetings held between October 2015 and January 2017, and were distributed via email to receive input from all working group members. A concept version of this document was provided to the Netherlands Heart Institute (formerly known as ICIN), the Working Group Congenital Cardiology of the Netherlands Society of Cardiology (NVVC), the Netherlands Association for Cardio-Thoracic Surgery (NVT) and the chairman of the Dutch General Practitioners' Expert Group on Cardiovascular Diseases (HartVaathAG). After the comments were processed, the consensus document was approved by all members of the working group.

3. Results

3.1. Definition

The definition of TAA has been the subject of considerable debate among clinicians and researchers for decades. In the international literature, different sets of normal reference values for aortic measurements are provided. Except for the aortic root, these values are often based on small studies. The expected normal aortic diameters depend on age, gender, and body surface area. In adults, an aortic diameter of 40 mm or more is generally considered dilated [4,6]. In adults with short stature

and in children, a smaller size can already be considered dilated. Calculating Z-scores (number of standard deviations from the predicted mean) is a helpful way to correlate aortic diameters to body size and to track aortic growth over time. There are several online tools available (e.g. www.parameterz.org and www.marfan.org) to calculate Z-scores using published reference data [7,8]. An aortic diameter Z-score ≥ 2.0 in adults and ≥ 3.0 in children is considered enlarged [8,9]. Above the 95th percentile for height, the aortic diameter does not increase linearly but seems to reach a plateau [10]. In patients with large body size, the Z-score seems to underestimate the aortic root dilatation and is therefore unreliable. In adult women with Turner syndrome, the use of aortic size index is preferred [11].

We recommend to use an absolute threshold of 40 mm for the definition of aortic dilatation. In adults with short stature and in children, we recommend to use a Z-score of ≥ 2.0 and ≥ 3.0 , respectively, in order to adjust for small body size. In adult women with Turner syndrome, aortic dilatation is defined as aortic size index > 2.0 cm/m².

3.2. Factors increasing the likelihood of a genetic predisposition for TAA

3.2.1. Aortic size

Although there is no scientific evidence for this contention, we assume that the contribution of strong genetic factors is larger in patients with more severe disease, e.g. an aortic size ≥ 45 mm. Of course, the presence of other risk factors such as age and hypertension also needs to be considered (as summarized in Section 3.2.2). We expect that non-genetic factors are the major contributors to TAA below 45 mm. Patients with an aortic diameter between 40 and 45 mm should be judged on a case-by-case basis, e.g. depending on age, body size, family history and configuration of the aorta (e.g. a pear-shaped aortic root).

3.2.2. Traditional cardiovascular risk factors

Ageing and hypertension are important risk factors for developing TAA [12]. In our experience, the chance of finding a disease-causing mutation significantly decreases at older age, unless the medical or family history provides further clues (see below). Familial disease tends to occur at relatively younger age [1,13]. A genetic cause should therefore be suspected in patients with thoracic aortic disease diagnosed before the age of 50 years, irrespective of the presence of hypertension, and patients diagnosed between 50 and 60 years without hypertension. There is no convincing association with other traditional cardiovascular risk factors. Tobacco use and dyslipidemia may contribute to *expansion* (but not *formation*) of TAA, and aortic dissection [14–16]. Diabetes mellitus is not clearly associated with thoracic aortic disease [17]. Some studies even suggest a negative association [18]. In contrast to aneurysms of the descending thoracic or abdominal aorta, atherosclerosis is relatively infrequent in ascending TAA [15]. The presence of hypertension does not exclude a genetic etiology: hypertension can also be a feature of shared underlying biological processes [19–21].

3.2.3. Positive family history

Family history is a simple yet powerful tool to recognize a genetic disorder in a family, and should therefore be part of the medical record of every TAA patient. In TAA patients with a “positive” family history of TAA or a related disorder an underlying genetic cause is very likely. To our knowledge, there is no single, generally accepted definition of a ‘positive’ family history. A positive family history is most commonly defined as having at least one first-degree relative (parents, siblings or children) with a thoracic aortic aneurysm or dissection. Considering the small size of modern families, the reduced penetrance of hereditary thoracic aortic disease, and the association with aneurysms along the arterial tree (especially abdominal and intracranial aneurysms), we believe this definition should be broadened here. We suggest to define a positive family history as having at least one first- or second-degree relative with (1) a thoracic aortic aneurysm or dissection, (2) an aneurysm or dissection elsewhere in the arterial tree, diagnosed below 60

years of age, (3) a left-sided congenital heart defect (e.g. congenital aortic valve stenosis or bicuspid aortic valve) or patent ductus arteriosus, or (4) sudden death below 45 years of age.

3.2.4. Syndromic features

The presence of syndromic features greatly increases the chance of finding a genetic cause [22]. An overview of characteristic or easy recognizable clinical features associated with syndromic forms of thoracic aortic disease is provided in Table 1.

In summary, we recommend genetic testing in all TAA patients that fulfill at least one of the above mentioned criteria. The results of genetic tests are not always straightforward and may be difficult to interpret. In addition, the outcome of the tests can have important implications for the patient and his or her relatives. Therefore, the working group recommends that genetic testing is initiated by a trained professional (e.g. a clinical geneticist or cardiologist trained in this field), to provide the appropriate pre- and post-test counseling and correct interpretation of test results.

3.3. Genetic testing

TAA represents a genetically heterogeneous group of disorders, that show significant phenotypic overlap. In patients fulfilling the revised Ghent criteria for Marfan syndrome (e.g. combination of thoracic aortic disease with ectopia lentis), the probability of finding a *FBN1* mutation is high, between 66% and 91% [23–25]. Therefore, targeted *FBN1* analysis can be considered in these cases. If no specific syndromic features are present, next-generation sequencing (NGS) of multiple genes is the most efficient and cost-effective method [22]. According to the European Society of Human Genetics, this should at least include the following “core genes” *ACTA2*, *COL3A1*, *FBN1*, *FLNA*, *MAT2A*, *MFAP5*, *MYH11*, *MYLK*, *NOTCH1*, *PRKG1*, *SMAD3*, *TGFB2*, *TGFB3*, *TGFBR1* and *TGFBR2* [26]. An overview of the most common TAA-related genes and disorders with their associated phenotypes is displayed in Table 2.

The statistical power to detect small intragenic copy number variants using NGS data is suboptimal, though algorithms have improved

considerably over the last few years. Additional high-resolution copy number analysis might be necessary.

A small subset of patients with TAA carry a (sub)microscopic deletion or duplication that might, at least partially, have contributed to aneurysm formation [27–29]. Because such copy number variants may comprise several consecutive genes with divergent functions, these patients often display additional abnormalities (“contiguous gene syndrome”). Chromosomal microarray is therefore recommended in TAA patients with concurrent neuropsychiatric disorders (e.g. intellectual disability) or multiple congenital anomalies. Furthermore, TAA can be a rare manifestation of, for example, Alagille syndrome [30], Noonan syndrome [31] and neurofibromatosis type 1 [32]. Targeted sequencing of the relevant disease genes should be considered in these cases.

3.4. Cardiovascular screening of relatives

Existing international guidelines are often vague and/or inconsistent with regard to screening recommendations for relatives of TAA patients. We experience an urgent need for more detailed instructions to achieve a more uniform approach to family screening in TAA. However, good data are scarce.

3.4.1. Whom to screen

The ESC recommends to investigate first-degree relatives of patients with thoracic aortic disease, but mentions only parents and siblings (and not children) [4]. The ACC/AHA also recommends aortic imaging for first-degree relatives, but adds that imaging of second-degree family members is reasonable if thoracic aortic disease is identified in at least one first-degree relative [5].

If a disease-causing mutation has been identified in the proband, the working group recommends to offer presymptomatic genetic testing to relatives. This is best undertaken using a stepwise approach called “cascade screening”. Cardiovascular screening of mutation carriers should take place at or in close collaboration with an academic center, according to gene-specific management guidelines (see for example [33,34]).

If no disease-causing mutation has been identified in the proband, screening should be offered to all first-degree relatives (parents, siblings and children) of patients fulfilling the criteria as mentioned in Section 3.2 and summarized in Fig. 1.

3.4.2. When to screen

The ESC recommends cardiac screening of “healthy” at-risk relatives every 5 years, but does not mention specific age ranges. The ACC/AHA advises imaging every 2 years in familial TAA.

If the familial mutation is known, the working group refers to gene-specific guidelines and protocols. If no disease-causing mutation has been identified in the proband, the timing of screening depends on the family history. A positive family history is associated with more aggressive aortic disease, e.g. younger age of onset, higher growth rate and increased risk of developing aortic dissection in relatives, and therefore warrants closer monitoring [1,35].

In case of *familial* TAA (see definition of positive family history in Section 3.2.3), we suggest to start screening at the age of 25 years or 10 years below the youngest case in the family, if the latter ends up below 25 years. We assume that clinically relevant disease will rarely be detected in children or young adults below these age limits, while the psychological impact of screening should not be underestimated. If the initial screening reveals no abnormalities, we recommend to continue screening every 5 years. If the aortic diameters are very small or remain stable over time, 10-year intervals seem reasonable. We suggest to discontinue screening by age 65 years. However, if the first screening takes place after the age of 60 years, we recommend at least one follow-up. In case the screening reveals an abnormality, follow-up should be adjusted accordingly.

Table 1

List of most characteristic or easy recognizable clinical features associated with syndromic forms of thoracic aortic disease.

Craniofacial features	Craniosynostosis Widely spaced eyes (hypertelorism) Cleft palate or bifid uvula
Ocular features	Lens subluxation/dislocation (ectopia lentis) Retinal detachment High myopia (−6.00 diopters or higher) Iris hypoplasia or flocculi
Cardiovascular features	Mitral valve prolapse Arterial tortuosity Multiple aneurysms or dissections Left-sided congenital heart defect or patent ductus arteriosus
Musculoskeletal features	Pectus excavatum or carinatum Joint hypermobility or contractures Recurrent joint subluxations/dislocations Severe, early-onset osteoarthritis Severe kyphosis or scoliosis
Cutaneous features	Thin, translucent skin with easily visible veins Hyperelastic skin Livedo reticularis Striae at unusual sites/not related to weight gain Atrophic or wide scars
Other features	Short or tall stature Disproportionately long limbs (dolichostenomelia) Abnormal long and slender fingers (arachnodactyly) Spontaneous pneumothorax Recurrent abdominal wall hernias Spontaneous rupture of internal organs

Table 2
Overview of the most common TAA-related genes and disorders with their associated phenotypes.

Genes	Disorders (inheritance)	Main features
<i>Genes encoding components of the extracellular matrix</i>		
BGN	Meester-Loeys syndrome (XL)	Early-onset aortic aneurysm and dissection, hypertelorism, pectus deformity, joint hypermobility, contractures, mild skeletal dysplasia
COL1A1	Classical Ehlers-Danlos syndrome (AD)	Skin hyperextensibility, dystrophic scarring, joint hypermobility
COL3A1	Vascular Ehlers-Danlos syndrome (AD)	Arterial rupture without preceding dilatation, bowel perforations, uterine rupture during pregnancy, thin and translucent skin, easy bruising, acrogeria
COL4A5	X-linked Alport syndrome (XL)	Progressive renal failure, sensorineural hearing loss, anterior lenticonus
COL5A1	Classical Ehlers-Danlos syndrome (AD)	See COL1A1
COL5A2	Classical Ehlers-Danlos syndrome (AD)	See COL1A1
EFEMP2	Autosomal recessive cutis laxa type IB (AR)	Multiple arterial aneurysms and tortuosity, emphysema, inguinal and diaphragmatic hernia, skin hyperlaxity, downsloping palpebral fissures
ELN	Autosomal dominant cutis laxa 1 (AD), supravalvular aortic stenosis (AD)	Supravalvular aortic stenosis, peripheral arterial stenosis, skin hyperlaxity, premature aged appearance, gastrointestinal diverticula, inguinal hernia
FBN1	Marfan syndrome (AD)	Mitral valve prolapse, ectopia lentis, pectus deformity, myopia
FBN2	Congenital contractural arachnodactyly (AD)	Contractures, arachnodactyly, scoliosis, crumpled ears
LOX	Familial thoracic aortic aneurysm 10 (AD)	Aortic root aneurysm, ascending aortic aneurysm, bicuspid aortic valve
MFAP5	Familial thoracic aortic aneurysm 9 (AD)	Aortic root aneurysm, paroxysmal atrial fibrillation
PLOD1	Kyphoscoliotic Ehlers-Danlos syndrome (AR)	Congenital muscle hypotonia, early-onset kyphoscoliosis, joint hypermobility
<i>Genes encoding component of the TGFβ pathway</i>		
SKI	Shprintzen-Goldberg syndrome (AD)	Craniosynostosis, hypertelorism, micrognathia, high palate, arachnodactyly, joint contractures, hypotonia, developmental delay
SMAD2	No OMIM phenotype	Arterial aneurysms and dissections
SMAD3	Loeys-Dietz syndrome 3 (AD)	Early-onset osteoarthritis, see further TGFBR1
SMAD4	Juvenile polyposis/hereditary hemorrhagic telangiectasia syndrome (AD)	Gastrointestinal hamartomatous polyps, cutaneous and mucosal telangiectasia, epistaxis, arteriovenous malformations
TGFBR1	Loeys-Dietz syndrome 1 (AD)	Aortic root aneurysm, arterial aneurysms and dissections, arterial tortuosity, hypertelorism, left palate, bifid uvula, pectus deformity, scoliosis, club feet
TGFBR2	Loeys-Dietz syndrome 2 (AD)	See TGFBR1
TGFBR3	Loeys-Dietz syndrome 4 (AD)	Mitral valve prolapse, see further TGFBR1
TGFBR3	Loeys-Dietz syndrome 5 (AD)	See TGFBR1
<i>Genes encoding component of the vascular smooth muscle cell contractile apparatus</i>		
ACTA2	Familial thoracic aortic aneurysm 6 (AD)	Iris flocculi, livedo reticularis, premature coronary artery disease and stroke
FLNA	Periventricular nodular heterotopia (XL)	Periventricular heterotopia, epilepsy, joint hypermobility, patent ductus arteriosus
MYH11	Familial thoracic aortic aneurysm 4 (AD)	Aortic dissection, patent ductus arteriosus
MYLK	Familial thoracic aortic aneurysm 7 (AD)	Ascending aortic aneurysm and dissection
PRKG1	Familial thoracic aortic aneurysm 8 (AD)	Early-onset aortic dissection, coronary artery aneurysm and dissection
<i>Other genes and chromosomal abnormalities</i>		
FOXE3	Familial thoracic aortic aneurysm 11 (AD)	Ascending aortic aneurysm and dissection
GATA5	No OMIM phenotype	Bicuspid aortic valve
MAT2A	No OMIM phenotype	Aortic root aneurysm, ascending aortic aneurysm, bicuspid aortic valve
NOTCH1	Aortic valve disease 1 (AD)	Bicuspid aortic valve, calcific aortic stenosis
SLC2A10	Arterial tortuosity syndrome (AR)	Generalized arterial tortuosity, arterial aneurysms and stenosis, skin hyperextensibility, joint laxity, inguinal and diaphragmatic hernia, elongated face, micrognathia
45,X0	Turner syndrome (chromosomal)	Short stature, lymphedema, webbed neck, low posterior hairline, low-set ears, amenorrhea, coarctation of the aorta, bicuspid aortic valve

AD, autosomal dominant; AR, autosomal recessive; OMIM, Online Mendelian Inheritance in Man (www.omim.org); XL, X-linked.

In sporadic TAA, we believe a single screening will suffice. However, if this screening takes place before the age of 40 years, a second screening might be considered at older age (above 50 years).

3.4.3. How to screen

The ESC and ACC/AHA guidelines do not comment on the imaging modality of choice.

Transthoracic echocardiography (TTE) is a relatively cheap, widely available and simple imaging modality for serial measurement of the aortic root, the most commonly affected site of the thoracic aorta. The aortic valve can be evaluated simultaneously. However, TTE cannot reliably image all aortic segments, in particular the arch and descending aorta may be difficult to visualize [36]. Given the high prevalence of abdominal aortic aneurysms among families with TAA, screening of the abdominal aorta should be routinely performed [37,38]. Computed tomography (CT) and magnetic resonance imaging (MRI) are excellent imaging modalities to visualize both the lumen and wall of the entire aorta and its side branches. Both techniques are suitable for diagnosis and monitoring of aortic aneurysms (location, size and extension) and its relationship to surrounding structures. Major advantages of CT are the short time required for image acquisition and processing, and

the ability to detect calcifications. Major drawbacks are the need for iodinated contrast agents with their potential adverse reactions, and the radiation exposure. The latter is especially relevant in young individuals, in particular pregnant women, and serial follow-up. MRI is the imaging modality of choice in these cases. Major drawbacks of MRI are the relatively limited availability, longer examination times, and higher costs. Furthermore, the use of MRI is limited in patients with metallic implants (e.g. pacemakers and occlusion devices) and claustrophobia [36].

In summary, TTE is the primary imaging tool for screening of family members. We recommend to perform CT or MRI at initial evaluation, to exclude the presence of aneurysms at areas poorly visualized by TTE. Furthermore, we encourage routine screening of the abdominal aorta. If there is a family history of aneurysms, dissections or tortuosity outside the thoracic aorta, more extensive screening should be considered. Screening for intracranial aneurysms is usually recommended in families with at least two affected [39].

4. Discussion

Patients with TAA often remain asymptomatic until aortic dissection or rupture occurs with high mortality rates. Preventive treatment saves

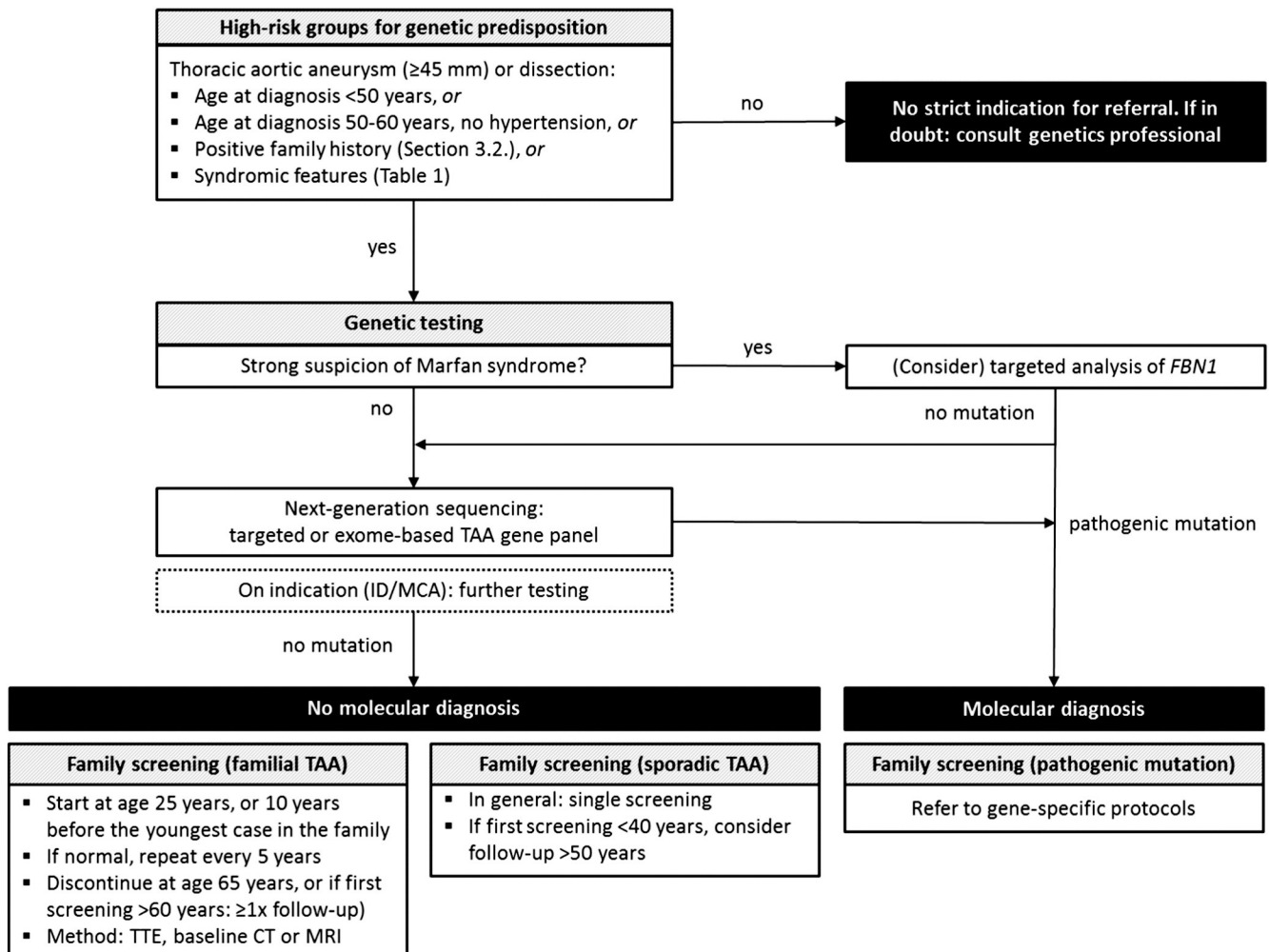


Fig. 1. Summary of recommendations. CT, computed tomography; FBN1, fibrillin 1 gene; ID, intellectual disability; MCA, multiple congenital anomalies; MRI, magnetic resonance imaging; TAA, thoracic aortic aneurysm; TTE, transthoracic echocardiography.

lives. Therefore, we should be able to identify those individuals at risk of having or developing thoracic aortic disease. In the absence of detailed international guidelines, we have put forward recommendations for family screening and genetic evaluation of TAA patients. Due to the lack of high level evidence, our recommendations are largely based on consensus opinion of experts. These may need to be revised and updated as new data become available. We hope that this consensus statement will stimulate further national and international discussions. This document is meant to be a first step towards further research and subsequent development of evidence-based guidelines.

Funding

This work was supported by the Dutch Heart Foundation (2014T007).

Conflicts of interest

None.

Acknowledgements

The authors would like to thank all members of the National Working Group on BAV & TAA for their time and dedication. The full text of this consensus statement (in Dutch) is available at <http://www.vkgn.org/vakinformatie/richtlijnen-en-protocollen>.

Appendix A. Supplementary data

Supplementary data to this article can be found online at <https://doi.org/10.1016/j.ijcard.2018.01.145>.

References

- [1] G. Albornoz, M.A. Coady, M. Roberts, et al., Familial thoracic aortic aneurysms and dissections—incidence, modes of inheritance, and phenotypic patterns, *Ann. Thorac. Surg.* 82 (4) (2006) 1400–1405.
- [2] V. Pressler, McNamara JJ, Aneurysm of the thoracic aorta. Review of 260 cases, *J. Thorac. Cardiovasc. Surg.* 89 (1) (1985) 50–54.
- [3] G.A. Kuzmik, M. Feldman, M. Tranquilli, J.A. Rizzo, M. Johnson, J.A. Elefteriades, Concurrent intracranial and thoracic aortic aneurysms, *Am. J. Cardiol.* 105 (3) (2010) 417–420.
- [4] R. Erbel, V. Aboyans, C. Boileau, et al., 2014 ESC guidelines on the diagnosis and treatment of aortic diseases: document covering acute and chronic aortic diseases of the thoracic and abdominal aorta of the adult. The task force for the diagnosis and treatment of aortic diseases of the European Society of Cardiology (ESC), *Eur. Heart J.* 35 (41) (2014) 2873–2926.
- [5] L.F. Hiratzka, G.L. Bakris, J.A. Beckman, et al., 2010 ACCF/AHA/AATS/ACR/ASA/SCA/SCAI/SIR/STS/SVM guidelines for the diagnosis and management of patients with thoracic aortic disease. A report of the American College of Cardiology Foundation/American Heart Association Task Force on Practice Guidelines, American Association for Thoracic Surgery, American College of Radiology, American Stroke Association, Society of Cardiovascular Anesthesiologists, Society for Cardiovascular Angiography and Interventions, Society of Interventional Radiology, Society of Thoracic Surgeons, and Society for Vascular Medicine, *J. Am. Coll. Cardiol.* 55 (14) (2010) e27–e129.

- [6] A. Pelliccia, F.M. Di Paolo, E. De Blasiis, et al., Prevalence and clinical significance of aortic root dilation in highly trained competitive athletes, *Circulation* 122 (7) (2010) 698–706 (3 p following).
- [7] S.D. Colan, D.B. McElhinney, E.C. Crawford, J.F. Keane, J.E. Lock, Validation and re-evaluation of a discriminant model predicting anatomic suitability for biventricular repair in neonates with aortic stenosis, *J. Am. Coll. Cardiol.* 47 (9) (2006) 1858–1865.
- [8] R.B. Devereux, G. de Simone, D.K. Arnett, et al., Normal limits in relation to age, body size and gender of two-dimensional echocardiographic aortic root dimensions in persons ≥ 15 years of age, *Am. J. Cardiol.* 110 (8) (2012) 1189–1194.
- [9] M. Gautier, D. Detaint, C. Fermanian, et al., Nomograms for aortic root diameters in children using two-dimensional echocardiography, *Am. J. Cardiol.* 105 (6) (2010) 888–894.
- [10] C.M. Reed, P.A. Richey, D.A. Pulliam, G.W. Somes, B.S. Alpert, Aortic dimensions in tall men and women, *Am. J. Cardiol.* 71 (7) (1993) 608–610.
- [11] L.A. Matura, V.B. Ho, D.R. Rosing, C.A. Bondy, Aortic dilatation and dissection in Turner syndrome, *Circulation* 116 (15) (2007) 1663–1670.
- [12] M. Covella, A. Milan, S. Totaro, et al., Echocardiographic aortic root dilatation in hypertensive patients: a systematic review and meta-analysis, *J. Hypertens.* 32 (10) (2014) 1928–1935 (discussion 35).
- [13] A.S. Chou, W.G. Ma, S.C. Mok, et al., Do familial aortic dissections tend to occur at the same age? *Ann. Thorac. Surg.* 103 (2) (2017) 546–550.
- [14] O.E. Dapunt, J.D. Galla, A.M. Sadeghi, et al., The natural history of thoracic aortic aneurysms, *J. Thorac. Cardiovasc. Surg.* 107 (5) (1994) 1323–1332 (discussion 32–3).
- [15] H. Achneck, B. Modi, C. Shaw, et al., Ascending thoracic aneurysms are associated with decreased systemic atherosclerosis, *Chest* 128 (3) (2005) 1580–1586.
- [16] D. Oladokun, B.O. Patterson, J. Sobocinski, et al., Systematic review of the growth rates and influencing factors in thoracic aortic aneurysms, *Eur. J. Vasc. Endovasc. Surg.* 51 (5) (2016) 674–681.
- [17] S.A. LeMaire, L. Russell, Epidemiology of thoracic aortic dissection, *Nat. Rev. Cardiol.* 8 (2) (2011) 103–113.
- [18] S.K. Prakash, C. Pedroza, Y.A. Khalil, D.M. Milewicz, Diabetes and reduced risk for thoracic aortic aneurysms and dissections: a nationwide case-control study, *J. Am. Heart Assoc.* 1 (2) (2012).
- [19] A. Pfeifer, P. Klatt, S. Massberg, et al., Defective smooth muscle regulation in cGMP kinase I-deficient mice, *EMBO J.* 17 (11) (1998) 3045–3051.
- [20] G. Faury, M. Pezet, R.H. Knutsen, et al., Developmental adaptation of the mouse cardiovascular system to elastin haploinsufficiency, *J. Clin. Invest.* 112 (9) (2003) 1419–1428.
- [21] L. Zaccagna, C. Vecchione, A. Notte, et al., *Emilin1* links TGF- β maturation to blood pressure homeostasis, *Cell* 124 (5) (2006) 929–942.
- [22] L. Campens, B. Callewaert, L. Muino Mosquera, et al., Gene panel sequencing in heritable thoracic aortic disorders and related entities inverted question mark results of comprehensive testing in a cohort of 264 patients, *Orphanet J. Rare Dis.* 10 (1) (2015) 9.
- [23] B. Loeys, L. Nuytinck, I. Delvaux, S. De Bie, A. De Paep, Genotype and phenotype analysis of 171 patients referred for molecular study of the fibrillin-1 gene *FBN1* because of suspected Marfan syndrome, *Arch. Intern. Med.* 161 (20) (2001) 2447–2454.
- [24] B. Loeys, J. De Backer, P. Van Acker, et al., Comprehensive molecular screening of the *FBN1* gene favors locus homogeneity of classical Marfan syndrome, *Hum. Mutat.* 24 (2) (2004) 140–146.
- [25] C. Stheneur, G. Colod-Beroud, L. Faivre, et al., Identification of the minimal combination of clinical features in probands for efficient mutation detection in the *FBN1* gene, *Eur. J. Hum. Genet.* 17 (9) (2009) 1121–1128.
- [26] M. Arslan-Kirchner, E. Arbustini, C. Boileau, et al., Clinical utility gene card for: hereditary thoracic aortic aneurysm and dissection including next-generation sequencing-based approaches, *Eur. J. Hum. Genet.* 24 (1) (2015) 146–150.
- [27] S.Q. Kuang, D.C. Guo, S.K. Prakash, et al., Recurrent chromosome 16p13.1 duplications are a risk factor for aortic dissections, *PLoS Genet.* 7 (6) (2011), e1002118.
- [28] A.S. Guemann, J. Andrieux, F. Petit, et al., *ELN* gene triplication responsible for familial supravalvular aortic aneurysm, *Cardiol. Young* 25 (4) (2015) 712–717.
- [29] Y. Hilhorst-Hofstee, B.C. Hamel, J.B. Verheij, et al., The clinical spectrum of complete *FBN1* allele deletions, *Eur. J. Hum. Genet.* 19 (3) (2011) 247–252.
- [30] B.M. Kamath, N.B. Spinner, K.M. Emerick, et al., Vascular anomalies in Alagille syndrome: a significant cause of morbidity and mortality, *Circulation* 109 (11) (2004) 1354–1358.
- [31] J.W. Cornwall, R.S. Green, J.C. Nielsen, B.D. Gelb, Frequency of aortic dilation in Noonan syndrome, *Am. J. Cardiol.* 113 (2) (2014) 368–371.
- [32] G.S. Oderich, T.M. Sullivan, T.C. Bower, et al., Vascular abnormalities in patients with neurofibromatosis syndrome type I: clinical spectrum, management, and results, *J. Vasc. Surg.* 46 (3) (2007) 475–484.
- [33] D.P. Judge, H.C. Dietz, Marfan's syndrome, *Lancet* 366 (9501) (2005) 1965–1976.
- [34] G. MacCarrick, J.H. Black 3rd, S. Bowdin, et al., Loeys-Dietz syndrome: a primer for diagnosis and management, *Genet. Med.* 16 (8) (2014) 576–587.
- [35] W.G. Ma, A.S. Chou, S.C.M. Mok, et al., Positive family history of aortic dissection dramatically increases dissection risk in family members, *Int. J. Cardiol.* 240 (2017) 132–137.
- [36] S.A. Goldstein, A. Evangelista, S. Abbara, et al., Multimodality imaging of diseases of the thoracic aorta in adults: from the American Society of Echocardiography and the European Association of Cardiovascular Imaging: endorsed by the Society of Cardiovascular Computed Tomography and Society for Cardiovascular Magnetic Resonance, *J. Am. Soc. Echocardiogr.* 28 (2) (2015) 119–182.
- [37] S.C. Bekkers, J.H. Habets, E.C. Cheriex, et al., Abdominal aortic aneurysm screening during transthoracic echocardiography in an unselected population, *J. Am. Soc. Echocardiogr.* 18 (5) (2005) 389–393.
- [38] F. Roshanali, M.H. Mandegar, M.A. Yousefnia, A. Mohammadi, B. Baharvand, Abdominal aorta screening during transthoracic echocardiography, *Echocardiography* 24 (7) (2007) 685–688.
- [39] W.I. Schievink, D.J. Schaid, H.M. Rogers, D.G. Piepgras, V.V. Michels, On the inheritance of intracranial aneurysms, *Stroke* 25 (10) (1994) 2028–2037.