



Half-Dose Photodynamic Therapy versus High-Density Subthreshold Micropulse Laser Treatment in Patients with Chronic Central Serous Chorioretinopathy

The PLACE Trial

Elon H.C. van Dijk, MD,¹ Sascha Fauser, MD, PhD,^{2,3} Myrte B. Breukink, MD, PhD,⁴ Rocio Blanco-Garavito, MD,⁵ Joannes M.M. Groenewoud, MSc,⁶ Jan E.E. Keunen, MD, PhD,⁴ Petrus J.H. Peters, MD,⁷ Greet Dijkman, MD,¹ Eric H. Souied, MD, PhD,⁵ Robert E. MacLaren, MD, PhD,⁸ Giuseppe Querques, MD, PhD,^{5,9} Susan M. Downes, MD, PhD,⁸ Carel B. Hoyng, MD, PhD,⁴ Camiel J.F. Boon, MD, PhD^{1,10}

Purpose: To compare the anatomic and functional efficacy and safety of half-dose photodynamic therapy (PDT) versus high-density subthreshold micropulse laser (HSML) treatment in patients with chronic central serous chorioretinopathy (cCSC).

Design: Open-label, multicenter, randomized controlled clinical trial.

Participants: Patients with cCSC whose disease had to be confirmed by both clinical characteristics and findings on multimodal imaging.

Methods: Eligible patients were randomized in a 1:1 allocation ratio. Treatment was evaluated during a follow-up visit, and the same treatment was repeated in patients who still demonstrated subretinal fluid (SRF).

Main Outcome Measures: The primary end point was the complete disappearance of SRF at the first evaluation visit at 6 to 8 weeks after treatment. As a secondary outcome measure, we assessed this anatomic result at the final evaluation visit at 7 to 8 months after treatment. Other secondary outcomes covered functional improvement and included change in best-corrected visual acuity (BCVA; measured in Early Treatment Diabetic Retinopathy Study [ETDRS] letters), retinal sensitivity (measured using microperimetry), and vision-related quality of life using a validated questionnaire.

Results: Between November 2013 and September 2016, 179 patients were included: 89 patients were assigned randomly to half-dose PDT, and 90 were assigned randomly to HSML treatment. At their first evaluation visit, SRF had resolved in 51.2% and 13.8% of patients, respectively ($P < 0.001$). At their final evaluation visit, a significantly higher percentage of PDT-treated patients demonstrated no SRF (67.2% vs. 28.8%; $P < 0.001$). Moreover, at the first evaluation visit, the PDT-treated patients showed a significantly higher increase in BCVA ($+4.60 \pm 6.62$ ETDRS letters vs. $+1.39 \pm 8.99$ ETDRS letters; $P = 0.011$), and a significantly higher increase in retinal sensitivity on microperimetry ($+2.01 \pm 3.04$ dB vs. $+0.92 \pm 3.65$ dB; $P = 0.046$); however, the improvement in vision-related quality of life was similar (score of $+2.87 \pm 8.35$ vs. $+2.56 \pm 7.36$, respectively; $P = 0.800$).

Conclusions: Half-dose PDT is superior to HSML for treating cCSC, leading to a significantly higher proportion of patients with complete resolution of SRF and functional improvement. *Ophthalmology* 2018;125:1547-1555 © 2018 by the American Academy of Ophthalmology. This is an open access article under the CC BY-NC-ND license (<http://creativecommons.org/licenses/by-nc-nd/4.0/>).



Supplemental material available at www.aaojournal.org.

Central serous chorioretinopathy (CSC) is a relatively common chorioretinal disease associated with a sudden loss of central vision. Although the cause of CSC is currently unknown, it affects primarily middle-aged men and is associated with corticosteroid use, stress, and certain genetic susceptibility factors.¹⁻³ In CSC, congestion,

hyperpermeability, and thickening of the choroid lead to impaired function of the retinal pigment epithelium (RPE), which normally maintains the outer blood-retina barrier. The resulting loss of integrity in this barrier leads to the accumulation of subretinal fluid (SRF), which leads to marked central vision loss, primarily affecting the macula.¹

In acute CSC, sudden-onset loss of central vision occurs because of a single point of leakage in the RPE; such cases tend to resolve spontaneously within several months.¹ However, at least 15% of patients with CSC have chronic SRF accumulation, with associated persistent vision loss and more extensive pathologic features of the retina and choroid. In these cases of chronic CSC (cCSC), persistent SRF can lead to progressive and irreversible damage to photoreceptors, resulting in both a guarded visual prognosis and a decline in quality of life among these relatively young patients.^{4–6} Although the efficacy of a variety of treatment methods for cCSC has been evaluated retrospectively, no evidence-based consensus regarding the optimal clinical management of cCSC currently exists because of a lack of large prospective, randomized controlled treatment trials.^{1,7} The 2 most commonly performed treatments for cCSC are photodynamic therapy (PDT) with verteporfin (Visudyne (Novartis, Basel, Switzerland)), originally developed to treat age-related macular degeneration,⁸ and high-density subthreshold micropulse laser (HSML) treatment. Although both treatments have reported anatomic success rates (i.e., complete resolution of SRF) of 41% to 100% and a favorable safety profile,^{1,7,9–15} there is currently no consensus with respect to which intervention may be more effective. For example, in the United Kingdom, the National Health Service has not approved either of these treatments for cCSC. Herein, we report the results of the Half-Dose Photodynamic Therapy versus High-Density Subthreshold Micropulse Laser Treatment in Patients with Chronic Central Serous Chorioretinopathy (PLACE) trial, a prospective multicenter study of patients with cCSC in which we directly compared both safety and efficacy between half-dose PDT and HSML treatment.

Methods

Study Design

The PLACE trial was an investigator-initiated, open-label, multicenter, randomized controlled treatment trial conducted at 5 academic medical centers in 4 European countries. The study was performed in accordance with the tenets of the Declaration of Helsinki, and all participating centers received approval from their respective institutional review board and ethics committee (clinicaltrials.gov identifier, NCT01797861). The protocol has been published previously.¹⁶

Participants

In this trial, we enrolled both men and women 18 years of age or older with cCSC, based on both clinical characteristics and findings on multimodal imaging. On multimodal imaging, SRF that affected the fovea visible on spectral-domain OCT scan (Fig 1A), 1 or more regions of active leakage (so-called hot spots) combined with RPE window defects visible on fluorescein angiography (FA; Fig 1B), and hyperfluorescent changes typical of cCSC visible on indocyanine green angiography (ICGA; Fig 1C) were mandatory to be eligible for inclusion. In addition, SRF on OCT, subjective visual symptoms related to cCSC, or both had to be present for at least 6 weeks for inclusion in the study. Subretinal fluid did not need to include the fovea at the first evaluation visit for the patient to be eligible for treatment, provided there was persistent

SRF in the macula, which was interpreted as persistent active disease. Study eye exclusion criteria included previous treatment for active CSC in the study eye; evidence of any other diagnosis that could explain SRF or vision loss; best-corrected visual acuity (BCVA) of 20/200 or worse (Snellen equivalent); profound chorioretinal atrophy in the central macular area visible on ophthalmoscopy and OCT; myopia exceeding 6 diopters; continuous or progressive vision loss, or both, SRF, or a combination thereof (visible on OCT) for more than 18 months; absence of active leakage visible on FA; absence of hyperfluorescence on ICGA; presence of soft drusen in the study eye, other eye, or both; and signs of choroidal neovascularization visible on ophthalmoscopy, FA, ICGA, or a combination thereof. Moreover, CSC patients with intraretinal fluid on OCT were not included in the study because this is often viewed as evidence of prolonged disease with more pronounced irreversible structural and functional changes, which may lead to a decreased response to treatment.¹⁷ More importantly, it may be difficult in CSC cases with intraretinal fluid—especially without OCT angiography, which was not available at the time of the start of the study—to exclude neovascularization definitely. Nonocular exclusion criteria included current topical or systemic treatment with corticosteroids, corticosteroid use within 3 months before the initial trial treatment, an anticipated start of corticosteroid treatment within the first 7 to 8 months after the start of the trial period, contraindications for PDT treatment (e.g., pregnancy, porphyria, or severely reduced liver function), and contraindications for FA or ICGA (e.g., known allergies, particularly to shellfish, previous reactions). Eligible patients were identified and counselled in their respective participating hospitals. Written informed consent was obtained from each patient before participation.

Randomization and Masking

Patients were assigned randomly (at a 1:1 ratio) to receive either half-dose PDT or HSML treatment. Randomization was performed using a central computerized procedure using block randomization with alternating block sizes of 4, 5, and 6, with stratification in the including hospitals, and without minimization. We did not take baseline characteristics of our patients into account before randomization, which can be considered to be standard for this type of study. The Department for Health Evidence at the Radboud University Medical Center performed the randomization procedure. Because of the nature of the interventions, neither the clinical staff nor the patients could be blinded with respect to the treatment group.

Procedures

Each patient's demographic characteristics and medical history were documented at the baseline visit. An extensive ophthalmologic examination was performed, including assessing Early Treatment Diabetic Retinopathy Study (ETDRS) BCVA, retinal sensitivity (measured using microperimetry), and vision-related quality of life (measured using the validated 25-item National Eye Institute Visual Function Questionnaire [NEI-VFQ25]).¹⁸ Microperimetry was measured using 2 different devices, the MPI (Nidek Technologies, Padova, Italy) and the Macular Integrity Assessment (CenterVue, Padova, Italy); a previously published conversion method then was applied to obtain values with the same dynamic range.¹⁹ Fundus photography, OCT, fundus autofluorescence, fluorescein angiography, and ICGA imaging were performed by certified medical photographers. After eligibility was determined by a central reading center, patients were assigned randomly to the treatment groups and then received either half-dose PDT or HSML treatment within 3 weeks of randomization. For each treatment

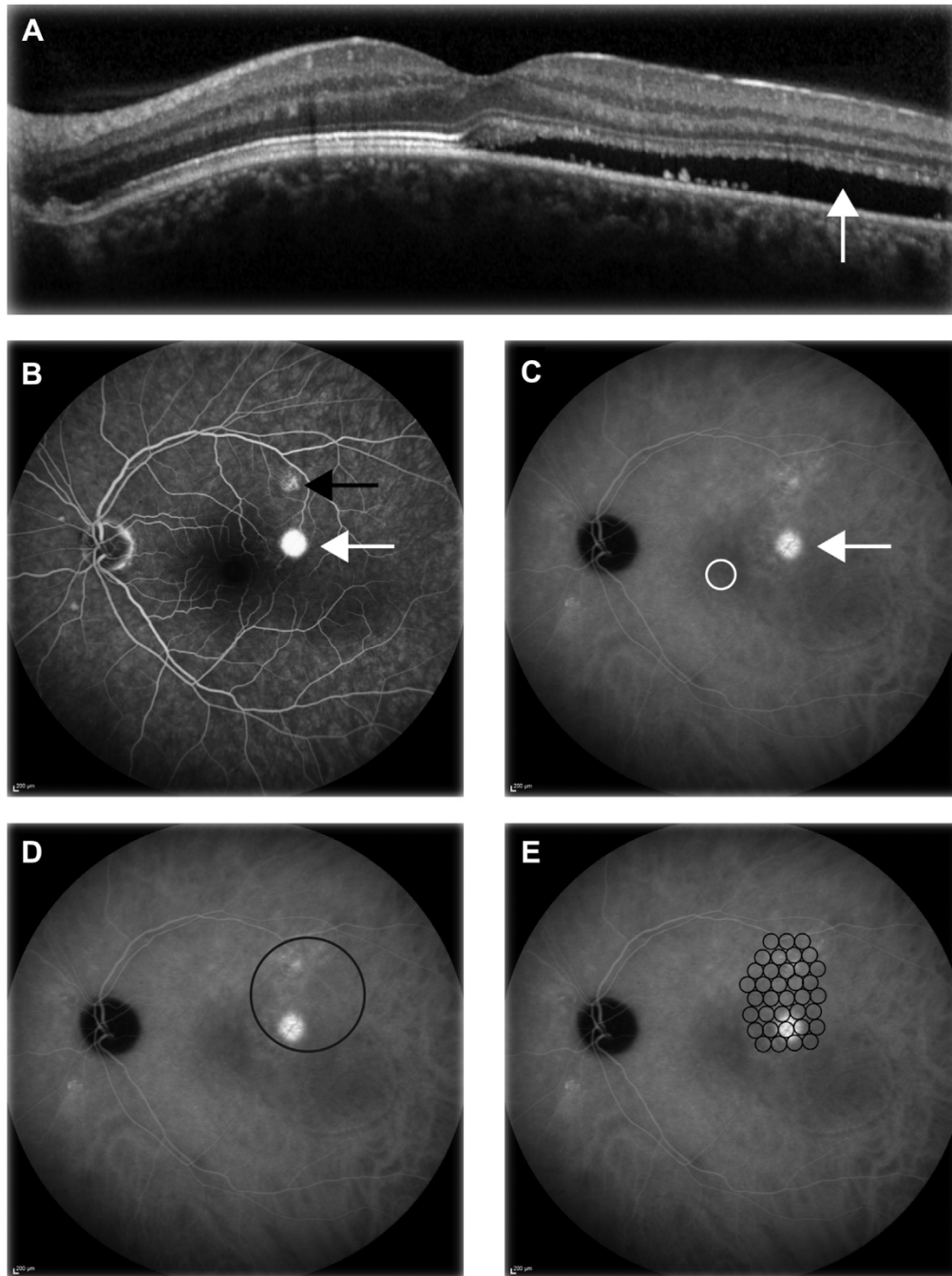


Figure 1. Example images from a 48-year-old man with chronic central serous chorioretinopathy showing the areas that would be treated using half-dose photodynamic therapy (PDT) and the areas that would be treated using high-density subthreshold micropulse laser (HSML). **A**, OCT image showing subretinal fluid (*arrow*). **B**, Fluorescein angiography image showing a hot spot of leakage (*white arrow*) as well as retinal pigment epithelium abnormalities (*black arrow*). **C**, Indocyanine green angiography image showing hyperfluorescent changes in the choroid; the arrow indicates the most evident changes, which extend more superiorly; the fovea is indicated by the white circle. **D**, Indocyanine green angiography image showing the area that would be treated using half-dose PDT, indicated by the black circle. **E**, Indocyanine green angiography image showing the area that would be treated using HSML treatment, indicated by small black circles. Note that the area depicted for HSML treatment is a schematic representation only; the actual nonoverlapping adjacent spots relative to the fundus are smaller than depicted here.

method, the ocular area to be treated was determined by the central reading center based on the hyperfluorescent areas of leakage seen on ICGA to avoid interobserver variability on the interpretation of the extent these choroidal abnormalities. This approach was used

because ICGA-guided therapy targets the primary affected tissue (i.e., the choroid) and decreases the risk of undertreatment because ICGA generally reveals more extensive abnormalities compared with FA (Fig 1). Care was taken to include the focal area(s) of

leakage on FA in the treatment area. All diagnostic and therapeutic devices were maintained and serviced by certified personnel at the participating centers in accordance with the manufacturers' instructions.

Verteporfin was developed initially for PDT-based treatment of neovascular age-related macular degeneration; however, it is now used commonly as an off-label medication for treating cCSC.^{7,8} A safety-enhanced protocol, in which half the dosage of verteporfin is used, has been shown to induce the desired treatment outcome in a similar percentage as after performing PDT using full-dose verteporfin, but reducing the occurrence of adverse events (AEs).^{11,20} Patients in the half-dose PDT group received an intravenous infusion of 3 mg/m² verteporfin delivered over a period of 10 minutes. Exactly 15 minutes after the start of this infusion, a contact lens was positioned on the eye, the treatment spot was centered using predefined criteria for ICGA-guided treatment, and PDT was applied using standard parameters (fluency, 50 J/cm²; wavelength, 689 nm; and treatment duration, 83 seconds). Where necessary, the fovea was included in the area to be treated. In the HSML-treated group, several adjacent nonoverlapping spots were applied during ICGA-guided treatment using an 810-nm diode laser, keeping a distance of 500 µm from the foveal center. To minimize the likelihood of undertreatment, a relatively high power of 1800 mW (which is considered to be within the upper range of subthreshold settings) was applied to a relatively large ICGA-guided treatment area.²¹ In addition, the duty cycle was 5%, the frequency was 500 Hz, the exposure time was 0.2 seconds per spot, and the spot size was 125 µm. Because subthreshold treatment was desired, the power of the treatment was reduced in 300-mW increments if any retinal discoloration was visible after a test treatment spot was applied outside the macular area, at the beginning of the procedure. All laser operators in the study (S.F., J.E.E.K., P.J.H.P., G.D., E.H.S., R.E.M., G.Q., S.M.D.) underwent formal training and were approved by the chief investigator (C.J.F.B.).

In patients in whom SRF was still present within the macular area at evaluation 6 to 8 weeks after treatment (i.e., at the first evaluation visit), the same treatment was repeated, which is often considered to be part of standard care, and a second evaluation visit was scheduled 6 to 8 weeks after this second treatment. All patients underwent a final evaluation visit 7 to 8 months after the first treatment. At each evaluation visit, the patients underwent a complete ophthalmologic examination and imaging as described previously.

Outcomes

The primary outcome measure was the complete absence of SRF on OCT (anatomic success) at the first evaluation visit (i.e., 6 to 8 weeks after the first treatment). In addition, the following protocol-defined key secondary outcome measures in both the half-dose PDT group and the HSML treatment group were assessed: a complete absence of SRF on OCT at the final evaluation visit; the number of repeat (i.e., second) treatments needed in each treatment arm; and the change in ETDRS BCVA, retinal sensitivity on microperimetry, and vision-related quality of life measured using the NEI-VFQ25, from baseline to both first and final evaluation visits. Adverse events and serious AEs were reported to the data safety monitoring board, which had the option to terminate the study prematurely if deemed necessary.

Statistical Analysis

This randomized controlled trial was designed to be a superiority study. We calculated that a sample size of 156 patients (78 in each group) would be required at the first evaluation visit to detect a

difference of 22% in treatment success with a power of at least 80%; this calculation was based on previously published retrospective studies regarding PDT and HSML treatment in cCSC, possible positive publication bias, our own empirical experience, and an interim analysis.^{1,7,11,12,14}

Statistical analysis on the primary outcome measure was performed using a cross-table to assess the relative risk. The key secondary analyses, complete absence of SRF on OCT at the final evaluation visit and number of repeat treatments needed in each treatment arm, also were performed using a cross-table. Continuous secondary end points were analyzed using an analysis of covariance with baseline and treatment as factors. Categorical secondary variables were analyzed using a chi-square test. Changes in the replies to the NEI-VFQ25 are reported using a scale ranging from 0 to 100, as described previously.¹⁸ The PLACE trial was registered internationally with ClinicalTrials.gov (identifier, NCT01797861) and was assigned the EudraCT number 2012-004555-36.

Results

We initially screened a total of 309 patients for eligibility; after applying the inclusion and exclusion criteria, 179 patients (89 patients in the PDT treatment arm and 90 patients in the HSML treatment arm) were determined to be eligible and were enrolled between November 2013 and September 2016 (Fig 2). Eighty patients in each treatment arm underwent their respective treatment in accordance with the study protocol (Fig 2). Because of the presence of SRF at the first evaluation visit, 108 of the original 160 patients (67.5%) underwent repeat treatment. Six patients who would have required repeat treatment based on the protocol did not receive this second treatment (Fig S1, available at www.aaojournal.org), and 1 patient was excluded from the trial after the first evaluation visit because of corticosteroid use. Two patients did not attend the second evaluation visit, but did attend the final evaluation visit. Nineteen patients did not attend the final evaluation visit. In total, 67 and 66 patients in the half-dose PDT and HSML groups, respectively, were analyzed after their final evaluation visit (Fig 2).

The baseline characteristics were balanced between the 2 groups (Table 1). Specifically, there was no significant difference between the half-dose PDT group and the HSML-treated group with respect to BCVA (76.9±8.32 ETDRS letters vs. 75.9±9.22 ETDRS letters, respectively; $P = 0.478$), retinal sensitivity measured using microperimetry (20.5±4.21 dB vs. 20.3±4.80 dB, respectively; $P = 0.755$), or vision-related quality of life measured using the NEI-VFQ25 (81.2±13.0 points vs. 83.1±11.5 points, respectively; $P = 0.158$).

At the first evaluation visit, a significantly higher percentage of patients in the PDT-treated group showed complete resolution of SRF (the primary outcome measure) compared with the HSML-treated group (51.2% vs. 13.8%, respectively; $P < 0.001$). After HSML treatment, the relative risk of persistent SRF at the first evaluation visit after HSML treatment was 1.77 (95% confidence interval, 1.39–2.52) compared with receiving half-dose PDT. At the final evaluation visit, a significantly higher percentage of patients in the PDT group showed complete resolution of SRF compared with the HSML-treated group (67.2% vs. 28.8%, respectively; $P < 0.001$), and the relative risk of persistent SRF at the final evaluation visit after HSML treatment was 2.17 (95% confidence interval, 1.49–3.16) compared with receiving half-dose PDT (Table 2).

In the half-dose PDT group, the mean PDT laser spot size for the first and second treatments was 4.01±1.57 mm and 4.04±1.54 mm, respectively. In the HSML treatment group, 187±209 spots with a mean power of 1739±213 mW were applied at the first

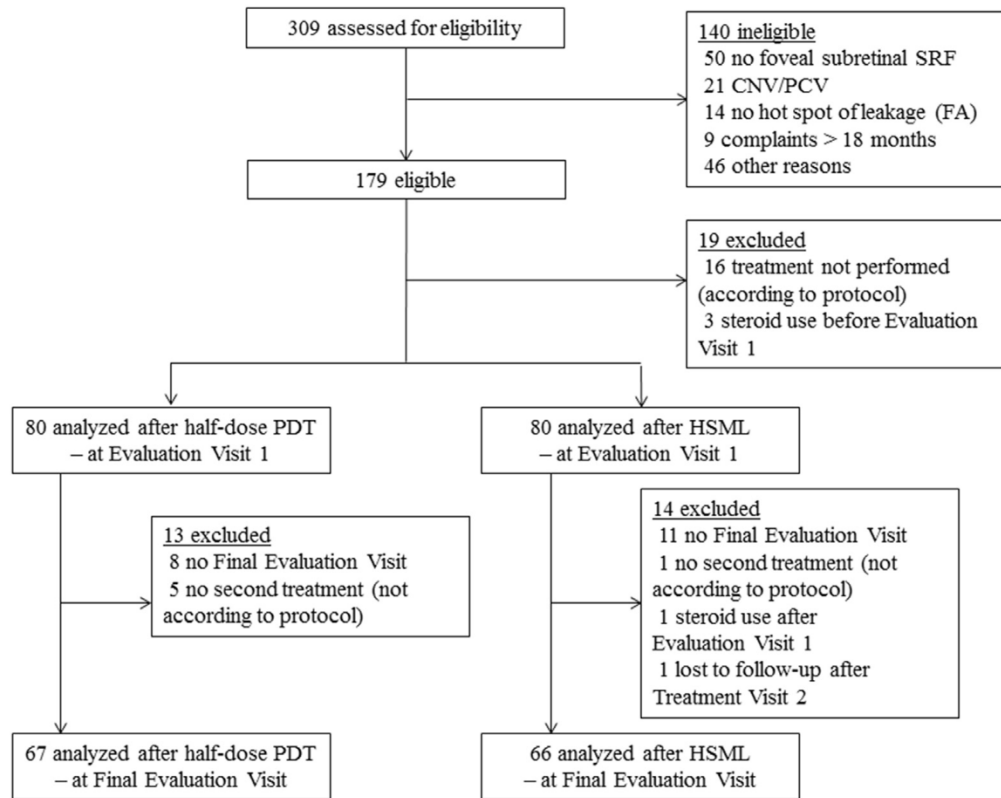


Figure 2. Flow diagram showing the trial profile for the primary outcome population. CNV = choroidal neovascularization; FA = fluorescein angiography; HSML = high-density subthreshold micropulse laser treatment; PCV = polypoidal choroidal vasculopathy; PDT = photodynamic therapy; SRF = subretinal fluid.

treatment, and 188 ± 237 spots with a mean power of 1746 ± 184 mW were applied at the second treatment. A total of 99 patients required a second evaluation visit because of undergoing repeat treatment based on the presence of SRF measured on OCT at the first evaluation visit; during the second evaluation visit, 32.4% of patients (11 of 34 patients) and 15.4% of patients (10 of 65 patients) in the half-dose PDT group and HSML group, respectively, showed complete resolution of SRF on OCT; however, this difference was not statistically significant ($P = 0.053$).

At the first evaluation visit, the patients in the half-dose PDT group showed a significantly higher increase in BCVA compared with the HSML treatment group (4.60 ± 6.62 ETDRS letters vs. 1.39 ± 8.99 ETDRS letters, respectively; $P = 0.011$). At the final evaluation visit, the increase in BCVA relative to baseline was 6.78 ± 8.54 ETDRS letters and 4.48 ± 7.29 ETDRS letters in the PDT and HSML groups, respectively ($P = 0.099$). Retinal sensitivity on microperimetry increased in both treatment groups, and this increase was significantly higher in the PDT group compared with the HSML-treated group at both the first evaluation visit (2.01 ± 3.04 dB vs. 0.92 ± 3.65 dB, respectively; $P = 0.046$) and the final evaluation visit (3.24 ± 3.08 dB vs. 1.38 ± 4.45 dB, respectively; $P = 0.008$). Finally, the change in vision-related quality of life measured using the NEI-VFQ25 increased in both groups; however, this increase did not differ significantly between the PDT- and HSML-treated groups at either the first evaluation visit (2.87 ± 8.35 points vs. 2.56 ± 7.36 points, respectively; $P = 0.800$) or the final evaluation visit (7.03 ± 10.8 points vs. 4.48 ± 9.85 points, respectively; $P = 0.158$; [Table 2](#)).

During the course of the trial, SRF recurred in 4 patients in the PDT group and 1 patient in the HSML group (corresponding to 5%

and 1.3% of patients, respectively; $P = 0.176$). Twelve AEs were recorded in 10 patients in the PDT group, and 9 AEs were recorded in 7 patients in the HSML group (corresponding to 12.5% and 8.8% of patients, respectively). None of these AEs were treatment related. A total of 4 patients (2 each in the PDT and HSML groups) reported a serious AE that was unrelated to the study treatment, and none of the patients died during the trial. One patient in the HSML group demonstrated a vision-threatening AE in which BCVA decreased by more than 30 ETDRS letters; this decline in visual acuity was considered to have been caused by an increase in SRF, despite treatment. All of the side effects reported in this trial are listed in [Table 3](#).

Discussion

Treatment usually is indicated for patients with cCSC, because persistent SRF leakage in the macula can lead to significant visual disability and decreased vision-related quality of life.^{1,5} To date, however, the best treatment for cCSC has been the subject of controversy because of a lack of prospective randomized controlled trials, leading to a wide variety of recommended treatments.^{1,7,22} Herein, we performed a large prospective, multicenter, randomized controlled treatment trial comparing the 2 most commonly used treatments for cCSC.^{1,7,11,12,14} We found that the efficacy of half-dose PDT with respect to complete resolution of SRF was significantly higher compared with HSML

Table 1. Baseline Characteristics of Patients Included in Assessment of Primary Outcome Measure

Characteristics	Half-Dose Photodynamic Therapy (n = 80)	High-Density Subthreshold Micropulse Laser Treatment (n = 80)	P Value
Demographics			
Gender			0.072
Female	20 (25)	11 (13.8)	
Male	60 (75)	69 (86.3)	
Age (yrs)	48.9±8.9	48.6±8.3	0.819
Ethnicity			
White	71 (88.8)	70 (87.5)	0.807
Other	9 (11.2)	10 (12.5)	
Clinical characteristics			
Duration of visual symptoms (mos)	6 (3.76–11)	6 (4–9.75)	0.796
Stress during month before visual symptoms started, measured with the Cohen stress questionnaire outcome on a scale from 0–40	14.7±7.4*	14.8±7.5	0.922
Best-corrected visual acuity (Early Treatment Diabetic Retinopathy Study letters)	76.9±8.32	75.9 ±9.22	0.478
Retinal sensitivity on microperimetry (dB)	20.5±4.21	20.3±4.80	0.755
Composite score on vision-related quality of life measured with the NEI-VFQ25	81.2±13.0	83.1±11.5	0.158

NEI-VFQ25 = 25-item National Eye Institute Visual Function Questionnaire.

Data are no. (%), median (range), or mean ± standard deviation.

*Data were available for 79 patients.

treatment at both short-term and long-term follow-up visits. Moreover, functional outcome was better after half-dose PDT compared with HSML treatment with respect to both increased retinal sensitivity at the first and final evaluation visits and increased BCVA at the first evaluation visit. In contrast, the treatment groups did not differ significantly with respect to BCVA at the final evaluation visit or to overall quality of life (measured using the NEI-VFQ25). Our study was designed primarily to assess a morphologic end point, namely the complete resolution of SRF, which is a prerequisite for preserving or restoring function, or both. In

this respect, microperimetry may be a more sensitive and earlier functional end point than BCVA, given that the recovery of BCVA can be delayed in cCSC after treatment.⁹

The significantly better anatomic and functional outcomes after PDT treatment may be attributed to the fact that PDT targets the choroidal tissue, which seems to be the tissue primarily affected in cCSC. In CSC, the accumulation of SRF—which affects photoreceptor function and thus vision—results from a leaky outer blood–retina barrier at the level of the RPE; however, this impaired barrier function is likely induced by a primary dysfunction of the underlying choroid, given that

Table 2. Treatment Effect on Primary and Secondary Outcome Measures

Outcome Measures	Half-Dose Photodynamic Therapy (n)	High-Density Subthreshold Micropulse Laser Treatment (n)	P Value
Complete resolution of subretinal fluid			
At first evaluation visit (at 6–8 wks after treatment)	51.2% (41/80)	13.8% (11/80)	< 0.001
At final evaluation visit (at 7–8 mos after treatment)	67.2% (45/67)	28.8% (19/66)	< 0.001
Change in best-corrected visual acuity (Early Treatment Diabetic Retinopathy Study letters)*			
At first evaluation visit (at 6–8 wks after treatment)	+4.60±6.62 (n = 80)	+1.39±8.99 (n = 80)	0.011
At final evaluation visit (at 7–8 mos after treatment)	+6.78±8.54 (n = 67)	+4.48±7.29 (n = 66)	0.099
Change in retinal sensitivity on microperimetry (dB)*			
At first evaluation visit (at 6–8 wks after treatment)	+2.01±3.04 (n = 76)†	+0.92±3.65 (n = 77)†	0.046
At final evaluation visit (at 7–8 mos after treatment)	+3.24±3.08 (n = 62)†	+1.38±4.45 (n = 60)†	0.008
Change in composite score on vision-related quality of life using NEI-VFQ25 (on a scale from 0–100)*			
At first evaluation visit (at 6–8 wks after treatment)	+2.87±8.35 (n = 80)	+2.56±7.36 (n = 79)†	0.800
At final evaluation visit (at 7–8 mos after treatment)	+7.03±10.8 (n = 67)	+4.48±9.85 (n = 66)	0.158

NEI-VFQ25 = 25-item National Eye Institute Visual Function Questionnaire.

Data are no. (%) or mean ± standard deviation.

*Compared with baseline.

†Data were not available for all patients.

Table 3. Adverse Events

	Half-Dose Photodynamic Therapy (80 Patients)	High-Density Subthreshold Micropulse Laser Treatment (80 Patients)
Serious adverse events*	2 (2 patients)	2 (2 patients)
No. of adverse events	12 (10 patients)	9 (7 patients)
Viral infectious disease of the upper respiratory tract	0	3
Corneal erosion	2	0
Arthritis	1	0
Allergic response to verteporfin	1	0
Allergic response to dye administered during angiography	1	0
Bladder cancer	1	0
Chalazion	0	1
Finger laceration	1	0
Gingivitis	1	0
Keratoconjunctivitis sicca	0	1
Lateral epicondylitis	1	0
Newly diagnosed arterial hypertension	1	0
Spinal disc herniation	1	0
Squamous cell carcinoma of the skin	1	0
Tenosynovitis	0	1
Uterine fibroids	0	1
Vitamin D deficiency	0	1
YAG laser capsulotomy for posterior capsule opacification	0	1
Vision-threatening adverse events	0	1

*Note that none of the adverse events were related to the study treatment. YAG = yttrium aluminum garnet.

choroidal abnormalities (imaged using ICGA) often outweigh both the changes in the RPE and leakage visible on FA. The effect of PDT seems to depend on transient choroidal ischemia and subsequent choroidal vascular remodelling²³; in contrast, the delivery of brief subthreshold micropulses to the RPE during HSML treatment has been suggested to induce the production of intracellular biological factors that stimulate RPE function without causing visible damage to the retina.²⁴ Given the significant differences in treatment outcome between half-dose PDT and HSML treatment in our study, we suggest that choroidal abnormalities should be targeted in cCSC. Nevertheless, whether HSML treatment has therapeutic effects on the choroid beyond the RPE currently is unknown. None of the patients in either treatment group reported treatment-related AEs. This finding is consistent with previous reports of extremely rare AEs when applying PDT at reduced settings; such rare AEs include choroidal neovascularization and occur in less than 1% of patients.^{11,14,25–28} Importantly, choroidal neovascularization has also been described as part of the natural course of cCSC.²⁹

In this trial, the observed treatment outcome in both treatment groups was likely the result of the intervention, because we included only patients who showed SRF for at least 6 weeks and who demonstrated typical findings of

active cCSC on multimodal imaging at presentation; thus, SRF would not be expected to resolve spontaneously in these patients. Moreover, we measured a significant difference in outcome between the half-dose PDT group and the HSML group. In the HSML treatment group, the laser power was in the upper range of subthreshold settings, and adjacent laser spots were treated to achieve confluent treatment coverage; in addition, the area to be treated was relatively large and guided by ICGA. Despite these measures to minimize undertreatment with HSML,²¹ the outcome was still more favorable in the group that received half-dose PDT. Importantly, the patients in the PDT group received only half of the dose of verteporfin originally described for treating neovascular age-related macular degeneration⁸; this reduced dose was chosen to minimize the occurrence of serious AEs after treatment while still providing comparable treatment outcomes.^{20,30,31} However, a distance of 500 μm from the foveal center was kept only in the HSML-treated group to prevent possible damage to the fovea, which has been described to be a possible adverse effect of treatment and could have influenced the results of our study. Still, we assume that not including the fovea in the area to be treated could have affected the study outcome only minimally because the fovea included only a very small part of the total area that required treatment; treatment often was quite extensive because it was based on ICGA abnormalities while using HSML settings at the upper limit for this treatment technique.

The strengths of the PLACE trial include its prospective design and the relatively large number of patients. In addition, we used the complete resolution of SRF on OCT as the desired treatment effect, because the prolonged presence of SRF can cause irreversible photoreceptor damage.⁶ Moreover, our cohort of cCSC patients was well characterized, and the diagnosis of cCSC was verified in each patient by a central reading center based on typical findings of cCSC on multimodal imaging; in addition, we excluded patients who had undergone previous cCSC treatment, who had undergone previous or current corticosteroid use, and whose disease duration was longer than 18 months. These criteria resulted in a cohort of patients who ranged from demonstrating relatively focal cCSC to more extensive cCSC. Finally, with respect to both anatomic and functional outcomes, a follow-up assessment was performed 7 to 8 months after the first treatment; thus, prolonged follow-up studies should be performed to assess the long-term efficacy of both treatments, particularly given that SRF recurred in 5 patients during the follow-up period.

In conclusion, the results of our large prospective, multicenter, randomized controlled treatment trial showed that half-dose PDT provides superior outcome compared with HSML treatment in patients with cCSC. This finding provides key insight into developing best-practice guidelines for treating CSC. In addition, the results of this trial may be used to justify changing the existing reimbursement restrictions in several countries regarding the off-label use of verteporfin in PDT for treating cCSC.

Acknowledgments

The authors thank the members of the data safety monitoring committee, G. J. van der Wilt (chair), J. in 't Hout, and N. Crama, for monitoring the trial and evaluating the interim analysis.

References

- Daruich A, Matet A, Dirani A, et al. Central serous chorioretinopathy: recent findings and new physiopathology hypothesis. *Prog Retin Eye Res*. 2015;48:82–118.
- de Jong EK, Breukink MB, Schellevis RL, et al. Chronic central serous chorioretinopathy is associated with genetic variants implicated in age-related macular degeneration. *Ophthalmology*. 2015;122(3):562–570.
- van Dijk EHC, Schellevis RL, van Bergen M, et al. Association of a haplotype in the nr3c2 gene, encoding the mineralocorticoid receptor, with chronic central serous chorioretinopathy. *JAMA Ophthalmol*. 2017;135(5):446–451.
- Loo RH, Scott IU, Flynn Jr HW, et al. Factors associated with reduced visual acuity during long-term follow-up of patients with idiopathic central serous chorioretinopathy. *Retina*. 2002;22(1):19–24.
- Breukink MB, Dingemans AJ, den Hollander AI, et al. Chronic central serous chorioretinopathy: long-term follow-up and vision-related quality of life. *Clin Ophthalmol*. 2017;11:39–46.
- Wang MS, Sander B, Larsen M. Retinal atrophy in idiopathic central serous chorioretinopathy. *Am J Ophthalmol*. 2002;133(6):787–793.
- Salehi M, Wenick AS, Law HA, et al. Interventions for central serous chorioretinopathy: a network meta-analysis. *Cochrane Database Syst Rev*. 2015;(12), CD011841.
- Guidelines for using verteporfin (Visudyne) in photodynamic therapy to treat choroidal neovascularization due to age-related macular degeneration and other causes. *Retina*. 2002;22(1):6–18.
- Scholz P, Ersoy L, Boon CJ, Fauser S. Subthreshold micropulse laser (577 nm) treatment in chronic central serous chorioretinopathy. *Ophthalmologica*. 2015;234(4):189–194.
- Lim JJ, Glassman AR, Aiello LP, et al. Collaborative retrospective macula society study of photodynamic therapy for chronic central serous chorioretinopathy. *Ophthalmology*. 2014;121(5):1073–1078.
- Chan WM, Lai TY, Lai RY, et al. Safety enhanced photodynamic therapy for chronic central serous chorioretinopathy: one-year results of a prospective study. *Retina*. 2008;28(1):85–93.
- Yadav NK, Jayadev C, Mohan A, et al. Subthreshold micropulse yellow laser (577 nm) in chronic central serous chorioretinopathy: safety profile and treatment outcome. *Eye (Lond)*. 2015;29(2):258–264. quiz 265.
- Malik KJ, Sampat KM, Mansouri A, et al. Low-intensity/high-density subthreshold micropulse diode laser for chronic central serous chorioretinopathy. *Retina*. 2015;35(3):532–536.
- Tseng CC, Chen SN. Long-term efficacy of half-dose photodynamic therapy on chronic central serous chorioretinopathy. *Br J Ophthalmol*. 2015;99(8):1070–1077.
- Silva RM, Ruiz-Moreno JM, Gomez-Ulla F, et al. Photodynamic therapy for chronic central serous chorioretinopathy: a 4-year follow-up study. *Retina*. 2013;33(2):309–315.
- Breukink MB, Downes SM, Querques G, et al. Comparing half-dose photodynamic therapy with high-density subthreshold micropulse laser treatment in patients with chronic central serous chorioretinopathy (the place trial): study protocol for a randomized controlled trial. *Trials*. 2015;16:419.
- Iida T, Yannuzzi LA, Spaide RF, et al. Cystoid macular degeneration in chronic central serous chorioretinopathy. *Retina*. 2003;23(1):1–7; quiz 137–138.
- Mangione CM, Lee PP, Gutierrez PR, et al. Development of the 25-item National Eye Institute Visual Function Questionnaire. *Arch Ophthalmol*. 2001;119(7):1050–1058.
- Parodi MB, Triolo G, Morales M, et al. Mip1 and maia fundus perimetry in healthy subjects and patients affected by retinal dystrophies. *Retina*. 2015;35(8):1662–1669.
- Nicolo M, Eandi CM, Alovisei C, et al. Half-fluence versus half-dose photodynamic therapy in chronic central serous chorioretinopathy. *Am J Ophthalmol*. 2014;157(5):1033–1037.
- Wood EH, Karth PA, Sanislo SR, et al. Nondamaging retinal laser therapy for treatment of central serous chorioretinopathy: what is the evidence? *Retina*. 2017;37(6):1021–1033.
- Mehta PH, Meyerle C, Sivaprasad S, et al. Preferred practice pattern in central serous chorioretinopathy. *Br J Ophthalmol*. 2017;101(5):587–590.
- Chan WM, Lam DS, Lai TY, et al. Choroidal vascular remodelling in central serous chorioretinopathy after indocyanine green guided photodynamic therapy with verteporfin: a novel treatment at the primary disease level. *Br J Ophthalmol*. 2003;87(12):1453–1458.
- Yu AK, Merrill KD, Truong SN, et al. The comparative histologic effects of subthreshold 532- and 810-nm diode micropulse laser on the retina. *Invest Ophthalmol Vis Sci*. 2013;54(3):2216–2224.
- Karakus SH, Basarir B, Pinarci EY, et al. Long-term results of half-dose photodynamic therapy for chronic central serous chorioretinopathy with contrast sensitivity changes. *Eye (Lond)*. 2013;27(5):612–620.
- Lim JW, Kang SW, Kim YT, et al. Comparative study of patients with central serous chorioretinopathy undergoing focal laser photocoagulation or photodynamic therapy. *Br J Ophthalmol*. 2011;95(4):514–517.
- Senturk F, Karacorlu M, Ozdemir H, et al. Microperimetric changes after photodynamic therapy for central serous chorioretinopathy. *Am J Ophthalmol*. 2011;151(2):303–309.e1.
- Smretschnig E, Ansari-Shahrezaei S, Hagen S, et al. Half-fluence photodynamic therapy in chronic central serous chorioretinopathy. *Retina*. 2013;33(2):316–323.
- Chan WM, Lam DS, Lai TY, et al. Treatment of choroidal neovascularization in central serous chorioretinopathy by photodynamic therapy with verteporfin. *Am J Ophthalmol*. 2003;136(5):836–845.
- Schnurrbusch UE, Jochmann C, Einbock W, Wolf S. Complications after photodynamic therapy. *Arch Ophthalmol*. 2005;123(10):1347–1350.
- Kim YK, Ryoo NK, Woo SJ, Park KH. Comparison of visual and anatomical outcomes of half-fluence and half-dose photodynamic therapy in eyes with chronic central serous chorioretinopathy. *Graefes Arch Clin Exp Ophthalmol*. 2015;53(12):2063–2073.

Footnotes and Financial Disclosures

Originally received: November 20, 2017.

Final revision: April 11, 2018.

Accepted: April 16, 2018.

Available online: May 15, 2018.

Manuscript no. 2017-2591.

¹ Department of Ophthalmology, Leiden University Medical Center, Leiden, the Netherlands.

² Department of Ophthalmology, University Hospital of Cologne, Cologne, Germany.

³ F. Hoffmann-La Roche, Basel, Switzerland.

⁴ Department of Ophthalmology, Radboud University Medical Center, Nijmegen, the Netherlands.

⁵ Department of Ophthalmology, Centre Hospitalier Intercommunal de Creteil University Paris Est Creteil, Creteil, France.

⁶ Department for Health Evidence, Radboud University Medical Center, Nijmegen, the Netherlands.

⁷ Department of Ophthalmology, Bergman Clinics B.V., Velp, the Netherlands.

⁸ Oxford Eye Hospital, John Radcliffe Hospital, Oxford, United Kingdom.

⁹ Department of Ophthalmology, IRCCS Ospedale San Raffaele, Vita-Salute University, Milan, Italy.

¹⁰ Department of Ophthalmology, Academic Medical Center, University of Amsterdam, Amsterdam, the Netherlands.

Presented at: European Society of Retina Specialists Annual Meeting, September 2017, Barcelona, Spain.

Financial Disclosure(s):

The author(s) have no proprietary or commercial interest in any materials discussed in this article.

Supported by Stichting Macula Fonds; Retina Nederland Onderzoek Fonds; Stichting Blinden-Penning; Algemene Nederlandse Vereniging ter Voorkoming van Blindheid; Landelijke Stichting voor Blinden en Slechtzienden, which contributed through Uitzicht (Delft, the Netherlands); Rotterdamse Stichting Blindenbelangen (Rotterdam, the Netherlands); Stichting Leids Oogheelkundig Ondersteuningsfonds (Leiden, the Netherlands); Haagse Stichting Blindenhulp (The Hague, the Netherlands); Stichting Ooglijders (Rotterdam, the Netherlands); and the Oxford NIHR Biomedical Research Center (Oxford, United Kingdom); the Gisela Thier Fellowship of Leiden University, Leiden, the Netherlands (C.J.F.B.); and the Netherlands Organisation for Scientific Research (VENI grant to C.J.F.B.). These funding organizations provided unrestricted grants and had no role in the design or conduct of this research. This investigator-initiated study received funding

from Novartis Pharma B.V. (Arnhem, the Netherlands) solely for the purchase of verteporfin (Visudyne) to enable photodynamic therapy treatment at the Oxford site, because photodynamic therapy currently is not reimbursed routinely by the United Kingdom National Health Service for treating central serous chorioretinopathy. Novartis Pharma B.V. had no role in funding, designing, conducting, or evaluating the study, nor in the writing of this manuscript.

HUMAN SUBJECTS: This study included human subjects or tissues. Study protocol was approved by the respective institutional review board and ethics committee (NCT01797861) of the participating centers. Informed consent was obtained from all human subjects. This research adhered to the tenets of the Declaration of Helsinki.

No animal subjects were used in this study.

Author Contributions:

Conception and design: van Dijk, Fauser, Breukink, Groenewoud, Keunen, Querques, Downes, Hoyng, Boon

Analysis and interpretation: van Dijk, Fauser, Groenewoud, Boon

Data collection: van Dijk, Fauser, Breukink, Blanco-Garavito, Groenewoud, Keunen, Peters, Dijkman, Souied, MacLaren, Querques, Downes, Hoyng, Boon

Obtained funding: None

Overall responsibility: van Dijk, Fauser, Breukink, Blanco-Garavito, Groenewoud, Keunen, Peters, Dijkman, Souied, MacLaren, Querques, Downes, Hoyng, Boon

Abbreviations and Acronyms:

AE = adverse event; **BCVA** = best-corrected visual acuity; **cCSC** = chronic central serous chorioretinopathy; **CSC** = central serous chorioretinopathy; **ETDRS** = Early Treatment Diabetic Retinopathy Study; **FA** = fluorescein angiography; **HSML** = high-density subthreshold micropulse laser; **ICGA** = indocyanine green angiography; **NEI-VFQ25** = 25-item National Eye Institute Visual Function Questionnaire; **OCT** = optical coherence tomography; **PDT** = photodynamic therapy; **PLACE** = Half-Dose Photodynamic Therapy versus High-Density Subthreshold Micropulse Laser Treatment in Patients with Chronic Central Serous Chorioretinopathy; **RPE** = retinal pigment epithelium; **SRF** = subretinal fluid.

Correspondence:

Camiel J. F. Boon, MD, PhD, Department of Ophthalmology, Leiden University Medical Center, P. O. Box 9600, 2300 RC Leiden, the Netherlands. E-mail: c.j.f.boon@lumc.nl.