



Long-Term Outcome of Direct Relief of Subaortic Stenosis in Single Ventricle Patients

World Journal for Pediatric and
Congenital Heart Surgery
2018, Vol. 9(6) 638-644
© The Author(s) 2018



Article reuse guidelines:
sagepub.com/journals-permissions
DOI: 10.1177/2150135118793087
journals.sagepub.com/home/pch



Friso M. Rijnberg, MD¹, Vladimir Sojak, MD, PhD¹,
Nico A. Blom, MD, PhD², and Mark G. Hazekamp, MD, PhD¹

Abstract

Background: Single ventricle patients with unrestrictive pulmonary blood flow and (potential) subaortic stenosis are challenging to manage and optimal surgical strategy is unknown. Direct relief of subaortic stenosis by enlargement of the ventricular septal defect and/or subaortic chamber has generally been replaced by a Damus-Kaye-Stansel or Norwood procedure due to concerns of iatrogenic heart block, reobstruction, or ventricular dysfunction. Studies reporting long-term outcome after the direct approach are limited. The aim of our study was to describe and analyze our experience with direct relief of subaortic stenosis in single ventricle patients. **Methods:** Demographic data, characteristics, and pre-operative, operative and outcome details were collected for children undergoing direct relief of subaortic stenosis between 1989 and 2016. **Results:** Twenty-three patients (median age: 7.4 months, range: 10 days to 5.5 years) underwent direct relief of subaortic stenosis. Complete follow-up was available for all patients (median: 15.6 years, range: 34 days to 26.3 years). Seven (30%) patients had recurrence of subaortic stenosis. One (4%) patient developed complete heart block and one patient developed moderate ventricular dysfunction. Five (50%) patients developed a (pseudo)aneurysm at site of the patch and ventriculotomy. There were two perioperative deaths. Eighty-six percent of patients underwent a successful Fontan procedure. **Conclusions:** Direct relief of subaortic stenosis is associated with a substantial risk of reobstruction and patch (pseudo)aneurysm formation. However, risk of heart block is low and long-term outcome is good with the majority of patients reaching Fontan completion. In our opinion, the direct approach appears to be a good and relatively simple procedure in selected cases for the treatment of subaortic stenosis.

Keywords

single ventricle, unrestricted pulmonary blood flow, ventricular septal defect, subaortic stenosis, univentricular, relief, patch enlargement, bulboventricular foramen

Submitted May 10, 2018; Accepted July 8, 2018.

Introduction

Single ventricle (SV) with unrestrictive pulmonary blood flow and (potential) systemic ventricular outflow tract obstruction remains a rare and challenging anomaly with heterogeneous underlying anatomy.¹ Classical examples are double inlet left ventricle (DILV) or tricuspid atresia (TA) with associated transposition of the great arteries (TGA). In these patients, systemic blood flow needs to pass through a ventricular septal defect (VSD), sometimes called bulboventricular foramen, to a rudimentary subaortic outlet chamber. Such a VSD tends to become restrictive and has been linked to initial pulmonary artery banding (PAB) due to ventricular hypertrophy²⁻⁵ or after volume unloading surgery (Glenn or Fontan) due to altered ventricular geometry,⁶ particularly when associated with aortic arch (AA) obstruction.^{7,8} Subaortic or AA obstruction has been widely recognized as a risk factor for a good Fontan outcome.

Therefore, early relief of such obstruction is mandatory. However, initial neonatal management in this patient group is not uniform, varying from an aggressive neonatal Norwood (NW) or Damus-Kaye-Stansel (DKS) approach to a more conservative initial PAB ± AA plasty with potential later relief of developed subaortic stenosis (SAS) concomitant with the Glenn or Fontan procedure. Subaortic stenosis can occur

¹ Department of Cardiothoracic Surgery, Leiden University Medical Center, Leiden, the Netherlands

² Department of Pediatric Cardiology, Leiden University Medical Center, Leiden and Academic Medical Center, Amsterdam, the Netherlands

Corresponding Author:

Friso M. Rijnberg, Department of Cardiothoracic Surgery, Leiden University Medical Center, Albinusdreef 2, Leiden 2333ZA, the Netherlands.
Email: f.m.rijnberg@lumc.nl

Abbreviations and Acronyms

AA	aortic arch
DILV	double inlet left ventricle
DKS	Damus-Kaye-Stansel
DORV	double outlet right ventricle
NW	Norwood
PAB	pulmonary artery banding
RV	right ventricle
SAS	subaortic stenosis
SV	single ventricle
TA	tricuspid atresia
TGA	transposition of the great arteries
VSD	ventricular septal defect

because of (1) a restrictive subaortic chamber, (2) a restrictive VSD, (3) subaortic fibrous tissue/membrane, or (4) a combination of these causes. Subaortic stenosis can be relieved directly by means of VSD and/or subaortic chamber enlargement or indirectly by means of a NW or DKS procedure, in which the actual subaortic obstruction is bypassed by connecting the pulmonary trunk with the aorta. In addition, some centers have used a palliative arterial switch procedure for this purpose.⁹ The direct approach has been mostly replaced by the DKS/NW procedure because of the risk of heart block, development of recurrent SAS, and ventricular dysfunction due to a ventriculotomy, thus making these patients potentially less suitable for a Fontan pathway. However, the DKS/NW procedure can result in left pulmonary artery compression by the neo-aortic root or in semilunar valve insufficiency due to altered root geometry. Moreover, these operations carry higher mortality and morbidity when performed in a neonatal period.^{1,10,11}

There are only few reports on long-term outcomes in SV patients who underwent direct relief of SAS by enlargement of VSD and/or subaortic outflow chamber.¹² In this study, we aim to revisit this partially abandoned concept by describing and analyzing our experience with the direct approach for relief of SAS in SV patients.

Patients and Methods

We conducted a retrospective study in children with SV and unobstructed pulmonary blood flow, in whom initial or later SAS had been relieved directly via VSD and/or subaortic chamber enlargement. The study was approved by the ethics committee, and individual consent for the study was waived due to its retrospective study design. At our institution, this is the preferred approach in children who do not strictly need a NW or DKS procedure. In patients with a small aortic valve, ascending aorta, or otherwise unsuitable anatomy (eg, unbalanced atrioventricular septal defect (AVSD)), an initial DKS/NW procedure was considered the only available option. Data from medical records were analyzed for demographic, pre-, peri-, and post-operative characteristics (Table 1). Primary end points included mortality, achievement of Fontan circulation, and adequacy of SAS relief. Secondary end points were the incidence of recurrent SAS, heart

Table 1. General Characteristics and Demographic Data.^a

Characteristic	Results
Age relief SAS	7.2 months (10 days to 4.7 years)
Age at first operation	34 days (0 days to 11.2 months)
Sex (M/F)	(12/11)
Weight (kg)	3.3 (2.2-4.3)
Left SV morphology	20 (91)
Aortic arch obstruction	12 (55)
Pulmonary artery banding	23 (100)
Glenn	20 (91)
Age Glenn	8.3 months (3.1 months to 3.7 years)
Fontan	19 (83)
Age Fontan (years)	3.1 (1.4-5.3)
Mortality	4 (17)
Follow-up	15.6 years (34 days to 26.3 years)

Abbreviations: SAS, subaortic stenosis; SV, single ventricle

^aValues are reported as median (range) or as percentage.

block, subaortic chamber aneurysm, ventricular function, and semilunar valve function.

Data are presented as medians with ranges where appropriate. The presence of SAS was established by means of preoperative echocardiography or catheterization and/or perioperative evaluation of subaortic outflow tract by the surgeon. Any measurable gradient, VSD/aortic valve ratio <1.0, or restriction at level of the subaortic chamber was considered relevant and formed an indication for relief using VSD and/or subaortic chamber enlargement.

Surgical Technique

All operations were performed via median sternotomy using cardiopulmonary bypass and cold antegrade cardioplegia. The approach of VSD enlargement could be via a right ventricle (RV) ventriculotomy, right atrium, pulmonary valve, or aorta and was based on surgeon preference. Ventricular septal defect and/or subaortic chamber enlargement was performed according to the technique firstly described by Cheung et al.¹³ The VSD was enlarged superiorly or apically toward the obtuse margin of the heart (Figure 1A, dashed line). When a ventricular approach was used, the vertical incision was closed with a patch (Figure 1B). A RV ventriculotomy was the preferred approach in cases in which preoperative echocardiography showed a small subaortic chamber, thereby allowing thorough inspection and muscle resection in this area.

Results

In the period 1989 to 2016, 23 children (median age: 7.4 months, range: 10 days to 5.5 years) received direct relief of SAS at our institution. Patient demographics and general characteristics are shown in Table 1. Primary diagnoses are listed in Table 2. All patients underwent staged approach SV palliation with initial PAB ± AA repair (n = 11, 48%) and required primary relief of SAS at presentation or somewhere down the pathway (Figure 2, Table 3). Nine (39%) patients underwent direct relief of SAS

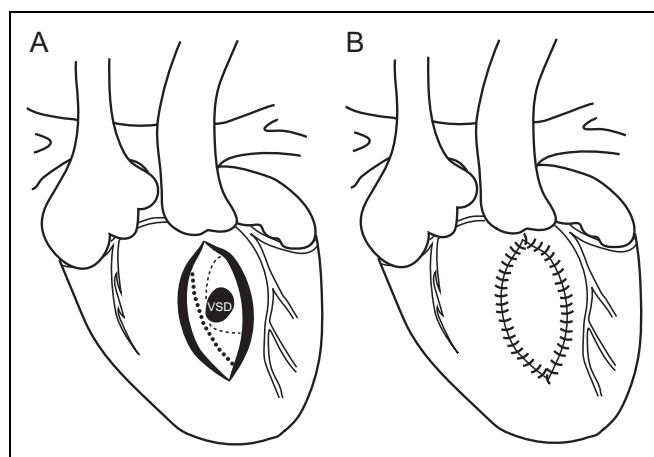


Figure 1. A, View of a patient with double inlet left ventricle (DILV) + transposition of great arteries (TGA), where systemic blood flow needs to pass through the VSD into a rudimentary right ventricle (RV) toward the aorta. After a ventriculotomy, the ventricular septal defect (VSD) can be enlarged safely in the superior and apical directions toward the obtuse margin. The safe margin (dashed line) and suspected course of the conduction system (circles) are indicated. B, After enlarging the VSD, the subaortic chamber is enlarged with a patch.

Table 2. Primary Diagnosis.^a

Diagnosis	Number
DILV + TGA	17 (9)
TA + TGA	2 (1)
ccTGA ± TA	3 (1)
DORV	1 (1)

Abbreviations: ccTGA, congenital corrected transposition of great arteries; DORV, double outlet right ventricle; DILV, double inlet left ventricle; TA, tricuspid atresia; TGA, transposition of great arteries

^aNumber of patients with aortic arch obstruction are shown in parenthesis.

as part of the first operation (median age: 29 days, range: 7 days to 9.5 months), nine (39%) patients at the time of Glenn procedure (median age: 7.4 months, range: 4.4 months to 3.4 years), one between Glenn and Fontan procedures (age: 3.2 years), four (17%) concomitant with Fontan procedure (median age: 3.6 years, range: 1.4-4.8 years), and in one patient 3.5 years after Fontan completion. Concomitant surgery at the time of first stage palliation was atrioventricular valve (AVV) repair in one. Surgical procedures concomitant with the Glenn procedure were Blalock-Taussig shunt (n = 4), PAB (n = 2), AVV repair (n = 2), AVV closure (n = 1), and a NW procedure (n = 1). Management of the pulmonary valve at the time of the Glenn procedure was variable and based on surgeon preference. Concomitant surgery at the time of Fontan was AVV repair (n = 3), AVV closure (n = 3), DKS (n = 1), and pulmonary artery augmentation (n = 1).

Approach of VSD enlargement was via a RV ventriculotomy in 11 (42%) procedures, right atrium in 4 (15%), pulmonary artery in 1 (4%), and aorta in (38%) 10 procedures. In ten patients, a patch was used to enlarge the subaortic (RV) outlet

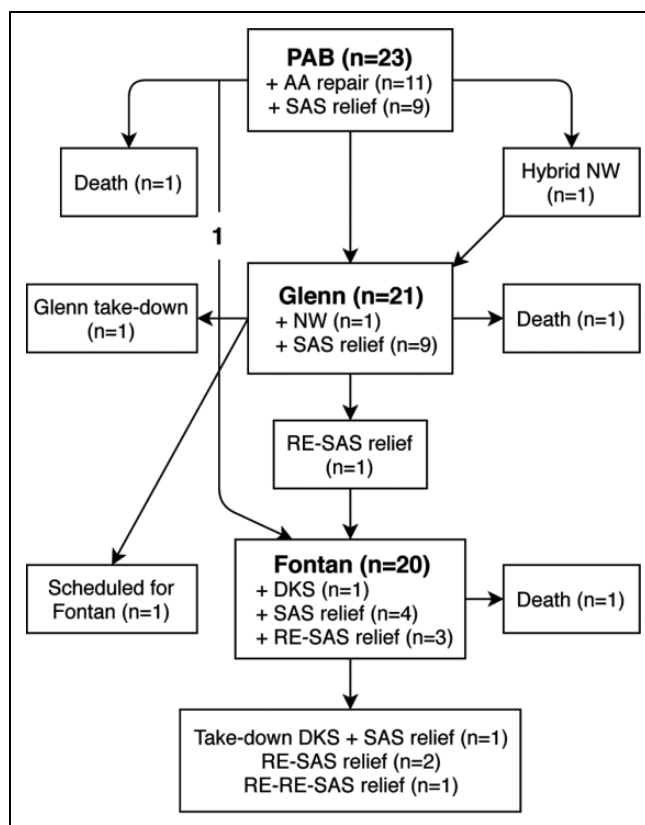


Figure 2. Clinical pathway of single ventricle (SV) patients.

chamber (six xenopericard, one Gore-Tex, two pulmonic homograft, and in one unknown).

Two patients underwent both the direct and indirect approaches and were excluded from primary end point analysis as long-term outcome in these patients was not considered to reflect one particular approach. One patient had DILV + TGA, a severely hypoplastic AA and SAS, and underwent primary palliation with a hybrid NW procedure + VSD and subaortic chamber enlargement, thereby successfully deferring the NW procedure to stage II. The other patient received a DKS procedure concomitant with Fontan completion for relief of SAS. After 1.9 years, the DKS was closed and the VSD enlarged due to severe pulmonary regurgitation.

Primary Outcome

Complete follow-up was available for all patients for a median period of 15.6 years (range: 34 days to 26.3 years). Overall mortality was 17% (4/23), of which two were perioperative deaths. One patient died two days after initial PAB + AA repair + subaortic chamber enlargement due to unexpected cardiac arrest without known cause. One patient died one day after Fontan completion + VSD enlargement. This patient was reoperated for fenestration creation because of low cardiac output, which was complicated by cardiac arrest with severe neurological damage. One child with DILV + TGA, mitral atresia, and dysplastic tricuspid valve underwent two tricuspid valve

Table 3. Clinical Pathway.^a

No.	Diagnosis	First Procedure	Timing of SAS Relief				SAS Mechanism/ Gradient	RE-SAS Mechanism/ Gradient
			SAS Relief Glenn	Interstage II-III SAS Relief	SAS Relief Fontan	Post-Fontan SAS Relief		
1	DILV + TGA	PAB	VSD↑ + SAC↑	-	-	-	VSD ratio <1.0	-
2	DILV + TGA	PAB + VSD↑ + SAC↑	-	RE-VSD↑	-	-	12 mm Hg	36 mm Hg
3	TA + TGA	PAB + AAR + SAC↑	-	-	VSD↑	-	23 mm Hg	-
4	ccTGA + TA	PAB	VSD↑	-	-	-	VSD ratio 0.7	-
5	DILV + TGA	PAB + MVP + AAR + VSD↑ + SAC↑	-	-	RE-VSD↑	-	VSD ratio <1.0, 3 mm	8 mm Hg
6	DILV + TGA	PAB + AAR + SAC↑	-	-	No Fontan	-	Restrictive SAC	-
7	DILV + TGA	PAB	-	-	VSD↑	RE-VSD↑	20 mm Hg	40 mm Hg
8	DILV + TGA	PAB + AAR + VSD↑	-	-	-	-	VSD ratio <1.0, 3 mm	-
9	DILV + TGA	PAB	VSD↑	-	RE-VSD↑	RE-RE-VSD↑	VSD ratio <1.0	35 mm Hg, RE-RE 46 mm Hg
10	TA + TGA	PAB	VSD↑	-	-	-	30 mm Hg	-
11	DILV + TGA + TA	PAB	No Glenn	-	VSD↑	-	10 mm Hg, 9 mm	-
12	DILV + TGA	PAB + VSD↑ + SAC↑	NW	-	-	-	VSD ratio <1.0	-
13	DILV + TGA	PAB	VSD↑	-	-	-	5 mm Hg	-
14	DILV + TGA	PAB + AAR + VSD↑	-	-	-	-	VSD ratio 0.7	-
15	DILV + TGA	PAB + AAR + VSD↑ + SAC↑	-	-	-	RE-VSD↑	VSD ratio 0.6	70 mm Hg
16	ccTGA + TA	PAB	VSD↑	-	-	-	VSD ratio <1.0, 6 mm	-
17	DILV + TGA	PAB	SAC↑	-	-	-	Restrictive SAC	-
18	DILV + TGA + MA	PAB + AAR	-	VSD↑	No Fontan	-	21 mm Hg	-
19	DILV + TGA	PAB + AAR	VSD↑ + SAC↑	-	Scheduled	-	25 mm Hg	-
20	DILV + TGA	PAB + AAR + SAC↑	No Glenn	-	No Fontan	-	Restrictive SAC	-
21	ccTGA	PAB + AAR	-	-	VSD↑	Fibrous tunnel	VSD ratio <1.0	49 mm Hg
22	DORV	PAB + AAR	VSD↑	-	-	-	20 mm Hg	-
23	DILV + TGA	PAB	-	-	DKS	VSD↑	VSD ratio <1.0	-

Abbreviations: AAR, aortic arch repair; ccTGA, congenital corrected transposition of the great arteries; DILV, double inlet left ventricle; DKS, Damus-Kaye-Stansel; DORV, double outlet right ventricle; MA, mitral atresia; MVP, mitral valve plasty; NW, Norwood; PAB, pulmonary artery banding; SAC↑, subaortic chamber enlargement; SAS, subaortic stenosis; TA, tricuspid atresia; TGA, transposition of the great arteries; VSD↑, ventricular septal defect enlargement; RE-VSD, redo VSD enlargement.

^aVSD ratio = VSD/aortic valve diameter ratio.

repairs and eventually tricuspid valve replacement with post-operative poor ventricular function. This child died of end-stage heart failure at an age of 4.3 years. One late death occurred 16.5 years after Fontan completion after a large cerebral vascular accident. Eighteen out of 21 (excluding the two patients with both direct and indirect approaches) patients underwent Fontan completion and one (86%) patient is scheduled for completion.

At latest follow-up, there was complete relief of SAS in 17 of 18 patients. In one patient, there was a stable laminar flow with a velocity of 3.0 m/s over the VSD and is monitored frequently with echocardiography.

Secondary Outcome

Twenty out of 23 patients received a total of 26 VSD enlargement procedures (including reobstructions), of which 3 were in the neonatal period. Two patients underwent neonatal subaortic chamber enlargement only because of adequately sized VSD.

These five neonatal patients presented with adequately sized aortic valve and ascending aorta with restriction at the level of the VSD (n = 3) and/or subaortic chamber (n = 4). One (4%) patient developed iatrogenic complete heart block for which a pacemaker was implanted. Five (50%) patients developed an aneurysm at site of the ventriculotomy, which was a true aneurysm in one and false in four and was repaired concomitantly during Fontan procedure in two and in a separate operation in three patients. The patient with a true aneurysm had an aneurysm of the entire subaortic ventricle, not only of the xenopericard patch, and required plication of the subaortic RV at the time of Fontan.

At latest follow-up, no patients had more than trivial aortic regurgitation. Ventricular function was good in 17, mildly impaired in 1, and moderately impaired in 1 patient (NT-proBNP median: 151, range: 50-591 ng/L [n = 12], ASAT 28, range: 17-62 U/L, ALAT 27, range: 14-46 U/L [n = 15]). All surviving patients are in New York Heart Association class 1-2.

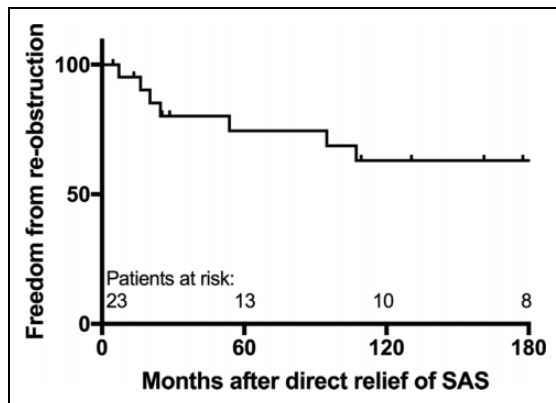


Figure 3. Freedom from recurrent subaortic stenosis (SAS) after first relief of SAS via the direct approach. The hazard of recurrent SAS is highest in the first few years, but can occur up till ten years after first relief of SAS.

In total, seven (30%) patients developed reobstruction after direct SAS relief. Six reobstructions occurred at VSD level and reobstruction was caused by a fibrous subaortic tunnel in one patient. One patient developed a second reobstruction. These reobstructions were addressed in one patient 19 days after Glenn, in three patients during Fontan procedure, and in three patients 8.9, 4.5, and 5.7 years after the Fontan procedure. The patient with a second reobstruction underwent VSD enlargement 11.0 years after Fontan completion. The risk of reobstruction was evident up until 10 years after first direct relief of SAS (Figure 3). We could not identify any risk factors for reobstruction. There was no association between age at first relief of SAS or presence of AA hypoplasia/coarctation with risk of reobstruction.

Comment

The management of SV patients with (potential) SAS is subjected to different possible strategies. The conservative option is an initial PAB ± AA repair. Early and interim results were, however, not optimal with poor candidacy for Fontan palliation.^{14,15} Therefore, others use a more aggressive neonatal modified NW/DKS procedure, thereby relieving any (potential) SAS at the first operation. However, this approach is associated with substantial perioperative mortality, reaching up to 27%.¹⁵ Contemporary results of the NW procedure for non-hypoplastic left heart syndrome report considerable early mortality, with 15.4% in-hospital mortality and 14.5% interstage mortality. Although left dominant morphologies (such as DILV + TGA and TA + TGA) have superior results compared with right dominant morphologies, early mortality still approaches 13% to 20% and can be higher in low-volume centers.^{10,11,16}

When SAS occurs early, most surgeons will perform a DKS or NW procedure. Another possible option is direct relief of SAS by enlarging the VSD and/or subaortic outflow chamber, but this method has mainly been reserved for patients with pulmonary regurgitation, pulmonary stenosis, or for patients who present late after Fontan palliation in which pulmonary

valves are closed and therefore are unsuitable for DKS repair.¹ This is based on relative good experiences with the DKS procedure and the possible disadvantages associated with the direct approach. Because most centers abandoned this technique, there is no study describing the long-term outcome of the direct approach in a relatively contemporary patient cohort.

In a large single-center series, Lan et al described the outcome in 140 patients with DILV/TA + TGA (median follow-up: 7.7 years). Overall survival was 71%, with 24% mortality in patients without relief of SAS and 32% in patients with relief of SAS (n = 95). Fifty-one patients received DKS and 44 patients underwent VSD enlargement with a similar cumulative mortality percentage of 33% versus 32%. Overall Fontan completion/suitability was 76%.¹²

Recently, long-term results (median: 17 years) of a large cohort of 152 DILV + TGA and 59 TA + TGA patients from the Australia and New Zealand Fontan registry have been reported. In their experience, 5% of DILV patients had SAS at presentation and 44% developed SAS over time. Overall, 91% of DILV patients and 60% of TA patients proceeded to Fontan completion.¹⁷

In our selected cohort of mainly DILV + TGA patients with (developed) SAS, survival was 83% and the Fontan procedure was achieved or scheduled in 86% of patients. Differences with Lan et al can be explained by an earlier era of that report and the inclusion of a higher amount of TA + TGA patients, which have significantly higher mortality than DILV + TGA patients.^{12,17} Our results are however comparable to the results of Franken et al, where overall (with and without development of SAS) 91% of DILV + TGA patients proceeded to Fontan completion.¹⁷

When SAS is present at birth, many centers adopt a strategy of a neonatal NW or DKS procedure to relieve SAS and to concomitantly address AA hypoplasia when present. Subaortic stenosis at birth was associated with increased risk of death in the report by Franken et al. Association with a particular neonatal surgical strategy for relief of SAS could however not be established. In our experience, we had five patients who underwent neonatal relief of SAS by VSD ± subaortic chamber enlargement (n = 3) or by subaortic chamber enlargement only (n = 2). One of these latter two patients suffered from cardiac arrest 3 days postoperatively without known cause. The other patient underwent VSD enlargement at the time of Fontan procedure due to recurrence of SAS at VSD level. The other three patients underwent an uncomplicated Fontan procedure and are doing well without reobstruction at an age of 10.9, 7.5, and 15.6 years.

In one patient with a severely hypoplastic AA and SAS, we used a hybrid NW + VSD enlargement to delay the NW procedure to the next stage with good result. In our opinion, neonatal VSD enlargement can be an acceptable option in selected patients and can thereby possibly delay DKS or NW surgery to a later stage when necessary with potential better outcome. Furthermore, we used the direct approach in one patient after DKS failure because of severe pulmonary regurgitation 1.9 years after Fontan with good outcome.

The risk of complete heart block has been reported to be between 0% and 34%.^{12,18–22} In our experience, one (4%) patient received a pacemaker because of complete heart block out of 26 performed VSD enlargement procedures. Ventricular function was well preserved in all but one of our patients and we did not encounter cases with new aortic valve insufficiency.

The rate of reobstruction reported in the literature varies between 11% and 44%.^{4,18,20,21,23} and can occur many years after Fontan completion.²⁴ This is in line with our experience, where 30% developed recurrent SAS, of which one patient had a second reobstruction. In four of these patients, reobstruction occurred 8.9, 5.7, 4.5, and 11 years after Fontan completion indicating the continuous hazard of reobstruction. Regular follow-up with echocardiography is therefore important for these patients even many years after Fontan repair.

In our experience, however, reoperation for reobstruction could be done without associated mortality. To address the high rate of reobstruction, one option would be to enlarge the VSD more aggressively, which in our opinion can be done without increased risk of heart block when strictly performed in the described direction.¹³ Another option would be to always do a DKS at the time of Glenn or Fontan procedure. As a large proportion of DILV + TGA patients develop SAS, which is reported to occur in up to 44% of patients over time,¹⁷ some centers have adopted a strategy where every patient receives a DKS procedure, independent of the occurrence of SAS, at stage II or during Fontan.^{17,25,26} However, although short- and mid-term outcome of the pulmonary valve (neoaortic) after DKS is good,^{25–27} the long-term 15- to 20-year outcome is mainly unknown.²⁸ Whether a universal DKS/NW, and therefore inherently an unnecessary DKS in some patients, is the best option for these patients is not known. To keep the option of future DKS open in these patients, we prefer to spare the pulmonary valve at the time of Glenn procedure, especially in patients with previous SAS.

In a study by Jahangiri et al, no formation of aneurysms was reported for a series of 23 patients undergoing VSD and subaortic outflow chamber enlargement.¹⁸ Karl et al reported the formation of an aneurysm in one out of two patients in which they enlarged the VSD via ventriculotomy.⁸ In our experience, five out of ten patients developed an aneurysm, of which four were false aneurysms and one was a true aneurysm. Two of these patients required a separate operation to address this. We speculate that the reason for these false aneurysms, besides technically, can be the cause of the abnormal blood flow inherent to this technique, where blood has to travel from the left ventricle through the VSD in an abnormal angle. Collision of this blood flow with the patch can be the cause of the increased risk of false aneurysms and is an area for future research with 4-D flow magnetic resonance imaging.

Indications for the Direct Approach

In our opinion, there are 3 groups of SV patients with (potential) SAS: (1) patients with small aortic valve and/or ascending aorta \pm SAS, for which a NW/DKS procedure is the only

available option, (2) patients with an adequately sized subaortic pathway, who undergo primary palliation with PAB \pm AA repair at our center, and (3) patients with adequately sized aortic valve and ascending aorta but with restriction at the level of the VSD or subaortic chamber. For these patients, we prefer to perform PAB \pm AA repair with direct relief of SAS when present or perform direct relief of SAS in a later stage when it develops.

Limitations and Strengths

This is a retrospective, single-center study which includes patients over a long time frame and is limited by its small sample size. Strength of this study is its relative contemporary cohort and long-term follow-up of SV patients who underwent direct relief of SAS.

Conclusion

In our experience, the relief of SAS via the direct approach appears to result in good long-term outcome in terms of survival and Fontan suitability. When enlarging the VSD strictly via the described approach, risk of complete heart block is low. The ventricular function remained well preserved and we did not encounter new aortic valve insufficiencies. However, risk of reobstruction is high and can occur many years after Fontan completion. Furthermore, we encountered a substantial risk of formation of an aneurysm at site of the patch and the ventriculotomy.

In conclusion, direct relief of SAS appears to offer a relatively simple solution for a select group of SV patients with SAS. Although this approach is associated with a substantial risk of patch aneurysms and reobstruction, this could be treated without associated mortality and long-term results appear to be good. Optimization of our current approach by more aggressive VSD enlargement or prophylactic DKS at the time of Glenn or Fontan may reduce the burden of these complications and is subject to future study.

The definitive role of VSD and/or subaortic chamber enlargement within the clinical pathway of SV patients with (potential) SAS is in our opinion therefore not limited to patients with pulmonary valve problems and can defer DKS/NW, if necessary, to an older age.

Authors' Note

The authors had full control of the design of the study, methods used, outcome parameters, analysis of data, and production of the written report.

Declaration of Conflicting Interests

The author(s) declared no potential conflicts of interest with respect to the research, authorship, and/or publication of this article.

Funding

The author(s) received no financial support for the research, authorship, and/or publication of this article.

References

1. Alsoufi B. Management of the single ventricle and potentially obstructive systemic ventricular outflow tract. *J Saudi Heart Assoc.* 2013;25(3): 191-202.
2. Miura T, Kishimoto H, Kawata H, Hata M, Hoashi T, Nakajima T. Management of univentricular heart with systemic ventricular outflow obstruction by pulmonary artery banding and Damus-Kaye-Stansel operation. *Ann Thorac Surg.* 2004;77(1): 23-28.
3. Odum JN, Laks H, Drinkwater DC Jr, et al. Staged surgical approach to neonates with aortic obstruction and single-ventricle physiology. *Ann Thorac Surg.* 1999;68(3): 962-967; discussion 968.
4. Jensen RA Jr, Williams RG, Laks H, Drinkwater D, Kaplan S. Usefulness of banding of the pulmonary trunk with single ventricle physiology at risk for subaortic obstruction. *Am J Cardiol.* 1996;77(12): 1089-1093.
5. Serraf A, Conte S, Lacour-Gayet F, et al. Systemic obstruction in univentricular hearts: surgical options for neonates. *Ann Thorac Surg.* 1995;60(4): 970-976; discussion 976-977.
6. Donofrio MT, Jacobs ML, Norwood WI, Rychik J. Early changes in ventricular septal defect size and ventricular geometry in the single left ventricle after volume-unloading surgery. *J Am Coll Cardiol.* 1995;26(4): 1008-1015.
7. Matitiau A, Geva T, Colan SD, et al. Bulboventricular foramen size in infants with double-inlet left ventricle or tricuspid atresia with transposed great arteries: influence on initial palliative operation and rate of growth. *J Am Coll Cardiol.* 1992;19(1): 142-148.
8. Karl TR, Watterson KG, Sano S, Mee RB. Operations for subaortic stenosis in univentricular hearts. *Ann Thorac Surg.* 1991; 52(3): 420-427; discussion 427-428.
9. Lacour-Gayet F, Serraf A, Fermont L, et al. Early palliation of univentricular hearts with subaortic stenosis and ventriculoarterial discordance. The arterial switch option. *J Thorac Cardiovasc Surg.* 1992;104(5): 1238-1245.
10. Alsoufi B, McCracken C, Kanter K, Shashidharan S, Kogon B. Current results of single ventricle palliation of patients with double inlet left ventricle. *Ann Thorac Surg.* 2017;104(6): 2064-2071.
11. Alsoufi B, Slesnick T, McCracken C, et al. Current outcomes of the Norwood operation in patients with single-ventricle malformations other than hypoplastic left heart syndrome. *World J Pediatr Congenit Heart Surg.* 2015;6(1): 46-52.
12. Lan YT, Chang RK, Laks H. Outcome of patients with double-inlet left ventricle or tricuspid atresia with transposed great arteries. *J Am Coll Cardiol.* 2004;43(1): 113-119.
13. Cheung HC, Lincoln C, Anderson RH, et al. Options for surgical repair in hearts with univentricular atrioventricular connection and subaortic stenosis. *J Thorac Cardiovasc Surg.* 1990;100(5): 672-681.
14. Franklin RC, Sullivan ID, Anderson RH, Shinebourne EA, Deanfield JE. Is banding of the pulmonary trunk obsolete for infants with tricuspid atresia and double inlet ventricle with a discordant ventriculoarterial connection? Role of aortic arch obstruction and subaortic stenosis. *J Am Coll Cardiol.* 1990;16(6): 1455-1464.
15. Tchervenkov CI, Shum-Tim D, Beland MJ, Jutras L, Platt R. Single ventricle with systemic obstruction in early life: comparison of initial pulmonary artery banding versus the Norwood operation. *Eur J Cardiothorac Surg.* 2001;19(5): 671-677.
16. Hornik CP, He X, Jacobs JP, et al. Relative impact of surgeon and center volume on early mortality after the Norwood operation. *Ann Thorac Surg.* 2012;93(6): 1992-1997.
17. Franken LC, Admiraal M, Verrall CE, et al. Improved long-term outcomes in double-inlet left ventricle and tricuspid atresia with transposed great arteries: systemic outflow tract obstruction present at birth defines long-term outcome. *Eur J Cardiothorac Surg.* 2017;51(6): 1051-1057.
18. Jahangiri M, Shinebourne EA, Ross DB, Anderson RH, Lincoln C. Long-term results of relief of subaortic stenosis in univentricular atrioventricular connection with discordant ventriculoarterial connections. *Ann Thorac Surg.* 2001;71(3): 907-910.
19. Cerillo AG, Murzi B, Giusti S, Crucean A, Redaelli S, Vanini V. Pulmonary artery banding and ventricular septal defect enlargement in patients with univentricular atrioventricular connection and the aorta originating from an incomplete ventricle. *Eur J Cardiothorac Surg.* 2002;22(2): 192-199.
20. Hiramatsu T, Imai Y, Kurosawa H, et al. Midterm results of surgical treatment of systemic ventricular outflow obstruction in Fontan patients. *Ann Thorac Surg.* 2002;73(3): 855-860; discussion 860-851.
21. Clarke AJ, Kasahara S, Andrews DR, et al. Mid-term results for double inlet left ventricle and similar morphologies: timing of Damus-Kaye-Stansel. *Ann Thorac Surg.* 2004;78(2): 650-657; discussion 657.
22. Rodefeld MD, Ruzmetov M, Schamberger MS, Girod DA, Turentine MW, Brown JW. Staged surgical repair of functional single ventricle in infants with unobstructed pulmonary blood flow. *Eur J Cardiothorac Surg.* 2005;27(6): 949-955.
23. Pass RH, Solowiejczyk DE, Quaegebeur JM, et al. Bulboventricular foramen resection: hemodynamic and electrophysiologic results. *Ann Thorac Surg.* 2001;71(4): 1251-1254.
24. Finta KM, Beekman RH, Lupinetti FM, Bove EL. Systemic ventricular outflow obstruction progresses after the Fontan operation. *Ann Thorac Surg.* 1994;58(4): 1108-1112; discussion 1112-1103.
25. Shimada M, Hoashi T, Kagisaki K, Shiraishi I, Yagihara T, Ichikawa H. Clinical outcomes of prophylactic Damus-Kaye-Stansel anastomosis concomitant with bidirectional Glenn procedure. *J Thorac Cardiovasc Surg.* 2012;143(1): 137-143, 143 e131.
26. Alsoufi B, Al-Wadai A, Khan M, et al. Outcomes of Damus-Kaye-Stansel anastomosis at time of cavopulmonary connection in single ventricle patients at risk of developing systemic ventricular outflow tract obstruction. *Eur J Cardiothorac Surg.* 2014; 45(1): 77-82.
27. Fiore AC, Rodefeld M, Vijay P, et al. Subaortic obstruction in univentricular heart: results using the double barrel Damus-Kaye Stansel operation. *Eur J Cardiothorac Surg.* 2009;35(1): 141-146.
28. Yamauchi S, Kawata H, Iwai S, et al. Risk factors for semilunar valve insufficiency after the Damus-Kaye-Stansel procedure. *Ann Thorac Surg.* 2015;100(5): 1767-1772.