



Universiteit
Leiden
The Netherlands

Trials Testing the Value of Imaging Use in Valve Disease and in Transcatheter Valvular Interventions

Leipsic, J.; Bax, J.J.; Webb, J.G.; Martin, R.; Blanke, P.

Citation

Leipsic, J., Bax, J. J., Webb, J. G., Martin, R., & Blanke, P. (2017). Trials Testing the Value of Imaging Use in Valve Disease and in Transcatheter Valvular Interventions. *Jacc: Cardiovascular Imaging*, 10(3), 286-295. doi:10.1016/j.jcmg.2016.09.031

Version: Not Applicable (or Unknown)
License: [Leiden University Non-exclusive license](#)
Downloaded from: <https://hdl.handle.net/1887/95053>

Note: To cite this publication please use the final published version (if applicable).

Trials Testing the Value of Imaging Use in Valve Disease and in Transcatheter Valvular Interventions



Jonathon Leipsic, MD,^a Jeroen J. Bax, MD, PhD,^b John G. Webb, MD,^a Randolph Martin, MD,^c Philipp Blanke, MD^a

ABSTRACT

The role of imaging in the diagnosis of valvular heart disease is well established through years of investigation and validation. However, the role of imaging in guiding the treatment decision-making for valvular heart disease is less well established, and there is a striking paucity of randomized trial data to help inform these decisions. Given this relative absence of randomized trial data, the present article highlights some of the most important knowledge gaps and defines meaningful opportunities for the field to help advance the care of patients with valvular heart disease in a cost-effective fashion. (The PARTNER 3-Trial: The Safety and Effectiveness of the SAPIEN 3 Transcatheter Heart Valve in Low Risk Patients With Aortic Stenosis [P3]; [NCT02675114](#); Medtronic Transcatheter Aortic Valve Replacement in Low Risk Patients; [NCT02701283](#)) (J Am Coll Cardiol Img 2017;10:286-95) © 2017 by the American College of Cardiology Foundation.

Randomized controlled trials represent the highest quality data afforded to clinicians to help inform downstream decision-making. Recently, there has been an explosion of new prospective randomized trials that have been structured to define the role of anatomic and functional testing for the evaluation of coronary artery disease in patients with stable chest pain (1-4). However, in the arena of structural heart diseases such as valvular heart disease, the role of noninvasive imaging in downstream decision-making has largely been based on observational data; there are few randomized trial data available, despite the very well-established role for such data in the diagnosis of valvular pathologies validated over decades against invasive assessment (5,6). It is particularly noteworthy that although consensus exists that imaging helps support patient management, there are few comparative effectiveness studies randomizing subjects either to undergo

different imaging modalities or strategies versus no imaging guidance.

Although there may seem to be a deficit of data, the very supportive nature that noninvasive imaging plays in transcatheter valvular interventions does not lend itself to randomization. The focus is the optimization of procedural outcomes, and the imaging needed to facilitate this focus varies based on site expertise and the evolution of the technology. Despite the lack of randomized trials affirming the clinical utility of imaging in valvular heart disease, imaging is increasingly being used to assess pre-procedural risk, as well as for the assessment of procedural success as core laboratory-adjudicated endpoints in large interventional transcatheter valvular trials. The present study thus highlights the evolving role of noninvasive imaging for pre-procedural planning in transcatheter valvular interventions and also as an endpoint in clinical trials. In doing so, our aim was to

From the ^aDepartment of Radiology and Cardiology, Centre for Heart Valve Innovation, University of British Columbia, Vancouver, British Columbia, Canada; ^bLeiden University Medical Center, Leiden, the Netherlands; and the ^cPiedmont Medical Center, Atlanta, Georgia. Dr. Leipsic has served as a consultant for Edwards Lifesciences, Circle Cardiovascular Imaging, Valtech, and Valcare; has received institutional support for computed tomography core laboratory services from Edwards Lifesciences, Medtronic, Neovasc, Tendyne, and GDS; and holds stock options for HeartFlow and Circle Cardiovascular Imaging. Dr. Webb has served as a consultant for Edwards Lifesciences. Dr. Blanke has served as a consultant for Edwards Lifesciences, Tendyne, Neovasc, Circle Cardiovascular Imaging, and HeartFlow; and has received institutional support for computed tomography core laboratory services from Edwards Lifesciences, Medtronic, Neovasc, Tendyne, and GDS. All other authors have reported that they have no relationships relevant to the contents of this paper to disclose. Pamela Douglas, MD, served as the Guest Editor for this paper.

Manuscript received September 8, 2016; revised manuscript received September 19, 2016, accepted September 22, 2016.

emphasize the important supportive role imaging plays in transcatheter valvular interventions, as endpoints in valvular heart disease intervention trials, and finally the potential outstanding questions regarding imaging in valvular disease that may lend themselves to be answered through randomized clinical trials (**Central Illustration**).

IMAGING TO SUPPORT PRE-PROCEDURAL PLANNING FOR TRANSCATHETER VALVULAR INTERVENTIONS

With surgical valvular interventions, there is little need for additional imaging to aid in procedural planning in advance of the procedure. However, with the advent of transcatheter valvular interventions, the requirement to evaluate device landing zones and valvular structures became acutely apparent in a way previously not needed. Until then, the aortic annulus was a less well-defined anatomic entity, at least from an imaging perspective, because previously it was not relevant to guide any surgical device selection. As it became apparent that the sex of the patient was not enough to help inform device selection and sizing, the field changed its focus toward imaging to help inform the procedure and improve clinical outcomes.

With this increased focus came more thoughtful and thorough investigation, which quickly highlighted that even traditional 2-dimensional echocardiographic measurements were not sufficient to comprehensively assess the noncircular anatomy. Consistently, 3-dimensional multidetector computed tomography (MDCT) scanning and transesophageal echocardiography (TEE) have been shown to enhance annular assessment and enable more effective device selection that has facilitated an improvement in clinical outcomes (5-7). In particular, a steady reduction has occurred in the extent and frequency of paravalvular regurgitation (PAR), as well as annular injury and coronary occlusion, mainly due to a better understanding of anatomic risk, ultimately allowing for more informed and individualized procedural planning.

Through imaging, many of the historical myths regarding cardiac anatomy have been dispelled. It was assumed, until recently, that the aortic annulus was round. In 2008, the elliptical geometric nature of the aortic annulus was discovered by using MDCT studies, with significant differences between the short- and long-axis annular dimensions (8), which makes granular device sizing on the basis of 2-dimensional imaging more or less impossible. The rates of moderate or greater paravalvular aortic regurgitation (PAR) in the early trial experiences were 12.2% and 10% in the



PARTNER (Placement of Aortic Transcatheter Valves) IA and US CoreValve Pivotal Study transcatheter aortic valve replacement (TAVR) cohorts, respectively (9,10). Given that PAR has been shown to be associated with increased mortality in multiple randomized trial subanalyses (11-13), procedural modifications to prevent PAR have become a more prominent focus. With the use of MDCT scanning and 3-dimensional TEE, as well as further iterations of the transcatheter heart valves (THVs), there has been a steadily decline in the burden of significant PAR through more appropriate and granular device sizing (**Figure 1**). The recently reported PARTNER SAPIEN 3 intermediate-risk data showed a very low 30-day rate of moderate or severe PAR (3.4%), which was at least in part believed to be attributable to the systematic use of 3-dimensional imaging for more specific THV sizing (12-14). In addition, the low 30-day mortality rate reflects a reduction in major vascular complications, life-threatening bleeding, and other acute procedural complications such as coronary occlusion and annular rupture. Both of these factors contributed to early mortality in previous TAVR studies and are likely associated with the reduced mortality seen in this trial. The investigators surmised that in addition to increasing operator experience, the systematic utilization of MDCT scanning for vascular access and annular sizing allowed these meaningful improvements in clinical outcomes.

Building on the positive impact with TAVR, the early experiences with transcatheter mitral valve replacement have been enriched by the use of advanced imaging. The segmentation of the non-planar saddle-shaped mitral annulus has become routine in the advanced imaging laboratories that are supporting early feasibility trials in the transcatheter mitral valve replacement space (**Figure 2**). In addition, advanced imaging has already shed substantial light on various potential mechanisms for left ventricular outflow tract (LVOT) obstruction and the patterns of ventricular remodeling unique to the different mechanisms of mitral regurgitation (MR) (15-18). There are a number of predisposing factors for LVOT obstruction that relate to anatomic and device-related issues. Importantly, significant LVOT anatomy variation exists owing to configuration of the interventricular septum, left ventricular size, and aorto-mitral angulation (19). In particular, a hypertrophied, bulging septum reduces the LVOT and neo-LVOT cross-sectional areas.

ABBREVIATIONS AND ACRONYMS

- CMR** = cardiac magnetic resonance
- CT** = computed tomography
- CTA** = computed tomography angiography
- ICA** = invasive coronary angiography
- LVOT** = left ventricular outflow tract
- MDCT** = multidetector computed tomography
- MR** = mitral regurgitation
- MRI** = magnetic resonance imaging
- PAR** = paravalvular regurgitation
- TAVR** = transcatheter aortic valve replacement
- TEE** = transesophageal echocardiography
- THV** = transcatheter heart valve

CENTRAL ILLUSTRATION Imaging for Valvular Heart Disease

Clinical Trials Evaluating the Role of Imaging in Transcatheter Procedures	Supportive of Procedural Intervention	Imaging as an Endpoint	Trials Needed-Gaps in Knowledge
 Aortic  Mitral	<ul style="list-style-type: none"> • TAVR- Annular sizing, Transcatheter Heart Valve Selection, Identification of adverse aortic root features, • Annular sizing with 3D Echocardiography and CT; Discrimination of Risk of LVOT Obstruction; CT to assess the landing zone for Transcatheter Devices 	<ul style="list-style-type: none"> • CT post-implant for the assessment of deployment depth in the setting of conduction disturbances and the presence of leaflet thickening in symptomatic patients with increasing gradient and asymptomatic subjects for surveillance • MRI and Echocardiographic assessment of post treatment remodeling of the left ventricle; Post-Implant CT imaging to evaluate device positioning and expansion and Echocardiographic assessment of hemodynamics 	<ul style="list-style-type: none"> • Randomization of CT vs CT and Echocardiography prior to TAVR; • CT guided Invasive Coronary Angiography vs Mandatory Coronary Angiography Prior to TAVR • MRI vs Echocardiographic guided surgical intervention for Mitral Regurgitation

Leipsic, J. et al. *J Am Coll Cardiol Img.* 2017;10(3):286-95.

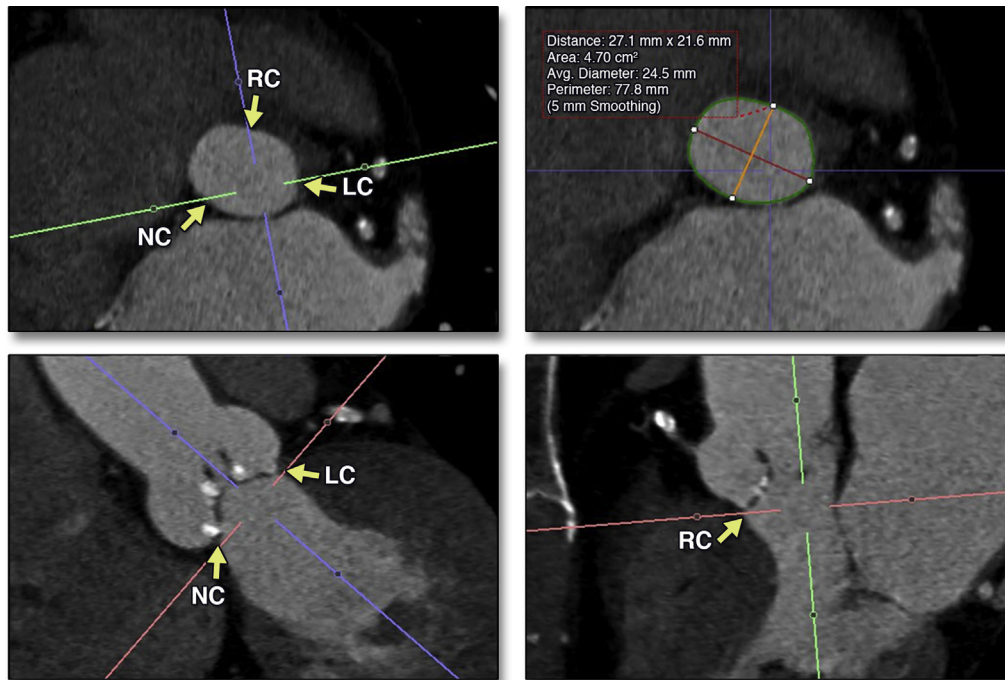
Current understanding, gaps in knowledge and future opportunities.

Given these varied mechanisms but the consistent relationship between device size and the extent of ventricular protrusion and the risk of LVOT obstruction, T models of risk integrating the concept of the neo-LVOT have become essential for patient screening in a more granular fashion than would be possible with planar imaging. Computed tomography (CT) transcatheter mitral valve replacement simulation can predict neo-LVOT geometry by embedding either a cylindrical or cone-shaped contour, or even a device-specific stereolithographic contour, into the CT dataset; this action is then followed by segmentation and planimetric assessment of the neo-LVOT cross-sectional area. Unfortunately, this virtual assessment is somewhat limited, however, because there are no well-defined threshold values for the neo-LVOT area yet available; this limitation currently forces the field to default to experiences from patients with hypertrophic obstructive cardiomyopathy, in whom the risk of developing an LVOT gradient >50 mm Hg has been shown to

correspond with LVOT area cutoffs ranging from 0.85 to 2.0 cm² (20-23). In the early feasibility trials, it seems reasonable to perform both MDCT scanning and TEE. However, as the procedure evolves, there is an opportunity to assess the true incremental value of MDCT scanning beyond TEE, which is needed for MR quantification, by randomizing patients to undergo transcatheter mitral valve replacement with MDCT and without MDCT guidance.

While the field develops an understanding on how to use imaging to screen, select, and guide transcatheter mitral valve implantation, the knowledge supporting transcatheter mitral valve repair is much more mature. The MitraClip system (Abbott Vascular, Minneapolis, Minnesota) has been the most studied device used for the treatment of mitral insufficiency. The EVEREST II (Endovascular Valve Edge-to-Edge Repair Study) 5-year data confirmed that the MitraClip device reduces the severity of MR and its symptoms while promoting favorable reverse remodeling of the left ventricle at 5 years'

FIGURE 1 Planimetric Assessment of Systolic Annular Dimensions



Representative computed tomography (CT) image analysis performed for assessment pre-transcatheter aortic valve replacement (TAVR). Multiplanar oblique imaging is used to create an image reconstruction of the annular plane. This approach enables the image reviewer to measure the annular (area 4.70 cm²) and perimeter (77.8 mm). LC = left cusp; NC = noncoronary cusp; RC = right cusp.

post-procedure (24). Patient selection relies heavily on high-quality echocardiographic guidance with the key inclusion criterion being the presence of a regurgitant jet between A2 and P2 and not between the commissures. There are specific echocardiographic measurements for functional MR (e.g., the coaptation length must be at least 2 mm and the coaptation depth <11 mm). For patients with a flail leaflet, the flail gap needs to be <10 mm with a flail width <15 mm (25). Before the discrimination of these findings, the main and irreplaceable role of echocardiography is determination of the mechanism of MR and its severity.

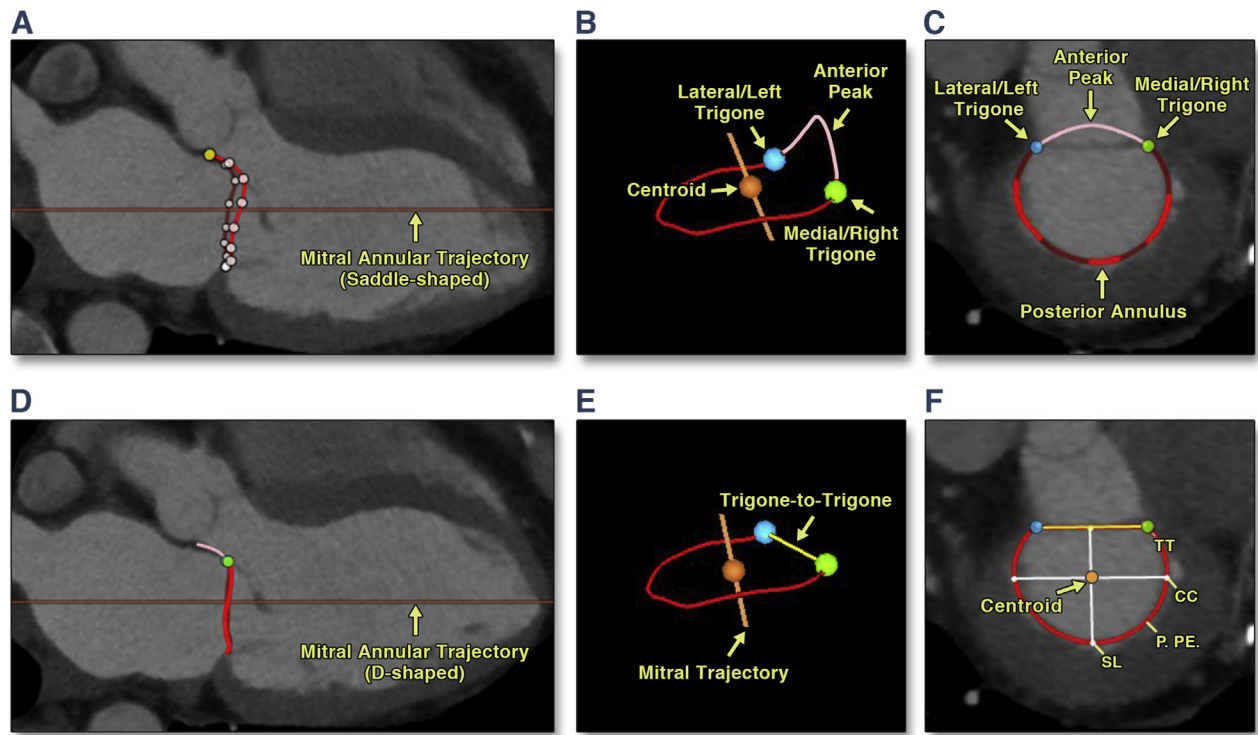
IMAGING AS AN ENDPOINT OF A CLINICAL TRIAL

POST-PROCEDURAL THV ASSESSMENT. Echocardiographic assessment both intraprocedurally and post-procedurally is essential for the evaluation of THV function (26). Intraprocedurally, with the advent of recapturable devices, findings of increased THV gradients on TEE can allow the proceduralist to reposition the valve to allow for more optimal deployment

and hemodynamics. Standardization of reporting and grading of THV dysfunction has been a focus of the Valve Academic Research Consortium update (27) (Table 1). Importantly, however, the definitions and criteria will almost certainly continue to be refined as reports of normative values from various transcatheter devices become available from ongoing registries and trials.

Paravalvular regurgitation post-TAVR. With the improvement in clinical outcomes after structural heart disease interventions, investigators have pursued endpoints beyond mortality, myocardial infarction, and stroke. In the TAVR space, the standardization and reproducibility of paravalvular leakage quantification with echocardiography has been essential for the adjudication of procedural outcomes. Invasive measures of PAR have proven to be only modestly reliable and to correlate weakly with downstream clinical outcomes (10,11). Echocardiographic adjudication of PAR has evolved since its introduction into clinical practice. Several parameters and criteria have been proposed in the recent American Society of Echocardiography/European Association of Cardiovascular Imaging and Valve Academic Research

FIGURE 2 3D Mitral Annular Segmentation on CT Scanning



(A) Saddle-shaped mitral annular segmentation as a cubic spline interpolation. (B) Pink line = anterior peak; red line = posterior peak (posterior mitral leaflet insertion); green and blue dots = fibrous trigones. Importantly, the anterior peak projects into the left ventricular outflow tract (short-axis view [C] and long-axis view [D]). The more planar D-shaped annular contour is created by truncating the saddle-shaped contour at the trigone-to-trigone distance (yellow lines [E and F]). Important measurements are the projected area septal-to-lateral (SL) and commissure to commissure (CC) distances; the latter is oriented perpendicularly to SL while transecting through the centroid (F). Reprinted with permission from Blanke et al. (20). CT = computed tomography; P. PE. = posterior perimeter.

Consortium-2 guidelines (26-32) to assess PAR by using echocardiography. Using these criteria for grading PAR, echocardiographic assessment post-implantation has proven to be highly discriminatory for downstream clinical outcomes.

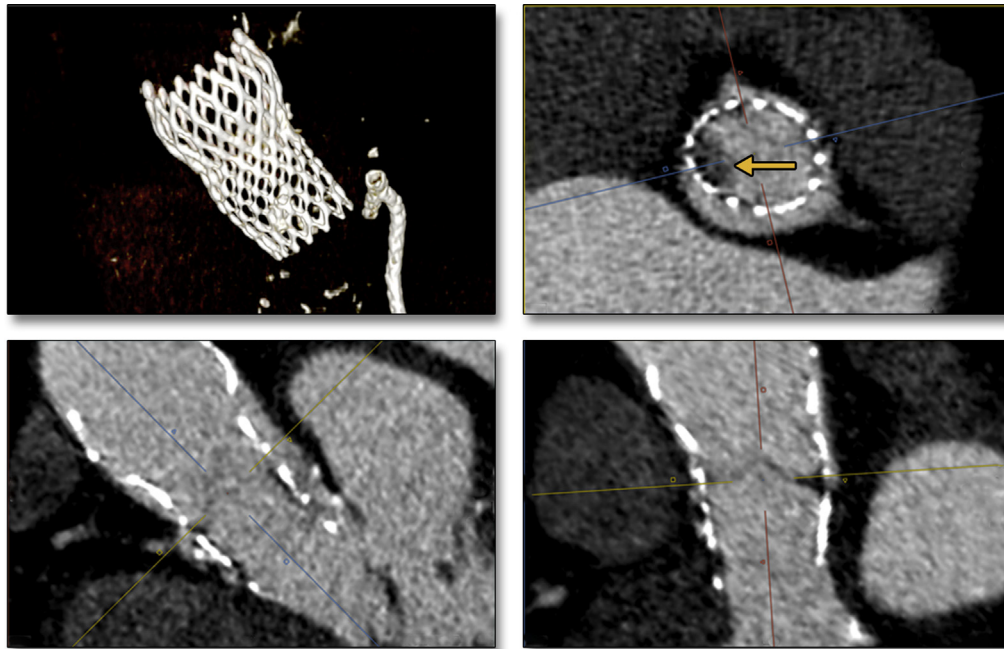
Recently, Kodali et al. (13), in the largest published single study to evaluate the impact of PAR, noted that patients with moderate/severe PAR demonstrated, on average, an increase in left ventricular end-diastolic volume with less reduction in left ventricular mass

TABLE 1 Valve Academic Research Consortium-2 Guidelines for the Diagnosis of Transcatheter Valve Dysfunction (27)

Prosthetic Aortic Valve Stenosis*	Normal	Mild Stenosis	Moderate-Severe Stenosis
PPM	Insignificant	Moderate	Severe
Quantitative parameters (flow-dependent)†			
Peak velocity	<3 m/s	3-4 m/s	>4 m/s
Mean gradient	<20 mm Hg	20-40 mm Hg	>40 mm Hg
Quantitative parameters (flow-independent)			
Doppler velocity index	≥0.35	0.35-0.25	<0.25
Effective orifice area, cm ² for BSA ≥1.6 m ²	>1.1 cm ²	1.0-0.8 cm ²	<0.8 cm ²
Effective orifice area, cm ² for BSA <1.6 m ²	>0.9 cm ² /m ²	0.9-0.6 cm ² /m ²	<0.6 cm ² /m ²
EOA indexed (cm ² /m ²) for BMI <30 kg/m ²	>0.85 cm ² /m ²	0.85-0.65 cm ² /m ²	<0.65 cm ² /m ²
EOA indexed (cm ² /m ²) for BMI ≥30 kg/m ²	>0.70 cm ² /m ²	0.90-0.60 cm ² /m ²	<0.60 cm ² /m ²

BMI = body mass index; BSA = body surface area; EOA = effective orifice area; PPM = patient prosthesis mismatch.

FIGURE 3 Multiplanar CT Imaging After Self-Expanding TAVR Implantation



Volume-rendered and multiplanar-reformatted imaging of a CoreValve (Medtronic, St. Paul, Minnesota) implanted 20 days previously showing an area of hypoattenuation at the 9 o'clock position (**arrow**) in keeping with subclinical thrombus formation. Abbreviations as in [Figure 1](#).

and reduced improvement in New York Heart Association functional class. Furthermore, both mild and greater than mild PAR resulted in significantly higher 1-year mortality. The impact of mild PAR on mortality remains controversial: other studies have not consistently found a link between mild PAR and an increase in 1-year mortality. In the FRANCE-2 (French Aortic National CoreValve and Edwards) registry, in which site-graded PAR was analyzed, patients with grade 1 or mild PAR did not have increased 1-year mortality compared with patients with no PAR or trace PAR. One potential explanation for this difference is the variability in the assessment of PAR severity (29-31).

In addition, cardiac magnetic resonance (CMR), with its tomographic nature and lack of reliance on echocardiographic windows, has recently been shown to be highly valuable for the adjudication of PAR severity. Phase contrast mapping of flow velocities allows for the quantification of flow velocity and volume without intravenous contrast (32,33). Ribeiro et al. (32) recently showed that not only is CMR reproducible but it is feasible to use in nearly all patients post-TAVR, with 97% of subjects having PAR

successfully evaluated. In addition, and incremental to echocardiography, CMR-graded PAR strongly predicts adverse clinical events after TAVR. While the data are mounting and are consistent, the need for routine clinical integration of CMR post-TAVR is neither well established nor clear. Although seemingly incremental to echocardiography, to add the additional costs and burden, CMR will likely need to be shown to help guide clinical decision-making post-TAVR that helps improve clinical outcomes. Given that interventional management of PAR is varied in its use, a trial randomizing between post-implant echocardiography and magnetic resonance imaging (MRI) to guide downstream treatment decision-making would be highly complex. This complexity would occur more because of the lack of clarity regarding how to best manage moderate PAR rather than because of the difficulties of performing MRI post-TAVR.

Leaflet thickening. Clinical valve thrombosis post-TAVR typically manifests with symptoms of heart failure and rising echocardiographic gradients. In a large registry of >4,200 patients undergoing TAVR, Latib et al. (34) documented the frequency of clinically

apparent valve thrombosis as 0.6% over a 2-year median follow-up period (Figure 3). In contrast, subclinical leaflet thrombus or hypoattenuating leaflet thickening has been recently identified at a much higher rate by using routine post-implant MDCT. The incidence of hypoattenuating leaflet thickening has varied across series and reports as well as across THV platforms, ranging from 10% to 44%, and is importantly uniquely identified on CT scans (35-37). Early follow-up studies suggest that the anatomic findings almost certainly relate to fibrin/thrombus because they resolve after patients are given Coumadin and are commonly not identified in those subjects who are receiving therapeutic anticoagulation therapy at the time of CT scanning; however, the clinical impact of these findings remain unclear. Importantly, there has been only a modest indication for increased risk of transient ischemic attacks (37) in a single study but no indication for increased risk of stroke or structural valve degeneration. As such, post-implant MDCT scanning has been embedded within both of the recently initiated low-risk trials in which patients are randomized to undergo surgery and TAVR (NCT02675114 and NCT02701283). Importantly, this action will represent a meaningful opportunity to more clearly define the incidence of hypoattenuating leaflet thickening and its clinical impact in a multicenter approach, thereby eliminating selection and reporting bias and mitigating the risk of site intervention by having the CT examinations evaluated by a single core laboratory. This step is essential to help combat the desire to layer tests and overimage with no clear evidence of appropriate clinical utility (38,39).

Randomized trials evaluating the clinical utility of imaging. Much attention has been given to defining our understanding of how to use imaging to diagnose and treat valvular disease. Unfortunately, less focus has been given to the cost-effectiveness and therapeutic impact that imaging has on valvular disease management. Although the realm of diagnostics may not always enable testing to be randomized to determine clinical utility, in a time of rising health care costs and increasingly scarce resources, it behooves us as imagers to ensure that imaging is used in a clinically efficacious and cost-effective fashion.

QUESTIONS TO BE ANSWERED BY POTENTIAL RANDOMIZED TRIALS

ARE ECHOCARDIOGRAPHY AND CT SCANNING BOTH NEEDED IN ADVANCE OF TAVR? At present, the question of whether echocardiography and CT scanning are both needed in advance of TAVR could

undoubtedly be debated from both sides. There is a strong push toward a minimalistic approach to TAVR to facilitate more rapid discharge and help contain (if not reduce) costs. Thus, many heart teams have moved away from TEE support at the time of the procedure to allow for conscious sedation as opposed to general anesthesia. Although this approach seems obvious to reduce length of stay and subsequently reduce costs, its effectiveness remains theoretical because it has never been proven in a prospective randomized trial. In largely single-center studies, there have been early successes from using minimalistic approaches by enabling earlier discharge and reducing the morbidity of general anesthesia with the use of pre-implantation CT scanning and balloon sizing of the annulus for device selection (4,40).

Although the potential for cost savings and more rapid discharge is real, others have shown that the elimination of TEE is not without risk. Early experiences published by Bagur et al. (41) showed that the use of TEE significantly reduced fluoroscopic time and the amount of intra-arterial contrast used to assist the procedure. The FRANCE2 registry documented a higher incidence of post-procedural aortic regurgitation in those patients who underwent TAVR with local anesthesia without TEE support than those with general anesthetic and TEE support. Finally, in the Brazilian TAVR registry, the use of TEE at the time of the procedure was associated with a reduced risk of overall (hazard ratio: 0.57) and late (hazard ratio: 0.47) mortality (42). Given these conflicting results, it would seem that there is equipoise between these 2 strategies that in our opinion can only be broken with the use of a prospective randomized trial.

IS INVASIVE CORONARY ANGIOGRAPHY MANDATORY BEFORE TAVR OR CAN A SELECTIVE INVASIVE CORONARY ANGIOGRAPHY STRATEGY SUPPORTED BY COMPUTED TOMOGRAPHY ANGIOGRAPHY WORK?

Coronary computed tomography angiography (CTA) has established itself as the noninvasive gold standard for the detection of and exclusion from obstructive anatomic coronary disease compared with invasive coronary angiography (ICA). This high diagnostic performance, however, has been validated in patients with stable chest pain typically in sinus rhythm, reduced and stable resting heart rates, and supported by the use of beta-blockade (43). Patients being evaluated before TAVR are much more likely to not be in sinus rhythm, and beta-blockade is generally avoided due to the presence of severe aortic stenosis, however (44). Furthermore, patients are often assumed to have a high burden of coronary artery calcification, with anticipated low specificity of coronary findings on CT

scanning, given the well-known relationship of the aortic valve calcification and coronary artery calcification. Owing to the assumed limitations of CTA, particularly when TAVR was introduced, CTA has played a very limited role in the evaluation of coronary artery disease before TAVR. This scenario is further confounded by the fact that the management of coronary artery disease before TAVR is not well established.

The role of ICA before TAVR was originally to evaluate the extent and severity of coronary artery disease, as well as to assess the iliofemoral access, the aortic root angulation, and coronary ostial height and to obtain a gross assessment of annular dimensions. Over time, pre-TAVR CT scanning has reduced the necessity of ICA for most of these tasks with the exception of the evaluation of coronary artery disease, although this scenario is also changing with the rapid technology developments in the field of CT scanning. These developments include single-beat/whole heart coverage, significantly improved mechanical temporal resolution with dual-source technology, and new algorithmic approaches to motion correction. Thus, there is a growing body of largely single-center data which suggest that coronary CTA in the pre-TAVR population is accurate compared with ICA (44-46).

Building on these technical and accuracy studies, Chieffo et al. (46), in a large single-center observational cohort, have provided data which suggest that a selective ICA strategy guided by the presence of obstructive coronary artery disease findings according to coronary CTA is a safe clinical approach. In 491 patients treated with TAVR, 375 (76.3%) underwent only coronary CTA, whereas coronary CTA and ICA were performed in 116 (21.7%) patients. The investigators noted no differences in crude major adverse cardiovascular and cerebrovascular event rates at 30 days and 1 year between the 2 groups. After multivariable adjustment, coronary CTA performed alone was not associated with a higher risk of major adverse cardiac events at 1 year of follow-up (hazard ratio: 0.89; 95% confidence interval: 0.49 to 1.60; $p = 0.69$). They also noted a shorter overall in-hospital stay (in-hospital admission to final discharge) in patients who just underwent coronary CTA (9 [7 to 14] days vs. 10 [8 to 16] days with mandatory ICA; $p = 0.04$).

Despite the potential of coronary CTA to screen patients for the presence of prognostic relevant coronary artery disease and subsequently eliminate a significant number of ICAs being performed before TAVR, most heart teams remain appropriately hesitant for a number of reasons, including the lack of randomized trial data. A randomized trial testing the

hypothesis that a coronary CTA with ad hoc coronary angiography is noninferior to a routine combination of coronary angiography with coronary CTA is warranted; such data could help provide unbiased evidence for safety, efficacy, and efficiency regarding the use of a complete noninvasive assessment of patients referred for TAVR. This approach may also help lead to shorter referral-to-procedure times and possibly reduce ancillary costs related to a TAVR procedure.

CAN MRI HELP IN THE GRADING OF THE SEVERITY OF MR AND THE SELECTION OF PATIENTS TO UNDERGO MITRAL VALVE INTERVENTION?

Echocardiography is by far the most commonly used method for the diagnosis and grading of MR. In patients with severe MR, American College of Cardiology/American Heart Association guidelines recommend surgical intervention in the setting of left ventricular dysfunction, even in the absence of symptoms (47-49). A more aggressive approach has recently been advocated, with proponents arguing that results are superior when there is earlier surgical intervention (47-49). The clinical outcomes after mitral valve surgery, both repair and replacement, show improved quality of life in the setting of durable resolution of MR and left ventricular remodeling. Interestingly, recently published experiences by Uretsky et al. suggest that pre-intervention MRI adjudication of MR severity allows for the identification of patients with severe MR who are likely to experience left ventricular remodeling post-intervention. In this study, there was a strong correlation between post-surgical left ventricular remodeling and MR severity as assessed by using MRI ($r = 0.85$; $p < 0.0001$) but no correlation between post-surgical left ventricular remodeling and MR severity as assessed by using echocardiography ($r = 0.32$; $p = 0.1$) (45). Importantly, the agreement between MRI and echocardiographic estimates of MR severity was modest in the overall cohort ($r = 0.6$; $p < 0.0001$), and there was a poorer correlation in the subset of patients sent for surgery ($r = 0.4$; $p = 0.01$). The investigators suggest that the reasons for the greater likelihood of left ventricular remodeling with MRI identifying severe MR may relate to the overestimation of MR with echocardiography. These data are not the first to show discordance between MRI and echocardiography in terms of MR severity. This outcome has been described repeatedly in the literature (47-49); however, this study was the first to suggest that MRI may be more accurate through the tighter correlation with downstream remodeling seen in the MRI arm.

These interesting data call into question whether MRI can help better identify patients who should undergo mitral valve intervention. Historically, such data may motivate a change in practice but to avoid unnecessary layering of tests, it would be prudent to perform a trial randomizing patients to undergoing echocardiography versus MRI for the determination of MR severity and the appropriateness of mitral valve intervention. Without these data, and given the years of experience using echocardiography for MR adjudication, we must learn from past mistakes and not rush to change practice without prospective randomized data.

CONCLUSIONS

Current knowledge and clinical practice in the field of imaging for valvular heart disease is supported by very modest, if any, randomized trial data. In valvular disease intervention, imaging plays important supportive roles to help optimize clinical outcomes and, as such, it largely does not lend itself to randomization. Decisions regarding when and how to

image should be made on the basis of a number of factors, including site expertise, patient factors, and procedural expectations. Although many of the issues may not lend themselves to randomization, there are a number of opportunities to meaningfully advance the field of valvular heart disease through prospective randomized trials. Imaging has rapidly ascended to become an essential clinical tool to aid in the diagnosis of valvular disease and to assist procedural intervention. However, we must not simply be fascinated by improving imaging quality but constantly focus on improving our understanding of how imaging can help improve downstream clinical outcomes, which is, in fact, why we image in the first place: not for a beautiful image but to help the patients we collectively serve.

ADDRESS FOR CORRESPONDENCE: Dr. Jonathon Leipsic, Advanced Cardiac Imaging, UBC Department of Medical Imaging, Centre for Heart Valve Innovation, St. Paul's Hospital, 1081 Burrard Street, Vancouver, British Columbia V6Z 1Y6, Canada. E-mail: jleipsic@providencehealth.bc.ca.

REFERENCES

1. SCOT-HEART investigators. CT coronary angiography in patients with suspected angina due to coronary heart disease (SCOT-HEART): an open-label, parallel-group, multicentre trial. *Lancet* 2015;385:2383-91.
2. Williams MC, Hunter A, Shah AS, et al. Use of coronary computed tomographic angiography to guide management of patients with coronary disease. *J Am Coll Cardiol* 2016;67:1759-68.
3. Dedic A, Lubbers MM, Schaap J, et al. Coronary CT angiography for suspected ACS in the era of high-sensitivity troponins: randomized multicenter study. *J Am Coll Cardiol* 2016;67:16-26.
4. Douglas PS, Hoffmann U, Patel MR, et al. Outcomes of anatomical versus functional testing for coronary artery disease. *N Engl J Med* 2015;372:1291-300.
5. Burwash IG, Forbes AD, Sadahiro M, et al. Echocardiographic volume flow and stenosis severity measures with changing flow rate in aortic stenosis. *Am J Physiol* 1993;265:H1734-43.
6. Baumgartner H, Stefenelli T, Niederberger J, Schima H, Maurer G. 'Overestimation' of catheter gradients by Doppler ultrasound in patients with aortic stenosis: a predictable manifestation of pressure recovery. *J Am Coll Cardiol* 1999;33:1655-6.
7. Binder RK, Webb JG, Willson AB, et al. The impact of integration of a multidetector computed tomography annulus area sizing algorithm on outcomes of transcatheter aortic valve replacement: a prospective, multicenter, controlled trial. *J Am Coll Cardiol* 2013;62:431-8.
8. Piazza N, de Jaegere P, Schultz C, Becker AE, Serruys PW, Anderson RH. Anatomy of the aortic valvar complex and its implications for transcatheter implantation of the aortic valve. *Circ Cardiovasc Interv* 2008;1:74-81.
9. Tops LF, Wood DA, Delgado V, et al. Noninvasive evaluation of the aortic root with multislice computed tomography implications for transcatheter aortic valve replacement. *J Am Coll Cardiol* 2008;1:321-30.
10. Leipsic J, Gurvitch R, Labounty TM, et al. Multidetector computed tomography in transcatheter aortic valve implantation. *J Am Coll Cardiol* 2011;4:416-29.
11. Leon MB, Smith CR, Mack M, et al. Transcatheter aortic-valve implantation for aortic stenosis in patients who cannot undergo surgery. *N Engl J Med* 2010;363:1597-607.
12. Adams DH, Popma JJ, Reardon MJ, et al. Transcatheter aortic-valve replacement with a self-expanding prosthesis. *N Engl J Med* 2014;370:1790-8.
13. Kodali SK, Williams MR, Smith CR, et al. Two-year outcomes after transcatheter or surgical aortic-valve replacement. *N Engl J Med* 2012;366:1686-95.
14. Yang TH, Webb JG, Blanke P, et al. Incidence and severity of paravalvular aortic regurgitation with multidetector computed tomography nominal area oversizing or undersizing after transcatheter heart valve replacement with the Sapien 3: a comparison with the Sapien XT. *J Am Coll Cardiol* 2015;8:462-71.
15. Webb J, Gerosa G, Lefèvre T, et al. Multicenter evaluation of a next-generation balloon-expandable transcatheter aortic valve. *J Am Coll Cardiol* 2014;64:2235-43.
16. Kodali S, Thourani VH, White J, et al. Early clinical and echocardiographic outcomes after SAPIEN 3 transcatheter aortic valve replacement in inoperable, high-risk and intermediate-risk patients with aortic stenosis. *Eur Heart J* 2016;37:2252-62.
17. Blanke P, Dvir D, Naoum C, et al. Prediction of fluoroscopic angulation and coronary sinus location by CT in the context of transcatheter mitral valve implantation. *J Cardiovasc Comput Tomogr* 2015;9:183-92.
18. Blanke P, Dvir D, Cheung A, et al. A simplified D-shaped model of the mitral annulus to facilitate CT-based sizing before transcatheter mitral valve implantation. *J Cardiovasc Comput Tomogr* 2014;8:459-67.
19. Blanke P, Dvir D, Cheung A, et al. Mitral annular evaluation with CT in the context of transcatheter mitral valve replacement. *J Am Coll Cardiol* 2015;8:612-5.
20. Blanke P, Naoum C, Webb J, et al. Multimodality imaging in the context of transcatheter mitral valve replacement: establishing consensus among modalities and disciplines. *J Am Coll Cardiol* 2015;8:1191-208.
21. Douglas PS, Waugh RA, Bloomfield G, et al. Implementation of echocardiography core laboratory best practices: a case study of the PARTNER I trial. *J Am Soc Echocardiogr* 2013;26:348-58.e3.
22. Blanke P, Naoum C, Dvir D, et al. Predicting LVOT obstruction in transcatheter mitral valve implantation: concept of the Neo-LVOT. *J Am Coll Cardiol* 2016 Mar 9 [E-pub ahead of print].
23. Fukuda S, Lever HM, Stewart WJ, et al. Diagnostic value of left ventricular outflow area in

- patients with hypertrophic cardiomyopathy: a real-time three-dimensional echocardiographic study. *J Am Soc Echocardiogr* 2008;21:789-95.
24. Feldman T, Kar S, Elmariah S, et al. Randomized comparison of percutaneous repair and surgery for mitral regurgitation. *J Am Coll Cardiol* 2015;66:2844-54.
25. Feldman T, Kar S, Rinaldi M, EVEREST Investigators. Percutaneous mitral repair with the MitraClip system: safety and midterm durability in the initial EVEREST (Endovascular Valve Edge-to-Edge Repair Study) cohort. *J Am Coll Cardiol* 2009;54:686-94.
26. Hahn RT, Little S, Monaghan M, et al. Recommendations for comprehensive intraprocedural echocardiographic imaging during TAVR. *J Am Coll Cardiol Img* 2015;8:261-87.
27. Kappetein AP, Head SJ, Généreux P, et al., Valve Academic Research Consortium-2. Updated standardized endpoint definitions for transcatheter aortic valve implantation: the Valve Academic Research Consortium-2 consensus document. *J Thorac Cardiovasc Surg* 2013;145:6-23.
28. Nishimura R, Otto C, Bonow R, et al. 2014 AHA/ACC guideline for the management of patients with valvular heart disease: a report of the American College of Cardiology/American Heart Association Task Force on Practice Guidelines. *J Am Coll Cardiol* 2014;63:e57-185.
29. Kodali S, Pibarot P, Douglas PS, et al. Paravalvular regurgitation after transcatheter aortic valve replacement with the Edwards Sapien valve in the PARTNER trial: characterizing patients and impact on outcomes. *Eur Heart J* 2015;36:449-56.
30. Belle E, Juthier F, Susen S, et al. Post-procedural aortic regurgitation in balloon-expandable and self-expandable TAVR procedures: analysis of predictors and impact on long-term mortality: insights from the FRANCE2 Registry. *Circulation* 2014;129:1415-27.
31. Pibarot P, Hahn RT, Weissman NJ, Monaghan MJ. Assessment of paravalvular regurgitation following TAVR: a proposal of unifying grading scheme. *J Am Coll Cardiol Img* 2015;8:340-60.
32. Ribeiro HB, Orwat S, Hayek S, et al. Cardiovascular magnetic resonance to evaluate aortic regurgitation after transcatheter aortic valve replacement. *J Am Coll Cardiol* 2016;68:577-85.
33. Cavalcante JL, Lalude O, Schoenhagen P, et al. Cardiovascular magnetic resonance imaging for structural and valvular heart disease interventions. *J Am Coll Cardiol Intv* 2016;9:399-425.
34. Latib A, Naganuma T, Abdel-Wahab M, et al. Treatment and clinical outcomes of transcatheter heart valve thrombosis. *Circ Cardiovasc Interv* 2015;8:e001779.
35. Leetmaa T, Hansson NC, Leipsic J, et al. Early aortic transcatheter heart valve thrombosis: diagnostic value of contrast-enhanced multi-detector computed tomography. *Circ Cardiovasc Interv* 2015;8:e001596.
36. Pache G, Schoechlin S, Blanke P, et al. Early hypo-attenuated leaflet thickening in balloon-expandable transcatheter aortic heart valves. *Eur Heart J* 2016;37:2263-71.
37. Makkar RR, Fontana G, Jilaihawi H, et al. Possible subclinical leaflet thrombosis in bioprosthetic aortic valves. *N Engl J Med* 2015;373:2015-24.
38. Carrier M, Righini M, Le GG. Symptomatic subsegmental pulmonary embolism: what is the next step? *J Thromb Haemost* 2012;10:1486-90.
39. Carrier M, Righini M, Wells PS, et al. Subsegmental pulmonary embolism diagnosed by computed tomography: incidence and clinical implications. A systematic review and meta-analysis of the management outcome studies. *J Thromb Haemost* 2010;8:1716-22.
40. Babaliaros V, Devireddy C, Lerakis S, et al. Comparison of transfemoral transcatheter aortic valve replacement performed in the catheterization laboratory (minimalist approach) versus hybrid operating room (standard approach): outcomes and cost analysis. *J Am Coll Cardiol Intv* 2014;7:898-904.
41. Bagur R, Rodés-Cabau J, Doyle D, et al. Usefulness of TEE as the primary imaging technique to guide transcatheter transapical aortic valve implantation. *J Am Coll Cardiol Img* 2011;4:115-24.
42. de Brito FS Jr., Carvalho LA, Sarmento-Leite R, et al., Brazilian TAVI Registry Investigators. Outcomes and predictors of mortality after transcatheter aortic valve implantation: results of the Brazilian registry. *Catheter Cardiovasc Interv* 2015;85:E153-62.
43. Leipsic JA, Labounty TM, Hague CJ, et al. Effect of a novel vendor-specific motion-correction algorithm on image quality and diagnostic accuracy in persons undergoing coronary CT angiography without rate-control medications. *J Cardiovasc Comput Tomogr* 2012;6:164-71.
44. Opolski MP, Kim WK, Walther C. Diagnostic accuracy of computed tomography angiography for the detection of coronary artery disease in patients referred for transcatheter aortic valve implantation. *Clinical Res Cardiol* 2015;104:471-80.
45. Hamdan A, Wellnhofer E, Konen E, et al. Coronary CT angiography for the detection of coronary artery stenosis in patients referred for TAVR. *J Cardiovasc Comput Tomogr* 2015;9:31-41.
46. Chieffo A, Giustino G, Spagnolo P, et al. Routine screening of coronary artery disease with computed tomographic coronary angiography in place of invasive coronary angiography in patients undergoing transcatheter aortic valve replacement. *Circ Cardiovasc Interv* 2015;8:e002025.
47. Enriquez-Sarano M, Sundt TM 3rd. Early surgery is recommended for mitral regurgitation. *Circulation* 2010;121:804-11; discussion 812.
48. Gillam LD, Schwartz A. Primum non nocere: the case for watchful waiting in asymptomatic "severe" degenerative mitral regurgitation. *Circulation* 2010;121:813-21; discussion 821.
49. Uretsky S, Gillam L, Lang R, et al. Discordance between echocardiography and MRI in the assessment of mitral regurgitation severity: a prospective multicenter trial. *J Am Coll Cardiol* 2015;65:1078-88.

KEY WORDS aortic stenosis, TAVR, transcatheter mitral valve replacement, valvular heart disease