



Universiteit
Leiden
The Netherlands

**Atypical hemolytic uremic syndrome and C3 glomerulopathy:
conclusions from a "Kidney Disease: Improving Global Outcomes"
(KDIGO) Controversies Conference**

Goodship, T.H.J.; Cook, H.T.; Fakhouri, F.; Fervenza, F.C.; Fremeaux-Bacchi, V.; Kavanagh, D.; ... ; Conf Participants

Citation

Goodship, T. H. J., Cook, H. T., Fakhouri, F., Fervenza, F. C., Fremeaux-Bacchi, V., Kavanagh, D., ... Smith, R. J. H. (2017). Atypical hemolytic uremic syndrome and C3 glomerulopathy: conclusions from a "Kidney Disease: Improving Global Outcomes" (KDIGO) Controversies Conference. *Kidney International*, 91(3), 539-551.
doi:10.1016/j.kint.2016.10.005

Version: Not Applicable (or Unknown)
License: [Leiden University Non-exclusive license](#)
Downloaded from: <https://hdl.handle.net/1887/115945>

Note: To cite this publication please use the final published version (if applicable).

Atypical hemolytic uremic syndrome and C3 glomerulopathy: conclusions from a “Kidney Disease: Improving Global Outcomes” (KDIGO) Controversies Conference



OPEN

Timothy H.J. Goodship¹, H. Terence Cook², Fadi Fakhouri³, Fernando C. Fervenza⁴, Véronique Frémeaux-Bacchi⁵, David Kavanagh¹, Carla M. Nester^{6,7}, Marina Noris⁸, Matthew C. Pickering², Santiago Rodríguez de Córdoba⁹, Lubka T. Roumenina^{10,11,12}, Sanjeev Sethi¹³ and Richard J.H. Smith^{6,7}; for Conference Participants¹⁴

¹Institute of Genetic Medicine, Newcastle University, Newcastle upon Tyne, UK; ²Centre for Complement and Inflammation Research, Department of Medicine, Imperial College Hammersmith Campus, London, UK; ³INSERM, UMR-S 1064, and Department of Nephrology and Immunology, CHU de Nantes, Nantes, France; ⁴Department of Nephrology and Hypertension, Mayo Clinic, Rochester, Minnesota, USA; ⁵Assistance Publique-Hôpitaux de Paris, Hôpital Européen Georges Pompidou, Paris, France; ⁶Molecular Otolaryngology and Renal Research Laboratories, Carver College of Medicine, University of Iowa, Iowa City, Iowa, USA; ⁷Division of Nephrology, Department of Internal Medicine, Carver College of Medicine, University of Iowa, Iowa City, Iowa, USA; ⁸IRCCS-Istituto di Ricerche Farmacologiche “Mario Negri,” Clinical Research Center for Rare Diseases “Aldo e Cele Daccò,” Ranica, Bergamo, Italy; ⁹Centro de Investigaciones Biológicas, Consejo Superior de Investigaciones Científicas, Madrid, Spain; Centro de Investigación Biomédica en Enfermedades Raras, Madrid, Spain; ¹⁰Institut National de la Santé et de la Recherche Médicale, Unité Mixte de Recherche S1138, Complément et Maladies, Centre de Recherche des Cordeliers, Paris, France; ¹¹Université Paris Descartes Sorbonne Paris-Cité, Paris, France; ¹²Université Pierre et Marie Curie (UPMC-Paris-6), Paris, France; and ¹³Department of Laboratory Medicine and Pathology, Mayo Clinic, Rochester, Minnesota, USA

In both atypical hemolytic uremic syndrome (aHUS) and C3 glomerulopathy (C3G) complement plays a primary role in disease pathogenesis. Herein we report the outcome of a 2015 Kidney Disease: Improving Global Outcomes (KDIGO) Controversies Conference where key issues in the management of these 2 diseases were considered by a global panel of experts. Areas addressed included renal pathology, clinical phenotype and assessment, genetic drivers of disease, acquired drivers of disease, and treatment strategies. In order to help guide clinicians who are caring for such patients, recommendations for best treatment strategies were discussed at length, providing the evidence base underpinning current treatment options. Knowledge gaps were identified and a prioritized research agenda was proposed to resolve outstanding controversial issues.

Kidney International (2017) **91**, 539–551; <http://dx.doi.org/10.1016/j.kint.2016.10.005>

KEYWORDS: anti-complement therapies; atypical hemolytic uremic syndrome; C3 glomerulopathy; complement; glomerulonephritis; kidney disease

Copyright © 2016, International Society of Nephrology. Published by Elsevier Inc. This is an open access article under the CC BY-NC-SA license (<http://creativecommons.org/licenses/by-nc-sa/4.0/>).

Correspondence: Timothy H.J. Goodship, Institute of Genetic Medicine, Newcastle University, Central Parkway, Newcastle upon Tyne, NE1 3BZ, UK. E-mail: tim.goodship@ncl.ac.uk; and Richard J.H. Smith, University of Iowa, 200 Hawkins Drive—21151 PFP, Iowa City, IA 52242, USA. E-mail: richard-smith@uiowa.edu

¹⁴See Appendix for list of other conference participants.

Received 9 August 2016; revised 10 October 2016; accepted 20 October 2016; published online 16 December 2016

The 2 prototypical complement-mediated kidney diseases are atypical hemolytic uremic syndrome (aHUS) and C3 glomerulopathy (C3G).

Atypical hemolytic uremic syndrome is an ultra-rare disease characterized by acute kidney injury, thrombocytopenia, and microangiopathic hemolytic anemia that occurs with a reported incidence of approximately 0.5 per million per year. Other diseases that can present with a similar phenotype include Shiga toxin-producing *E. coli*-associated hemolytic uremic syndrome (STEC-HUS), thrombotic thrombocytopenic purpura, and other multisystem disorders. Criteria have been established to facilitate the diagnosis of aHUS. At least 50% of patients with aHUS have an underlying inherited and/or acquired complement abnormality, which leads to dysregulated activity of the alternative pathway at the endothelial cell surface. There are, however, noncomplement inherited abnormalities such as mutations in *DGKE*, which can result in an aHUS phenotype. Until recently, the prognosis for aHUS was poor, with the majority of patients developing end-stage renal disease within 2 years of presentation. However, with the introduction of eculizumab, a humanized monoclonal antibody against C5, it is now possible to control the renal disease and prevent development of end-stage renal disease.

C3G is also ultra-rare (incidence approximately 1 per million per year) and defines a group of incurable kidney diseases driven by uncontrolled activation of the complement cascade that leads to C3 deposition within the glomerulus. Most frequently, dysregulation occurs at the level of the C3 convertase of the alternative pathway in the fluid phase and is driven by genetic and/or acquired defects. Broad

interindividual variability gives rise to 2 major subtypes of disease, dense deposit disease (DDD) and C3 glomerulonephritis (C3GN), that are resolved by characteristic findings on renal biopsy.

The objective of this Kidney Disease: Improving Global Outcomes (KDIGO) conference was to gather a global panel of multidisciplinary clinical and scientific expertise to identify key issues relevant to the optimal management of these 2 diseases and to propose a research agenda to resolve outstanding controversial issues.

RENAL PATHOLOGY

aHUS

Atypical hemolytic uremic syndrome is a “thrombotic” microangiopathy (TMA), the pathological features of which represent tissue responses to endothelial injury. In some biopsies, overt thrombosis as evidenced by intraluminal fibrin or fibrin-platelet plugging is not seen. Nonthrombotic features include endothelial swelling and denudation, mesangiolysis, double contours of the glomerular basement membrane, and subendothelial accumulation of electron-lucent, flocculent material. In arteries and arterioles, intramural fibrin, myxoid intimal thickening, and concentric myointimal proliferation (onion-skinning) may occur. It is illogical to describe cases with these features and clear absence of thrombosis as thrombotic microangiopathy. We therefore suggest referring to the process as microangiopathy, with further specification of whether thrombosis is present (Table 1).

Areas of controversy and gaps in knowledge. C5b-9 staining can be seen in microangiopathy attributed to complement abnormalities, drug toxicity, and after hematopoietic stem cell

transplantation.¹ However, its presence is not reliable and we do not know whether this variability reflects technical or biological differences (Table 1).

In general, it is not possible to determine etiology from morphology. Because morphologic features do not allow identification of etiology, it is important for the pathologist to provide a differential diagnosis, especially in patients with severe hypertension, where attributing changes to hypertension alone may lead to failure to identify other specific causes such as complement dysfunction.

C3G

C3G defines a disease spectrum caused by abnormal control of complement activation, deposition, or degradation that results in predominant glomerular C3 fragment deposition associated with characteristic deposits as seen by electron microscopy (EM).² Based on EM appearance, C3G may be subclassified as DDD (dense osmiophilic intramembranous deposits) or C3GN (light dense, amorphous mesangial, paramesangial, subendothelial, and subepithelial deposits) (Table 2).

A renal biopsy is required to diagnose C3G. The pattern seen on light microscopy can be very diverse, and a diagnosis of C3G can only be made on immunofluorescence (IF). The criterion on IF with the best balance of sensitivity and specificity is the presence of dominant C3 staining, with the intensity of C3 staining at least 2 orders of magnitude greater than any other immunoreactant (i.e., IgG, IgM, IgA, and C1q).³ This criterion captures about 90% of DDD cases, but possibly fewer C3GN cases.³ In the remaining cases, the initial kidney biopsy may not show C3-dominant glomerulonephritis (GN), but subsequent biopsies may, reflecting an evolution in disease over time and suggesting that in cases with an atypical clinical course, repeat biopsies may be

Table 1 | Morphological features in microangiopathy

Active lesions	Chronic lesions
Glomeruli <ul style="list-style-type: none"> • Thrombi • Endothelial swelling or denudation • Fragmented red blood cells • Subendothelial flocculent material by EM • Mesangiolysis • Microaneurysms 	Glomeruli <ul style="list-style-type: none"> • Double contours of peripheral capillary walls by LM, with variable mesangial interposition • New subendothelial basement membrane by EM • Widening of the subendothelial zone by EM
Arterioles <ul style="list-style-type: none"> • Thrombi • Endothelial swelling or denudation • Intramural fibrin • Fragmented red blood cells • Intimal swelling • Myocyte necrosis 	Arterioles <ul style="list-style-type: none"> • Hyaline deposits
Arteries <ul style="list-style-type: none"> • Thrombi • Myxoid intimal swelling • Intramural fibrin • Fragmented red blood cells 	Arteries <ul style="list-style-type: none"> • Fibrous intimal thickening with concentric lamination (onion skin)

EM, electron microscopy; LM, light microscopy.

Table 2 | Morphological features of C3G

Light microscopy
Active lesions <ul style="list-style-type: none"> • Mesangial expansion with or without hypercellularity • Endocapillary hypercellularity including monocytes and/or neutrophils • Capillary wall thickening with double contours (the combination of capillary wall thickening and mesangial increase is referred to as a membranoproliferative pattern) • Necrosis • Cellular/fibrocellular crescents Chronic lesions <ul style="list-style-type: none"> • Segmental or global glomerulosclerosis • Fibrous crescents
Immunofluorescence microscopy <ul style="list-style-type: none"> • Typically dominant C3 staining
Electron microscopy <ul style="list-style-type: none"> • DDD: Dense osmiophilic mesangial and intramembranous electron dense deposits • C3GN: Amorphous mesangial with or without capillary wall deposits including subendothelial, intramembranous and subepithelial electron dense deposits • Subepithelial “humps” may be seen in both DDD and C3GN

C3G, C3 glomerulopathy; DDD, dense deposit disease; C3GN, C3 glomerulonephritis.

useful.³ The timing of the initial biopsy is crucial because C3G often presents in the context of an acute infection, and C3 dominance can be seen in self-limiting postinfectious glomerulonephritis. There are no morphological features in acute exudative GN that predict resolution or progression. Humps are no longer considered pathognomonic of postinfectious glomerulonephritis, as they are frequently found in C3G. Cases of acute exudative GN with double contours of the glomerular basement membrane should heighten suspicion for C3GN. EM should be conducted in all cases to unequivocally distinguish DDD and C3GN, as this distinction is clinically important. In addition, in light of recent descriptions of GN with masked monotypic Ig deposits,^{4,5} staining for IgG and light chains on pronase-digested paraffin sections should be considered for all cases of C3GN on standard IF, especially in adults.

Areas of controversy and gaps in knowledge. There is evidence that staining for C4d can distinguish C3G from immune complex-mediated GN, though its role is not established.^{5–7} Further studies on both frozen and paraffin sections are required.

There are numerous knowledge gaps. Broadly, correlations between renal biopsy appearances, etiology, and clinical outcome including response to therapy are ill defined. IF staining is subjective and semiquantitative, and reliability and reproducibility have not been studied. While the EM appearance of DDD is well-defined and is used as a standard against which to assess the role of IF,³ it is not clear whether EM appearances in C3GN are characteristic and can confirm the diagnosis if IF is equivocal. The significance of some EM findings, such as the hump-like subepithelial deposits, is uncertain, and in some cases, distinguishing DDD and C3GN by EM is difficult. While it is possible to objectively assess the density of deposits on EM, the value of this approach requires further study.

It is possible to identify different C3 breakdown products in glomeruli by IF⁸ or mass spectrometry after laser capture microdissection.^{9,10} This methodology can also be used to detect other complement components (i.e., factor H-related proteins, C5–C9). It is not known whether some of these complement components in specific tissue compartments (e.g., C5b-9) might identify a subset of patients likely to benefit from a specific type of therapy (e.g., anti-C5 therapy). An increased understanding of the significance of different complement components would be facilitated by detailed IF studies using well-characterized antibodies.

CLINICAL PHENOTYPE AND ASSESSMENT

aHUS

The term aHUS has been used historically to define *any* HUS not caused by STEC-HUS. Current classifications reflect an increased understanding of disease mechanisms including the impact of genetic background and etiologic triggers.¹¹ As a result, some clinicians now use the term “primary aHUS” when an underlying abnormality of the alternative pathway of complement is strongly suspected and other causes of

secondary aHUS have been excluded (Figure 1). However, even in some of these patients, a complement abnormality will not be identified. In many patients with an underlying complement risk factor, a trigger is required for aHUS to manifest.¹² Triggers include autoimmune conditions, transplants, pregnancy, infections, drugs, and metabolic conditions.¹³ It may be difficult to show unequivocally that a trigger unmasks latent complement defects. Additional work is required to define the impact of complement risk factors in these subgroups.

Acute versus chronic disease? In general, we do not understand the time course of a clinical episode of aHUS and whether disease activity persists. However, many patients appear to be at life-long risk for the recurrent acute presentation of aHUS. Disease penetrance for an acute episode of aHUS is age-related, and by age 70 may be as high as 64%,¹⁴ an observation that supports the existence of additional disease modifiers. A small percentage (3%–5%) of patients carry more than 1 pathogenic genetic variant, supporting a relationship between mutation burden and penetrance.¹⁵ Presentation in later life is consistent with the need for an environmental trigger. Discordance between the pathological and clinical manifestations of the disease is sometimes seen. For instance, a thrombotic microangiopathy can sometimes be present on renal biopsy in the absence of thrombocytopenia.

The introduction of eculizumab has changed the natural history of aHUS. Prior to eculizumab, most patients with aHUS progressed to end-stage renal disease, at which time the TMA process usually ceased.¹⁶ With complement inhibitory therapy, glomerular perfusion and function are maintained. How the renal endothelium is altered and interacts with the complement system following withdrawal of complement inhibitors is unclear and may be informed by clinical trials.

C3G

In contrast to the acute presentation of aHUS, in the majority of patients with C3G, the disease follows a chronic, indolent course with persistent alternative pathway activation resulting in a 10-year renal survival of approximately 50%.¹⁷ However, cases of C3G presenting as a rapidly progressive GN are well recognized.^{18–20}

Extrarenal manifestations of aHUS and C3G

Extrarenal manifestations are reported in up to 20% of patients with aHUS (Supplementary Table S1). It is unclear whether these manifestations are a direct consequence of complement activation, TMA, or other factors such as severe hypertension and uremia. Interestingly, despite sharing many of the same rare genetic variants in *CFH*²¹ and *CFI*²² described in age-related macular degeneration, drusen formation is not commonly reported in aHUS.²³

In C3G (DDD and C3GN), acquired partial lipodystrophy²⁴ and retinal drusen^{25,26} are reported and appear to be direct consequences of complement activation. Acquired

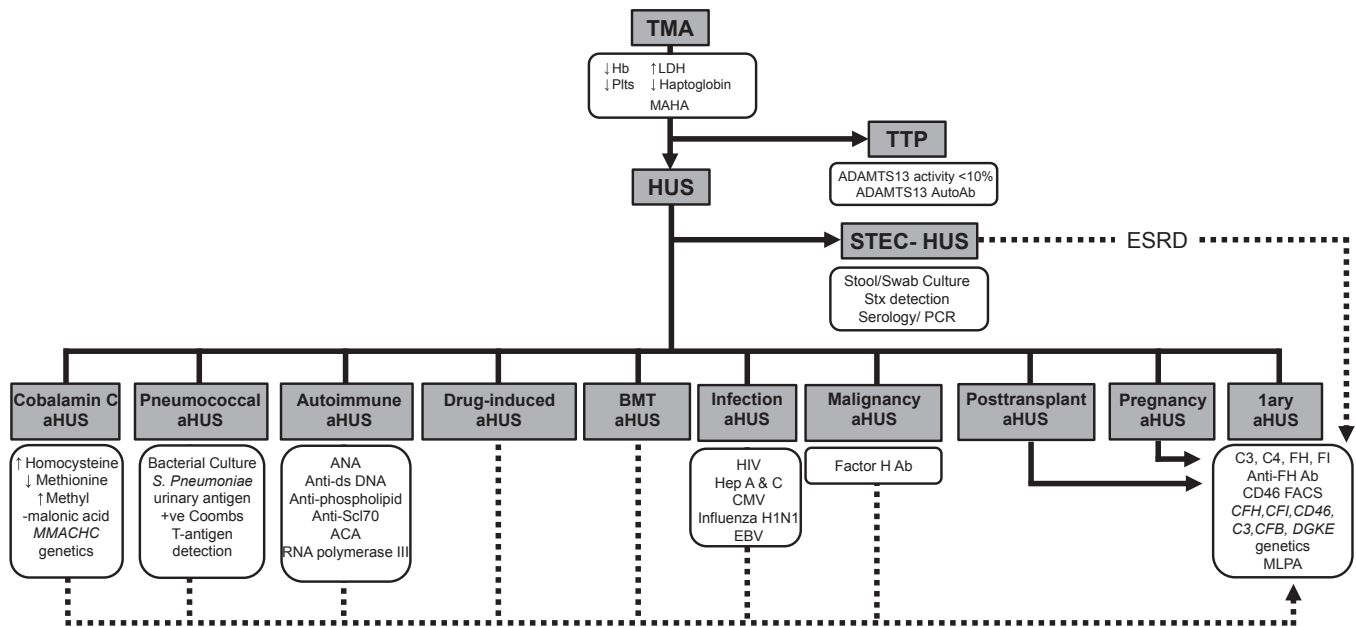


Figure 1 | TMA diagnostic flow chart. Following the diagnosis of a TMA, clinical and laboratory evaluation is required to establish the etiology. ADAMTS13 activity is urgently required to exclude TTP prior to treatment with eculizumab in adults but is not a prerequisite in children. Investigation for STEC-HUS should be undertaken in all individuals with suspected aHUS. In all pediatric aHUS, plasma and urinary evaluation for cbIc deficiency is mandatory. All individuals with suspected primary aHUS should have a complete evaluation for complement-mediated aHUS. Individuals with pregnancy-associated aHUS and *de novo* transplantation associated aHUS should also have a full complement evaluation due to the high prevalence of rare genetic variants described in these subgroups. In other secondary cases of aHUS, insufficient evidence exists to recommend a full genetic evaluation, although it is noted that rare genetic variants have been described in many of these cases. Rarely, in severe cases of STEC-HUS resulting in ESRD, rare genetic variants have been described following HUS recurrence in a subsequent renal transplant. In cases where the role of complement is as yet unclear, the clinician should decide on the evaluation based on the clinical consequences of positive result (e.g., listing for renal transplantation as demonstrated by the dotted line). Factor H autoantibodies have been reported in non-small cell lung cancer, although a causative association with malignancy associated aHUS has yet to be made.¹⁰⁷ 1ary, primary; Ab, antibody; ACA, anticentromere antibody; aHUS, atypical hemolytic uremic syndrome; ANA, antinuclear antibody; anti-Scl-70, anti-topoisomerase I antibody; BMT, bone marrow transplant; CMV, cytomegalovirus; DGKE, diacylglycerol kinase ϵ ; EBV, Epstein-Barr virus; ESRD, end-stage renal disease; FACS, flow cytometry; Hb, hemoglobin; Hep, hepatitis; HUS, hemolytic uremic syndrome; LDH, lactate dehydrogenase; MAHA, microangiopathic hemolytic anemia; MLPA, multiplex ligation-dependent probe amplification; PCR, polymerase chain reaction; Plts, platelets; STEC-HUS, Shiga toxin *E. coli* HUS; Stx, Shiga toxin; TMA, thrombotic microangiopathy; TTP, thrombotic thrombocytopenic purpura.

partial lipodystrophy is most commonly seen in individuals with C3 nephritic factors. Factor D, required for formation of the C3 convertase, is highly expressed in adipocytes, which undergo C3 nephritic factor-induced complement-dependent lysis.²⁷ Drusen, the accumulation of lipids and complement-rich proteins between Bruch's membrane and the retinal pigment epithelium, are commonly seen in age-related macular degeneration but occur at an earlier age in C3G.²⁸

Laboratory investigations

Once routine biochemical and hematological analysis has demonstrated a TMA, investigations should focus on determining the underlying etiology and excluding other diagnoses (Supplementary Table S2, Figure 1). The most urgent requirement is to measure ADAMTS13 activity to diagnose or exclude thrombotic thrombocytopenic purpura. Because the incidence of thrombotic thrombocytopenic purpura is much lower in children than in adults, expert opinion recommends that in children, treatment with eculizumab should not be delayed while ADAMTS13 activity is being determined;

however, signs of nonresponse should be carefully monitored. By contrast, in adults, measuring ADAMTS13 activity is recommended prior to eculizumab initiation. Investigation for STEC-HUS should be routine in all patients with presumed aHUS, as approximately 5% of STEC-HUS cases have no prodromal diarrhea, whereas 30% of complement-mediated aHUS cases have concurrent diarrhea or gastroenteritis (Figure 1).²⁹

Complement investigations of aHUS and C3G

Serum or plasma levels of complement proteins should be measured in all patients with primary aHUS and C3G prior to plasma therapy. C3 levels will be low in 30% to 50% of aHUS cases and up to 75% of C3G cases.^{9,17} Low C3 levels are also seen in the acute phase of STEC-HUS and pneumococcal aHUS.¹¹ CD46 surface expression should be evaluated by flow cytometry for suspected aHUS. Complement functional assays and activation markers can also be obtained. The clinical interpretation of these tests requires further study.³⁰ (Supplementary Table S3).

GENETIC DRIVERS OF DISEASE

aHUS

Studies of hundreds of patients with aHUS have provided an excellent understanding of genetic drivers of disease and have informed genotype–phenotype correlations that predict progression of disease, response to therapy, and the risk of recurrence after transplantation. This level of understanding supports an individualized approach to patient management and treatment based on expert interpretation of genetic profiles, and mandates genetic screening and molecular diagnostics in every patient. Delays in obtaining results from genetic or molecular diagnostic studies should not prevent a clinical diagnosis or postpone treatment, as early anti-complement treatment is crucial to preserve renal function and avoid irreversible sequelae.³¹

C3G

Our understanding of the genetics of C3G is not yet comparable to that of aHUS, and more data are required to inform genotype–phenotype correlations. This knowledge gap can be addressed by screening large numbers of patients with C3G, studying the effects of disease-associated variants on function, and correlating these data with clinical outcomes (Supplementary Table S4).^{32–35}

There is no clear benefit to performing genetic analysis in every case of C3G, however genetic results may assist in treatment decisions (i.e., anti-complement therapy vs. immunosuppression) and should be undertaken in familial cases and when there is suspicion of a genetic defect.^{36–40}

Genetic testing

The minimum set of genes that should be screened in aHUS and C3G includes *CFH*, *CD46*, *CFI*, *C3*, *CFB*, *THBD*, *CFHR1*, *CFHR5*, and *DGKE*.^{41–46} Because of the frequent concurrence of genetic risk factors in aHUS, this analysis should also include genotyping for the risk haplotypes *CFH-H3* and *MCP_{ggaac}*.⁴⁷ Genetic analyses must include suitable technologies to detect copy number variation, hybrid genes, and other complex genomic rearrangements in the *CFH/CFHRs* genomic region.^{48–53}

The identification of a pathogenic genetic variant in a patient with aHUS reinforces the diagnosis and establishes with accuracy the cause of the disease, facilitating patient management, effective treatment, and genetic counseling. In C3G, however, present knowledge is insufficient except in cases of *CFHR* rearrangements leading to fusion genes (such as *CFHR5* nephropathy), FH or FI deficiency, or with *C3* mutations.^{36–40,54,55}

Genetic analysis is essential in living-related kidney donor transplantation.⁵⁶ The general recommendation in aHUS is that transplantation from living-related kidney donors should only be considered if causative genetic (or acquired) factors are clearly identified in the recipient and the related donor is free of these factors. In this setting, the presence in the donor of *CFH* or *MCP* aHUS risk haplotypes is not a contraindication to donation.

In C3G, we recommend that all planned recipients of a living-related kidney be screened and if a genetic abnormality is found, the donor should be tested to exclude that genetic abnormality. If the donor is found to carry the same genetic abnormality as the recipient, current evidence would suggest that while this finding may not constitute an absolute contraindication to donation, each case should be evaluated on an individual basis by experts in this area, taking into account the family history and specific genetic abnormality. The theoretical risks that donation may trigger disease onset must be discussed with the donor.

Genetic testing is recommended for patients in whom discontinuation of anticomplement therapies is being considered.

Understanding genetic variants. Genetic variants should be classified as benign, likely benign, variant of uncertain significance, likely pathogenic, or pathogenic following international guidelines.⁵⁷

In aHUS, pathogenic variants specifically impair the capacity to protect host endothelial cells and platelets from complement damage or activation.^{58–67} It is clear that the combination of different pathogenic variants and/or the combination of pathogenic variants and common risk variants in *CFH* and *MCP* determine overall individual risk/predisposition to aHUS.^{14,15,43,47,68–71} Genetic makeup also influences disease progression, response to therapies, and recurrence after transplantation (Supplementary Table S5).^{56,72,73}

C3G, in contrast, appears mechanistically more complex than aHUS, with massive C3 activation in plasma and complement dysregulation on surfaces, including the glycocalyx overlying the glomerular endothelial pores.^{2,17,38,51,55,74–78} We have limited information about genotype–phenotype correlations to distinguish different C3G subtypes, inform prognosis, and/or recommend treatment.

It is highly recommended that genetic results be interpreted by a laboratory with expertise in aHUS and C3G (Supplementary Tables S6 and S7).

ACQUIRED DRIVERS OF DISEASE

aHUS

In aHUS, the best studied are FH autoantibodies, which are typically associated with homozygosity for *delCFHR3-CFHR1*. Positive results should be confirmed in a second sample at least 4 weeks after the initial sample. Testing should also be performed in the prerenal transplant period. In pediatric patients, FH autoantibody assays should be performed following consensus guidelines: at diagnosis and, if positive, at days 7, 14, and 28, monthly, and at 1 year.¹¹ Relapses of anti-FH-associated HUS occur in about 20% to 25% of patients.

C3G

In C3G, C3 nephritic factors, FH autoantibodies and, in older adults, free light chains should be assayed (Supplementary Table S8). The results of autoantibody assays require expert interpretation, with their relevance to disease interpreted in

the context of the results for all other complement assays and genetic screens.

TREATMENT STRATEGIES

aHUS

All patients with a clinical diagnosis of primary aHUS are eligible for treatment with a complement inhibitor (Supplementary Table S9). The dosing schedule reported in the trials is recommended, although 2 options for altered dosing have been considered: (i) the minimal dose required to achieve complement blockade; and (ii) a discontinuation dosing schedule.⁷⁹ No data exist to support either option, and both require monitoring of complement activity (Table 3). The treatment of FH autoantibody-driven aHUS involves the use of anticellular therapy and is guided by antibody titer (Figure 2). Interruption of anticomplement therapy during intercurrent illness, a time of high-risk for aHUS relapse, is not recommended unless an infection with an encapsulated organism is suspected or documented.

If access to eculizumab is unavailable, plasma therapy can be used. Plasma exchange should also be considered for anti-FH-positive aHUS and in the emergency treatment of critically ill patients with severe TMA (e.g., coma or convulsions) and a strong presumption of TTP until evidence of residual ADAMTS13 activity exceeds 10%.⁸⁰ The use of plasma exchange when eculizumab is available may be associated

with some improvement, but there is a risk that delaying the onset of eculizumab may lead to a suboptimal therapeutic outcome.

Treatment duration is controversial, and to date there is no evidence to support lifelong therapy in all aHUS patients. Discontinuation of plasma therapy or complement inhibition is feasible at least in some patients with aHUS. The consensus favored a minimal period of treatment to allow optimal renal recovery without early relapse (Figure 3). Prospective studies are crucial to assess parameters predictive of relapse and to define how genetics, quality of renal recovery, age, presence or absence of a triggering event, and biomarkers related to complement activation and/or endothelial cell injury inform this decision.

Eculizumab increases the risk of meningococcal infection.¹¹ Patients should receive vaccination against meningococcus, including type B; however, vaccination should not delay the start of eculizumab. Antibiotic prophylaxis is mandated during the first 2 weeks. Controversy remains as to whether vaccination is efficacious in patients with acute kidney injury, chronic kidney disease, and/or during immunosuppression. It is unknown whether antimeningococcal antibodies are protective in the setting of complement blockade; therefore, it is recommended that antibiotic prophylaxis be maintained for the treatment duration and up to 2 to 3 months after discontinuation.

Table 3 | Monitoring eculizumab therapy

CH50 (Total complement activity)	<p>Description</p> <ul style="list-style-type: none"> Measures the combined activity of all of the complement pathways Tests the functional capability of serum complement components to lyse 50% of sheep erythrocytes in a reaction mixture Will be low in congenital complement deficiency (C1–8) or during complement blockade Normal range is assay dependent <p>Recommended goal during therapeutic complement blockade</p> <ul style="list-style-type: none"> <10% of normal
AH50 (Alternative pathway hemolytic activity)	<p>Description</p> <ul style="list-style-type: none"> Measures the combined activity of the alternative and terminal complement pathways Tests the functional capability of alternate or terminal pathway complement components to lyse 50% of rabbit erythrocytes in a Mg²⁺-EGTA buffer Will be low in congenital C3, FI, FB, properdin, FH, and FD deficiencies or during terminal complement blockade Normal range is assay dependent <p>Recommended goal during therapeutic complement blockade</p> <ul style="list-style-type: none"> <10% of normal
Eculizumab trough	<p>Description</p> <ul style="list-style-type: none"> May be a free or bound level ELISA-based assay using C5 coated plates, patient sera, and an anti-human IgG detection system Not affected by complement deficiencies <p>Recommended trough level during therapeutic complement blockade</p> <ul style="list-style-type: none"> 50–100 µg/ml <p>The following assays are under investigation (or awaiting to be replicated in different laboratories)⁶² as a means to monitor therapeutic complement blockade</p> <ul style="list-style-type: none"> Free C5 <i>In vitro</i> human microvascular endothelial cell test⁶² sC5b-9 (also referred to as sMAC and TCC) may remain detectable in aHUS patients in remission and therefore is not recommended as a monitoring tool
Alternative assays	

aHUS, atypical hemolytic uremic syndrome; C3, complement component 3; C5, complement component 5; EGTA, ethyleneglycol tetraacetic acid; ELISA, enzyme-linked immunosorbent assay; FB, complement factor B; FD, complement factor D; FH, complement factor H; FI, complement factor I; sC5b-9, soluble C5b-9; sMAC, soluble membrane attack complex; TCC, terminal complement complex.

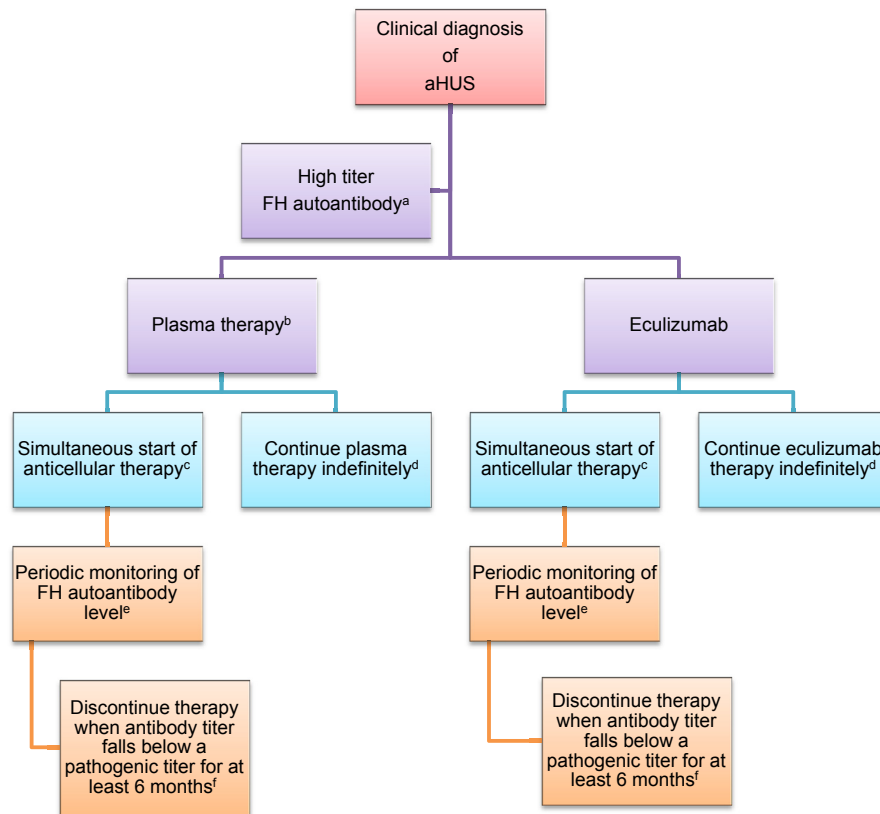


Figure 2 | Treatment of complement factor H autoantibody-mediated aHUS. There are no prospective controlled studies in patients with atypical hemolytic uremic syndrome (aHUS) due to anti-factor H protein (FH) antibodies, and thus the proposed management is based on a pediatric consensus.¹¹

^aAbnormal titer depends on the testing laboratory.

^bThe decision to use plasma therapy versus eculizumab will be based on patient age and local resource availability.

^cCyclophosphamide, rituximab, or mycophenolate mofetil.

^dThe decision to continue anticomplement therapy indefinitely is not informed by data.

^eThe interval may be monthly or quarterly and is based on local resources.

^fThis recommendation is based on limited retrospective case reviews.^{108–110}

Documentation of increased complement activity^{11,31,79,81,82} in the setting of aHUS after an external trigger suggests clinical benefit of complement blockade especially in the setting of severe sequelae.^{17,77,83} However, in the absence of trial data, complement inhibition in these forms of aHUS remains controversial.

Transplant. Kidney transplantation should be delayed until at least 6 months after the start of dialysis because limited renal recovery may occur several months after starting eculizumab.^{82,84} The resolution of hematological TMA features and extrarenal manifestations is a prerequisite for transplantation. The decision to use anticomplement therapy during transplantation should be based on recurrence risk (Table 4).

Living-related kidney donation carries a risk for recurrence in the recipient and a risk of *de novo* disease in the donor should the donor carry an at-risk genetic variant.⁸¹ Potential donors with evidence of abnormal alternative complement pathway activity should be excluded. If the potential living-related donor does not carry a pathogenic variant in a

complement gene and has no evidence of abnormal complement activation, donation is feasible.³¹

Liver transplant remains an option in patients with liver-derived complement protein abnormalities, in particular for renal transplant recipients with uncontrolled disease activity despite eculizumab therapy.⁸⁵

C3G

A single randomized controlled trial using steroid as monotherapy in mesangiocapillary GN⁸³ has been published. Given the change in terminology and disease characterization and the potential confounding effect on trial stratification, the results of this trial are of limited use in guiding current treatment considerations for C3G. A retrospective study supports the effectiveness of mycophenolate mofetil in a select group.⁸⁶ Outlined here is a tiered approach to treatment based primarily on expert opinion, with limited support from retrospective cohort studies^{87–103} (Table 5). In the absence of more specific data, monitoring of anticomplement therapy should be similar to that used in aHUS (Table 3).

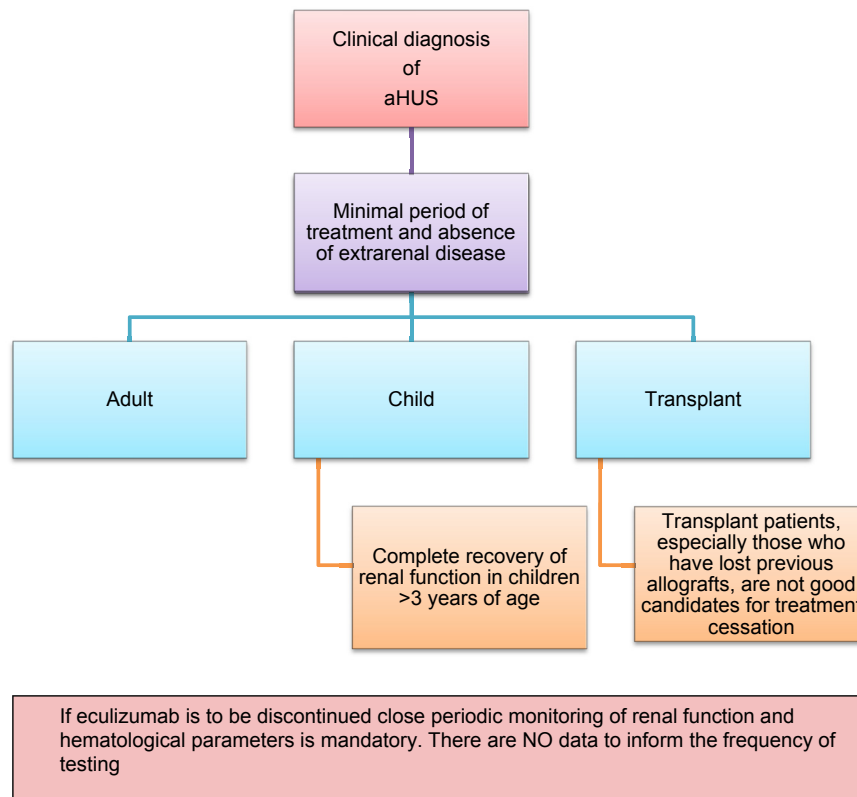


Figure 3 | Recommendations for cessation of treatment with complement inhibitors. There are no prospective controlled studies in patients with atypical hemolytic uremic syndrome (aHUS) to define criteria for discontinuation of eculizumab therapy. This flow diagram is based on expert opinion.^{111–114} Discontinuation can be considered on a case-by-case basis in patients after at least 6 to 12 months of treatment and at least 3 months of normalization (or stabilization in the case of residual chronic kidney disease) of kidney function. Earlier cessation (at 3 months) may be considered in patients (especially children) with pathogenic variants in *MCP* if there has been rapid remission and recovery of renal function. In patients who have undergone dialysis, eculizumab should be maintained for at least 4 to 6 months before considering discontinuation. In this setting, the assessment of fibrotic changes in the kidney using a biopsy may be helpful. In patients who have undergone transplant, especially patients who have lost previous allografts, discontinuation is not recommended.

No specific recommendation can be made for plasma therapy or rituximab (an anti-CD20 antibody). The conference attendees acknowledged published reports that support the effectiveness of plasma therapy in the setting of C3G induced specifically by pathogenic variants in factor H; however, this approach appears to be beneficial to only a select subgroup of patients with C3G.⁷⁷

Transplant. No specific data are available to inform decisions surrounding transplantation in C3G. Recommendations reflect expert opinion and limited case reports (Supplementary Table S10). C3G recurs in allografts at a high rate, leading to graft loss in approximately 50% of patients.

RESEARCH RECOMMENDATIONS

We believe a cross-disciplinary approach should be undertaken for the recommendations listed below. This should include combining pathology, clinical phenotyping, genetics, and therapy prospectively using scoring systems such as the MEST score in IgA nephropathy.¹⁰⁴

Renal pathology

aHUS. A comparative study of biopsies from patients with well-documented malignant hypertension and patients

with well-documented alternative complement pathway disease is required to identify morphological and/or immunohistochemical features that may distinguish between these groups. A longitudinal study of patients with features of chronic microangiopathy on biopsy but without a history of acute presentation is needed to define associations with clinical features, etiology, and outcome.

C3G. A comprehensive study is needed to define the relationship of morphology to etiology, clinical course, and response to therapy, which would be best achieved by a multicenter collection of well-annotated cases, analyzed by a group of renal pathologists in a manner similar to that used for the Oxford classification of IgA nephropathy.^{105,106} The study should include: light microscopy with histologic markers of activity and chronicity; IF, including routine studies together with staining for C3 fragments and other complement proteins; and EM, including objective assessment of deposit density, quantity, and distribution.

Clinical phenotype and evaluation of aHUS and C3G

A consensus on the terminology covering TMAs and aHUS should be sought as more information concerning their pathogenesis becomes available.

Table 4 | Prophylaxis against aHUS recurrence in allografts based on a risk-assessment strategy^a

Recurrence risk	Treatment regimen
High risk (50-100%) <ul style="list-style-type: none"> • Previous early recurrence • Pathogenic mutation^a • Gain-of-function mutation 	Prophylactic eculizumab ^{b,c} Note: Start on the day of transplantation due to potential for severe recurrence and limited recovery of function in renal grafts compared with native kidneys
Moderate risk <ul style="list-style-type: none"> • No mutation identified • Isolated <i>CFI</i> mutations • Complement gene mutation of unknown significance • Persistent low titer FH autoantibody 	Prophylactic eculizumab or plasma exchange ^d
Low risk (<10%) <ul style="list-style-type: none"> • Isolated <i>MCP</i> mutations • Persistently negative FH autoantibodies 	No prophylaxis

aHUS, atypical hemolytic uremic syndrome; CFI, complement factor I gene; FH, complement factor H protein; MCP, membrane cofactor protein gene.

^aRequires complete screening of all genes implicated in aHUS.

^bProphylactic regimens are based on local center protocols; no trial data exist to support superiority of 1 protocol over another.

^cLiver transplantation can be considered for renal transplant recipients with liver-derived complement protein abnormalities, uncontrolled disease activity despite eculizumab therapy, or financial considerations regarding cost of long-term eculizumab therapy.

^dThe decision to perform or not to perform prophylactic plasma exchange or complement inhibition is left to the discretion of the clinician.

Clinical studies are required to define how complement biomarkers correlate with current or impending aHUS relapse and/or renal involvement, to identify risk factors for aHUS relapse upon cessation of anti-complement therapy, to identify alternative anticomplement therapeutics for aHUS, to assess the value of proximal (at the level of the alternative pathway) anticomplement therapy in C3G, and to determine whether complement biomarkers can inform clinical outcome in C3G patients.

Genetic and acquired drivers of disease

Genetic testing should be undertaken in all persons with suspected primary aHUS, although in cases of secondary aHUS, the role of genetic testing must be clarified. Exceptions include *de novo* posttransplant aHUS and pregnancy-associated aHUS, both of which require genetic testing.

In C3G, except for particular cases, present knowledge is insufficient to establish robust phenotype–genotype correlations. Comprehensive genetic testing is required to fill this knowledge gap.

The impact of acquired autoantibodies such as C3 nephritic factor and FH autoantibody must be followed in longitudinal studies to define their relevance to disease course in the context of the results of all other complement assays and genetic screening.

Table 5 | Recommended treatment approach for C3G^a

All patients <ul style="list-style-type: none"> • Optimal blood pressure control (suggested blood pressure below the 90% in children and ≤120/80 mm Hg in adults) <ul style="list-style-type: none"> ◦ Priority agents include angiotensin converting enzyme inhibitors and angiotensin receptor blockers • Optimal nutrition for both normal growth in children and healthy weight in adults • Lipid control
Moderate disease <p>Description</p> <ul style="list-style-type: none"> • Urine protein over 500 mg/24 h despite supportive therapy <p>or</p> <ul style="list-style-type: none"> • Moderate inflammation on renal biopsy <p>or</p> <ul style="list-style-type: none"> • Recent increase in serum creatinine suggesting risk for progressive disease <p>Recommendation</p> <ul style="list-style-type: none"> • Prednisone • Mycophenolate mofetil
Severe disease <p>Description</p> <ul style="list-style-type: none"> • Urine protein over 2000 mg/24 h despite immunosuppression and supportive therapy <p>or</p> <ul style="list-style-type: none"> • Severe inflammation represented by marked endo- or extracapillary proliferation with or without crescent formation despite immunosuppression and supportive therapy <p>or</p> <ul style="list-style-type: none"> • Increased serum creatinine suggesting risk for progressive disease at onset despite immunosuppression and supportive therapy <p>Recommendation</p> <ul style="list-style-type: none"> • Methylprednisolone pulse dosing as well as other anti-cellular immune suppressants have had limited success in rapidly progressive disease • Data are insufficient to recommend eculizumab as a first-line agent for the treatment of rapidly progressive disease

C3G, C3 glomerulopathy.

^aBased on a single, small prospective trial, case reports, and expert opinion.

In patients with aHUS and C3G in whom neither genetic nor acquired drivers of disease are identified, concerted efforts should be made to elucidate disease triggers.

Treatment and clinical trial strategies for aHUS and C3G

Despite remarkable advances in our understanding of the underlying pathological mechanisms involved in C3G and aHUS, much remains to learn about treatment. Because eculizumab has altered the natural history of aHUS, controversy has arisen in several areas of treatment. Dosing schedule and treatment duration remain controversial and should be rigorously studied.

The treatment of C3G has not been studied thoroughly. In the absence of trial data, retrospective reviews, case studies, and expert opinion inform the current approach to C3G treatment. The development and trial of complement inhibitors as therapeutic interventions for C3G is a high priority. For the purposes of selecting patients for clinical trials, the conference participants felt that only a single phenotypic parameter

warranted consideration: the EM designation as either DDD or C3GN. While data demonstrating that EM will predict treatment response to current therapeutic options are lacking, limited retrospective studies suggest that there is a difference in renal survival between the 2 groups.¹⁷

Although stratification based on sC5b-9 appears appealing,⁸⁸ particularly when considering terminal complement blockade therapeutics, there is a paucity of data to support the reliability of this assay as a true marker of disease pathology. There is also insufficient evidence to support stratification according to C5b-9 staining of renal biopsy tissue. The conference participants believed there was sufficient evidence in other glomerular diseases to exclude patients from C3G trials if they were stable on prior supportive therapy or immune suppression after a 3-month period, had rapidly progressive disease, or had more than 25% sclerosis on renal biopsy.

CONCLUSION

In this report, we document the proceedings of a KDIGO Controversies Conference on the management of aHUS and C3G. We have made recommendations pertinent to the diagnosis and treatment of patients with these 2 diseases based on current expert opinion practices. In addition, we have identified knowledge gaps and offered suggestions for future research. While there are knowledge gaps in both diseases, it is clear that the evidence base for the management of patients with C3G lags behind that of aHUS, and addressing this disparity should be a priority. Though we have presented these 2 diseases as distinct entities, it is clear that there is substantial overlap not only in the pathogenesis but also in the clinical presentation such that some patients may show features of both. This should not be overlooked.

DISCLOSURE

THJG declared that his employer (Newcastle University) has received consultancy fees on his behalf from Akari Therapeutics and Alexion. HTC declared having received consultancy fees from Achillion and speaker honoraria from Alexion. FF declared having received consultancy fees and speaker honoraria from Alexion. VFB declared having received consultancy fees from Alexion. DK declared having equity ownership/stock options on Gyroscope Therapeutics and received research support from Fight for Sight, Kidney Research UK, Macular Society, Medical Research Council, Northern Counties Kidney Research Fund, and Wellcome Trust. CMN declared having received consultancy fees from Achillion and royalties from UpToDate. MN declared having received consultancy fees from Alexion and Novartis. MCP declared having received consultancy fees from Achillion and research support from Alexion. SRdC declared having received speaker honoraria from Alexion. LTR declared having received research support from CSL Behring. All the other authors declared no competing interests.

The conference was sponsored by Kidney Disease: Improving Global Outcomes (KDIGO) and supported in part by unrestricted educational grants from Achillion Pharmaceuticals, Akari Therapeutics, Alexion Pharmaceuticals, and Omeros.

SUPPLEMENTARY MATERIAL

Table S1. Extrarenal manifestations reported in aHUS, DDD, and C3GN.

Table S2. Investigations recommended for TMA.

Table S3. Complement studies for aHUS and C3G.

Table S4. Genetic drivers in aHUS and C3G.

Table S5. Genotype-phenotype correlations in aHUS.

Table S6. Categorization of the genetic variants.

Table S7. Complement assays that should be considered in addition to genetic screening in aHUS and C3G.

Table S8. Acquired drivers of disease in aHUS and C3G: screening recommendations.

Table S9. Eculizumab dosing in aHUS based on dosing goal.

Table S10. Transplant considerations in C3G.

Supplementary material is linked to the online version of the paper at www.kidney-international.org.

REFERENCES

1. Chua JS, Baelde HJ, Zandbergen M, et al. Complement factor C4d is a common denominator in thrombotic microangiopathy. *J Am Soc Nephrol.* 2015;26:2239–2247.
2. Pickering MC, D'Agati VD, Nester CM, et al. C3 glomerulopathy: consensus report. *Kidney Int.* 2013;84:1079–1089.
3. Hou J, Markowitz GS, Bomback AS, et al. Toward a working definition of C3 glomerulopathy by immunofluorescence. *Kidney Int.* 2014;85:450–456.
4. Larsen CP, Ambuzs JM, Bonsib SM, et al. Membranous-like glomerulopathy with masked IgG kappa deposits. *Kidney Int.* 2014;86:154–161.
5. Larsen CP, Messias NC, Walker PD, et al. Membranoproliferative glomerulonephritis with masked monotypic immunoglobulin deposits. *Kidney Int.* 2015;88:867–873.
6. Cook HT. C4d staining in the diagnosis of C3 glomerulopathy. *J Am Soc Nephrol.* 2015;26:2609–2611.
7. Sethi S, Nasr SH, De Vriese AS, et al. C4d as a diagnostic tool in proliferative GN. *J Am Soc Nephrol.* 2015;26:2852–2859.
8. West CD, Witte DP, McAdams AJ. Composition of nephritic factor-generated glomerular deposits in membranoproliferative glomerulonephritis type 2. *Am J Kidney Dis.* 2001;37:1120–1130.
9. Sethi S, Fervenza FC, Zhang Y, et al. C3 glomerulonephritis: clinicopathological findings, complement abnormalities, glomerular proteomic profile, treatment, and follow-up. *Kidney Int.* 2012;82:465–473.
10. Sethi S, Gamez JD, Vrana JA, et al. Glomeruli of Dense Deposit Disease contain components of the alternative and terminal complement pathway. *Kidney Int.* 2009;75:952–960.
11. Loirat C, Fakhouri F, Ariceta G, et al. An international consensus approach to the management of atypical hemolytic uremic syndrome in children. *Pediatr Nephrol.* 2016;31:15–39.
12. Caprioli J, Noris M, Brioschi S, et al. Genetics of HUS: the impact of MCP, CFH, and IF mutations on clinical presentation, response to treatment, and outcome. *Blood.* 2006;108:1267–1279.
13. Kavanagh D, Goodship TH, Richards A. Atypical hemolytic uremic syndrome. *Semin Nephrol.* 2013;33:508–530.
14. Sansbury FH, Cordell HJ, Bingham C, et al. Factors determining penetrance in familial atypical haemolytic uraemic syndrome. *J Med Genet.* 2014;51:756–764.
15. Bresin E, Rurai E, Caprioli J, et al. Combined complement gene mutations in atypical hemolytic uremic syndrome influence clinical phenotype. *J Am Soc Nephrol.* 2013;24:475–486.
16. Noris M, Remuzzi G. Hemolytic uremic syndrome. *J Am Soc Nephrol.* 2005;16:1035–1050.
17. Servais A, Noel LH, Roumenina LT, et al. Acquired and genetic complement abnormalities play a critical role in dense deposit disease and other C3 glomerulopathies. *Kidney Int.* 2012;82:454–464.
18. Fervenza FC, Smith RJ, Sethi S. Association of a novel complement factor H mutation with severe crescentic and necrotizing glomerulonephritis. *Am J Kidney Dis.* 2012;60:126–132.
19. Sandhu G, Bansal A, Ranade A, et al. C3 glomerulopathy masquerading as acute postinfectious glomerulonephritis. *Am J Kidney Dis.* 2012;60:1039–1043.
20. Vernon KA, Goicoechea de Jorge E, Hall AE, et al. Acute presentation and persistent glomerulonephritis following streptococcal infection in a patient with heterozygous complement factor H-related protein 5 deficiency. *Am J Kidney Dis.* 2012;60:121–125.

21. Yu Y, Triebwasser MP, Wong EK, et al. Whole-exome sequencing identifies rare, functional CFH variants in families with macular degeneration. *Hum Mol Genet.* 2014;23:5283–5293.
22. Kavanagh D, Yu Y, Schramm EC, et al. Rare genetic variants in the CFI gene are associated with advanced age-related macular degeneration and commonly result in reduced serum factor I levels. *Hum Mol Genet.* 2015;24:3861–3870.
23. Recalde S, Tortajada A, Subias M, et al. Molecular Basis of Factor H R1210C Association with Ocular and Renal Diseases. *J Am Soc Nephrol.* 2016;27:1305–1311.
24. Misra A, Peethambaram A, Garg A. Clinical features and metabolic and autoimmune derangements in acquired partial lipodystrophy: report of 35 cases and review of the literature. *Medicine (Baltimore).* 2004;83:18–34.
25. Dalvin LA, Ferverza FC, Sethi S, Pulido JS. Shedding light on fundus drusen associated with membranoproliferative glomerulonephritis: breaking stereotypes of types I, II, and III. *Retin Cases Brief Rep.* 2016;10:72–78.
26. Duvall-Young J, MacDonald MK, McKechnie NM. Fundus changes in (type II) mesangiocapillary glomerulonephritis simulating drusen: a histopathological report. *Br J Ophthalmol.* 1989;73:297–302.
27. Mathieson PW, Wurzner R, Oliveria DB, et al. Complement-mediated adipocyte lysis by nephritic factor sera. *J Exp Med.* 1993;177:1827–1831.
28. Fritsche LG, Chen W, Schu M, et al. Seven new loci associated with age-related macular degeneration. *Nat Genet.* 2013;45:433–439.
29. Gerber A, Karch H, Allerberger F, et al. Clinical course and the role of shiga toxin-producing *Escherichia coli* infection in the hemolytic-uremic syndrome in pediatric patients, 1997–2000, in Germany and Austria: a prospective study. *J Infect Dis.* 2002;186:493–500.
30. Angioi A, Ferverza FC, Sethi S, et al. Diagnosis of complement alternative pathway disorders. *Kidney Int.* 2016;89:278–288.
31. Zuber J, Fakhouri F, Roumenina LT, et al. Use of eculizumab for atypical haemolytic uraemic syndrome and C3 glomerulopathies. *Nat Rev Nephrol.* 2012;8:643–657.
32. Bu F, Borsa NG, Jones MB, et al. High-Throughput genetic testing for thrombotic microangiopathies and C3 glomerulopathies. *J Am Soc Nephrol.* 2016;27:1245–1253.
33. de Cordoba SR. Complement genetics and susceptibility to inflammatory disease. Lessons from genotype-phenotype correlations. *Immunobiology.* 2016;221:709–714.
34. Noris M, Brioschi S, Caprioli J, et al. Familial haemolytic uraemic syndrome and an MCP mutation. *Lancet.* 2003;362:1542–1547.
35. Richards A, Kemp EJ, Liszewski MK, et al. Mutations in human complement regulator, membrane cofactor protein (CD46), predispose to development of familial hemolytic uremic syndrome. *Proc Natl Acad Sci U S A.* 2003;100:12966–12971.
36. Ault BH, Schmidt BZ, Fowler NL, et al. Human factor H deficiency. Mutations in framework cysteine residues and block in H protein secretion and intracellular catabolism. *J Biol Chem.* 1997;272:25168–25175.
37. Levy M, Halbwachs-Mecarelli L, Gubler MC, et al. H deficiency in two brothers with atypical dense intramembranous deposit disease. *Kidney Int.* 1986;30:949–956.
38. Martinez-Barricarte R, Heurich M, Valdes-Canedo F, et al. Human C3 mutation reveals a mechanism of dense deposit disease pathogenesis and provides insights into complement activation and regulation. *J Clin Invest.* 2010;120:3702–3712.
39. Montes T, Goicoechea de Jorge E, Ramos R, et al. Genetic deficiency of complement factor H in a patient with age-related macular degeneration and membranoproliferative glomerulonephritis. *Mol Immunol.* 2008;45:2897–2904.
40. Schejbel L, Schmidt IM, Kirchoff M, et al. Complement factor H deficiency and endocapillary glomerulonephritis due to paternal isodisomy and a novel factor H mutation. *Genes Immun.* 2011;12:90–99.
41. Abarrategui-Garrido C, Martinez-Barricarte R, Lopez-Trascasa M, et al. Characterization of complement factor H-related (CFHR) proteins in plasma reveals novel genetic variations of CFHR1 associated with atypical hemolytic uremic syndrome. *Blood.* 2009;114:4261–4271.
42. Delvaeye M, Noris M, De Vriese A, et al. Thrombomodulin mutations in atypical hemolytic-uremic syndrome. *N Engl J Med.* 2009;361:345–357.
43. Fremeaux-Bacchi V, Fakhouri F, Garnier A, et al. Genetics and outcome of atypical hemolytic uremic syndrome: a nationwide French series comparing children and adults. *Clin J Am Soc Nephrol.* 2013;8:554–562.
44. Lemaire M, Fremeaux-Bacchi V, Schaefer F, et al. Recessive mutations in DGKE cause atypical hemolytic-uremic syndrome. *Nat Genet.* 2013;45:531–536.
45. Maga TK, Nishimura CJ, Weaver AE, et al. Mutations in alternative pathway complement proteins in American patients with atypical hemolytic uremic syndrome. *Hum Mutat.* 2010;31:E1445–E1460.
46. Noris M, Remuzzi G. Atypical hemolytic-uremic syndrome. *N Engl J Med.* 2009;361:1676–1687.
47. Esparza-Gordillo J, Goicoechea de Jorge E, Buil A, et al. Predisposition to atypical hemolytic uremic syndrome involves the concurrence of different susceptibility alleles in the regulators of complement activation gene cluster in 1q32. *Hum Mol Genet.* 2005;14:703–712.
48. Challis RC, Araujo GS, Wong EK, et al. A de novo deletion in the regulators of complement activation cluster producing a hybrid complement factor H/complement factor H-related 3 gene in atypical hemolytic uremic syndrome. *J Am Soc Nephrol.* 2016;27:1617–1624.
49. Chen Q, Wiesener M, Eberhardt HU, et al. Complement factor H-related hybrid protein deregulates complement in dense deposit disease. *J Clin Invest.* 2014;124:145–155.
50. Gale DP, de Jorge EG, Cook HT, et al. Identification of a mutation in complement factor H-related protein 5 in patients of Cypriot origin with glomerulonephritis. *Lancet.* 2010;376:794–801.
51. Tortajada A, Yebenes H, Abarrategui-Garrido C, et al. C3 glomerulopathy-associated CFHR1 mutation alters FHR oligomerization and complement regulation. *J Clin Invest.* 2013;123:2434–2446.
52. Valoti E, Alberti M, Tortajada A, et al. A novel atypical hemolytic uremic syndrome-associated hybrid CFHR1/CFH gene encoding a fusion protein that antagonizes factor H-dependent complement regulation. *J Am Soc Nephrol.* 2015;26:209–219.
53. Venables JP, Strain L, Routledge D, et al. Atypical haemolytic uraemic syndrome associated with a hybrid complement gene. *PLoS Med.* 2006;3:e431.
54. Athanasiou Y, Voskarides K, Gale DP, et al. Familial C3 glomerulopathy associated with CFHR5 mutations: clinical characteristics of 91 patients in 16 pedigrees. *Clin J Am Soc Nephrol.* 2011;6:1436–1446.
55. Chauvet S, Roumenina LT, Bruneau S, et al. A familial C3GN secondary to defective C3 regulation by complement receptor 1 and factor H. *J Am Soc Nephrol.* 2016;27:1665–1677.
56. Noris M, Remuzzi G. Managing and preventing atypical hemolytic uremic syndrome recurrence after kidney transplantation. *Curr Opin Nephrol Hypertens.* 2013;22:704–712.
57. Richards S, Aziz N, Bale S, et al. Standards and guidelines for the interpretation of sequence variants: a joint consensus recommendation of the American College of Medical Genetics and Genomics and the Association for Molecular Pathology. *Genet Med.* 2015;17:405–424.
58. Frimat M, Tabarin F, Dimitrov JD, et al. Complement activation by heme as a secondary hit for atypical hemolytic uremic syndrome. *Blood.* 2013;122:282–292.
59. Goicoechea de Jorge E, Harris CL, Esparza-Gordillo J, et al. Gain-of-function mutations in complement factor B are associated with atypical hemolytic uremic syndrome. *Proc Natl Acad Sci U S A.* 2007;104:240–245.
60. Manuclian T, Hellwege J, Meri S, et al. Mutations in factor H reduce binding affinity to C3b and heparin and surface attachment to endothelial cells in hemolytic uremic syndrome. *J Clin Invest.* 2003;111:1181–1190.
61. Marinozzi MC, Vergoz L, Rybkine T, et al. Complement factor B mutations in atypical hemolytic uremic syndrome—disease-relevant or benign? *J Am Soc Nephrol.* 2014;25:2053–2065.
62. Noris M, Galbusera M, Gastoldi S, et al. Dynamics of complement activation in aHUS and how to monitor eculizumab therapy. *Blood.* 2014;124:1715–1726.
63. Perez-Caballero D, Gonzalez-Rubio C, Gallardo ME, et al. Clustering of missense mutations in the C-terminal region of factor H in atypical hemolytic uremic syndrome. *Am J Hum Genet.* 2001;68:478–484.
64. Roumenina LT, Jablonski M, Hue C, et al. Hyperfunctional C3 convertase leads to complement deposition on endothelial cells and contributes to atypical hemolytic uremic syndrome. *Blood.* 2009;114:2837–2845.
65. Sanchez-Corral P, Perez-Caballero D, Huarte O, et al. Structural and functional characterization of factor H mutations associated with

- atypical hemolytic uremic syndrome. *Am J Hum Genet.* 2002;71:1285–1295.
66. Schramm EC, Roumenina LT, Rybkine T, et al. Mapping interactions between complement C3 and regulators using mutations in atypical hemolytic uremic syndrome. *Blood.* 2015;125:2359–2369.
 67. Stahl AL, Vaziri-Sani F, Heinen S, et al. Factor H dysfunction in patients with atypical hemolytic uremic syndrome contributes to complement deposition on platelets and their activation. *Blood.* 2008;111:5307–5315.
 68. Bernabeu-Herrero ME, Jimenez-Alcazar M, Anter J, et al. Complement factor H, FHR-3 and FHR-1 variants associate in an extended haplotype conferring increased risk of atypical hemolytic uremic syndrome. *Mol Immunol.* 2015;67:276–286.
 69. Caprioli J, Castelletti F, Bucchioni S, et al. Complement factor H mutations and gene polymorphisms in haemolytic uraemic syndrome: the C-257T, the A2089G and the G2881T polymorphisms are strongly associated with the disease. *Hum Mol Genet.* 2003;12:3385–3395.
 70. Harris CL, Heurich M, Rodriguez de Cordoba S, et al. The complotype: dictating risk for inflammation and infection. *Trends Immunol.* 2012;33:513–521.
 71. Pickering MC, de Jorge EG, Martinez-Barricarte R, et al. Spontaneous hemolytic uremic syndrome triggered by complement factor H lacking surface recognition domains. *J Exp Med.* 2007;204:1249–1256.
 72. Noris M, Caprioli J, Bresin E, et al. Relative role of genetic complement abnormalities in sporadic and familial aHUS and their impact on clinical phenotype. *Clin J Am Soc Nephrol.* 2010;5:1844–1859.
 73. Sanchez Chinchilla D, Pinto S, Hoppe B, et al. Complement mutations in diacylglycerol kinase-epsilon-associated atypical hemolytic uremic syndrome. *Clin J Am Soc Nephrol.* 2014;9:1611–1619.
 74. Abrera-Abeleda MA, Nishimura C, Frees K, et al. Allelic variants of complement genes associated with dense deposit disease. *J Am Soc Nephrol.* 2011;22:1551–1559.
 75. Barbour TD, Ruseva MM, Pickering MC. Update on C3 glomerulopathy. *Nephrol Dial Transplant.* 2016;31:717–725.
 76. Goicoechea de Jorge E, Caesar JJ, Malik TH, et al. Dimerization of complement factor H-related proteins modulates complement activation in vivo. *Proc Natl Acad Sci U S A.* 2013;110:4685–4690.
 77. Licht C, Heinen S, Jozsi M, et al. Deletion of Lys224 in regulatory domain 4 of Factor H reveals a novel pathomechanism for dense deposit disease (MPGN II). *Kidney Int.* 2006;70:42–50.
 78. Wong EK, Anderson HE, Herbert AP, et al. Characterization of a factor H mutation that perturbs the alternative pathway of complement in a family with membranoproliferative GN. *J Am Soc Nephrol.* 2014;25:2425–2433.
 79. Legendre CM, Licht C, Muus P, et al. Terminal complement inhibitor eculizumab in atypical hemolytic-uremic syndrome. *N Engl J Med.* 2013;368:2169–2181.
 80. Mannucci PM, Cugno M. The complex differential diagnosis between thrombotic thrombocytopenic purpura and the atypical hemolytic uremic syndrome: Laboratory weapons and their impact on treatment choice and monitoring. *Thromb Res.* 2015;136:851–854.
 81. Donne RL, Abbs I, Barany P, et al. Recurrence of hemolytic uremic syndrome after live related renal transplantation associated with subsequent de novo disease in the donor. *Am J Kidney Dis.* 2002;40:E22.
 82. Povey H, Vundru R, Junglee N, et al. Renal recovery with eculizumab in atypical hemolytic uremic syndrome following prolonged dialysis. *Clin Nephrol.* 2014;82:326–331.
 83. Tarshish P, Bernstein J, Tobin JN, et al. Treatment of mesangiocapillary glomerulonephritis with alternate-day prednisone—a report of the International Study of Kidney Disease in Children. *Pediatr Nephrol.* 1992;6:123–130.
 84. Licht C, Greenbaum LA, Muus P, et al. Efficacy and safety of eculizumab in atypical hemolytic uremic syndrome from 2-year extensions of phase 2 studies. *Kidney Int.* 2015;87:1061–1073.
 85. Coppo R, Bonaudo R, Peruzzi RL, et al. Liver transplantation for aHUS: still needed in the eculizumab era? *Pediatr Nephrol.* 2016;31:759–768.
 86. Rabasco C, Cavero T, Roman E, et al. Effectiveness of mycophenolate mofetil in C3 glomerulonephritis. *Kidney Int.* 2015;88:1153–1160.
 87. Besbas N, Gulhan B, Gucer S, et al. A novel CFHR5 mutation associated with C3 glomerulonephritis in a Turkish girl. *J Nephrol.* 2014;27:457–460.
 88. Bomback AS, Smith RJ, Barile GR, et al. Eculizumab for dense deposit disease and C3 glomerulonephritis. *Clin J Am Soc Nephrol.* 2012;7:748–756.
 89. Bonucchi D, Leonelli M, Damiano F, et al. [Post-transplant recurrence of glomerulonephritis: a complex clinical case]. *G Ital Nefrol.* 2010;27 Suppl 52:S82–S84.
 90. Daina E, Noris M, Remuzzi G. Eculizumab in a patient with dense-deposit disease. *N Engl J Med.* 2012;366:1161–1163.
 91. Garnier AS, Augusto JF, Pellier I, et al. Successful long-term outcome of kidney transplantation in a patient with X-linked thrombocytopenia: 9-year follow-up. *Transplantation.* 2014;98:e57–e58.
 92. Gurkan S, Fyfe B, Weiss L, et al. Eculizumab and recurrent C3 glomerulonephritis. *Pediatr Nephrol.* 2013;28:1975–1981.
 93. Herlitz LC, Bomback AS, Markowitz GS, et al. Pathology after eculizumab in dense deposit disease and C3 GN. *J Am Soc Nephrol.* 2012;23:1229–1237.
 94. Inman M, Prater G, Fatima H, et al. Eculizumab-induced reversal of dialysis-dependent kidney failure from C3 glomerulonephritis. *Clin Kidney J.* 2015;8:445–448.
 95. Kerns E, Rozansky D, Troxell ML. Evolution of immunoglobulin deposition in C3-dominant membranoproliferative glomerulopathy. *Pediatr Nephrol.* 2013;28:2227–2231.
 96. Le Quintrec M, Lionet A, Kandel C, et al. Eculizumab for treatment of rapidly progressive C3 glomerulopathy. *Am J Kidney Dis.* 2015;65:484–489.
 97. McCaughan JA, O'Rourke DM, Courtney AE. Recurrent dense deposit disease after renal transplantation: an emerging role for complementary therapies. *Am J Transplant.* 2012;12:1046–1051.
 98. Oosterveld MJ, Garrelfs MR, Hoppe B, et al. Eculizumab in pediatric Dense Deposit Disease. *Clin J Am Soc Nephrol.* 2015;10:1773–1782.
 99. Ozkaya O, Nalcacioglu H, Tekcan D, et al. Eculizumab therapy in a patient with dense-deposit disease associated with partial lipodystrophy. *Pediatr Nephrol.* 2014;29:1283–1287.
 100. Radhakrishnan S, Lunn A, Kirschfink M, et al. Eculizumab and refractory membranoproliferative glomerulonephritis. *N Engl J Med.* 2012;366:1165–1166.
 101. Rousset-Rouviere C, Cailliez M, Garaix F, et al. Rituximab fails where eculizumab restores renal function in C3nef-related DDD. *Pediatr Nephrol.* 2014;29:1107–1111.
 102. Sanchez-Moreno A, De la Cerda F, Cabrera R, et al. Eculizumab in dense-deposit disease after renal transplantation. *Pediatr Nephrol.* 2014;29:2055–2059.
 103. Vivarelli M, Pasini A, Emma F. Eculizumab for the treatment of dense-deposit disease. *N Engl J Med.* 2012;366:1163–1165.
 104. Barbour SJ, Espino-Hernandez G, Reich HN, et al. The MEST score provides earlier risk prediction in IgA nephropathy. *Kidney Int.* 2016;89:167–175.
 105. Cattran DC, Coppo R, Cook HT, et al. The Oxford classification of IgA nephropathy: rationale, clinicopathological correlations, and classification. *Kidney Int.* 2009;76:534–545.
 106. Roberts IS, Cook HT, Troyanov S, et al. The Oxford classification of IgA nephropathy: pathology definitions, correlations, and reproducibility. *Kidney Int.* 2009;76:546–556.
 107. Amornsiripanitch N, Hong S, Campa MJ, et al. Complement factor H autoantibodies are associated with early stage NSCLC. *Clin Cancer Res.* 2010;16:3226–3231.
 108. Dragon-Durey MA, Sethi SK, Bagga A, et al. Clinical features of anti-factor H autoantibody-associated hemolytic uremic syndrome. *J Am Soc Nephrol.* 2010;21:2180–2187.
 109. Khandelwal P, Gupta A, Sinha A, et al. Effect of plasma exchange and immunosuppressive medications on antibody titers and outcome in anti-complement factor H antibody-associated hemolytic uremic syndrome. *Pediatr Nephrol.* 2015;30:451–457.
 110. Sinha A, Gulati A, Saini S, et al. Prompt plasma exchanges and immunosuppressive treatment improves the outcomes of anti-factor H autoantibody-associated hemolytic uremic syndrome in children. *Kidney Int.* 2014;85:1151–1160.
 111. Sheerin NS, Kavanagh D, Goodship TH, et al. A national specialized service in England for atypical haemolytic uraemic syndrome—the first year's experience. *QJM.* 2016;109:27–33.
 112. Wetzels JF, van de Kar NC. Discontinuation of eculizumab maintenance treatment for atypical hemolytic uremic syndrome. *Am J Kidney Dis.* 2015;65:342.

113. Ardissino G, Possenti I, Tel F, et al. Discontinuation of eculizumab treatment in atypical hemolytic uremic syndrome: an update. *Am J Kidney Dis.* 2015;66:172–173.
114. Ardissino G, Testa S, Possenti I, et al. Discontinuation of eculizumab maintenance treatment for atypical hemolytic uremic syndrome: a report of 10 cases. *Am J Kidney Dis.* 2014;64:633–637.

APPENDIX

Other Conference Participants

Charlie E. Alpers, USA; Gerald B. Appel, USA; Gianluigi Ardissino, Italy; Gema Ariceta, Spain; Mustafa Arici, Turkey; Arvind Bagga, India; Ingeborg M. Bajema, The Netherlands; Miguel Blasco, Spain;

Linda Burke, USA; Thomas D. Cairns, UK; Mireya Carratala, Spain; Vivette D. D'Agati, USA; Mohamed R. Daha, The Netherlands; An S. De Vriese, Belgium; Marie-Agnès Dragon-Durey, France; Agnes B. Fogo, USA; Miriam Galbusera, Italy; Daniel P. Gale, UK; Hermann Haller, Germany; Sally Johnson, UK; Mihály Józsi, Hungary; Diana Karpman, Sweden; Lynne Lanning, USA; Moglie Le Quintrec, France; Christoph Licht, Canada; Chantal Loirat, France; Francisco Monfort, Spain; B. Paul Morgan, UK; Laure-Hélène Noël, France; Michelle M. O'Shaughnessy, USA; Marion Rabant, France; Eric Rondeau, France; Piero Ruggenenti, Italy; Neil S. Sheerin, UK; Jenna Smith, USA; Fabrizio Spoletti, Italy; Joshua M. Thurman, USA; Nicole C.A.J. van de Kar, The Netherlands; Marina Vivarelli, Italy; Peter F. Zipfel, Germany