



Universiteit  
Leiden  
The Netherlands

## **Incidence, Clinical Presentation, and Predictors of Clinical Restenosis in Coronary Bioresorbable Scaffolds**

Polimeni, A.; Weissner, M.; Schochlow, K.; Ullrich, H.; Indolfi, C.; Dijkstra, J.; ... ; Gori, T.

### **Citation**

Polimeni, A., Weissner, M., Schochlow, K., Ullrich, H., Indolfi, C., Dijkstra, J., ... Gori, T. (2017). Incidence, Clinical Presentation, and Predictors of Clinical Restenosis in Coronary Bioresorbable Scaffolds. *Jacc: Cardiovascular Interventions*, 10(18), 1819-1827.  
doi:10.1016/j.jcin.2017.07.034

Version: Not Applicable (or Unknown)  
License: [Leiden University Non-exclusive license](#)  
Downloaded from: <https://hdl.handle.net/1887/115193>

**Note:** To cite this publication please use the final published version (if applicable).



# Incidence, Clinical Presentation, and Predictors of Clinical Restenosis in Coronary Bioresorbable Scaffolds

Alberto Polimeni, MD,<sup>a,b</sup> Melissa Weissner,<sup>a</sup> Katharina Schochlow,<sup>a</sup> Helen Ullrich,<sup>a</sup> Ciro Indolfi, MD,<sup>b</sup> Jouke Dijkstra,<sup>c</sup> Remzi Anadol,<sup>a</sup> Thomas Münzel, MD,<sup>a</sup> Tommaso Gori, MD, PhD<sup>a</sup>

## ABSTRACT

**OBJECTIVES** The aim of this study was to describe the incidence and clinical characteristics, including intracoronary imaging features, of clinical restenosis in bioresorbable coronary scaffolds (BRS). Further, the authors searched for clinical and procedural predictors of scaffold restenosis (ScR) and report on the clinical outcomes after treatment of ScR in a cohort of consecutive all-comer patients.

**BACKGROUND** Data from randomized controlled trials demonstrate a higher rate of target lesion failure in patients treated with BRS as compared with those treated with metal drug-eluting stents. Although in-scaffold thrombosis has been thoroughly investigated, there are little data available on the incidence and characteristics of ScR.

**METHODS** A total of 657 consecutive patients (age  $63 \pm 12$  years, 79% men, 21% diabetics, 67% acute coronary syndrome) who received a total of 883 BRS for the treatment of coronary artery stenoses between May 2012 and January 2015 were enrolled in a retrospective registry.

**RESULTS** During the median follow-up of 1,076 days (interquartile range: 762 to 1,206 days), a total of 49 cases of ScR were found in 41 patients (Kaplan-Meier incidence: 2.4%, 6.0%, and 9.0% at 12-, 24-, and 36-month follow-up, respectively). ScR presented as stable angina or as incidental finding in 73% of the cases. The angiographic pattern was complex (type II to IV) in 55% of the ScR lesions. The neointima was homogeneous with high signal intensity in all but 3 cases at optical coherence tomography. Prior revascularization (hazard ratio [HR]: 2.7; 95% confidence interval [CI]: 1.5 to 5.1;  $p = 0.002$ ), diabetes (HR: 2.9; 95% CI: 1.5 to 5.4;  $p = 0.001$ ), lesion types B2 or C (HR: 2.8; 95% CI: 1.5 to 5.4;  $p = 0.002$ ), and implantation technique (HR: 0.3; 95% CI: 0.1 to 0.6;  $p = 0.001$ ) emerged as independent predictors of ScR. Oversizing (HR: 6.29; 95% CI: 2.4 to 16.4), undersizing (HR: 5.15; 95% CI: 1.99 to 13.30), and a residual stenosis  $>27\%$  (HR: 8.9; 95% CI: 3.6 to 21.8) were associated with an increased ScR risk.

**CONCLUSIONS** The 3-year incidence of ScR was similar to that observed in similar settings with newer-generation drug-eluting stents. It is often associated with a benign presentation and a complex angiographic pattern. Predictors of ScR match those of metallic stent restenosis, and the implantation technique used at index appears to play an important role. (J Am Coll Cardiol Intv 2017;10:1819-27) © 2017 by the American College of Cardiology Foundation.

From the <sup>a</sup>Kardiologie I, Zentrum für Kardiologie, University Medical Center Mainz and Deutsches Zentrum für Herz und Kreislauf Forschung, Standort Rhein-Main, Germany; <sup>b</sup>Division of Cardiology, Department of Medical and Surgical Sciences, “Magna Graecia” University, Catanzaro, Italy; and the <sup>c</sup>Division of Image Processing, Department of Radiology, Leiden University Medical Center, Leiden, the Netherlands. Dr. Gori has received DZHK (German Center for Cardiac and Cardiovascular Research) funding for research. Dr. Münzel has received funding from the Center for Translational Vascular Biology, Mainz. Dr. Polimeni is a fellow of the European Association of Percutaneous Coronary Interventions. Drs. Indolfi, Münzel, and Gori have received speaker fees from Abbott Vascular and St. Jude Medical. Abbott Vascular had no role in any phase of this research. All other authors have reported that they have no relationships relevant to the contents of this paper to disclose.

Manuscript received April 25, 2017; revised manuscript received June 19, 2017, accepted July 12, 2017.

## ABBREVIATIONS AND ACRONYMS

**BRS** = bioresorbable coronary scaffold

**CI** = confidence interval

**HR** = hazard ratio

**IQR** = interquartile range

**MLD** = minimal lumen diameter

**OCT** = optical coherence tomography

**QCA** = quantitative coronary angiography

**RVD** = reference vessel diameter

**ScR** = scaffold restenosis

Recent data from randomized controlled trials and meta-analyses with long-term follow-up reported increased rates of target lesion failure after implantation of coronary bioresorbable coronary scaffolds (BRS) as compared with metallic drug-eluting stents (1–4). Given its high impact in terms of mortality and morbidity, a major focus has been placed on the pathophysiology of scaffold thrombosis, whereas much less evidence is available to date regarding the incidence of scaffold restenosis (ScR). As well, little data exist on the clinical presentation and possible mechanisms of this additional complication of BRS.

SEE PAGE 1828

Possibly due to the larger strut thickness, imaging studies have demonstrated that the implantation of BRS is associated with fewer uncovered struts and a thicker neointimal coverage compared with drug-eluting stents (5,6). Although this has been interpreted as a positive healing phenomenon in the setting of unstable plaques, neointimal proliferation may also lead to an increased risk of restenosis and concur to the incidence of device failure. In line with this, the 3-year data of the ABSORB II study showed a larger mean change in minimal lumen area from post-procedure in the scaffold group as compared with the drug-eluting stent group ( $p = 0.04$ ), resulting in a larger incidence of binary in-device restenosis (7.0% vs. 0.7%;  $p = 0.003$ ) (1). In contrast, in the recent AIDA (Amsterdam Investigator-Initiated Absorb Strategy All-Comers Trial) trial, the 2-year incidence of ScR was 4.1%, similar ( $p = 0.53$ ) to that recorded in drug-eluting stents (4.6%; hazard ratio [HR]: 0.87; 95% confidence interval [CI]: 0.55 to 1.36) (2).

The incidence of ScR in more complex all-comers settings has not been reported yet. As well, it remains to be investigated whether clinical and procedural factors may influence the incidence of ScR, and whether this risk can be addressed at the time of implantation.

## METHODS

The study belongs to the MICAT (Mainz Intracoronary daTabase) project (NCT02180178), which is approved by the ethics committee of the Landesärztekammer Mainz.

**PATIENTS AND DEFINITIONS.** Clinical characteristics and quantitative coronary angiography (QCA) data of

all consecutive patients treated with a BRS (Absorb 1.1, Abbott Vascular, Santa Clara, California) between May 2012 and January 2015 in our institution were collected in a retrospective registry. Patient data were treated anonymously. Bypass grafts and in-stent restenoses were not treated with BRS, and implantation of BRS in calcific or tortuous vessels, in bifurcations with side branch  $>2$  mm, and in ostial lesions (starting January 1, 2014) was also discouraged. Overlap between BRS was minimized. Dual antiplatelet therapy (with prasugrel or ticagrelor for acute coronary syndrome patients) was recommended for 12 months in all.

Follow-up was obtained by trained personnel using standardized methods (7). Clinical restenosis was defined as the presence of symptoms or functional evidence of ischemia and a diameter stenosis  $>50\%$  as assessed in the local core laboratory or the presence of at least 70% diameter stenosis in the BRS or the 5 mm at the proximal or distal edge (8). The differential diagnosis with BRS thrombosis was based on clinical presentation or angiographic or imaging evidence of device thrombosis.

The outcome of patients treated using an implantation protocol designed to specifically address the issue of incomplete BRS expansion was compared with that of patients treated with a standard implantation technique. The “optimal implantation technique” included 1:1 pre- and post-dilatation with a noncompliant balloon, appropriate sizing ( $<15\%$  deviation from the QCA reference vessel diameter [RVD]), RVD between the available nominal BRS sizes (2.5 to 3.5 mm), and achievement of a final residual stenosis  $<20\%$ .

**QCA AND OPTICAL COHERENCE TOMOGRAPHY ANALYSIS.** A list of the methods, definitions, measurements performed, and local reproducibility has been previously published (7,9,10). Briefly, the key QCA parameters (Xcelera, Philips, Amsterdam, the Netherlands) included the in-BRS minimal lumen diameter (MLD), the final RVD, and the following derived indexes:

A parameter expressing the relation of device size to vessel size:

$$\frac{\text{BRS nominal size}}{\text{RVD}}$$

Post-procedural *in-scaffold* residual stenosis calculated as:

$$\text{In-scaffold residual stenosis} = 100 \cdot \frac{\text{RVD} - \text{MLD}}{\text{RVD}}$$

Optical coherence tomography (OCT) features of ScR were collected at the time of the event to

provide a descriptive analysis of the presence of malapposition, strut fracture, scaffold size, and tissue characteristics; see the [Online Appendix](#) as well as Gori et al. (11) for definitions and reproducibility of the measurements. Images were acquired with the C7XR imaging console and Dragonfly imaging catheter (Optis, St. Jude Medical, St. Paul, Minnesota) and analyzed offline with the QCU-CMS software Version 4.69 (Leiden University, Leiden, the Netherlands). The neointima was characterized based on the intensity (homogeneous vs. nonhomogeneous) and the smoothness of the luminal borders. Homogeneous neointima showed uniform signal properties without focal variation or attenuation. Heterogeneous neointima presented as a layered pattern with an endoluminal high backscattering layer and an abluminal low-backscattering layer (12).

**STATISTICAL ANALYSIS.** Continuous variables are presented as mean  $\pm$  SD or median (interquartile range [IQR]) based on the inspection of the Q-Q plots. Accordingly, they were compared using a Student unpaired *t* test, Mann-Whitney *U* test, Kruskal-Wallis test, or analysis of variance. Categorical variables are presented as counts and percentages, and were compared using the Fisher exact test. Kaplan-Meier analysis was used to derive the event rates and plot time-to-event curves. Cox proportional hazards analysis was performed to identify the clinical and procedural parameters relevant for ScR. Potential covariates were prioritized a priori for data analysis with an approximately 1:10 covariate-to-case ratio to minimize overmodeling (13). Potential covariates were chosen based on a review of literature on drug-eluting stent restenosis and included diabetes, prior revascularization, treatment of complex lesions (American Heart Association lesion type B2 or C) at index, implantation technique (including procedural parameters as well as parameters of vessel size, BRS sizing, and BRS or vessel expansion). Univariate and multivariable HRs and 95% CIs are reported accordingly. The hypothesis that both undersizing and oversizing (nominal or RVD ratio) and a larger percent residual stenosis might be associated with increased restenosis risk was investigated for possible dichotomization by inspection at 0.1-percentile intervals. A generalized estimating equation model was used to evaluate the differences in the QCA parameters (MLD, RVD, and % stenosis) with consideration of correlation structure (multiple lesions per patient). Statistical analyses were performed with MedCalc version 9 (MedCalc Software, Mariakerke, Belgium) and R Statistical Software (R Foundation for Statistical Computing, Vienna, Austria).

**TABLE 1 Clinical and Procedural Characteristics**

	All Patients (N = 657)	Patients Without ScR (n = 616)	Patients With ScR (n = 41)	p Value
Age, yrs	63 $\pm$ 12	63 $\pm$ 12	64 $\pm$ 11	0.54
Male	531 (79)	497 (79)	34 (83)	0.42
Hypertension	489 (73)	458 (72)	31 (76)	0.76
Diabetes	144 (22)	126 (20)	18 (44)	<0.001
Smoking	277 (42)	266 (42)	11 (27)	0.06
Family history of CAD	142 (21)	138 (22)	4 (10)	0.07
Hyperlipidemia	274 (41)	253 (40)	21 (51)	0.12
Prior CABG	14 (2)	13 (2)	1 (2)	0.98
Prior PCI	186 (28)	166 (26)	20 (49)	0.004
Prior stroke/TIA	27 (4)	24 (4)	3 (7)	0.28
LVEF, %	52 $\pm$ 9	52 $\pm$ 9	52 $\pm$ 9	0.29
Silent/stable angina	280 (37)	251 (35)	29 (48)	0.06
Unstable angina	87 (11)	79 (11)	8 (13)	0.62
NSTEMI	212 (27)	196 (28)	16 (27)	0.99
STEMI	177 (23)	170 (24)	7 (12)	0.02
BRS per patient	1.4 $\pm$ 0.8	1.4 $\pm$ 0.8	1.8 $\pm$ 1.1	0.017
Hybrid BVS+DES	342 (53)	319 (53)	23 (50)	0.62
LM treated with BRS	0 (0)	0 (0)	0 (0)	1.00
LAD treated with BRS	339 (44)	313 (44)	26 (43)	0.80
LCX treated with BRS	191 (25)	179 (25)	12 (20)	0.52
RCA treated with BRS	233 (31)	211 (30)	22 (37)	0.38
Graft treated with BRS	1 (0.1)	1 (0.1)	0 (0)	0.97
Ostial lesion	61 (8)	54 (8)	7 (12)	0.55
AHA lesion type B2 or C	322 (42)	285 (41)	37 (62)	<0.001
CTO	21 (3)	14 (2)	7 (12)	<0.001
Pre-dilatation	752 (99)	696 (99)	56 (93)	0.22
Minimum stent diameter, mm	2.90 $\pm$ 0.47	2.97 $\pm$ 0.44	2.84 $\pm$ 0.34	0.002
Total length BVS per patient, mm	27 $\pm$ 18	27 $\pm$ 19	34 $\pm$ 14	<0.001
Post-dilatation	365 (48)	340 (49)	25 (42)	0.87
Overlap	92 (13)	81 (12)	11 (22)	0.02
Bifurcation	92 (14)	88 (14)	4 (9)	0.28
Clopidogrel	168 (42)	150 (26)	18 (37)	0.03
Prasugrel	265 (42)	248 (43)	17 (35)	0.51
Ticagrelor	112 (18)	109 (19)	3 (6)	0.06

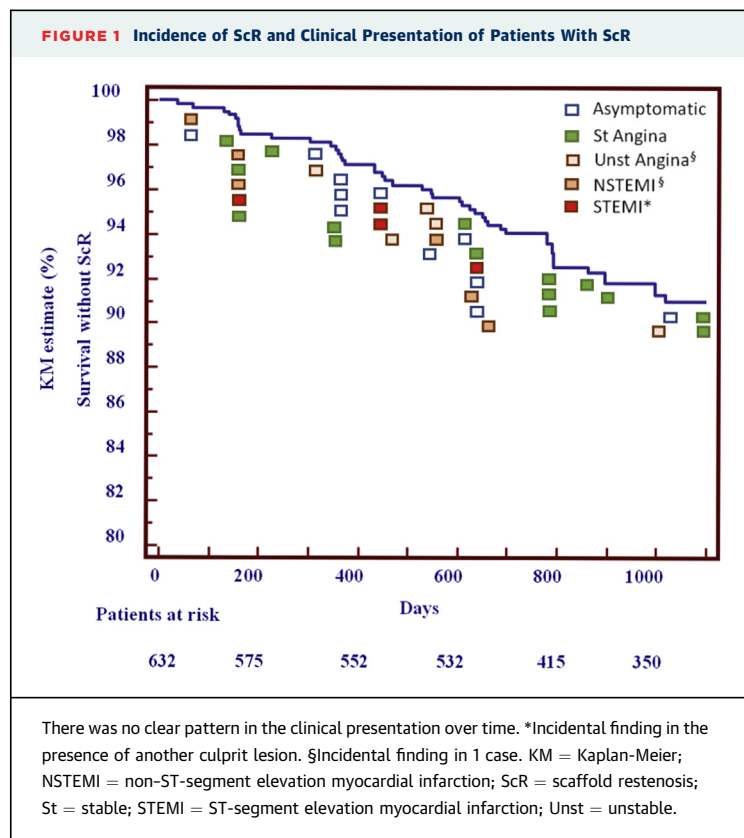
Values are mean  $\pm$  SD or n (%).

AHA = American Heart Association; BRS = bioresorbable coronary scaffold; BVS = bioresorbable vascular scaffold; CABG = coronary artery bypass grafting; CAD = coronary artery disease; CTO = chronic total occlusion; DES = drug-eluting stent(s); eGFR = estimated glomerular filtration rate; LAD = left anterior descending artery; LCX = left circumflex artery; LM = left main; LVEF = left ventricular ejection fraction; NSTEMI = non-ST-segment elevation myocardial infarction; PCI = percutaneous coronary intervention; RCA = right coronary artery; ScR = in-scaffold restenosis; STEMI = ST-segment elevation myocardial infarction; TIA = transient ischemic attack.

## RESULTS

A total of 657 patients (mean age 63  $\pm$  12 years, 79% men, 22% diabetic, 63% acute coronary syndrome) who received a total of 883 BRS (1.4  $\pm$  0.8 per patient) were included. The median follow-up was 1,076 days (IQR: 762 to 1,206 days), with a 3-year follow-up in 386 of 416 (93%) patients who had reached 3 years at the time of the last follow-up; a 2-year follow-up was available in 586 (89%) patients.

The clinical and procedural characteristics of the patients with or without ScR are presented in [Table 1](#).



**Figure 1** depicts the Kaplan-Meier curve for the incidence of ScR and the corresponding clinical presentation. A total of 49 ScRs were recorded in 41 patients. The Kaplan-Meier incidence of ScR was 2.4% at 12 months, 6% at 2 years, and 9% at 3 years. The most frequent presentation included stable angina (n = 15) or incidental diagnosis in asymptomatic patients (n = 11) or in patients with ST-segment elevation myocardial infarction with the culprit lesion in a separate vessel (n = 4). ScR presented as non-ST-segment elevation myocardial infarction in 4 patients and unstable angina in another 4. In 2 patients (1 with unstable angina and 1 with non-ST-segment elevation myocardial infarction), a type Ib ScR was an incidental finding as symptoms were likely driven by thrombosis in another scaffold. The differential diagnosis of ScR versus in-BRS thrombosis was confirmed in these cases by OCT. In sum, ScR presented as acute coronary syndrome only in 8 of 41 patients.

Patients with ScR had more frequently diabetes (44% vs. 20%;  $p < 0.001$ ), prior percutaneous revascularization (49% vs. 26%;  $p = 0.004$ ), complex stenoses (62% vs. 41% for B2 or C lesions and 12% vs. 2% for chronic total occlusions; both  $p < 0.001$ ). The total

**TABLE 2 QCA Characteristics and Outcomes**

	Lesions Without ScR (n = 593)	Lesions With ScR (n = 49)	p Value
Pre-procedural MLD, mm	$0.59 \pm 0.51$	$0.60 \pm 0.50$	0.310
Pre-procedural RVD, mm	$2.99 \pm 0.61$	$2.44 \pm 0.84$	<0.001
Stenosis, %	$79.5 \pm 17.4$	$71.9 \pm 18.6$	0.012
Post-procedural MLD, mm	$2.58 \pm 0.43$	$2.05 \pm 0.51$	<0.001
Post-procedural RVD, mm	$2.98 \pm 0.45$	$2.79 \pm 0.51$	0.014
Residual stenosis	$14.0 \pm 10.5$	$26.0 \pm 15.9$	<0.001

Values are mean  $\pm$  SD.

MLD = minimal lumen diameter; RVD = reference vessel diameter; ScR = in-scaffold restenosis.

implanted length was larger ( $34 \pm 14$  mm vs.  $27 \pm 19$  mm;  $p < 0.001$ ) and the minimum stent diameter smaller ( $2.84 \pm 0.34$  mm vs.  $2.97 \pm 0.44$  mm;  $p = 0.002$ ) in ScR patients. The QCA characteristics at index are presented in **Table 2**. Features of patients with ScR included a smaller RVD, a smaller post-procedural MLD, and a larger residual stenosis (all  $p < 0.001$ ).

#### ANGIOGRAPHIC AND OCT CHARACTERISTICS OF ScR.

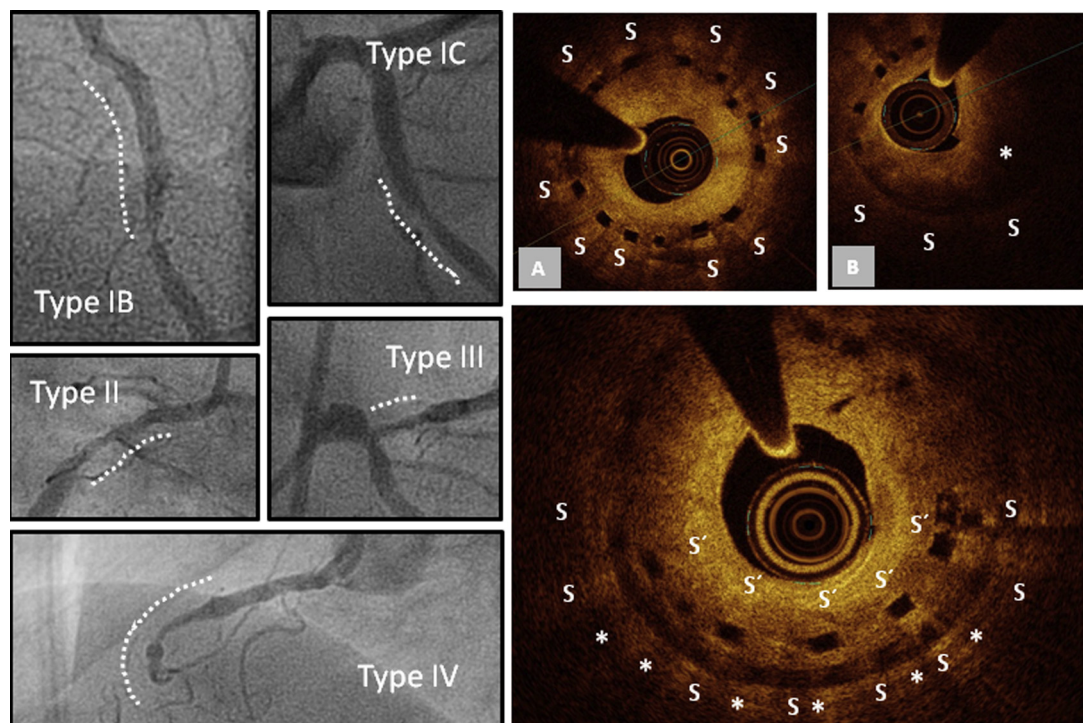
Data are presented in **Figures 2 and 3** and **Online Table S1**. At angiography, 22 restenoses were focal (type Ib, margin, n = 10; and type Ic, focal body, n = 12), 13 were diffuse intrastent (type II), 5 were proliferative (type III), and 9 were total occlusions. OCT movies were available in 27 lesions (n = 24) with ScR and are compared in **Online Table S2** with those of 115 lesions (115 patients) who underwent elective OCT. Scaffolds and lumen diameters or areas were consistently smaller in ScR lesions (all  $p < 0.001$ ). The neointima was mostly homogeneous and presented a high intensity (n = 23). An inhomogeneous neointima with low-intensity areas was present in only 4 cases. In 1 case, ScR was likely caused by BRS fracture and subsequent formation of an endothelial bridge between originally noncontiguous struts. There was no case of neoatherosclerosis. Fractures were significantly more frequent in ScR lesions as compared with control OCTs (60.8% vs. 34.8%;  $p = 0.03$ ). Malapposed struts and evaginations were a rare finding in ScR lesions (n = 1 and n = 4, respectively;  $p = 0.016$  and  $p = 0.019$  compared with control OCT).

#### TREATMENT OF ScR AND OUTCOME AFTER TREATMENT.

ScR lesions (n = 49) were treated with implantation of a drug-eluting stent in 33 cases, with percutaneous transluminal coronary angioplasty only or percutaneous transluminal coronary angioplasty with a drug-eluting balloon (n = 4 for both, all occurring within 6 months of implantation), with another BRS in 1 case, and with surgery in another 1 in which multiple



**FIGURE 2** Angiographic and OCT Patterns of Restenosis



**Left panels** show types of angiographic restenosis. The **right panels** show types of neointima at optical coherence tomography (OCT): **(A)** high intensity, homogeneous with smooth borders; **(B)** with evidence of low-intensity areas (**asterisk**). Stent struts are marked with S or S' (overlap).

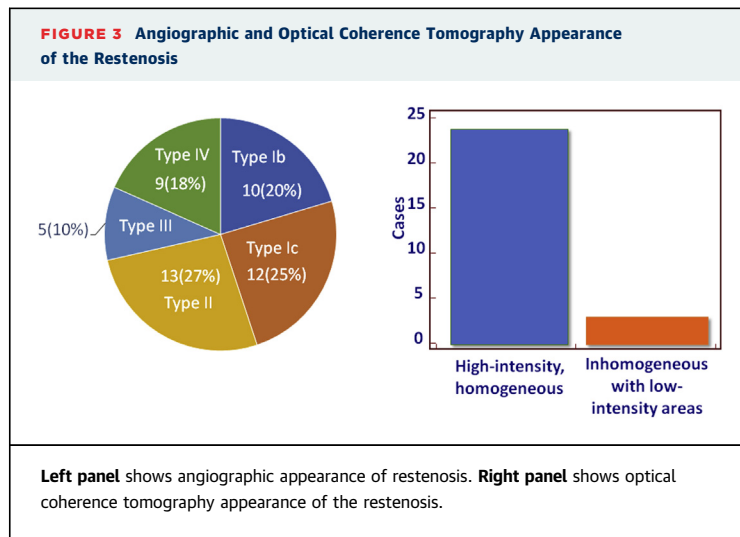
other de novo lesions were present. In 6 patients or lesions (full occlusions) a therapy was not possible. Follow-up was available in all patients at 545 (IQR: 168 to 866) days after the diagnosis of ScR. One patient died at home 14 days after drug-eluting balloon treatment of a type 2 restenosis, which presented at 152 days after implant. The patient had been on treatment with prasugrel since the index procedure. No other event was reported.

**PREDICTORS OF ScR.** The full results of the univariate Cox regression analysis, including pre-specified and non-pre-specified variables, are presented in [Online Table S2](#). The results of the multivariable analysis are presented in [Table 3](#): prior revascularization (HR: 2.72), diabetes (HR: 2.89), treatment of B2 or C lesions (HR: 2.81), and implantation technique (HR: 0.30) were all independent predictors of ScR. The model p value was <0.001, the receiver-operating characteristic c-statistic was 0.76.

Both BRS oversizing (nominal BRS diameter or RVD >1.13; i.e., choice of a BRS 13% larger than the vessel

diameter) and undersizing (nominal or RVD ratio <0.91; i.e., choice of a BRS 9% smaller than the reference vessel) were associated with an increased incidence of ScR (HR: 6.29; 95% CI: 2.40 to 16.40; and HR: 5.15; 95% CI: 1.99 to 13.30, respectively) ([Central Illustration](#)). Intermediate degrees of under- and oversizing showed a linear relationship between missizing and risk of ScR. In line with the concept that oversizing might be a predictor of ScR, a  $\geq 10\%$  increase in RVD from baseline to final after implantation was also associated with an increased risk of ScR (HR: 2.03; 95% CI: 1.12 to 3.67;  $p = 0.0196$ ).

The incidence of ScR increased with increasing degree of residual stenosis beyond 27% HR: 8.86; 95% CI: 3.60 to 21.81;  $p < 0.0001$ ). On receiver-operating characteristic analysis, a residual stenosis >27% was associated with a sensitivity and specificity of 53% and 91% in the prediction of ScR, respectively. The area under the receiver-operating characteristic curve was 0.736. Finally, the incidence of ScR was higher for RVDs smaller than 2.7 mm and further increased below 2.57 mm ([Central Illustration](#)).



## DISCUSSION

Despite significant progress with drug-eluting technologies, in-stent restenosis remains 1 of the limiting factors for the success of coronary stent implantation, and an important challenge for new technologies (14). The pathophysiology of this phenomenon is multifactorial and comprises patient-related factors (e.g., diabetes and a history of restenosis), procedure-related factors (number and size of stents used, stent overlap, percent residual stenosis), and lesion-related factors (small vessel size, American Heart Association or American College of Cardiology lesion complexity including features such as chronic total occlusion, ostial lesions, long lesions, and calcific lesions) (15–17).

We extend these notions from metallic stents to BRS. The main findings of the present study include the following. First, despite the complexity of the lesions, the 3-year incidence of ScR in a series of consecutive patients was similar to that observed in similar settings with newer-generation drug-eluting stents; ScR had mostly (three-quarters of the cases) a benign presentation. Second, the angiographic appearance of ScR is complex (type II to IV) in a significant fraction of ScRs, and, confirming previous case reports (18), the neointima appears to be mostly mature and compatible with fibrotic tissue at OCT. Evidence compatible with neoatherosclerosis was not found. Third, the predictors of ScR are similar to those known for metallic stents and include diabetes, treatment of complex lesions, and prior intervention. Similar to scaffold thrombosis (7), the technique used at the time of implantation has a central role in reducing the incidence of ScR. Last, both BRS oversizing and undersizing, as well as vessel size and

**TABLE 3 Independent Correlates of ScR**

	p Value	HR	95% CI
Prior revascularization	0.0017	2.7211	1.4593–5.0740
Diabetes	0.0009	2.8907	1.5491–5.3941
AHA lesion type B2/C	0.0020	2.8062	1.4651–5.3749
Implantation technique	0.0014	0.2975	0.1420–0.6232

AHA = American Heart Association; CI = confidence interval; HR = hazard ratio; ScR = scaffold restenosis.

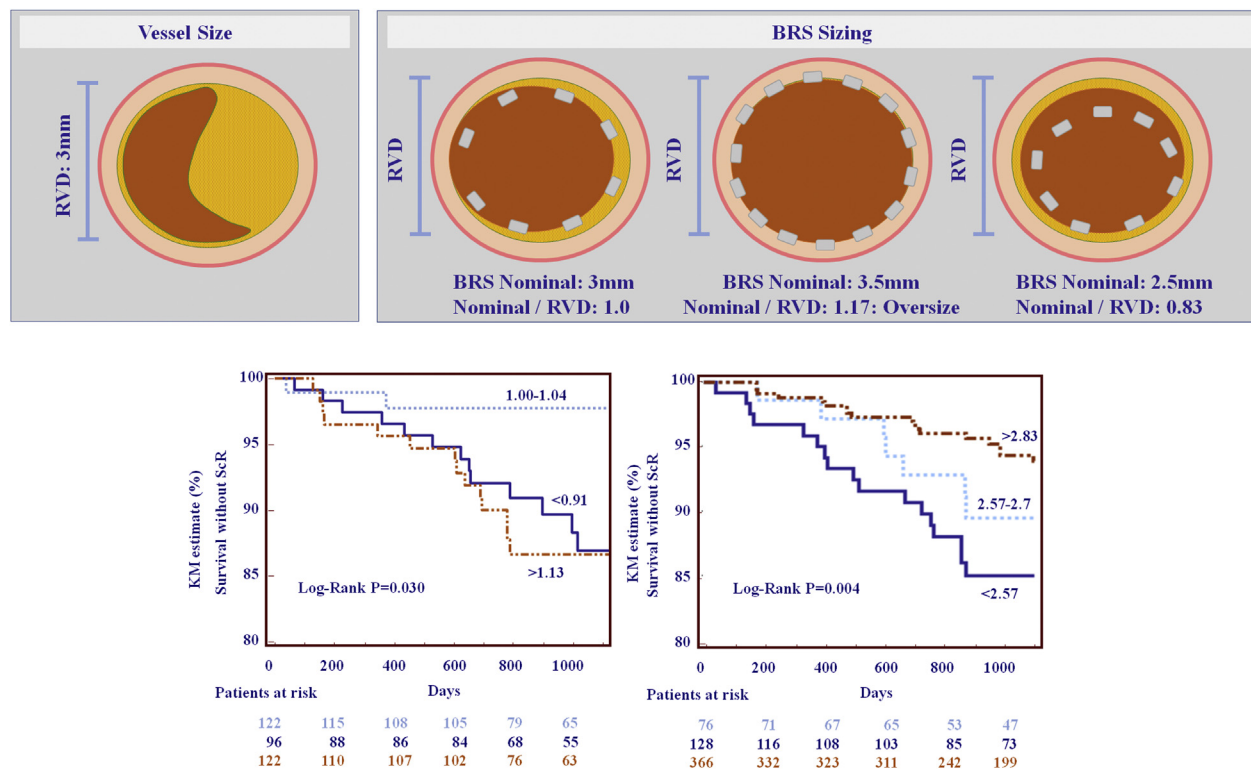
residual stenosis at index, are associated with an increased risk of ScR.

**POSSIBLE MECHANISMS OF ScR.** Initial data from serial analyses of BRS reported a tissue response quantitatively similar to that following implantation of newer-generation stents (19). Later analyses based on computational fluid dynamics techniques (20); however, demonstrated that the thick protruded struts of the BRS cause proximal and distal blood flow disturbance and recirculation microenvironments, resulting in areas of low blood wall shear stress, which stimulate neointima formation. Oversizing of the implanted device may amplify this phenomenon through 2 mechanisms: first, the increased strut density increases recirculation areas; second, the vessel wall injury is also a well-known stimulus for neointima proliferation. The existence of a possible relationship between stent oversizing and risk of restenosis has long been disputed for metallic devices (21). The present data appear to confirm the existence of such a relationship with BRS.

The possible role of undersizing is even more complex: on one side, incomplete strut apposition causes shear flow disturbances resulting in a delay in adluminal neointimal coverage (22); on the other side, classical fluid dynamic studies (23) demonstrate that stent undersizing may result in an heterogeneous pattern of wall shear stress, which is associated with both neointimal hyperplasia and thrombosis. Data from the ABSORB cohort B show that the physiological correction of malapposition involves neointimal growth from the strut to the vessel wall through a so-called “confluent model” (i.e., a proliferation of endothelial cells from the injured vessel wall to the surface of the stent). Both phenomena might have contributed to the observed bimodal distribution of the risk of ScR for low and high values of nominal or RVD ratio. The role of residual stenosis and RVD as predictors of ScR is in line with findings from drug-eluting stents (15–17).

With regard to the type of neointima, the most common pattern was a high-intensity, homogeneous tissue compatible with fibrotic, mature neointima.

# **CENTRAL ILLUSTRATION** Description of the Concept of Vessel Size (RVD), Vessel Sizing (Relationship Between Nominal Device Diameter and RVD)



Polimeni, A. et al. J Am Coll Cardiol Interv. 2017;10(18):1819-27.

The **bottom left panel** shows scaffold restenosis (ScR) as a function of bioresorbable coronary scaffold (BRS) sizing (nominal diameter/reference vessel diameter [RVD]). (**Top panels**) Undersizing (choice of a BRS >9% smaller than the RVD, or nominal diameter/RVD <0.91) and oversizing (nominal diameter/RVD >1.13) were both associated with increased risk of ScR. Oversizing might lead to vessel trauma and increased strut density, which both stimulate proliferation. Undersizing might lead to malapposition and disruption in the laminarity of the flow, also a stimulus for neointima growth. The **bottom right panel** shows the incidence of ScR was also significantly higher for vessels with RVD <2.7 mm. Importantly, the incidence further increased for smaller RVD, showing a gradient in the risk of ScR with decreasing RVD. KM = Kaplan-Meier.

Low-intensity areas (peristrut), possibly suggestive of inflammatory reactions, were rarer. Although in the absence of histological confirmation any conclusion regarding the nature of these tissues should be taken with caution, along with the absence of features typical of neoatherosclerosis or inflammatory reactions such as evaginations or malappositions, uncovered struts, and microvessels, and with mostly stable clinical presentation, these data appear to be compatible with a progressive growth of (benign) fibrotic neointima. Finally, the more frequent presence of fractures in ScR is compatible with the concept that fractures struts might represent a mechanical stimulus for neointima proliferation (24).

**ROLE OF THE IMPLANTATION TECHNIQUE.** Due to the larger strut width and the resulting larger

abluminal surface area, BRS exert a lower “penetrating” pressure at the time of implantation, which might result in less embedment of struts in the vessel wall, in turn leading to flow turbulence and lower shear stress. This concept is compatible with our evidence that an accurate implantation technique, ultimately aimed at optimizing both vessel and BRS expansion, is associated with a reduction in ScR.

**STUDY LIMITATIONS.** The registry nature of this study has clear inherent limitations, and although the methods used for the acquisition and analysis of the data were similar to those used in randomized controlled trials, the evidence provided here should be seen as hypothesis generating and exploratory. On the other side, the absence of inclusion or exclusion criteria and the complexity of the patients or lesions treated here provide directly applicable information.



Although an external independent laboratory was not involved, QCA and OCT data were analyzed using standard operating procedures by dedicated staff otherwise independent of the study. As mentioned, ScR is a multifactorial phenomenon in which vessel or stent geometry, strut thickness, and a number of patient or lesion or procedural characteristics play a role. By including the American College of Cardiology or American Heart Association classification as a variable, we computed the sum of multiple variables (e.g., lesion length, tortuosity, chronic total occlusion, ostial location). Larger databases are necessary to investigate each of these features. Because treatment of calcific lesions and tortuous vessels or lesions was discouraged or contraindicated from the beginning, we do not have enough cases to run a separate analysis for these endpoints. This “safety bias” did not allow investigating a possible predictor of events exactly because the risk of events was felt to be unacceptably high from the beginning. The absence of an OCT assessment at the time of the implantation is also a clear limitation, and the absence of routine angiographic follow-up allows us to conclude on clinical, but not angiographic, restenosis.

## CONCLUSIONS

The 3-year incidence of ScR was similar to that observed in similar settings with newer-generation drug-eluting stents. ScR in BRS had mostly a benign presentation but a complex angiographic pattern.

The incidence of ScR was lower when an optimal implantation technique was used.

**ADDRESS FOR CORRESPONDENCE:** Dr. Tommaso Gori, Kardiologie I, Zentrum für Kardiologie, University Medical Center Mainz, Langenbeckstrasse 1, 55131 Mainz, Germany. E-mail: [tommaso.gori@unimedizin-mainz.de](mailto:tommaso.gori@unimedizin-mainz.de).

## PERSPECTIVES

**WHAT IS KNOWN?** Data from randomized controlled trials demonstrate a higher rate of target lesion failure in patients treated with BRS as compared with those treated with metal drug-eluting stents.

**WHAT IS NEW?** We investigated the incidence, clinical presentation, and predictors of clinical restenosis (ScR) in a cohort of consecutive all-comer patients. We found that the incidence of ScR is often associated with a benign presentation and a complex angiographic pattern. The technique used at the time of implantation has a central role in reducing the incidence of ScR.

**WHAT IS NEXT?** Larger-scale direct comparative trials with long-term follow-up and imaging are required to better define the relative outcomes between these devices.

## REFERENCES

- Serruys PW, Chevalier B, Sotomi Y, et al. Comparison of an everolimus-eluting bioresorbable scaffold with an everolimus-eluting metallic stent for the treatment of coronary artery stenosis (ABSORB II): a 3 year, randomised, controlled, single-blind, multicentre clinical trial. *Lancet* 2016;388:2479–91.
- Woudstra P, Grundeken MJ, Kraak RP, et al. Amsterdam Investigator-initiated Absorb strategy all-comers trial (AIDA trial): a clinical evaluation comparing the efficacy and performance of ABSORB everolimus-eluting bioresorbable vascular scaffold strategy vs the XIENCE family (XIENCE PRIME or XIENCE Xpedition) everolimus-eluting coronary stent strategy in the treatment of coronary lesions in consecutive all-comers: rationale and study design. *Am Heart J* 2014;167:133–40.
- Polimeni A, Anadol R, Munzel T, Indolfi C, De Rosa S, Gori T. Long-term outcome of bioresorbable vascular scaffolds for the treatment of coronary artery disease: a meta-analysis of RCTs. *BMC Cardiovasc Disord* 2017;17:147.
- Stone GW, Gao R, Kimura T, et al. 1-year outcomes with the Absorb bioresorbable scaffold in patients with coronary artery disease: a patient-level, pooled meta-analysis. *Lancet* 2016;387:1277–89.
- Kallinikou Z, Arroyo D, Togni M, et al. Vascular response to everolimus- and biolimus-eluting coronary stents versus everolimus-eluting bioresorbable scaffolds—an optical coherence tomography substudy of the EVERBIO II trial. *Swiss Med Wkly* 2016;146:w14274.
- Raber L, Onuma Y, Brugaletta S, et al. Arterial healing following primary PCI using the Absorb everolimus-eluting bioresorbable vascular scaffold (Absorb BVS) versus the durable polymer everolimus-eluting metallic stent (XIENCE) in patients with acute ST-segment elevation myocardial infarction: rationale and design of the randomised TROFI II study. *EuroIntervention* 2016;12:482–9.
- Puricel S, Cuculi F, Weissner M, et al. Bioresorbable coronary scaffold thrombosis: multicenter comprehensive analysis of clinical presentation, mechanisms, and predictors. *J Am Coll Cardiol* 2016;67:921–31.
- Cutlip DE, Windecker S, Mehran R, et al. Clinical end points in coronary stent trials: a case for standardized definitions. *Circulation* 2007;115:2344–51.
- Gori T, Schulz E, Hink U, et al. Clinical, angiographic, functional, and imaging outcomes 12 months after implantation of drug-eluting bioresorbable vascular scaffolds in acute coronary syndromes. *J Am Coll Cardiol Interv* 2015;8:770–7.
- Gori T, Jansen T, Weissner M, et al. Coronary evaginations and peri-scaffold aneurysms following implantation of bioresorbable scaffolds: incidence, outcome, and optical coherence tomography analysis of possible mechanisms. *Eur Heart J* 2016;37:2040–9.
- Gori T, Wiebe J, Capodanno D, et al. Early and midterm outcomes of bioresorbable vascular scaffolds for ostial coronary lesions: insights from the GHOST-EU registry. *EuroIntervention* 2016;11:e550–6.

12. Song L, Mintz GS, Yin D, et al. Characteristics of early versus late in-stent restenosis in second-generation drug-eluting stents: an optical coherence tomography study. *EuroIntervention* 2017;13:294–302.
13. Harrell FE Jr., Lee KL, Califf RM, Pryor DB, Rosati RA. Regression modelling strategies for improved prognostic prediction. *Stat Med* 1984;3:143–52.
14. Indolfi C, De Rosa S, Colombo A. Bioresorbable vascular scaffolds - basic concepts and clinical outcome. *Nat Rev Cardiol* 2016;13:719–29.
15. Kastrati A, Schomig A, Elezi S, et al. Predictive factors of restenosis after coronary stent placement. *J Am Coll Cardiol* 1997;30:1428–36.
16. Abizaid A, Kornowski R, Mintz GS, et al. The influence of diabetes mellitus on acute and late clinical outcomes following coronary stent implantation. *J Am Coll Cardiol* 1998;32:584–9.
17. Elezi S, Kastrati A, Neumann FJ, Hadamitzky M, Dirschinger J, Schomig A. Vessel size and long-term outcome after coronary stent placement. *Circulation* 1998;98:1875–80.
18. Indolfi C, Mongiardo A, Spaccarotella C, Caiazzo G, Torella D, De Rosa S. Neointimal proliferation is associated with clinical restenosis 2 years after fully bioresorbable vascular scaffold implantation. *Circ Cardiovasc Imaging* 2014;7:755–7.
19. Gomez-Lara J, Brugaletta S, Farooq V, et al. Head-to-head comparison of the neointimal response between metallic and bioresorbable everolimus-eluting scaffolds using optical coherence tomography. *J Am Coll Cardiol Intv* 2011;4:1271–80.
20. Bourantas CV, Papafakis MI, Kotsia A, et al. Effect of the endothelial shear stress patterns on neointimal proliferation following drug-eluting bioresorbable vascular scaffold implantation: an optical coherence tomography study. *J Am Coll Cardiol Intv* 2014;7:315–24.
21. Colombo A. Influence of residual stenosis after coronary stent implantation on development of restenosis and stent thrombosis. *Am J Cardiol* 2003;92:1013.
22. Gutierrez-Chico JL, Gijzen F, Regar E, et al. Differences in neointimal thickness between the adluminal and the abluminal sides of malapposed and side-branch struts in a polylactide bioresorbable scaffold: evidence in vivo about the abluminal healing process. *J Am Coll Cardiol Intv* 2012;5:428–35.
23. Chen HY, Hermiller J, Sinha AK, Sturek M, Zhu L, Kassab GS. Effects of stent sizing on endothelial and vessel wall stress: potential mechanisms for in-stent restenosis. *J Appl Physiol* 2009;106:1686–91.
24. Omar A, Pendyala LK, Ormiston JA, Waksman R. Review: stent fracture in the drug-eluting stent era. *Cardiovasc Revasc Med* 2016;17:404–11.

---

**KEY WORDS** bioresorbable scaffolds, optical coherence tomography, restenosis

---

**APPENDIX** For expanded Methods and references sections as well as supplemental tables, please see the online version of this article.