



Universiteit
Leiden
The Netherlands

Early phase clinical drug development for HPV-induced disorders: novel tools and treatments

Rijsbergen, M.

Citation

Rijsbergen, M. (2020, February 19). *Early phase clinical drug development for HPV-induced disorders: novel tools and treatments*. Retrieved from <https://hdl.handle.net/1887/85448>

Version: Publisher's Version

License: [Licence agreement concerning inclusion of doctoral thesis in the Institutional Repository of the University of Leiden](#)

Downloaded from: <https://hdl.handle.net/1887/85448>

Note: To cite this publication please use the final published version (if applicable).

Cover Page



Universiteit Leiden



The handle <http://hdl.handle.net/1887/85448> holds various files of this Leiden University dissertation.

Author: Rijsbergen, M.

Title: Early phase clinical drug development for HPV-induced disorders: novel tools and treatments

Issue Date: 2020-02-19

Chapter 3

STEREOPHOTOGRAMMETRIC 3D PHOTOGRAPHY IS AN ACCURATE AND PRECISE PLANIMETRIC METHOD FOR THE CLINICAL VISUALIZATION AND QUANTIFICATION OF HPV-INDUCED SKIN LESIONS

M. Rijsbergen, L. Pagan, T. Niemeyer - van der Kolk, R. Rijneveld,
G. Hogendoorn, C. Lemoine, Y. Meija Miranda, G. Feiss, J.N. Bouwes Bavink,
J. Burggraaf, M.I.E. van Poelgeest, R. Rissmann

Journal of the European Academy of Dermatology and Venereology.
2019 Aug; 33(8): 1506-1512

Abstract

BACKGROUND Quantification of HPV-induced skin lesions is essential for the clinical assessment of the course of disease and the response to treatment. However, clinical assessments that measure dimensions of lesions using a caliper, do not provide complete insight into 3D lesions and its inter-rater variability is often poor.

OBJECTIVE The aim of this study was to validate a stereophotogrammetric 3D camera system for the quantification of HPV-induced lesions.

METHODS The camera system was validated for accuracy, precision and inter-operator and inter-rater variability. Subsequently, 3D photographs were quantified and compared to caliper measurements for clinical validation by Bland-Altman modelling, based on data from 80 patients with cutaneous warts (CW), 24 with anogenital warts (AGW) patients and 12 with high-grade squamous intraepithelial lesions of the vulva (vulvar HSIL) with a total lesion count of 220 CW, 74 AGW and 31 vulvar HSIL.

RESULTS Technical validation showed excellent accuracy (coefficients of variation (CV) $\leq 0.68\%$) and reproducibility (CVs $\leq 2\%$), a good to excellent agreement between operators (CVs $\leq 8.7\%$) and a good to excellent agreement between different raters for all three lesion types (ICCs ≥ 0.86). When comparing 3D with caliper measurements, excellent biases were found for diameter of AGW (long diameter 5%), good biases for diameter of AGW (short diameter 10%) and height of CW (8%) and acceptable biases were found for the diameter of CW (11%) and vulvar HSIL (short diameter 14%, long diameter 16%). An unfavorable difference between these methods (bias 25%) was found for the assessment of height of AGWs.

CONCLUSION Stereophotogrammetric 3D imaging is an accurate and reliable method for the clinical visualization and quantification of HPV-induced skin lesions.

Introduction

The human papilloma virus (HPV) is responsible for a spectrum of dermatological and gynaecological lesions. Low-risk HPV types are associated with cutaneous warts (CW) and anogenital warts (AGW), whilst high-risk types can cause (pre-)malignant lesions of the tissues of the anogenital tract, including high-grade squamous intraepithelial lesions of the vulva (vulvar HSIL, formerly referred to as usual-type vulvar intraepithelial neoplasia, uVIN).¹⁻⁴ Standard treatment for HPV-induced lesions includes surgical excision or ablative therapy; however, these can be mutilating and cause physical, psychological and (psycho-)sexual problems.^{5,6} Overall, current treatment options for HPV are associated with poor response, high recurrence rates and treatment limiting side effects.^{7,8} Therefore, new treatment options for HPV-related lesions are under investigation. The response to new dermatological therapies is often measured by calipers using traditional linear size assessments. These techniques fail to deliver complete insight into lesion dimensions as they can only assess the diameter and, if applicable, height of a lesion, and do not determine surface area or volumetric parameters.^{9,10} Three-dimensional (3D) imaging might offer a solution to these limitations. These techniques are already widely used in the field of plastic surgery and anthropometry to add objective measuring techniques to clinical practice.¹¹⁻¹³ Advantages of 3D imaging include the possibility of offline 3D visualization for dimensional quantification and photo documentation over time. A validated 3D imaging system would enable the accurate and highly sensitive characterization of detailed skin lesions, and would allow for an adequate evaluation of new therapies for HPV-induced lesions.

Stereophotogrammetry is a technique that obtains two or more images from different angles, which can subsequently be reconstructed into a 3D image and has been validated for use in scars, basal cell carcinoma, wounds and wrinkles.¹⁴⁻²⁰ Currently, this method remains unvalidated for the analysis of HPV-related skin lesions. Before it can be used in the clinical practice, 3D imaging using stereophotogrammetry requires technical verification for the analysis of HPV-related lesions. Therefore, the aim of this study was to validate stereophotogrammetric 3D photography for the clinical assessment of CW, AGW and vulvar HSIL.

Materials and methods

DEVICE & ANALYSIS TOOLS

The LifeViz® Micro (Quantificare, Sophia Antipolis, France) is a compact stereophotogrammetric 3D imaging system. The package includes hardware consisting of a 15.1 megapixels, single lens reflex camera (Canon, Tokyo, Japan) with a polar flash system and a dual beam pointer used to standardize photographing distance at 20 cm. All photographs were taken according to a pre-defined standard operating procedure (see Supplemental Fig. 1) in identical environmental conditions and standardized positioning of the patient depending on lesion type (see Supplemental Fig. 2 and 3). All photographs were made in the same room with closed blinds and room lights on. The camera distance was set to “micro” to standardize the system-lesion distance to 20 cm by means of an integrated dual beam pointer. Before taking the photographs the circumstances were verified using a checklist (Supplementary Fig. 4). Photographs were always free hand images and the camera system was perpendicularly pointed at the lesion of interest. Baseline photographs were used as reference for follow-up photography. Subsequently, the photograph was taken as soon as the dual beam pointers merged onto the lesion of interest. Image management, 3D image reconstruction, and 3D analysis were performed using DermaPix® software (Quantificare, Cedex, France), which is an image management software package providing a database system and quantification features. The photographs were uploaded in the software system processed as described in Supplemental Fig. 1. The 3D analysis module was opened to generate a heat map (indicating height levels). As result ‘difference’ could be selected in the menu and the contour was loaded to verify the correct cement of the manual contour. The lesion dimensions were provided after loading of the contour.

TECHNICAL VALIDATION

For the technical validation of the 3D camera system, a twelve inch ruler (Schaedler Quinzel Inc., Parsippany NJ, USA) and a wart-like object manufactured out of lightweight air-drying modeling clay (Hema, the Netherlands) were used.

Accuracy of the stereophotogrammetric 3D imaging system (i.e. ‘3D camera system’) was determined regarding absolute linear measurement by 3D

photography of the twelve inch ruler and regarding multiple dimensions measurement using the wart-like object. Repeated (N=40) 3D images were taken of the wart-like phantom object under identical conditions to determine the precision of repeated measurements. The inter-operator reliability of the 3D camera system was determined to validate the use by ten different photographers. All obtained 3D images were processed and quantified by one trained assessor.

PATIENT CHARACTERISTICS

For the clinical validation, i.e. inter rater variability and clinical application, of the 3D camera system, HPV-induced skin lesions were photographed during three phase 2 clinical trials. These were randomized, double-blind, placebo-controlled studies to evaluate the efficacy and safety of a topically applied novel drug on lesions caused by HPV (Supplementary Table 1). All lesions were measured by a caliper by a trained physician and trained operators subsequently obtained 3D photographs during all study visits.

CLINICAL VALIDATION

The images of the CW were processed and quantified by four individual and independent raters. Also four individuals scored the AGW lesions. Finally, 3D images of vulvar HSIL were independently quantified by two raters. The concordance between different assessors of the 3D images in the imaging software (i.e. inter-rater variability) was determined by comparing the quantification results of all clinical 3D images of skin lesions taken at the baseline study visit.

In addition, the HPV-induced lesions in the three trials were assessed by caliper measurements and 3D photography during all visits. The 3D measurements were compared to manual measurements acquired with a digital Vernier caliper (0-150 mm, Aerospace). The caliper measurements of CW and AGW were performed by trained physicians and the vulvar HSIL measurements were performed by a trained physician and a gynaecologist. The 3D photographs were taken by trained clinical staff. For the CW and AGW, the analysis of the 3D photographs was performed after all patients completed all visits by one clinical rater. The analysis of the 3D photographs of vulvar HSIL was performed after all patients completed all visits by two raters (the trained physician and gynaecologist who also performed the caliper measurements) who independently rated all images and had a consensus meeting afterwards.

The raters who quantified the 3D photographs of the AGW and vulvar HSIL also performed the clinical caliper measurements. The quantification process was performed after all patients completed all visits. The analysis of the 3D data was performed individually and blinded to the assessment of the other operators.

The Declaration of Helsinki was the guiding principle for trial execution and all subjects gave informed consent before any procedure. The study was approved by the Dutch Medical Ethics Committee (“Stichting Beoordeling Ethiek Biomedisch Onderzoek”, Assen, the Netherlands).

The clinical results on the efficacy and safety of the novel drugs investigated in the phase 2 trials will be published elsewhere.

STATISTICAL ANALYSIS

For the technical validation, the accuracy, precision and inter-operator reliability of the camera system were expressed by the mean (μ) and standard deviation (SD) per measured domain of all images, which were used to determine the coefficient of variation (CV) in percentage. We pre-specified a CV ≤5% as excellent, a CV 6-10% as good and a CV 11-20% as acceptable. The intra-class correlation coefficient (ICC) was established to quantify the variability of the 3D image processing and quantification. The ICC was determined in a two-way mixed model, with investigators as fixed and the subjects as random variable.²¹ ICC values of 0.7-0.8, 0.8-0.9 and ≥0.9 were considered as of acceptable, good and excellent agreement, respectively.^{22,23}

Clinical validation was approached by visualizing the data in Bland-Altman plots per parameter (where applicable; long diameter, short diameter and height) to represent the agreement between caliper and 3D measurements.^{24,25} These plots calculate the mean difference between the two measurements (bias, in mm) and the limits of agreement (LOA). We used a linear mixed model specified to calculate the bias and limits of agreement based on the repeated measurements as described previously.²⁶ Based on the size of the lesions, we predefined the biases of ≤5%, 6-10% and 11-20% as percentages of the mean baseline caliper measurement as excellent, good and acceptable, respectively. These specifications were derived from analytical methods for clinical trials and practice.^{27,28} The comparative analysis between caliper and 3D measurements was not performed until all 3D data was quantified to avoid subjectivity in the manual contours.

Results

TECHNICAL VALIDATION

The technical validation revealed a high accuracy with CVs ranging from 0 to 0.68% for 3D measurements of units of absolute ruler length (Fig. 1). The precision of a phantom object analyzed in diameter, height, volume and surface area resulted in CVs of 0.69%, 2.0%, 1.5% and 1.1%, respectively.

The inter-operator variability resulted in CVs of 1.9% for longest diameter, 8.7% for height, 2.8% for volume and 2.7% for surface area, indicating that analysis of 3D images taken by different trained persons yields similar results. For the inter-rater variability, 220 images of different CW, 72 images of different AGW and 31 different images of vulvar HSIL were quantified by the raters (see Table 1). The ICCs of the inter-rater variability for CW were 0.97, 0.90 and 0.88 for diameter, height and volume respectively. The inter-rater variability was similar for common and plantar warts (data not shown). In AGW we found an ICC of 0.91 for long diameter, 0.86 for short diameter, 0.90 for height and 0.98 for volume. For vulvar HSIL we found an ICC of 0.97 for long diameter, 0.94 for short diameter and 0.96 for surface. These data indicate that analysis of the 3D images by different raters yielded comparable results.

CLINICAL VALIDATION

Two-hundred-twenty (220) CW of 80 patients were included, of which 114 common and 106 plantar warts. In total, 1110 measurements of CW were performed, all of which (100%) were eligible for diameter, height and volume analysis. Subject characteristics are summarized in Table 1. An example of the three lesion types and the 3D reconstruction are shown in Fig 2.

Table 1. The inter-rater variability of 3D photography in HPV-induced skin lesions.

	Cutaneous warts (CW)			Anogenital warts (AGW)			Vulvar HSIL			
	Dia- meter	Height	Volume	Long diameter	Short diameter	Height	Volume	Long diameter	Short diameter	Surface
ICC	0.97	0.90	0.88	0.91	0.86	0.90	0.98	0.97	0.94	0.96
95% CI	0.96, 0.98	0.88, 0.92	0.85, 0.91	0.87, 0.94	0.80, 0.91	0.85, 0.94	0.96, 0.99	0.93, 0.99	0.88, 0.97	0.91, 0.98

ICC=intra-class correlation coefficient; CI=confidence interval; ICC values of >0.9 were considered as excellent and >0.8 as good

Figure 1. 3D reconstruction of the twelve inch ruler (A) and wart-like object (B).
Three-D reconstruction of the twelve inch ruler by the image reconstruction software (A), and the wart-like object in a 3D reconstruction with a heat-map showing the height of the object which is used for the 3D analysis (B). (see inside back-cover for image in color)




Figure 2. Three-dimensional reconstruction by stereophotogrammetry. A representative lesion for all three HPV-induced lesions (cutaneous warts, anogenital warts and vulvar HSIL) with on the left the 2D photograph, in the middle the 3D reconstruction and on the right the heat map showing height differences and the manual contour around the lesion. (see inside back-cover for image in color)

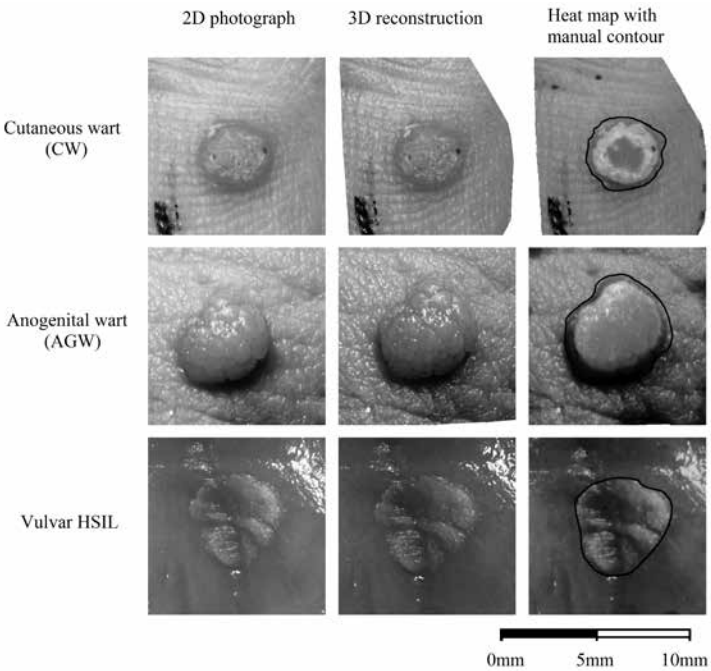
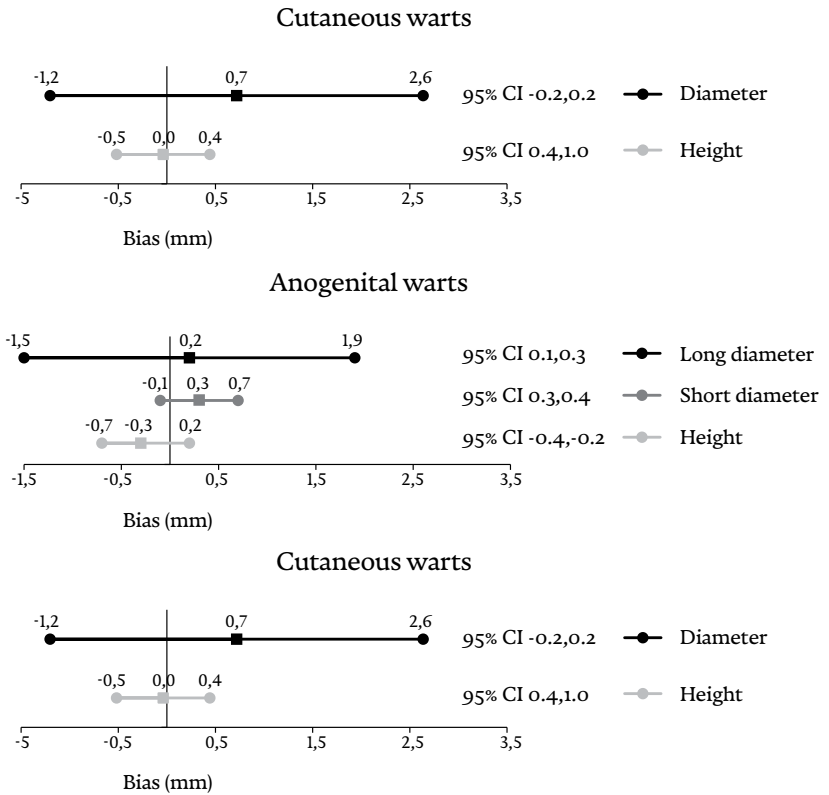


Figure 3. Forest plot of the bias and Limit of Agreement (LOA) from the Bland-Altman analysis for common and plantar warts, anogenital warts and vulvar HSIL. Forest plots of the outcomes of the Bland-Altman analysis in CW, AGW and vulvar HSIL.



CI= confidence interval, bias is indicated by a square, corresponding LoA are indicated by dots.

Forest plots of the outcomes of Bland-Altman analysis in CW, AGW and vulvar HSIL are shown in Fig. 3. In CW we found a bias of 0.7mm (11%) with LOA of -1.2mm and 2.6mm for diameter. The bias for height was -0.04mm (8%) with LOA of -0.5mm and 0.4mm (Fig. 3A). Outcomes for common and plantar warts separately showed no differences (data not shown).

Seventy-two (72) individual AGW of a total of 24 patients were included. In total, 341 measurements were performed, all of which (100%) were eligible for diameter analysis and 270 (79.2%) were eligible for height and volume

measurements. The 71 photographs (20.8%) unsuitable for height and volume measurements showed abundant presence of hairs or shadows, which impeded the construction of a 3D image. The results of the Bland-Altman analysis are shown in a forest plot (Fig. 3B). For the measurement of long diameter, we found a bias of 0.2mm (5%) with LOA between -1.5mm and 1.9mm. For short diameter we found a bias of 0.3mm (10%) and LOA ranging from -0.08mm and 0.7mm. Height bias was calculated as -0.3mm (25%) with LOA -0.7mm and 0.2mm.

Thirty-one (31) vulvar HSIL lesions of 12 patients were included and a total of 170 measurements were collected. All were eligible for diameter analysis (100%) and 164 (96.5%) were eligible for surface measurements. Photos were deemed unsuitable for further analysis when the imaging software was unable to compute a correct 3D image because of shadows and hairs disturbing the image. The bias values for long and short diameter were 2.3mm (14%) and 1.8mm (16%), with LOA ranging from -8.9mm and 13.4mm, and -7.1mm and 10.8mm, respectively (Fig. 3C).

Discussion

This validation study is the first to demonstrate that stereophotogrammetric 3D imaging is an accurate and precise method for the characterisation of HPV-related lesions and is applicable for the assessment of these lesions in a clinical setting.

The technical validation revealed an excellent accuracy with CVs<0.68%, an excellent reproducibility with CVs≤2% and a good to excellent agreement with CVs≤8.7% for the inter-operator variability. This indicates that 3D imaging is an exact and highly reproducible method. Three-dimensional photography of HPV-related lesions is also reliable for individual raters to assess the obtained photographs, established by good to excellent ICC values (0.86–0.98). These results indicate that a single photograph taken in standardized conditions by a trained operator is sufficient for reliable quantification of the lesions.

The clinical validation of diameter and height measurements yielded an acceptable (11%) and good (8%) bias between caliper and 3D imaging for CW. For AGW, we found an excellent (5%) and a good (10%) bias for the long and short diameter, respectively, but an unacceptable bias (25%) for the height of the AGW. For vulvar HSIL the calculated biases for comparison of the methods

caliper and 3D measurements were acceptable for both the long (14%) and short (16%) diameter. However, we did not investigate the errors induced by variation of environmental factors such as lighting, distance, variation of the plane/positioning in an artificial manner but focused on the standardized procedure to readily use it for monitoring HPV-induced lesions in clinical practice or after intervention in a clinical trial setting. Of note, calibration of the device was not necessary as both the high accuracy (Fig. 1) and the finding of a good inter-day precision could be confirmed by the manufacturer. The latter was determined by repeatedly (N=27) analysing the geometric parameters over a period of 3 months which showed CVs ranging from 0.65% for diameter to 3.72% for volume (see Supplemental Table 2).

Our technical and clinical validation results correspond to findings in earlier studies utilizing stereophotogrammetry as a method for the qualification of dermatological lesions. Robertson and colleagues found an ICC of 0.98 for volume quantification of hemangiomas in children using the same stereophotogrammetric system as utilized in this study.²⁹ Moreover, a previous study evaluating pressure ulcer wounds also found excellent inter-operator variability between operators (ICC=0.99).¹⁶ The evaluation of scars with stereophotogrammetry demonstrated excellent reliability and validity of the technique, although there was only moderate agreement between 3D quantification results and the gold standard (weighing of simulated clay scars).¹⁴ Other studies using stereophotogrammetry for breast dimension assessments reported moderate to good agreement with manual measurements due to difficulties in exact determination of the borders.^{11,12}

This study was limited by the absence of a comparison between the caliper and 3D measurements for volume and surface area. Indirectly, volume can only be calculated by a formula for an ellipse using the caliper measurements which often inaccurately reflects the shape of most warts. However, reliably including the third dimension of lesions and thus parameters like lesion volume and height of CW and AGW for detecting drug effects would be advantageous and indisputable for clinicians and drug developers. A similar limitation applies for area calculation of vulvar HSIL. There is no formula that encompasses the dimensions of HSIL and on the uneven genital tissue surface estimation techniques such as planimetry by tracing cannot be performed.¹⁵ For these reasons, other type of research must be performed to investigate the reliability of stereophotogrammetrically acquired volume and surface estimations like the artificial system used by Skvara et al.¹⁸

A limitation of the imaging software was that the contour around the lesions had to be drawn manually by the investigator. A system automatically determining the borders of the lesion would be of great added value but the current auto-contour function of the software did not pass the face validity criteria, i.e. already simple assignments would lead to obvious incorrect contour representation (data not shown). However, drawing the manual outline and the subsequent automatically calculated size led to reproducible results, indicated by a low inter-rater variability (Table 1).

Limitations of stereophotogrammetry of genital HPV-related lesions concern the plane surface in the vicinity of the lesion of interest, which is a prerequisite for the analysis tool during 3D reconstruction. Achieving a plane surface is complicated in case of periungual warts, AGW on the labia, frenulum or in the perianal area, or by areas disrupted by the presence of hairs projecting over the lesion of interest. The difficulty of accurately picturing curved body parts is a feature of 3D imaging systems that has been noted previously.¹³⁻¹⁵ These confounders might have resulted in unreliable measurement of height, surface and volume in this study. It is imperative that these data are correctly obtained by the 3D system, as caliper measurements only yield rough estimates of these parameters. For instance, we had to omit 20.8% of the volume and height quantification results of the AGW study due to suboptimal image reconstructions. Therefore, we advise potential users of stereophotogrammetry to pay extra attention to the removal of obscuring hairs during photography. We discarded images with irregularities in 3D reconstructions and erroneous measurements caused by hairs from the data that was analyzed for this study.

Recent studies suggested that following immunotherapy, lesions can firstly increase in size before regression, a phenomenon known as pseudoprogession. This is caused by influx of immune cells and measured according to the IRECIST, a guideline for response criteria for use in immunotherapeutic trials.^{30,31} Future research should take into account the applicability of 3D photography as a potential biomarker for response to immune therapy in combination with histologic immune infiltration assessments.

Overall, the added value of 3D imaging over caliper measurements is the enhanced accuracy of the measurement. Additional potential applications of 3D imaging of vulvar HSIL would be collegial or post-hoc consultation, clinical follow-up and training purposes to increase disease awareness among clinicians. Furthermore, stereophotogrammetric photo documentation and

offline visualization of the lesions offers an accurate and precise manner to follow the lesions during clinical trials. While the focus of our investigation was on the clinical application of 3D photography for geometric parameters of HPV-induced lesions one might speculate of its potential value for the objective measurement of lesions with distinct features such as textural changes of the skin in atopic dermatitis or other inflammatory skin conditions.

In conclusion, this study shows that stereophotogrammetry is an adequate tool for accurate and precise evaluation of HPV-induced skin lesions. Furthermore, it is applicable as a method for accurate and reproducible photo documentation of lesions. Being a portable, hand-held system, the validated system offers flexibility and practical advantages over other 3D imaging systems.¹³⁻¹⁵ These results need validation in larger cohorts and regarding other skin conditions. In addition, future studies should aim at the examination of 3D photography as a possible biomarker for lesion size assessment and treatment response.

REFERENCES

- 1 Bruggink SC, de Koning MN, Gussekloo J, et al. Cutaneous wart-associated HPV types: prevalence and relation with patient characteristics. *Journal of clinical virology : the official publication of the Pan American Society for Clinical Virology* 2012;55(3):250-5.
- 2 de Koning MN, Khoe LV, Eekhof JA, et al. Lesional HPV types of cutaneous warts can be reliably identified by surface swabs. *Journal of clinical virology : the official publication of the Pan American Society for Clinical Virology* 2011;52(2):84-7.
- 3 Rock B, Shah KV, Farmer ER. A morphologic, pathologic, and virologic study of anogenital warts in men. *Archives of Dermatology* 1992;128(4):495-500.
- 4 Faber MT, Sand FL, Albieri V, et al. Prevalence and type distribution of human papillomavirus in squamous cell carcinoma and intraepithelial neoplasia of the vulva. *International journal of cancer* 2017;141(6):1161-69.
- 5 Hillemanns P, Wang X, Staehle S, et al. Evaluation of different treatment modalities for vulvar intraepithelial neoplasia (VIN): CO(2) laser vaporization, photodynamic therapy, excision and vulvectomy. *Gynecol Oncol* 2006;100(2):271-5.
- 6 Likes WM, Stegbauer C, Tillmanns T, et al. Correlates of sexual function following vulvar excision. *Gynecol Oncol* 2007;105(3):600-3.
- 7 Stanley MA. Genital human papillomavirus infections: current and prospective therapies. *J Gen Virol* 2012;93(Pt 4):681-91.
- 8 Hanna E, Abadi R, Abbas O. Imiquimod in dermatology: an overview. *Int J Dermatol* 2016;55(8):831-44.
- 9 Committee Opinion No.675: Management of Vulvar Intraepithelial Neoplasia. *Obstetrics and gynecology* 2016;128(4):e178-82.
- 10 van de Nieuwenhof HP, van der Avoort IA, de Hullu JA. Review of squamous premalignant vulvar lesions. *Crit Rev Oncol Hematol* 2008;68(2):131-56.
- 11 Hoeffelin H, Jacquemin D, Defaweux V, et al. A methodological evaluation of volumetric measurement techniques including three-dimensional imaging in breast surgery. *Biomed Res Int* 2014;2014:573249.
- 12 Catherwood T, McCaughan E, Greer E, et al. Validation of a passive stereophotogrammetry system for imaging of the breast: a geometric analysis. *Med Eng Phys* 2011;33(8):900-5.
- 13 Heike CL, Upson K, Stuhau E, et al. 3D digital stereophotogrammetry: a practical guide to facial image acquisition. *Head & Face Medicine* 2010;6:18-18.
- 14 Stekelenburg CM, Jaspers ME, Niessen FB, et al. In a clinimetric analysis, 3D stereophotogrammetry was found to be reliable and valid for measuring scar volume in clinical research. *Journal of clinical epidemiology* 2015;68(7):782-7.
- 15 Stekelenburg CM, van der Wal MB, Knol DL, et al. Three-dimensional digital stereophotogrammetry: a reliable and valid technique for measuring scar surface area. *Plastic and reconstructive surgery* 2013;132(1):204-11.
- 16 Davis AJ, Nishimura J, Seton J, et al. Repeatability and clinical utility in stereophotogrammetric measurements of wounds. *J Wound Care* 2013;22(2):90-2, 94-7.
- 17 Xu Y, Sun J, Carter RR, et al. Personalized prediction of chronic wound healing: an exponential mixed effects model using stereophotogrammetric measurement. *J Tissue Viability* 2014;23(2):48-59.
- 18 Skvara H, Burnett P, Jones J, et al. Quantification of skin lesions with a 3D stereovision camera system: validation and clinical applications. *Skin Res Technol* 2013;19(1):e182-90.
- 19 Skvara H, Kalthoff F, Meingassner JG, et al. Topical treatment of Basal cell carcinomas in nevroid Basal cell carcinoma syndrome with a smoothened inhibitor. *J Invest Dermatol* 2011;131(8):1735-44.
- 20 Lumenta DB, Selig H, Kitzinger HB, et al. Objective quantification of wrinkles: three-dimensional analysis of surface irregularity. *Plast Reconstr Surg* 2012;129(4):735e-7e.
- 21 Haber M, Gao J, Barnhart HX. Evaluation of Agreement between Measurement Methods from Data with Matched Repeated Measurements via the Coefficient of Individual Agreement. *Journal of data science : JDS* 2010;8(3):457-69.
- 22 Koo TK, Li MY. A Guideline of Selecting and Reporting Intraclass Correlation Coefficients for Reliability Research. *Journal of Chiropractic Medicine* 2016;15(2):155-63.
- 23 Shrout PE, Fleiss JL. Intraclass correlations: uses in assessing rater reliability. *Psychological bulletin* 1979;86(2):420-8.
- 24 Bland JM, Altman DG. Measuring agreement in method comparison studies. *Statistical methods in medical research* 1999;8(2):135-60.
- 25 Bland JM, Altman DG. Statistical methods for assessing agreement between two methods of clinical measurement. *Lancet (London, England)* 1986;1(8476):307-10.
- 26 Carstensen B, Simpson J, Gurrin LC. Statistical models for assessing agreement in method comparison studies with replicate measurements. *Int J Biostat* 2008;4(1):Article 16.
- 27 Klonoff DC. The need for clinical accuracy guidelines for blood glucose monitors. *Journal of diabetes science and technology* 2012;6(1):1-4.
- 28 Little TA. Establishing Acceptance Criteria for Analytical Methods. *ADVANTAR Communications Inc 131 w 1st street, Duluth, MN 55802 USA; 2016.*
- 29 Robertson SA, Kimble RM, Storey KJ, et al. 3D photography is a reliable method of measuring infantile haemangioma volume over time. *Journal of Pediatric Surgery* 2016;51(9):1552-56.
- 30 Seymour L, Bogaerts J, Perrone A, et al. iRECIST: guidelines for response criteria for use in trials testing immunotherapeutics. *Lancet Oncol* 2017;18(3):e143-e52.
- 31 Hodi FS, Hwu WJ, Kefford R, et al. Evaluation of Immune-Related Response Criteria and RECIST v1.1 in Patients With Advanced Melanoma Treated With Pembrolizumab. *J Clin Oncol* 2016;34(13):1510-7.