



Universiteit
Leiden
The Netherlands

Joining forces in endocrine cancer genetics: molecular testing, surveillance and treatment decision making in clinical practice

Tuin, K. van der

Citation

Tuin, K. van der. (2019, December 12). *Joining forces in endocrine cancer genetics: molecular testing, surveillance and treatment decision making in clinical practice*. Retrieved from <https://hdl.handle.net/1887/81575>

Version: Publisher's Version

License: [Licence agreement concerning inclusion of doctoral thesis in the Institutional Repository of the University of Leiden](#)

Downloaded from: <https://hdl.handle.net/1887/81575>

Note: To cite this publication please use the final published version (if applicable).

Cover Page



Universiteit Leiden



The following handle holds various files of this Leiden University dissertation:
<http://hdl.handle.net/1887/81575>

Author: Tuin, K. van der

Title: Joining forces in endocrine cancer genetics: molecular testing, surveillance and treatment decision making in clinical practice

Issue Date: 2019-12-12

This chapter describes an unusual case of apparent non-penetrance in a family with Multiple Endocrine Neoplasia syndrome type 2.



A 93-year-old MEN2a Mutation Carrier Without Medullary Thyroid Carcinoma: A Case Report and Overview of the Literature

K. van der Tuin, N. Hofland, N.M. Appelman-Dijkstra,
R.B. van der Lijst, T. van Wezel, H. Morreau, F.J. Hes

Cancer Research Frontiers. 2016 Feb; 2(1): 60-66

ABSTRACT

Background

Multiple Endocrine Neoplasia (MEN) type 2 is a neuroendocrine neoplasia predisposition syndrome caused by a heterozygous germline mutation in the *RET* proto-oncogene. Mutation carriers have a lifetime risk of nearly 100% of developing medullary thyroid carcinoma. Approximately 40-50% of patients with MEN2A develop a pheochromocytoma and 20-30% develop primary hyperparathyroidism.

Case report

We describe an unusual case of apparent non-penetrance in a 93-year-old carrier of an apparent *de novo* *RET* germline mutation (c.1858T>C, p.C620R) without clinical symptoms of MEN2A. Different tissue types were tested for this mutation, making mosaicism less likely. His son was diagnosed at the age of 50 years old with metastasized medullary thyroid carcinoma. Pathological examination of material of a prophylactic thyroidectomy from his 19-year-old grandson showed multiple micro-carcinomas.

Discussion and conclusion

This unusual case of a 93-year-old carrier without apparent medullary thyroid carcinoma questions the full penetrance of a germline mutation in *RET* codon 620. Further investigation of genetic modifiers is warranted, to further explore phenotypic risk profiles of specific *RET* genotypes. (*Cancer Research Frontiers.2: 60-66 2016*)

INTRODUCTION

Medullary thyroid cancer (MTC) originates from the calcitonin-producing thyroid C-cells derived from the neural crest, and represents approximately 5-10% of all thyroid tumours, and about 15% of all thyroid cancer-related deaths. MTC may occur sporadically (75%) or as part of an autosomal dominantly inherited cancer syndrome (25%); multiple endocrine neoplasia (MEN) type 2. MEN2 is a neuroendocrine neoplasia predisposition syndrome characterized by variable penetrance of MTC and other endocrinopathies.^{1,2} MEN2 includes two phenotypes; MEN2A (95%), subdivide in four variants (Classical MEN2A, MEN2A with cutaneous lichen amyloidosis, MEN2A with Hirschsprung's Disease and familial MTC) and MEN2B (5%). In all subtypes of MEN2, MTC is generally the first neoplastic manifestation because of its earlier manifestation and higher penetrance compared with other endocrinopathies.

MEN2 is caused by a heterozygous germline mutation in the *RET* proto-oncogene that is located on chromosome 10 and encodes a membrane-bound tyrosine kinase receptor with extracellular and cytoplasmic domains. Receptor tyrosine kinases transduce the extracellular signals for processes such as diverse as cell growth, differentiation, survival and programmed cell death. The majority of MEN2A and FMTC cases are caused by activating missense mutations in the extracellular cysteine codons in exon 10 and exon 11. Mutations in this extracellular domain lead to ligand-independent homodimerization of the receptor with constitutive activation and downstream signalling of the mitogen-activated protein [MAP] kinase pathway.

The estimated prevalence of MEN2A is 1-2 per 200,000 persons in the general population^{3,4} and males and females are equally affected. In general, *RET* germline mutation carriers are reported to have a lifetime risk of nearly 100% of developing MTC. Approximately 40-50% of patients with MEN2A develop a pheochromocytoma and 20-30 develop primary hyperparathyroidism.⁵⁻⁸ In the majority of MEN2 families, associations between specific *RET* mutations (genotype) and aggressiveness of MTC and presence of their endocrine tumour (phenotype) are well documented.⁸⁻¹⁰ As mentioned, the penetrance of MTC in MEN2A is reported high, i.e. almost complete at advanced age.⁶ Here, we describe an unusual case of non-penetrance in a 93-year-old carrier of an *de novo RET* germline mutation without clinical symptoms of MEN2A.

7

CASE PRESENTATION

A 50-year-old male with no family history of endocrine malignancy presented with swelling in the neck and vocal cord paralysis. Physical examination showed enlarged lymph nodes in the neck and blood investigation revealed elevated serum levels of calcitonin (Ctn) and carcinoembryonic antigen (CEA). Neck ultrasound imaging showed a solitary lesion in the left thyroid lobe of 2.3 cm in diameter with calcification and pathologic lymphadenopathy on both sides, mainly in the mid and inferior jugular region. No pheochromocytoma screening was performed at that time. After surgery the diagnosis of metastasized medullary thyroid carcinoma was histopathologically confirmed. Molecular genetic analysis revealed the presence of a germline mutation in exon 10 of the *RET* proto-oncogene (NM_020975.4: c.1858T>C, p.C620R). In addition, DNA-testing for the *RET* mutation was recommended for his family members. The family history showed no signs of Hirschsprung's disease. Subsequently, investigation of other potentially affected endocrine organ systems was performed, there were no signs of pheochromocytoma or hyperparathyroidism. Annually clinical and biochemical screening was done. Five years later, he underwent adrenalectomy because of clinical symptoms (vertigo and palpitations), chemically suspected pheochromocytoma (increased catecholamine excess in urine) and growth of a lesion

in the left adrenal (12mm within one year). Histological examination showed adrenal medullary hyperplasia, but there was insufficient evidence for the definitive diagnosis pheochromocytoma.

His 19-year-old son, was identified as a pre-symptomatic mutation carrier and underwent prophylactic total thyroidectomy. Blood investigation showed no increased calcitonin or CEA levels and catecholamine excess in urine was not found. Histopathological analysis showed 3 foci of medullar micro-carcinoma, 1mm, 2mm and 3mm respectively, with some surrounding C-cell hyperplasia.

The father of the proband was also identified as a carrier of the *RET* mutation at an age of 91 years old without thyroid surgery or any symptoms of the thyroid or other health problems. However, he did not want any further clinical evaluation for MEN2A. We confirmed the presence for the *RET* mutation in colon, spleen and nasal polyps, making germline mosaicism very unlikely. Additional sequencing of the whole coding sequence of the *RET* gene was performed to exclude other mutations in the *RET* gene in the 91-year-old patient which could conceal the effects of the c.1858T>C mutation. He died at age 93 because of respiratory insufficiency with a recently diagnosed prostate carcinoma with possibly bone metastasis. No clinical or laboratory diagnostic evaluation was performed during hospitalisation that would have indicated the presence of MTC, pheochromocytoma or primary hyperparathyroidism. In particular no blood test for Ctn, calcium, catecholamine or PTH levels and no thyroid ultrasound or CT-scan of the head neck region. No autopsy was conducted.

Furthermore, no other paternal family members were identified as mutation carriers (see pedigree Figure 1). The first generation was not available for DNA testing, they had no symptoms of MTC, pheochromocytoma or primary hyperparathyroidism, although no specific diagnostic evaluation was performed. In the second generation, 11 siblings did not carry the *RET* germline mutation, while three siblings were not available for DNA testing. These three siblings deceased after the age of 50 years old and had no symptoms nor diagnostic evaluation. Subsequently, their offspring was offered testing for the *RET* mutation. In total, 10 children of these three siblings were tested and all did not carry the *RET* mutation, while one sibling was not available for DNA testing. This strongly suggests a *de novo* origin of the *RET* mutation in the father of the proband. Written informed consent was obtained from the patients for publication of this case report and any accompanying images.

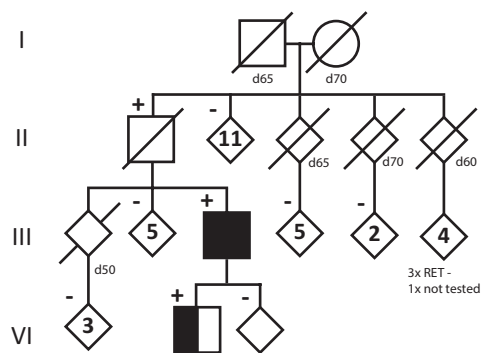


Figure 1. Multiple endocrine neoplasia type 2A pedigree showing *RET* mutation carriers (*RET*+) and non-carriers (*RET*-). Please note that the pedigree has been adjusted to protect the identity of the family without a loss of scientific integrity. Circles represent females; squares represent males; diamonds represent undisclosed gender. Ages of death (d) are given in the nearest 5-year tier, medullar thyroid carcinoma and adrenal hyperplasia (fully shaded), medullar thyroid carcinoma (half shaded), *RET* mutation carriers (*RET*+) and non-carriers (*RET*-).

DISCUSSION

In order to appreciate the relevance of apparent non-penetrance in a 93-year-old carrier of a *RET* germline mutation, we must first examine the reported genotype-phenotype correlations of the *RET* proto-oncogene codon 620. In 2011, the International RET Exon 10 Consortium, comprising 27 centres from 15 countries obtained molecular based neoplastic risk profiles and codon-specific age related penetrance.⁶ Fifty percent penetrance for MTC was achieved by the age of 31 years for mutations in codon 620, reaching 80% penetrance by age 50 and almost 100% by age 70. Given these percentages, survival beyond middle age was thought unlikely without the intervention of thyroidectomy. There was no significant difference in age at diagnosis between symptomatic and screened ascertainment for MTC. Age related penetrance in patients in whom pheochromocytomas were assessed was 23% at 50 years. Penetrance was significantly different between pheochromocytomas ascertained from symptomatic assessment and those detected under surveillance. This underscores the great importance of clinical surveillance. The International RET Exon 10 Consortium, examined 23 families with a total of 101 mutation carriers with the same mutation as our family (codon 620 c.1858T>C). The median age of MTC was 29 years, ranges 6-73 years. About 15% of these patients also had a pheochromocytoma, and 3% had hyperparathyroidism. Our case, an asymptomatic carrier of the codon 620 *RET* mutation at the age of 93 years old, albeit without any prior intervention or treatment, questions the full penetrance of this *RET* mutation. Notably, the occurrence of MTC in a 87-year-old patient was described, also with a codon 620 mutation.¹¹ Moreover, no further cases of MTC have been reported in MEN2A patients older than 75 years old, although this information may not have been the focus of reporting.

In 2015, the International Workshop on MEN published a consensus statement on the management of hereditary medullary thyroid carcinoma.¹² Carriers of the *RET* codon 620 mutation, characterised as moderate risk, are recommended to undergo prophylactic thyroidectomy during childhood, or young adulthood, the timing and extent of surgery will be guided by the serum Ctn levels (Table 1). One concern is whether it is justifiable to put children and young adults at risk for permanent recurrent laryngeal nerve palsies and permanent hypoparathyroidism.⁹ Prospective surveillance and early treatment of other manifestations of MEN2A, like pheochromocytoma and hyperparathyroidism, can reduce the morbidity and mortality.¹³

About 90-95% of individuals with MEN2A have an affected parent, and 5-10% are *de novo* cases.^{14, 15} Our 93-year-old *RET* mutation carrier is most likely one of these rare *de novo* cases, because none of his 14 siblings (or their tested offspring) were *RET* mutation carriers. Bayesian statistics lower the *a priori* chance of inherited disease from 95% to a *post prior* chance of 0.05%.

Because of the age-dependent risk ratio and the extremely rare incomplete penetrance of the mutant allele, testing for this specific mutation in asymptomatic parents of MEN2A-affected children carrying the *RET* codon 620 mutation is important.^{16, 17} Our 93-year-old patient is most likely an example of this rare incomplete penetrance. Alternatively, MTC in an apparently *de novo* patient may arise from paternal mosaicism in one or more germ layers or organ systems without *RET* mutation in peripheral blood. In our 93-year-old apparent asymptomatic person, the *RET* mutation was detected in three different germ layers; peripheral blood, colon, spleen, nasal polyps and obviously affected germ cells, making mosaicism less likely. In addition, no cases of mosaic *RET* mutations have been reported.

Inter- and intra-familial phenotypic variability is described among the MEN2 families, also when the disease is caused by the same *RET* mutation.¹⁸ At present, knowledge of possible genetic modifiers that may affect the clinical course of this disease is still limited. Some research projects suggest a role for genetic modifiers. Examples of these are additional somatic mutations¹⁹ or specific polymorphisms, such as over-representation of the G12S polymorphism of the *SDHD*

Table 1. Summary of the American Thyroid Association [2015] recommended genotype-bases management of *RET* mutation carriers¹²

ATA Group	<i>RET</i> genotype*		MEN2 classification	Recommended Start Interventions			
	Exon	Codon Mutation		PE/US/Ctn	TTX	Screening PHEO	Screening HPT
HST	16	M918T	MEN2B	1 month	before the first year of life †	11 years	NA
H	11	C634F/G/R/S/W/Y	Classical MEN2A / MEN2A with CL	3 years	at or before 5 years of age†	11 years	11 years
MOD	15	A883F	MEN2B				NA
	10	C609F/G/R/S/W/Y C611R/S/W/Y C618F/G/R/S/W/Y C620F/G/R/S/W/Y	Classical MEN2A	5 years	Childhood, or young adulthood†	16 years	16 years
		C611F	FMTC			NA	NA
		C609G C611S C618/R/S C620/R/S/W	MEN2A with HD				
	11	C630R/Y D631Y S649L K666E	Classical MEN2A			16 years	16 y
	13	E768D	FMTC			NA	NA
		L790F Y791F	Classical MEN2A			16 years	16 years
	14	V804L/M	Classical MEN2A / MEN2A with CL			16 years / NA	16 years / NA
	15	S891A	Classical MEN2A			16 years	16 years
	16	R912P	FMTC			NA	NA

ATA=American Thyroid Association risk categories (HST=highest risk, H=high risk, MOD=moderate), *RET*=REarranged during Transfection, PE=Annual physical examination, US=cervical ultrasound, Ctn= serum Calcitonin levels, TTX=Total thyroidectomy, PHEO=Pheochromocytoma, HPT=hyperparathyroidism, CL=cutaneous lichen amyloidosis, HD=Hirschsprung's Disease, FMTC=familial medullar thyroid carcinoma, NA= not applicable.*Include most common mutation and no chromosomal alterations activating *RET* such as deletions, insertions, duplications, multiple mutations, and homozygous mutations. † the timing and extent of surgery guided by serum Ctn levels.

gene in patients with MEN2A syndrome.²⁰ The high prevalence of the G12S variant in these patients supports its genetic modifier role, but this association remains to be established. Besides polymorphisms, mitochondrial DNA mutations are suggested to be involved in medullary thyroid carcinoma tumorigenesis and/or progression.²¹ MTC could harbor imbalance between mutant and wild type *RET* alleles and in addition, *RET* copy number alterations, either *RET* gene amplification or chromosome 10 aneuploidy are described.²² Less is known about protective genetic modifiers.

CONCLUSION

In the current report, we described an unusual case of apparently non-penetrance, in a 93-year-old carrier of an apparent *de novo* *RET* germline mutation. Firstly, this observation questions


the full penetrance of this *RET* germline mutation. Secondly, this case-report sheds new light on the carefully weighing of the benefit of potential cure by prophylactic thyroidectomy in older asymptomatic MEN2A carriers against over-treating in these carriers. Further investigation of genetic modifiers is warranted, to explore nucleotide specific genotype-phenotype correlations in MEN2A.

ACKNOWLEDGEMENTS

We acknowledge the family described for their kind participation, and the laboratory for molecular (DNA) diagnostics, Utrecht (In particular Dr. D. Dooijes and T. Yimam), for their very good work with the genetic analysis.

REFERENCES

- Lakhani VT, You YN, Wells SA. The multiple endocrine neoplasia syndromes. *Annu Rev Med* 2007;58:253-265.
- Peczowska M, Januszewicz A. Multiple endocrine neoplasia type 2. *Fam Cancer* 2005;4(1):25-36.
- Moline J, Eng C. Multiple endocrine neoplasia type 2: an overview. *Genet Med* 2011;13(9):755-764.
- Machens A, Lorenz K, Sekulla C et al. Molecular epidemiology of multiple endocrine neoplasia 2: implications for RET screening in the new millennium. *Eur J Endocrinol* 2013;168(3):307-314.
- Eng C, Clayton D, Schuffenecker I et al. The relationship between specific RET proto-oncogene mutations and disease phenotype in multiple endocrine neoplasia type 2. International RET mutation consortium analysis. *JAMA* 1996;276(19):1575-1579.
- Frank-Raue K, Rybicki LA, Erlic Z et al. Risk profiles and penetrance estimations in multiple endocrine neoplasia type 2A caused by germline RET mutations located in exon 10. *Hum Mutat* 2011;32(1):51-58.
- Raue F, Frank-Raue K. Update multiple endocrine neoplasia type 2. *Fam Cancer* 2010;9(3):449-457.
- Brandi ML, Gagel RF, Angeli A et al. Guidelines for diagnosis and therapy of MEN type 1 and type 2. *J Clin Endocrinol Metab* 2001;86(12):5658-5671.
- Gimm O, Ukkat J, Niederle BE et al. Timing and extent of surgery in patients with familial medullary thyroid carcinoma/multiple endocrine neoplasia 2A-related RET mutations not affecting codon 634. *World J Surg* 2004;28(12):1312-1316.
- Kouvaraki MA, Shapiro SE, Perrier ND et al. RET proto-oncogene: a review and update of genotype-phenotype correlations in hereditary medullary thyroid cancer and associated endocrine tumors. *Thyroid* 2005;15(6):531-544.
- Jaggard MK, MacRae C, Ifeachoo S, Robinson S, Tolley NS. New presentation of familial medullary thyroid carcinoma in 87-year-old patient with high-risk RET proto-oncogene codon 620 mutation. *J Laryngol Otol* 2009;123(7):796-800.
- Wells SA, Jr., Asa SL, Dralle H et al. Revised American Thyroid Association Guidelines for the Management of Medullary Thyroid Carcinoma The American Thyroid Association Guidelines Task Force on Medullary Thyroid Carcinoma. *Thyroid* 2015.
- Gagel RF, Tashjian AH, Jr., Cummings T et al. The clinical outcome of prospective screening for multiple endocrine neoplasia type 2a. An 18-year experience. *N Engl J Med* 1988;318(8):478-484.
- Eng C, Mulligan LM, Smith DP et al. Low frequency of germline mutations in the RET proto-oncogene in patients with apparently sporadic medullary thyroid carcinoma. *Clin Endocrinol (Oxf)* 1995;43(1):123-127.
- Schuffenecker I, Ginot N, Goldgar D et al. Prevalence and parental origin of de novo RET mutations in multiple endocrine neoplasia type 2A and familial medullary thyroid carcinoma. Le Groupe d'Etude des Tumeurs a Calcitonine. *Am J Hum Genet* 1997;60(1):233-237.
- Machens A, Dralle H. Multiple endocrine neoplasia type 2 and the RET protooncogene: from bedside to bench to bedside. *Mol Cell Endocrinol* 2006;247(1-2):34-40.
- Romei C, Cosci B, Renzini G et al. RET genetic screening of sporadic medullary thyroid cancer (MTC) allows the preclinical diagnosis of unsuspected gene carriers and the identification of a relevant percentage of hidden familial MTC (FMTC). *Clin Endocrinol (Oxf)* 2011;74(2):241-247.
- Wells SA, Jr., Pacini F, Robinson BC, Santoro M. Multiple endocrine neoplasia type 2 and familial medullary thyroid carcinoma: an update. *J Clin Endocrinol Metab* 2013;98(8):3149-3164.
- van VW, Klompaker R, Gloerich M et al. P18 is a tumor suppressor gene involved in human medullary thyroid carcinoma and pheochromocytoma development. *Int J Cancer* 2009;124(2):339-345.
- Lendvai N, Toth M, Valkusz Z et al. Overrepresentation of the G12S polymorphism of the SDHD gene in patients with MEN2A syndrome. *Clinics (Sao Paulo)* 2012;67 Suppl 1:85-89.
- Abu-Amro KK, Alzahrani AS, Zou M, Shi Y. Association of mitochondrial DNA transversion mutations with familial medullary thyroid carcinoma/multiple endocrine neoplasia type 2 syndrome. *Oncogene* 2006;25(5):677-684.
- Ciampi R, Romei C, Cosci B et al. Chromosome 10 and RET gene copy number alterations in hereditary and sporadic Medullary Thyroid Carcinoma. *Mol Cell Endocrinol* 2012;348(1):176-182.



PART IV

GENERAL DISCUSSION

