



Universiteit  
Leiden  
The Netherlands

## **Monogenic models of migraine : from clinical phenotypes to pathophysiological mechanisms**

Pelzer, N.

### **Citation**

Pelzer, N. (2018, November 28). *Monogenic models of migraine : from clinical phenotypes to pathophysiological mechanisms*. Retrieved from <https://hdl.handle.net/1887/67103>

Version: Not Applicable (or Unknown)

License: [Licence agreement concerning inclusion of doctoral thesis in the Institutional Repository of the University of Leiden](#)

Downloaded from: <https://hdl.handle.net/1887/67103>

**Note:** To cite this publication please use the final published version (if applicable).

Cover Page



Universiteit Leiden



The handle <http://hdl.handle.net/1887/67103> holds various files of this Leiden University dissertation.

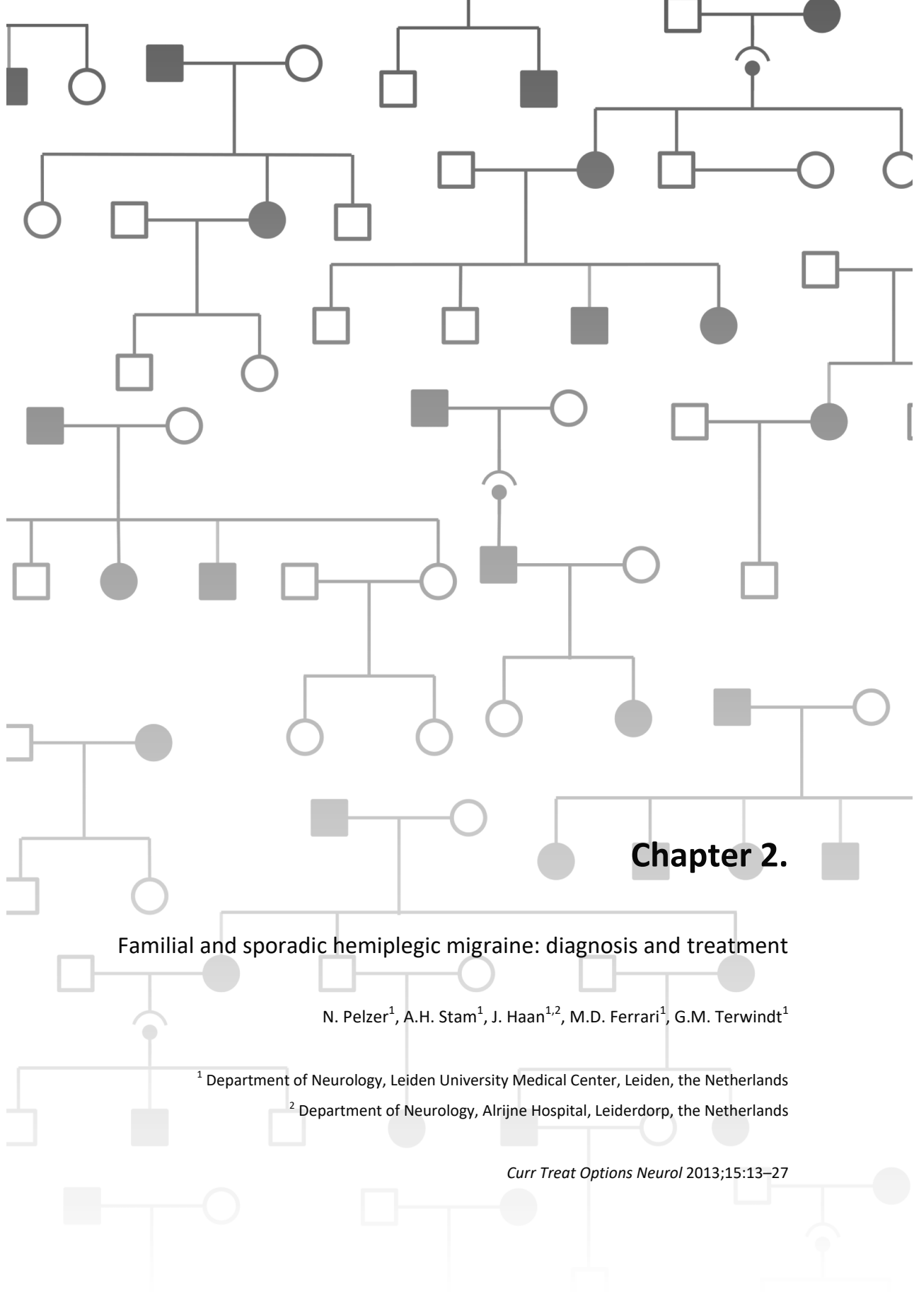
**Author:** Pelzer, N.

**Title:** Monogenic models of migraine : from clinical phenotypes to pathophysiological mechanisms

**Issue Date:** 2018-11-28

**Part I:**  
**Hemiplegic Migraine –**  
**a neuronal and glial monogenic migraine model**





## Chapter 2.

### Familial and sporadic hemiplegic migraine: diagnosis and treatment

N. Pelzer<sup>1</sup>, A.H. Stam<sup>1</sup>, J. Haan<sup>1,2</sup>, M.D. Ferrari<sup>1</sup>, G.M. Terwindt<sup>1</sup>

<sup>1</sup> Department of Neurology, Leiden University Medical Center, Leiden, the Netherlands

<sup>2</sup> Department of Neurology, Alrijne Hospital, Leiderdorp, the Netherlands

*Curr Treat Options Neurol* 2013;15:13–27

## Opinion statement

Hemiplegic migraine (HM) is a rare subtype of migraine with aura, characterised by transient hemiparesis during attacks. Diagnosis is based on the International Classification of Headache Disorders criteria (ICHD-II). Two types of HM are recognised: familial (FHM) and sporadic hemiplegic migraine (SHM). HM is genetically heterogeneous. Three genes have been identified (*CACNA1A*, *ATP1A2*, and *SCN1A*) but more, so far unknown genes, are involved. Clinically, attacks of the 3 subtypes cannot be distinguished. The diagnosis can be confirmed but not ruled out by genetic testing, because in some HM patients other, not yet identified, genes are involved. The presence of additional symptoms (such as chronic ataxia or epilepsy) may increase the likelihood of identifying a mutation. Additional diagnostics like imaging, CSF analysis, or an EEG are mainly performed to exclude other causes of focal neurological symptoms associated with headache. Conventional cerebral angiography is contraindicated in HM because this may provoke an attack. Because HM is a rare condition, no clinical treatment trials are available in this specific subgroup of migraine patients. Thus, the treatment of HM is based on empirical data, personal experience of the treating neurologist, and involves a trial-and-error strategy. Acetaminophen and NSAIDs often are the first choice in acute treatment. Although controversial in HM, triptans can be prescribed when headaches are not relieved sufficiently with common analgesics. An effective treatment for the severe and often prolonged aura symptoms is more warranted, but currently no such acute treatment is available. Prophylactic treatment can be considered when attack frequency exceeds 2 attacks per month, or when severe attacks pose a great burden that requires reduction of severity and frequency. In no strictly preferred order, flunarizine, sodium valproate, lamotrigine, verapamil, and acetazolamide can be tried. While less evidence is available for prophylactic treatment with topiramate, candesartan, and pizotifen, these drugs can also be considered. The use of propranolol in HM is more controversial, but evidence of adverse effects is insufficient to contraindicate beta-blockers.

## Introduction

Hemiplegic migraine (HM) is a rare, autosomal dominantly inherited, severe subtype of migraine with aura, with an estimated prevalence of 0.01%.<sup>1</sup> Beside common aura symptoms and migrainous headaches, attacks include transient hemiparesis varying from mild paresis to hemiplegia. Two types of HM are recognised. In Familial Hemiplegic Migraine (FHM) there is at least 1 first- or second-degree family member with HM attacks. In Sporadic Hemiplegic Migraine (SHM), the family history is negative for HM.<sup>2</sup> The core pathophysiological mechanisms of HM are considered to be similar to

those in migraine, especially in migraine with aura (MA), possibly occurring with lower threshold and more intensity, which would cause the more severe phenotype.

Migraine is considered a neurovascular disorder, with primary neuronal events secondarily affecting blood vessels.<sup>3</sup> The aura is caused by Cortical Spreading Depression (CSD), a brief wave (lasting seconds) of intense neuronal and glial depolarisation that slowly (2–5 mm/min) propagates across the cerebral cortex, followed by neuronal suppression.<sup>4</sup> This would account for the spreading character and propagation rate of aura symptoms. Depressed neuronal function presumably leads to oligemia, which passes across the cortex, preceded by a short phase of hyperemia, respectively representing negative and positive aura features.<sup>5</sup> Functional neuroimaging studies revealed similarities between blood flow changes in patients experiencing auras and CSD in experimental animals, suggesting CSD indeed occurs in humans.<sup>6</sup> Genetic and environmental factors may lower the CSD threshold, thereby increasing migraine susceptibility. The theory that dilatation of cranial arteries would cause migraine headaches, was reinforced by the beneficial effects of the potent vasoconstrictors ergot alkaloids and triptans.<sup>7,8</sup> However, imaging studies showed conflicting results, with some demonstrating dilatation of cerebral arteries, while others did not detect any blood flow changes during migraine headache.<sup>9,10</sup> Nowadays the trigeminovascular system is thought to play a central role. Activation of trigeminovascular efferents, which may be initiated by CSD, is postulated to cause release of vasoactive neuropeptides (e.g., CGRP, substance P, and NO) and thus leads to neurogenic inflammation and headache.<sup>11</sup> In addition, peripheral or central sensitization may cause altered perception of usually non-painful stimuli.<sup>12</sup>

As HM is rare and attack frequency is low, clinical drug trials have so far been deemed impossible and treatment largely follows guidelines for the common forms of migraine. There are no specific treatments for patients with known mutations. Most migraine-specific drugs for acute treatment only affect headache, whereas auras in HM often pose a greater burden to patients. Prophylactic treatment may not be strictly required because of low attack frequencies, but still prescribed because of the attacks' severity. Case reports and case series are currently the only guidelines for acute and prophylactic treatment of HM, and will be discussed in greater detail.

## Diagnosis

### Clinical symptomatology

Clinical diagnosis of HM is based on a physician's interview, led by the ICHD criteria of the International Headache Society (IHS) (see Table 1<sup>2</sup>), and a physical examination, which mainly serves

**Table 1:** Criteria for Familial Hemiplegic Migraine (FHM) and Sporadic Hemiplegic Migraine (SHM) by the International Headache Society.<sup>2</sup>

<p><b>Diagnostic criteria for FHM:</b></p> <p>A. At least 2 attacks fulfilling criteria B and C</p> <p>B. Aura consisting of fully reversible motor weakness and at least one of the following:</p> <ol style="list-style-type: none"> <li>1. fully reversible visual symptoms including positive features (e.g., flickering lights, spots or lines) and/or negative features (i.e., loss of vision)</li> <li>2. fully reversible sensory symptoms including positive features (i.e., pins and needles) and/or negative features (i.e., numbness)</li> <li>3. fully reversible dysphasic speech disturbance</li> </ol> <p>C. At least two of the following:</p> <ol style="list-style-type: none"> <li>1. at least one aura symptom develops gradually over <math>\geq 5</math> minutes and/or different aura symptoms occur in succession over <math>\geq 5</math> minutes</li> <li>2. each aura symptom lasts <math>\geq 5</math> minutes and <math>&lt; 24</math> hours</li> <li>3. headache fulfilling criteria B-D for 1.1 <b>Migraine without aura</b> begins during the aura or follows onset of aura within 60 minutes</li> </ol> <p>D. At least one first- or second-degree relative has had attacks fulfilling these criteria A-E</p> <p>E. Not attributed to another disorder</p>
<p><b>Diagnostic criteria for SHM:</b></p> <p>A. At least 2 attacks fulfilling criteria B and C</p> <p>B. Aura consisting of fully reversible motor weakness and at least one of the following:</p> <ol style="list-style-type: none"> <li>1. fully reversible visual symptoms including positive features (e.g., flickering lights, spots or lines) and/or negative features (i.e., loss of vision)</li> <li>2. fully reversible sensory symptoms including positive features (i.e., pins and needles) and/or negative features (i.e., numbness)</li> <li>3. fully reversible dysphasic speech disturbance</li> </ol> <p>C. At least two of the following:</p> <ol style="list-style-type: none"> <li>1. at least one aura symptom develops gradually over <math>\geq 5</math> minutes and/or different aura symptoms occur in succession over <math>\geq 5</math> minutes</li> <li>2. each aura symptom lasts <math>\geq 5</math> minutes and <math>&lt; 24</math> hours</li> <li>3. headache fulfilling criteria B-D for 1.1 <b>Migraine without aura</b> begins during the aura or follows onset of aura within 60 minutes</li> </ol> <p>D. No first- or second-degree relative has attacks fulfilling these criteria A-E</p> <p>E. Not attributed to another disorder</p>

to exclude other disorders. To diagnose FHM, obtaining the family history is essential. HM patients have an increased risk to also suffer from attacks of the common forms of migraine with (MA) and without aura (MO) (i.e., a co-prevalence risk of 55% for MA and 25% for MO), which often makes the interview difficult.<sup>13</sup> It may be challenging to distinguish complaints of sensory disturbances from those of a mild paresis. Apart from motor auras, which are only experienced by HM patients, the symptoms and their order of appearance during attacks are very similar for HM and MA.<sup>14</sup> However, HM patients are more likely to experience 2 or more aura symptoms, symptoms of longer duration, and more often have basilar-type auras than MA patients.<sup>14,15</sup> The mean age at onset of FHM is around 17 years (95% CI: 15–18; range 1–45 years), which is lower than the average of 21 years for familial MA.<sup>14</sup> HM attack frequency, though variable, is much lower than that of MA with an average of 3 attacks per year.<sup>16</sup> Similar to MO and MA, HM is 2–4 times more prevalent in females.<sup>1,14</sup> Severe atypical HM attacks may be prolonged (up to 6 weeks) and accompanied by confusion, decreased consciousness, fever, seizures, and even coma.<sup>17–19</sup> These symptoms may divert



physicians to other diagnoses. Triggering of attacks by a minor head trauma is commonly reported, with an average prevalence of 9% in a large FHM cohort. Cerebral or coronary angiography can also trigger attacks.<sup>17</sup> Based on clinical symptoms alone, subtypes of HM cannot be distinguished, although the presence of additional symptoms (such as chronic progressive ataxia or epilepsy) may be suggestive of certain genetic subtypes.

## Genetic testing

HM is genetically heterogeneous, with 3 identified genes. FHM shows autosomal dominant inheritance. FHM1 and SHM1 are caused by mutations in the *CACNA1A* gene on chromosome 19p13, encoding the ion-conducting,  $\alpha 1A$  -subunit of P/Q-type voltage-gated  $Ca^{2+}$ -channels.<sup>20</sup> These channels are localised in presynaptic nerve terminals of central neurons and when activated increase neurotransmission.<sup>21</sup> Over 25 HM-associated *CACNA1A* mutations are identified, representing a broad clinical spectrum.<sup>21</sup> FHM1 families with chronic progressive cerebellar signs, decreased level of consciousness and seizures during HM attacks have been described.<sup>17,22</sup> The p.S218L *CACNA1A* mutation is associated with a particularly severe phenotype, in which minor head trauma led to seizures, cerebral edema, and even fatal coma.<sup>18</sup> The FHM2/SHM2 *ATP1A2* gene on chromosome 1q23 encodes the  $\alpha 2$ -subunit of a  $Na^+/K^+$ -ATPase. This pump exchanges  $Na^+$  ions for  $K^+$  ions, creating a steep sodium gradient that facilitates removal of  $K^+$  and glutamate from the synaptic cleft into glial cells.<sup>21</sup> Nearly 50 *ATP1A2* mutations have been identified, with increasing reports of additional clinical features, such as epilepsy, permanent mental retardation, prolonged hemiplegia, confusion, and coma.<sup>19,21,23–25</sup> In clear contrast to FHM1/SHM1, progressive cerebellar signs are rare in FHM2/SHM2.<sup>26</sup> The FHM3 *SCN1A* gene on chromosome 2q24 encodes the  $\alpha$ -subunit of voltage-gated  $Na^+$ -channels, which are expressed on inhibitory central neurons, and when dysfunctional may cause neuronal hyperexcitability.<sup>27</sup> So far, *SCN1A* mutations have only been found in FHM, which justifies refraining from systematic screening of the *SCN1A* gene in SHM.<sup>28,29</sup>

HM mutations all convert to a mechanism of increased cerebral levels of  $K^+$  and glutamate in the synaptic cleft, which would increase neuronal excitability, and thereby can explain the increased susceptibility to Cortical Spreading Depression (CSD).<sup>21</sup>

Reported mutation detection rates vary between FHM and SHM. Although mutations appear to be more often detected in FHM, large unselected cohorts of FHM patients revealed *CACNA1A* mutations in 4%–7%,<sup>30,31</sup> and *ATP1A2* mutations in 7%,<sup>30</sup> while reported mutation detection rates in SHM range from 1%–36% for *CACNA1A*,<sup>28,29,32,33</sup> and from 1%–56% for *ATP1A2*.<sup>28,29,32</sup> In another

study, 45% of 20 FHM families had mutations in the *CACNA1A* or *ATP1A2* gene.<sup>27</sup> These large differences in detection rates may be explained by confusing severe MA with HM, or by investigating families with fewer affected individuals or more phenocopies (affected family members that are expected to be mutation carriers but are in fact not). Notably, mutation detection rates in SHM appeared to be higher in early-onset SHM, especially when associated with additional neurological symptoms.<sup>28</sup> Some clinically unaffected relatives carry *CACNA1A* or *ATP1A2* mutations, revealing reduced penetrance.<sup>23,29,30</sup> FHM3 families have thus far shown 100% penetrance, though only 5 *SCN1A* mutations have been described.<sup>21</sup> As some clinically affected individuals do not have a mutation in any of the known genes, there are likely more HM genes to be identified. It is important to realise that negative test results for mutations in *CACNA1A*, *ATP1A2*, and *SCN1A* do not exclude the clinical diagnosis of HM.

## Imaging

A cerebral MRI is recommended in every new HM patient to exclude other (structural) causes, especially when aura symptoms always occur on the same side. Permanent CT or MRI abnormalities are rare in HM. Cerebellar atrophy has been described in FHM1 patients with progressive cerebellar ataxia.<sup>22,34</sup> In a few cases, cortical cerebral atrophy or diffuse cortical and subcortical hyperintensities on T2-weighted MRI were found.<sup>35</sup> During and shortly after HM attacks, reversible CT or MRI abnormalities have been described, which can be linked to both vascular and neuronal mechanisms. Most often reported is diffuse (cortical) edema of the hemisphere contralateral to the motor deficit.<sup>36–39</sup> However, whether this concerns vasogenic or cytotoxic edema or both, has not been unequivocally elucidated. Some MRIs show mild gadolinium enhancement, which indicates opening of the blood-brain barrier and vasogenic edema.<sup>40–42</sup> Other MRIs have shown reversible decrease in water diffusion, indicative of cytotoxic edema.<sup>36,40</sup> Both hyper- and hypoperfusion of a single hemisphere have been observed with different techniques.<sup>37,42,43</sup> For all these phenomena it is difficult to determine whether they are primary or secondary. Large systematic follow-up imaging series using the same techniques in each patient are still lacking.

## Electroencephalography (EEG)

EEG abnormalities have been recorded many times during and after HM attacks, consisting of diffuse one-sided slow waves (theta- and/or delta-activity) in the hemisphere contralateral to the side of the motor symptoms.<sup>25</sup> Such EEG abnormalities can thus support the suspicion of HM. Spike-and-wave complexes have only been recorded in cases where epileptic seizures were observed simultaneously.<sup>34,44</sup>

## Cerebral angiography

Conventional and MR angiography have shown narrowing or even obliteration of intracranial arteries in the acute phase, though never followed by signs of ischemia.<sup>45,46</sup> Dilatation of the middle cerebral artery has also been demonstrated.<sup>42</sup> Conventional cerebral angiography has however been reported to provoke HM attacks, or worsen a patient's condition dramatically.<sup>17,19,35,47</sup> Cerebral angiography via a catheter is therefore contraindicated in HM, and alternatives such as MR or CT angiography are recommended.

## Differential diagnosis

Sensory auras may cause the sensation of being unable to grasp or lift objects and may be interpreted as mild motor auras. Differences between loss of strength, numbness or lack of coordination must be emphasised during patient interviews. Symptomatic causes must be suspected when auras always occur on the same side, and cerebral vasculitis, arteriovenous malformations, arterial dissections, and brain tumors must be excluded by CT or MRI imaging. Though epilepsy and HM often co-occur, Todd's palsies can be confused with motor auras.<sup>17,24,44</sup> Migraine auras often start insidiously (within minutes), in contrast to vascular events or epileptic seizures that develop suddenly or within seconds. If an ischemic event cannot be excluded sufficiently, patients must be screened for thromboembolic disease.

HM may be accompanied by fever and decreased level of consciousness, making it difficult to distinguish from a meningo-encephalitis.<sup>38</sup> CSF lymphocytosis and elevated protein levels have often been reported during HM attacks.<sup>48</sup>

Approximately 100 cases of transient headache with neurological deficits and cerebrospinal fluid lymphocytosis (HaNDL) have been described, with remarkable resemblance to HM.<sup>49,50</sup> CSF analysis reveals lymphocytosis and often increased protein levels, with normal neuroimaging, CSF culture, and virological tests. Transient, focal, nonepileptiform EEG changes, provocation of attacks by cerebral angiography, and even reversible radiological abnormalities are however reported.<sup>49-52</sup> While these characteristics are all congruent with HM, the spontaneous resolution of HaNDL within 3 months by definition is not. However, recurrence of attacks after 3 months cannot be excluded in most HaNDL patients, despite follow-up of up to 3 years. Apart from an incidental fever, the viral prodrome and fever in 50% of HaNDL cases has not been described in HM. Visual auras were reported by 18% of HaNDL patients, compared with 89%–91% of HM patients.<sup>16\*,49</sup> Genetic screening for HM was negative, but was only performed for the *CACNA1A* gene in 8 HaNDL patients.<sup>53</sup> Given all

these similarities, HaNDL may not be a separate disorder, but part of the HM phenotypic spectrum, which however remains to be established.

When episodic hemiplegia occurs before the age of 18 months, alternating hemiplegia of childhood (AHC) may be considered. Recently, mutations in the *ATP1A3* gene were discovered in over 70% of AHC patients, enabling confirmation of AHC and differentiation from HM.<sup>54</sup> A positive family history may point towards FHM, but it must be kept in mind that hemiplegic or prolonged aura attacks have been described in familial disorders such as cerebral autosomal dominant arteriopathy with subcortical infarcts and leukoencephalopathy (CADASIL),<sup>55</sup> and mitochondrial myopathy with encephalopathy, lactic acidosis, and stroke (MELAS).<sup>56</sup>

## Treatment

### Diet and lifestyle

Stress, bright lights, sleep disturbances, physical exertion, drinks, and food products have all been reported as trigger factors for HM.<sup>57</sup> Recent evidence suggests that stress is more likely part of the premonitory phase of the migraine attack than a trigger, which may also apply to the other trigger factors.<sup>58</sup> A trigger factor that is convincingly described in HM is (minor) head trauma, which is often followed by severe attacks, sometimes including coma.<sup>17,22,25,43,44</sup> In specific cases with the p.S218L *CACNA1A* mutation, attacks were even fatal.<sup>18</sup> Based on these cases, patients can be advised not to practice contact sports.

### Pharmacologic treatment

#### **Prophylactic treatment with reported efficacy (see Table 2 for additional drug information)**

##### ***Flunarizine***

In animal studies, the long-acting Ca<sup>2+</sup>-channel blocker flunarizine was suggested to block neuronal Na<sup>+</sup> and Ca<sup>2+</sup> currents and raise CSD thresholds, possibly decreasing cortical hyperexcitability.<sup>59</sup> Flunarizine 10 mg daily was effective in 3 HM case reports.<sup>39,60,61</sup> In a pediatric case series including 5 FHM and 8 SHM patients, flunarizine reduced attack frequency in 85%, compared with 51% in MO and MA patients. Adverse events were reported by 20% of the 72 patients, leading to discontinuation in 18%. These results may suggest that flunarizine is effective in HM.<sup>62</sup>

### **Verapamil**

Verapamil blocks L-type  $\text{Ca}^{2+}$ -channels, but at high doses may also block P/Q-type channels, which are involved in FHM1.<sup>63</sup> In an HM patient, attack frequency decreased with oral verapamil 240 mg daily.<sup>64</sup> Five other SHM patients were either headache free or reported reduced attack severity and frequency on oral verapamil dosages of 120 to 360 mg daily.<sup>65,66</sup>

### **Sodium valproate**

Sodium valproate inhibits GABA transaminase, activates glutamic acid decarboxylase, and blocks  $\text{Na}^+$ -channels and low-voltage-activated T-type  $\text{Ca}^{2+}$ -channels, causing enhanced neuronal inhibition.<sup>67</sup> Efficacy in migraine is often reported, including migraine with persistent aura, but efficacy in HM is only described in a case with co-occurring epilepsy, for both the generalised tonic-clonic seizures and the following HM attacks.<sup>24,68,69</sup>

### **Lamotrigine**

Lamotrigine inhibits glutamate release by blocking voltage-gated  $\text{Na}^+$ -channels and N- and P/Q-type voltage-activated  $\text{Ca}^{2+}$ -channels.<sup>70</sup> In a double-blind randomised trial in the common forms of migraine, lamotrigine failed to show a benefit over placebo as prophylaxis.<sup>71</sup> Nonetheless, in 2 MA patients, persistent visual auras resolved after 100 mg lamotrigine daily.<sup>72</sup> Two pilot studies, one of which included patients with motor auras, observed beneficial effects on aura frequency and duration, not specified for aura symptoms.<sup>73,74</sup> A study in 59 patients showed reduced frequency and intensity of all aura symptoms in 75% of patients, including 8 patients with motor auras.<sup>75</sup> Two HM patients in a cohort with severe migraine auras showed reduced attack frequency after 3 to 6 months of 100–150 mg lamotrigine daily.<sup>76</sup> None of the studies reported an effect on headache. The specific effect on auras in these studies suggests a role for lamotrigine in treatment of migraine with disabling auras, such as HM.

### **Acetazolamide**

Acetazolamide is clinically effective in episodic ataxia type 2 (EA-2), which is also caused by *CACNA1A* mutations.<sup>20</sup> Acetazolamide inhibits carbonic anhydrase and lowers serum bicarbonate levels. Modulation of pH may aid in stabilizing abnormal ion channels.<sup>77</sup> Acetazolamide 250 mg b.i.d. has been reported to either cease attacks or decrease attack frequency in 7 HM patients.<sup>22,78–80</sup> Attacks relapsed in 2 patients after dosage reduction or discontinuation.<sup>79,80</sup> An open trial including 5 patients with motor auras reported a stronger effect on attack frequency for MA than MO, but effects were not specified for aura symptoms.<sup>81</sup> A randomised, placebo-controlled trial with

Table 2: Additional information on prophylactic and abortive drugs with reported efficacy in hemiplegic migraine.

Drug	Standard dosage	Contraindications	Main drug interactions	Main side effects	Special points	Costs
Flunarizine	10 mg daily	Depression, parkinsonism, extrapyramidal syndrome.	Phenytoin and carbamazepine reduce plasma levels, antacids and proton pump inhibitors lower biological availability. Alcohol and other central depressants amplify sedative effects.	Weight gain, increased appetite, drowsiness, depression, fatigue, extrapyramidal reactions.	Treatment should be stopped after 6 months, and only restarted when attacks return. Contraindicated during pregnancy or lactation (effects unknown).	Relatively inexpensive.
Verapamil	120 mg 2–3 times daily, with a maximum of 240 mg 3 times daily.	Heart failure, 2 <sup>nd</sup> or 3 <sup>rd</sup> degree atrioventricular block, Wolff-Parkinson-White syndrome, sick-sinussyndrome, paroxysmal atrial fibrillation or flutter, sinusbradycardia, hypotension or recent myocardial infarction.	Beta-blockers, flecainide and amiodarone increase cardiac depressant effects; increased risk of bradycardia, conduction disturbances and digoxin toxicity with digoxin; remifentanyl and sufentanil increased risk of bradycardia and hypotension; lithium has unpredictable interactions; verapamil increases blood alcohol levels.	Dizziness, headache, chest tightness, flushing, bradycardia, atrioventricular block (1 <sup>st</sup> degree), worsening of heart failure, hypotension, edema, nausea, fatigue and hyperprolactinaemia.	Contraindicated during the first trimester of pregnancy, and only on strict indication during second and third trimester.	Relatively inexpensive.
Sodium valproate	500–2000 mg daily, in divided doses.	Liver or pancreas dysfunction, hemorrhagic diathesis, porphyria.	Increased effects of barbiturates, antipsychotics, MAO-inhibitors, benzodiazepines, primidone, antidepressants, acetylsalicylic acid and anticoagulants; potentiation of toxic effect of carbamazepine; decreased metabolism of lamotrigine with increased risk of skin rashes; increased levels of valproate with felbamate; increased metabolism of valproate and risk of convulsions with mefloquine; decrease of valproate levels with carbapenems.	Gastro-intestinal complaints, weight gain, tremor, liver damage, drowsiness, apathy, ataxia, confusion, encephalopathy, increased bleeding time due to an effect on trombocyte aggregation, and rarely bone marrow suppression.	Contraindicated in pregnancy because of risk of teratogenicity. Check children for side effects during lactation.	Relatively inexpensive.

Drug	Standard dosage	Contraindications	Main drug interactions	Main side effects	Special points	Costs
Lamotrigine	Start-up dosage of 25 mg daily, slowly increasing to 100–200 mg daily, with a maximum of 500 mg daily.	None reported.	Effects on lamotrigine's glucuronidation may require dosage adjustments: decreased levels with concurrent use of phenytoin, carbamazepine, phenobarbital, primidol; increased plasma levels of oxcarbazepine and topiramate; increased levels and a higher chance of skin rash with valproate; decreased levels with oral contraceptives (which should be taken continuously).	Skin rash, dizziness, sleep disturbances, nausea, ataxia.	May increase reaction time. Abrupt withdrawal must be avoided. During pregnancy use only low doses and check blood levels. Check children for side effects during lactation.	Relatively expensive.
Acetazolamide	250 to 1000 mg per day in divided doses.	Chronic noncongestive angle-closure glaucoma, sodium or potassium depletion, hyperchloremic acidosis, liver- and kidney insufficiency, M. Addison, pulmonary heart disease, hypersensitivity to sulphonamides.	Increased risk of metabolic acidosis and central toxicity with salicylates; increased risk of hypopotassemia with potassium wasting diuretics and corticosteroids; increased risk of osteomalacia with anticonvulsants; increased serum levels of phenytoin; increased renal excretion of lithium and primidone; reduced renal excretion of quimidine and methadon; potentiation of folic acid antagonists, oral hypoglycaemic agents and oral anticoagulants.	Paresthesiae, drowsiness, fatigue, dizziness, depression, weight loss and gastrointestinal disturbances.	With prolonged use and/or high dosages a metabolic acidosis can develop. Contraindicated in pregnancy or during lactation.	Relatively expensive.

**References:** Information on contraindications, main drug interactions, main side effects and special points: from MIMS online, Pharmacotherapeutic Compass (Dutch)  
**Costs:** based on calculations by the collective of health insurances in the Netherlands: The consumer reimbursement price is based on the Pharmacy Purchase Price and includes 6% VAT as well as a 6.82% clawback (with a maximum of € 6.80 per prescription), but without the dispensing fee for the pharmacist.

acetazolamide 250 mg b.i.d. for common migraine was stopped prematurely due to a high side effect rate of 80% (especially paresthesiae) and 34% drop out of patients.<sup>82</sup> Such results were unexpected, as EA-2 patients report good tolerance.<sup>77</sup> When other prophylactic drugs do not show efficacy, acetazolamide could be used in HM, with strict monitoring of side effects.

### ***Other prophylactic drugs***

Topiramate is a drug of first choice in prophylaxis of MO and MA and influences activity of Na<sup>+</sup>- and Ca<sup>2+</sup>-channels, GABA-A receptors and the AMPA/kainate subtype of glutamate receptors. It may also weakly inhibit subtypes of carbonic anhydrases.<sup>68,83</sup> Efficacy of topiramate in HM specifically has not been described. The only report mentions worsening of HM symptoms after 2 trials of 25 mg topiramate during 5 and 7 days, with prompt recovery after discontinuation.<sup>84</sup> Candesartan and pizotifen are drugs of second choice in migraine. Though clinical experience with these 3 drugs may be good, there is no literature to support prescription in HM yet.

### **Controversial prophylactic drugs**

#### ***Beta-blockers***

Propranolol and metoprolol are non-selective beta-blockers, with membrane-stabilizing properties and no intrinsic sympathicomimetic activity. Though commonly prescribed in migraine, beta-blockers have been postulated to induce cerebral infarcts or prolonged aura in migraineurs, partly by reducing cerebral blood flow.<sup>83,85</sup> Other reports however, suggest that cerebral blood flow is not altered,<sup>86</sup> and beneficial effects of propranolol in HM have been reported.<sup>22</sup> Cessation of attacks or decreased attack frequency was described in 2 FHM patients with propranolol and pizotifen.<sup>87</sup> Three other HM patients showed complete cessation of attacks for 13 months to 3 years with propranolol in daily doses of 30 to 80 mg.<sup>88</sup> Propranolol 160 mg daily resulted in marked reduction of aura and headache duration in another HM patient, but without improved attack frequency.<sup>43</sup> HM patients treated with metoprolol have not been described. Prescribing propranolol in HM remains controversial, and careful monitoring after the first use must be considered.

### **Abortive treatment with reported efficacy (see Table 2 for additional drug information)**

Abortive treatment with 5 mg IV verapamil ceased headache and auras in 3 patients, during multiple HM attacks.<sup>64,65,89</sup> Acute treatment with acetazolamide in an FHM patient resolved aura symptoms within 1–3 h on 5 occasions, whereas normally hospitalization used to be required.<sup>90</sup>



## Controversial abortive drugs

### *Ergot alkaloids and triptans*

Ergot alkaloids and triptans are migraine-specific drugs for acute headache treatment. Ergot alkaloids interact with adrenergic, dopaminergic, and serotonergic receptors, including agonist effects on several 5-HT<sub>1</sub> receptor subtypes, and block release of substance P, and CGRP.<sup>7</sup> Triptans are 5-HT<sub>1B/1D</sub> receptor agonists, which constrict distended cerebral blood vessels and inhibit release of vasoactive neuropeptides and neurotransmitters from trigeminal nerves.<sup>8</sup> Triptans seem more effective than ergot alkaloids in clinical studies, and are preferred because of fewer side effects.<sup>91</sup> A study in isolated human coronary arteries deemed it unlikely that therapeutic levels of ergot alkaloids and triptans would cause cardiac ischemia in healthy individuals, though they remain contraindicated in coronary disease. Vasoconstriction lasted approximately 3 times longer with ergots than with triptans, making triptans the safer choice.<sup>92</sup> As auras were ascribed mainly to vasoconstriction, a fear of migrainous strokes or aggravation of auras led to the contraindication of triptans in HM. As CSD is now thought to underlie auras, physicians are questioning this contraindication.<sup>93</sup> Thirteen migraineurs with prominent auras, including motor auras in 4 patients, were treated with several triptans without adverse events.<sup>93</sup> A Finnish cohort of 40 FHM and 36 SHM patients showed good to excellent response to triptans in 47 patients and poor response in only 11 patients. Side effects were minor, like chest pain, nausea and fatigue, although a triptan may have induced or enhanced 1 HM attack.<sup>94</sup> Serious adverse events with triptans in HM appear to be rare, and beneficial effects on the disabling attacks may overrule the risks.

### *Ketamine*

Ketamine is a non-competitive N-methyl-d-aspartate-receptor Ca<sup>2+</sup>-channel antagonist that blocks glutamate, and may also interact with opioid receptors. In clinical studies, ketamine produced general and local anesthesia.<sup>95</sup> As NMDA-receptor antagonists blocked CSD in animal studies, trial doses of 25 mg ketamine were administered via a nasal spray to 11 FHM patients, with some improvement of auras and headache severity, while 6 patients reported no benefits, and feelings of alienation and mild ataxia were reported as side effects.<sup>96</sup> Because ketamine may cause dependence and tolerance with prolonged use, and has dangerous effects in larger dosages, its use is currently not considered appropriate for HM patients.

### *Nimodipine*

Apart from possible efficacy of flunarizine and verapamil, not all calcium antagonists appear to be safe in HM. A trial treatment with IV nimodipine 5–10 ml per h in HM with prolonged aura led to

worsening of aura symptoms within hours and a generalised tonic-clonic seizure the next day. Though nimodipine may prevent vasospasms by lowering the calcium influx, in this case it may have increased arterial hypotension, resulting in cerebral hypoperfusion and hypoxia. Because of the severe adverse events in this case, nimodipine is not advised in prolonged HM attacks.<sup>43</sup>

### **Future pharmacologic treatment**

#### ***CGRP receptor antagonists***

CGRP is involved in sensory neurotransmission, and is present in meningeal trigeminovascular afferents that may be involved in migraine.<sup>11</sup> CGRP antagonists, such as telcagepant, have been effective in acute migraine treatment in several clinical trials and appear not to cause vasoconstriction, which would be a major benefit compared with triptans<sup>97,98</sup> Evidence of liver toxicity with prophylactic use has however halted further trials with telcagepant, and efficacy in HM has not yet been investigated.<sup>99\*</sup>

### **Interventional procedures – surgery-assistive devices**

Neuromodulation is rapidly emerging in the treatment of various headache disorders.<sup>100</sup> No studies have yet been performed in HM, and although some devices seem promising in headache treatment, specific trials will have to be awaited. The same is true for injections with botulinum toxin.

### **Pediatric considerations**

Because HM attacks often start at a young age, many case reports concern children. Children under 5 years old are rarely diagnosed with HM, because they are unable to express their complaints. The prophylactic drugs acetazolamide, lamotrigine, sodium valproate, flunarizine, propranolol, topiramate, and pizotifen can be used in dosages adjusted to the child's bodyweight. The efficacy and safety of candesartan has not been investigated in children. Ergot alkaloids are insufficiently investigated in children and should not be prescribed. Triptans should not be prescribed to children under 12 years old and only considered if children just under 18 years old have an adult body weight.

**Acknowledgments:** This work was supported by grants of the Netherlands Organization for Scientific Research (NWO) (VICI 918.56.602, M.D.F.; 907-00-217, G.M.T.; 920-03-473, A.H.S.; VIDI 91711319, G.M.T.)

**Disclosure:** Dr. Pelzer received support for conference visits from Menarini and Allergan UK. Dr. Ferrari received grant and consultancy or industry support from Almirall, Coherex, Colucid, Eisai, GlaxoSmithKline,

Linde, MAP, Medtronic, Menarini, Merck & Co., Minster, Pfizer, Allergan, and St. Jude and independent support from NWO, NIH, European Community FP6, Biomed EC, and the Dutch Heart Foundation. Dr. Terwindt received grant and consultancy/industry support from Merck & Co., Janssen-Cilag, Allergan, and Menarini, and independent support from NWO. Dr. Stam and Dr. Haan reported no potential conflicts of interest relevant to this article.

## References and Recommended Reading

Papers of particular interest, published recently, have been highlighted as • Of importance

1. Thomsen LL, Kirchmann EM, Faerch RS, et al. An epidemiological survey of hemiplegic migraine. *Cephalalgia* 2002;22:361–375.
2. The International Classification of Headache Disorders: 2nd edition. *Cephalalgia* 2004;24:9–160.
3. Goadsby PJ, Lipton RB, Ferrari MD. Migraine – current understanding and treatment. *N Engl J Med* 2002;346:257–270.
4. Lauritzen M. Pathophysiology of the migraine aura. The spreading depression theory. *Brain* 1994;117:199–210.
5. Olesen J, Larsen B, Lauritzen M. Focal hyperemia followed by spreading oligemia and impaired activation of rCBF in classic migraine. *Ann Neurol* 1981;9:344–352.
6. Hadjikhani N, Sanchez Del Rio M, Wu O, et al. Mechanisms of migraine aura revealed by functional MRI in human visual cortex. *Proc Natl Acad Sci USA* 2001;98:4687–4692.
7. Bigal ME, Tepper SJ. Ergotamine and dihydroergotamine: a review. *Curr Pain Headache Rep* 2003;7:55–62.
8. Ferrari MD, Saxena PR. Clinical and experimental effects of sumatriptan in humans. *Trends Pharmacol Sci* 1993;14:129–133.
9. Schoonman GG, van der Grond J, Kortmann C, et al. Migraine headache is not associated with cerebral or meningeal vasodilatation—a 3 T magnetic resonance angiography study. *Brain* 2008;131:2192–2200.
10. Asghar MS, Hansen AE, Amin FM, et al. Evidence for a vascular factor in migraine. *Ann Neurol* 2011;69:635–645.
11. Stam AH, Haan J, van den Maagdenberg AM, et al. Migraine and genetic and acquired vasculopathies. *Cephalalgia* 2009;29:1006–1017.
12. Burstein R, Yarnitsky D, Goor-Aryeh I, et al. An association between migraine and cutaneous allodynia. *Ann Neurol* 2000;47:614–624.
13. Thomsen LL, Olesen J, Russell MB. Increased risk of migraine with typical aura in probands with familial hemiplegic migraine and their relatives. *Eur J Neurol* 2003;10:421–427.
14. Eriksen MK, Thomsen LL, Olesen J. Implications of clinical subtypes of migraine with aura. *Headache* 2006;46:286–297.
15. Haan J, Terwindt GM, Ophoff RA, et al. Is familial hemiplegic migraine a hereditary form of basilar migraine? *Cephalalgia* 1995;15:477–481.
16. • Russell MB, Ducros A. Sporadic and familial hemiplegic migraine: pathophysiological mechanisms, clinical characteristics, diagnosis, and management. *Lancet Neurol* 2011;10:457–470.
17. Ducros A, Denier C, Joutel A, et al. The clinical spectrum of familial hemiplegic migraine associated with mutations in a neuronal calcium channel. *N Engl J Med* 2001;345:17–24.

18. Kors EE, Terwindt GM, Vermeulen FL, et al. Delayed cerebral edema and fatal coma after minor head trauma: role of the *CACNA1A* calcium channel subunit gene and relationship with familial hemiplegic migraine. *Ann Neurol* 2001;49:753–760.
19. Jurkat-Rott K, Freilinger T, Dreier JP, et al. Variability of familial hemiplegic migraine with novel *ATP1A2* Na<sup>+</sup>/K<sup>+</sup>-ATPase variants. *Neurology* 2004;62:1857–1861.
20. Ophoff RA, Terwindt GM, Vergouwe MN, et al. Familial hemiplegic migraine and episodic ataxia type-2 are caused by mutations in the Ca<sup>2+</sup> channel gene *CACNL1A4*. *Cell* 1996;87:543–552.
21. de Vries B, Frants RR, Ferrari MD, van den Maagdenberg AMJM. Molecular genetics of migraine. *Hum Genet* 2009;126:115–132.
22. Kors EE, Haan J, Giffin NJ, et al. Expanding the phenotypic spectrum of the *CACNA1A* gene T666M mutation: a description of 5 families with familial hemiplegic migraine. *Arch Neurol* 2003;60:684–688.
23. Riant F, De Fusco M, Aridon P, et al. *ATP1A2* mutations in 11 families with familial hemiplegic migraine. *Hum Mutat* 2005;26:281.
24. Lebas A, Guyant-Marechal L, Hannequin D, et al. Severe attacks of familial hemiplegic migraine, childhood epilepsy and *ATP1A2* mutation. *Cephalalgia* 2008;28:774–777.
25. Vanmolkot KR, Stroink H, Koenderink JB, et al. Severe episodic neurological deficits and permanent mental retardation in a child with a novel FHM2 *ATP1A2* mutation. *Ann Neurol* 2006;59:310–314.
26. Spadaro M, Ursu S, Lehmann-Horn F, et al. A G301R Na<sup>+</sup>/K<sup>+</sup>-ATPase mutation causes familial hemiplegic migraine type 2 with cerebellar signs. *Neurogenetics* 2004;5:177–185.
27. Dichgans M, Freilinger T, Eckstein G, et al. Mutation in the neuronal voltage-gated sodium channel *SCN1A* in familial hemiplegic migraine. *Lancet* 2005;366:371–377.
28. Riant F, Ducros A, Ploton C, et al. De novo mutations in *ATP1A2* and *CACNA1A* are frequent in early-onset sporadic hemiplegic migraine. *Neurology* 2010;75:967–972.
29. de Vries B, Freilinger T, Vanmolkot KR, et al. Systematic analysis of three FHM genes in 39 sporadic patients with hemiplegic migraine. *Neurology* 2007;69:2170–2176.
30. Thomsen LL, Kirchmann M, Bjornsson A, et al. The genetic spectrum of a population-based sample of familial hemiplegic migraine. *Brain* 2007;130:346–356.
31. Stuart S, Roy B, Davies G, et al. Detection of a novel mutation in the *CACNA1A* gene. *Twin Res Hum Genet* 2012;15:120–125.
32. Thomsen LL, Oestergaard E, Bjornsson A, et al. Screen for *CACNA1A* and *ATP1A2* mutations in sporadic hemiplegic migraine patients. *Cephalalgia* 2008;28:914–921.
33. Terwindt G, Kors E, Haan J, et al. Mutation analysis of the *CACNA1A* calcium channel subunit gene in 27 patients with sporadic hemiplegic migraine. *Arch Neurol* 2002;59:1016–1018.
34. Vahedi K, Denier C, Ducros A, et al. *CACNA1A* gene de novo mutation causing hemiplegic migraine, coma, and cerebellar atrophy. *Neurology* 2000;55:1040–1042.
35. Hayashi R, Tachikawa H, Watanabe R, et al. Familial hemiplegic migraine with irreversible brain damage. *Intern Med* 1998;37:166–168.
36. Butteriss DJ, Ramesh V, Birchall D. Serial MRI in a case of familial hemiplegic migraine. *Neuroradiology* 2003;45:300–303.

37. Spacey SD, Vanmolkot KR, Murphy C, et al. Familial hemiplegic migraine presenting as recurrent encephalopathy in a Native Indian family. *Headache* 2005;45:1244–1249.
38. Ohmura K, Suzuki Y, Saito Y, et al. Sporadic hemiplegic migraine presenting as acute encephalopathy. *Brain Dev* 2012;34:691–695.
39. Bhatia R, Desai S, Tripathi M, et al. Sporadic hemiplegic migraine: report of a case with clinical and radiological features. *J Headache Pain* 2008;9:385–388.
40. Jacob A, Mahavish K, Bowden A, et al. Imaging abnormalities in sporadic hemiplegic migraine on conventional MRI, diffusion and perfusion MRI and MRS. *Cephalalgia* 2006;26:1004–1009.
41. Dreier JP, Jurkat-Rott K, Petzold GC, et al. Opening of the blood-brain barrier preceding cortical edema in a severe attack of FHM type II. *Neurology* 2005;64:2145–2147.
42. Iizuka T, Sakai F, Suzuki K, et al. Implication of augmented vasogenic leakage in the mechanism of persistent aura in sporadic hemiplegic migraine. *Cephalalgia* 2006;26:332–335.
43. Mjaset C, Russell MB. Intravenous nimodipine worsening prolonged attack of familial hemiplegic migraine. *J Headache Pain* 2008;9:381–384.
44. Beauvais K, Cave-Riant F, De Barace C, et al. New *CACNA1A* gene mutation in a case of familial hemiplegic migraine with status epilepticus. *Eur Neurol* 2004;52:58–61.
45. Prodan CI, Holland NR, Lenaerts ME, Parke JT. Magnetic resonance angiogram evidence of vasospasm in familial hemiplegic migraine. *J Child Neurol* 2002;17:470–472.
46. Gonzalez-Alegre P, Tippin J. Prolonged cortical electrical depression and diffuse vasospasm without ischemia in a case of severe hemiplegic migraine during pregnancy. *Headache* 2003;43:72–75.
47. Pierelli F, Grieco GS, Pauri F, et al. A novel *ATP1A2* mutation in a family with FHM type II. *Cephalalgia* 2006;26:324–328.
48. Motta E, Rosciszewska D, Miller K. Hemiplegic migraine with CSF abnormalities. *Headache* 1995;35:368–370.
49. Gomez-Aranda F, Canadillas F, Marti-Masso JF, et al. Pseudomigraine with temporary neurological symptoms and lymphocytic pleocytosis. A report of 50 cases. *Brain* 1997;120:1105–1113.
50. Berg MJ, Williams LS. The transient syndrome of headache with neurologic deficits and CSF lymphocytosis. *Neurology* 1995;45:1648–1654.
51. Yilmaz A, Kaleagasi H, Dogu O, et al. Abnormal MRI in a patient with ‘headache with neurological deficits and CSF lymphocytosis (HaNDL). *Cephalalgia* 2010;30:615–619.
52. Raets I. Diffusion restriction in the splenium of the corpus callosum in a patient with the syndrome of transient headache with neurological deficits and CSF lymphocytosis (HaNDL): a challenge to the diagnostic criteria? *Acta Neurol Belg* 2012;112:67–69.
53. Chapman KM, Szczygielski BI, Toth C, et al. Pseudomigraine with lymphocytic pleocytosis: a calcium channelopathy? Clinical description of 10 cases and genetic analysis of the familial hemiplegic migraine gene *CACNA1A*. *Headache* 2003;43:892–895.
54. Heinzen EL, Swoboda KJ, Hitomi Y, et al. De novo mutations in *ATP1A3* cause alternating hemiplegia of childhood. *Nat Genet* 2012;44:1030–1034.
55. Hutchinson M, O’Riordan J, Javed M, et al. Familial hemiplegic migraine and autosomal

- dominant arteriopathy with leukoencephalopathy (CADASIL). *Ann Neurol* 1995;38:817–824.
56. Montagna P, Gallassi R, Medori R, et al. MELAS syndrome: characteristic migrainous and epileptic features and maternal transmission. *Neurology* 1988;38:751–754.
57. Hansen JM, Hauge AW, Ashina M, Olesen J. Trigger factors for familial hemiplegic migraine. *Cephalalgia* 2011;31:1274–1281.
58. Schoonman GG, Evers DJ, Ballieux BE, et al. Is stress a trigger factor for migraine? *Psychoneuroendocrinology* 2007;32:532–538.
59. Ye Q, Yan LY, Xue LJ, et al. Flunarizine blocks voltage-gated Na<sup>+</sup> and Ca<sup>2+</sup> currents in cultured rat cortical neurons: a possible locus of action in the prevention of migraine. *Neurosci Lett* 2011;487:394–399.
60. Tobita M, Hino M, Ichikawa N, et al. A case of hemiplegic migraine treated with flunarizine. *Headache* 1987;27:487–488.
61. De Cunto A, Bensa M, Tonelli A. A case of familial hemiplegic migraine associated with a novel *ATP1A2* gene mutation. *Pediatr Neurol* 2012;47:133–136.
62. Mohamed BP, Goadsby PJ, Prabhakar P. Safety and efficacy of flunarizine in childhood migraine: 11 years' experience, with emphasis on its effect in hemiplegic migraine. *Dev Med Child Neurol* 2012;54:274–277.
63. Dobrev D, Milde AS, Andreas K, Ravens U. The effects of verapamil and diltiazem on N-, P- and Q-type calcium channels mediating dopamine release in rat striatum. *Br J Pharmacol* 1999;127:576–582.
64. Yu W, Horowitz SH. Familial hemiplegic migraine and its abortive therapy with intravenous verapamil. *Neurology* 2001;57:1732–1733.
65. Yu W, Horowitz SH. Treatment of sporadic hemiplegic migraine with calcium-channel blocker verapamil. *Neurology* 2003;60:120–121.
66. Razavi M, Razavi B, Fattal D, et al. Hemiplegic migraine induced by exertion. *Arch Neurol* 2000;57:1363–1365.
67. Cutrer FM, Limmroth V, Moskowitz MA. Possible mechanisms of valproate in migraine prophylaxis. *Cephalalgia* 1997;17:93–100.
68. Evers S, Afra J, Frese A, et al. EFNS guideline on the drug treatment of migraine—revised report of an EFNS task force. *Eur J Neurol* 2009;16:968–981.
69. Rothrock JF. Successful treatment of persistent migraine aura with divalproex sodium. *Neurology* 1997;48:261–262.
70. Stefani A, Spadoni F, Siniscalchi A, Bernardi G. Lamotrigine inhibits Ca<sup>2+</sup> currents in cortical neurons: functional implications. *Eur J Pharmacol* 1996;307:113–116.
71. Steiner TJ, Findley LJ, Yuen AW. Lamotrigine versus placebo in the prophylaxis of migraine with and without aura. *Cephalalgia* 1997;17:109–112.
72. Chen WT, Fuh JL, Lu SR, Wang SJ. Persistent migrainous visual phenomena might be responsive to lamotrigine. *Headache* 2001;41:823–825.
73. Lampl C, Buzath A, Klinger D, Neumann K. Lamotrigine in the prophylactic treatment of migraine aura – a pilot study. *Cephalalgia* 1999;19:58–63.
74. D'Andrea G, Granella F, Cadaldini M, Manzoni GC. Effectiveness of lamotrigine in the prophylaxis of migraine with aura: an open pilot study. *Cephalalgia* 1999;19:64–66.
75. Lampl C, Katsarava Z, Diener HC, Limmroth V. Lamotrigine reduces migraine aura and migraine attacks in patients with migraine with aura. *J Neurol Neurosurg Psychiatry* 2005;76:1730–1732.

76. Pascual J, Caminero AB, Mateos V, et al. Preventing disturbing migraine aura with lamotrigine: an open study. *Headache* 2004;44:1024–1028.
77. Strupp M, Zwergal A, Brandt T. Episodic ataxia type 2. *Neurotherapeutics* 2007;4:267–273.
78. Battistini S, Stenirri S, Piatti M, et al. A new *CACNA1A* gene mutation in acetazolamide-responsive familial hemiplegic migraine and ataxia. *Neurology* 1999;53:38–43.
79. Athwal BS, Lennox GG. Acetazolamide responsiveness in familial hemiplegic migraine. *Ann Neurol* 1996;40:820–821.
80. Koch HJ, Sykora A, Hausn P. Off-label use of acetazolamide in a patient with familial hemiplegic migraine and concomitant psychotic episodes. *Psychiatr Prax* 2010;37:148–151.
81. De Simone R, Marano E, Di Stasio E, et al. Acetazolamide efficacy and tolerability in migraine with aura: a pilot study. *Headache* 2005;45:385–386.
82. Vahedi K, Taupin P, Djomby R, et al. Efficacy and tolerability of acetazolamide in migraine prophylaxis: a randomized placebo-controlled trial. *J Neurol* 2002;249:206–211.
83. Silberstein SD, Goadsby PJ. Migraine: preventive treatment. *Cephalalgia* 2002;22:491–512.
84. Striano P, Zara F, Santorelli FM, Striano S. Topiramate-associated worsening symptoms in a patient with familial hemiplegic migraine. *J Neurol Sci* 2008;272:194–195.
85. Bardwell A, Trott JA. Stroke in migraine as a consequence of propranolol. *Headache* 1987;27:381–383.
86. Olesen J, Hougaard K, Hertz M. Isoproterenol and propranolol: ability to cross the blood-brain barrier and effects on cerebral circulation in man. *Stroke* 1978;9:344–349.
87. Zifkin B, Andermann E, Andermann F, Kirkham T. An autosomal dominant syndrome of hemiplegic migraine, nystagmus, and tremor. *Ann Neurol* 1980;8:329–332.
88. Lai CW, Ziegler DK, Lansky LL, Torres F. Hemiplegic migraine in childhood: diagnostic and therapeutic aspects. *J Pediatr* 1982;101:696–699.
89. Hsu DA, Stafstrom CE, Rowley HA, et al. Hemiplegic migraine: hyperperfusion and abortive therapy with intravenous verapamil. *Brain Dev* 2008;30:86–90.
90. Omata T, Takanashi J, Wada T, et al. Genetic diagnosis and acetazolamide treatment of familial hemiplegic migraine. *Brain Dev* 2011;33:332–334.
91. Tfelt-Hansen P, Saxena PR, Dahlof C, et al. Ergotamine in the acute treatment of migraine: a review and European consensus. *Brain* 2000;123:9–18.
92. Maassen van den Brink A, Reekers M, Bax WA, et al. Coronary side-effect potential of current and prospective antimigraine drugs. *Circulation* 1998;98:25–30.
93. Klapper J, Mathew N, Nett R. Triptans in the treatment of basilar migraine and migraine with prolonged aura. *Headache* 2001;41:981–984.
94. Artto V, Nissila M, Wessman M, et al. Treatment of hemiplegic migraine with triptans. *Eur J Neurol* 2007;14:1053–1056.
95. Hirota K, Lambert DG. Ketamine: its mechanism(s) of action and unusual clinical uses. *Br J Anaesth* 1996;77:441–444.
96. Kaube H, Herzog J, Kaufer T, et al. Aura in some patients with familial hemiplegic migraine can be stopped by intranasal ketamine. *Neurology* 2000;55:139–141.

97. Connor KM, Shapiro RE, Diener HC, et al. Randomized, controlled trial of telcagepant for the acute treatment of migraine. *Neurology* 2009;73:970–977.
98. Ho TW, Ferrari MD, Dodick DW, et al. Efficacy and tolerability of MK-0974 (telcagepant), a new oral antagonist of calcitonin gene-related peptide receptor, compared with zolmitriptan for acute migraine: a randomized, placebo-controlled, parallel-treatment trial. *Lancet* 2008;372:2115–2123.
99. Hoffmann J, Goadsby PJ. New agents for acute treatment of migraine: CGRP Receptor Antagonists, iNOS Inhibitors. *Curr Treat Options Neurol* 2012;14:50–59.
100. Jenkins B, Tepper SJ. Neurostimulation for primary headache disorders, part 1: pathophysiology and anatomy, history of neuromodulation in headache treatment, and review of peripheral neuromodulation in primary headaches. *Headache* 2011;51:1254–66.