



Universiteit
Leiden
The Netherlands

Tenosynovial giant cell tumours

Mastboom, M.J.L.

Citation

Mastboom, M. J. L. (2018, November 13). *Tenosynovial giant cell tumours*. Retrieved from <https://hdl.handle.net/1887/66888>

Version: Not Applicable (or Unknown)

License: [Licence agreement concerning inclusion of doctoral thesis in the Institutional Repository of the University of Leiden](#)

Downloaded from: <https://hdl.handle.net/1887/66888>

Note: To cite this publication please use the final published version (if applicable).

Cover Page



Universiteit Leiden




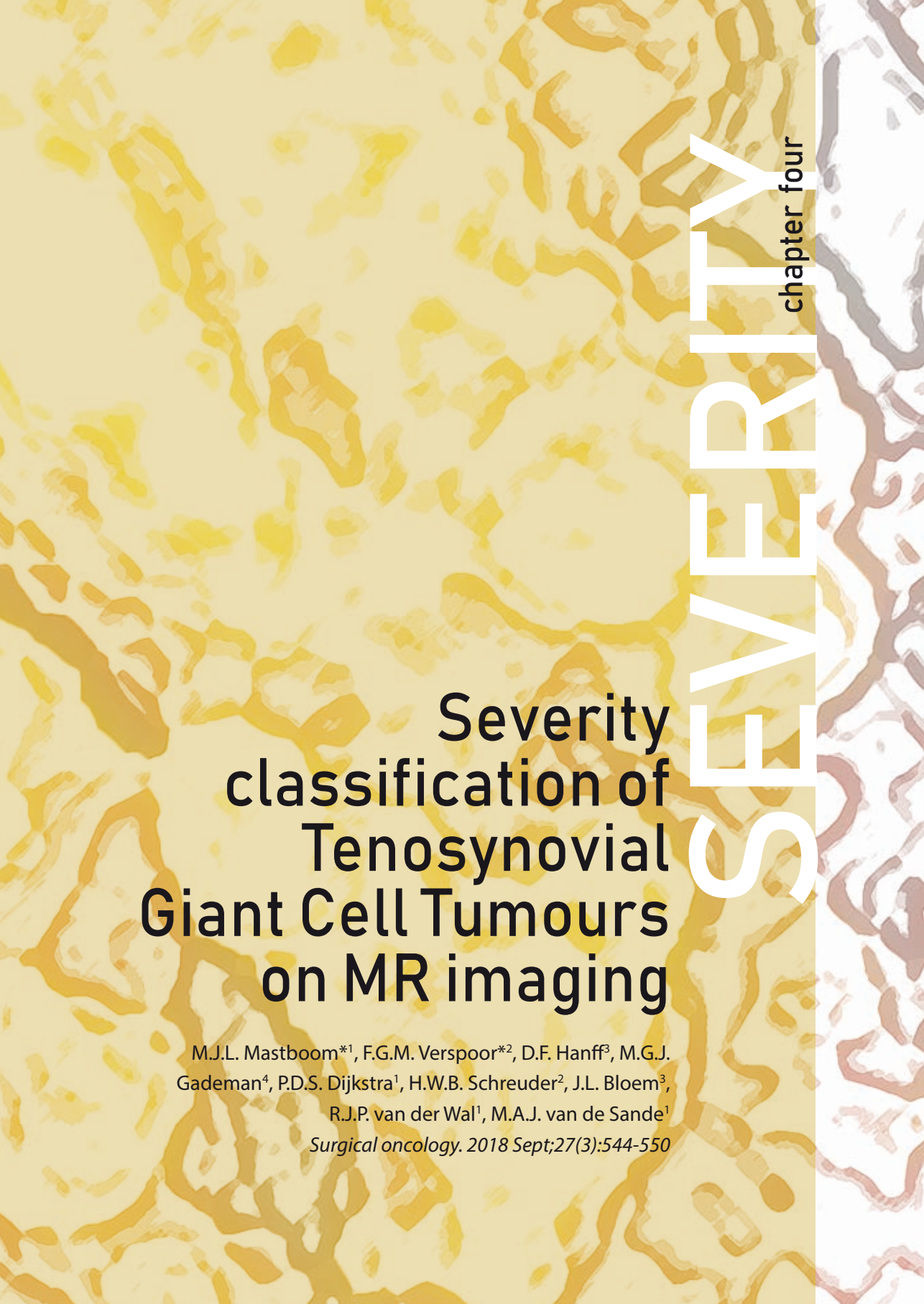
The handle <http://hdl.handle.net/1887/66888> holds various files of this Leiden University dissertation.

Author: Mastboom, M.J.L.

Title: Tenosynovial giant cell tumours

Issue Date: 2018-11-13





Severity classification of Tenosynovial Giant Cell Tumours on MR imaging

M.J.L. Mastboom*¹, F.G.M. Verspoor*², D.F. Hanff³, M.G.J. Gademan⁴, P.D.S. Dijkstra¹, H.W.B. Schreuder², J.L. Bloem³,
R.J.P. van der Wal¹, M.A.J. van de Sande¹
Surgical oncology. 2018 Sept;27(3):544-550

SEVERITY
chapter four

¹ Orthopaedic Surgery, Leiden University Medical Centre, Leiden, the Netherlands

² Orthopaedic Surgery, Radboud University Medical Centre, Nijmegen, the Netherlands

³ Radiology, Leiden University Medical Centre, Leiden, the Netherlands

⁴ Clinical Epidemiology, Leiden University Medical Centre, Leiden, the Netherlands

*Authors contributed equally to this work.

Abstract

Aim

Current development of novel systemic agents requires identification and monitoring of extensive Tenosynovial Giant Cell Tumours (TGCT). This study defines TGCT extension on MR imaging to classify severity.

Methods

In part one, six MR parameters were defined by field-experts to assess disease extension on MR images: type of TGCT, articular involvement, cartilage-covered bone invasion, and involvement of muscular/tendinous tissue, ligaments or neurovascular structures. Inter- and intra-rater agreement were calculated using 118 TGCT MR scans. In part two, the previously defined MR parameters were evaluated in 174 consecutive, not previously used, MR-scans. TGCT severity classification was established based on highest to lowest Hazard Ratios (HR) on first recurrence.

Results

In part one, all MR parameters showed good inter- and intra-rater agreement ($Kappa \geq 0.66$). In part two, cartilage-covered bone invasion and neurovascular involvement were rarely appreciated ($<13\%$) and therefore excluded for additional analyses. Univariate analyses for recurrent disease yielded positive associations for type of TGCT $HR12.84(95\%CI4.60-35.81)$, articular involvement $HR6.00(95\%CI2.14-16.80)$, muscular/tendinous tissue involvement $HR3.50(95\%CI1.75-7.01)$ and ligament-involvement $HR4.59(95\%CI2.23-9.46)$. With these, a TGCT severity classification was constructed with four distinct severity-stages. Recurrence free survival at 4 years (log rank $p < 0.0001$) was 94% in mild localized (n56, 1 recurrence), 88% in severe localized (n31, 3 recurrences), 59% in moderate diffuse (n32, 12 recurrences) and 36% in severe diffuse (n55, 33 recurrences).

Conclusion

The proposed TGCT severity classification informs physicians and patients on disease extent and risk for recurrence after surgical treatment. Definition of the most severe subgroup attributes to a universal identification of eligible patients for systemic therapy or trials for novel agents.

Introduction

Tenosynovial Giant Cell Tumour (TGCT) affecting large joints is an orphan, mono-articular, potentially locally aggressive disease with high recurrence rates. According to the 2013 WHO classification of tumours of soft tissue and bone, at the base of growth pattern, a radiological distinction is made between single nodule (localized-TGCT) and multiple lesions (diffuse-TGCT). These types differ in their clinical presentation, response to treatment and prognosis, but histologically, they seem identical¹⁻⁴.

Localized-type TGCT is classified as a circumscribed benign small (between 0.5 and 4 cm) mass^{1, 5}. Standard treatment of choice is excision. Subsequently, overall reported recurrence rates are relatively low: 0-6%⁶. On the contrary, diffuse-type TGCT, previously named Pigmented Villonodular Synovitis (PVNS), extensively involves the synovial membrane and infiltrates adjacent structures⁶.⁷ Reported recurrence rates of diffuse-TGCT following open synovectomy are 14% up till 67% and after arthroscopic synovectomy 40% up till 92%⁶. Recurrent or residual disease, frequently requiring multiple, sometimes mutilating operations, may result in total joint arthroplasties, morbidity and loss of quality of life⁸⁻¹². With this large variety in disease presentation and recurrence rates, a more comprehensive and outcome-based classification is asked for. The emerging era of systemic targeted and multimodality therapies (available in trial settings) increases the need for a method to select eligible patients in order to create comparable patient cohorts¹³⁻¹⁵.

In diagnosing and treating TGCT, magnetic resonance (MR) imaging is the most distinctive imaging technique^{4, 16-19}. MR imaging reveals conspicuous nodular (localized-type) or villous proliferation of synovium (diffuse-type). However, current literature lacks specific MR discriminating features to describe or quantify tumour extent in relation to clinical outcome. Uniform MR descriptions are of utmost importance for clinical and research purposes. Therefore this study aims to sub-classify tumour severity especially in diffuse-type TGCT. First, a group of radiologists and orthopaedic surgeons identified and defined potentially distinguishing parameters. Second, these MR parameters were applied on a different study-population to establish TGCT severity subgroups.

Methods

Part I: Identification and evaluation of TGCT specific MR parameters

Using case discussions in expert meetings with two dedicated musculoskeletal radiologists and three oncological orthopaedic surgeons, six MR parameters were selected in relation to anatomical or surgical landmarks. These parameters were 1 type of TGCT (based on 2013 WHO classification^{1,2}), 2 articular involvement, 3 cartilage-covered bone invasion, 4 involvement of muscular/tendinous tissue, 5 involvement of ligaments and 6 involvement of neurovascular structures (*figure 1*) (*Appendix*).

To evaluate usability and reproducibility, 118 MR scans of TGCT patients, treated at the Leiden University Medical Centre (LUMC), were randomly retrieved (MM). The six MR parameters were evaluated in a heterogeneous group of TGCT cases as scans included cases of various large joints (knee (79; 67%), ankle (13; 11%), foot (10; 9%)), severity subtypes and treatment phases. MR scans were conducted using a 1.5 or 3.0 Tesla unit Philips (Best, The Netherlands) Ingenia MR with dedicated coils. Standard musculoskeletal scan-protocol included: T1- and T2-weighted fast spin echo, T1-weighted fat-suppressed post Gd-chelate contrast and optionally T2* gradient-echo sequences in two planes (transversal and either sagittal or coronal). To assess inter- and intra-rater agreement, all MR scans were evaluated by one dedicated musculoskeletal radiologist (DH) and by two dedicated orthopaedic surgeons (RW, MS). MR evaluation was blinded to patient characteristics.

Inter-rater agreement and accompanying 95% confidence interval (95% CI) between three physicians was calculated for all 118 cases by Fleiss-Kappa (dichotomous outcomes in all parameters, except for articular involvement with three outcomes). To evaluate intra-rater agreement with the accompanying 95% CI (linear weighted kappa), 36 randomly chosen MR scans (31%) were again evaluated three months after initial evaluation by the senior orthopaedic surgeon (MS).

Part II: Application of TGCT MR parameter

None of the MR scans in part I were used in part II. The combined TGCT-database of two sarcoma centres in The Netherlands (LUMC and Radboud University Medical Centre (RUMC)) was used to include consecutive MR scans conducted between 2005 and 2015 (n=283). MR scan inclusion criteria were: pre-treatment MR scan of histologically proven TGCT of large joints, conducted in two planes (transversal and either sagittal or coronal), and open resection as primary treatment

Figure 1 Definition of six TGCT specific MR parameters

TGCT-type

- a. Localized-type on a sagittal PD-weighted FSE MR image of a 49 year old female patient. Localized-TGCT is defined according to WHO as a well circumscribed nodular lesion at synovial lining of bursa, joint or tendon sheath.
- b. Diffuse-type on a sagittal PD-weighted FSE MR image of a 24 year old male patient. Diffuse-TGCT is defined as a multinodular lesion involving a larger part or multiple compartments of the synovial lining.

Articular involvement

- c. Intra-articular well circumscribed lesion on posterior cruciate ligament on a PD-weighted FSE MR image of a 18 year old female patient. Intra-articular involvement is defined as TGCT involvement inside synovial lining of joint.
- d. Extra-articular involvement, along gastrocnemius muscle insertion, on a sagittal T1-weighted FSE MR image of a 33 year old male patient. Extra-articular involvement is defined as TGCT involvement outside synovial lining of the joint.
- e. Both intra- and extra-articular involvement on a sagittal T1-weighted fat-suppressed MR image after intravenous administration of gadolinium of a 63 year old female patient with TGCT. Extensive tumour growth anterior and posterior.

Cartilage-covered bone invasion

- f. Cartilage covered bone invasion on a sagittal T1-weighted FSE MR image of a 59 year old male patient. Square presents cartilage covered bone, defined as clear invasion of bone through cartilage; not only touch cartilage. Circle presents not-cartilage covered bone invasion.

Muscular/tendinous tissue involvement

- g. Muscular/tendinous tissue involvement, anterior vastus medialis muscle and posterior hamstrings tendon, on a sagittal T1-weighted fat-suppressed MR image after intravenous administration of gadolinium of a 63 year old female patient with TGCT. Muscular/tendinous tissue is defined as involvement of muscular/tendinous tissue or >180 degrees engagement of tendon/muscle.

Ligament involvement

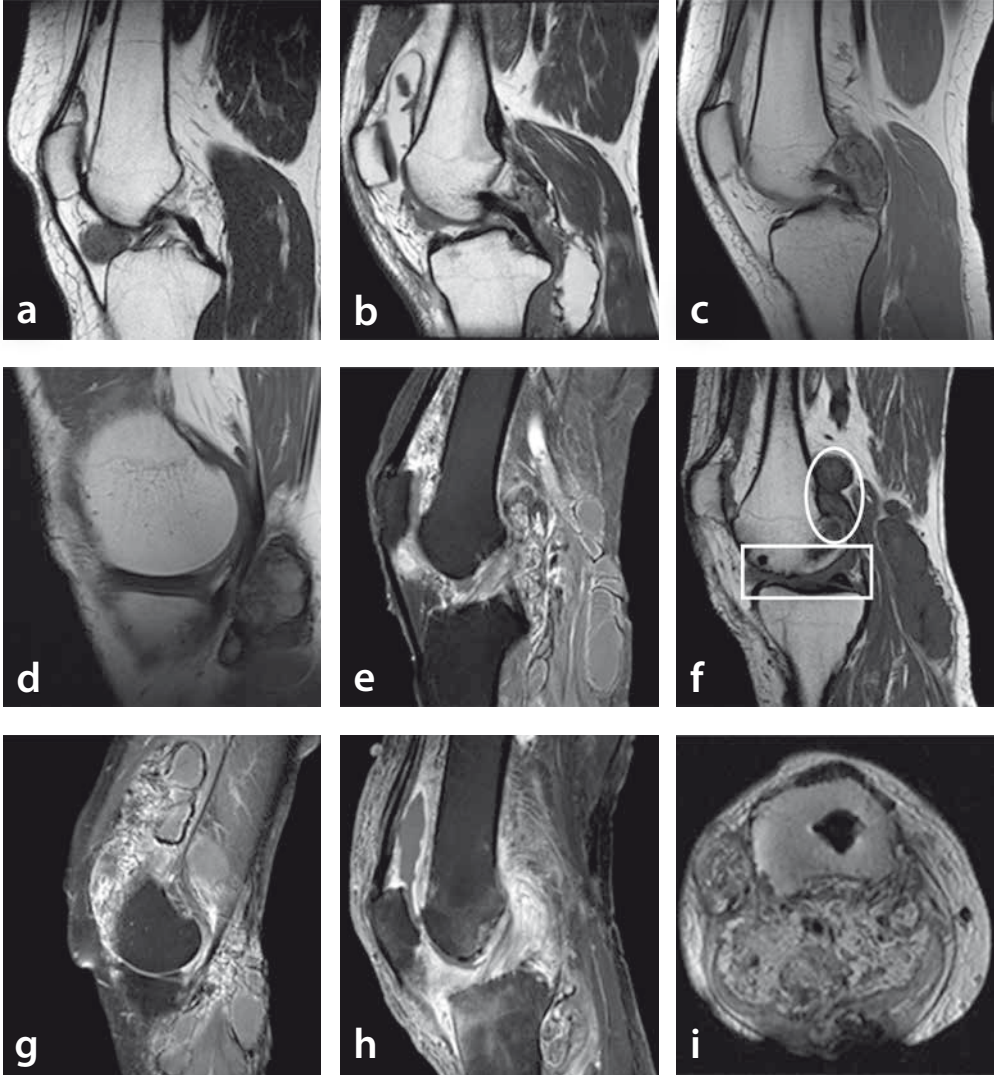
- h. Cruciate ligament enhancement on a sagittal T1-weighted fat-suppressed MR image after intravenous administration of gadolinium of a 64 year old male patient. Ligament involvement is defined as involvement of ligament or >180 degrees engagement of ligament.

Neurovascular structures involvement

- i. Popliteal artery engagement on an axial PD-weighted FSE MR image of a 62 year old female patient, referred to a tertiary sarcoma centre with extensive TGCT. Neurovascular involvement is defined as > 180 degrees engagement of the artery or nerve.

FSE, Fast Spin Echo; PD, Proton Density

Figure e & g is the same female patient.



in one of the two participating centres. Large joints were defined as all joints proximal to and excluding metatarsophalangeal and metacarpophalangeal joints. When TGCT affected the knee, one diagnostic arthroscopy prior to open resection was allowed, since tumour extent would not be affected. Open synovectomy was defined as gross total resection of disease, either one- or two-staged, without adjuvant therapy. 174/283 Patients met the inclusion criteria (*figure 2*). Median follow-up was 36 (IQR 21-60) months, maximum follow-up 12 years after primary surgery.

The senior author (MS) evaluated the six defined MR parameters (part I) on these pre-treatment scans (77 LUMC, 97 RUMC). MR evaluation was blinded to patient characteristics and clinical outcome. Patient and tumour characteristics were gathered: gender, localization (affected joint), age at time of the MR scan, date of open synovectomy, first local recurrence and date of first recurrence (on MR imaging), and date of last follow-up. Median follow-up was calculated from date of primary surgery to date of last clinical follow-up, including interquartile range (IQR). Recurrence free survival was calculated from date of surgery to recurrent disease or last contact.

As outcome, first recurrence was defined as new disease presence after synovectomy or growing residual disease (diagnosed on follow-up MR scan). Proposed risk factors were gender, localization (knee versus other joints) and age at the time of the MR scan (below or above 40 years). Hazard ratios (HRs) and their corresponding 95% CI were estimated for risk factors and MR parameters

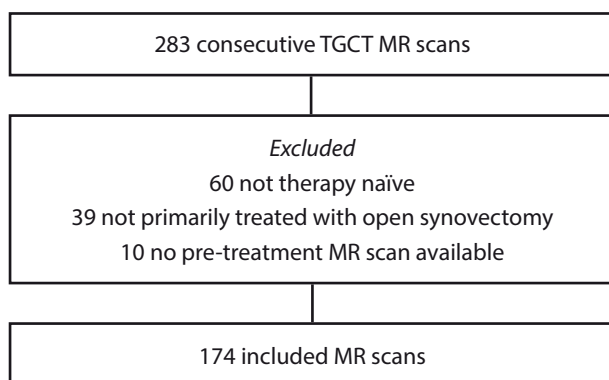


Figure 2 Inclusion flowchart part II TGCT severity classification.

(part I) by univariate and multivariate Cox regression analyses to estimate the relation on recurrent disease. Since estimating HR is unreliable for rarely present MR parameters, only parameters with an adequate number of presence (minimum of 20%) were used for additional analyses. Recurrence free survival close to median time of follow-up was calculated by Kaplan Meier analyses and log rank test. Time zero was defined as date of primary open synovectomy.

At the base of HRs with positive associations of risk factors and MR parameters on first recurrences, the TGCT severity classification was established. The TGCT subgroup flow chart started with the MR parameter with highest HR, followed by descending HRs. Statistical Package for Social Statistics (SPSS) version 23 was used for analyses.

Ethical statement

This study was approved by the institutional review board from our institution (registration number P13.029). No funding was received.

Results

Part I: Evaluation of TGCT specific MR parameters

Inter-rater agreements for type of TGCT, articular involvement, cartilage-covered bone invasion, and involvement of muscular/tendinous tissue, ligaments or neurovascular structures were 0.71; 0.68; 0.66; 0.67; 0.75 and 0.73, respectively. Intra-rater agreements for these parameters were between 0.72 and 1.00 (*table 1*). Since inter- and intra-rater agreements were good²⁰ for these six MR features, all parameters were considered viable to use for TGCT subgroup analyses.

Part II: Application of TGCT MR parameters

Out of 174 MR scans, the knee was affected most (122; 70%), followed by the ankle (20; 12%) (*table 2*). In univariate analyses, none of the proposed risk factors were associated with recurrent disease ($p>0.37$) (*table 3*) and consequently not used for further analyses. Both MR parameters cartilage-covered bone invasion and involvement of neurovascular structures were rarely seen on MR images ($< 13\%$) and in accordance with our exclusion criteria not used for additional analyses. In univariate analyses, the remaining four MR parameters were associated with recurrent disease ($p<0.002$) (*table 3*); strongest association was seen in diffuse-type compared with localized-type

Table 1 Inter- and intra-rater agreement (kappa) in six MR parameters

Agreement	Type of TGCT	Articular involvement	Cartilage-covered bone invasion	Muscular/ tendinous tissue involvement	Ligament involvement	Neurovascular involvement
Inter-rater	0.71 (0.60-0.81)	0.68 (0.58-0.78)	0.66 (0.56-0.76)	0.67 (0.56-0.77)	0.75 (0.57-0.93)	0.73 (0.62-0.83)
Intra-rater	0.94 (0.82-1.06)	0.89 (0.74-1.04)	0.79 (0.39-1.19)	0.72 (0.50-0.94)	0.86 (0.68-1.04)	1.00 (1.00-1.00)

Inter-rater, Agreement between three physicians (one musculoskeletal radiologist, two orthopaedic surgeons).

Intra-rater, Agreement for 31% of MR scans initially evaluated and re-evaluated 3 months thereafter by the senior orthopaedic surgeon.

Interpretation of inter- and intra-rater agreement (K-value) ²⁰

Agreement value	Strength of agreement
< 0.20	Poor
0.21 - 0.40	Fair
0.41 - 0.60	Moderate
0.61 - 0.80	Good
0.81 - 1.00	Very good

(HR 12.84 (95%CI 4.60-35.81)), subsequently intra- and extra-articular involvement compared with extra-articular (HR 6.00 (95%CI 2.14-16.80)) and involvement of muscular/tendinous tissue or ligaments compared with no involvement (HR 3.50 (95%CI 1.75-7.01), HR 4.59 (95%CI 2.23-9.46), respectively).

Multivariate analyses for MR parameters did not show individual positive association, except for parameter type of TGCT (*supplementary material I*).

Four TGCT severity subtypes were established using a flowchart that begins with the parameters with highest HR (parameter type of TGCT), followed by parameters with descending HRs. These four subtypes showed a clinically relevant or significant prognostic value for recurrent disease and were classified as: mild localized (n56, 1 recurrence), severe localized (n31, 3 recurrences), moderate diffuse (n32, 12 recurrences) and severe diffuse (n55, 33 recurrences).

1. **Mild localized** contained localized-type, either intra- or extra-articular involvement without involvement of muscular/tendinous tissue/ligaments.
2. **Severe localized** included localized-type, either intra- or extra-articular lesions and either or both involvement of muscular/tendinous tissue/ligaments.
3. **Moderate diffuse** comprised diffuse-type with intra- and/or extra-articular disease without involvement of muscular/tendinous tissue/ligaments.
4. **Severe diffuse** was diffuse-type including intra- and extra-articular involvement and involvement of at least one of the three structures (muscular/tendinous tissue/ligaments) (*figure 3*).

Recurrence free survival at 4 years (close to median follow-up diffuse-type) for the four patient groups according to the new MR subtypes descended from 94% in mild localized, to 88% in severe localized, to 59% in moderate diffuse and to 36% in the least favorable subtype, severe diffuse. Median time to local recurrence in moderate diffuse and severe diffuse subtypes was 29.5 (IQR 14.5-48.0) and 22.0 (IQR 11.8-33.5) months, respectively. Majority of recurrent disease cases were already treated with a re-operation (32/49, 65%). One patient, classified as severe diffuse, died of another disease, after four months and was censored at that time. Novel MR based TGCT severity and associated Kaplan Meier survival curves presented significant difference between the four patient groups (log rank $p < 0.0001$) and additional differentiation compared with solely subclassifying in localized- and diffuse-TGCT (*figure 4 and supplementary material II*).

Table 2 TGCT MR scan demographics

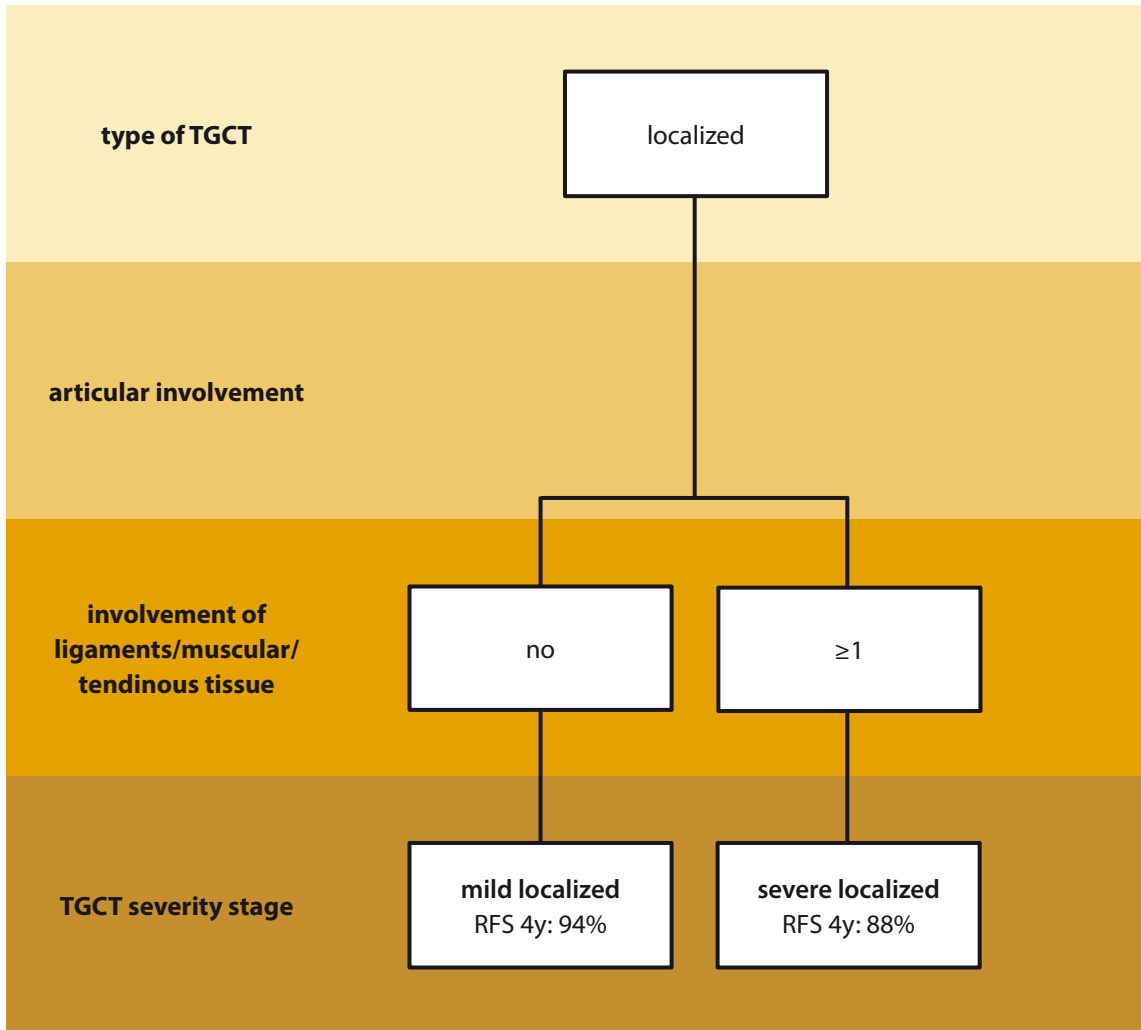
	Cases (%)	Cases localized TGCT (%)	Cases diffuse TGCT (%)
Total number of MR scans	174	87	87
Gender			
Female	105 (60)	33 (38)	36 (41)
Male	69 (40)	54 (62)	51 (59)
Median age at MR scan (IQR)	37 (26-48) years	37 (24-47) years	36 (26-49) years
Localization			
Knee	122 (70)	63 (72)	59 (68)
Hip	8 (5)	0 (0)	8 (9)
Ankle	20 (12)	10 (11)	10 (11)
Foot	9 (5)	5 (6)	4 (5)
Elbow	6 (3)	4 (5)	2 (2)
Other	9 (5)	5 (6)	4 (5)
Median follow-up (IQR)	36 (21-60) months	32 (17-56) months	41 (24-63) months
Total number of recurrences			
Recurrent disease	49 (28)	4 (5)	45 (52)
No recurrent disease	125 (72)	83 (95)	42 (48)

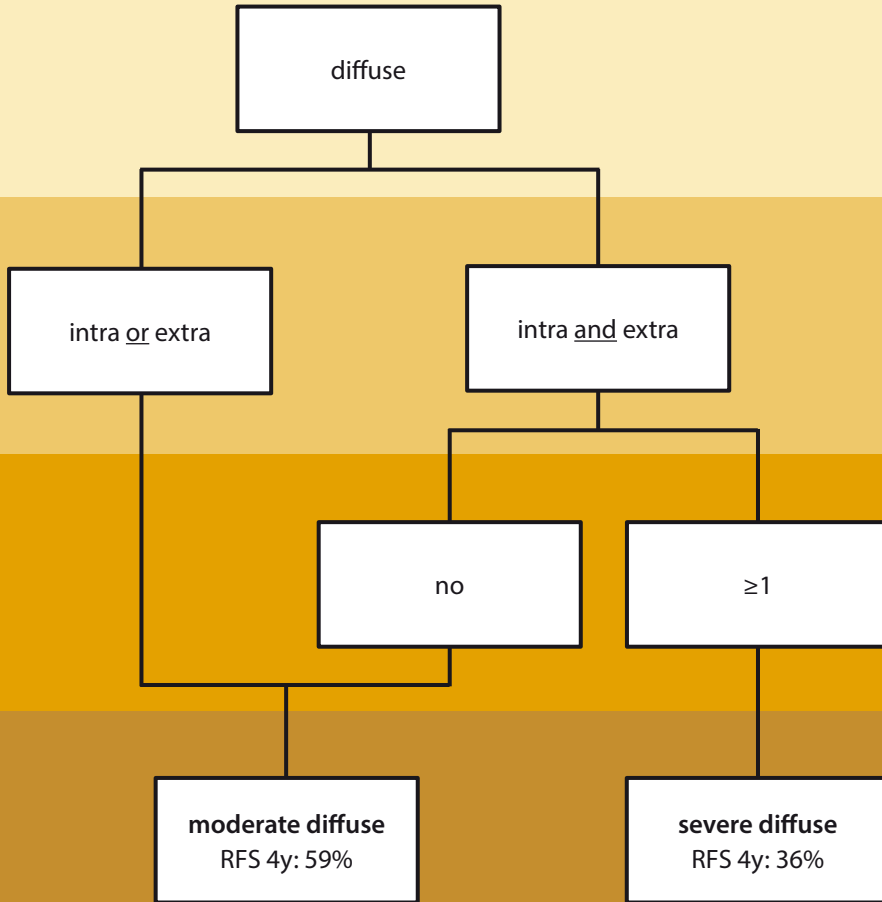
IQR, interquartile range

Table 3 Risk of recurrence on MR imaging; univariate analyses in proposed risk factors and four MR parameters.

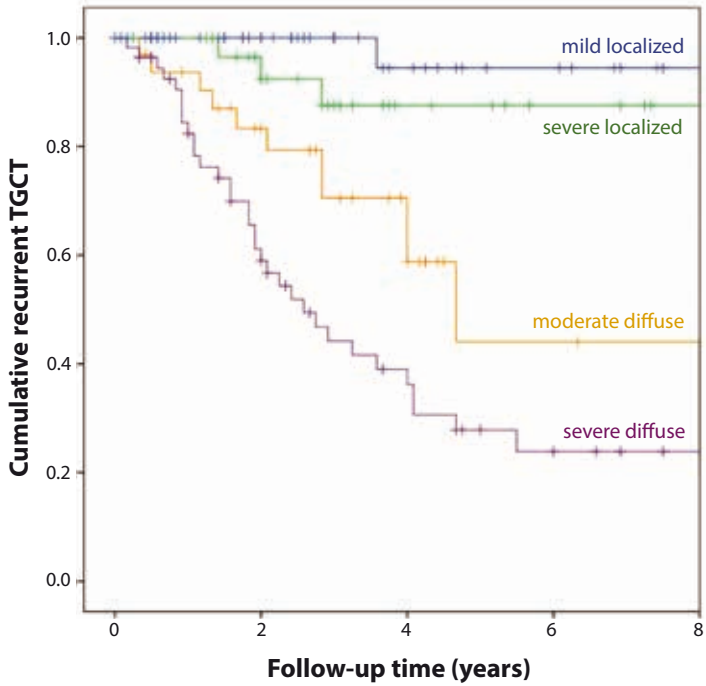
	n (%)	Hazard ratio (95% CI)	P
Gender			
Male	69 (40)	1.29 (0.74-2.27)	0.37
Female	105 (60)	1	
Age			
<40 years	91 (52)	1.15 (0.66-2.02)	0.63
>40 years	83 (48)	1	
Localization			
Knee	122 (70)	1.15 (0.63-2.12)	0.65
Other joint	52 (30)	1	
TGCT-type			
Diffuse	87 (50)	12.84 (4.60-35.81)	<0.000
Localized	87 (50)	1	
Articular involvement			
Intra-articular	59 (34)	1.11 (0.31-3.95)	0.87
Intra- and extra-articular	75 (43)	6.00 (2.14-16.80)	0.001
Extra-articular	40 (23)	1	
Muscular/tendinous tissue involvement			
Yes	90 (52)	3.50 (1.75-7.01)	<0.000
No	84 (48)	1	
Ligament involvement			
Yes	86 (49)	4.59 (2.23-9.46)	<0.000
No	88 (51)	1	

Figure 3 TGCT severity classification, containing four severity subtypes: mild localized, severe localized, moderate diffuse and severe diffuse.





RFS 4y, Recurrence Free Survival at 4 years



Time (years)	0	2	4	6	8
Number at risk	174	105	51	24	10

Figure 4 TGCT recurrence free survival curve for four TGCT severity subtypes, affecting large joints, estimated with Kaplan Meier method. Time zero was date of primary open synovectomy. One patient, classified as severe diffuse died of another disease after 4 months and was censored at that time.

Discussion

This is the first study to define severity subtypes in Tenosynovial Giant Cell Tumours (TGCT) based on a combination of four MR imaging parameters. These subtypes correlate with a spectrum of disease severity ranging from low to high risk of local recurrence after surgical intervention.

Within this present era of systemic targeted and multimodality therapies (available in trial settings) in TGCT, standalone surgical resection cannot be regarded the gold standard anymore for more severe cases²¹. Because of the lack of clear-cut boundaries in diffuse-TGCT, complete resection is difficult and at times technically impossible or undesirable with joint function preservation and quality of life in mind. In patients with locally advanced TGCT or (multiple) recurrence(s), systemic therapies targeting the *CSF1/CSF1R* axis have been investigated; less potent drugs as nilotinib and imatinib^{22, 23}, and more specific inhibitors as emactuzumab (RG7155), pexidartinib (PLX3397) and cabiralizumab (FPA008). Emactuzumab (N=29) had an overall response rate of 86% (two patients with a complete response) and a rate of disease control of 96%, including a significant functional and symptomatic improvement (median follow up 12 months)²⁴. In a randomized, placebo-controlled phase 3 study, pexidartinib showed an improved overall response rate by RECIST: 39% in the pexidartinib-group (N=61) and 0% of placebo-group (N=59), after median six months follow-up²⁵. The preliminary results with cabiralizumab (N=22) are consistent, with radiographic response and improvement in pain and function in five out of 11 patients 28¹⁵. However, long term efficacy data have not yet been reported with these newer agents.

Patient inclusion for these trials is very heterogeneous. A strict patient selection is desirable, to accurately evaluate effect of these treatments. At present, patient selection for trial inclusion is established by preference of treating physician and might differ per centre. Defining more aggressive TGCT subtypes and including these uniformly defined patients into trials would more adequately investigate the effect and toxicities of treatment²⁶. In this study, we propose to include patients defined with 'severe diffuse' TGCT subtype. Monitoring the effect of systemic therapy also benefits from clear agreements on parameters.

Uniform MR descriptions are of utmost importance for clinical and research purposes. Thus far, no well-defined tumour parameters exist. Definition of unambiguous MR criteria is challenging,

because of the rarity of the tumour and small number of heterogeneous cases, variety of joints involved, different disease severity as well as several treatment modalities^{2,27}. So far, MR imaging has shown to be the best discriminating method to evaluate TGCT^{4,28}. In our study, six objective clinically relevant MR parameters were defined in relation to anatomical or surgical landmarks. According to our exclusion criteria for the development of the severity classification, parameters cartilage covered bone invasion and neurovascular involvement showed inadequate number of presence and were therefore not used. However, in larger case series these two parameters might correlate with more aggressive disease and hence a higher recurrence rate.

To date, no radiology-based TGCT severity classification exists. Subdividing between localized- and diffuse-TGCT seems an oversimplification that fails to estimate differences in recurrent rates for individual patients. Murphey et al. presented an extensive review of different TGCT features on several imaging techniques, without relating these features to disease severity, treatment or recurrences⁴. Van der Heijden et al. further sub-classified diffuse-TGCT affecting the knee in 30 patients into mild or severe, without linking to recurrent disease. Mild diffuse-TGCT was defined as involvement of either anterior or posterior compartment of the knee, with the cruciate ligaments as boundary. Severe diffuse-TGCT was defined as involvement of both compartments, with or without extra-articular extension⁹. In contrast to most literature, we selected a homogeneously treated patient population to develop four severity subtypes, by only including patients initially treated with an open synovectomy.

In line with most papers, especially papers on trial medication, and based on clinical practice, we included all large joints to sub-classify disease severity for TGCT. Prior research did not show a (significant) difference in recurrence rates for both localized and diffuse disease when comparing the knee with other joints^{6,27,29,30}. A recent TGCT incidence calculation study showed a predominance of the knee in 46% in localized- and 64% in diffuse-type (excluding digits)⁵, in line with our overrepresentation of the knee of 70%. In the future, a TGCT severity classification focused on the knee would contain more detailed knee-specific MR parameters and equal treatment approaches.

Limitations to this study: primary, the resulting HRs had wide confidence intervals, indicating low

precision in the estimates. This is likely related to the relatively small sample size, given that the patients were divided into several groups based on the MR parameters. Secondly, because of the relatively small number of recurrences in severity subtypes mild localized (n 1) and severe localized (n 3), Hazard Ratios may be unreliable. Therefore, it was not feasible to estimate a cox model and to generate a true prediction model. Additionally, localized-TGCT is known to have few recurrences and often remains without clinical complaints after resection. In both sarcoma centres, patients are therefore discharged from follow-up after the first follow-up post-surgery and requested to return again when clinical complaints present. In our analyses, 31 localized-type patients were censored at date of last clinical follow-up within the first two years in survival curve (*figure 4*). Less often, patients with diffuse-type have also lacked follow-up (13 censored first two years). It could be assumed that these patients did not have complaints and recurrent disease. Furthermore, in study part two (establishing TGCT subtypes), newest included MR scans originated from 2015. These cases had a maximum follow-up of two years. Since it is known that local recurrence might develop years after initial surgery^{2, 11, 29}, in our study a median of 29.5 in moderate diffuse and 22.0 months in severe diffuse-TGCT subtypes, underestimation of recurrence free survival could be present. Finally, even though quite a large number of MR scans (174) were used in development of the severity classification, in larger case-series including long follow-up time, it might be possible to differentiate further in disease severity and assess additional subtypes.

To conclude, in reporting TGCT affecting large joints on MR imaging, six parameters are helpful in discriminating disease extent. Patients can be accurately monitored by using these MR parameters. With respect to recurrence, a combination of four MR parameters classifies patients into one of four severity subtypes, presented with distinct recurrence free survival rates. In the era of personalized medicine, treatment is individualized for each patient depending on the extent of disease. Because histopathological prognostic factors are lacking, sub-classification of TGCT on MR imaging is a potential tool to stratify future patient prognosis and identify candidates for targeted therapies, thereby aiding with the decision in daily practice.

Supplementary data

Supplementary data related to this article can be found at
<https://doi.org/10.1016/j.suronc.2018.07.002>

Appendix

TGCT MR parameters, affecting large joints, in therapy naïve primary TGCT patients

Agreement:

- Involvement of a structure: when signal intensity is changed to TGCT signal intensity, this structure is considered to be involved with TGCT and to be scored.
- When involvement of a structure is unclear: choose '**structure involved**' (when in doubt; over-scoring, not under-scoring).

MI parameters

1. TGCT-type

- **Localized-type**[†]: well circumscribed nodular lesion at synovial lining of bursa, joint or tendon sheath
- **Diffuse-type**^{††}: multinodular lesion involving a larger part or all of the synovial lining

2. Articular involvement

- **Intra-articular**[§]: inside synovial lining of joint
- **Extra-articular**^{§§}: outside synovial lining of joint
- **Both intra- and extra-articular**

3. Cartilage-covered bone invasion

- **Yes**: clear invasion of bone *invading* cartilage; *not only* touch cartilage
- **No**: no bone invasion or solely bone-usuration or bone invasion *not* cartilage-covered

4. Muscular/tendinous tissue involvement*

- **Yes**: involvement of muscular/tendinous tissue or >180 degrees encasement of tendon/muscle
- **No**: no involvement or encasement of tendon/muscle

5. Ligament involvement**

- **Yes**: involvement of ligament or >180 degrees encasement of ligament
- **No**: no involvement or encasement of ligament

6. Neurovascular structure involvement[#]

- **Yes:** encasement >180 degrees of important nerves and/or vessels
- **No:** no encasement of nerves or vessels

[†] **Localized-type:** be careful to always classify one nodular lesion as localized-type. Also when one nodular lesion is reeved by another structure (it might seem like additional nodules).

^{††} **Diffuse-type:** be careful to always classify diffuse-type when two or more tendon sheaths or muscles are involved. Do not classify these cases as one large nodule.

[§] **Intra-articular:** concerning the knee: cruciate ligaments are counted as intra-articular structures as the synovial lining of the ligaments should be considered intra-articular.

^{§§} **Extra-articular:** concerning the knee: Hoffa

* **Muscular/tendinous tissue involvement:** concerning the knee: also account parameter when solely popliteus muscle involvement is present.

** **Ligament involvement:** TGCT involvement of ligament, in hand or foot: account parameter when intra-tarsal/digital ligaments, ankle syndesmore and plantar fascia are involved. TGCT concerning the knee with ligament involvement: anterior and/or posterior cruciate ligament, and/or medial/lateral collateral ligament.

[#] **Neurovascular involvement:** in hand or foot: also digital or sensible nerves

References

1. de St. Aubain S, van de Rijn M. Tenosynovial giant cell tumour, localized type. In: Fletcher CDM BJ, Hogendoorn PCW, Mertens F, editor. WHO Classification of Tumours of Soft Tissue and Bone. 5. 4 ed 2013. p. 100-1.
2. de St. Aubain S, van de Rijn M. Tenosynovial giant cell tumour, diffuse type. In: Fletcher CDM BJ, Hogendoorn PCW, Mertens F, editor. WHO Classification of Tumours of Soft Tissue and Bone. 5. 2013. p. 102-3.
3. Frassica FJ, Khanna JA, McCarthy EF. The role of MR imaging in soft tissue tumor evaluation: perspective of the orthopedic oncologist and musculoskeletal pathologist. *Magnetic resonance imaging clinics of North America*. 2000;8(4):915-27.
4. Murphey MD, Rhee JH, Lewis RB, Fanburg-Smith JC, Flemming DJ, Walker EA. Pigmented villonodular synovitis: radiologic-pathologic correlation. *Radiographics*. 2008;28(5):1493-518.
5. Mastboom MJL, Verspoor FGM, Verschoor AJ, Uittenbogaard D, Nemeth B, Mastboom WJB, et al. Higher incidence rates than previously known in tenosynovial giant cell tumors. *Acta orthopaedica*. 2017:1-7.
6. van der Heijden L, Gibbons CL, Hassan AB, Kroep JR, Gelderblom H, van Rijswijk CS, et al. A multidisciplinary approach to giant cell tumors of tendon sheath and synovium--a critical appraisal of literature and treatment proposal. *J Surg Oncol*. 2013;107(4):433-45.
7. Tyler WK, Vidal AF, Williams RJ, Healey JH. Pigmented villonodular synovitis. *The Journal of the American Academy of Orthopaedic Surgeons*. 2006;14(6):376-85.
8. Mastboom MJL, Verspoor FGM, Gelderblom H, van de Sande MAJ. Limb Amputation after Multiple Treatments of Tenosynovial Giant Cell Tumour: Series of 4 Dutch Cases. *Case reports in orthopedics*. 2017;2017:7402570.
9. van der Heijden L, Mastboom MJ, Dijkstra PD, van de Sande MA. Functional outcome and quality of life after the surgical treatment for diffuse-type giant-cell tumour around the knee: a retrospective analysis of 30 patients. *Bone Joint J*. 2014;96-B(8):1111-8.
10. Verspoor FG, Hannink G, Scholte A, Van Der Geest IC, Schreuder HW. Arthroplasty for tenosynovial giant cell tumors. *Acta orthopaedica*. 2016;87(5):497-503.
11. Verspoor FG, Zee AA, Hannink G, van der Geest IC, Veth RP, Schreuder HW. Long-term follow-up results of primary and recurrent pigmented villonodular synovitis. *Rheumatology (Oxford)*. 2014;53(11):2063-70.
12. Griffin AM, Ferguson PC, Catton CN, Chung PW, White LM, Wunder JS, et al. Long-term outcome of the treatment of high-risk tenosynovial giant cell tumor/pigmented villonodular synovitis with radiotherapy and surgery. *Cancer*. 2012;118(19):4901-9.
13. Tap WD, Wainberg ZA, Anthony SP, Ibrahim PN, Zhang C, Healey JH, et al. Structure-Guided Blockade of CSF1R Kinase in Tenosynovial Giant-Cell Tumor. *The New England journal of medicine*. 2015;373(5):428-37.
14. Ries CH, Cannarile MA, Hoves S, Benz J, Wartha K, Runza V, et al. Targeting tumor-associated macrophages with anti-CSF-1R antibody reveals a strategy for cancer therapy. *Cancer cell*. 2014;25(6):846-59.
15. Sankhala KK, Blay JY, Ganjoo KN, Italiano A, Hassan AB, Kim TM, et al. A phase I/II dose escalation and expansion study of cabiralizumab (cabira; FPA-008), an anti-CSF1R antibody, in tenosynovial giant cell tumor (TGCT, diffuse pigmented villonodular synovitis D-PVNS). *ASCO conference 2017*. 35 (15 Supplement 1).
16. Hughes TH, Sartoris DJ, Schweitzer ME, Resnick DL. Pigmented villonodular synovitis: MRI characteristics. *Skeletal radiology*. 1995;24(1):7-12.
17. Nordemar D, Oberg J, Brosjo O, Skorpil M. Intra-Articular Synovial Sarcomas: Incidence and Differentiating Features from Localized Pigmented Villonodular Synovitis. *Sarcoma*. 2015;2015:903873.

18. Poletti SC, Gates HS, 3rd, Martinez SM, Richardson WJ. The use of magnetic resonance imaging in the diagnosis of pigmented villonodular synovitis. *Orthopedics*. 1990;13(2):185-90.
19. Wang C, Song RR, Kuang PD, Wang LH, Zhang MM. Giant cell tumor of the tendon sheath: Magnetic resonance imaging findings in 38 patients. *Oncology letters*. 2017;13(6):4459-62.
20. Altman D. *Practical Statistics for Medical Research*. Hall/CRC Ca, editor 1990.
21. Staals EL, Ferrari S, Donati DM, Palmerini E. Diffuse-type tenosynovial giant cell tumour: Current treatment concepts and future perspectives. *Eur J Cancer*. 2016;63:34-40.
22. Cassier PA, Gelderblom H, Stacchiotti S, Thomas D, Maki RG, Kroep JR, et al. Efficacy of imatinib mesylate for the treatment of locally advanced and/or metastatic tenosynovial giant cell tumor/pigmented villonodular synovitis. *Cancer*. 2012;118(6):1649-55.
23. Gelderblom H, Cropet C, Chevreau C, Boyle R, Tattersall M, Stacchiotti S, et al. Nilotinib in locally advanced pigmented villonodular synovitis: a multicentre, open-label, single-arm, phase 2 trial. *Lancet Oncol*. 2018.
24. Cassier PA, Italiano A, Gomez-Roca CA, Le Tourneau C, Toulmonde M, Cannarile MA, et al. CSF1R inhibition with emactuzumab in locally advanced diffuse-type tenosynovial giant cell tumours of the soft tissue: a dose-escalation and dose-expansion phase 1 study. *Lancet Oncol*. 2015;16(8):949-56.
25. Tap WD, Stacchiotti S, Palmerini P, Ferrari S, Desai J, Bauer S, Blay JY, Alcindor T, Ganjoo KN, Martin Broto J, Ryan CW, Edward Shuster DE, Zhang L, Wang Q, Hsu H, Lin PS, Tong S, Wagner AJ, editor Final results of ENLIVEN: A global, double-blind, randomized, placebo-controlled, phase 3 study of pexidartinib in advanced tenosynovial giant cell tumor (TGCT). ASCO conference; 2018; Chicago.
26. Gounder MM, Thomas DM, Tap WD. Locally Aggressive Connective Tissue Tumors. *Journal of clinical oncology : official journal of the American Society of Clinical Oncology*. 2018;36(2):202-9.
27. Chiari C, Pirich C, Brannath W, Kotz R, Trieb K. What affects the recurrence and clinical outcome of pigmented villonodular synovitis? *Clin Orthop Relat Res*. 2006;450:172-8.
28. Gouin F, Noailles T. Localized and diffuse forms of tenosynovial giant cell tumor (formerly giant cell tumor of the tendon sheath and pigmented villonodular synovitis). *Orthop Traumatol Surg Res*. 2017;103(15):S91-S7.
29. Palmerini E, Staals EL, Maki RG, Pengo S, Cioffi A, Gambarotti M, et al. Tenosynovial giant cell tumour/pigmented villonodular synovitis: outcome of 294 patients before the era of kinase inhibitors. *Eur J Cancer*. 2015;51(2):210-7.
30. Barile A, Sabatini M, Iannesi F, Di Cesare E, Splendiani A, Calvisi V, et al. Pigmented villonodular synovitis (PVNS) of the knee joint: magnetic resonance imaging (MRI) using standard and dynamic paramagnetic contrast media. Report of 52 cases surgically and histologically controlled. *La Radiologia medica*. 2004;107(4):356-6.