



Universiteit
Leiden
The Netherlands

Optimising the treatment of patients with long bone metastases

Willeumier, J.J.

Citation

Willeumier, J. J. (2018, November 6). *Optimising the treatment of patients with long bone metastases*. Retrieved from <https://hdl.handle.net/1887/66719>

Version: Not Applicable (or Unknown)

License: [Licence agreement concerning inclusion of doctoral thesis in the Institutional Repository of the University of Leiden](#)

Downloaded from: <https://hdl.handle.net/1887/66719>

Note: To cite this publication please use the final published version (if applicable).

Cover Page



Universiteit Leiden



The handle <http://hdl.handle.net/1887/66719> holds various files of this Leiden University dissertation.

Author: Willeumier, J.J.

Title: Optimising the treatment of patients with long bone metastases

Issue Date: 2018-11-06



Chapter 9

Treatment of pathological fractures of the long bones

J.J. Willeumier, Y.M. van der Linden, M.A.J. van de Sande,
P.D.S. Dijkstra

EFORT Open reviews 2016 May; 1 (5): 136-145

Abstract

- Bone metastases of the long bones often lead to pain and pathological fractures. Local treatment consists of radiotherapy or surgery. Treatment strategies are strongly based on the risk of the fracture and expected survival.
- Diagnostic work-up consists of CT and biopsy for diagnosis of the primary tumour, bone-scan or PET-CT for dissemination status, patient history and blood test for evaluation of general health, and biplanar radiograph or CT for evaluation of the involved bone.
- A bone lesion with an axial cortical involvement of >30 mm has a high risk of fracturing and should be stabilised surgically.
- Expected survival should be based on primary tumour type, performance score, and presence of visceral and cerebral metastases.
- Radiotherapy is the primary treatment for symptomatic lesions without risk of fracturing. The role of post-operative radiotherapy remains unclear.
- Main surgical treatment options consist of plate fixation, intramedullary nails and (endo) prosthesis. The choice of modality depends on the localisation, extent of involved bone, and expected survival. Adjuvant cement should be considered in large lesions for better stabilisation.

Introduction

Bone metastases arise most commonly in patients suffering from breast, prostate, kidney or lung cancer.¹ Two-thirds of all patients dying of cancer reportedly develop bone metastases,² however a modern, image-based study would probably present an even higher number. Due to constantly improving treatments the duration of the palliative phase is prolonged. Longer survival unfortunately gives each patient more time to develop metastases.

Bone metastases of the long bones may lead to pain, pathological fractures, immobility, decreased functioning, and hypercalcaemia. Over half of the patients experience clinical symptoms for which treatment is required,³ of whom only a minority is surgically treated.⁴ In the long bones, pain is the most common symptom, followed by impending or actual pathologic fractures in 10-25% of the patients.⁵ Pathologic fractures of the femur, 75% of which presenting in the proximal part, are roughly 3.5 times as common as fractures of the humerus.⁶

This review discusses the local management of (impending) pathological fractures of the long bones, with focus on surgical treatment strategies.

Diagnosis and evaluation

For successful management the following adage should be followed: stop; think and stage; act. The most important information is gathered with the following four questions and flow-chart (figure 9.1).

What is the origin of the lesion?

A bone lesion with unknown aetiology is a primary bone tumour until proven otherwise. Denying this possibility might deprive patients of correct and curative treatments. If the patient has no history of malignancy a (PET-)CT scan of the chest and abdomen should be performed. In case no primary tumour is visible, a core needle biopsy of the bone lesion should be performed for histologic identification before treatment is engaged. When the patient has already known malignancy, but has no previous metastases and the lesion is solitary, a biopsy should be considered. In case of multiple lesions and a malignancy at high-risk for developing metastases (e.g. lung cancer), generally no additional histological confirmation is necessary.

What is the dissemination status?

The presence of other disease localisations influences the treatment strategy. Bone dissemination can be grouped into three categories: solitary lesion,

oligometastases (between two and four bone metastases), or diffuse. Solitary lesions can in some cases (i.e. primary kidney cancer or bone sarcoma) be treated with curative, albeit generally palliative, intent.⁷ Defining a difference between oligometastases and diffuse metastases throughout the skeleton is a relatively new concept. Especially for kidney and breast cancer patients it is hypothesised that a more aggressive local treatment in the case of oligometastases might improve survival.⁸ In the past, the principal examination to assess the bone dissemination status was a total-body bone scintigraphy (technetium-99m or fluoride-18 scan). Currently the use of PET-CT is accelerating due to its increased accessibility and superior sensitivity and specificity to bone scintigraphy.⁹ Additionally, PET-CT provides information on other (visceral) disease localisations. If PET-CT is unavailable, then an additional CT of the thorax/abdomen should be considered to analyse visceral dissemination.

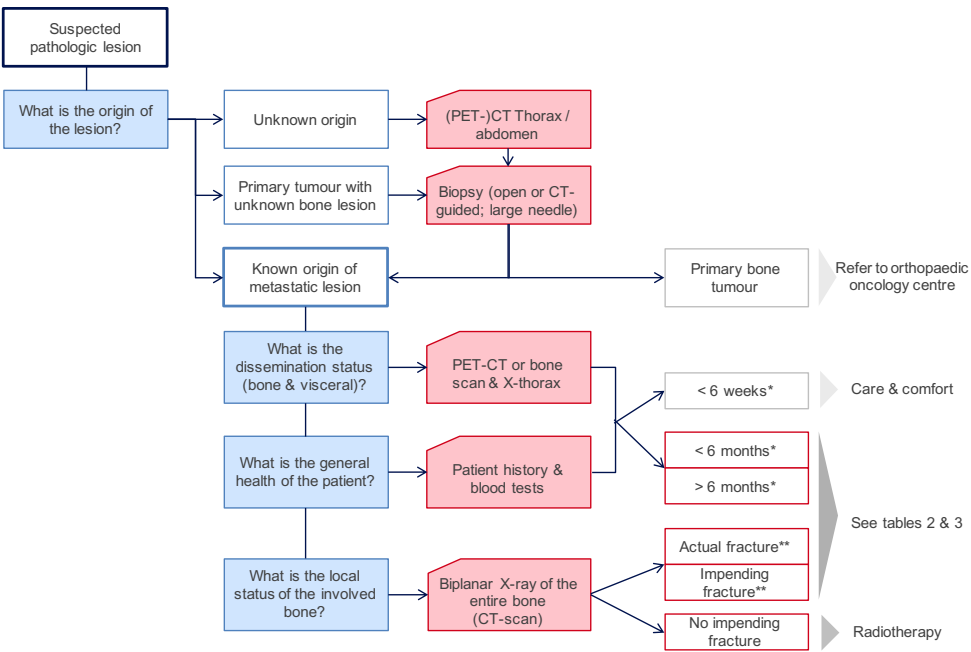


Figure 9.1 Flowchart of diagnostic tests.
*Survival prediction according to primary tumour type, patient performance score, visceral or cerebral metastases.¹⁹ **Fracture risk according to axial cortical involvement or circumferential cortical involvement of >50%.¹³

What is the general health of the patient?

The general health status can be deduced from the patient history (nutritional status, weight loss and cognitive status, for example). Dehydration, thirst or drowsiness can suggest hypercalcaemia and blood tests (serum calcium and albumin) should be performed. If surgery is planned, laboratory studies should include a complete differential blood-cell count, erythrocyte sedimentation rate, C-reactive protein, electrolyte count (sodium, potassium), and serum alkaline phosphate.

What is the local status of the involved bone?

In daily practise, bi-planar conventional radiographs of the whole affected long bone are mandatory to evaluate the extent of the cortical destruction of the involved bone lesion and whether other adjacent bone lesions are present. The cortical destruction is a measure for estimating the fracture risk. A CT scan is a more precise alternative for obtaining this information; however, routine use of CT scans is less practical and more expensive than radiographs and thus not advised as a primary imaging modality.

The information gathered with the standard work-up provides the basis for staging of the patient and determining the treatment strategy. The first step is the decision in a multi-disciplinary meeting on whether surgery is required. Radiotherapy is the treatment of choice for small lesions, while surgery is indicated for actual fractures. The difficulty lies in the group of patients with larger lesions and an uncertain risk of fracturing. All treatments aim to maintain optimal, pain-free function of the extremities and should ensure direct weight bearing and mobility. Two important principles should be adhered.

Prophylactic stabilisation of bone should be performed if there is a substantial risk of fracturing. If the risk of fracturing is low, the appropriate treatment is radiotherapy. While there is general consensus about the advantages of operating impending fractures over actual fractures, a clear, international definition of ‘a substantial risk’ has not been defined.¹⁰ To prevent over- and under-treatment, a careful balance between the advantages of a prophylactic treatment *versus* the risks of surgery and disadvantages of over-treatment for the patient has to be made. Multiple different factors for an impending fracture have been described, such as pain, size, site, and lesion aspect.^{11,12} However, because these factors are based on retrospective research, their predictive value is low.¹⁰ Based on prospective research, we advise the use of the axial cortical involvement of > 30mm and a circumferential cortical involvement of >50% as predictive factors for fracturing (figure 9.2).¹³ Although the future of

fracture risk analysis is CT-based,¹⁴ the axial cortical involvement is the most practical tool to use if only conventional radiographs are available.

The selected rigid fixation should be durable for the remaining lifetime of the patient, while the recovery and rehabilitation time should not exceed the life expectancy. Survival can range from days to many years depending primarily on the primary tumour type. Median survival for patients with bone metastases from lung cancer is three months, while this extends to ten months for prostate and 17 months for breast cancer.¹⁵ Multiple factors are considered prognostic for survival besides primary tumour type and various prognostic models based on these factors have been designed, as shown in table 9.1.^{4,15-20} We advise the prediction of survival according to a simple and straightforward model, including primary tumour type, performance score, and the presence of visceral or cerebral metastases (figure 9.3).¹⁹

If survival is less than six weeks, the possible benefits of a surgical intervention need to be strongly considered and generally care with conservative measures should be sought (such as care at a hospice). If surgical intervention is absolutely required, it should be as minimally invasive as possible with a short recovery time. For patients with an expected short-term survival (between six weeks and six months), more invasive procedures are warranted. However, the use of extensive reconstructions or large, complication-prone prostheses should not be pursued. Long-term survival (expected survival > six months) justifies and requires comprehensive surgery.

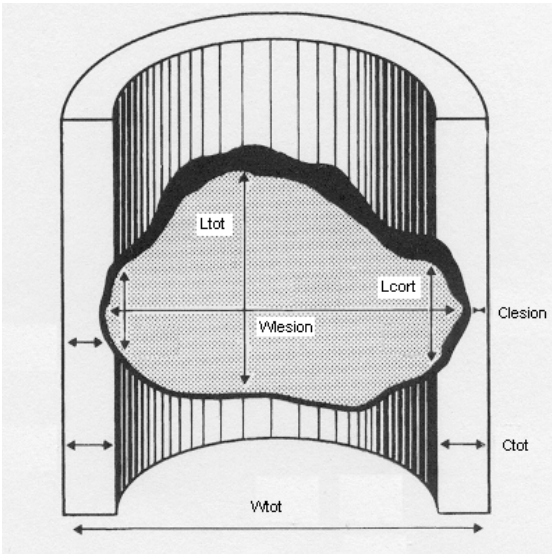


Figure 9.2 Measurement of metastatic lesions in the femur (in mm): largest axial measurement of lesion (L-lesion), largest transverse extension of the lesion (W-lesion), largest axial cortical involvement (L-cort). (Reprinted with permission from: van der Linden YM, Kroon HM, Dijkstra SPDS, Lok JJ, Noordijk EM, Leer JWH, et al. Simple radiographic parameter predicts fracturing in metastatic femoral bone lesions: results from a randomised trial. Radiotherapy and Oncology. 2003; 69(1):21-31)

Table 9.1 Prognostic factors for survival in patients with bone metastases

	BAU	FOR	RAT	BOL	KAT	WES	JAN
Site of bone	Skeletal	Skeletal	Skeletal	Spinal	Skeletal	Skeletal	LB
Number of patients	241	189	1195	1043	350	1157	927
Primary treatment	Sur	Sur	Sur	Con/Sur	Con/Sur	Con	Sur
Primary tumour	X	X	X	X	X	X ^{++†}	X
Performance status			X	X	X	X ^{++†}	
Visceral metastasis	X	X	X	X	X	X [†]	X
Cerebral metastases	X			X	X		
Lymph node		X					
Number of metastases	X		X		X		X
Chemotherapy					X		
Age							X
Comorbidity							X
BMI <18.5 kg/m ²							X
Laboratory results		X			X		X
Gender		X				X [†]	
Pathologic fracture	X	X					
Surgeons' estimate		X					
Patient reported pain						X [†]	

BAU: Bauer 1995¹⁶; FOR: Forsberg 2011¹⁷; RAT: Ratasvuori 2013¹⁸; BOL: Bollen 2014¹⁹; KAT: Katagiri revised 2014²⁰; WES: Westhoff 2014¹⁵ *simplified model, †complex model; JAN: Janssen 2015. Skeletal: all sites. Spinal: axial skeleton. LB: long bones. Con: chemo/radiotherapy, Sur: surgery.

Radiotherapy

Palliative radiotherapy for painful bone metastases is well established and provides an effective symptomatic treatment. Overall response rate is 60%, depending on the primary tumour and the expected survival time.²¹ A single fraction of 8 Gy is presently considered standard treatment for painful lesions with a low risk of fracture. If pain is recurrent after a single fraction, a second or third fraction of 8 Gy can be given without many treatment side-effects. For large lesions with extensive osseous destruction, it is believed that a higher total dose given in a fractionated scheme will lead to a higher tumour response with remineralisation to strengthen the bone and postpone the occurrence of a fracture.²²

Post-operative radiotherapy is commonly advised as prophylaxis for tumour progression and implant failure.²³ However, this is not evidence based and further prospective research should be performed before statements can be made concerning the effectiveness of adjuvant radiotherapy for all patients.

1. Clinical Profile	Favorable				Moderate		Unfavorable	
2. Karnofsky	100 - 80		70 - 10		100 - 80	70 - 10	100 - 80	70 - 10
3. Visceral/ brain metastases	No	Yes	No	Yes				
Category	A >12	B 6-12	B 6-12	C 3-6	B 6-12	C 3-6	C 3-6	D < 3

Figure 9.3 Prediction model for survival. Category (A-D) indicates expected survival in months. (Reprinted with permission from: Bollen L, van der Linden YM, Pondaag W, Fiocco M, Pattynama BPM, Marijnen CAM, et al. Prognostic factors associated with survival in patients with symptomatic spinal bone metastases: a retrospective cohort study of 1 043 patients. *Neuro-Oncology*. 2014 Jul; 16(7):991-8)

Surgery

Differing skeletal locations, life expectancies, patient characteristics (for example obesity) and types of fractures lead to variation in treatments. The planned procedure generally entails an intralesional approach. A more extensive procedure is unnecessary for oncologic control. An en-bloc resection is only indicated when there is vast destruction of bone or in the rare occasion of a curative intent of the procedure. In patients with actual fractures due to metastases of kidney and thyroid cancer, pre-operative embolisation of the metastasis is advised to prevent excessive peri-operative blood loss.²⁴ Surgery should be performed within 72 hours following embolisation.

For all pathologic fractures of the long bones, three principal surgical treatment options exist: intramedullary nail, plate, or (endo) prosthesis.

Intramedullary nails offer several advantages: they protect a long segment of bone, the necessary dissection is relatively small, blood supply to the

periosteum is preserved, and rigid fixation can be achieved by locking with proximal and distal interlocking screws, and/or by using bone cement surrounding the nail.²⁵ All intramedullary nails need distal locking to provide rotation stabilisation and prevent failure of fixation.²⁶ Proximal fixation can be achieved with standard screws or with an interlocking lag screw or helical blade, for both the femur and the humerus. The large lag screw or helical blade allows for a stronger construct due to the increased surface area contact. An intramedullary nail allows for immediate and unrestricted stability. With time, however, intramedullary nails without cement augmentation are at risk of failure, because they are load-sharing devices instead of load-bearing devices. Other disadvantages are the need for adequate bone stock at the site of the locking screw(s) and its inapplicability for lesions close to the joint.

Plate fixation offers several advantages: damage to the muscle cuff can be avoided, very distal fractures can also be adequately fixated, and a rigid fixation is possible with locking screws. In addition, the open approach provides good access and visualisation for curettage, fracture reduction and reposition, and application of adjuvant cement. The downsides of using a plate are the large incision needed, a longer surgical procedure and the lack of prophylactic fixation of the entire bone.

Prosthetic reconstructions (endoprosthesis, segmental prostheses, hemi- and total joint arthroplasty) provide immediate stability, independent of the degree of fracture healing, and the risk of local progression or implant failure is minimized.²⁷ The principal drawback of this method is the high risk of complications.²⁸ The surgery is extensive, muscles need detaching and reattaching, and it is associated with increased blood loss.²⁹ In addition, if post-operative radiotherapy is believed to be an important adjuvant treatment, endoprostheses should not be used due to radiotherapy-induced osteoporosis and impaired bone healing, leading to inadequate screw fixation.³⁰ The high costs of endoprostheses used to be a significant factor to take into account. However, manufacturers are developing cheaper endoprostheses indicated especially for metastatic disease so this has become a less decisive aspect.

Each region has its own options and treatment strategies, as shown in tables 9.2 and 9.3 for the femur and humerus, respectively. If the tibia, ulna, or radius is involved, treatment strategies for the humerus should be followed. Despite the extensive period of time during which bone metastases have been treated, no randomised controlled trials have been performed to evaluate the best surgical procedures for each setting.³¹ Therefore, the recommended procedures are mostly based on retrospective observational studies and clinical experience.

Femur

Pathologic fractures of the proximal femur are most common in the femoral neck, followed by the sub and intertrochanteric regions, the diaphysis, and distal femur.³² The different treatment approaches are given in table 9.2.

In general, the treatment strategy of the femur depends on the involvement of the acetabulum. If the acetabulum is grossly affected, a (modular) total hip arthroplasty (THA) with cup augmentation is indicated. When placing a THA for metastatic disease a relatively high risk of dislocation should be acknowledged. The muscular cuff is very likely weak or insufficient due to previous systemic treatment, radiotherapy, or immobilisation. To minimize the risk of hip dislocation we recommend a dual-mobility cup. In cases with extensive involvement of the proximal femur and acetabulum and where long-term survival is expected, a hemi-pelvic endoprosthesis is more suitable. If the acetabulum is unaffected or marginally affected (less than one-third of the circumference), the strategy depends on the localisation.

For pathologic fractures of the femoral head and neck a (cemented) hemi-arthroplasty is recommended. The secondary degenerative changes associated with hemiarthroplasties will rarely present.³³ A long stem provides prophylactic stabilisation of the entire femur shaft, but is accompanied with higher risks of complications such as thrombo-embolic events.³⁴ It is unclear in literature whether a long stem should be routinely placed.³⁵

The optimal treatment of pathologic fractures of the trochanteric region is a frequently discussed issue. The options consist of intramedullary reconstruction nails and prosthetic reconstruction, but there is poor evidence as to which serves patients better.³⁶ The decision is primarily based on the quality of bone stock. If the bone stock is sufficient to create a stable situation (i.e. a small or solitary lesion), an intramedullary reconstruction nail including femoral neck and head fixation is advised for both actual and impending fractures as for both patients with a short and long expected survival.³⁷ Cement can be considered to prevent mechanical failure, especially if the expected survival is long. If there is insufficient bone stock and doubt exists concerning the durability of the screw fixation in the femoral head, the choice of treatment needs more careful consideration. For patients with short-term survival, an intramedullary reconstruction nail with cement will provide sufficient stability, despite poor bone stock and irrelevant to the type of fracture. Patients with long-term expected survival and an actual fracture should be treated with a proximal femur modular tumour-prosthesis (PF-MTP) to provide an adequately durable situation (figure 9.4).³⁸ A PF-MTP can also be considered if patients with a long-

term survival present with an impending fracture; however, it might not be necessary, and intramedullary nailing with cement can provide sufficient stabilisation.

Pathologic fractures of the diaphysis are commonly treated with intramedullary nails or plate osteosynthesis. If multiple lesions exist throughout the diaphysis, an intramedullary nail is recommended. Large lesions (>6cm) can be curetted prior to stabilisation and adjuvant cement will further stabilise the nail (figure 9.5). An intramedullary nail is also recommended for an impending fracture through a small or solitary lesion. However, if an actual fracture presents through a small lesion, open reduction and plate fixation with adjuvant cement is an adequate option, irrespective of the expected survival. In cases with a long survival and solitary metastases (for example, renal cell) or very large and destructive diaphyseal lesions, a segmental prosthesis of the diaphysis is an option.

The treatment of pathologic fractures of the distal femur generally consists of plating with adjuvant cement. However, if the condyles or metaphyses are largely affected the fixation of a plate is often impossible. In that case a distal femur modular tumour-prosthesis (DF-MTP) is recommended (figure 9.6). A DF-MTP should also be considered for patients with long-term survival and fractures due to distal or metaphyseal lesions. If there is no actual fracture yet and survival is short-term, cement injection only, or in combination with radio-frequency ablation, can be sufficient. However, if long-term survival is expected this might not provide sufficient prophylactic stabilization for an impending fracture, and an intramedullary nail with cement in the lesion or a DF-MTP should be considered.

Humerus

After the femur, the humerus is the second most commonly affected long bone by metastases.³⁹ The mainstay treatment is rigid surgical stabilisation because of a high incidence of nonunion and inadequate relief of pain with conservative treatment.⁴⁰ Although the upper extremities are not primarily weight-bearing, the proximal humerus is subject to rotational and bending forces due to the action of the rotator cuff, deltoid, pectoralis major and latissimus dorsi muscles. This demands great torsional strength of any kind of implant.⁴¹ An overview of treatment options is given in table 9.3.

For the humeral head, options consist of plate fixation or a cemented hemi-arthroplasty. The latter should be considered for actual fractures in patients with long-term survival needing elaborate reconstruction due to inadequate

bone stock. However, if the expected survival is short, there is adequate bone stock, or there is only an impending fracture one should refrain from being too invasive. Lesions in the proximal humerus generally require curettage and augmentation to prevent rapid local progression and loosening of the osteosynthesis.⁴² Therefore plate fixation is often the fixation method of choice. This gives immediate rigidity and allows for unrestricted function quickly post-operative.⁴³ Fixation with an ante-grade intramedullary nail and helical blade (or screws) strengthened with adjuvant cement is also possible; however, this is more appropriate in cases with extended involvement of the shaft than in cases with only proximal involvement. Total shoulder prostheses are not advised for bone metastases due to the high rate of complications, mainly recurring dislocations. If the glenoid is affected together with the proximal humerus, this can be filled up with cement.

Fractures affecting the humeral shaft can be treated with plate fixation or intramedullary fixation (figure 9.7a and b, respectively). In the region between 2-3 cm distal to the greater tuberosity and 5 cm proximal to the olecranon fossa, intramedullary nails achieve adequate stabilisation.⁴⁴ Depending on the lesion size, adjuvant cement might be required to provide adequate fixation. If an open approach is chosen for augmentation, a plate fixation can then also be chosen. Impending fractures of the shaft can always be treated with intramedullary nails. In patients with short expected survival or high surgical risks (ASA 4), percutaneous, photodynamic intramedullary stabilization systems can also be an option to examine.⁴⁵ The humeral diaphysis can also be treated with segmental prostheses according to the indications in the femur diaphysis.⁴⁶

Bone metastases arising in the distal humerus are rare and present unique treatment challenges.⁴⁷ For actual fractures, intramedullary stabilisation will generally not provide sufficient stabilisation due to the anatomical localisation, thus plating with cement is advised. An impending fracture of the distal humerus can in most cases be treated with an intramedullary nail. Prosthetic reconstruction of the distal humerus rarely gives an adequate outcome and is associated with significant risks for complications and infections, and should not be pursued in a palliative setting.

Conclusion

The treatment of patients with impending or actual pathological fractures of the long bones requires multi-disciplinary teamwork. Treatment highly depends on the fracture risk in relation to expected survival. Further individual tailoring is

required to define the most optimal palliative strategy for each affected patient to maintain his or her quality of life.

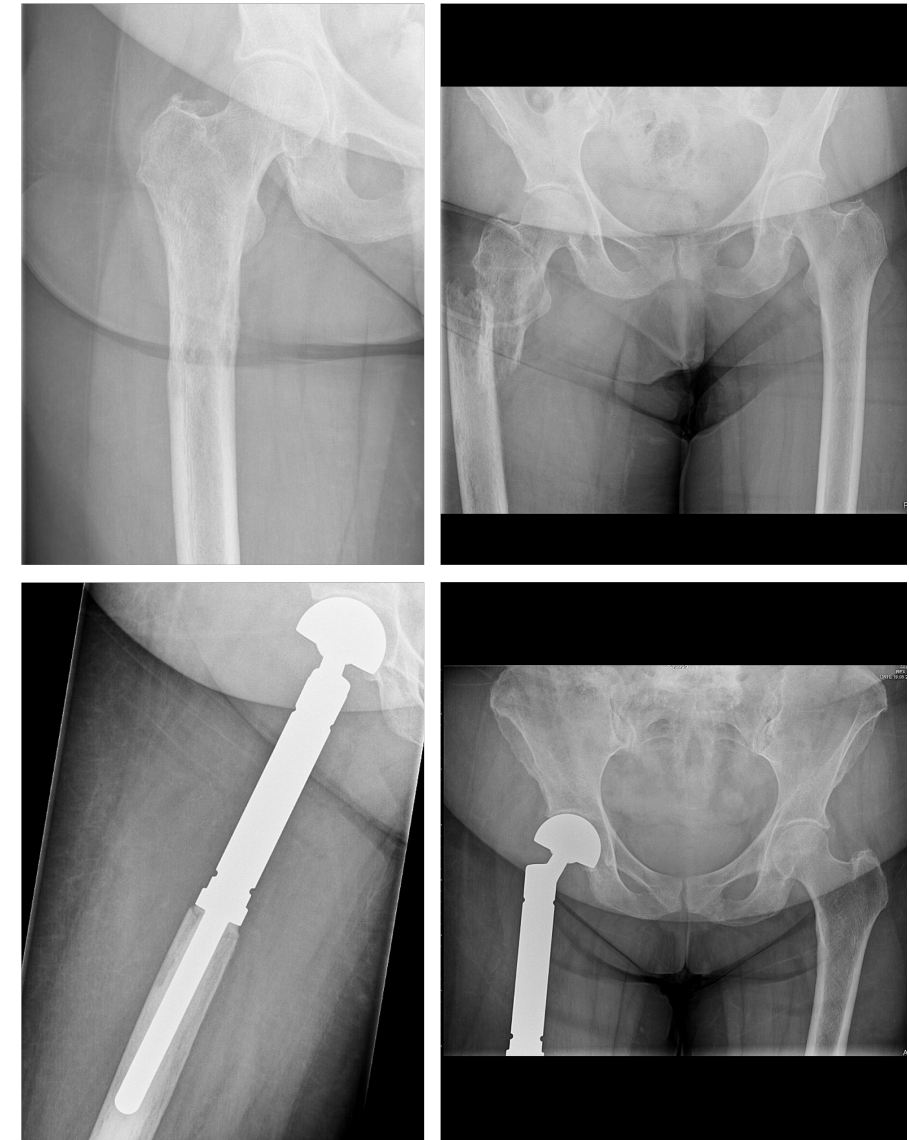


Figure 9.4 Patient with osseous and pulmonary metastases from breast cancer. Progression of the proximal femur lesion in one month with subtrochanteric pathologic fracture as result. Expected survival: > 6 months. A PF-MTP with cement was placed.

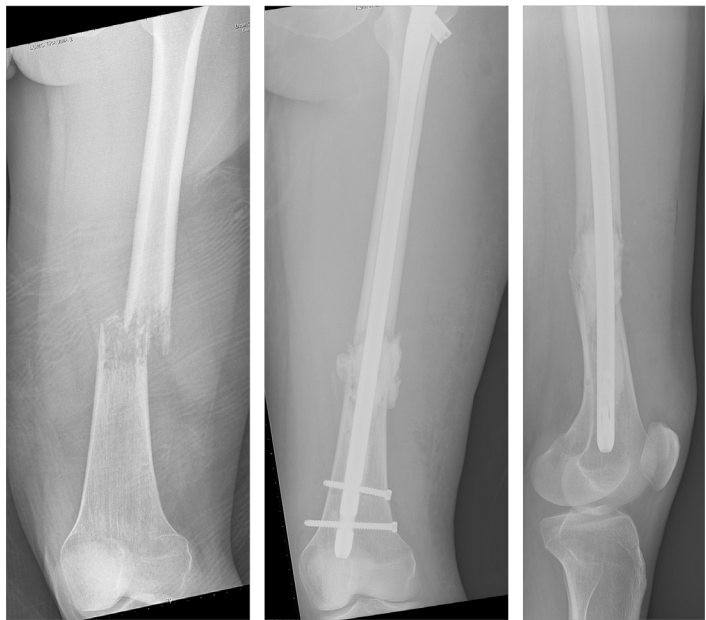

Figure 9.5 Patient with osseous and cerebral metastases from melanoma. Pathologic diaphyseal femur fracture after turning in bed. Expected survival < 6 months. Fracture stabilisation with intramedullary nail with curettage and augmentation of the lesion.

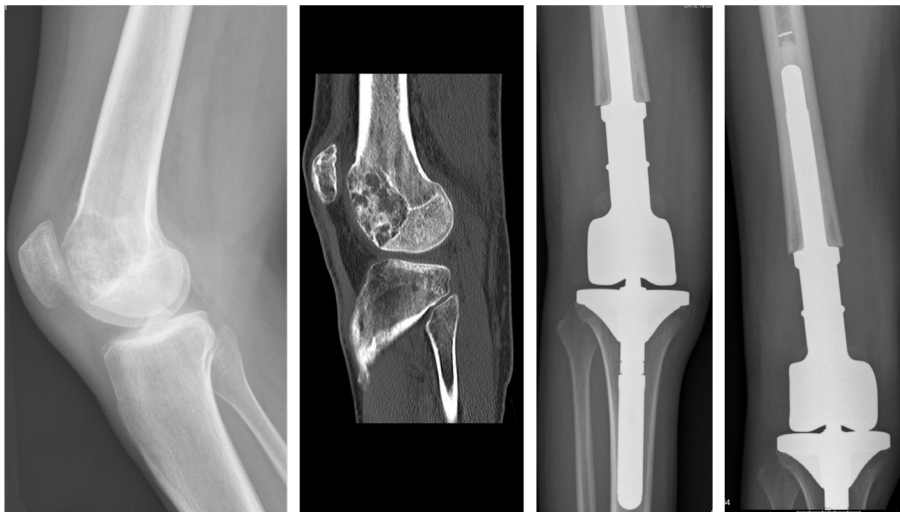

Figure 9.6 Patient with solitary bone metastasis from non small cell lung carcinoma (diagnosed and treated 4,5 years ago). Metastasis of distal femur with extensive destruction 1,5 year after radiotherapy for this lesion. Expected survival: > 6 months. Resection and reconstruction with DF-MTP.

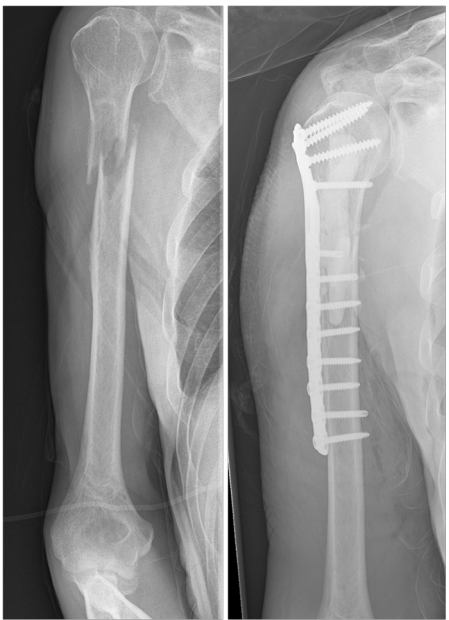

Figure 9.7a Patient with osseous metastases from lung carcinoma. Pathologic fracture of proximal humerus diaphysis. Expected survival < 6 months. Plate fixation with cement.

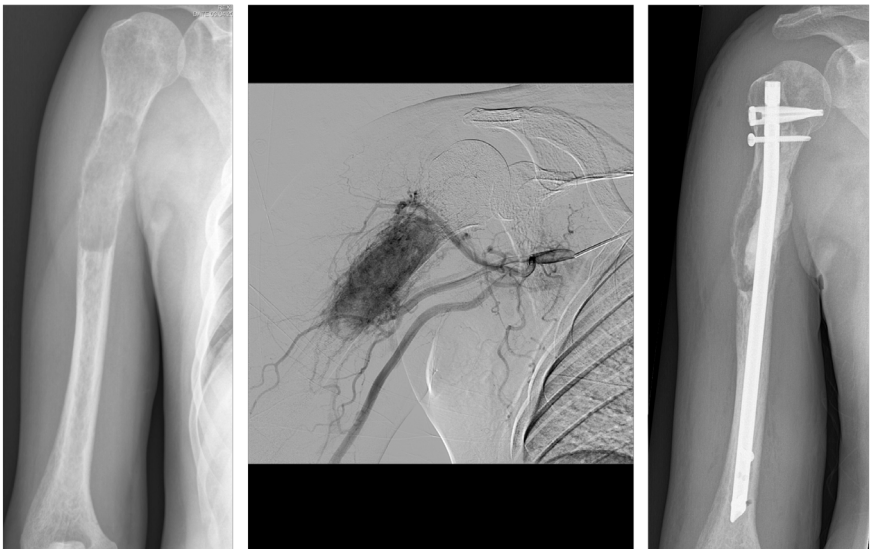


Figure 9.7b Patient with osseous metastases from renal cell carcinoma. Pathologic fracture of proximal humerus diaphysis. Expected survival < 6 months. Pre-operative embolisation and intramedullary nail fixation with cement and helical blade.

Table 9.2 Surgical treatment of metastatic lesions of the femur

	Actual fracture		Impending fracture	
	Short-term survival (< 6 months)	Long-term survival (> 6 months)	Short-term survival (< 6 months)	Long-term survival (> 6 months)
Acetabulum largely affected	THP	THP or pAMP + C	THP	THP or pAMP + C
Head/neck	Hemi + C	Hemi + C	Hemi + C	Hemi + C
Inter/sub trochanteric	IMN	IMN	IMN	IMN
	Adequate bone stock (small / solitary*)			
	Inadequate bone stock (large / multiple*)	PF-MTP + C	IMN	IMN or PF-MTP + C
Diaphysis	Small / solitary*	Plate [#] + C	Plate [#] + C or IMN	IMN or SP
Metaphysis	Large / multiple*	IMN	IMN	IMN or SP
		Plate [#] + C	(Plate [#] +) C	IMN
Condyles	Small / solitary*	Plate [#] + C	(Plate [#] +) C	(Plate [#] +) cement or DF-MTP
	Large / multiple*	DF-MTP	DF-MTP	DF-MTP

All types of treatments are intralesional. Adjuvant cement (C; polymethylmetacrylate) with intramedullary nails is indicated if expected survival is long or if the bone stock is inadequate. Treat sites with impaired strength with cement, i.e. at screw fixation through nail and at metastatic lesion.

[#]The use of locked plate-screw plate fixations generally makes double plating unnecessary. If conventional plates are used, double plating should be considered. *Number of metastases in the affected region. THP = total hip arthroplasty; Hemi = hemi hip arthroplasty; pAMP = periacetabular modular prosthesis; IMN = antegrade placed intramedullary nail (reconstruction type); PF-MTP = proximal femur modular tumour prosthesis; DF-MTP = distal femur modular tumour prosthesis; SG = segmental prosthesis.

Table 9.3 Surgical treatment of metastatic lesions of the humerus

	Actual fracture		Impending fracture	
	Short-term survival (< 6 months)	Long-term survival (> 6 months)	Short-term survival (< 6 months)	Long-term survival (> 6 months)
Proximal humerus head	bone	IMN + HB	IMN + HB	IMN + HB
	Adequate stock			
	Inadequate stock	Plate [#] + C	IMN + HB + C or HSP + C	IMN + HB + C
glenoid		Cement	Cement	Cement
Shaft	Small / solitary*	Plate [#] + C or IMN	Plate [#] + C or IMN or SP	IMN or SP
	Large / multiple*	IMN	IMN or SP	IMN or SP
Distal	All sizes	Plate [#] + C	Plate [#] + C	Plate [#] + C

All types of treatments are intralesional. Adjuvant cement (C; polymethylmetacrylate) with intramedullary nails is indicated if expected survival is long or if the bone stock is inadequate. Treat sites with impaired strength with cement, i.e. at screw fixation through nail and at metastatic lesion.

[#]The use of locked plate-screw plate fixations generally makes double plating unnecessary. If conventional plates are used, double plating should be considered. *Number of metastases in the affected region. IMN = intramedullary nail; SP = segmental prosthesis; HB = helical blade. HSP = hemi shoulder prosthesis.

References

1. Coleman RE. Metastatic bone disease: clinical features, pathophysiology and treatment strategies. *Cancer Treat Rev* 2001;27-3:165-76.
2. Galasko CSB. *The anatomy and pathways of skeletal metastases*. Boston: GK Hall, 1981.
3. Oster G, Lamerato L, Glass A, Richert-Boe K, Lopez A, Chung K, Richhariya A, Dodge T, Wolff G, Balakumaran A, Edelsberg J. Natural history of skeletal-related events in patients with breast, lung, or prostate cancer and metastases to bone: a 15-year study in two large US health systems. *Supportive Care in Cancer* 2013;21-12:3279-86.
4. Katagiri H, Okada R, Takagi T, Takahashi M, Murata H, Harada H, Nishimura T, Asakura H, Ogawa H. New prognostic factors and scoring system for patients with skeletal metastasis. *Cancer Med* 2014.
5. Saad F, Lipton A, Cook R, Chen YM, Smith M, Coleman R. Pathologic fractures correlate with reduced survival in patients with malignant bone disease. *Cancer* 2007;110-8:1860-7.
6. Piccioli A, Spinelli MS, Maccauro G. Impending fracture: A difficult diagnosis. *Injury* 2014;45 Suppl 6:S138-41.
7. Ratasvuori M, Wedin R, Hansen BH, Keller J, Trovik C, Zaikova O, Bergh P, Kalen A, Laitinen M. Prognostic role of en-bloc resection and late onset of bone metastasis in patients with bone-seeking carcinomas of the kidney, breast, lung, and prostate: SSG study on 672 operated skeletal metastases. *J Surg Oncol* 2014.
8. Di Lascio S, Pagani O. Oligometastatic breast cancer: a shift from palliative to potentially curative treatment? *Breast Care (Basel)* 2014;9-1:7-14.
9. Pires AO, Borges US, Lopes-Costa PV, Gebrim LH, da Silva BB. Evaluation of bone metastases from breast cancer by bone scintigraphy and positron emission tomography/computed tomography imaging. *Eur J Obstet Gynecol Reprod Biol* 2014.
10. Van der Linden YM, Dijkstra PD, Kroon HM, Lok JJ, Noordijk EM, Leer JW, Marijnen CA. Comparative analysis of risk factors for pathological fracture with femoral metastases. *J Bone Joint Surg Br* 2004;86-4:566-73.
11. Harrington KD. New Trends in the Management of Lower Extremity Metastases. *Clinical Orthopaedics and Related Research* 1982;169:53-61.
12. Mirels H. Metastatic disease in long bones. A proposed scoring system for diagnosing impending pathologic fractures. *Clin Orthop Relat Res* 1989-249:256-64.
13. van der Linden YM, Kroon HM, Dijkstra SPDS, Lok JJ, Noordijk EM, Leer JWH, Marijnen CAM. Simple radiographic parameter predicts fracturing in metastatic femoral bone lesions: results from a randomised trial. *Radiotherapy and Oncology* 2003;69-1:21-31.
14. Damron TA, Nazarian A, Entezari V, Brown C, Grant W, Calderon N, Zurakowski D, Terek RM, Anderson ME, Cheng EY, Aboulafia AJ, Gebhardt MC, Snyder BD. CT-based Structural Rigidity Analysis Is More Accurate Than Mirels Scoring for Fracture Prediction in Metastatic Femoral Lesions. *Clin Orthop Relat Res* 2015.
15. Westhoff PG, de Graeff A, Monninkhof EM, Bollen L, Dijkstra SP, van der Steen-Banasik EM, van Vulpen M, Leer JW, Marijnen CA, van der Linden YM, Dutch Bone Metastasis Study G. An easy tool to predict survival in patients receiving radiation therapy for painful bone metastases. *Int J Radiat Oncol Biol Phys* 2014;90-4:739-47.
16. Bauer H, Wedin R. Survival after surgery for spinal and extremity metastases. Prognostication in 241 patients. *Acta Orthop Scand* 1995;66-2:143-6.
17. Forsberg JA, Eberhardt J, Boland PJ, Wedin R, Healey JH. Estimating survival in patients with operable skeletal metastases: an application of a bayesian belief network. *PLoS One* 2011;6-5:e19956.
18. Ratasvuori M, Wedin R, Keller J, Nottrott M, Zaikova O, Bergh P, Kalen A, Nilsson J, Jonsson H, Laitinen M. Insight opinion to surgically treated metastatic bone disease: Scandinavian Sarcoma Group Skeletal Metastasis Registry report of 1195 operated skeletal metastasis. *Surg Oncol* 2013;22-2:132-8.
19. Bollen L, van der Linden YM, Pondaag W, Fiocco M, Pattynama BP, Marijnen CA, Nelissen RG, Peul WC, Dijkstra PD. Prognostic factors associated with survival in patients with symptomatic spinal bone metastases: a retrospective cohort study of 1 043 patients. *Neuro Oncol* 2014.
20. Janssen SJ, van der Heijden AS, van Dijke M, Ready JE, Raskin KA, Ferrone ML, Hornicek FJ, Schwab JH. 2015 Marshall Urist Young Investigator Award: Prognostication in Patients With Long Bone Metastases: Does a Boosting Algorithm Improve Survival Estimates? *Clin Orthop Relat Res* 2015.
21. Chow E, Zeng L, Salvo N, Dennis K, Tsao M, Lutz S. Update on the systematic review of palliative radiotherapy trials for bone metastases. *Clin Oncol (R Coll Radiol)* 2012;24-2:112-24.
22. van der Linden YM, Lok JJ, Steenland E, Martijn H, van Houwelingen H, Marijnen CA, Leer JW, Dutch Bone Metastasis Study G. Single fraction radiotherapy is efficacious: a further analysis of the Dutch Bone Metastasis Study controlling for the influence of retreatment. *Int J Radiat Oncol Biol Phys* 2004;59-2:528-37.
23. Townsend PW, Smalley SR, Cozad SC, Rosenthal HG, Hassanein RE. Role of postoperative radiation therapy after stabilization of fractures caused by metastatic disease. *Int J Radiat Oncol Biol Phys* 1995;31-1:43-9.
24. Pazonis TJ, Papanastassiou ID, Maybody M, Healey JH. Embolization of hypervascular bone metastases reduces intraoperative blood loss: a case-control study. *Clin Orthop Relat Res* 2014;472-10:3179-87.
25. Kistler BJ, Damron TA. Latest Developments in Surgical and Minimally Invasive Treatment of Metastatic Bone Disease. *Current Surgery Reports* 2014;2-4.
26. Miller BJ, Soni EE, Gibbs CP, Scarborough MT. Intramedullary nails for long bone metastases: why do they fail? *Orthopedics* 2011;34-4.

27. Harvey N, Ahlmann ER, Allison DC, Wang L, Menendez LR. Endoprostheses last longer than intramedullary devices in proximal femur metastases. *Clin Orthop Relat Res* 2012;470-3:684-91.
28. Pala E, Trovarelli G, Calabro T, Angelini A, Abati CN, Ruggieri P. Survival of modern knee tumor megaprotheses: failures, functional results, and a comparative statistical analysis. *Clin Orthop Relat Res* 2015;473-3:891-9.
29. Issack PS, Barker J, Baker M, Kotwal SY, Lane JM. Surgical management of metastatic disease of the proximal part of the femur. *J Bone Joint Surg Am* 2014;96-24:2091-8.
30. Dijkstra S, Stapert J, Boxma H, Wiggers T. Treatment of pathological fractures of the humeral shaft due to bone metastases: a comparison of intramedullary locking nail and plate osteosynthesis with adjunctive bone cement. *Eur J Surg Oncol* 1996;22-6:621-6.
31. Wood TJ, Racano A, Yeung H, Farrokhhyar F, Ghert M, Deheshi BM. Surgical Management of Bone Metastases: Quality of Evidence and Systematic Review. *Ann Surg Oncol* 2014.
32. Wedin R, Bauer HC. Surgical treatment of skeletal metastatic lesions of the proximal femur: endoprosthesis or reconstruction nail? *J Bone Joint Surg Br* 2005;87-12:1653-7.
33. van Egmond PW, Taminiau AHM, van der Heide HJL. Hemiarthroplasties in young patients with osteonecrosis or a tumour of the proximal femur; an observational cohort study. *BMC Musculoskeletal Disorders* 2013;14-1:31.
34. Herrenbruck T, Erickson E, Damron TA, Heiner J. Adverse clinical events during cemented long-stem femoral arthroplasty. *Clinical orthopaedics and related research* 2002;395:154-63.
35. Xing Z, Moon BS, Satcher RL, Lin PP, Lewis VO. A long femoral stem is not always required in hip arthroplasty for patients with proximal femur metastases. *Clin Orthop Relat Res* 2013;471-5:1622-7.
36. Steensma M, Healey JH. Trends in the surgical treatment of pathologic proximal femur fractures among Musculoskeletal Tumor Society members. *Clin Orthop Relat Res* 2013;471-6:2000-6.
37. Piccioli A, Rossi B, Scaramuzzo L, Spinelli MS, Yang Z, Maccauro G. Intramedullary nailing for treatment of pathologic femoral fractures due to metastases. *Injury* 2014;45-2:412-7.
38. Henrichs MP, Krebs J, Gosheger G, Streitbuerger A, Nottrott M, Sauer T, Hoell S, Singh G, Harges J. Modular tumor endoprostheses in surgical palliation of long-bone metastases: a reduction in tumor burden and a durable reconstruction. *World J Surg Oncol* 2014;12-1:330.
39. Toma CD, Dominkus M, Nedelcu T, Abdolvahab F, Assadian O, Krepler P, Kotz R. Metastatic bone disease: a 36-year single centre trend-analysis of patients admitted to a tertiary orthopaedic surgical department. *J Surg Oncol* 2007;96-5:404-10.
40. Sarahrudi K, Wolf H, Funovics P, Pajenda G, Hausmann JT, Vecsei V. Surgical treatment of pathological fractures of the shaft of the humerus. *J Trauma* 2009;66-3:789-94.
41. Al-Jahwari A, Schemitsch EH, Wunder JS, Ferguson PC, Zdero R. The biomechanical effect of torsion on humeral shaft repair techniques for completed pathological fractures. *J Biomech Eng* 2012;134-2:024501.
42. Weiss KR, Bhumbra R, Biau DJ, Griffin AM, Deheshi B, Wunder JS, Ferguson PC. Fixation of pathological humeral fractures by the cemented plate technique. *J Bone Joint Surg Br* 2011;93-8:1093-7.
43. Frassica FJ, Frassica DA. Evaluation and treatment of metastases to the humerus. *Clin Orthop Relat Res* 2003-415 Suppl:S212-S8.
44. Redmond BJ, Biermann JS, Blasier RB. Interlocking intramedullary nailing of pathological fractures of the shaft of the humerus. *J Bone Joint Surg Am* 1996;78-6:891-6.
45. Vegt P, Muir JM, Block JE. The Photodynamic Bone Stabilization System: a minimally invasive, percutaneous intramedullary polymeric osteosynthesis for simple and complex long bone fractures. *Med Devices (Auckl)* 2014;7:453-61.
46. Ahlmann ER, Menendez LR. Intercalary endoprosthetic reconstruction for diaphyseal bone tumours. *J Bone Joint Surg Br* 2006;88-11:1487-91.
47. Wedin R, Hansen BH, Laitinen M, Trovik C, Zaikova O, Bergh P, Kalen A, Schwarz-Lausten G, Vult von SF, Walloe A, Keller J, Weiss RJ. Complications and survival after surgical treatment of 214 metastatic lesions of the humerus. *Journal of Shoulder and Elbow Surgery* 2012;21-8:1049-55.