



Universiteit
Leiden
The Netherlands

Deep neuromuscular blockade and neuromuscular reversal : applications and implications

Boon, M.

Citation

Boon, M. (2018, October 10). *Deep neuromuscular blockade and neuromuscular reversal : applications and implications*. Retrieved from <https://hdl.handle.net/1887/66119>

Version: Not Applicable (or Unknown)

License: [Licence agreement concerning inclusion of doctoral thesis in the Institutional Repository of the University of Leiden](#)

Downloaded from: <https://hdl.handle.net/1887/66119>

Note: To cite this publication please use the final published version (if applicable).

Cover Page



Universiteit Leiden



The handle <http://hdl.handle.net/1887/66119> holds various files of this Leiden University dissertation.

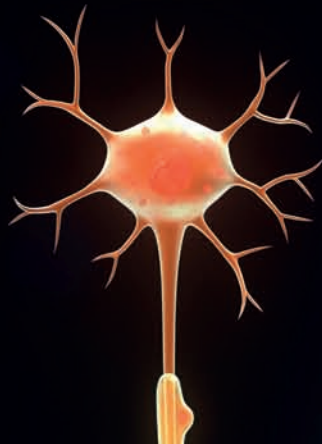
Author: Boon, M.

Title: Deep neuromuscular blockade and neuromuscular reversal: applications and implications

Issue Date: 2018-10-10

Section 4

Perspectives

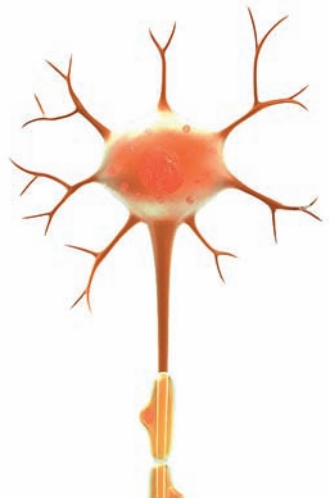

Chapter 7

Recent advances in neuromuscular blocking during anaesthesia

Martijn Boon, Christian Martini, Albert Dahan

F1000Research 2018, 7:167



ABSTRACT

Muscle relaxation is a routine part of anaesthesia and has important advantages. However, the lingering effects of muscle relaxants in the postoperative period have historically been associated with postoperative adverse events. Neuromuscular reversal, together with neuromuscular monitoring, is a recognized strategy to reduce the rate of postoperative residual relaxation but has only marginally improved outcome in the past decades.

Sugammadex, a novel reversal agent with unique encapsulating properties, has changed the landscape of neuromuscular reversal and opened new opportunities to improve patient care. By quickly and completely reversing any depth of neuromuscular block it may reduce the rate of residual relaxation and improve respiratory recovery. In addition, sugammadex has made the use of deep neuromuscular block possible during surgery. Deep neuromuscular block may improve surgical working conditions and allow for a reduction in insufflation pressures during selected laparoscopic procedures. Whether and how this may impact outcomes is not well established.

INTRODUCTION

Muscle relaxants or neuromuscular blocking agents (NMBAs), introduced in 1942 by Griffith and Johnson, revolutionized the practice of anaesthesiology.¹ NMBAs block neuromuscular transmission at the neuromuscular junction by binding to the postsynaptic nicotinic acetylcholine receptor. This renders these receptors unavailable for acetylcholine-mediated neuromuscular signal transmission (see Fig. 1). In practice, NMBAs enable anaesthetists to temporarily paralyze patients during anaesthesia. The introduction of NMBAs in anaesthesia meant that optimal surgical conditions (*i.e.* by ensuring an immobile patient) could be achieved with lower doses of volatile or intravenous anaesthetics, improving hemodynamic stability. Consequently, induction of muscle relaxation became an established part of the classic anaesthesia triad, alongside unconsciousness (hypnosis) and pain relief.² However, like most medication, NMBAs are not devoid of disadvantages. Lingering effects of NMBAs in the postoperative period, also known as *postoperative residual curarization* (PORC), may cause life-threatening respiratory complications in the first hours after surgery.³ In 1954, Beecher et al. were the first to note a six fold increase in anaesthesia-related mortality when NMBAs were used.⁴ Despite the development of short-acting agents and neuromuscular monitoring techniques, NMBAs continue to be associated with severe adverse events after anaesthesia, even today.^{5,6}

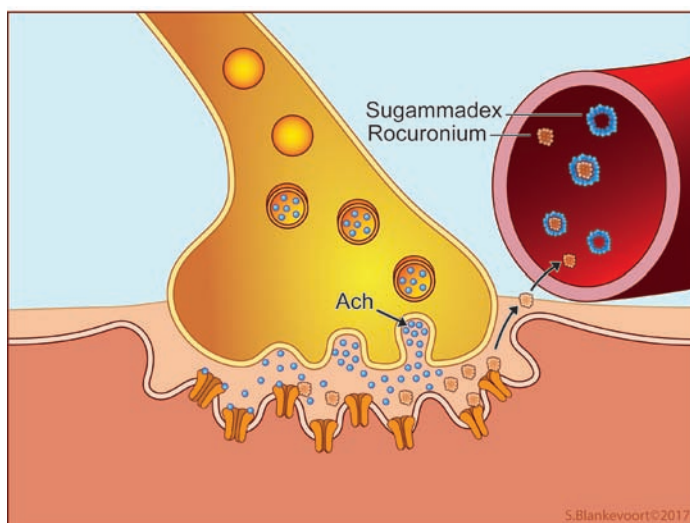


Figure 1. This figure shows the connection between the end of a motor neuron and a muscle fiber membrane (also called neuromuscular junction). Signal transmission occurs by the release of acetylcholine (Ach, blue dots) from the neuron. Ach is able to open an ion-channel on the post synaptic muscle membrane, causing post synaptic membrane depolarization. Rocuronium is able to block signal transmission by inhibiting Ach to bind to the post synaptic ion-channel. The effect of rocuronium can be terminated by sugammadex, which encapsulates rocuronium in the blood plasma.

Reversal of neuromuscular block

Currently two concepts of neuromuscular reversal exist. A moderate neuromuscular block (moderate NMB; see below) is traditionally reversed with an acetylcholinesterase inhibitor such as neostigmine. These drugs increase the amount of acetylcholine in the neuromuscular junction by inhibiting the enzyme acetylcholinesterase. The increased levels of acetylcholine compete with the NMBA molecules for the postsynaptic nicotine receptors (*i.e.* competitive antagonism) and tip the balance towards enhanced signal transmission. Encapsulation of NMBA molecules by sugammadex represents a novel reversal strategy. Sugammadex is a modified γ -cyclodextrin, which is able to selectively bind free plasma NMBA molecules (Fig. 1).⁷ Encapsulation by sugammadex immediately inactivates these NMBA molecules, rendering them permanently unavailable for redistribution to the neuromuscular junction.⁸ Sugammadex produces rapid and safe reversal of the commonly used non-depolarizing NMBAs rocuronium and vecuronium.^{9, 10} It encapsulates and consequently inactivates these NMBA molecules on a one-to-one basis and is able to reverse both moderate and deep or even intense levels of NMB.¹¹⁻¹³ Importantly, sugammadex reversal is much faster and more intense than reversal with acetylcholinesterase inhibitors.¹⁴ For example, the average time for reversal of a moderately deep neuromuscular block is 2.7 min after administration of sugammadex 2 mg kg⁻¹, compared to 17.9 min after administration of neostigmine 50 μ g.kg⁻¹.¹⁵ In addition, sugammadex is well tolerated by patients and is devoid of cholinergic side effects.^{14, 16} Sugammadex has been available in Europe since 2008 and has been approved by the FDA for use in the USA in 2015.

Although the introduction of sugammadex represents a great improvement in reversal of the neuromuscular block, there are some important aspects that deserve consideration. First, only NMB-induced by rocuronium, vecuronium and pancuronium can be reversed with sugammadex, leaving acetylcholinesterase inhibitors the only choice for reversal of the other NMBAs, such as cisatracurium. In the future, new broad spectrum encapsulating agents may become available for all NMBAs.¹⁷ Second, the cost of sugammadex is significant (in the Netherlands one ampoule of 200 mg costs 78 euro). It is unclear whether sugammadex reversal leads to an improved postoperative outcome that justifies its cost. The same holds true for another emerging area of interest made possible by sugammadex, which is the application of a deep neuromuscular block during anaesthesia. With the introduction of sugammadex the use of a deep NMB during surgery is now possible without having to fear for prolonged recovery times. Deep NMB may improve surgical working conditions for some procedures and allows for a reduction in insufflation pressures during laparoscopic surgeries.¹⁸⁻²¹ However, the impact of deep NMB on patient outcome is still unclear.

Monitoring depth of neuromuscular block

Neuromuscular monitoring during anaesthesia is most commonly performed using the *train-of-four* (TOF) method.²² Train-of-four peripheral nerve monitors (such as the TOF-Watch™ monitor) are usually applied at the distal fore arm to stimulate the ulnar nerve. Here, four consecutive supramaximal electrical stimuli (a *train-of-four*) will evoke contractions (*twitches*) at the m. adductor pollicis of the thumb. Under normal conditions, the amplitude of all 4 motor responses will be equal. With an increasing degree of NMB (induced by non-depolarizing NMBAs), the amplitude of the latter twitches decreases, relative to the first twitches; a phenomenon called *fade*. Eventually, as NMB increases, all twitches will become absent (see figure 2). Thus, the number of detectable thumb twitches and the degree of fading corresponds with the intensity of the NMB. The degree of fading can be further expressed as a ratio, by dividing the motor response of the fourth twitch (T4) to the first twitch (T1), *i.e.* the T4/T1 ratio or the so-called *TOF ratio*. Available evidence indicates that the NMB has to be recovered to a TOF ratio of 0.9 or greater to allow for safe extubation of the patient.²³⁻²⁷

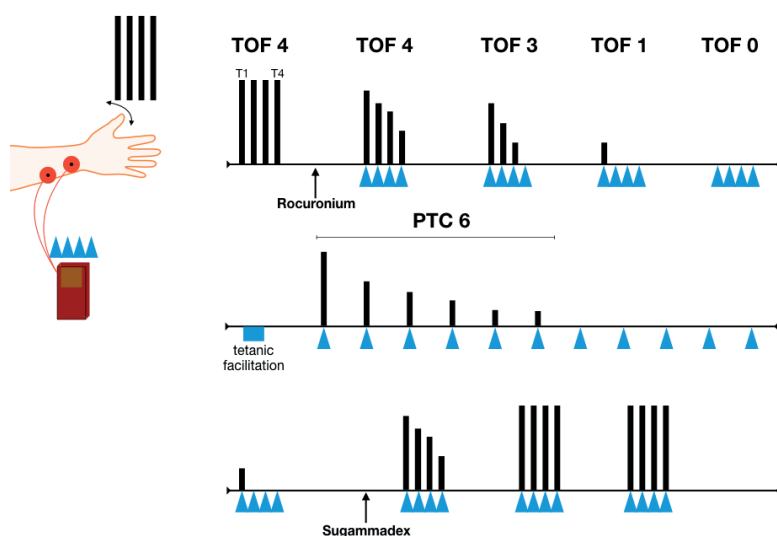


Figure 2. Neuromuscular monitoring. The figure shows, from top to bottom, the typical course neuromuscular block after a single administration of muscle relaxant (*i.e.* rocuronium). The above line shows the disappearance of train-of-four twitches after rocuronium administration. The middle part shows the decline in post-tetanic-count twitches as neuromuscular block deepens in the first minutes. The bottom line shows the return of train-of-four twitches after administration of the reversal agent sugammadex. TOF: train-of-four; PTC: post-tetanic-count. Blue arrows resemble electrical stimuli

When high doses of NMBAs are given, train-of-four measurement at the ulnar nerve will show zero thumb twitches (TOF = 0). To measure the degree of NMB in this instance, a tetanic stimulus of 50Hz for 5 seconds is applied to the ulnar nerve. The tetanic stimulus

causes a large amount of acetylcholine to be released in the neuromuscular junction. This *tetanic facilitation* is subsequently followed by 10 - 15 single electrical stimuli delivered at 1-s intervals. The number of measured thumb twitches make up the *post-tetanic-count* (PTC).²⁸ For example, when 6 thumb twitches are observed following the tetanic facilitation, the PTC equals 6 (see figure 2). With TOF and PTC measurements, the depth of the NMB can be classified as follows: (1) moderate NMB: TOF count 1-3 out of 4 twitches; (2) deep NMB: TOF count 0 twitches and PTC > 0 twitches; and (3) intense NMB: TOF count 0 twitches and PTC = 0 twitches.

Postoperative residual curarization

Full recovery of NMB at the end of anaesthesia is essential for the return of adequate respiration and upper airway muscle function.^{3,29,30} By definition, PORC is present when some level of NMB (TOF ratio < 0.9) persists after extubation. This can readily occur as most NMBAs have much longer recovery times than the often-short acting opioids and hypnotics used during general anaesthesia. Incidences of PORC range between 20 and 60% of patients in the post-anaesthesia care unit (PACU).³⁰⁻³² Residual curarization negatively affects pulmonary and upper airway muscle function. It promotes upper airway collapse and ventilatory compromise. This is relevant, as even a small degree of residual curarization (*e.g.* TOF ratio between 0.6-0.9) is associated with increased upper airway collapsibility and dysfunction of pharyngeal and upper oesophageal sphincter muscles.^{23,27} Additionally, NMBAs directly block the hypoxic ventilatory response due to blocking of nicotinic acetylcholine receptors at the carotid bodies.²⁴ Inhibition of the hypoxic ventilatory response renders patients at increased risk for hypoxia. Due to these effects, PORC is highly associated with postoperative respiratory complications.^{3,29} Use of a neuromuscular monitor and adequate reversal of NMB are essential strategies that will reduce the incidence of PORC.

Prevention of postoperative residual curarization

With the use of neostigmine and other acetylcholinesterase inhibitors, a variable degree of residual NMB often persists.³³ It is therefore not surprising that the effect of NMB-reversal with neostigmine on postoperative respiratory complications and outcome is at best ambiguous. Increasing evidence shows that NMB-reversal with neostigmine (without the guidance of a TOF watch) does not improve postoperative respiratory safety³⁴ and may even be associated with increased rates of atelectasis,³⁵ hypoxemia³⁶ and consequently reintubation³⁷. There are several explanations for these findings. Timely administration and exclusive reversal of a moderate NMB are important for successful reversal. Evidently, this requires adequate neuromuscular monitoring. In addition, time to full reversal following neostigmine treatment displays wide between-patient variations and is unpredictable. Sugammadex has the potential to do better in both respects,

as it allows for fast, complete and predictable reversal of both moderate and deep NMB.^{15, 16, 38, 39} Emerging evidence shows that NMB-reversal with sugammadex reduces the rate of postoperative residual curarization compared to reversal with neostigmine (see table 1).^{33, 36, 40} A recent investigation reported a 0% PORC rate in patients reversed with sugammadex, *versus* 46% in those who received neostigmine.⁴⁰ These results are promising, however, in an unmonitored setting PORC after sugammadex reversal still occurs in 4% of patients.^{33, 36, 41} This highlights the need for adequate neuromuscular monitoring in any setting where NMBAs are used, regardless the type of reversal agent.

Table 1. Studies comparing sugammadex and neostigmine on incidence of postoperative residual curarization and pulmonary outcome.

Author	Year	Design	Comparison	Monitoring	PORC	Pulmonary outcome
Kotake ⁴¹	2013	Prospective observational	Sugammadex vs. neostigmine	No	4.3% vs. 23.9%**	UA
Ledowski ⁴⁴	2014	Retrospective cohort	Sugammadex vs. neostigmine	Available	UA	Reduced pulmonary outcome score in ASA 3-4 patients**
Brueckmann ⁴⁰	2015	RCT	Sugammadex vs. neostigmine	Available	0% vs. 43.3%**	Respiratory disorders 1.4% vs. 6.5% # hypoxemia 1.4% vs. 2.6%#
Boon ³⁶	2016	RCT	Sugammadex vs. neostigmine	No	4% vs. 70%**	Lowest O ₂ saturation 93.3 vs. 96.8%**
Nemes ³³	2017	RCT	Sugammadex vs. neostigmine	No	3.7% vs. 15.4%#	UA

RCT: randomized controlled trial; UA: unavailable; PORC: postoperative residual curarization (TOF ratio <0.9 after extubation). *p<0.05, **p<0.001, #p>0.05

We argue that NMB reversal with sugammadex will decrease the incidence of postoperative pulmonary complications by causing complete recovery of ventilatory muscle strength. This was shown in two studies in healthy volunteers. Sugammadex-reversal led to a higher degree of diaphragmatic and intercostal muscle activation and higher arterial pO₂ values compared to neostigmine reversal.^{42, 43} In addition, it is likely that sugammadex will allow for a better return of the hypoxic ventilatory drive, which is attenuated at very low levels of residual neuromuscular block.²⁴ Especially in vulnerable patients such as the obese and elderly, full recovery of the ventilatory muscles and hypoxic ventilatory reflex are crucial to prevent pulmonary complications. Initial evidence from a retrospective study shows that sugammadex reversal was associated with reduced incidence of

pulmonary complications in elderly ASA 3 and 4 patients compared to reversal with neostigmine.⁴⁴ In a small prospective study, sugammadex-reversal was associated with less hypoxemic events in the PACU compared to neostigmine-reversal.³⁶ The current evidence is far from complete and future prospective studies should determine the exact value of sugammadex in improving post anaesthesia pulmonary outcome.

Deep neuromuscular block: prevention of diaphragmatic contractions and optimized surgical conditions

Most important advantages of a deep NMB over a moderate block are the loss of (sudden) diaphragmatic contractions and significant improvement in surgical conditions especially of procedures confined to a narrow space, such as laparoscopic surgery. Various studies show that the diaphragm has a high resistance to NMBAs in comparison to other muscles.⁴⁵⁻⁴⁷ For example, Fernando and colleagues showed that an intense NMB is required to silence the diaphragm in response to stimulation of the carina.⁴⁵ Similarly, Werba and colleagues showed that diaphragmatic responses evoked by tracheal suctioning lead to coughing, bucking and elevated intracranial pressures in neurosurgical patients, unless deep NMB was applied.⁴⁶ In addition, during laparoscopic surgery, efferent activation of the diaphragm from brainstem chemo-sensitive respiratory centres may occur as a result of elevated arterial pCO₂ levels (due to CO₂ insufflation). Only with deep NMB are these diaphragmatic contractions effectively prevented.

Martini et al. assessed the effect of deep *versus* moderate NMB on surgical conditions during laparoscopic retroperitoneal urologic surgery.¹⁹ They developed the validated 5-point Leiden - surgical rating scale (L-SRS, 0-5; extremely poor to optimal working conditions) to objectively qualify the quality of the surgical field as experienced by the surgeon at various points during the procedure.^{19,20,48} The study showed an improvement of 0.7 L-SRS points (mean L-SRS 4.0 vs. 4.7) when deep NMB was applied, an improvement deemed clinically significant by the surgical team.¹⁹ In many other procedures, a similar effect of deep NMB was found,^{18,20,21,49-51} but it is important to acknowledge that some studies found no effect of deep NMB on surgical conditions (see table 2).⁵² A recent meta-analysis confirmed the positive effect of a deep NMB on surgical conditions and reduced postoperative pain scores, however significant heterogeneity between the included studies reduces the overall quality of evidence.⁵³ It is important to realize that other factors such as deep anaesthesia may positively affect surgical working conditions. However, deep anaesthesia, although applicable, is associated with less hemodynamic stability and prolonged recovery times.

Adversaries of deep NMB claim that the gains in surgical conditions with deep NMB are modest at best and are not worth the extra effort and cost of the reversal agents (su-

Table 2. Studies assessing deep NMB on surgical conditions during open and laparoscopic surgery (normal pressure pneumoperitoneum).

Author	Specialty	Control	Intervention	Scale	Mean score	% Unacceptable surgical conditions
Martini ¹⁹	Urology (laparoscopy)	Moderate NMB	Deep NMB	L-SRS	4.0 vs 4.7**	18% vs 1%
Yoo ²¹	Urology (laparoscopy)	Moderate NMB	Deep NMB	L-SRS	3.0 vs 4.0**	UA
Boon ⁴⁹	Urology (laparoscopy)	Deep NMB + hypercapnia	Deep NMB + hypocapnia	L-SRS	4.84 vs 4.77#	1 vs 1%
Torensma ²⁰	Bariatric surgery (laparoscopy)	Moderate NMB	Deep NMB	L-SRS	4.2 vs 4.8**	UA
Baete ⁶⁰	Bariatric surgery (laparoscopy)	Moderate NMB	Deep NMB	L-SRS	4.1 vs 3.9#	UA
Madsen ⁵⁹	Gynaecology (laparoscopy)	No NMB	Deep NMB	1 (optimal) - 4 (unacceptable)	1.7 vs. 1.0*	UA
Blobner ¹⁸	General surgery (laparoscopy)	No NMB	Deep NMB	0 (not acceptable) - 100 (excellent)	UA	0 vs 28%*
Rosenberg ⁵¹	General surgery (laparoscopy)	Moderate NMB	Deep NMB	0 (poor) - 10 (excellent)	6.8 vs. 7.9*	UA
Madsen ⁵⁰	General surgery (laparotomy)	Moderate NMB	Deep NMB	L-SRS	4.0 vs. 4.75**	17 vs. 49%**

NMB: neuromuscular block; UA: unavailable; L-SRS: Leiden- surgical rating scale: 1 (extremely poor) – 5 (optimal)¹⁹. *p<0.05, **p<0.001, #p>0.05

gammadex).^{54,55} We argue that the observed differences in L-SRS are clinically relevant, the incidence of suboptimal conditions is greatly reduced during deep NMB (especially the occurrence of sudden diaphragmatic contractions)^{18-20,49}, and most important, deep NMB is associated with less postoperative pain and a reduced incidence of unplanned 30-day readmission.^{20,56}

Finally, there are indications that a deep NMB allows for lower intra-abdominal pressure during laparoscopic surgery. Reduced insufflation pressure is associated with less postoperative pain.⁵⁷ Deep NMB might cause an increase in abdominal wall compliance and consequently an increase in intra-abdominal space.^{58,59} However, while various studies indeed show that deep NMB allows titration to lower intra-abdominal pressures with still acceptable surgical conditions, the gain in intra-abdominal space may be marginal⁵⁹, and the incidence of unacceptable surgical conditions remained substantial higher than under standard pressures. The feasibility of low-pressure pneumoperitoneum hence needs further investigation.

CONCLUSIONS

Neuromuscular blocking agents have important advantages but also serious disadvantages. Postoperative residual curarization is an important threat, especially in patients that are not adequately reversed or monitored. An important new development is the introduction of the reversal agent sugammadex. Sugammadex may help reduce the incidence of postoperative residual curarization and improve postoperative respiratory recovery. In addition, sugammadex enables the use of a deep NMB during general anaesthesia. While the deep NMB has been shown to improve surgical conditions and reduce postoperative pain in a variety of procedures, its place in anaesthesia is not yet fully determined.

REFERENCES

- 1 Griffith HR JG. The use of curare in general anesthesia. *Anesthesiology* 1942; 3: 418-20
- 2 Gray TC, Rees GJ. The role of apnoea in anaesthesia for major surgery. *Br Med J* 1952; 2: 891-2
- 3 Berg H, Roed J, Viby-Mogensen J, et al. Residual neuromuscular block is a risk factor for postoperative pulmonary complications. A prospective, randomised, and blinded study of postoperative pulmonary complications after atracurium, vecuronium and pancuronium. *Acta Anaesthesiologica Scandinavica* 1997; 41: 1095-103
- 4 Beecher HK, Todd DP. A study of the deaths associated with anesthesia and surgery: based on a study of 599, 548 anesthetics in ten institutions 1948-1952, inclusive. *Annals of surgery* 1954; 140: 2-35
- 5 Grosse-Sundrup M, Henneman JP, Sandberg WS, et al. Intermediate acting non-depolarizing neuromuscular blocking agents and risk of postoperative respiratory complications: prospective propensity score matched cohort study. *BMJ (Clinical research ed)* 2012; 345: e6329
- 6 Harrison GG. Death attributable to anaesthesia. A 10-year survey (1967--1976). *Br J Anaesth* 1978; 50: 1041-6
- 7 Bom A, Bradley M, Cameron K, et al. A novel concept of reversing neuromuscular block: chemical encapsulation of rocuronium bromide by a cyclodextrin-based synthetic host. *Angew Chem Int Ed Engl* 2002; 41: 266-70
- 8 Welliver M, McDonough J, Kalynych N, Redfern R. Discovery, development, and clinical application of sugammadex sodium, a selective relaxant binding agent. *Drug Des Devel Ther* 2009; 2: 49-59
- 9 Sorgenfrei IF, Norrild K, Larsen PB, et al. Reversal of rocuronium-induced neuromuscular block by the selective relaxant binding agent sugammadex: a dose-finding and safety study. *Anesthesiology* 2006; 104: 667-74
- 10 Suy K, Morias K, Cammu G, et al. Effective reversal of moderate rocuronium- or vecuronium-induced neuromuscular block with sugammadex, a selective relaxant binding agent. *Anesthesiology* 2007; 106: 283-8
- 11 Puhlinger FK, Rex C, Sielenkamper AW, et al. Reversal of profound, high-dose rocuronium-induced neuromuscular blockade by sugammadex at two different time points: an international, multicenter, randomized, dose-finding, safety assessor-blinded, phase II trial. *Anesthesiology* 2008; 109: 188-97
- 12 Rex C, Wagner S, Spies C, et al. Reversal of neuromuscular blockade by sugammadex after continuous infusion of rocuronium in patients randomized to sevoflurane or propofol maintenance anesthesia. *Anesthesiology* 2009; 111: 30-5
- 13 de Boer HD, Driessen JJ, Marcus MA, Kerckamp H, Heeringa M, Klimek M. Reversal of rocuronium-induced (1.2 mg/kg) profound neuromuscular block by sugammadex: a multicenter, dose-finding and safety study. *Anesthesiology* 2007; 107: 239-44
- 14 Sacan O, White PF, Tufanogullari B, Klein K. Sugammadex reversal of rocuronium-induced neuromuscular blockade: a comparison with neostigmine-glycopyrrolate and edrophonium-atropine. *Anesth Analg* 2007; 104: 569-74
- 15 Khuenl-Brady KS, Wattwil M, Vanacker BF, Lora-Tamayo JI, Rietbergen H, Alvarez-Gomez JA. Sugammadex provides faster reversal of vecuronium-induced neuromuscular blockade compared with neostigmine: a multicenter, randomized, controlled trial. *Anesth Analg* 2010; 110: 64-73

- 16 Duvaldestin P, Kuizenga K, Saldien V, et al. A randomized, dose-response study of sugammadex given for the reversal of deep rocuronium- or vecuronium-induced neuromuscular blockade under sevoflurane anesthesia. *Anesth Analg* 2010; 110: 74-82
- 17 Haerter F, Simons JC, Foerster U, et al. Comparative Effectiveness of Calabation and Sugammadex to Reverse Non-depolarizing Neuromuscular-blocking Agents. *Anesthesiology* 2015; 123: 1337-49
- 18 Blobner M, Frick CG, Stauble RB, et al. Neuromuscular blockade improves surgical conditions (NISCO). *Surgical endoscopy* 2014
- 19 Martini CH, Boon M, Bevers RF, Aarts LP, Dahan A. Evaluation of surgical conditions during laparoscopic surgery in patients with moderate vs deep neuromuscular block. *Br J Anaesth* 2014; 112: 498-505
- 20 Torensma B, Martini CH, Boon M, et al. Deep Neuromuscular Block Improves Surgical Conditions during Bariatric Surgery and Reduces Postoperative Pain: A Randomized Double Blind Controlled Trial. *PLoS ONE* 2016; 11: e0167907
- 21 Yoo YC, Kim NY, Shin S, et al. The Intraocular Pressure under Deep versus Moderate Neuromuscular Blockade during Low-Pressure Robot Assisted Laparoscopic Radical Prostatectomy in a Randomized Trial. *PLoS ONE* 2015; 10: e0135412
- 22 Ali HH, Utting JE, Nightingale DA, Gray TC. Quantitative assessment of residual curarization in humans. *Br J Anaesth* 1970; 42: 802-3
- 23 Eriksson LI, Sundman E, Olsson R, et al. Functional assessment of the pharynx at rest and during swallowing in partially paralyzed humans: simultaneous videomanometry and mechanomyography of awake human volunteers. *Anesthesiology* 1997; 87: 1035-43
- 24 Eriksson LI, Lennmarken C, Wyon N, Johnson A. Attenuated ventilatory response to hypoxaemia at vecuronium-induced partial neuromuscular block. *Acta Anaesthesiologica Scandinavica* 1992; 36: 710-5
- 25 Eikermann M, Groeben H, Husing J, Peters J. Accelerometry of adductor pollicis muscle predicts recovery of respiratory function from neuromuscular blockade. *Anesthesiology* 2003; 98: 1333-7
- 26 Eikermann M, Blobner M, Groeben H, et al. Postoperative upper airway obstruction after recovery of the train of four ratio of the adductor pollicis muscle from neuromuscular blockade. *Anesth Analg* 2006; 102: 937-42
- 27 Sundman E, Witt H, Olsson R, Ekberg O, Kuylenstierna R, Eriksson LI. The incidence and mechanisms of pharyngeal and upper esophageal dysfunction in partially paralyzed humans: pharyngeal videoradiography and simultaneous manometry after atracurium. *Anesthesiology* 2000; 92: 977-84
- 28 Viby-Mogensen J, Howardy-Hansen P, Chraemmer-Jorgensen B, Ording H, Engbaek J, Nielsen A. Posttetanic count (PTC): a new method of evaluating an intense nondepolarizing neuromuscular blockade. *Anesthesiology* 1981; 55: 458-61
- 29 Murphy GS, Szokol JW, Marymont JH, Greenberg SB, Avram MJ, Vender JS. Residual neuromuscular blockade and critical respiratory events in the postanesthesia care unit. *Anesth Analg* 2008; 107: 130-7
- 30 Murphy GS, Szokol JW, Avram MJ, et al. Residual Neuromuscular Block in the Elderly: Incidence and Clinical Implications. *Anesthesiology* 2015; 123: 1322-36
- 31 Fortier LP, McKeen D, Turner K, et al. The RECITE Study: A Canadian Prospective, Multicenter Study of the Incidence and Severity of Residual Neuromuscular Blockade. *Anesth Analg* 2015; 121: 366-72

- 32 Murphy GS, Brull SJ. Residual neuromuscular block: lessons unlearned. Part I: definitions, incidence, and adverse physiologic effects of residual neuromuscular block. *Anesth Analg* 2010; 111: 120-8
- 33 Nemes R, Fulesdi B, Pongracz A, et al. Impact of reversal strategies on the incidence of postoperative residual paralysis after rocuronium relaxation without neuromuscular monitoring: A partially randomised placebo controlled trial. *Eur J Anaesthesiol* 2017; 34: 609-16
- 34 Meyer MJ, Bateman BT, Kurth T, Eikermann M. Neostigmine reversal doesn't improve postoperative respiratory safety. *BMJ (Clinical research ed)* 2013; 346: f1460
- 35 Herbstreit F, Zigrann D, Ochterbeck C, Peters J, Eikermann M. Neostigmine/glycopyrrolate administered after recovery from neuromuscular block increases upper airway collapsibility by decreasing genioglossus muscle activity in response to negative pharyngeal pressure. *Anesthesiology* 2010; 113: 1280-8
- 36 Boon M, Martini C, Broens S, et al. Improved postoperative oxygenation after antagonism of moderate neuromuscular block with sugammadex versus neostigmine after extubation in 'blinded' conditions. *Br J Anaesth* 2016; 117: 410-1
- 37 Sasaki N, Meyer MJ, Malviya SA, et al. Effects of neostigmine reversal of nondepolarizing neuromuscular blocking agents on postoperative respiratory outcomes: a prospective study. *Anesthesiology* 2014; 121: 959-68
- 38 Lee C, Jahr JS, Candiotti KA, Warriner B, Zornow MH, Naguib M. Reversal of profound neuromuscular block by sugammadex administered three minutes after rocuronium: a comparison with spontaneous recovery from succinylcholine. *Anesthesiology* 2009; 110: 1020-5
- 39 Blobner M, Eriksson LI, Scholz J, Motsch J, Della Rocca G, Prins ME. Reversal of rocuronium-induced neuromuscular blockade with sugammadex compared with neostigmine during sevoflurane anaesthesia: results of a randomised, controlled trial. *Eur J Anaesthesiol* 2010; 27: 874-81
- 40 Brueckmann B, Sasaki N, Grobara P, et al. Effects of sugammadex on incidence of postoperative residual neuromuscular blockade: a randomized, controlled study. *Br J Anaesth* 2015; 115: 743-51
- 41 Kotake Y, Ochiai R, Suzuki T, et al. Reversal with sugammadex in the absence of monitoring did not preclude residual neuromuscular block. *Anesth Analg* 2013; 117: 345-51
- 42 Schepens T, Cammu G, Saldien V, et al. Electromyographic activity of the diaphragm during neostigmine or sugammadex-enhanced recovery after neuromuscular blockade with rocuronium: a randomised controlled study in healthy volunteers. *Eur J Anaesthesiol* 2015; 32: 49-57
- 43 Cammu G, Schepens T, De Neve N, Wildemeersch D, Foubert L, Jorens PG. Diaphragmatic and intercostal electromyographic activity during neostigmine, sugammadex and neostigmine-sugammadex-enhanced recovery after neuromuscular blockade: A randomised controlled volunteer study. *Eur J Anaesthesiol* 2017; 34: 8-15
- 44 Ledowski T, Falke L, Johnston F, et al. Retrospective investigation of postoperative outcome after reversal of residual neuromuscular blockade: sugammadex, neostigmine or no reversal. *Eur J Anaesthesiol* 2014; 31: 423-9
- 45 Fernando PU, Viby-Mogensen J, Bonsu AK, Tamilarasan A, Muchhal KK, Lambourne A. Relationship between posttetanic count and response to carinal stimulation during vecuronium-induced neuromuscular blockade. *Acta Anaesthesiologica Scandinavica* 1987; 31: 593-6
- 46 Werba A, Klezl M, Schramm W, et al. The level of neuromuscular block needed to suppress diaphragmatic movement during tracheal suction in patients with raised intracranial pressure: a study with vecuronium and atracurium. *Anaesthesia* 1993; 48: 301-3
- 47 Donati F, Antzaka C, Bevan DR. Potency of pancuronium at the diaphragm and the adductor pollicis muscle in humans. *Anesthesiology* 1986; 65: 1-5

- 48 Nervil GG, Medici R, Thomsen JLD, et al. Validation of subjective rating scales for assessment of surgical workspace during laparoscopy. *Acta Anaesthesiologica Scandinavica* 2017; 61: 1270-7
- 49 Boon M, Martini C, Hellinga M, Bevers R, Aarts L, Dahan A. Influence of variations in arterial PCO₂ on surgical conditions during laparoscopic retroperitoneal surgery. *Br J Anaesth* 2016; 117: 59-65
- 50 Madsen MV, Scheppan S, Mork E, Kissmeyer P, Rosenberg J, Gatke MR. Influence of deep neuromuscular block on the surgeons assessment of surgical conditions during laparotomy: a randomized controlled double blinded trial with rocuronium and sugammadex. *Br J Anaesth* 2017; 119: 435-42
- 51 Rosenberg J, Herring WJ, Blobner M, et al. Deep Neuromuscular Blockade Improves Laparoscopic Surgical Conditions: A Randomized, Controlled Study. *Adv Ther* 2017; 34: 925-36
- 52 Baete S, Vercruyse G, Vander Laenen M, et al. The Effect of Deep Versus Moderate Neuromuscular Block on Surgical Conditions and Postoperative Respiratory Function in Bariatric Laparoscopic Surgery: A Randomized, Double Blind Clinical Trial. *Anesth Analg* 2017; 124: 1469-75
- 53 Bruintjes MH, Van Helden E, Braat AE, et al. Deep neuromuscular blockade to optimize surgical space conditions during laparoscopic surgery: a systematic review and meta-analysis. *Br J Anaesth* 2017; 118: 834-42
- 54 Kopman AF, Naguib M. Laparoscopic surgery and muscle relaxants: is deep block helpful? *Anesth Analg* 2015; 120: 51-8
- 55 Kopman AF, Naguib M. Is deep neuromuscular block beneficial in laparoscopic surgery? No, probably not. *Acta Anaesthesiologica Scandinavica* 2016; 60: 717-22
- 56 Martini C, Boon M, Yang K, Shuvaya S, Dahan A. A Retrospective Study on the Effect of Deep Neuromuscular Block on Healthcare Resource Utilization. Abstract A1025. Annual meeting of the American Society of Anesthesiology, 2017
- 57 Sarli L, Costi R, Sansebastiano G, Trivelli M, Roncoroni L. Prospective randomized trial of low-pressure pneumoperitoneum for reduction of shoulder-tip pain following laparoscopy. *Br J Surg* 2000; 87: 1161-5
- 58 Barrio J, Errando CL, San Miguel G, et al. Effect of depth of neuromuscular blockade on the abdominal space during pneumoperitoneum establishment in laparoscopic surgery. *Journal of Clinical Anesthesia* 2016; 34: 197-203
- 59 Madsen MV, Gatke MR, Springborg HH, Rosenberg J, Lund J, Istre O. Optimising abdominal space with deep neuromuscular blockade in gynaecologic laparoscopy—a randomised, blinded cross-over study. *Acta Anaesthesiologica Scandinavica* 2015; 59: 441-7
- 60 Baete S, Vercruyse G, Vander Laenen M, et al. The Effect of Deep Versus Moderate Neuromuscular Block on Surgical Conditions and Postoperative Respiratory Function in Bariatric Laparoscopic Surgery: A Randomized, Double Blind Clinical Trial. *Anesth Analg* 2017; 124: 1469-75