



Universiteit  
Leiden  
The Netherlands

## **Childhood sexual abuse and its effect on adolescent brain structure**

Rinne-Albers, M.A.W.

### **Citation**

Rinne-Albers, M. A. W. (2020, October 14). *Childhood sexual abuse and its effect on adolescent brain structure*. Retrieved from <https://hdl.handle.net/1887/137820>

Version: Publisher's Version

License: [Licence agreement concerning inclusion of doctoral thesis in the Institutional Repository of the University of Leiden](#)

Downloaded from: <https://hdl.handle.net/1887/137820>

**Note:** To cite this publication please use the final published version (if applicable).

Cover Page



Universiteit Leiden



The handle <http://hdl.handle.net/1887/137820> holds various files of this Leiden University dissertation.

**Author:** Rinne-Albers, M.A.W.

**Title:** Childhood sexual abuse and its effect on adolescent brain structure

**Issue Date:** 2020-10-14

## Chapter 2 REVIEW

### Neuroimaging in children, adolescents and young adults with psychological trauma

Mirjam A.W. Rinne-Albers, Nic J.A. van der Wee, Francien Lamers-Winkelman, Robert R.J.M. Vermeiren

*European Child and Adolescent Psychiatry*, 2013, 22: 745-755

## *Abstract*

Childhood psychological trauma is a strong predictor of psychopathology. Preclinical research points to the influence of this type of trauma on brain development. However, the effects of psychological trauma on the developing human brain are less known and a challenging question is whether the effects can be reversed or even prevented. The aim of this review is to give an overview of neuroimaging studies in traumatized juveniles and young adults up till 2012. Neuroimaging studies in children and adolescents with traumatic experiences were found to be scarce. Most studies were performed by a small number of research groups in the United States and examined structural abnormalities. The reduction of hippocampal volume reported in adults with PTSD could not be confirmed in juveniles. The most consistent finding in children and adolescents who experienced psychological trauma are structural abnormalities of the corpus callosum. We could not identify any studies investigating treatment effects. Neuroimaging studies in traumatized children and adolescents clearly lag behind studies in traumatized adults as well as studies on ADHD and autism.

## *1. Introduction*

In countries all over the world, varying from low to high-income, similar proportions of respondents, as many as one in three, reported adversities in childhood, including psychological trauma (1). This poses an important problem for mental health, as childhood adversity is known to be a strong predictor for both child and adult affective psychopathology such as anxiety disorders, posttraumatic stress disorders and depression (1;2).

The maturation of the human brain is a complex process which lasts into early adulthood and can be strongly influenced by experiences (3);(4). Differentiation of brain structures during development takes place through the formation of new neurons, dendrites and synapses, the selective 'pruning' of neurons, dendrites and synapses, and the myelination of neurons. These processes are influenced by neuronal hormones like the stress hormones cortisol and catecholamines (5).

Preclinical science has shown that structure and functioning of the developing brain are highly vulnerable to the effects of adversity, particularly in certain critical time windows. An extensive body of animal research in rodents, as well as in non-human primates, has demonstrated that childhood adversity - like prolonged maternal separation or maternal stress - has profound immediate and long lasting (into adulthood) effects on functioning of the HPA axis (3;6). In general, HPA axis effects are more profound after earlier and repeated exposure to adversity. The sequelae of exposure to adversity are not limited to disturbances in HPA axis functioning, but typically also involve increases in anxiety related behaviour and impairment in cognitive functioning (7);(8). In animal studies, childhood adversity was found to be associated with changes in brain structures involved in stress and emotion regulation, such as the hippocampus and certain prefrontal regions (9;10), probably underlying vulnerability to the impact of stressors later in life. In humans too, a history of chronic traumatization during childhood and adolescence was found to be associated with structural and functional damage in emotion and stress regulating brain structures, for example in the hippocampus in adults reporting childhood abuse or in the medial prefrontal cortex in adults reporting childhood emotional maltreatment (11);(12). Interestingly, in animal studies compensatory fostering partially reversed several changes in the brain, while treatment with an SSRI was shown to have a similar effect in both animals and adult human studies (13). Also, cognitive behavioural treatment was found to normalize brain activity patterns in adults with post-traumatic stress disorder (14);(15). Taken together, data from studies in animals and adult humans show that childhood adversity can have a long lasting impact on brain structure and functioning, but animal data also suggest that interventions may reduce these effects not only in the mature, but also in the

developing brain. From a clinician's perspective these are intriguing findings and possibilities, raising interest in the current knowledge on the structural and functional effects of childhood adversity at the level of the developing brain, and more importantly, their malleability by treatment. This type of data could help identifying targets and time-windows for early intervention, treatment or perhaps prevention by enhancing resilience mechanisms in humans (11;16). We therefore performed a review of recent structural and functional neuroimaging studies in children and adolescents with a history of trauma or maltreatment.

## 2. Methods

The databases PubMed and Web of Science were searched on the keywords: *neuroimaging, MRI, fMRI* and crossed one by one with the terms *PTSD, trauma, psychotrauma, abuse* and again crossed with *children, adolescents, youth, young adults*. We also checked the references from the resulting articles to identify manuscripts not identified in the PubMed and Web of Science searches. Furthermore, we screened relevant review and meta-analysis articles for additional studies.

## 3. Results

### Literature search

Of the 27 articles we found, 26 were studies including a control group, published between 1999 and 2012. All studies, except for two, were conducted in the USA. The number of subjects varied between five and 61. Thirteen articles reported on findings in PTSD patients, the other articles on findings in persons with PTSD-symptoms (N=2) or various forms of psychological trauma: sexual abuse (N=2), interpersonal trauma (N=1), physical abuse/maltreatment (N=2, one with / without PTSD) (17), harsh corporal punishment (N=1), early deprivation (N=2), abuse (physical or sexual) or neglect (N=1) and parent verbal abuse (N=2). Age of participants ranged from 4 to 25 years. Two studies included only females, the other 25 mentioned a male/female ratio.

Most studies (N=24) were structural MRI studies, of which four were Diffusion Tensor Imaging studies (DTI); only three studies used functional MRI. There were three longitudinal studies, all of them structural. Nineteen studies were performed on a 1.5 Tesla scanner, the other eight on a 3 T scanner.

In nine articles Michael D. De Bellis was one of the authors, six articles were from Victor G. Carrion and his group at Stanford and seven came from the Harvard group of Martin H. Teicher. The De Bellis group published three studies on the volumes of different brain regions (total brain, lateral ventricle, hippocampus, pituitary) but all examined in the same group of 61 children and adolescents. (18-20)

**Table 1. Reviewed studies**

	Study	N	M/F	inclusion	contr	age	proc	task	long	med	Tesla
1	De Bellis MD, Pittsburgh, 1999	44	25/19	PTSD	+	6-17	struct		-	-	1.5
2	Carrion VG, Stanford, 2001	24	14/10	PTSD	+	7-14	struct		-	?	1.5
3	De Bellis MD, Pittsburgh, 2001	9	5/4	PTSD	+	10-13	struct		+	-	1.5
4	De Bellis MD, Pittsburgh, 2002	43	25/18	PTSD	+	6-17	struct		-	-	1.5
5	De Bellis MD, Pittsburgh, 2002	28	14/14	PTSD	+	4-16	struct		-	-	1.5
6	De Belis MD, Pittsburgh, 2003	61	31/30	Chron PTSD	+	4-17	struct		-	-	1.5
7	Yang P, Taiwan, 2004	5	1/4	Earthquake PTSD	+	12-14	funct	Visual / imaginary recollection of trauma	-	-	1.5
8	Thomas LA, Pittsburgh, 2004	61	31/30	Chronic PTSD	+	4-17	struct		-	-	1.5
9	Teicher MA, Harvard, 2004	28	13/15	Abuse / neglect	+	9-16	struct		-	?	1.5
10	Richert KA, Stanford, 2005	23	13/10	Trauma + PTSD-symptoms	+	7-14	struct		-	-	1.5
11	Tupler LA, Pittsburgh, 2006	61	31/30	Chron PTSD	+	4-17	struct		-	-	1.5
12	Eluvathingal TJ, Detroit, 2006	7	2/5	Early deprivation	+	7-13	struct (DTI)		-	-	1.5
13	De Bellis MD, Pittsburgh, 2006	58	30/28	PTSD	+	10--13	struct		-	-	1.5

14	Carrion VG, Stanford, 2007	15	6/9	Maltreatment	-	7-13	struct		+	-	1.5
15	Carrion VG, Stanford, 2008	24	14/10	PTSD	+	7-14	struct		-	-	1.5
16	Carrion VG, Stanford, 2008	16	7/9	PTSD	+	10-16	func	Response inhibition	-	-	3
17	Jackowski AP, Yale, 2008	17	7/10	PTSD	+	6-14	struct (DTI)		-	-	1.5
18	Andersen SL, Harvard, 2008	26	0/26	Childh Sex Abuse	+	18-22	struct		-	-	1.5
19	Mehta MA, London, 2009	14	6/8	Early deprivation	+	16.2 +/- 0.72	struct		+	-	1.5
20	Choi J, Harvard, 2009	16	4/12	Parent Verb Abuse	+	21.9 +/- 2.4	struct (DTI)		-	-	3
21	Tomoda A, Harvard, 2009	23	0/23	Childh Sex Abuse	+	18-22	struct		-	-	1.5
22	Tomoda A, Harvard, 2009	23	15/8	Harsh Corp Punishment	+	18-25	struct		-	-	3
23	Carrion VG, Stanford, 2010	16	6/10	PTSD sympt	+	10-17	func	Verbal declarative memory	-	No auton/HPA effect	3
24	Hanson, JL, Wisconsin, 2010	31	19/12	Physical abuse	+	12,0 +/- 0,2	struct		-	?	3
25	De Bellis MD, North Carolina, 2010	49/49	38/60	Maltreatment +/- PTSD	+	3-17	struct		-	?	3
26	Tomoda A, Harvard, 2011	21	9/12	Parent Verb Abuse	+	18-25	struct		-	-	3
27	Choi J, Harvard, 2011	20	4/16	Witnessing Domestic Violence	+	22,4 +/- 2,5	struct (DTI)		-	?	3

M/F= male / female ratio

Contr= controlled study

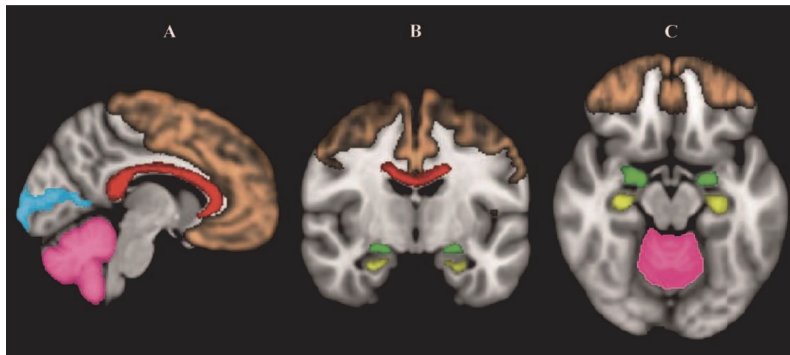
Proc= structural MRI / (DTI) / functional MRI

Task= functional MRI paradigm

Long= longitudinal study

Med= medication use during study

Tesla= 1.5 / 3 Tesla scanner



*Figure 1.* Summary of brain regions showing abnormalities in traumatized individuals superimposed on the MNI-152 standard brain (grey). **(A)** Sagittal section, **(B)** Coronal section, **(C)** Transversal section of the brain in which the frontal cortex (brown), corpus callosum (red), cerebellum (pink), visual cortex (blue), amygdala (green), hippocampus (yellow). In all depicted brain regions structural abnormalities were found. The few functional imaging studies found abnormalities in the cerebellum and the prefrontal, hippocampal and visual cortices. For details see table 2.

## Structural Neuroimaging

Structural MRI studies in traumatized children and adolescents have found abnormalities in a number of brain regions, with the hippocampus, corpus callosum, prefrontal cortex, total brain, sensory cortex, and cerebellum being the most frequently reported.

### Hippocampus

The hippocampus is an important part of the limbic system and plays a critical role in declarative memory, working memory, memory for episodic events and stress regulation. (21) The disturbances of verbal declarative memory in PTSD patients are related to the consistent finding of reduction in eleven of the 27 studies identified in the present review reported on the hippocampus, of which one DTI study and one functional MRI study (see table 2). In children most studies (N=6) found no change in hippocampal volume after exposure to psychological trauma. (17;23;24;24-27;27;27) These studies included prepubertal children as well as postpubertal adolescents. One larger matched controlled study (N=61) in children and adolescents with PTSD, aged 4-17 years, found even an increase in specific white matter volume. Here, hippocampal volume was positively related to age of trauma onset and level of psychopathology (20). The remaining two volumetric structural studies report a decrease in volume. In a study in young female adults (N=26), Andersen et al. found decreased hippocampal volume to be associated with sexual abuse at ages 3-5 years and 11-13 years. (28).

Choi, in a DTI study, found reduced fractional anisotropy (FA) in the cingulum bundle by the posterior tail of the left hippocampus in young adults (N=14) exposed to parental verbal abuse (29).

In a longitudinal study (N=15) in 7-13 year olds with a history of maltreatment, posttraumatic stress symptoms and cortisol at baseline predicted hippocampal volume reduction over a 12-18 month interval (30). The volumetric results seem to confirm the hypothesis that stress-induced prolonged exposure to glucocorticoids leads to cell death and a reduction in hippocampal volume over time. Experimental research in animals shows a link between early-life stress and later hippocampal anatomical abnormalities (3). However, De Bellis et al. did not find smaller



hippocampal volume in a longitudinal study with a two-year follow up in nine sexually abused children with PTSD (24).

In summary, findings about hippocampal volume in traumatized children are inconsistent and the reduction in hippocampal volume seen in adults with PTSD can not be confirmed in juveniles. As mentioned, it might be hypothesized that the reduction in volume appears over time and is therefore only visible in adulthood (31). Furthermore, findings from a study in adult patients comparing patients who developed PTSD in reaction to a single psychological trauma with patients who developed PTSD after multiple trauma and the results from a twin study in traumatised and non-traumatized adult patients (32) suggest that smaller hippocampal volume could be a sign of vulnerability instead of a consequence of psychological trauma, a sign that might appear only at later age (33)). Moreover, both theories might be true: a smaller hippocampus may be a vulnerability factor for PTSD and after trauma exposure PTSD can result in a smaller hippocampus.

### **Corpus callosum**

The corpus callosum (CC) connects the two hemispheres of the brain. Seven studies presented results on the corpus callosum, six structural and one DTI study. (see table 2) Of the six structural studies five found a reduction in cross sectional areas and one found no difference compared to controls. The DTI study reported localised reduced FA in the corpus callosum.

In the first MRI study in children with PTSD (N=44) (25) De Bellis et al. found a reduction in size of the midsagittal, middle and posterior regions of the corpus callosum. Symptoms of PTSD and dissociation correlated negatively with total and regional CC volumetric measurements. De Bellis et al. in later studies confirmed these findings (18;27). Mehta et al (N=14) found no difference in midsagittal CC area between early deprived Romanian adoptees and controls (26). Teicher et al. in a group of 28 abused or neglected child psychiatric inpatients found a significant reduction in cross sectional area of the corpus callosum compared to healthy controls, and to a lesser degree in comparison to psychiatric inpatients with other diagnoses (34). In this study the association in girls was strongest with sexual abuse, with the reduction in cross sectional area more located in the rostral part of the CC, whereas in boys the stronger association was with neglect and the reduction in the caudal part. The authors suggest that this can be explained by the fact that myelinization in the CC follows a rostral-caudal pattern and neglect usually takes place in an earlier phase of development. De Bellis et al. also found that the corpus callosum was more affected by early maltreatment in male than in female children (18).

Jackowski et al. (N=17), studying cerebral connectivity in a DTI study, found reduced fractional anisotropy in the medial and posterior corpus, pointing to less connectivity (35).

In traumatized children and adolescents most studies show reduced cross sectional area and connectivity of the CC (36). The structural findings seem to be gender specific and possibly also related to the period in the development that the abuse or neglect took place. The findings in children and adolescents seem to be in line with the results from studies in adults and preclinical data.

The reduction in cross sectional area of the CC was also found in two studies with adults with PTSD (37);(38). Preclinical research in rhesus monkeys showed a relationship between early life stress and a reduction of the CC (9). As the corpus callosum is crucial for cortical communication and individuals with a commissurotomy show discontinuities between perception, comprehension and response, PTSD symptoms like dissociation might be related to abnormalities in CC structure (25).

## Prefrontal Cortex

In the emotional circuit of the brain areas in the prefrontal cortex (PFC) are thought to exert control over the limbic system. Lesion studies showed that the medial prefrontal cortex modulates emotional responses through inhibition of the amygdala, where emotions are generated (22).

Six of the 23 structural articles identified found structural consequences of early psychological trauma in the prefrontal cortex, although the findings were equivocal.. Four studies found a decrease in volume: One study in children and adolescents with PTSD (N=28) reported a smaller volume of the prefrontal cortex and the prefrontal white matter (14). Andersen et al. reported decreased frontal cortex volume in young female adults (N=26) related to sexual abuse at ages 14-16 years, corresponding with a period of intensive cortical development in late adolescence (28). In physically abused children (N=31) Hanson et al. found a reduced volume of the orbitofrontal cortex. (39) Tomoda (40), using voxel based morphometry (VBM), found reduced prefrontal cortical gray matter volume (GMV) in the medial and dorsolateral frontal cortex in young adults (N=23) who experienced harsh corporal punishment during childhood.

In contrast, Carrion et al. found increased GMV in the prefrontal cortex (inferior and superior quadrants) of children 7-14 years of age (N=14) with PTSD (41). Finally, in a study by Richert and Carrion (N=23), children with PTSD symptoms showed a larger gray matter volume in the middle inferior and ventral regions of the PFC. The decreased volume of gray matter in the dorsal PFC correlated with increased functional impairment scores (42).

In line with the findings of reduced volume in some of the studies in children and adolescents, van Harmelen et al. (12) showed an association between maltreatment and a reduction in predominantly left dorsal medial prefrontal cortex volume in a study with adults reporting childhood emotional maltreatment.

Remarkably, in a cross-sectional review (43) reporting on neuroimaging findings in children and adolescents with mental disorders from 2005 to 2008, the frontal cortex was the region that showed the most structural and functional abnormalities in children and adolescents with anxiety disorders. In line with findings in adults (22) the group of children and adolescents with anxiety or depressive disorders (the affective cluster) was characterized by abnormalities of the frontal-limbic regions. In the same review the frontal cortex was also identified as the region where the structural and functional abnormalities were consistently found in the group of disorders with 'cognitive deficits' (ADHD, autism spectrum disorders, schizophrenia, anorexia nervosa, addiction).

The majority of structural studies in children and adolescents included in our review did not find structural abnormalities in the PFC associated with maltreatment or psychological trauma. This may be related to the inclusion of subjects based on exposure to a form of psychological trauma without the presence of psychopathology in a number of studies, the small numbers of subjects or differences in scanner resolution.

## Total brain

Total cerebral volume is examined as some consider it to be a marker for more diffuse cerebral damage. Four larger, also older (18;23;25;27;27) studies and one more recent study (26) reported a decrease in total cerebral volume in addition to other findings in youths with PTSD or a history of chronic psychological trauma. In traumatized adults, decreased total brain volume has not been reported. Results from animal studies showed that stress has a negative effect on brain development through the mechanisms of accelerated loss of neurons, delays in myelination of neurons and inadequate ways of pruning of neurons. These developmental processes are likely to be

controlled by the stress hormone cortisol and catecholamines (25). Through these mechanisms the stress and disturbances of stress regulation generated by psychological trauma are thought to influence brain development.

## **Sensory cortex**

Recently, three different studies from the group of Teicher found a relationship between certain types of maltreatment and alterations in the volume or FA (DTI) of parts of the sensory cortex in young adults (18-25 year), traumatized during childhood. Because brain development continues until the third decade of life, these results are relevant to our topic.. Especially in late adolescence and early adulthood, major changes still take place in the brain and data on this period may shed light on the differences in findings between children and adults with a history of psychological trauma.

The first study by Tomoda et al. found a relationship between the duration of sexual abuse before age 12 and a reduction in GMV in the primary and secondary visual cortex (VBM) of young women (N=23) (44). Choi et al. used DTI and found reduced fractional anisotropy in the visual limbic pathway (the inferior longitudinal fasciculus of the left lateral occipital lobe) in 20 young adults who witnessed domestic violence in childhood, compared to controls (45). In the third study by Tomoda et al. (N=21), exposure to parental verbal abuse was associated with an increase in GMV in the superior temporal gyrus (the auditory association cortex) (46). Taken together, these data suggest that parts of the sensory cortex involved in perception processing may be affected by exposure to extreme impressions during early development. Alternatively, it could also be the case that differences in structure and functioning of the sensory cortex influence the vulnerability to traumatization.

## **Cerebellum**

The cerebellum has a coordinating function in motor action, while more recent research suggests a similar role for the cerebellum in cognitive and emotional processes through its connection with limbic structures and the HPA axis (10);(47).

Two structural studies reported on the cerebellum and both found a decrease in volume. In the study of De Bellis et al. (N=58) the left, right and total cerebellum volume were smaller in children and adolescents with maltreatment related PTSD than in youngsters with generalized anxiety disorder and healthy controls. Cerebellar volume positively correlated with age of onset of the psychological trauma and negatively with the duration (48). Carrion et al. found a reduced volume of the pons and cerebellar vermis in 24 patients with paediatric PTSD. (41) Interestingly, a recent study in adult patients (N=42) (49) revealed a correlation between PTSD and reduced left cerebellar hemisphere and vermal volume in comparison to resilient controls who experienced psychological trauma but did not develop PTSD. Moreover, in the PTSD group vermal volume correlated negatively with traumatic symptoms and early traumatic life events.

## **Amygdala**

The amygdala plays an important role in emotional circuitry, especially in fear conditioning and threat appraisal (7). Abnormalities in the amygdala are strongly associated with affective disorders and probably also with vulnerability for psychopathology (43). To our knowledge, only three studies report on structural abnormalities of the amygdala in traumatized children and adolescents. One found an increase in volume compared to controls, the other two found no difference in volume. The study by Mehta (26) found increased amygdala volumes in a study (N = 14) in severe early deprived Romanian adoptees. Left amygdala volume was related to the time spent in the institutions in Romania.

De Bellis et al (24) in a longitudinal pilot study (N=9) found no difference in amygdala volume between children with maltreatment related PTSD and healthy controls at baseline, after at least two years' follow up and across time. In a more recent and somewhat larger (N=28) study by De Bellis et al. (27) in children and adolescents that had maltreatment related PTSD, the authors again found no differences in amygdala volume.

In adults, almost all functional MRI studies in PTSD show increased activation or reactivity of the amygdala (22). Structural findings concerning amygdala volume in adults with PTSD are mixed, with some studies showing smaller volumes and other no abnormalities. This is also true for adults with PTSD and a history of childhood maltreatment (21;31). Animal data show that the amygdala play a central role in the neurocircuits activated by early adverse experience like maternal separation causing dysregulation of the neuroendocrine stressresponse. (3)

## **Pituitary**

Thomas and De Bellis in one study specifically examined the pituitary gland because of its function in the HPA axis, controlling cortisol production in reaction to stress (19). In this larger study (N=61) the researchers did not find overall group differences in pituitary volume between the maltreatment related PTSD patients and healthy controls, but there was a significant age-by-group effect in the PTSD subjects. In the PTSD subjects pituitary volume increased more with age than in control subjects. This is an interesting finding as HPA axis abnormalities are known to be associated with PTSD. To our knowledge there are no specific MRI studies on the pituitary in adult traumatized patients.

## **Uncinate fasciculus**

The uncinate fasciculus (UF) connects parts of the prefrontal cortex (orbitofrontal) with the temporal lobe and the amygdala. Among the 24 reviewed structural articles there is only one small DTI study (N=7) of this structure. This connectivity study was a follow up of an earlier PET study in which a decreased glucose metabolism in limbic and paralimbic structures was found in neglected adopted children. The DTI study found a decreased fractional anisotropy in the left UF of adopted children who were subjected to early socio-emotional deprivation, compared to matched healthy controls. (50). The authors linked these DTI findings to the disturbances in neurocognitive and behavioral functioning, like a relative deficit in verbal memory. This in accordance with earlier studies that found a correlation between quantitative DTI measures of the left UF and neurocognitive variables such as general intelligence, visual and verbal memory and executive function in various patient populations. A recent review on DTI in anxiety disorders found three studies in adults in which the UF was identified as a structure where FA correlated negatively with anxiety traits, implicating the structure also in emotional functioning (51)

## **Summary of structural findings**

Because of the limited number of studies, the small sample size of many of the structural studies and the fact that some studies examined the same population, conclusions can only be tentative. The most robust findings seem to be a reduction in size of several regions of the corpus callosum and a decrease in total brain volume in traumatized children and adolescents. Recent research in young adults seems to point in the direction of an influence of early traumatization on the sensory cortex (visual and auditory cortex) and its connection to limbic areas. The reduction in hippocampal volume found in adults with PTSD is not found in children and adolescents. Findings on abnormalities in the PFC and the amygdala are limited or unequivocal.

## Functional Neuroimaging

Surprisingly, we could identify only three functional neuroimaging studies in children and youth with a history of psychological trauma or maltreatment.

Yang et al published a very small study (N=5) in which child earthquake survivors with PTSD were matched with non-PTSD survivors (52). Functional scans were made during visual perception and imaginary recollection of traumatic reminders and neutral pictures. Contrary to the control group, the PTSD group showed activation in the bilateral visual cortex, bilateral cerebellum and left parahippocampal gyrus. Under the same conditions the control group showed activation in the anterior cingulate cortex while the PTSD group did not. Although this is only one, very small study, the results may point in the direction of involvement of the visual cortex and the cerebellum, as Tomoda et al (44) and De Bellis et al. (48) suggested based on their structural studies of these regions.

In the second functional MRI study by Carrion et al. (53), 16 youths with PTS symptoms (PTSS) performed a response-inhibition Go/no-Go task. The 14 age and gender matched control subjects showed greater middle frontal cortex activation (Brodmann area 9/46) than the PTSS subjects. The PTSS subjects had greater medial frontal activation (Brodmann area 8/9, 17/18/19, 32/24, 37). A subgroup of seven youths with PTSS and a history of self injurious behaviour demonstrated increased insula and orbitofrontal activation. Insula activation correlated positively with PTSS severity.

Research in adult traumatized patients mostly shows a decreased activation in the PFC (22). The paradigms used in adults usually consist of exposure to visual or auditory stimuli related to a specific type of psychological trauma.

In the third fMRI study Carrion et al. found reduced activity in the hippocampus of 16 adolescents with PTS symptoms during a verbal declarative memory task in the scanner (54). This is in line with similar findings of reduced hippocampal activity in adults with PTSD during a verbal declarative memory task (22)

**Table 2. Results reviewed studies**

Structural (volumetric)		
Structure	Study	Results
Hippocampus	De Bellis MD, Pittsburgh, 1999	=
	Carrion VG, Stanford, 2001	=
	De Bellis MD, Pittsburgh, 2001	=
	De Bellis MD, Pittsburgh, 2002	=
	Tupler LA, Pittsburgh, 2006	↑ WMV↑ GMV =
	Carrion VG, Stanford, 2007	↓
	Andersen SL, Harvard, 2008	↓
	Mehta MA, Southampton, 2009	=
	De Bellis MD, Durham, 2010	=
Corpus callosum	De Bellis MD, Pittsburgh, 1999	CSA↓
	De Bellis MD, Pittsburgh, 2002	CSA↓
	De Bellis MD, Pittsburgh, 2003	CSA↓
	Teicher MH, Harvard, 2004	CSA↓
	Andersen SL, Harvard, 2008	CSA↓

	Mehta MA, Southampton, 2009	=
Frontal cortex	De Bellis MD, Pittsburgh, 2002	↓ WMV↓
	Richert KA, Stanford, 2005	GMV ↓/↑
	Carrion VG, Stanford, 2008	GMV↑
	Andersen SL, Harvard, 2008	↓
	Tomoda A, Harvard, 2009	GMV↓
	Hanson, JL, Wisconsin, 2010	↓
Total brain	De Bellis MD, Pittsburgh, 1999	↓
	Carrion VG, Stanford, 2001	↓
	De Bellis MD, Pittsburgh, 2002	↓
	De Bellis MD, Pittsburgh, 2003	↓
	Mehta MA, Southampton, 2009	GMV↓ WMV↓
Amygdala	De Bellis MD, Pittsburgh, 2001	=
	De Bellis MD, Pittsburgh, 2002	=
	Mehta MA, Southampton, 2009	↑
Visual cortex	Tomoda A, Harvard, 2009	GMV↓
Sup temp gyrus	De Bellis MD, Pittsburgh, 2002	GMV↑ WMV↓
	Choi J, Harvard, 2009	WMT↓
	Tomoda A, Harvard, 2011	GMV↑
Cerebellum	De Bellis MD, Pittsburgh, 2006	↓
	Carrion VG, Stanford, 2009	GMV↓ vermis
Pituitary	Thomas LA, Pittsburgh, 2004	=/↑

GMV= Grey Matter Volume  
WMV= White Matter Volume  
CSA= Cross Sectional Area

Diffusion Tensor Imaging (DTI )		
Structure	Study	Results
Hippocampus	Choi J, Harvard, 2009	FA↓ Cingulum bundle post tail left hippocampus
Corpus callosum	Jackowski AP, Yale, 2008	FA ↓ med + post corpus
Visual cortex	Choi J, Harvard, 2011	FA↓ Visual limbic pathway
Uncinate fasciculus	Eluvathingal TJ, Detroit, 2006	FA↓ Left

FA = fractional anisotropy

Functional		
Structure	Study	Results
Hippocampus	Carrion VG, Stanford, 2010	↓
Frontal cortex	Carrion VG, Stanford, 2008	Medial PFC↑ Middle PFC↓
Visual cortex	Yang P, Taiwan, 2004	↑
Cerebellum	Yang P, Taiwan, 2004	↑
Parahippocampal gyrus	Yang P, Taiwan, 2004	↑

## Discussion

Neuroimaging is considered an important tool to study the effects of psychological trauma on the brain. As a large body of evidence points at the immediate and long-term sequelae of traumatic experiences in childhood it is remarkable, however, that so few neuroimaging studies in traumatized juveniles have been published. With the exception of two studies, neuroimaging research in traumatized juveniles was conducted in the USA and by a limited number of groups. Most studies examined structural aspects and we could not identify studies on the effect of psychotherapy or pharmacotherapy. Neuroimaging research in traumatized children and adolescents lags behind research in other child and adolescent disorders like ADHD and autism, both in number and approach. For example, a review by Konrad and Eickhoff in 2010 about ADHD mentioned already 18 studies on connectivity alone. (55) A review by Williams in the same year on neuroimaging studies that helped explaining the nature of autism and related disorders, included almost 40 studies. (56) There are limited or no data available on structural and functional connectivity in traumatized children and adolescents, on brain activation patterns during cognitive and emotional tasks, on longitudinal effects, and on the effects of psychotherapy or pharmacotherapy.

There can be different explanations for this relative scarcity of neuroimaging studies in traumatized children and adolescents, such as difficulty of inclusion, high number of drop-outs, or the idea that this type of research is especially burdensome for these children and youngsters. In our own and others experience inclusion can be difficult for several reasons, for example because of obtaining parental consent when abuse takes place in the family circle or reluctance of professionals and parents to let this group of patients participate in research..

Given the limited number of studies, often conducted by the same groups, the small sample sizes and the often disparious findings, conclusions of our review must be considered tentative.

The most consistent structural finding seems to be a reduced volume of parts of the corpus callosum in traumatized juveniles. No clear picture emerges from the three functional studies. Several structural and functional findings are in line with results found in adult trauma patients, in juvenile and adult patients with affective disorders, and in animal studies. The reduction in size of brain structures, especially total brain and PFC, in traumatized children and adolescents is considered to be the result of deviant brain development caused by stress, in line with animal studies showing negative effects of stress on brain development. Active brain development is characterized by loss of neurons which is thought to be a process of controlled differentiation. As this controlled differentiation is at least partly under the influence of stress hormones, it can be hypothesized that psychological trauma, especially in critical time windows, overstimulates this process. Animal data have confirmed this hypothesis for early stress in relation to hippocampal atrophy, reduced fibre innervation and fibre density in some regions of the prefrontal cortex and the corpus callosum (9). The influence of severe stress can lead to long lasting changes in brain structure and function. In this light it is important to mention the strong relationship between childhood adverse experience and

later psychopathology in general as was recently reconfirmed by a large WHO survey in 21 countries (1) (See also: (57)).

Remarkably, some abnormalities, like the consistent finding of reduced volume of the hippocampus in adult psychological trauma patients are not found in traumatized children and adolescents. This underscores the importance of continued research into the interaction between psychological trauma and the developing brain. In addition, research in adults with PTSD and mood and anxiety disorders has shown changes in brain function and structure after successful psychotherapy (58-60). Children and youth with psychological trauma related psychopathology are typically treated with psychotherapy, but data on the malleability of their brain structure and function by therapy, or on critical neurobiological windows of opportunity for treatment are still lacking.

Research in developmental psychopathology and affective neuroscience has come a long way in describing the neurobiological basis of important cognitive and emotional processes and their disturbances, but more research efforts to unravel the neurobiology of the traumatized juvenile brain, and especially its potential for change, is clearly warranted (61;62).



## Reference List

1. Kessler RC, McLaughlin KA, Green JG, Gruber MJ, Sampson NA, Zaslavsky AM, Aguilar-Gaxiola S, Alhamzawi AO, Alonso J, Angermeyer M, Benjet C, Bromet E, Chatterji S, de GG, Demyttenaere K, Fayyad J, Florescu S, Gal G, Gureje O, Haro JM, Hu CY, Karam EG, Kawakami N, Lee S, Lepine JP, Ormel J, Posada-Villa J, Sagar R, Tsang A, Ustun TB, Vassilev S, Viana MC, Williams DR (2010) Childhood adversities and adult psychopathology in the WHO World Mental Health Surveys. *Br J Psychiatry* 197:378-385
2. MacMillan HL, Fleming JE, Streiner DL, Lin E, Boyle MH, Jamieson E, Duku EK, Walsh CA, Wong MY, Beardslee WR (2001) Childhood abuse and lifetime psychopathology in a community sample. *Am J Psychiatry* 158:1878-1883
3. Sanchez MM, Ladd CO, Plotsky PM (2001) Early adverse experience as a developmental risk factor for later psychopathology: evidence from rodent and primate models. *Dev Psychopathol* 13:419-449
4. Teicher MH (2002) Scars that won't heal: the neurobiology of child abuse. *Sci Am* 286:68-75
5. Teicher MH, Andersen SL, Polcari A, Anderson CM, Navalta CP (2002) Developmental neurobiology of childhood stress and trauma. *Psychiatr Clin North Am* 25:397-viii
6. Vermetten E, Bremner JD (2002) Circuits and systems in stress. II. Applications to neurobiology and treatment in posttraumatic stress disorder. *Depress Anxiety* 16:14-38
7. Pine DS (2003) Developmental psychobiology and response to threats: relevance to trauma in children and adolescents. *Biol Psychiatry* 53:796-808
8. Nock MK, Kaufman J, Rosenheck RA (2001) Examination of predictors of severe violence in combat-exposed Vietnam veterans. *J Trauma Stress* 14:835-841
9. Kaufman J, Plotsky PM, Nemeroff CB, Charney DS (2000) Effects of early adverse experiences on brain structure and function: clinical implications. *Biol Psychiatry* 48:778-790
10. McCrory E, De Brito SA, Viding E (2010) Research review: the neurobiology and genetics of maltreatment and adversity. *J Child Psychol Psychiatry* 51:1079-1095
11. Bremner JD, Vermetten E (2001) Stress and development: behavioral and biological consequences. *Dev Psychopathol* 13:473-489
12. van Harmelen AL, van Tol MJ, van der Wee NJ, Veltman DJ, Aleman A, Spinhoven P, van Buchem MA, Zitman FG, Penninx BW, Elzinga BM (2010) Reduced medial prefrontal cortex volume in adults reporting childhood emotional maltreatment. *Biol Psychiatry* 68:832-838
13. Vermetten E, Vythilingam M, Southwick SM, Charney DS, Bremner JD (2003) Long-term treatment with paroxetine increases verbal declarative memory and hippocampal volume in posttraumatic stress disorder. *Biol Psychiatry* 54:693-702
14. Felmingham K, Kemp A, Williams L, Das P, Hughes G, Peduto A, Bryant R (2007) Changes in anterior cingulate and amygdala after cognitive behavior therapy of posttraumatic stress disorder. *Psychol Sci* 18:127-129
15. Roy MJ, Francis J, Friedlander J, Banks-Williams L, Lande RG, Taylor P, Blair J, McLellan J, Law W, Tarpley V, Patt I, Yu H, Mallinger A, Difede J, Rizzo A, Rothbaum B (2010) Improvement in cerebral function with treatment of posttraumatic stress disorder. *Ann N Y Acad Sci* 1208:142-149
16. Newport DJ, Stowe ZN, Nemeroff CB (2002) Parental depression: animal models of an adverse life event. *Am J Psychiatry* 159:1265-1283

17. De Bellis MD, Hooper SR, Woolley DP, Shenk CE (2010) Demographic, maltreatment, and neurobiological correlates of PTSD symptoms in children and adolescents. *J Pediatr Psychol* 35:570-577
18. De Bellis MD, Keshavan MS (2003) Sex differences in brain maturation in maltreatment-related pediatric posttraumatic stress disorder. *Neurosci Biobehav Rev* 27:103-117
19. Thomas LA, De B (2004) Pituitary volumes in pediatric maltreatment-related posttraumatic stress disorder. *Biol Psychiatry* 55:752-758
20. Tupler LA, De B (2006) Segmented hippocampal volume in children and adolescents with posttraumatic stress disorder. *Biol Psychiatry* 59:523-529
21. Karl A, Schaefer M, Malta LS, Dorfel D, Rohleder N, Werner A (2006) A meta-analysis of structural brain abnormalities in PTSD. *Neurosci Biobehav Rev* 30:1004-1031
22. Bremner JD (2007) Neuroimaging in posttraumatic stress disorder and other stress-related disorders. *Neuroimaging Clin N Am* 17:523-38, ix
23. Carrion VG, Weems CF, Eliez S, Patwardhan A, Brown W, Ray RD, Reiss AL (2001) Attenuation of frontal asymmetry in pediatric posttraumatic stress disorder. *Biol Psychiatry* 50:943-951
24. De Bellis MD, Hall J, Boring AM, Frustaci K, Moritz G (2001) A pilot longitudinal study of hippocampal volumes in pediatric maltreatment-related posttraumatic stress disorder. *Biol Psychiatry* 50:305-309
25. De Bellis, Keshavan MS, Clark DB, Casey BJ, Giedd JN, Boring AM, Frustaci K, Ryan ND (1999) A.E. Bennett Research Award. Developmental traumatology. Part II: Brain development. *Biol Psychiatry* 45:1271-1284
26. Mehta MA, Golembo NI, Nosarti C, Colvert E, Mota A, Williams SC, Rutter M, Sonuga-Barke EJ (2009) Amygdala, hippocampal and corpus callosum size following severe early institutional deprivation: the English and Romanian Adoptees study pilot. *J Child Psychol Psychiatry* 50:943-951
27. De Bellis MD, Keshavan MS, Shifflett H, Iyengar S, Beers SR, Hall J, Moritz G (2002) Brain structures in pediatric maltreatment-related posttraumatic stress disorder: a sociodemographically matched study. *Biol Psychiatry* 52:1066-1078
28. Andersen SL, Tomada A, Vincow ES, Valente E, Polcari A, Teicher MH (2008) Preliminary evidence for sensitive periods in the effect of childhood sexual abuse on regional brain development. *J Neuropsychiatry Clin Neurosci* 20:292-301
29. Choi J, Jeong B, Rohan ML, Polcari AM, Teicher MH (2009) Preliminary evidence for white matter tract abnormalities in young adults exposed to parental verbal abuse. *Biol Psychiatry* 65:227-234
30. Carrion VG, Weems CF, Reiss AL (2007) Stress predicts brain changes in children: a pilot longitudinal study on youth stress, posttraumatic stress disorder, and the hippocampus. *Pediatrics* 119:509-516
31. Woon FL, Hedges DW (2008) Hippocampal and amygdala volumes in children and adults with childhood maltreatment-related posttraumatic stress disorder: a meta-analysis. *Hippocampus* 18:729-736
32. Gilbertson MW, Shenton ME, Ciszewski A, Kasai K, Lasko NB, Orr SP, Pitman RK (2002) Smaller hippocampal volume predicts pathologic vulnerability to psychological trauma. *Nat Neurosci* 5:1242-1247

33. Yehuda R, Golier JA, Tischler L, Harvey PD, Newmark R, Yang RK, Buchsbaum MS (2007) Hippocampal volume in aging combat veterans with and without post-traumatic stress disorder: relation to risk and resilience factors. *J Psychiatr Res* 41:435-445
34. Teicher MH, Dumont NL, Ito Y, Vaituzis C, Giedd JN, Andersen SL (2004) Childhood neglect is associated with reduced corpus callosum area. *Biol Psychiatry* 56:80-85
35. Jackowski AP, Douglas-Palumberi H, Jackowski M, Win L, Schultz RT, Staib LW, Krystal JH, Kaufman J (2008) Corpus callosum in maltreated children with posttraumatic stress disorder: a diffusion tensor imaging study. *Psychiatry Res* 162:256-261
36. Jackowski AP, de Araujo CM, de Lacerda AL, Mari JJ, Kaufman J (2009) Neurostructural imaging findings in children with post-traumatic stress disorder: brief review. *Psychiatry Clin Neurosci* 63:1-8
37. Kitayama N, Brummer M, Hertz L, Quinn S, Kim Y, Bremner JD (2007) Morphologic alterations in the corpus callosum in abuse-related posttraumatic stress disorder: a preliminary study. *J Nerv Ment Dis* 195:1027-1029
38. Villarreal G, Hamilton DA, Graham DP, Driscoll I, Qualls C, Petropoulos H, Brooks WM (2004) Reduced area of the corpus callosum in posttraumatic stress disorder. *Psychiatry Res* 131:227-235
39. Hanson JL, Chung MK, Avants BB, Shirtcliff EA, Gee JC, Davidson RJ, Pollak SD (2010) Early stress is associated with alterations in the orbitofrontal cortex: a tensor-based morphometry investigation of brain structure and behavioral risk. *J Neurosci* 30:7466-7472
40. Tomoda A, Suzuki H, Rabi K, Sheu YS, Polcari A, Teicher MH (2009) Reduced prefrontal cortical gray matter volume in young adults exposed to harsh corporal punishment. *Neuroimage* 47 Suppl 2:T66-T71
41. Carrion VG, Weems CF, Watson C, Eliez S, Menon V, Reiss AL (2009) Converging evidence for abnormalities of the prefrontal cortex and evaluation of midsagittal structures in pediatric posttraumatic stress disorder: an MRI study. *Psychiatry Res* 172:226-234
42. Richert KA, Carrion VG, Karchemskiy A, Reiss AL (2006) Regional differences of the prefrontal cortex in pediatric PTSD: an MRI study. *Depress Anxiety* 23:17-25
43. Mana S, Paillere Martinot ML, Martinot JL (2010) Brain imaging findings in children and adolescents with mental disorders: a cross-sectional review. *Eur Psychiatry* 25:345-354
44. Tomoda A, Navalta CP, Polcari A, Sadato N, Teicher MH (2009) Childhood sexual abuse is associated with reduced gray matter volume in visual cortex of young women. *Biol Psychiatry* 66:642-648
45. Choi J, Jeong B, Polcari A, Rohan ML, Teicher MH (2012) Reduced fractional anisotropy in the visual limbic pathway of young adults witnessing domestic violence in childhood. *Neuroimage* 59:1071-1079
46. Tomoda A, Sheu YS, Rabi K, Suzuki H, Navalta CP, Polcari A, Teicher MH (2011) Exposure to parental verbal abuse is associated with increased gray matter volume in superior temporal gyrus. *Neuroimage* 54 Suppl 1:S280-S286
47. Durston S (2008) Converging methods in studying attention-deficit/hyperactivity disorder: what can we learn from neuroimaging and genetics? *Dev Psychopathol* 20:1133-1143
48. De Bellis, Kuchibhatla M (2006) Cerebellar volumes in pediatric maltreatment-related posttraumatic stress disorder. *Biol Psychiatry* 60:697-703
49. Baldacara L, Jackowski AP, Schoedl A, Pupo M, Andreoli SB, Mello MF, Lacerda AL, Mari JJ, Bressan RA (2011) Reduced cerebellar left hemisphere and vermal volume in adults with PTSD from a community sample. *J Psychiatr Res* 45:1627-1633

50. Eluvathingal TJ, Chugani HT, Behen ME, Juhasz C, Muzik O, Maqbool M, Chugani DC, Makki M (2006) Abnormal brain connectivity in children after early severe socioemotional deprivation: a diffusion tensor imaging study. *Pediatrics* 117:2093-2100
51. Ayling E, Aghajani M, Fouche JP, van der Wee N (2012) Diffusion tensor imaging in anxiety disorders. *Curr Psychiatry Rep* 14:197-202
52. Yang P, Wu MT, Hsu CC, Ker JH (2004) Evidence of early neurobiological alternations in adolescents with posttraumatic stress disorder: a functional MRI study. *Neurosci Lett* 370:13-18
53. Carrion VG, Garrett A, Menon V, Weems CF, Reiss AL (2008) Posttraumatic stress symptoms and brain function during a response-inhibition task: an fMRI study in youth. *Depress Anxiety* 25:514-526
54. Carrion VG, Haas BW, Garrett A, Song S, Reiss AL (2010) Reduced hippocampal activity in youth with posttraumatic stress symptoms: an FMRI study. *J Pediatr Psychol* 35:559-569
55. Konrad K, Eickhoff SB (2010) Is the ADHD brain wired differently? A review on structural and functional connectivity in attention deficit hyperactivity disorder. *Hum Brain Mapp* 31:904-916
56. Williams DL, Minshew NJ (2007) Understanding autism and related disorders: what has imaging taught us? *Neuroimaging Clin N Am* 17:495-509, ix
57. Felitti VJ, Anda RF, Nordenberg D, Williamson DF, Spitz AM, Edwards V, Koss MP, Marks JS (1998) Relationship of childhood abuse and household dysfunction to many of the leading causes of death in adults. The Adverse Childhood Experiences (ACE) Study. *Am J Prev Med* 14:245-258
58. Bryant RA, Felmingham K, Kemp A, Das P, Hughes G, Peduto A, Williams L (2008) Amygdala and ventral anterior cingulate activation predicts treatment response to cognitive behaviour therapy for post-traumatic stress disorder. *Psychol Med* 38:555-561
59. Frewen PA, Dozois DJ, Lanius RA (2008) Neuroimaging studies of psychological interventions for mood and anxiety disorders: empirical and methodological review. *Clin Psychol Rev* 28:228-246
60. Nardo D, Hogberg G, Looi JC, Larsson S, Hallstrom T, Pagani M (2010) Gray matter density in limbic and paralimbic cortices is associated with trauma load and EMDR outcome in PTSD patients. *J Psychiatr Res* 44:477-485
61. Pine DS (2007) Research review: a neuroscience framework for pediatric anxiety disorders. *J Child Psychol Psychiatry* 48:631-648
62. Shonkoff JP (2011) Protecting brains, not simply stimulating minds. *Science* 333:982-983