# Reducing uncertainties in image-guided radiotherapy of rectal cancer

Ende, R.P.J. van den

**Author**: Ende, R.P.J. van den
**Title**: Reducing uncertainties in image-guided radiotherapy of rectal cancer
**Issue date**: 2020-10-22



# Chapter 5

# Feasibility of gold fiducial markers as a surrogate for GTV position in image-guided radiotherapy of rectal cancer

Roy P.J. van den Ende
Ellen M. Kerkhof
Lisanne S. Rigter
Monique E. van Leerdam
Femke P. Peters
Baukelien van Triest
Marius Staring
Corrie A.M. Marijnen
Uulke A. van der Heide

International Journal of Radiation Oncology, Biology, Physics 105:1151–9 (2019)

# ABSTRACT

## Purpose

To evaluate the feasibility of fiducial markers as a surrogate for GTV position in image-guided radiotherapy of rectal cancer.

## Methods and materials

We analyzed 35 fiducials in 19 rectal cancer patients who received short course radiotherapy or long-course chemoradiotherapy. A MRI exam was acquired before and after the first week of radiotherapy and daily pre- and post-irradiation CBCT scans were acquired in the first week of radiotherapy. Between the two MRI exams, the fiducial displacement relative to the center of gravity of the GTV ($COG_{GTV}$) and the $COG_{GTV}$ displacement relative to bony anatomy was determined. Using the CBCT scans, inter- and intrafraction fiducial displacement relative to bony anatomy was determined.

## Results

The systematic error of the fiducial displacement relative to the $COG_{GTV}$ was 2.8, 2.4 and 4.2 mm in the left-right (LR), anterior-posterior (AP) and craniocaudal (CC) direction. Large interfraction systematic errors of up to 8.0 mm and random errors up to 4.7 mm were found for $COG_{GTV}$ and fiducial displacements relative to bony anatomy, mostly in the AP and CC directions. For tumors located in the mid- and upper rectum these errors were up to 9.4 mm (systematic) and 5.6 mm (random) compared to 4.9 mm and 2.9 mm for tumors in the lower rectum. Systematic and random errors of the intrafraction fiducial displacement relative to bony anatomy were ≤2.1 mm in all directions.

## Conclusions

Large interfraction errors of the $COG_{GTV}$ and the fiducials relative to bony anatomy were found. Therefore, despite the observed fiducial displacement relative to the $COG_{GTV}$, the use of fiducials as a surrogate for GTV position reduces the required margins in the AP and CC direction for a GTV boost using image-guided radiotherapy of rectal cancer. This reduction in margin may be larger in patients with tumors located in the mid- and upper rectum compared to the lower rectum.


# INTRODUCTION

Neoadjuvant radiotherapy reduces local recurrence rates after surgery in rectal cancer patients [1–4]. A pathological complete response is observed in 15-25% of patients after neoadjuvant chemoradiation [5,6]. In addition, dose escalation is suggested to result in higher complete response rates, which is attractive considering the increased interest in organ preservation [6–10].

The current clinical practice for setup correction in external-beam radiotherapy of rectal cancer is based on bony anatomy using cone beam computed tomography (CBCT) [11]. To ensure proper gross tumor volume (GTV) coverage in a GTV boost setting, a planning target volume (PTV) margin of 7-30 mm is used to accommodate delineation errors, setup errors and inter- and intrafraction motion of the GTV [12–16]. Setup correction based on the GTV instead of bony anatomy may decrease the required PTV margins. However, this is challenging due to the limited soft tissue contrast of CBCT [17]. MR-guided radiotherapy systems could be used to perform setup correction based on a direct visualization of the GTV with superior soft tissue contrast [18]. However, such systems are not widely available yet. Given that fiducial markers have been proven useful for setup correction in other tumor locations such as pancreas, esophagus and prostate [19–21], fiducials may be useful as a surrogate for GTV position in rectal cancer. Several studies have reported on the use of fiducials in the rectum and focus on marker visibility and migration [22], fiducial retention and adverse events [23,24] and the use of fiducials to aid in the delineation of the target volume [25]. However, none have investigated the potential benefit of fiducials for setup correction in radiotherapy of rectal cancer.

In order to use fiducials as a surrogate for the GTV, the position of the fiducials must be representative of the position of the GTV. The aim of this study was therefore to evaluate the feasibility of fiducials as a surrogate for GTV position in radiotherapy of rectal cancer.

## METHODS AND MATERIALS

### Patients

Between July 2015 and September 2016, we included 20 patients with proven rectal adenocarcinoma who were scheduled for short-course radiotherapy (SC-RT; 5x5 Gy) or long-course chemoradiotherapy (LC-CRT; 25x2 Gy combined with capecitabine 825 mg/m$^2$ twice daily on days of radiotherapy) followed by total mesorectal excision. Patients were treated in supine position. Before each radiotherapy fraction, patients were asked to void their bladder and subsequently drink 300 cc of water to reproduce bladder filling.

Exclusion criteria were contraindication for fiducial insertion (coagulopathy or anticoagulantia that could not be stopped), prior pelvic irradiation, pelvic surgery or hip replacement surgery, pregnancy, a contraindication for MRI or world health organization performance status 3-4. This study was registered at the Dutch Trial Registry (REMARK study, registration no. NL4473) [26].

### Fiducials

We used four types of fiducials, inserted in five patients each (Visicoil 0.5x5 mm and Visicoil 0.75x5 mm [IBA Dosimetry, GmbH, Germany], Cook 0.64x3.4 mm [COOK Medical, Limerick, Ireland] and Gold Anchor 0.28x20 mm (unfolded length)[Naslund Medical AB, Sweden]). We endoscopically placed the

fiducials in the tumor and mesorectum at least one day before the start of radiotherapy. The fiducial insertion strategy is described in Rigter *et al.* [24].

## MRI processing

We performed two multiparametric MRI exams for each patient on a Philips Achieva 1.5T, Philips Achieva 3T, Philips Achieva dStream 3T or Philips Ingenia 3T. Details of the scan protocol are listed in the supplementary materials. We acquired a first MRI exam up to two weeks before or up to one week after the start of radiotherapy and a second MRI exam between one and two weeks after the start of radiotherapy. In an earlier study, we evaluated the MRI visibility of the fiducials and we identified 17 out of 34 fiducials on the first MRI and 9 out of 30 fiducials on the second MRI [27]. The Visicoil 0.75 and the Gold Anchor were the best visible fiducials on MRI. In addition, a consensus meeting with a radiologist (EP) and a resident radiation oncologist (ER) was held to identify more fiducials for this study. We delineated the artifacts that the fiducials created on MRI on the tT2-TSE scan with help of the other available sequences. The coordinate of the center of gravity (COG) of this delineation represented the fiducial position.

The GTV was delineated on the tT2-TSE scan of both MRI exams by one observer (RE) and subsequently checked by a radiation oncologist (FP) in Oncentra (Elekta, Veenendaal, the Netherlands). We registered the tT2-TSE sequence of the second MRI exam to the tT2-TSE sequence of the first MRI exam using Elastix [28] with a rigid transformation based on the bony anatomy of the pelvis and the sacrum.

We selected both ischial spines and the pubic symphysis as anatomical landmarks on the bony anatomy on the MRI exams to assess registration accuracy. The registration accuracy was defined as the mean and standard deviation of the distances between a landmark position on the registered second MRI exam and the corresponding landmark position on the first MRI exam.

To determine the displacement of the fiducials relative to the GTV, we calculated the displacement for each fiducial relative to the center of gravity of the GTV delineation ($COG_{GTV}$) on the second MRI with respect to the first MRI. Subsequently, we determined the mean of means (M) by calculating the mean displacement over all fiducials and the group systematic error (Σ) by calculating the standard deviation over all fiducial displacements [29].

To determine the interfraction GTV displacement relative to bony anatomy, we calculated the displacement of the $COG_{GTV}$ relative to bony anatomy on the second MRI with respect to the first MRI. Subsequently, we determined the mean of means by calculating the mean displacement over all $COG_{GTV}$ displacements and the group systematic error by calculating the standard deviation over all $COG_{GTV}$ displacements [29].

To test for differences in displacement between proximal and distal tumors, we calculated the interfraction $COG_{GTV}$ displacement relative to bony anatomy on MRI separately for patients with a tumor in the mid- and upper rectum (7-16 cm from anal verge) and the lower rectum (0-6 cm from anal verge) [30].

## CBCT processing

During the first week of radiotherapy, we acquired daily pre- and post-irradiation CBCT scans (Elekta XVI, reconstructed slice thickness 1.0 mm, pixel spacing 1.0 mm x 1.0 mm). For the patients that were treated with LC-CRT, pre-irradiation CBCT scans were acquired weekly after the first week of radiotherapy.

The first pre-irradiation CBCT scan was used as the reference scan. We registered all subsequent CBCT scans to the reference scan using Elastix with a rigid registration based on the bony anatomy of the pelvis and the sacrum [28]. The registration accuracy was assessed using the same method as described for the MRI exams, with the promontory as an additional anatomical landmark.

We segmented fiducials on the reference and registered CBCT scans by manually selecting a point on each fiducial. A box of 12x12x12 mm was automatically created around each selected point and a threshold that was well above the image intensities of the surrounding soft tissue was applied to segment the fiducial. The coordinate of the COG for each fiducial segmentation was used as the position for each fiducial.

The displacement of the COG of all fiducials ($COG_{FID}$) as a result of changes in fiducial configuration was calculated as follows. For patients with two or more fiducials in situ, the position of each fiducial relative to the $COG_{FID}$ was determined on each pre-irradiation CBCT scan. To assess the resulting displacement of the $COG_{FID}$, we calculated the standard deviation of each fiducial position relative to $COG_{FID}$ over all pre-irradiation CBCT scans ($SD_{FID}$) and subsequently calculated the standard deviation (SD) of the $COG_{FID}$ for each patient with two or more fiducials in situ:

$$SD\ of\ COG_{FID} = \frac{\sqrt{SD^2_{FID_1} + SD^2_{FID_2} + \ldots + SD^2_{FID_n}}}{n}$$

with $SD^2_{FID_1}$, $SD^2_{FID_2}$, ..., $SD^2_{FID_n}$ the squared standard deviation of a fiducial position relative to $COG_{FID}$ over all pre-irradiation CBCT scans in the patient and $n$ the number of fiducials in the patient. Subsequently, we determined the group random error ($\sigma$) by calculating the root-mean-square of all the standard deviations of $COG_{FID}$ [29].

To determine the interfraction fiducial displacement relative to bony anatomy, we calculated the displacement of each fiducial on each pre-irradiation CBCT scan with respect to the reference scan.

To determine the intrafraction fiducial displacement relative to bony anatomy, we calculated the displacement of each fiducial on the post-irradiation CBCT scan with respect to the pre-irradiation CBCT scan of the same fraction. For each fiducial, we calculated a mean displacement and corresponding standard deviation over all fractions for the inter- and intrafraction displacement in the left-right (LR), anterior-posterior (AP) and craniocaudal (CC) direction. Subsequently, we calculated for the inter- and intrafraction fiducial displacement the mean of means over all fiducials and the group systematic and random error by calculating the standard deviation of the mean displacements of all fiducials and the root-mean-square of the standard deviation of all fiducials [29].

To test for differences in displacement between proximal and distal tumors, we calculated the interfraction fiducial displacement relative to bony anatomy separately for patients with a tumor in the mid- and upper rectum (7-16 cm from anal verge) and the lower rectum (0-6 cm from anal verge) [30].

## Treatment margins

To determine PTV margins, we quadratically added systematic and random errors of the different components to derive the combined errors for the GTV position in three image-guidance scenarios, using the Van Herk *et al.* margin recipe [31]. For setup correction based on bony anatomy, the inter- and intrafraction displacement of the GTV relative to the bony anatomy needs to be considered. We derived the interfraction displacement relative to bony anatomy in two ways. First from the $COG_{GTV}$ displacement on MRI and second from the fiducial displacements on CBCT. Both were combined with the intrafraction fiducial displacement on CBCT to calculate the errors for setup correction based on bony anatomy. In a scenario of setup correction based on fiducials, we also need to consider the position uncertainty of the GTV relative to the fiducials. Therefore, we combined the fiducial displacement relative to the $COG_{GTV}$ with the $COG_{FID}$ displacement as a result of changes in fiducial configuration and the intrafraction fiducial displacement relative to bony anatomy on CBCT. In a scenario in which the GTV can be visualized directly for setup correction, we only used the errors of the intrafraction fiducial displacement relative to bony anatomy.

## Statistical analysis

We used SPSS Statistics 23 (IBM Corp. Released 2015. IBM SPSS Statistics for Windows, Version 23.0. Armonk, NY: IBM Corp.) for statistical analysis. Because of the small sample size in this study, we used the non-parametric Mann-Whitney U test to test for differences between the mean and standard deviation of the fiducial displacements according to the distance from the anal verge.

# RESULTS

## Patients and fiducials

One patient was excluded as all fiducials were inadvertently inserted in the prostate. Therefore, 19 patients were available for analysis, of whom 8 received SC-RT and 11 received LC-CRT. Patient characteristics are shown in Table 1. The fiducial retention in the REMARK study was described earlier [32]. A total of 35 fiducials in situ were available for analysis on CBCT, of which 26 fiducials in the tumor and 9 in the mesorectum [27]. The consensus meeting resulted in 22 identified fiducials on the first MRI and 17 identified fiducials on the second MRI. All 17 fiducials identified on the second MRI were also identified on the first MRI. Of those, 14 fiducials were inserted in the tumor and 3 fiducials were inserted in the mesorectum. Examples of a GTV delineation and a fiducial on the T2-TSE sequence of both MRI exams and a fiducial on two CBCT scans is shown in Figure 1.

## Imaging

Median time from the first MRI to the start of radiotherapy was 0 days (range -5 to 12 days). Median time between the first and second MRI exam was 7 days (range 4-21 days). For two patients who were treated with LC-CRT, the first MRI exam was acquired 2 days (2 fractions) and 5 days (3 fractions) after start of radiotherapy. The median delineated GTV volume was 22.8 cc (range 6.9 – 64.6 cc) for the first MRI and 15.2 cc (range 6.1 – 71.0 cc) for the second MRI. Median difference between the GTV volumes of the first and second MRI was -3.0 cc (range -26.5 – 6.4 cc), with a negative difference indicating a smaller volume in the second MRI. Fourteen out of nineteen delineated GTV volumes were smaller on the second MRI. The MRI registration error was on average 0.0 ± 0.6 mm (LR), 0.2 ± 1.4 mm (AP) and -0.1 ± 1.3 mm (CC).

A total of 219 CBCT scans were acquired in 19 patients (range 2 - 21 per patient), of which 132 pre-irradiation CBCT scans in 19 patients and 87 post-irradiation CBCT scans in 17 patients. The average time between pre- and post-irradiation CBCT scans was 9 ± 1 minutes. The CBCT registration error was on average -0.1 ± 0.7 mm (LR), -0.2 ± 0.9 mm (AP) and 0.0 ± 0.8 mm (CC).

**Table 1.** Patient characteristics

| Patient | Sex | Age (years) | cTNM | Distance from anal verge (cm) | Tx | Fiducial type | Number of pre-irradiation CBCT scans | Number of post-irradiation CBCT scans | Number of implanted fiducials | Number of fiducials in situ at end of Tx* | Number of fiducials identified on both first and second MRI* |
|---|---|---|---|---|---|---|---|---|---|---|---|
| 1 | M | 71 | T3N0M0 | 5 | SC-RT | Visicoil 0.5 | 5 | 5 | 3 | 1 | 1 |
| 2 | M | 82 | T3N0M0 | 0 | SC-RT | Visicoil 0.5 | 5 | 4 | 3 | 2 | 1 |
| 3 | M | 63 | T2N0M0 | 2 | LC-CRT | Visicoil 0.5 | 10 | 4 | 3 | 1 | 0 |
| 4 | M | 60 | T3N1M0 | 8 | LC-CRT | Visicoil 0.5 | 10 | 4 | 3 | 3 | 0 |
| 5 | F | 60 | T3N1M0 | 2 | SC-RT | Visicoil 0.5 | 2 | 0 | 3 | 1 | 1 |
| 6 | M | 67 | T3N2M0 | 8 | LC-CRT | Visicoil 0.75 | 10 | 6 | 3 | 1 | 1 |
| 7 | F | 52 | T3N1M0 | 8 | SC-RT | Visicoil 0.75 | 5 | 0 | 3 | 2 | 0 |
| 8 | M | 75 | T3N0M0 | 10 | SC-RT | Visicoil 0.75 | 4 | 2 | 3 | 2 | 2 |
| 9 | M | 82 | T2N1M0 | 15 | SC-RT | Visicoil 0.75 | 5 | 5 | 3 | 1 | 1 |
| 10 | M | 63 | T3N1M0 | 15 | SC-RT | Visicoil 0.75 | 5 | 5 | 3 | 1 | 1 |
| 11 | F | 62 | T2N1M0 | 11 | SC-RT | COOK | 5 | 5 | 3 | 2 | 0 |
| 12 | M | 58 | T3N0M0 | 1 | LC-CRT | COOK | - | - | 4 | - | - |
| 13 | M | 57 | T3N2M0 | 7 | LC-CRT | COOK | 10 | 5 | 4 | 1 | 1 |
| 14 | F | 60 | T3N1M0 | 2 | SC-RT | COOK | 5 | 5 | 4 | 3 | 0 |
| 15 | M | 59 | T3N2M0 | 8 | LC-CRT | COOK | 11 | 8 | 4 | 3 | 0 |
| 16 | M | 63 | T3N0M0 | 1 | LC-CRT | Gold Anchor | 9 | 5 | 3 | 2 | 2 |
| 17 | M | 65 | T3N2M0 | 2 | LC-CRT | Gold Anchor | 9 | 5 | 3 | 1 | 1 |
| 18 | M | 59 | T2N1M0 | 16 | SC-RT | Gold Anchor | 5 | 5 | 3 | 2 | 2 |
| 19 | F | 61 | T3N1M0 | 10 | SC-RT | Gold Anchor | 5 | 5 | 3 | 3 | 1 |
| 20 | M | 51 | T3N0M0 | 2 | LC-CRT | Gold Anchor | 12 | 9 | 3 | 3 | 2 |
| Total | | | | | | | 132 | 87 | 64 | 35 | 17 |

M = male, F = female, Tx = treatment schedule, SC-RT = short course radiotherapy, LC-CRT = long course chemoradiotherapy.
*Excludes fiducials that were inadvertently inserted in the prostate.

## Inter- and intrafraction displacement

The systematic error of the interfraction fiducial displacement relative to the $COG_{GTV}$ was 2.8 mm (LR), 2.4 mm (AP) and 4.2 mm (CC) as shown in Table 2. The random error of the interfraction displacement of the $COG_{FID}$ was <1 mm in all directions.

The systematic error of the $COG_{GTV}$ displacement relative to bony anatomy was substantially larger than the systematic error of the fiducial displacement relative to bony anatomy on CBCT in the AP (7.2 mm vs 4.8 mm) and CC direction (8.0 mm vs 4.6 mm). This was mainly due to two patients who showed a large $COG_{GTV}$ displacement on MRI in the AP and CC direction: 15 mm and -20 mm (AP), and -16 mm and 20 mm (CC). After reviewing the MRI exams, we observed a large difference in the amount of air in the rectum which displaced the GTV. In one of these patients also a large difference in bladder filling was observed. In the other 17 patients, the group systematic error of the $COG_{GTV}$ displacement relative to bony anatomy was 4.1 mm (AP) and 5.6 mm (CC), in line with the fiducial displacement relative to bony anatomy on CBCT.

**Table 2.** Mean of means, systematic error and random error for the different analyses

| | | | LR (mm) | AP (mm) | CC (mm) | Available data | |
|---|---|---|---|---|---|---|---|
| Position uncertainty of GTV w.r.t. fiducials | Interfraction displacement fiducials w.r.t. $COG_{GTV}$ (MRI) | M | -0.9 | 0.5 | -0.2 | MRI scans | 26 |
| | | ∑ | 2.8 | 2.4 | 4.2 | Fiducials | 17 |
| | | σ | - | - | - | Patients | 13 |
| | Interfraction displacement of $COG_{FID}$ as a result of changes in fiducial configuration (CBCT) | M | - | - | - | CBCT scans | 76 |
| | | ∑ | - | - | - | Fiducials | 27 |
| | | σ | 0.6 | 0.9 | 0.9 | Patients | 11 |
| Interfraction displacement w.r.t. bony anatomy | Interfraction displacement of $COG_{GTV}$ (MRI) | M | -0.2 | 0.5 | -1.2 | MRI scans | 38 |
| | | ∑ | 2.8 | 7.2 | 8.0 | Patients | 19 |
| | | σ | - | - | - | | |
| | Interfraction displacement of fiducials (CBCT) | M | 0.4 | -2.7 | 1.2 | CBCT scans | 132 |
| | | ∑ | 3.6 | 4.8 | 4.6 | Fiducials | 35 |
| | | σ | 2.7 | 4.2 | 4.7 | Patients | 19 |
| Intrafraction displacement w.r.t. bony anatomy | Intrafraction displacement of fiducials (CBCT) | M | -0.1 | -0.5 | 1.1 | CBCT scans | 87 |
| | | ∑ | 0.8 | 1.4 | 1.6 | Fiducials | 32 |
| | | σ | 1.4 | 1.7 | 2.1 | Patients | 17 |

LR = left-right, AP = anterior-posterior, CC = craniocaudal, M = mean of means, ∑ = systematic error, σ = random error

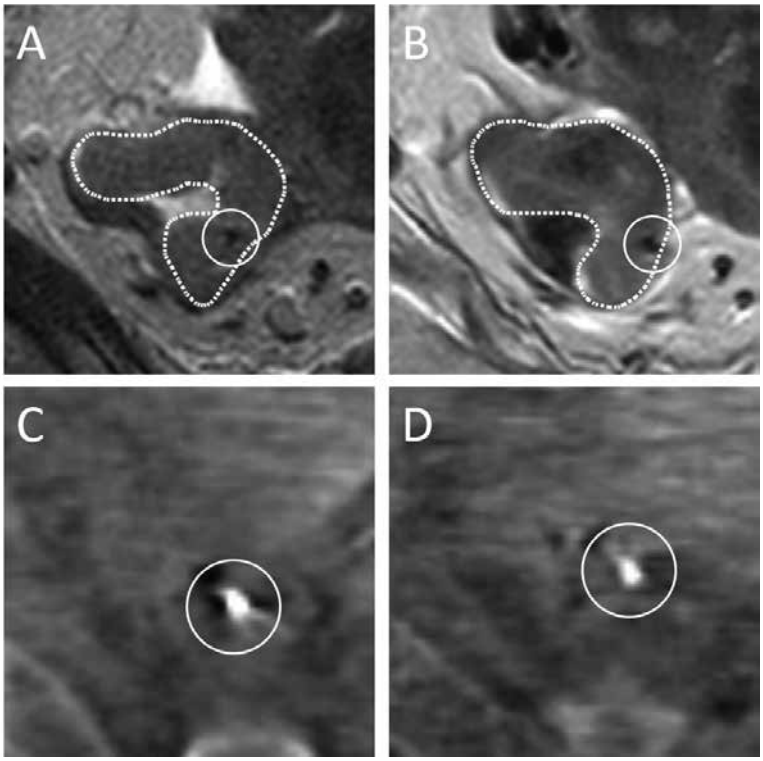


**Figure 1.** Examples of a GTV delineation and a fiducial on the T2-TSE sequence of both MRI exams (A and B) and the same fiducial on two pre-irradiation CBCT scans (C and D) for patient 19.

For the interfraction $COG_{GTV}$ displacement relative to bony anatomy, the systematic error was 3.0 mm (LR), 8.7 mm (AP) and 9.4 mm (CC) for patients with a tumor in the mid- and upper rectum, while it was 1.3 mm (LR), 4.7 mm (AP) and 4.9 mm (CC) for patients with a tumor in the lower rectum. Similarly, for the interfraction fiducial displacement relative to bony anatomy on CBCT, systematic and random errors were 3.8 and 3.4 mm (LR), 6.1 and 5.1 mm (AP) and 5.5 and 5.6 mm (CC) for the mid- and upper group and 3.1 and 1.1 mm (LR), 1.6 and 2.3 mm (AP) and 2.8 and 2.9 mm (CC) for the lower rectum group. The standard deviation of the interfraction fiducial displacements relative to bony anatomy was significantly higher for patients with a tumor in the mid- and upper rectum compared to patients with a tumor in the lower rectum in the LR ($p<0.01$), AP ($p=0.03$) and CC ($p=0.04$) direction. An overview of the inter- and intrafraction fiducial displacements relative to bony anatomy split according to tumor location is shown in Figure 2 and Figure 3.

Systematic and random errors of the intrafraction fiducial displacement relative to bony anatomy were ≤2.1 mm in all directions.

## Setup correction scenarios

For setup correction based on bony anatomy, the estimated margins were 8.3 mm (LR), 19.5 mm (AP) and 21.9 mm (CC) using the $COG_{GTV}$ displacement relative to bony anatomy, and 11.3 mm (LR), 15.7 mm (AP) and 15.8 mm (CC) using the fiducial displacement relative to bony anatomy (Table 3). For setup correction based on fiducials, a reduction to 8.3 mm (LR and AP) and 12.8 mm (CC) was observed. Setup correction based on a direct visualization of the GTV would further reduce required margins to 3.0 mm (LR), 4.7 mm (AP) and 5.5 mm (CC).

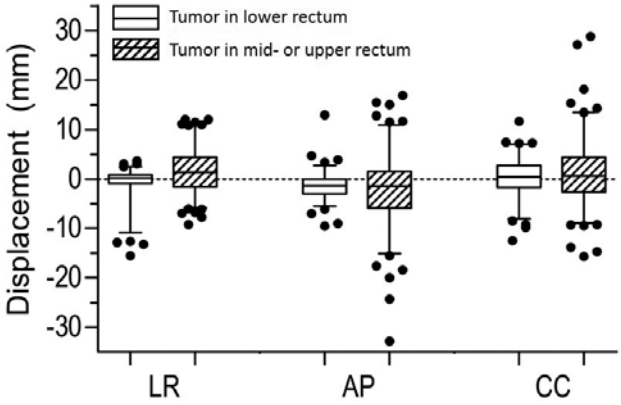


**Figure 2.** Boxplots of the interfraction fiducial displacements relative to bony anatomy on CBCT in the LR, AP and CC direction, split according to tumor location.

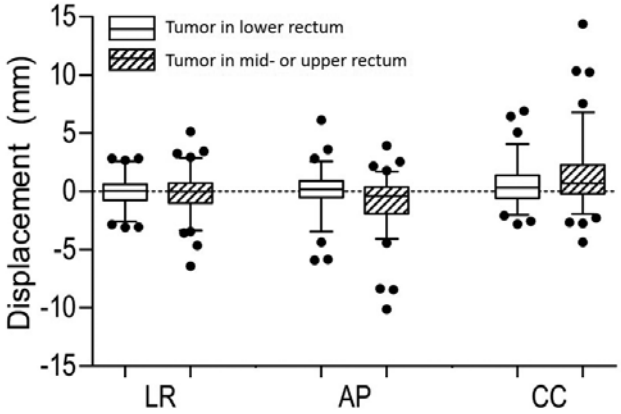


**Figure 3.** Boxplots of the intrafraction fiducial displacements relative to bony anatomy on CBCT in the LR, AP and CC direction, split according to tumor location.

**Table 3.** Systematic error, random error and corresponding margin for different setup correction scenarios

| | | LR (mm) | AP (mm) | CC (mm) |
|---|---|---|---|---|
| Setup correction based on bony anatomy ($COG_{GTV}$ MRI data) | Σ | 2.9 | 7.3 | 8.2 |
| | σ | 1.4 | 1.7 | 2.1 |
| | **Margin** | 8.3 | 19.5 | 21.9 |
| Setup correction based on bony anatomy (fiducial CBCT data) | Σ | 3.7 | 5.0 | 4.9 |
| | σ | 3.0 | 4.5 | 5.1 |
| | **Margin** | 11.3 | 15.7 | 15.8 |
| Setup correction based on fiducials | Σ | 2.9 | 2.8 | 4.5 |
| | σ | 1.5 | 1.9 | 2.3 |
| | **Margin** | 8.3 | 8.3 | 12.8 |
| Setup correction based on GTV | Σ | 0.8 | 1.4 | 1.6 |
| | σ | 1.4 | 1.7 | 2.1 |
| | **Margin** | 3.0 | 4.7 | 5.5 |

LR = left-right, AP = anterior-posterior, CC = craniocaudal, Σ = systematic error, σ = random error

# DISCUSSION

The aim of this study was to evaluate the feasibility of fiducials as a surrogate for GTV position in rectal cancer. Despite fiducial displacement relative to the $COG_{GTV}$, an advantage for fiducial setup correction was observed in the AP and CC direction compared to bony anatomy setup correction. Consequently, the use of fiducials in a GTV boost setting allows for more precise irradiation of the GTV and sparing of organs at risk. More organ motion of the proximal rectum compared to the distal rectum is reported [33–35]. Although only a small number of patients were included in our study, a similar difference was observed. This suggests that the advantage of setup correction based on fiducials may be larger in patients with a proximal tumor.

The interfraction systematic error of the $COG_{GTV}$ relative to bony anatomy, as based on MRI, was substantially larger than the systematic and random errors of the fiducial displacements on CBCT. This is mainly due to large displacement of the $COG_{GTV}$ in two patients on MRI and may be explained by the absence of patient preparation before the MRI exams. For the calculation of the displacement of the $COG_{FID}$ as a result of changes in fiducial configuration, the $COG_{FID}$ was used as a reference point, assuming that all fiducials contributed equally to changes in fiducial configuration.

There is an inherent inaccuracy in determining exact fiducial locations on MRI, for instance due to the asymmetrical artifacts of the fiducials [36]. With help of the other available sequences, we delineated the fiducials on the tT2-TSE scan as it had the smallest artifacts [27]. Therefore, we believe that the inaccuracy in selecting the exact fiducial location has a minor effect on the observed fiducial displacements on MRI.

In the last two decades, organ motion in rectal cancer patients has been actively investigated and most studies focus on the movement of the clinical target volume (CTV) relative to bony anatomy [11,33,34,37–39]. Only a few papers have investigated the position variability of the GTV to determine the required margins for a GTV boost. Kleijnen *et al.* studied the motion of the rectum and GTV based on repeated MRI data [40–42]. They evaluated the intra- and interfraction displacement of the GTV relative to bony anatomy on time intervals of 1 minute, 9.5 minutes, 18 minutes and 1-4 days using daily MRI exams in 16 patients. They report a required margin of around 8 mm in all directions for both the 9.5 minute and 1-4 days timepoints [33]. However, a direct comparison is difficult since they used a different method to calculate the displacements and corresponding margins and they did not report the tumor location for each patient.

Furthermore, Kleijnen *et al.* report that although setup errors based on the rectal wall were slightly reduced compared to bony anatomy, a similar PTV margin was found. More importantly, the rectal wall could not be used as a surrogate for the GTV position, because displacement of the rectal wall and the GTV along the direction of the rectal wall will not be detected due to the absence of anatomical landmarks on the rectal wall [41]. They conclude that in order to further reduce uncertainties in a GTV boost setting, direct or indirect online tumor visualization is needed. In our study, we have shown that fiducials as an indirect visualization of the GTV reduces uncertainties. However, an uncertainty of the GTV position relative to the fiducials remains.

The suggested margins for setup correction based on bony anatomy as reported by Kleijnen *et al.* [42] are lower than those in our study, especially in the AP direction. However, a direct comparison is difficult since they did not report on the tumor location and intrafraction displacement of the tumor. Brierley *et al.* assessed the interfraction displacement of the rectum, mesorectum and GTV relative to bony anatomy [35]. They found that the GTV displacement was greatest in the CC direction, which is confirmed by the results in our study.

A limitation of the use of fiducials might be the low retention rate. In our study, a total of 64 fiducials were inserted, of which 35 fiducials were still in situ at the end of radiotherapy [24]. Furthermore, the insertion of fiducials is an invasive procedure. Previous studies on fiducial insertion in the rectum report no serious adverse events [22,24,25]. In one study, a small amount of bleeding that resolved spontaneously was reported in one out of 54 patients [23].

A limitation of this study is the small number of patients. Therefore, the determined margins and the observed difference between proximal and distal tumors would need confirmation in a larger study. As only 3 fiducials in the mesorectum were identified on both MRI exams, no conclusions can be drawn about fiducial displacement with respect to the tumor between fiducials implanted in the tumor and the mesorectum. Furthermore, we evaluated the displacement of the fiducials relative to the GTV only for the first week of radiotherapy. If fiducials would be used for the full duration of a long-course radiotherapy schedule, the displacement of the fiducials relative to the GTV should be investigated for all five weeks. Because of logistical reasons, the time between the MRI exams differed between patients. However, the difference is mainly due to the time range of the first MRI exam relative to the start of radiotherapy. Finally, the estimated margins presented in this paper are based on the position of the fiducials and GTV and do not include other remaining errors involved in the treatment process.

## CONCLUSIONS

The results of this study show that despite the observed fiducial displacement relative to the GTV, the use of fiducials as a surrogate for GTV position reduces required margins in the AP and CC direction for a GTV boost using image-guided radiotherapy of rectal cancer. The reduction of required margins may be higher in patients with a proximal compared to a distal tumor. However, this needs to be confirmed in a larger study.

# REFERENCES


1. Van Gijn W, Marijnen CAM, Nagtegaal ID, Kranenbarg EMK, Putter H, Wiggers T, *et al.* Preoperative radiotherapy combined with total mesorectal excision for resectable rectal cancer: 12-year follow-up of the multicentre, randomised controlled TME trial. *Lancet Oncol* 2011;12:575–82.
2. Bosset JF, Calais G, Mineur L, Maingon P, Stojanovic-Rundic S, Bensadoun RJ, *et al.* Fluorouracil-based adjuvant chemotherapy after preoperative chemoradiotherapy in rectal cancer: Long-term results of the EORTC 22921 randomised study. *Lancet Oncol* 2014;15:184–90.
3. Sauer R, Liersch T, Merkel S, Fietkau R, Hohenberger W, Hess C, *et al.* Preoperative versus postoperative chemoradiotherapy for locally advanced rectal cancer: Results of the German CAO/ARO/AIO-94 randomized phase III trial after a median follow-up of 11 years. *J Clin Oncol* 2012;30:1926–33.
4. Sebag-Montefiore D, Stephens RJ, Steele R, Monson J, Grieve R, Khanna S, *et al.* Preoperative radiotherapy versus selective postoperative chemoradiotherapy in patients with rectal cancer (MRC CR07 and NCIC-CTG C016): a multicentre, randomised trial. *Lancet* 2009;373:811–20.
5. Maas M, Nelemans PJ, Valentini V, Das P, Rödel C, Kuo LJ, *et al.* Long-term outcome in patients with a pathological complete response after chemoradiation for rectal cancer: A pooled analysis of individual patient data. *Lancet Oncol* 2010;11:835–44.
6. Sanghera P, Wong DWY, McConkey CC, Geh JI, Hartley A. Chemoradiotherapy for Rectal Cancer: An Updated Analysis of Factors Affecting Pathological Response. *Clin Oncol* 2008;20:176–83.
7. Appelt AL, Ploen J, Vogelius IR, Bentzen SM, Jakobsen A. Radiation dose-response model for locally advanced rectal cancer after preoperative chemoradiation therapy. *Int J Radiat Oncol Biol Phys* 2013;85:74–80.
8. Hall MD, Schultheiss TE, Smith DD, Fakih MG, Wong JYC, Chen YJ. Effect of increasing radiation dose on pathologic complete response in rectal cancer patients treated with neoadjuvant chemoradiation therapy. *Acta Oncol (Madr)* 2016;55:1392–9.
9. Ortholan C, Romestaing P, Chapet O, Gerard JP. Correlation in rectal cancer between clinical tumor response after neoadjuvant radiotherapy and sphincter or organ preservation: 10-year results of the Lyon R 96-02 randomized trial. *Int J Radiat Oncol Biol Phys* 2012;83.
10. Burbach JPM, Den Harder AM, Intven M, Van Vulpen M, Verkooijen HM, Reerink O. Impact of radiotherapy boost on pathological complete response in patients with locally advanced rectal cancer: A systematic review and meta-analysis. *Radiother Oncol* 2014;113:1–9.
11. Nijkamp J, de Jong R, Sonke JJ, Remeijer P, van Vliet C, Marijnen C. Target volume shape variation during hypo-fractionated preoperative irradiation of rectal cancer patients. *Radiother Oncol* 2009;92:202–9.
12. Vestermark LW, Jacobsen A, Qvortrup C, Hansen F, Bisgaard C, Baatrup G, *et al.* Long-term results of a phase II trial of high-dose radiotherapy (60 Gy) and UFT/l-leucovorin in patients with non-resectable locally advanced rectal cancer (LARC). *Acta Oncol (Madr)* 2008;47:428–33.
13. Seierstad T, Hole KH, Sælen E, Ree AH, Flatmark K, Malinen E. MR-guided simultaneous integrated boost in preoperative radiotherapy of locally advanced rectal cancer following neoadjuvant chemotherapy. *Radiother Oncol* 2009;93:279–84.
14. Mohiuddin M, Paulus R, Mitchell E, Hanna N, Yuen A, Nichols R, *et al.* Neoadjuvant chemoradiation for distal rectal cancer: 5-year updated results of a randomized phase 2 study of neoadjuvant combined modality chemoradiation for distal rectal cancer. *Int J Radiat Oncol Biol Phys* 2013;86:523–8.

15. Engineer R, Mohandas KM, Shukla PJ, Shrikhande S V., Mahantshetty U, Chopra S, *et al.* Escalated radiation dose alone vs. concurrent chemoradiation for locally advanced and unresectable rectal cancers: Results from phase II randomized study. *Int J Colorectal Dis* 2013;28:959–66.

16. Burbach JM, Verkooijen HM, Intven M, Kleijnen J-PPJEJ, Bosman ME, Raaymakers BW, *et al.* RandomizEd controlled trial for pre-operAtive dose-escaLation BOOST in locally advanced rectal cancer (RECTAL BOOST study): study protocol for a randomized controlled trial. *Trials* 2015;16:58.

17. Tan J, Lim Joon D, Fitt G, Wada M, Lim Joon M, Mercuri A, *et al.* The utility of multimodality imaging with CT and MRI in defining rectal tumour volumes for radiotherapy treatment planning: A pilot study. *J Med Imaging Radiat Oncol* 2010;54:562–8.

18. Oelfke U. Magnetic Resonance Imaging-guided Radiation Therapy: Technological Innovation Provides a New Vision of Radiation Oncology Practice. *Clin Oncol* 2015;27:495–7.

19. Van Der Horst A, Wognum S, Dávila Fajardo R, De Jong R, Van Hooft JE, Fockens P, *et al.* Interfractional position variation of pancreatic tumors quantified using intratumoral fiducial markers and daily cone beam computed tomography. *Int J Radiat Oncol Biol Phys* 2013;87:202–8.

20. Jin P, van der Horst A, de Jong R, van Hooft JE, Kamphuis M, van Wieringen N, *et al.* Marker-based quantification of interfractional tumor position variation and the use of markers for setup verification in radiation therapy for esophageal cancer. *Radiother Oncol* 2015;117:412–8.

21. Beltran C, Herman MG, Davis BJ. Planning Target Margin Calculations for Prostate Radiotherapy Based on Intrafraction and Interfraction Motion Using Four Localization Methods. *Int J Radiat Oncol Biol Phys* 2008;70:289–95.

22. Moningi S, Walker AJ, Malayeri AA, Rosati LM, Gearhart SL, Efron JE, *et al.* Analysis of fiducials implanted during EUS for patients with localized rectal cancer receiving high-dose rate endorectal brachytherapy. *Gastrointest Endosc* 2015;81:765–9.

23. Dhadham GC, Hoffe S, Harris CL, Klapman JB. Endoscopic ultrasound-guided fiducial marker placement for image-guided radiation therapy without fluoroscopy: safety and technical feasibility. *Endosc Int Open* 2016;4:E378-82.

24. Rigter LS, Rijkmans EC, Inderson A, van den Ende RPJ, Kerkhof EM, Ketelaars M, *et al.* EUS-guided fiducial marker placement for radiotherapy in rectal cancer: feasibility of two placement strategies and four fiducial types. *Endosc Int Open* 2019;07:E1357–64.

25. Vorwerk H, Liersch T, Rothe H, Ghadimi M, Christiansen H, Hess CF, *et al.* Gold markers for tumor localization and target volume delineation in radiotherapy for rectal cancer. *Strahlentherapie Und Onkol* 2009;185:127–33.

26. Dutch Trial Registry; registration no. NL4473. Accessed September 16, 2019.

27. van den Ende RPJ, Rigter LS, Kerkhof EM, van Persijn van Meerten EL, Rijkmans EC, Lambregts DMJ, *et al.* MRI visibility of gold fiducial markers for image-guided radiotherapy of rectal cancer. *Radiother Oncol* 2019;132:93–9.

28. Klein S, Staring M, Murphy K, Viergever MA, Pluim JPW. Elastix: A toolbox for intensity-based medical image registration. *IEEE Trans Med Imaging* 2010;29:196–205.

29. Van Herk M. Errors and Margins in Radiotherapy. *Semin Radiat Oncol* 2004;14:52–64.

30. Salerno G, Sinnatamby C, Branagan G, Daniels IR, Heald RJ, Moran BJ. Defining the rectum: surgically, radiologically and anatomically. *Colorectal Dis* 2006;8 Suppl 3:5–9.

31. Van Herk M, Remeijer P, Rasch C, Lebesque J V. The probability of correct target dosage: Dose-population histograms for deriving treatment margins in radiotherapy. *Int J Radiat Oncol Biol Phys* 2000;47:1121–35.

32. Nijkamp J, Swellengrebel M, Hollmann B, De Jong R, Marijnen C, Van Vliet-Vroegindeweij C, *et al.* Repeat CT assessed CTV variation and PTV margins for short- and long-course pre-operative RT of rectal cancer. *Radiother Oncol* 2012;102:399–405.

33. Chong I, Hawkins M, Hansen V, Thomas K, McNair H, O'Neill B, *et al.* Quantification of organ motion during chemoradiotherapy of rectal cancer using cone-beam computed tomography. *Int J Radiat Oncol Biol Phys* 2011;81:431–8.

34. Brierley JD, Dawson LA, Sampson E, Bayley A, Scott S, Moseley JL, *et al.* Rectal motion in patients receiving preoperative radiotherapy for carcinoma of the rectum. *Int J Radiat Oncol Biol Phys* 2011;80:97–102.

35. Gurney-Champion OJ, Lens E, Van Der Horst A, Houweling AC, Klaassen R, Van Hooft JE, *et al.* Visibility and artifacts of gold fiducial markers used for image guided radiation therapy of pancreatic cancer on MRI. *Med Phys* 2015;42:2638–47.

36. Nuyttens JJ, Robertson JM, Yan D, Martinez A. The variability of the clinical target volume for rectal cancer due to internal organ motion during adjuvant treatment. *Int J Radiat Oncol Biol Phys* 2002;53:497–503.

37. Raso R, Scalco E, Fiorino C, Broggi S, Cattaneo GM, Garelli S, *et al.* Assessment and clinical validation of margins for adaptive simultaneous integrated boost in neo-adjuvant radiochemotherapy for rectal cancer. *Phys Medica* 2015;31:167–72.

38. Daly ME, Murphy JD, Mok E, Christman-Skieller C, Koong AC, Chang DT. Rectal and bladder deformation and displacement during preoperative radiotherapy for rectal cancer: Are current margin guidelines adequate for conformal therapy? *Pract Radiat Oncol* 2011;1:85–94.

39. Kleijnen J-PJE, van Asselen B, Burbach JPM, Intven M, Philippens MEP, Reerink O, *et al.* Evolution of motion uncertainty in rectal cancer: implications for adaptive radiotherapy. *Phys Med Biol* 2016;61:1–11.

40. Kleijnen J-PJE, van Asselen B, Intven M, Burbach JPM, Philippens MEP, Lagendijk JJW, *et al.* Does setup on rectal wall improve rectal cancer boost radiotherapy? *Radiat Oncol* 2018;13:61.

41. Kleijnen J-PJE, van Asselen B, Van den Begin R, Intven M, Burbach JPM, Reerink O, *et al.* MRI-based tumor inter-fraction motion statistics for rectal cancer boost radiotherapy. *Acta Oncol (Madr)* 2019;58:232–6.