



Universiteit  
Leiden  
The Netherlands

## **Management of (traumatic) anterior shoulder instability: current treatment and future perspectives The open Bankart procedure still state of the art in 2020**

Berendes, T.D.

### **Citation**

Berendes, T. D. (2020, September 23). *Management of (traumatic) anterior shoulder instability: current treatment and future perspectives The open Bankart procedure still state of the art in 2020*. Retrieved from <https://hdl.handle.net/1887/136943>

Version: Publisher's Version

License: [Licence agreement concerning inclusion of doctoral thesis in the Institutional Repository of the University of Leiden](#)

Downloaded from: <https://hdl.handle.net/1887/136943>

**Note:** To cite this publication please use the final published version (if applicable).

Cover Page



Universiteit Leiden



The handle <http://hdl.handle.net/1887/136943> holds various files of this Leiden University dissertation.

**Author:** Berendes, T.D.

**Title:** Management of (traumatic) anterior shoulder instability: current treatment and future perspectives The open Bankart procedure still state of the art in 2020

**Issue Date:** 2020-09-23

6

# Chapter 6

---

## The open-modified Bankart procedure: a 16–26 years follow-up study

Thomas Berendes · Nina Mathijssen · Hennie Verburg · Gerald Kraan

*Arch Orthop Trauma Surg. 2018;138(5):597-603*

## Abstract

**Introduction:** A Bankart procedure is a surgical technique for the repair of recurrent shoulder joint dislocations. This study reports the long-term results of the open-modified Bankart procedure.

**Methods:** We performed a retrospective cohort study in which patients were included who had open-modified Bankart surgery for posttraumatic instability problems of their shoulder in the absence of a substantial osseous glenoid defect, 16–26 years ago. Instability was measured with the Rowe and Oxford shoulder instability score. Furthermore, we measured physical functioning with the Constant–Murley score and the Dutch simple shoulder test. Pain was measured with the NRS for pain. Osteoarthritis was scored according the Samilson–Prieto score. Quality of life was measured with the SF-12 score. The operated shoulder was compared to the non-operated contralateral shoulder regarding instability and osteoarthritis.

**Results:** 39 patients were included with an average follow-up of 21 years (range 16–26 years). The number of patients with redislocations of their shoulder after surgery was 4 (10%). 23% of the study group described moments of subluxation or positive apprehension. Radiological signs of osteoarthritis were present in 20 shoulders (51%), of which 75% had grade 1 arthropathy according to the Samilson Prieto score. The incidence of osteoarthritis of the operated shoulder was significantly greater compared to the non-operated shoulder. The mean Rowe score was 85 points (25–100) and the Constant score 92 points (70–100).

**Conclusion:** We conclude that the open-modified Bankart procedure is a reliable surgical procedure with good long-term results, 16–26 years after surgery. However, it does not prevent the development of shoulder osteoarthritis, since a high number of patients had (mainly mild) radiological osteoarthritis.

**Keywords:** Shoulder · Joint instability · Surgery · Osteoarthritis

## Introduction

Dislocation of the glenohumeral joint in anterior direction is the most common dislocation in human joints with a reported incidence of 1–2% in the general population.<sup>1–12</sup>

The recurrence rate after an acute first-time anterior shoulder dislocation (AFASD) in young patients under 20 years of age is high and reported up to 90%.<sup>1–12</sup> In patients older than 40 years, the incidence significantly drops to 10–15%.<sup>3,13</sup> The majority of all recurrences occur within the first 2 years after the primary dislocation.<sup>2,14–17</sup> The best treatment of AFASD in young patients remains a debated issue. Nowadays, a wide variety of pathologic entities has been described in association with shoulder instability, and many therapeutic strategies have been developed to address these. In young patients with recurrent dislocations or in selected patients who are active in sports, surgical treatment is propagated.<sup>18</sup> In the Netherlands, the operation of choice for this instability problem is until recently most often the Bankart repair.<sup>19</sup>

In our hospital (Reinier de Graaf, Delft, the Netherlands), the introduction of the open-modified Bankart-stabilizing procedure started in 1989 and was always carried out in the same way by two senior orthopedic surgeons. A mid-term follow-up study (10–15 years) for the same cohort of patients was previously been published in 2007.<sup>20</sup> Several other studies on the long-term outcome of the Bankart procedure have already been reported in literature.<sup>21–24</sup> They all had reliable results in restoring shoulder stability, demonstrated low rates of recurrent instability, dislocation, and reoperation. However, it seems that the procedure does not prevent the development of shoulder osteoarthritis. Therefore, further investigation is needed to assess the impact of Bankart procedures on the development of long-term osteoarthritis. Our current research focusses on the long-term results regarding stability and osteoarthritis at time of final follow-up, with a minimum follow-up of 16 years after surgery.

The goal of this study was to compare the results regarding stability, function, and osteoarthritis of the operated shoulder with the contralateral shoulder. Following the good results in 2007, it was hypothesized that patients had a restored shoulder joint stability and that the redislocation rate would be low. However, we expected to see an increase of radiological osteoarthritis.

## Patients and methods

All patients operated on between January 1989 and January 2004 for stabilization of the shoulder with the open-modified Bankart technique were screened for participation in the study. The indication had to be persisting instability after *traumatic* anterior luxation of the shoulder in the absence of a substantial osseous glenoid defect. To be eligible to

participate in this study, a subject had to be 18 years or older. Subjects had to be willing and to be able to participate the current study and they had to speak and write the Dutch language. Patients who had previous surgery on their affected shoulder or had surgery on their contralateral shoulder were excluded for this study.

All included patients visited the hospital for physical and radiological examination. Physical examination was being carried out by two objective examiners. Standardized physical examination was performed including two validated clinician-based outcome measurements, being the Rowe shoulder score, also known as rating sheet for Bankart repair and the score of Constant and Murley.<sup>24-27</sup> In the Rowe scoring system, stability, range of movement, and shoulder function are assessed. The Constant-Murley shoulder score is a shoulder-specific outcome scoring system that assesses pain, activities of daily living, range of motion (abduction, anteflexion, internal, and external rotation), and power.<sup>26,27</sup> We used a Hand-held dynamometer to measure muscle strength.

Furthermore, two shoulder-related patient reported outcome measures (PROM's) were completed by the patient: the Oxford shoulder instability score (OSIS) and the Dutch simple shoulder test (DSST).<sup>28-30</sup> The Oxford instability score is a shoulder-specific, condition-specific, patient-based outcome measure that uses a 12-item questionnaire in which each question has five-graded responses. It addresses symptoms of instability, pain, and activities of daily living, with the overall score being obtained as the arithmetic sum of each graded response without any need for further calculation. The Dutch Simple shoulder test assesses post-operative function by means of 12 questions with yes or no answers. Furthermore, pain was scored using the Numeric Pain Rating Scale Instructions (NRS) and quality of life was measured using the 12-Item Short Form Health Survey (SF-12).<sup>31</sup> The SF-12 score provides glimpses into the mental and physical functioning and overall health-related-quality of life of our patient group. The mean outcome scores of the 12-Item Short Form Health Survey (SF12) for our study group are expressed in terms of two meta-scores, divided into the physical component summary (PCS) and the mental component summary (MCS).

Radiological evaluation was performed by one objective examiner using the classification system of Samilson and Prieto.<sup>32</sup> True internal and external rotation views, as well as an axillary view, were taken of both shoulders. The results of the operated shoulder regarding stability, function, and osteoarthritis were compared to the results of the contralateral shoulder. To calculate the sample size, data from the study of Pelet and Fabre et al. were used.<sup>23,33</sup> They determined the Rowe score for instability of the shoulder after surgery with the open-modified Bankart procedure. The mean Rowe score of the operated shoulder was 80.0 and the mean Rowe score of the non-operated shoulder was 99.8. Standard deviation was 23. Using power of 90% and alpha of 0.05, the required sample size was 29 patients per group.

This study has been approved by the local Medical Ethics Committee (NL52656.098.15. METC ZWH nr: 15-024) and all patients gave written informed consent.

### **Operative technique**

The patient is under general anesthesia in a beach-chair position. Deltopectoral approach. The subscapularis tendon is incised vertically, approximately 1.5 cm medial to its insertion, leaving the inferior part intact. The capsule is incised vertically on the lateral side. A T-shaped capsular opening is created, raising a superior and an inferior capsular flap. The cortical layer of the glenoid rim is roughened with an osteotome to expose parts of bleeding cancellous bone.

Three-to-four holes for bone anchors are made on the edge of the glenoid. Mitek I and later Mitek II (DePuy Mitek, Raynham, Massachusetts) anchors were used. The labrum (or its remnants) and the medial capsular flap is then reattached to the glenoid and the rotator interval closed. The two capsular flaps are then shifted, the superior flap inferiorly and the inferior flap superiorly, until it is sufficiently tight. The arm is held in neutral rotation and in abduction of approximately 30° during this manoeuvre. Finally, two additional sutures are placed between the two capsular flaps to close the horizontal T incision of the repair. The subscapularis muscle is reattached anatomically to its insertion. Post-operatively, the arm is placed in a shoulder immobilizer for 6 weeks.

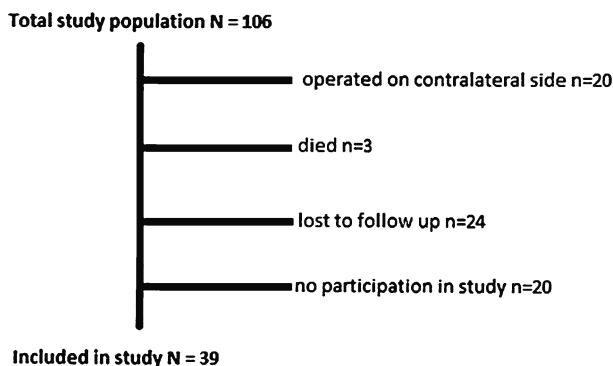
### **Statistical analysis**

Statistical analysis was performed using SPSS (version 22 for Windows, SPSS Inc., Chicago, Illinois). Simple cross-table analysis was used to quantify the relationship between discrete outcome variables, such as instability and osteoarthritis. To determine differences between the operated and the contralateral shoulder, we used the Chi-squared test or Fisher's exact test for the binary variables. In cases of paired binary data, we used the McNemar test and a paired *t*-test for mean differences.

## **Results**

106 patients were eligible for participation in this study of which 39 patients were included (Fig. 1). Median follow-up was 21 years (range 16–26 years). Most patients were male (32 out of 39, 82%) with an average age at time of operation of 31 years (range 18–47). Fourteen of the operations were on the dominant side (36%) and no complications were recorded.





**Fig. 1: Inclusion of patients.**

### **Post-operative glenohumeral osteoarthritis**

Twenty (51%) of the operated shoulders showed signs of osteoarthritis. Three (8%) of the contralateral shoulders showed signs of osteoarthritis (Table 1).

### **Stability**

Four patients (10%), all male, had encountered a redislocation after surgery. Two patients declared only a single redislocation. One patient stated four redislocations after surgery, all of which during sports activities (soccer and swimming). The other patient reported three redislocations, again all initiated during sport activities (soccer and volleyball). No redislocations were present in activities of daily living or at night in rest. All four patients also described moments of fear of subluxation in upper movements, especially during sports activity. Another five patients, together 23% of the study group described moments of subluxation, again mostly during sports activity. For all above-mentioned patients, their instability feelings disappeared after stopping their sports activities.

We compared the unstable group with the stable group, regarding Constant score, oxford and Dutch simple shoulder test for the operated side. No differences in constant score could be found ( $p = 0.642$ ;  $p = 0.050$ ; and  $p = 0.250$ , respectively). The Rowe score was different between these groups ( $p = 0.005$ ). The incidence of osteoarthritis between these groups was comparable ( $p = 0.327$ ). All tests are performed with a Mann-Whitney U test. The incidence of OA between groups was tested with a Chi-squared test.

### **Shoulder scores**

The mean Rowe score of the operated shoulder was 85 (range 25–100) and the mean Constant score for the operated side was 92 (range 70–100) (Table 1). The median Oxford shoulder instability score was 16 (range 11–31) and the median outcome of the Dutch simple shoulder test was 11 (range 7–12). The mean outcome scores of the

**Table 1: Osteoarthritis, Rowe and Constant-Murley score and NRS for pain and functional results**

	Operated shoulder	Contralateral shoulder	<i>p</i> -value
Osteoarthritis	20/39	3/39	<i>p</i> < 0.0001, McNemar test
Grade I	15/39	1/39	
Grade II	4/39	1/39	
Grade III	1/39	1/39	
Rowe score [mean (range) points]	85 (25-100)	97 (55-100)	0.002
Constant-Murley score [mean (range) points]	92 (70-100)	94 (82-100)	0.024
NRS pain (0/10) [mean (range) points]	1 (0-6)	0 (0-5)	0.071
External rotation [mean (range) ° in scapular plane]	70 (20-90)	80 (35-95)	< 0.001
Anteflexion [mean (range) ° in scapular plane]	176 (160-180)	177 (170-180)	0.096
Abduction [mean (range) ° in scapular plane]	175 (120-180)	178 (170-180)	0.090
Force [mean (range) kg]	16 (4-45)	16 (5-42)	0.483

SF-12 questionnaire for our study group divided into PCS SF-12 and MCS SF12 are, respectively, 42.5 (range 29–50) and 48.3 (range 31–58).

### Functional results

The mean external rotation (in the scapular plane) was 70° (range 20°–90°) for the operated side compared with 80° (range 35°–95°) on the contralateral non-operated side. We found a mean difference of 10° of external rotation in line of the scapula in favor of the non-operated side ( $p < 0.001$ ) (Table 1).

Twelve patients had a difference of 15° or more of external rotation in the scapular plane in the operated arm compared with the non-operated contralateral arm at time of follow-up. All patients had a minimum of 160° of anteflexion on the operated (and non-operated) arm. No patients had signs of diminished strength or atrophy of the shoulder muscle on the operated side (Table 1). No significant difference was found in external rotation in the scapular plane on the operated shoulders between two sub-groups of patients with versus without signs of osteoarthritis [mean external rotation 71 (range 20–90) versus 70 (35–90),  $p = 0.902$ ].

### Sport participation

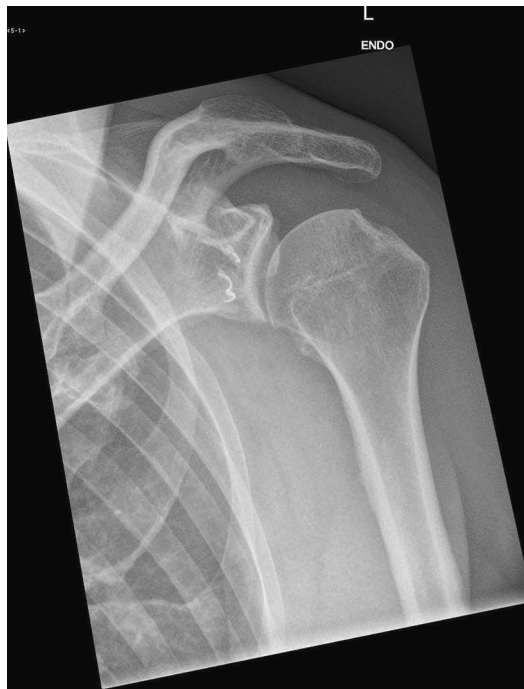None of the patients in this study were high-active or top sport athletes, both before and after the operation. At time of the final follow-up, ten patients (26%) did not participate

in sport activities, mostly for other reasons than their shoulder. Three patients (8%) stated stopping their sport (soccer) by reasons of their shoulder, one of which being a goalkeeper. Twenty-nine patients (74%) stated to do sport, all at recreative level, varying in overhead, contact to non-contact sports. Comparison of these two sub-groups (sport versus no sport at time of follow-up) showed no major differences regarding age, Rowe score ( $p = 0.530$ ) and Constant scores ( $p = 0.178$ ) and the presence of signs of osteoarthritis ( $p = 0.728$ ).

### Case presentations

Here, we present the X-ray of the operated left shoulder from a 42-year-old patient, 26 years after surgery, with three bone anchors in place (Fig. 2). You can see mild signs of glenohumeral arthrosis, rated grade 1 according to the Samilson and Prieto classification, with inferior humeral and/or glenoid exostosis < 3 mm in height.

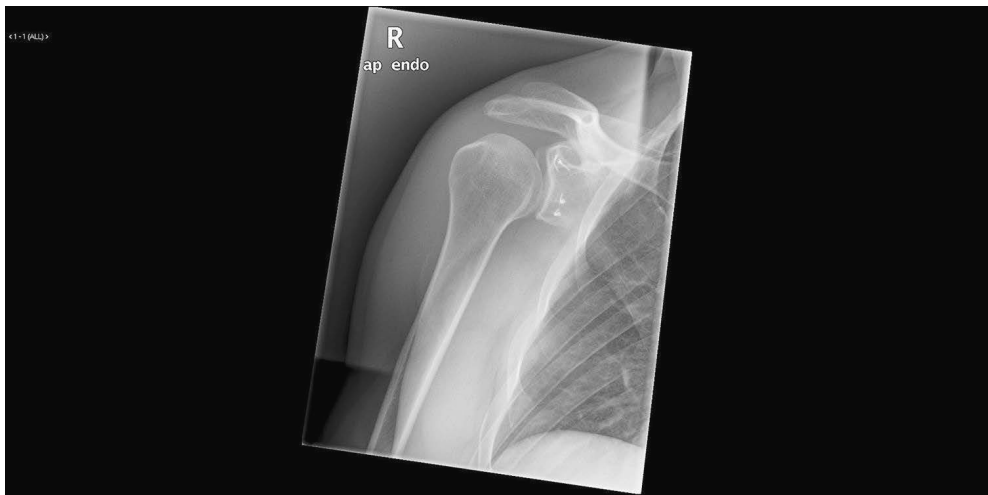No more dislocation or subluxations occurred after surgery with VAS scores for pain of 0 (in rest and for activity). At the final follow-up, the shoulder showed good functional outcome scores, with an exorotation of 70° (in 0° of abduction of the arm) versus 90° on his contralateral non-operated right shoulder. His sports activities at final time of follow-up were hockey, fitness, and skiing.



**Fig. 2:** X-ray of left shoulder with three bone anchors in place.

Another X-ray of a right shoulder is from another 57-year-old patient, 22 years after surgery, with four bone anchors in place (Fig. 3). Here, no signs of glenohumeral arthrosis are present.

Again, no dislocation or subluxations occurred after surgery with VAS scores for pain of 0 (in rest and for activity). At the final follow-up, the shoulder showed good functional outcome scores, with an exorotation of 80° (in 0° of abduction of the arm) versus 90° on his contralateral non-operated right shoulder. His sports activities at the final time of follow-up were running and skiing. Remarkable was that he luxated his non-operated left shoulder after surgery by a fall with skiing, while his operated right shoulder remained stable.



**Fig. 3: X-ray of right shoulder with four bone anchors in place.**

## Discussion

The purpose of this study was to describe the long-term results regarding stability and osteoarthritis 16–26 years after an open-modified Bankart procedure for persisting instability problems after AFASD. The Bankart lesion, or anterior labral detachment, is the most commonly recognized pathologic lesion of traumatic anterior instability. However, associated osseous deficiencies are also common, particularly in patients with recurrent instability or those with unsuccessful surgical stabilization. Osseous lesions may be present in up to 89% of failed stabilizations.<sup>34</sup> Until now, at least in the Netherlands, it is common to perform a reattachment procedure of the labral detachment possibly with a capsular procedure when no or only minor osseous defects are present.

Our study shows that the redislocation rate after the open-modified Bankart procedure is low, being 10% (4/39), 16–26 years after surgery, with an instability rate (dislocations and subluxations or positive apprehension) of 23% (9/39). This is in accordance with the long-term results of Pelet and Fabre with a mean follow-up of, respectively, 29 and 26 years.<sup>23,33</sup> In our earlier study (10–15 years follow-up), we had also a 10% (3/31) redislocation rate, with two redislocations after further trauma.<sup>20</sup> Therefore, in our study group of open-modified Bankart repairs, we do not see a decreasing effectiveness of the repair over time as in the study of Zimmermann in which he used an arthroscopic Bankart technique.<sup>35</sup> However, the definition of recurrence rate can be discussed. Whether a new dislocation after a severe trauma (i.e., contact sport) without any foregoing shoulder complaints occurring years after stabilization should be classified as a failure.<sup>20</sup> One can debate how we should define a failure after surgical treatment for anterior shoulder instability.<sup>36</sup> Subluxations are failures too, considering the fact that stable shoulder function is the purpose of treatment. The subjective experience of a shoulder subluxation or positive apprehension is very inconvenient and an adverse surgical outcome for patients. In addition, recurrent traumatic subluxation itself can be a reason for surgical treatment initially.<sup>36</sup>

Of course, one can also debate the term “acceptable outcome”, but comparing with the literature, a 10% redislocation rate and 23% instability rate (including redislocations and subluxations) at more than 16 years after surgery (16–26 year follow-up) is to our knowledge still not being recorded for the arthroscopic group. Again, a reference is being made to the high failure rate of the arthroscopic Bankart repairs in the study of Zimmermann.<sup>35</sup> Instability or positive apprehension persisted or recurred in his late study after a minimum of 6 years follow-up in 113 (42%) of the 271 arthroscopic Bankart procedures.

Our mid-term results showed already that the open-modified Bankart procedure did not prevent the development of shoulder osteoarthritis (OA), with a significant difference in the prevalence of OA on the operated side after dislocation of the shoulder compared with that on the contralateral, non-operated side.<sup>20</sup> For the operated side, we saw radiological signs of arthrosis in 10 out of 31 shoulders (32%), of which nine classified grade 1 and one grade 3 according the Samilson–Prieto classification. For the non-operated shoulders, only one patient showed signs of osteoarthritis (Samilson–Prieto grade 3). Our current study showed a higher rate of (meanly minor) OA in the operated group, being 51% ( $n = 20$  out of 39) versus OA of only 8% in the non-operated side in the same group. However, of those patients with arthropathy on the operated side, 15 patients (75%) had only minor signs of glenohumeral arthrosis (Samilson–Prieto stage I). Four shoulders were classified as grade 2 according the Samilson–Prieto classification and one shoulder grade 3. From this data, no certainty is given whether the stabilizing shoulder surgery itself is a potential contribution to the osteoarthritis process or the

(repetitive) chondral injuries sustained during the episodes of instability.<sup>37–44</sup> We did not see signs of functional loss in the group of OA in our study population comparing the non-OA group. The mean external rotation in the OA group was comparable to the mean external rotation in the non-OA group.

Our study had several limitations. This retrospective cohort study initially deals with people around the University city of Delft in The Netherlands. We do not know whether this will give a good reflection of the general Dutch population. This is probably a form of selection bias. However, we have no compared data with the rest of the population in The Netherlands.

Unfortunately, in our study, we see Attrition bias. It is a kind of selection bias caused by attrition (loss of participants) or dropouts. We had a high number of dropouts, with 24 patients being lost to follow-up, three patients died during the follow-up period and another 20 patients refused to participate with this study (not for reasons of their shoulder). Therefore, it gives biased results, where it is probably unequal in regard to outcome and results have to be interpreted with care.

However, we think that this study is of significant value because of its unique group of patients being operated on in the same manner by two senior orthopedic surgeons at a mean follow-up of 21 years (range 16–26 years). There is no management variation in patient pathways for AFASD in this cohort study, with a constant operative strategy through time. Thereby, we evaluated the patients included in the study in the same way compared with our earlier study in 2007, all with radiographic examination for both shoulders.<sup>20</sup> Our results of the open-modified Bankart procedure for traumatic anterior glenohumeral dislocations again showed that it is a safe and effective procedure with good long-term results. We think that it can serve as a golden standard for the nowadays frequently used arthroscopic procedures or the more osseous oriented reconstruction techniques.

In conclusion, the open-modified Bankart technique is a reliable surgical procedure with good long-term outcome, 16–26 years after surgery. However, it does not prevent the development of shoulder osteoarthritis, since a high number of patients had (mainly mild) radiological osteoarthritis.

## References

1. Moseley HF (1962) Recurrent dislocation of the shoulder. *Postgrad Med* 31:23–29. <http://www.ncbi.nlm.nih.gov/pub-med/14476433>. Accessed 27 Nov 2016
2. Rowe CR (1956) Prognosis in dislocations of the shoulder. *J Bone Jt Surg Am* 38-A(5):957–977
3. McLaughlin HL, MacLellan DI (1967) Recurrent anterior dislocation of the shoulder. II. A comparative study. *J Trauma* 7(2):191–201
4. Simonet WT, Cofield RH (2010) Prognosis in anterior shoulder dislocation. *Am J Sports Med* 12(1):19–24. <http://www.ncbi.nlm.nih.gov/pubmed/6703178>. Accessed 19 Sep 2010
5. Rowe CR, Sakellarides HT (1961) Factors related to recurrences of anterior dislocations of the shoulder. *Clin Orthop* 20:40–48. <http://www.ncbi.nlm.nih.gov/pubmed/13744116>. Accessed 27 Nov 2016
6. McLaughlin HL, Cavallaro WU (2016) Primary anterior dislocation of the shoulder. *Am J Surg* 80(6):615–621. <http://www.ncbi.nlm.nih.gov/pubmed/14790098>. Accessed 27 Nov 2016 (passim)
7. Hovelius L (1987) Anterior dislocation of the shoulder in teen-agers and young adults. Five-year prognosis. *J Bone Jt Surg Am* 69(3):393–399
8. Kiviluoto O, Pasila M, Jaroma H, Sundholm A (1980) Immobilization after primary dislocation of the shoulder. *Acta Orthop Scand* 51(6):915–919. <http://www.ncbi.nlm.nih.gov/pubmed/7211296>. Accessed 3 Jan 2014
9. Arciero RA, Wheeler JH, Ryan JB, McBride JT (1994) Arthroscopic Bankart repair versus nonoperative treatment for acute, initial anterior shoulder dislocations. *Am J Sport Med* 22(5):589–594
10. Henry JH, Genung JA (2010) Natural history of glenohumeral dislocation revisited. *Am J Sports Med* 10(3):135–137. <http://www.ncbi.nlm.nih.gov/pubmed/7114346>. Accessed 19 Sep 2010
11. Hovelius L, Augustini BG, Fredin H, Johansson O, Norlin R, Thorling J (1996) Primary anterior dislocation of the shoulder in young patients. A ten-year prospective study. *J Bone Jt Surg Am* 78(11):1677–1684
12. Wheeler JH, Ryan JB, Arciero RA, Molinari RN (1989) Arthroscopic versus nonoperative treatment of acute shoulder dislocations in young athletes. *Arthroscopy* 5(3):213–217
13. Rowe CR, Sakellarides HT (1961) Factors related to recurrences of anterior dislocations of the shoulder. *Clin Orthop* 20:40–48
14. Rowe CR (1978) Instabilities of the glenohumeral joint. *Bull Hosp Jt Dis* 39(2):180–186. <http://www.ncbi.nlm.nih.gov/pub-med/753446>. Accessed 27 Nov 2016
15. Townley CO (1950) The capsular mechanism in recurrent dislocation of the shoulder. *J Bone Jt Surg Am* 32A(2):370–380. <http://www.ncbi.nlm.nih.gov/pubmed/15412179>. Accessed 27 Nov 2016
16. Moseley HF (1963) The basic lesions of recurrent anterior dislocation. *Surg Clin N Am* 43:1631–1634. <http://www.ncbi.nlm.nih.gov/pubmed/14090212>. Accessed 27 Nov 2016
17. Adams JC (1948) Recurrent dislocation of the shoulder. *J Bone Jt Surg Br* 30B(1):26–38. <http://www.ncbi.nlm.nih.gov/pub-med/18864943>. Accessed 27 Nov 2016
18. Handoll HHG, Almaiyah MA, Rangan A (2004) Surgical versus non-surgical treatment for acute anterior shoulder dislocation. *Cochrane Database Syst Rev* 2004(1):CD004325. <https://doi.org/10.1002/14651858.CD004325.pub2>
19. Berendes TD, Pilot P, Nagels J, Vochteloo AJH, Nelissen RGHH (2015) Survey on the management of acute first-time anterior shoulder dislocation amongst Dutch public hospitals. *Arch Orthop Trauma Surg*. <https://doi.org/10.1007/s00402-015-2156-3>

20. Berendes TD, Wolterbeek R, Pilot P, Verburg H, te Slaa RL (2007) The open modified Bankart procedure: outcome at follow-up of 10 to 15 years. *J Bone Jt Surg Br* 89(8):1064–1068. <https://doi.org/10.1302/0301-620X.89B8.19280>
21. Chapnikoff D, Besson A, Chantelot C, Fontaine C, Migaud H, Duquenois A (2000) Bankart procedure: clinical and radio- logical long-term outcome. *Rev Chir Orthop Repar Appar Mot* 86(6): 558–565
22. Gill TJ, Micheli LJ, Gebhard F, Binder C (1997) Bankart repair for anterior instability of the shoulder. Long-term outcome. *J Bone Jt Surg Am* 79(6):850–857
23. Pelet S, Jolles BM, Farron A (2006) Bankart repair for recurrent anterior glenohumeral instability: results at twenty-nine years' follow-up. *J Shoulder Elb Surg* 15(2):203–207
24. Rowe CR, Patel D, Southmayd WW (1978) The Bankart procedure: a long-term end-result study. *J Bone Jt Surg Am* 60(1):1–16
25. Williams GN, Gangel TJ, Arciero RA, Uhorchak JM, Taylor DC (2016) Comparison of the single assessment numeric evaluation method and two shoulder rating scales. Outcomes measures after shoulder surgery. *Am J Sports Med* 27(2):214–221. <http://www.ncbi.nlm.nih.gov/pubmed/10102104>. Accessed 29 Apr 2016
26. Constant CR, Murley AH (1987) A clinical method of functional assessment of the shoulder. *Clin Orthop Relat Res* 214:160–164. <http://www.ncbi.nlm.nih.gov/pubmed/3791738>. Accessed 3 Feb 2016
27. Dawson J, Hill G, Fitzpatrick R, Carr A (2001) The benefits of using patient-based methods of assessment. Medium-term results of an observational study of shoulder surgery. *J Bone Jt Surg Br* 83(6):877–882
28. Dawson J, Fitzpatrick R, Carr A (1999) The assessment of shoulder instability. The development and validation of a questionnaire. *J Bone Jt Surg Br* 81(3):420–426
29. van der Linde JA, van Kampen DA, van Beers LWAH., van Deurzen DFF, Terwee CB, Willems WJ (2015) The Oxford Shoulder Instability Score; validation in Dutch and first-time assessment of its smallest detectable change. *J Orthop Surg Res* 10:146. <https://doi.org/10.1186/s13018-015-0286-5>
30. Constant CR, Murley AH (1987) A clinical method of functional assessment of the shoulder. *Clin Orthop Relat Res* 214:160–164
31. Ware J, Kosinski M, Keller SD (1996) A 12-Item Short-Form Health Survey: construction of scales and preliminary tests of reliability and validity. *Med Care* 34(3):220–233. <http://www.ncbi.nlm.nih.gov/pubmed/8628042>. Accessed 21 July 2016
32. Samilson RL, Prieto V (1983) Dislocation arthropathy of the shoulder. *J Bone Jt Surg Am* 65(4):456–460
33. Fabre T, Abi-Chahla ML, Billaud A, Geneste M, Durandeau A (2010) Long-term results with Bankart procedure: a 26-year follow-up study of 50 cases. *J Shoulder Elb Surg* 19(2):318–323. <https://doi.org/10.1016/j.jse.2009.06.010>
34. Schrupf MA, Maak TG, Delos D et al (2014) The management of anterior glenohumeral instability with and without bone loss: AAOS exhibit selection. *J Bone Joint Surg Am* 96(2):e12. <https://doi.org/10.2106/JBJS.L.01377>
35. Zimmermann SM, Scheyerer MJ, Farshad M, Catanzaro S, Rahm S, Gerber C (2016) Long-term restoration of anterior shoulder stability: a retrospective analysis of arthroscopic Bankart repair versus open Latarjet procedure. *J Bone Jt Surg Am* 98(23):1954–1961. <https://doi.org/10.2106/JBJS.15.01398>
36. van der Linde JA, van Kampen DA, Willems JW (2013) How should we define failure after surgical shoulder stabilization? *Arthroscopy* 29(10):1602. <https://doi.org/10.1016/j.arthro.2013.08.008>



37. Rosenberg BN, Richmond JC, Levine WN (1995) Long-term follow-up of Bankart reconstruction. Incidence of late degenerative glenohumeral arthrosis. *Am J Sport Med* 23(5):538–544
38. Cameron ML, Kocher MS, Briggs KK, Horan MP, Hawkins RJ (2003) The prevalence of glenohumeral osteoarthritis in unstable shoulders. *Am J Sport Med* 31(1):53–55
39. Hawkins RJ, Angelo RL (1990) Glenohumeral osteoarthritis. A late complication of the Putti-Platt repair. *J Bone Jt Surg Am* 72(8):1193–1197
40. Morrey BF, Janes JM (1976) Recurrent anterior dislocation of the shoulder. Long-term follow-up of the Putti-Platt and Bankart procedures. *J Bone Jt Surg Am* 58(2):252–256
41. O'Driscoll SW, Evans DC (1993) Long-term results of staple capsulorrhaphy for anterior instability of the shoulder. *J Bone Jt Surg Am* 75(2):249–258
42. Trevlyn DW (1992) Degenerative joint disease following extracapsular anterior shoulder reconstruction. *Contemp Orthop* 25:151–156
43. Zuckerman JD, Matsen 3rd FA (1984) Complications about the glenohumeral joint related to the use of screws and staples. *J Bone Jt Surg Am* 66(2):175–180
44. Saxena V, D'Aquila K, Maroon S et al (2016) T1ρ magnetic resonance imaging to assess cartilage damage after primary shoulder dislocation. *Am J Sports Med*. <https://doi.org/10.1177/0363546516655338>

