



Universiteit
Leiden
The Netherlands

Management of (traumatic) anterior shoulder instability: current treatment and future perspectives The open Bankart procedure still state of the art in 2020

Berendes, T.D.

Citation

Berendes, T. D. (2020, September 23). *Management of (traumatic) anterior shoulder instability: current treatment and future perspectives The open Bankart procedure still state of the art in 2020*. Retrieved from <https://hdl.handle.net/1887/136943>

Version: Publisher's Version

License: [Licence agreement concerning inclusion of doctoral thesis in the Institutional Repository of the University of Leiden](#)

Downloaded from: <https://hdl.handle.net/1887/136943>

Note: To cite this publication please use the final published version (if applicable).

Cover Page



Universiteit Leiden



The handle <http://hdl.handle.net/1887/136943> holds various files of this Leiden University dissertation.

Author: Berendes, T.D.

Title: Management of (traumatic) anterior shoulder instability: current treatment and future perspectives The open Bankart procedure still state of the art in 2020

Issue Date: 2020-09-23

2

Chapter 2

Labral (pathologic) similarities for the human shoulder and hip joint

Thomas Berendes · Timon Geurkink · Koen Willemsen · Harrie Weimans ·
Rene Castelein · Rob Nelissen · Bart Van der Wal

Open Access J Ortho. 2018; 1:101.

Introduction

Large differences exist between two- and four-legged locomotion, major morphological changes occurred in the human musculoskeletal system to facilitate its new purpose. The shoulder (glenohumeral) joints' primary purpose shifted from stability to increase mobility. Contradictory, the hip (acetabulofemoral) joints' primary purpose shifted from mobility to increase stability. However, stability and mobility are opposing functions and an optimal new equilibrium needed to be generated by means of morphological changes.

These morphological changes had a noticeable effect on the shoulder and hip joints. The shoulder and hip joints are the largest ball- and socket joint in the human body and etiologically they possess, next to distinct differences, also many similarities. Both joints are assisted through static and dynamic stabilizers. The static stabilizers include the bony anatomy, the labrum, the joint capsule and the ligaments. The dynamic stabilizers are the surrounding muscles. Together the static and dynamic stabilizers form a perfect morphological compromise between mobility and stability. However, this perfect compromise differs for the shoulder and hip as their specific demands differ.

The labrum is such a static stabilizing structure which morphology changed when the specific demand changed. It is important to know why such changes occur and what their implications are for clinical practice in both shoulder and hip surgery. In this review, we aim to compare the labrum of the hip and shoulder. We want to evaluate the similarities and differences, with special focus on its anatomy, general development, pathology and therapy.

General development

The human shoulder joint is conceptually a simple ball and socket joint although with little congruency. It is part of a more complex anatomic unit with the mobile scapula attached to the sternum by means of the clavicular bone (i.e. the sternoclavicular joint). As humans evolved to assume an upright position, the scapulohumeral complex underwent changes to comply with the demands of a non-weight-bearing joint. Over time, the inherent osseous articular congruity of the upper limbs was sacrificed for soft tissue stability to achieve a greater degree of mobility at the glenohumeral joint (Fig. 1). The scapulohumeral complex changed into an anatomic entity with a well- developed clavicle and sternum on the ventromedial side and a flat and wide strong scapula on the dorsolateral side. In humans or animals that use their upper limbs for holding, grasping, and climbing, the clavicle allows the scapula and humerus to be held away from the body to help the limb move free of the axial skeleton. The acromion became a relative massive structure covering the humeral head, thereby increasing the role of

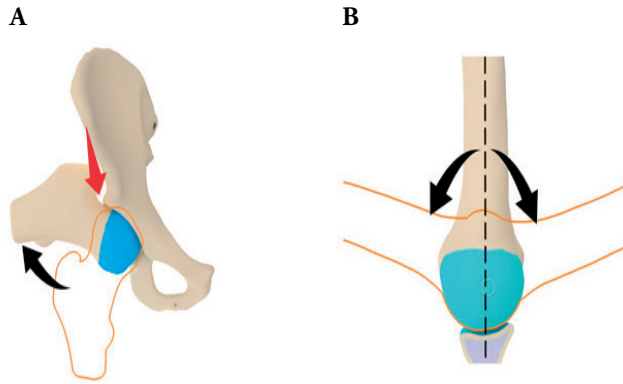


Fig. 1: Mobility of the hip and shoulder.

A. The intrinsic “stable” hip joint caused by the deep acetabular socket has a high stability at the expense of a limited mobility (red arrow).

B. The “mobile” shoulder joint is freely moveable over a wide range (black arrow) but lacks intrinsic stability.

the deltoid muscle in shoulder function. The coracoid extension over the glenohumeral joint increased in size over time and can mechanically limit anterior translation of the humerus relative to the glenoid in 90 degrees of shoulder abduction.

Like the shoulder, the hip is part of a complex system together with the pelvis and sacrolumbar spine. The human upright position, unlike other bipedal vertebrates, is characterized by lower extremities that are positioned right under the trunk. All other bipedals ambulate with flexed hips and knee joints. Therefore, in addition to the development of a lumbar lordosis, a pelvic lordosis developed and the hip joint was repositioned through both pelvic tilt and hip extension. This particular evolutionary process has enabled human fully upright ambulation with the trunk's center of gravity straight above the pelvis. This made the human hip an intriguing structure with a double extension, unique in nature.¹ As a result of this upright position, the hip became subjected to higher forces and developed in a vertical orientation as this decreases the necessary muscle force which is required to counteract gravity. The human pelvis changed from long, narrow and flat, to short wide and curved with a relatively long femur. This all has led to a remarkable efficiency of the human gait.² These bony alterations were accompanied by soft-tissue changes, especially changes in the muscle volume, moment arms and sometimes function. A typical example of these muscular changes is the transformation of the gluteus maximus, which transformed from a relatively small muscle into the strongest muscle of the human body, which straightens the hip.³ In the shoulder the deltoid muscle doubled in its proportional representation and constitutes approximately 41% of the scapulohumeral muscle mass, making it an important stabilizer of the shoulder.⁴

The acetabulum has a crescent-moon morphology that wraps around the superior, anterior and posterior aspects of the femoral head, facilitating a better load distribution. In contrast, the glenohumeral joint is more or less like a golf ball on a tee. The larger the area of contact between the cup and ball, the more stable the joint is. As a result of this, the pelvis is a relatively rigid structure compared to the freely moveable structure of the scapula as a result of a bony mismatch.⁵ This tendency towards instability of the shoulder is compensated for by many surrounding static and dynamic stabilizers, such as the labrum, joint capsule and glenohumeral ligaments and the deltoid and rotator cuff musculature.

A comparative overview between the two ball and socket joints has been made in Table 1.

Table 1: Comparison between two ball and socket joints, the shoulder and the hip⁵⁻⁷

| | Shoulder | Hip |
|-----------------------------|-----------------------|--------------------|
| Primary function | Mobility | Stability |
| Primary stabilizers | Dynamic stabilizers | Static stabilizers |
| Shape | Inverted comma / pear | Crescent-moon |
| Average vertical dimension | 36mm | 51mm |
| Average transverse diameter | 29mm | 49mm |
| Average depth | 3.4mm | 13mm |
| Ball: socket ratio | 3:1 | 1.2:1 |
| Degrees of coverage ball | 96 | 170 |
| Peak forces (x bodyweight) | <1 | 2.7-4.3 |
| Normal range of motion | | |
| Flexion | 150-180 | 100-120 |
| Extension | 50-60 | 30 |
| Abduction | 180 | 40-45 |
| Adduction | 0 | 20-30 |
| External rotation | 70-90 | 45-50 |
| Internal rotation | 70-90 | 40-45 |

Anatomy labrum

The anatomy of the glenoid and acetabular labrum has similarities but also some evident differences (Table 2). Both the glenoid and acetabular labrum are a rim of fibrocartilaginous structure, consisting of mostly type 1 collagen fibers, which is aligned along the outer ridge of both sockets.^{6,7}

The glenoid labrum forms a complete circle and acts both as a vacuum seal for the glenohumeral socket as well as a fibrous anchor from which the biceps tendon and

glenohumeral ligaments take their origin. The long head of the biceps tendon passes intra-articularly and inserts into the supraglenoid tubercle. It is often continuous with the superior portion of the labrum. The glenoid labrum is loosely attached superiorly above the equator and significant anatomic variability exists in this particular region between individuals.⁶ In contrast, the anterior inferior labrum is intimately attached to the glenoid rim and any detachment would indicate an abnormality.⁸

The human acetabular labrum is a horseshoe-like structure attached to the bony acetabular edge. Together with the inferiorly situated transverse acetabular ligament it forms a complete circle.⁹

Table 2: Comparison between the glenoid and acetabular labrum^{13,20,23,25,30}

| | Glenoid labrum | Acetabular labrum |
|------------------------|--|---|
| Shape | Circle | Horseshoe (Forms a complete circle together with the transverse ligament) |
| Shape in cross section | Triangular | Triangular |
| Average thickness | 3 mm | 4.7 mm |
| Average width | 4.0 mm (2.5 SD, range 1.1-9.3 mm) | 5.5 mm |
| Variability | Lots of variation, such as Sublabral foramen and Buford complex | Lots of variation, such as Posterior labrum sulcus |
| Orientation | Circumferential around bony rim | Anteriorly: parallel Posteriorly: perpendicular |
| Innervation | Free nerve endings, mainly derived from the (C4), C5, C6, and C7 nerve roots | Free nerve endings, mainly derived from the Quadratus femoris nerve and Obturator nerve (L4, L5, S1, S2 nerve roots) |
| Vascularity | Small branches of suprascapular -, circumflex scapular and humeral circumflex artery (derived from a. axillaris) | Periacetabular vascular ring, with branches of gluteal (derived from a. iliaca intima) and circumflex arteries (derived from a. femoralis profunda) |
| Insertions | Long head of biceps Long head of triceps Glenohumeral ligaments | Transverse acetabular ligament |

The collagen architecture of the glenoid labrum consists of three layers: (i) the superficial layer, with randomly orientated and loosely packed collagen fibres, considered to aid in lubrication; (ii) an intermediate layer; and (iii) the core layer, which forms the bulk of the tissue.¹⁰ The acetabular labrum can be divided into two parts, the articular (internal) and non-articular (external) surface. On the articular surface the labrum indirectly connects to the bone via the hyaline cartilage, while the external part, mainly composed of dense connective tissue, attaches directly to the bony rim on the non- articular side.^{7,9}

The morphology of the labrum differs depending on its localization and therefore the labrum is divided into different sections (Fig. 2). The fiber bundles of the glenoid labrum run in a circumferential orientation around the bony rim, with the anterior and inferior parts of the labrum smaller than the superior and posterior parts and most firmly attached posteriorly and inferiorly.¹¹ While the collagen fibers on the anterior side of the acetabular labrum have a parallel organization to the labral-chondral junction, the posterior fibers are oriented more perpendicularly.¹² The acetabular labrum is wider and thinner in the anterior region and thicker in the posterior region.⁹

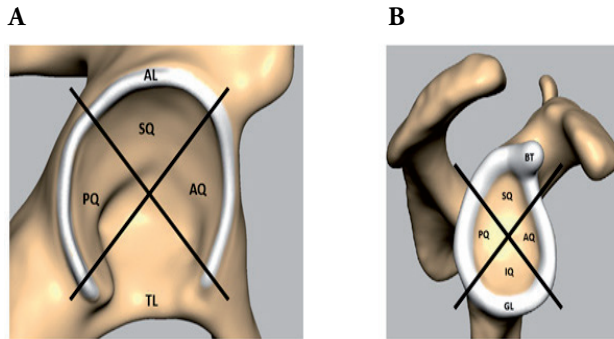


Fig. 2: Labral quadrants of (A) the hip and (B) shoulder.

A. AL: Acetabular Labrum, TL: Transverse Ligament, AQ: Anterior Quadrant, SQ: Superior Quadrant, PQ: Posterior Quadrant.

B. GL: Glenoid Labrum, BT: Biceps tendon, AQ: Anterior Quadrant, SQ: Superior Quadrant, PQ: Posterior Quadrant, IQ: Inferior Quadrant.

In the glenoid labrum, vascular supply occurs mainly in the peripheral attachment to the joint capsule.⁶ The superior and anterosuperior regions are less vascularized.^{6,7} As a result of this the labrum has limited ability to repair itself, however increased microvascularisation is found in case of a labral tear.⁹ For the acetabular labrum again, there is a relatively poor vascular supply, in which there are also differences between the anatomic zones. At the capsular contribution zone (zone I), there is a better vascularity than at the articular side zone (zone II). However, here there are no differences in vascularity patterns in the anterior, superior, posterior, and inferior labral regions, nor were they different in torn versus intact specimens.¹³ So, the internal part of the acetabular labrum is avascular as blood vessels are only seen in the peripheral one-third of the labrum, entering from the joint capsule. This may have implications for treatment, similar to those described for the meniscus of the knee.¹³

Corresponding with the vasculature the innervation of the labrum is unevenly distributed as well. The shoulder labrum is known to contain free nerve endings in its periphery, probably needed for proprioceptive feedback.¹⁴ For the acetabular labrum, most free nerve endings can be found in the anterosuperior region.^{15,16}

Anatomic variants of the labrum have been described in both the shoulder and hip. Often it is triangular in cross section, but it varies in size and thickness, sometimes being a prominent intra-articular structure with a free inner edge, sometimes round, flattened and at other times being virtually absent.^{17,18} Known anatomic variations for the glenoid labrum are for example the sublabral sulcus or the Buford complex.¹⁰ A sublabral foramen or hole is defined as a complete detachment of the labrum from the glenoid, as opposed to a sublabral recess or sulcus, where the labrum is lifted off the glenoid at the articular surface but there is still a deeper attachment.¹⁰ The Buford complex is an example of one of these variants whereby the anterosuperior labral tissue is absent and the middle glenohumeral ligament takes on a cordlike appearance.¹⁰ A common anatomic variant of the acetabular labrum is the posterior sublabral sulcus, often mistaken for labral pathology.¹⁹

Function labrum

As the anatomy of the glenoid and acetabular labrum are quite comparable, they show fundamental similarities in function as well. However, the exact functional role of the labrum is still undefined and discussed, it is known to function as an insertion site for other anatomical structures and to play a role in proprioception and nociception (Table 2). In addition to this, it is an essential part for stabilizing both the glenohumeral and acetabulofemoral joints.

The glenoid labrum, with the anteroinferior part being the major stabilizing part, increases the surface and volume of the shallow glenoid cavity (Table 3). Respectively the acetabular labrum fulfills the same function for the acetabular socket, however this function is less prominent in the hip as the bony acetabular socket is already deeper and much more stable than the glenoid socket.

Table 3: Comparison of labral functions between shoulder and hip^{27,31}

| Labral function | Shoulder | Hip |
|---|----------------|----------------------------|
| Increases surface | 33% | 28% |
| Increases volume | Up to 50% | Up to 33% |
| Tensile properties of intra-articular tissues elastic modulus (mean Mpa \pm SD) | 26.2 \pm 7.3 | 66.4 \pm 42.2 |
| % of load carried by labrum | Not applicable | Normal: 1-2% DDH: 4-11% |

Furthermore, it has been theorized that the labrum functions as a chock-block, limiting the translation of the ball within the socket, keeping the femoral and humeral head centralized, by forming a bumper around their socket.^{20,21} Concavity compression is an extension of this hypothesis, whereby the humeral head is compressed into the cavity of the glenoid by the rotator cuff musculature, further stabilizing the shoulder. This mechanism has been calculated to increase stability with an intact labrum and may be due to its role in centralizing the head within the glenoid.¹⁷ In addition, the labrum further stabilizes the joints by acting as a seal around the joint space, creating an intraarticular vacuum within the joint, which confers stability.^{18,22} It enhances joint lubrication and due to this seal, a layer of pressurized fluid is kept in the joint cavity, as the labrum restrict the synovial fluid from flowing out of the central joint compartment.²³ This layer of pressurized fluid also keeps the cartilage layers of the head and socket separated, preventing solid-on-solid contact, and functions as a shock absorber and load distributor.^{20,21,24} The labrum ensures a uniform distribution of forces over the cartilage, further helped by fluid in the cartilage giving it a cushioning function, resulting in a wider distribution of the transferred forces and lower cartilage strain.^{20,25} Labral loss or labral pathology has been shown to decrease the contact area of the articular surface of the glenohumeral joint, increasing the contact pressure. Absence of the acetabular labrum can result in almost doubling of the cartilage-on-cartilage stresses.^{20,24,26}

Labral pathology

Similarities / differences

The labrum often is involved in pathology. Labral pathology is more prevalent with advancing age. Beyond the age of 40, it commonly represents a natural degenerative process in the shoulder and hip, just as it is known for meniscal pathology in the knee.²⁷ By the 8th decade of life, up to 100% of cadaver specimens show signs of labral tearing in the hip and shoulder joint.²⁷ The presence of a labral tear does not in itself necessitate surgery.²⁷

Labral tears may have a variety of clinical presentations associated with a wide degree of clinical findings. There may or may not be a history of trauma. In the presence of a recalled incident such as twisting or falling, the trauma can vary from severe to very mild. The injury is usually caused by the joint being stressed in rotation. On examination, range of motion may not be limited but there may be pain at the extremes. There are a number of clinical tests, but generally speaking the combined movement of flexion and rotation causes pain in the joint.

A clear difference in labral pathology for hip and shoulder is that the location of the labral tear has shown big differences in clinical symptoms for the shoulder, as it has no effect on patient outcome in acetabular lesions.²⁸

The majority of acetabular labral lesions occur in the anterior region of the labrum, however Asian studies more often report the occurrence of labral tears in the posterior region, possibly due to a different lifestyle as they sit on the ground in a squatting position.²⁸⁻³⁰ Possible explanations for this phenomenon are that the anterosuperior region of the acetabular labrum is exposed to the highest strains, has a relatively poor vascularization and because of its orientation of the collagen fibers.^{12,18} In addition to this, it is thought that the acetabular labrum takes on a weight-bearing role at the extreme ranges of motion with excessive forces leading to tearing.²⁸

The exact distribution of the different labral lesions for the shoulder and hip is summarized in Table 4.

Table 4: Distribution of labral tears of shoulder and hip^{27,31,66,67}

| Hip, Labral tears | Anterior | Posterior | Inferior | Superior |
|-------------------------------|---|--|--|---|
| Western countries | 61-92% (mainly anterosuperior) | 7-25% | Not applicable | 0-15% |
| Asian countries | 0-20% | 50-86% | Not applicable | 0-10% |
| Shoulder, Labral tears | Anterior | Posterior | Inferior | Superior |
| Mondial | Rare | 15-55% | 0-6% | 55-72% / 80-90% |
| Specific clinical lesions | Anterosuperior (1/2): SLAP lesions, Anatomic variants (sublabral or Weitbrecht's foramen, Bufford complex) | Posteroinferior (4/5): Reverse Bankart POLPSA, posterior GLAD, Kim's lesion | Anteroinferior (3/4): Bankart, ALPSA, Perthes, GLAD | SLAP lesions (6/1/2): mostly type II, Andrew lesion |

Labral pathology correlated to age

Roughly, three groups of patients with corresponding pathology of the labrum for both hip and shoulder seems present. For reasons of clinical relevance, we classify them according to age.

1. young patients, in which no degenerative changes are being expected. (A-)traumatic instability is the most presented clinical symptom.
2. middle aged patients, in which early and distinct degenerative processes are being found. Impingement is the most related clinical symptom, often resulting in pain.
3. older patients, often having evidence of degeneration. Osteoarthritis is the most related clinical symptom, often resulting in stiffness and pain.

For the *younger patients*, a frequent cause of labral pathology is formed by the group of traumatic labral lesions. For the shoulder such a lesion often results in instability. Classic

examples are the Bankart, Perthes, ALPSA and GLAD lesions.³¹ In the hip, traumatic lesions are less frequent for this age group.³²

Traumatic hip dislocation sometimes will lead to recurrent instability after relocation.³³ This injury pattern show resemblance with that of traumatic shoulder instability. Matching lesions are: a Bankart-like lesion of the posterior labrum in the hip, a defect in the ischiofemoral ligament, similar to inferior glenohumeral ligament laxity of the shoulder; relative retroversion of femoral neck angle similar to loss of retroversion of the humeral neck and finally, Pipkin type 1 fracture of the femoral head, resembling a Hill-Sachs lesion of the humeral head.

Shoulder instability does not always mean labral pathology is present. Other pathologic conditions might lead to instability as well, such as Ehlers-Danlos / Marfan syndrome, neuromuscular disorders, muscle dysfunction or acquired or congenital bony defects.³⁴

A major group of labral shoulder pathology often seen in the middle-aged patients, is that of the superior labrum (SLAP) lesions, mostly not resulting in instability problems of the shoulder. SLAP lesions combine labral lesion and lesion of the proximal insertion of the long head of the biceps brachii tendon. The most frequent form is a SLAP type II lesion. They can be due to recurrent impingement or due to traction of the long head of the biceps.³⁵⁻³⁷ Another more degenerative type of labral pathology is seen in Walch's internal impingement, resulting in posterosuperior or posteroinferior lesions of the labrum. It is a result of repeated contact between the deep surface of the cuff and the posterosuperior aspect of the labrum, which in the end takes on a degenerative aspect, with a corresponding kissing lesion of the cuff.³⁸

In this specific *middle-aged group*, the occurrence of acetabular labral tears can have a variety of causes. The majority of labral pathology is idiopathic.³⁹ The rest of acetabular labral tears is most commonly due to the so-called femoroacetabular impingement syndrome (FAI). However, the exact prevalence of labral pathology remains unclear as many other abnormalities match the aging process. High percentages of labral tears have been found in several cadaveric studies, with reports of prevalences up to 93-96%.^{9,40} Most patients with acetabular labral tears complain about hip and/or groin pain, buttock pain, or radiating pain to the knee, with a long duration, often with a normal range of motion. In addition to this they can have mechanical symptoms such as clicking, locking, catching and giving way.^{28,29}

For the *older patients*, pain associated with osteoarthritis is the most presented symptom for both shoulder and hip joints, whereby again similarities are present. Labral lesions are being associated with early onset of shoulder and hip osteoarthritis. In 74% of patients with labral fraying or a labral tear this is accompanied with chondral damage, which is often more severe in the affected quadrant.⁴⁰

Similar labral pathology for both hip and shoulder can be seen in common clinical syndromes. For example, in cases of developmental dysplasia of the hip (DDH), the acetabulum is shallow, meaning that the femoral head not firmly fits into the socket. Developmental Dysplasia of the Hip (DDH) is commonly associated with labral hip pathology. DDH with an incomplete coverage of the femoral head show resemblance with pathology of shoulder instability. The role of the labrum as a weight carrier increases substantially in DDH compared to the normal situation.⁴¹ A combination of typical bony abnormalities can result in anterior hip instability or pain and in time, early degenerative changes due to these abnormal hip joint forces, will occur.

The impingement syndrome for the shoulder (nowadays called subacromial pain syndrome or SAPS) show great resemblances with the femoroacetabular impingement syndrome (FAI) for the hip joint. These types of repetitive lesions show similarities in labral pathology, resulting in a probable cause for pain. FAI consists of a group of structural acetabular and femoral abnormalities that result in abnormal contact between the anterior and anterosuperior femoral head-neck junction and acetabular rim during hip flexion and internal rotation. This contact can directly cause pain but also results in compromise of the underlying articular structures including the acetabular labrum and articular cartilage of the hip joint. These conditions can eventually result in focal labral tears, labral detachment, and complex degenerative tears of the labrum in this region. Also, partial and/or full-thickness cartilage wear and delaminating cartilage lesions along the anterosuperior peripheral aspects of the acetabular articular surface can appear, possibly in time resulting in early appearance of coxarthrosis.

For the shoulder, cuff tear arthropathy is a degenerative condition caused by longstanding massive cuff tear problems resulting in a high position of the humeral head against the undersurface of the acromion. The loss of these important stabilizers can eventually lead to a complex pattern of joint degeneration, referred to as rotator cuff tear arthropathy. The often superior migrated position of the humeral head under the acromial arc, shows great resemblance with the ball and socket appearance of the hip joint with a full covering of the femoral head, creating a more intrinsic stable situation, compensating for the loss of surrounding tissues such as cuff, labrum and capsule over time.

Therapy

Appropriate management of labral pathology begins with an understanding of the anatomy, etiology of pathology, and clinical correlation of pathology with symptoms and shoulder or hip dysfunction, this to prevent inappropriate surgical procedures. Nevertheless, little research on labral pathology has been done. Some describe significant improvements with conservative therapy.^{42,43} However, there are no studies investigating the long-term outcome of conservative management neither on surgical treatment.

Labral tears tend to occur on the articular non-vascular edge and may therefore not heal with conservative treatment.⁴⁰ It is not clear whether an “unhealed” labrum will remain symptomatic or whether it predisposes to early degenerative changes in the hip joint. In many patients, the labrum tear is associated with hip degeneration. However, in these patients the tear may have occurred as a result of degeneration instead of provoking it.^{9,39,40,44}

In general, several different strategies of treatment have been utilized to treat labral tears. Conservative treatment, such as non-steroidal anti-inflammatory drugs, physical therapy, hip joint injection (with corticosteroids) and adjustment of the patient’s activity patterns, are the first treatments of choice.

For the hip, arthroscopic management of hip disorders has received an increased amount of attention in the last few years. Although, the concept of hip arthroscopy was first introduced as early as 1931 by Burman.⁴⁵ When conservative treatment fails, operative treatment is increasingly proposed as the next treatment of choice. Surgical options are labral debridement or resection, labral repair or labral reconstruction. The way of thinking about these surgical interventions for labral tears has changed and is still subject to change. In the past, labral resection was the first treatment of choice. Partial labral debridement generally shows good results. However, this success significantly decreases in the presence of chondral lesions or FAI.⁴⁶ Nowadays, several studies indicate that a labral sparing treatment should be the golden standard, if the quality of the labrum allows it.⁴⁷ Not only labral repair or reconstruction can almost completely recover the labrum seal and protect the hip from increased cartilage strains, more importantly, it seems to protect the hip joint for a rapid progression of osteoarthritis as less cartilage damage was being found two-years postoperatively compared to a treatment with labral resection.^{25,47,48} Up to present day, no prospective randomized trials have been performed to look at the long-term outcome of the different treatment options for labral hip pathology. However, short-term outcome in hip arthroscopy versus physiotherapy in patients with FAI has been looked at more recently.⁴⁹ They reported that hip arthroscopy and personalized hip (physio-)therapy both improved hip-related quality of life for patients with FAI, but hip arthroscopy led to a greater improvement than did personalized hip (physio-)therapy in their short time follow up study. Provisional short or mid-term studies performed so far, suggest that hip arthroscopy is an effective treatment option when appropriate patient selection and indications have been made.^{46,50-53} Further follow-up and research are needed to look at the pros and cons for the patient.

For the shoulder, the same treatment algorithm is possible for labral pathology as for the hip. Again, conservative treatment is often the first treatment of choice, such as: activity modulation, anti-inflammatory medication and rest to relieve the symptoms. After that, patients may begin a rehabilitation program with the goals of improving glenohumeral and scapulothoracic motion and increasing the strength and endurance of the rotator cuff

and scapulothoracic muscles. Appropriate classification of the patient and the demands they place on their shoulder joint, helps to determine the best approach of management of labral tears. In many cases, nonsurgical methods are effective in relieving symptoms and if possible, helps with healing of the injured structures. Surgical options typically are being preserved for young high-demanding athlete patients or patients with heavy occupational demands involving frequent overhead activity, for whom conservative treatment methods are ineffective. Treatment varies depending on the type, size and location of labral tear and the degree of involvement of the long head of biceps tendon (LHBT) substance. Options include labral debridement, labral repair, LHBT tenodesis, and or tenotomy. A comparison between shoulder versus hip labral pathology treatment is summarized in Table 5.

Table 5: General comparison between shoulder versus hip labral pathology

| | Shoulder | Hip |
|-------------------|--|---|
| General treatment | Conservative treatment Operative treatment | Conservative treatment Operative treatment |
| Treatment options | Labral debridement, Labral repair, LHBT tenodesis / tenotomy, Bony reconstruction (ea. Latarjet procedure), Arthroplasty | Labral debridement, Labral resection, Labral repair, Osteotomies (periarticular (ea. Chiari / Triple)), Shelf procedure, Arthroplasty |

For the shoulder, a clear review analysis of treatment options for labral tears is recently been published.⁵⁴ For the anterior or inferior lesions often associated with instability, a multitude of surgical techniques have been described. This subject of glenohumeral instability remains complicated. Controversy remains regarding etiology, pathophysiology and (after-) treatment. The role of open and arthroscopic treatment methods continues to be debated. Nonoperative management still maintains a role as an early treatment modality, but high recurrence rates are being reported.⁵⁵ Nowadays, the presence of bony deficiency is considered to be very important as a cause of glenohumeral instability. Some degree of bony injury either to the glenoid or humeral head (together called bipolar bony lesions) is thought to occur in almost every patient with (traumatic) instability of the shoulder. To address this problem, bony reconstruction is more and more recommended, especially in patients with glenoid bone loss more than (15 to) 20%, or in patients with absence of the labrum, such as in revision casus.⁵⁶⁻⁵⁸

For the group of superior labrum lesions, also referred to as SLAP lesions, treatment is also still highly debated. In the case of failed nonoperative management, surgical treatment can be performed, mainly being reserved for the young high demanding patients.^{59,60} But results in literature of surgical treatment show great variation in success.^{54,59,61} For low-demanding patients, or patients with concomitant rotator cuff pathology, a long head biceps tenodesis or tenotomy is the preferred treatment of choice.^{62,63}

For posterior labral pathology, mainly presenting in pain more than instability, initial nonoperative treatment is also being applied. When this fails, arthroscopic treatment can be performed.^{38,64}

Conclusion

In conclusion, there are clear similarities between the shoulder and hip labrum morphology. An important similarity is the role of the labrum as a seal around the joint, creating an intraarticular vacuum in combination with the enhancement of joint lubrication. This allows for protection of the cartilage layers of the head and socket, creating shock absorption and load distribution. Another similarity is the enlargement of the contact area at the glenohumeral and the acetabulofemoral joint.

Pathology of the labrum has showed to increase cartilage loss resulting in signs of early arthrosis, which is more important in the hip joint, due to its weightbearing character. Treatment options for labral pathology for the shoulder and hip show great resemblances, including arthroscopic procedures such as labral debridement or repairs. However, there are different treatment indications, which are probably still subject to change since little clinical evidence with long term results is present for either intervention both conservative as well as surgical. For the shoulder labrum, instability and/or superior labral pathology including biceps tendinopathy is the most presented clinical symptom. For the hip labrum, femoroacetabular impingement is the most related clinical symptom.

No general advice for the management of labral pathology can be given. For any new technology or intervention, it is important to have phased introductions based on clinical evidence in order to create a safe and optimal treatment method for the patient.⁶⁵

References

1. Schlösser TPC, Janssen MMA, Vrtovec T, et al, 2014 Evolution of the ischio-iliac lordosis during natural growth and its relation with the pelvic incidence. *Eur Spine J* 23: 7: 1433-1441.
2. Abitbol MM, 1988 Effect of posture and locomotion on energy expenditure. *Am J Phys Anthropol* 77: 2: 191-199.
3. Hogervorst T, Bouma HW, de Vos J, 2009 Evolution of the hip and pelvis. *Acta Orthop Suppl* 80: 336: 1-39.
4. Rockwood Charles A, Matsen III Frederick A, Wirth Michael A, Lippitt Steven B, Fehringer Edward V SJW. *The Shoulder*.
5. Abood A, Jaffar S, Qusay M, 2006 Biomechanical Aspects of Shoulder and Hip Articulations: A Comparison of Two Ball and Socket Joints. *Biomechanical aspects of shoulder and hip articulations. A. Engineering* 2: 1: 1-14.
6. Cooper DE, Arnoczky SP, O'Brien SJ, Warren RF, DiCarlo E, Allen AA, 1992 Anatomy, histology, and vascularity of the glenoid labrum. An anatomical study. *J Bone Joint Surg Am* 74: 1: 46-52.
7. Petersen W, Petersen F, Tillmann B, 2003 Structure and vascularization of the acetabular labrum with regard to the pathogenesis and healing of labral lesions. *Arch Orthop Trauma Surg* 123: 6: 283-288.
8. Dodson CC, Dines DM, Dines JS, Walch G, Williams GR, 2014 *Controversies in Shoulder Instability*. Wolters Kluwer.
9. Seldes RM, Tan V, Hunt J, Katz M, Winiarsky R, Fitzgerald RH, 2001 Anatomy, histologic features, and vascularity of the adult acetabular labrum. *Clin Orthop Relat Res* 382.
10. Smith C, Funk L, 2010 The glenoid labrum. *Shoulder Elb* 2: 2: 87-93.
11. De Coninck T, Ngai SS, Tafur M, Chung CB, 2016 Imaging the Glenoid Labrum and Labral Tears. *RadioGraphics* 36: 1628-1647.
12. Cashin M, Uhthoff H, Neill MO', Beaulé PE, 2008 Embryology of the acetabular labral- chondral complex. *Bone Jt Surg [Br]* 90: 8: 1019-1024.
13. Kelly BT, Shapiro GS, Digiovanni CW, Buly RL, Potter HG, Hannafin JA, 2005 Vascularity of the hip labrum: a cadaveric investigation. *Arthroscopy* 21: 1: 3-11.
14. Vangsness CT, Ennis M, Taylor JG, Atkinson R, 1995. Neural anatomy of the glenohumeral ligaments, labrum, and subacromial bursa. *Arthroscopy* 11: 2: 180-184.
15. Kim YT, Azuma H, 1995 The Nerve Endings of the Acetabular Labrum. *Clin Orthop Relat Res* 320: 176-181.
16. Alzaharani A, Bali K, Gudena R, et al, 2014 The innervation of the human acetabular labrum and hip joint: an anatomic study. *BMC Musculoskelet Disord* 15: 1: 41.
17. Fehringer EV, Schmidt GR, Boorman RS, et al, 2003. The anteroinferior labrum helps center the humeral head on the glenoid. *J Shoulder Elb Surg* 12: 1: 53-58.
18. Crawford MJ, Dy CJ, Alexander JW, et al, 2007 The 2007 Frank Stinchfield Award. The biomechanics of the hip labrum and the stability of the hip. *Clin Orthop Relat Res* 465: 465: 16-22.
19. Dinauer PA, Murphy KP, Carroll JE, 2004 Sublabral sulcus at the posteroinferior acetabulum: a potential pitfall in MR arthrography diagnosis of acetabular labral tears. *AJR Am J Roentgenol* 183: 6: 1745-1753.
20. Ferguson SJ, Bryant JT, Ganz R, Ito K, 2003 An in vitro investigation of the acetabular labral seal in hip joint mechanics. *J Biomech* 36: 2:171-178.
21. Ferguson SJ, Bryant JT, Ganz R, Ito K, 2000 The acetabular labrum seal: a poroelastic finite element model. *Clin Biomech* 15: 6: 463-468.

22. Habermeyer P, Schuller U, Wiedemann E, 1992 The intra-articular pressure of the shoulder: an experimental study on the role of the glenoid labrum in stabilizing the joint. *Arthroscopy* 8: 2: 166-172.
23. Dwyer MK, Jones HL, Hogan MG, Field RE, McCarthy JC, Noble PC, 2014 The acetabular labrum regulates fluid circulation of the hip joint during functional activities. *Am J Sports Med* 42: 4: 812-819.
24. Ferguson SJ, Bryant JT, Ganz R, Ito K, 2000 The influence of the acetabular labrum on hip joint cartilage consolidation: A poroelastic finite element model. *J Biomech* 33: 8: 953-960.
25. Greaves LL, Gilbert MK, Yung AC, Kozlowski P, Wilson DR, 2010 Effect of acetabular labral tears, repair and resection on hip cartilage strain: A7T MR study. *J Biomech* 43: 5: 858-863.
26. Greis PE, Scuderi MG, Mohr A, Bachus KN, Burks RT, 2017 Glenohumeral articular contact areas and pressures following labral and osseous injury to the anteroinferior quadrant of the glenoid. *J shoulder Elb Surg* 11: 5: 442-451.
27. Medicine A college of occupational and enviremental. Shoulder disorders guideline.
28. Groh MM, Herrera JA, 2009 Comprehensive review of hip labral tears. *Curr Rev Musculoskelet Med* 2: 2: 105-117.
29. Lewis CL, Sahrman SA, 2006 Acetabular labral tears. *Phys Ther* 86: 1.
30. Bsar S, Frei H, Beaulé PE, 2016 The acetabular labrum: a review of its function. *Bone Joint J* 98B: 6: 730-735.
31. Clavert P 2015 Glenoid labrum pathology. *Orthop Traumatol Surg Res* 101: S19-S24.
32. Suarez-Ahedo C, Gui C, Rabe SM, Walsh JP, Chandrasekaran S, Domb BG, 2017 Relationship Between Age at Onset of Symptoms and Intraoperative Findings in Hip Arthroscopic Surgery. *Orthop J Sport Med* 5: 11: 232596711773748.
33. Mofidi A, Sankar R, Kutty S, Kaar K, Curtin W, 2002 Traumatic dislocation of hip joint following low-velocity trauma, similarities to glenohumeral instability. *Eur J Orthop Surg Traumatol* 12: 2: 108-114.
34. Krzyżanowski W, 2012 The use of ultrasound in the assessment of the glenoid labrum of the glenohumeral joint. Part I: Ultrasound anatomy and examination technique. *J Ultrason* 12: 49: 164-177.
35. Keener JD, Brophy RH, 2009 Superior labral tears of the shoulder: pathogenesis, evaluation, and treatment. *J Am Acad Orthop Surg* 17: 10: 627-637.
36. Beltran J, Jbara M, Maimon R, 2003 Shoulder: labrum and bicipital tendon. *Top Magn Reson Imaging* 14: 1: 35-49.
37. Musgrave DS, Rodosky MW, 2001 SLAP lesions: current concepts. *Am J Orthop (Belle Mead NJ)* 30: 1: 29-38.
38. Lévine C, Garret J, Grosclaude S, Borel F, Walch G, 2012 Surgical Technique Arthroscopic Posterior Glenoidplasty for Posterosuperior Glenoid Impingement in Throwing Athletes. *Clin Orthop Relat Res* 470: 6: 1571-1578.
39. Santori N, Villar RN, 2000 Acetabular labral tears: result of arthroscopic partial limbectomy. *Arthroscopy* 16: 1: 11-15.
40. McCarthy JC, Noble PC, Schuck MR, Wright J, Lee J, 2001 The Otto E. Aufranc Award: The role of labral lesions to development of early degenerative hip disease. *Clin Orthop Relat Res* 393: 25-37.
41. Henak CR, Ellis BJ, Harris MD, Anderson AE, Peters CL, Weiss JA, 2011 Role of the acetabular labrum in load support across the hip joint. *J Biomech* 44: 12: 2201-2206.
42. Yazbek PM, Ovanessian V, Martin RL, Fukuda TY, 2011 Nonsurgical treatment of acetabular labrum tears: a case series. *J Orthop Sports Phys Ther* 41: 5: 346-353.

43. Ikeda T, Awaya G, Suzuki S, Okada Y, Tada H, 1988 Torn acetabular labrum in young patients. Arthroscopic diagnosis and management. *J Bone Jt Surg Br* 70: 1: 13-16.
44. Dorrell JH, Catterall A, 1986 The torn acetabular labrum. *J Bone Joint Surg Br* 68: 400-403.
45. Burman MS, 2001 Arthroscopy or the direct visualization of joints: an experimental cadaver study 1931. *Clin Orthop Relat Res* 390: 5-9.
46. Safran MR, 2010 The acetabular labrum: anatomic and functional characteristics and rationale for surgical intervention. *J Am Acad Orthop Surg* 18: 338-345.
47. Espinosa N, Rothenfluh DA, Beck M, Ganz R, Leunig M, 2006 Treatment of Femoro-Acetabular Impingement. *J Bone Jt Surg* 88: 5: 925-935.
48. Philippon MJ, Nepple JJ, Campbell KJ, et al, 2014 The hip fluid seal-Part II: The effect of an acetabular labral tear, repair, resection, and reconstruction on hip fluid pressurization. *Knee Surgery, Sport Traumatol Arthrosc* 22: 4: 722-729.
49. Griffin DR, Dickenson EJ, Wall PDH, et al, 2018 Hip arthroscopy versus best conservative care for the treatment of femoroacetabular impingement syndrome (UK FASHIoN): a multicentre randomised controlled trial. *Lancet (London, England)* 391: 10136: 2225-2235.
50. Ross JR, Larson CM, Bedi A, 2017 Indications for Hip Arthroscopy. *Sport Heal A Multidiscip Approach* 9: 5: 402-413.
51. Harris JD, 2016 Hip labral repair: options and outcomes. *Curr Rev Musculoskelet Med* 9: 4: 361-367.
52. Clohisy JC, St John LC, Schutz AL, 2010 Surgical Treatment of Femoroacetabular Impingement: A Systematic Review of the Literature. *Clin Orthop Relat Res* 468: 2: 555-564.
53. Robertson WJ, Kadrmaz WR, Kelly BT, 2007 Arthroscopic Management of Labral Tears in the Hip. *Clin Orthop Relat Res* 455: 88-92.
54. Cagle PJ, Olujimi V, Parsons BO, 2018 Arthroscopic Treatment of Labral Tears: A Critical Analysis Review. *JBJS Rev* 6: 4: e4.
55. Rhee YG, Cho NS, Cho SH, 2009 Traumatic anterior dislocation of the shoulder: factors affecting the progress of the traumatic anterior dislocation. *Clin Orthop Surg* 1: 4: 188-193.
56. Shin S-J, Kim RG, Jeon YS, Kwon TH, 2017 Critical Value of Anterior Glenoid Bone Loss That Leads to Recurrent Glenohumeral Instability After Arthroscopic Bankart Repair. *Am J Sports Med* 45: 9: 1975-1981.
57. Jeon YS, Jeong HY, Lee DK, Rhee YG, 2018 Borderline Glenoid Bone Defect in Anterior Shoulder Instability: Latarjet Procedure Versus Bankart Repair. *Am J Sports Med* 036354651877697.
58. Shaha JS, Cook JB, Song DJ, et al, 2015 Redefining "Critical" Bone Loss in Shoulder Instability. *Am J Sports Med* 43: 7: 1719-1725.
59. Provencher MT, McCormick F, Dewing C, McIntire S, Solomon D 2013 A Prospective Analysis of 179 Type 2 Superior Labrum Anterior and Posterior Repairs. *Am J Sports Med* 41: 4: 880-886.
60. Taylor SA, Degen RM, White AE, et al, 2017 Risk Factors for Revision Surgery After Superior Labral Anterior-Posterior Repair: A National Perspective. *Am J Sports Med* 45: 7: 1640-1644.
61. Park J-Y, Chung S-W, Jeon S-H, Lee J-G, Oh K-S, 2013 Clinical and Radiological Outcomes of Type 2 Superior Labral Anterior Posterior Repairs in Elite Overhead Athletes. *Am J Sports Med* 41: 6: 1372-1379.
62. Thorsness RJ, Romeo AA, 2017 Diagnosis and Management of the Biceps- Labral Complex. *Instr Course Lect* 66: 65-77.
63. Frank RM, Cotter EJ, Strauss EJ, Jazrawi LM, Romeo AA, 2018 Management of Biceps Tendon Pathology. *J Am Acad Orthop Surg* 26: 4: e77-e89.
64. Bottoni CR, Franks BR, Moore JH, DeBerardino TM, Taylor DC, Arciero RA, 2005 Operative stabilization of posterior shoulder instability. *Am J Sports Med* 33: 7: 996-1002.

65. McCulloch P, Feinberg J, Philippou Y, et al, 2018 Progress in clinical research in surgery and IDEAL. *Lancet* 392: 10141: 88-94.
66. Suarez-Ahedo C, Gui C, Rabe SM, Walsh JP, Chandrasekaran S, Domb BG. Relationship Between Age at Onset of Symptoms and Intraoperative Findings in Hip Arthroscopic Surgery.
67. Simons P, Joeke E, Nelissen RG, Bloem JL, 1998 Posterior labrocapsular periosteal sleeve avulsion complicating locked posterior shoulder dislocation. *Skeletal Radiol* 27: 10: 588-590.