Universiteit Leiden
The Netherlands

Management of (traumatic) anterior shoulder instability: current treatment and future perspectives The open Bankart procedure still state of the art in 2020

Berendes, T.D.

Citation

Berendes, T. D. (2020, September 23). *Management of (traumatic) anterior shoulder instability: current treatment and future perspectives The open Bankart procedure still state of the art in 2020*. Retrieved from https://hdl.handle.net/1887/136943

Version:	Publisher's Version
License:	Licence agreement concerning inclusion of doctoral thesis in the Institutional Repository of the University of Leiden
Downloaded from:	https://hdl.handle.net/1887/136943

Note: To cite this publication please use the final published version (if applicable).

Cover Page

Universiteit Leiden

Leiden University Repository

The handle http://hdl.handle.net/1887/136943 holds various files of this Leiden University dissertation.

Author: Berendes, T.D.
Title: Management of (traumatic) anterior shoulder instability: current treatment and future perspectives The open Bankart procedure still state of the art in 2020
Issue Date: 2020-09-23

Management of (traumatic) anterior shoulder instability: current treatment and future perspectives

T.D. Berendes

Management of (traumatic) anterior shoulder instability: current treatment and future perspectives

The open Bankart procedure still state of the art in 2020

Thomas Berendes

Cover ProefschriftMaken.nl
Layout Renate Siebes | Proefschrift.nu
Printed by ProefschriftMaken.nl
ISBN 978-94-6380-940-5

© Thomas Berendes, Leiden 2020
All rights reserved. No part of this publication may be reproduced, stored in a retrieval system or transmitted, in any form or by any means, electronic, mechanical, photocopying, recording or otherwise, without prior permission of the author or the copyright-owning journals for previous published chapters.

Management of (traumatic) anterior shoulder instability: current treatment and future perspectives

The open Bankart procedure still state of the art in 2020

Proefschrift

ter verkrijging van de graad van Doctor
aan de Universiteit Leiden,
op gezag van Rector Magnificus prof. mr. C.J.J.M. Stolker,
volgens besluit van het College voor Promoties
te verdedigen op
woensdag 23 september 2020
klokke 11.15 uur

door

Thomas Diederik Berendes

geboren te Leiden
in 1975

Promotor:
Prof. dr. R.G.H.H. Nelissen

Copromotor:
Dr. B.C.H. van der Wal

Leden promotiecommissie:
Prof. dr. R.L. Diercks, Faculteit Medische Wetenschappen, UMCG
Prof. dr. I.B. Schipper, LUMC
Dr. A. van Noort, afdeling orthopedie, Spaarne Gasthuis
Prof. dr. P.D.S. Dijkstra, LUMC
Prof. dr. M.A.J. van de Sande, LUMC
Dr. P.B. de Witte, LUMC

Contents

Chapter 1	General introduction and aim of this thesis	**7**
Chapter 2	Labral (pathologic) similarities for the human shoulder and hip joint Berendes TD, Geurkink T, Willemsen K, Weinans H, Castelein R, Nelissen R, van der Wal B. Open Access J Ortho. 2018; 1:101.	**25**
Chapter 3	Validation of the Dutch version of the Oxford Shoulder Score Berendes T, Pilot P, Willems J, Verburg H, te Slaa R. J Shoulder Elbow Surg. 2010 Sep;19(6):829-36.	**45**
Chapter 4	Survey on the management of acute first-time anterior shoulder dislocation amongst Dutch public hospitals Berendes T, Pilot P, Nagels J, Vochteloo A, Nelissen R. Arch Orthop Trauma Surg. 2015 Apr;135(4):447-54.	**75**
Chapter 5	The open modified Bankart procedure: outcome at follow-up of 10 to 15 years Berendes T, Wolterbeek R, Pilot P, Verburg H, te Slaa R. J Bone Joint Surg Br. 2007 Aug;89(8):1064-8.	**91**
Chapter 6	The open-modified Bankart procedure: a 16–26 years follow-up study Berendes T, Mathijssen N, Verburg H, Kraan G. Arch Orthop Trauma Surg. 2018 Jan 3.	**103**
Chapter 7	A novel treatment for anterior shoulder instability Willemsen K, Berendes T, Geurkink T, Bleys R, Leeflang S, Weinans H, Castelein R, Nelissen R, van der Wal B. J Bone Joint Surg Am. 2019 Jul 17; 101(14):e68	**119**
Chapter 8	Summary, general discussion and future perspectives	**137**
Chapter 9	Samenvatting (summary in Dutch)	**151**
Chapter 10	Dankwoord	**169**
Chapter 11	Curriculum vitae	**175**
Chapter 12	List of publications – Milestones	**179**

1

Chapter 1

General introduction and aim of this thesis

1. Epidemiology

Traumatic anterior shoulder dislocations are the most common dislocations of the shoulder.[1] Based on an annual incidence of 30 shoulder dislocations per 100,000 inhabitants, with approximately 17 million inhabitants, the Netherlands can count on about 5100 shoulder dislocations per year.[2–5] Shoulder dislocations occur mainly during private or sports accidents. Age at first dislocation is the most important factor in predicting recurrence, being up to 95% for persons younger than 20 years and up to 80% under 30 years of age.[6] In general, more men than women are treated for a shoulder dislocation.[7] Most of the patients treated surgically for persistent shoulder instability are young and active, especially males aged between 15 and 35 years and women in the older age groups.

2. Diagnosis shoulder instability including etiopathology

Age and impact of the instability complaints are two important considerations for the type of intervention in patients with shoulder instability. Typically, patients present with a history of trauma. Symptoms may be vague, varying from pain, weakness and shoulder dysfunction. Discomfort in the overhead, abducted and externally rotated position of the shoulder is associated with anterior instability. Symptoms in the forward elevated and internally rotated position (i.e. when pushing open heavy doors) is more associated with posterior instability. Pain and paresthesias (because of traction on the brachial plexus) is often reported in patients with inferior instability (i.e. when carrying heavy objects). Physical examination should focus on both diagnosis and identification of associated injuries. For anterior instability, the apprehension-relocation test (or Fowler test) is the most sensitive (specificity: 87%, sensitivity: 40% for any labral lesion including SLAP).[8] Other tests associated with shoulder instability are the (modified) load-and-shift test with an optimal reliability of this test, when tested in 0° abduction for the posterior and inferior directions (intraclass correlation coefficient (ICC), for interrater reliability and test-retest reliability was 0.68 and 0.79, respectively) with a good reliability for the anterior direction when tested in 90° abduction (ICC: 0.72) and sulcus sign (Kappa value: < 0.5, ICC: 0.60), the latter reflecting inferior laxity of the capsule.[9] The two most reliable tests associated with posterior instability are the posterior stress test and the jerk test.[10]

Multiple **definitions of shoulder instability** are in circulation, creating imprecision and ambiguity surrounding this topic. Examples are: "glenohumeral instability is the inability to maintain the humeral head centered in the glenoid fossa" or "shoulder instability describes the susceptibility of a shoulder to subluxation or dislocation". "**Traumatic** instability" arises from an injury of sufficient magnitude to tear the glenohumeral capsule, ligaments, or rotator cuff or to produce a fracture of the humerus or glenoid (rim). Since shoulder instability as such ranges from asymptomatic instabilities, due to extrinsic shoulder problems (neuro-motor systems) to intrinsic, anatomical pathologies, a simple

validated **classification system** covering all instabilities does not exist. Nevertheless several classification systems have been suggested, but due to low validity of these classifications, clinical management decisions based on these classifications are multi interpretable.[11] The most commonly used and simple classification system, divides instability into two distinct groups based on the presence or absence of trauma, resulting in instability, direction of (partial) dislocation, and whether it involves one or both shoulders.[12] Later on, a more extensive classification is proposed including three types of shoulder instability recognizing both structural and non-structural components of shoulder instability. Even more, stressing a continuum between pathologies as cause for shoulder instability, with probably multifactorial origin after years, involving the brain-musculoskeletal system.[13]

The glenohumeral joint is a complex, mobile, multiaxial, ball-and-socket articulation that allows coordinated motion in the frontal, transverse, and sagittal planes. The latter allows for 360 degrees of circumduction. **Pathologies causing instability** can be categorized in ***structural*** (internal: rotator cuff, surface area of contact, capsulolabral complex) and ***non-structural*** (external, central and peripheral nervous system) elements.[13–15] The structural elements include abnormal morphology (either genetic or intrauterine), abnormal collagen, acquired (micro-)traumatic lesions over time or traumatic morphologic abnormalities.[13]

As for these ***structural causes***, a subclassification in soft tissue (shoulder capsule, glenoid labral rim, glenohumeral ligaments) and bony structures (glenoid cavity and humeral head) can be made. For that matter, an intact labrum deepens the shallow glenoid fossa up to 50%, thus improving its articulation and contact area with the humeral head up to 75%. It probably also serves as a chock block preventing excessive humeral head rollback.[16] The shoulder labrum is attached to the joint capsule, which is the layer of soft tissue encapsulating the joint. The shoulder joint capsule is lax and thin and by itself, offers little resistance or stability. Focal thickening of the anterior capsule present the capsuloligamentous structures, the three glenohumeral ligaments. These ligaments act as restraints, and thus stabilizers at the end-range of motion of the shoulder joint.[15,17,18] Typical labral lesions are associated with acute or chronic anterior shoulder instability, especially anterior and antero-inferior tears.[19] Bankart described the "essential lesion" of anterior shoulder instability to be an anteroinferior labral tear. That is why it bears the eponymous term *Bankart lesion*. However, different types of labral lesions can be encountered, such as: the Perthes lesion (traumatic) or Buford complex (non-traumatic); GLAD lesion (Gleno-Labral Articular Disruption); Broca-Hartmann pouch; ALPSA lesion and the **Bankart** lesion. Posterior labral tears or Polpsa lesions are much less frequent than anterior tears.[20] Whether all these conditions are physiologic ageing phenomena or only related to (multiple) (micro) traumatic injury(ies) is to be seen. Labral tears can occur in stable or in unstable shoulders, so when a labral tear is present not always operative treatment is necessary.[19] Controversy still exists as to which management strategy is best in each situation.[21] Glenoid bone loss, or bone loss at the humeral head, is also a commonly encountered

problem in (anterior) shoulder instability.[22,23] When an effective glenoid cavity is present, concavity-compression is a contributing mechanism for stabilizing the glenohumeral joint.[24–27] Following an initial shoulder dislocation, osseous defects are probably present in up to 22% of patients, and up to 88% of patients with recurrent instability.[22,28,29] The (critical) amount of (glenoid or bipolar) bone loss and its assessment of optimal treatment is currently a subject of debate.[23,30,31]

As for ***non-structural causes*** of instability (central and peripheral nervous system), the importance of intact rotator cuff musculature, with active muscular contraction has been highlighted for glenohumeral stability.[25,32,33] The mechanical restraints about the shoulder (glenoid-humeral head) contribute also to the feedback loop for stability by neural feedback (proprioception) to the central nervous system. The latter is integrated with other somatosensory, vestibular, and visual input, and ultimately results in the generation of efferent control over the dynamic restraints about the shoulder joint (neuromuscular control).[34] So, when mechanical restraints of the shoulder are disrupted, the instability problem becomes aggravated by means of pathologic changes in the neural feedback system.[34]

3. History of stabilizing surgical procedures, including Bankart repair

Historically, stabilizing surgical procedures for shoulder instability are either focused on passive stability constraints at the level of the joint capsule, dynamic augmentations and osseous procedures at the glenoid, humerus or both. An overview with a time-line when the procedure was introduced is given in Table 1. The procedures are stratified in open soft tissue, open osseous surgical procedures and arthroscopic procedures.[35–37]

The ***open Bankart procedure*** was first described in the *British Medical Journal* in 1923.[38,39] Originally, this stabilizing procedure was done for the patient with habitual anterior shoulder dislocation. Initially, Bankart described a lesion where the labrum was separated from both the glenoid and the capsule. For this, he developed a technique, abrading the glenoid to facilitate natural ingrowth of the reattached labrum, he also sutured the capsule to the detached labrum. During this procedure the subscapularis tendon was not shortened, preserving its function. Later on, he described the technique, reattaching the detached labrum including the joint capsule to the glenoid bone. Since then numerous modifications have been made, such as the Bankart procedure in association with a capsular shift.[40] Some of the surgical methods, such as the Magnusson-Stack procedure, Putti-Platt procedure, arthroscopic stapling, and transosseous suture fixation have been almost completely abandoned.[37,41,42] Other strategies, such as the Bankart repair, capsular shift, and remplissage (being a combined arthroscopic posterior capsulodesis and infraspinatus tenodesis using sutures and suture anchors that fills (Remplissage: French: to fill) the Hill-Sachs lesion have persisted for decades and nowadays have been adapted for arthroscopic use.[37,43]

Table 1: Historic overview of surgical procedures for shoulder instability problems

Soft tissue procedures	*Capsular procedures*	- *Injections with iodine tincture/blood*: Genzmer 1882; Mandel/ Kepler 1937 - *Shortening of shoulder capsule*: Ricard 1894, Gerster 1883, Bardenheuer 1896, Mikulicz 1896, Putti-Platt 1923, inferior capsular shift: Neer, Foster 1980 - *Shoulder capsule reinforcements, making use of fascia, tendon, periost or other material*: Gallie-le Mesurier 1948, Henderson 1943, Nicola 1929 - *Open Hill-Sachs "remplissage"*: Connolly 1972 - *Capsuloligamentary "retensioning" procedures*: Caspari 1987 - *Closing of rotator interval*: Rowe 1987 - "*Suture-only" labrum refixation*: Harryman 1994
	Rotator cuff muscle/ tendon procedures	- *Shortening of subscapularis*: Quervain 1910, Röbke 1912, Putti 1923, Platt 1925, Matti 1936, Boicev 1938, Magnuson & Stack 1943, Boicev & Osmond-Clarke 1948 - *Transposition of (part of) deltoid muscle*: Clairmont-Ehrlich 19 09 - *Open Hill-Sachs remplissage*: Connolly 1972
	Arthroscopic procedures	- *Capsular shift by means of "stapling technique"*: Johnson 1980 - *Labrum refixation*: Morgan 1987 - *Labrum refixation with "suture anchors"*: Snyder, Wolf 1990-1991 - *Capsular shift*: Duncan 1993 - "*Laser assisted/thermal capsular shrinkage"*: Thabit 1994 - *Closing of rotator interval*: Field, Treacy 1995-1997 - *Revision of Bankart procedure*: Kim 2002 - *Hill-Sachs remplissage*: Wolf 2004, Purchase 2008
Bone procedures	*Glenoid procedures*	- *Deepening of cavum glenoidalis*: Hildebrand 1902 - *Procedures focused on the edge of cavum glenoidalis*: Perthes 1906, **Bankart** 1923 - *Bone augmentation procedures on glenoid defect*: Eden 1918, Hybbinette 1917&1932, Noordenbos 1938, Leguit 1942 - *Coracoid (augmentation) procedures*: Oudard 1924, Noesske 1924, Latarjet 1954, Bristow 1958, Trillat 1954 - *Mini-open Bristow-Latarjet procedure*: Nourissat 2006
	Humeral procedures	- *Humeral head resection*: Cramer 1882 - *Glenohumeral arthrodesis*: Albert 1888 - *Rotational osteotomy of humerus*: Weber 1969
	Arthroscopic procedures	- *Latarjet procedure*: Lafosse 2007 - *Eden procedure*: Taverna, Scheibel 2008 - *Augmentation procedure by means of autograft of distal part of clavicle*: Tokish 2014 - *Latarjet procedure with "guided surgical approach and suture endobutton" fixation*: Boileau 2015 - *Dynamic anterior stabilisation with long biceps tendon and Bankart procedure*: Mehl 2019

The open (modified) Bankart repair, with good clinical outcome and a **low recurrence rate** is historically considered to be the gold standard of care and the benchmark for all current arthroscopic techniques for anterior shoulder instability.[44] However, for potential advantages (e.g. faster rehabilitation, smaller incisions etc.), the majority of Bankart repairs are being performed arthroscopically nowadays.[45–53] Both open and arthroscopic repairs have shown to decrease the recurrence rate of shoulder dislocation and are considered to be safe and reliable surgical treatment options[54–58] Nevertheless, a majority of studies report on the higher rate of recurrent instability using arthroscopic procedures compared to the traditional open procedures.[44,59–61] Therefore, recent studies have challenged this arthroscopic trend to treat shoulder instability, reviving the interest in open repair procedures.[45,54] Results of a recent meta-analysis of open versus arthroscopic shoulder stabilisation during the last two decennia demonstrated there were no significant improvements for clinical outcome or external rotation deficits in both groups.[62] But, although the recurrence rate of dislocation for open surgery remained comparable in this 20 year time period (10.7% and 10.8%), the recurrence rate after arthroscopic stabilisation was higher, although it decreased little 16.8% to 14.2%.

The (open) Latarjet procedure (transfer of coracoid including attached muscles to the deficient glenolabral area at the anterior glenoid) is like the Bankart repair also a viable surgical option for recurrent traumatic anterior instability of the shoulder joint and is by some the preferred treatment in cases of glenoid deficiency and in revision anterior stabilization.[63–68] The open Latarjet procedure yields the most reliable outcome of stabilization. However this bone block procedure has also the highest complication rate, especially when being performed arthroscopically by non-experienced surgeons.[69] In the meantime, a few modifications of the original technique described by Latarjet have been developed, such as the congruent arc technique (developed by DeBeer), which increases the joint surface contact area of the glenoid. Another modification is the technique described by Walch & Boileau.[70]

4. Evidence and evaluation of recurrence

Until today, the optimal approach and technique to address anterior shoulder instability remains controversial. How many instabilities will resolve "spontaneously" or after conservative treatment, with or without proprioceptive training, is unknown. In 2017, Galvin et al. outlined the natural history and best clinical practices for nonoperative management of anterior shoulder instability, including an algorithm to guide management of first-time dislocators (Figure 1).[71] They concluded that, despite the continues refinement of surgical techniques for anterior glenohumeral instability, there remains a significant role for nonoperative treatment. Many different surgical stabilizing shoulder procedures have been applied, of which almost all have been subject to discussion, because of varying

results at long-term follow-up.[72] The latter and the lack of full knowledge on epidemiology of the natural cause of (traumatic) shoulder dislocations and on the definition of shoulder instability as such, underscores why there is no consensus or best treatment guideline.[73]

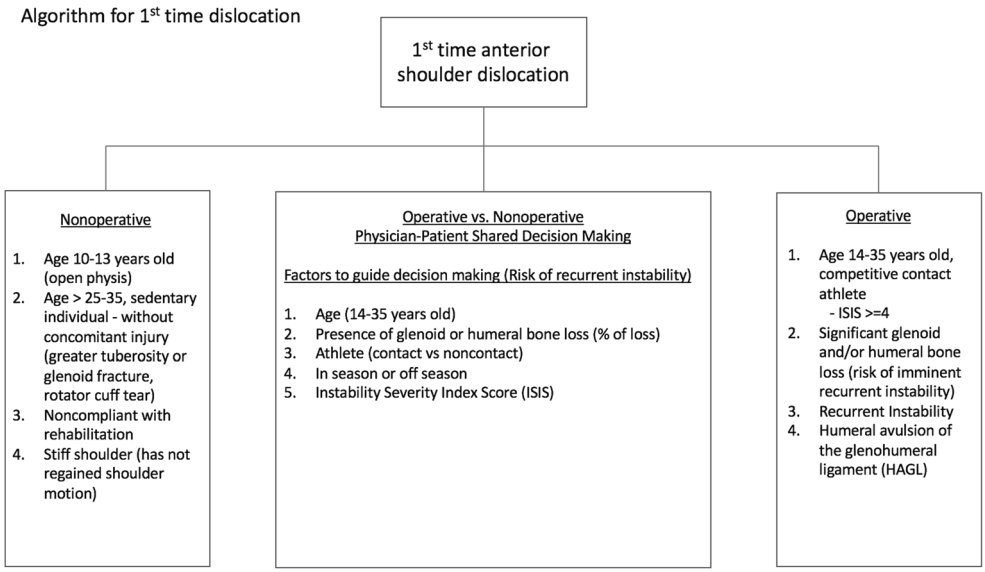

Fig. 1: Algorithm for first time dislocation.[71]

Factors predisposing to recurrent instability and revision stabilization procedures for anterior glenohumeral instability remains uncertain. There are publications of population based cohortstudies assessing risk factors of failure after stabilizing shoulder surgery, combining the results for open and arthroscopic procedures.[74,75] Common reasons for failure following previous anterior stabilizing surgery are: diagnostic errors missing associated pathology such as bony lesions; new trauma, for instance in contact or forced overhead sport; technical errors; younger age; capsular laxity or voluntary dislocations.[76–80] Underestimation of glenoid bone loss or bone loss at the humeral head is often related to redislocation before and after a stabilizing shoulder procedure.[81–84] Glenoid bone loss is a commonly encountered problem in anterior shoulder instability and should be identified to facilitate a better understanding of management of the patients in this group.[22,28,29] Following an initial shoulder dislocation, an osseous defect is probably present in up to 20% of patients, and up to 90% of patients with recurrent instability.[64,85] When recurrent symptomatic shoulder instability is present, several revision techniques are available, including open Bankart repair, bony augmentation procedures, and management of Hill Sachs defects.[86] Identifying, the patient`s primary pathology is a must. The latter includes knowledge on detailed understanding of the patient's shoulder anatomy and its static and dynamic restraints after the failed index procedure.

5. Patient perception on shoulder instability (PROM's)

An increasing number of outcome measurement tools have been designed to report on the effectiveness of treatment for shoulder pathologies. Patient's perceptions on the effect of an intervention have become more important to evaluate outcome. Using the *appropriate instrument* for evaluation of patient outcome data is essential if outcome measures are to be valid and clinically meaningful. Failure to account for patient reported outcome factors has been a major limitation in previous shoulder scoring systems.[87,88] Known scoring systems that address shoulder instability, in random order, include the Rowe/modified Rowe score (also known as rating sheet for Bankart repair);[89,90] the American Shoulder and Elbow Surgeons (ASES) score;[91,92] the L'Ìnsalata shoulder rating system / Shoulder Rating Questionnaire (SRQ);[93,94] the Melbourne Instability Shoulder Score (MISS);[95] the Disabilities of the Arm, Shoulder and Hand (DASH) score;[96,97] the Western Ontario Shoulder Instability Index (WOSI);[98] the Oxford Instability Score (OIS);[99,100] the Constant-Murley (CM) score;[101] the Athletic Shoulder Outcome Rating Scale (ASORS);[102] the University of California, Los Angeles (UCLA) score;[103] and the Simple Shoulder Test (SST).[87,104,105]

The **Oxford Shoulder Score** (OIS) was developed by Dawson et al.[99,106] Two different questionnaires exist; one was constructed in 1999 for instability patients, now called the OIS, and the other was constructed for shoulder operations other than instability (OSS), a few years earlier, in 1996. The shoulder questionnaires for instability problems that have already been translated and validated in Dutch are: the L'Ìnsalata shoulder rating system/Shoulder Rating Questionnaire (SRQ);[93,94] the Disabilities of the Arm, Shoulder and Hand (DASH) score;[96,97] and the Simple Shoulder Test (SST).[87,104,105] The Oxford Instability Score (OIS) has been translated and validated in Dutch five years after our Dutch validation of the OSS.[99,100,106,107]

Aims of thesis

1. Anatomical evaluation of one of the major passive constraints for shoulder instability, the labrum, and its phylogenetic counterpart at the hip joint (chapter 2)
2. Patient evaluation of outcome including discussion on Oxford Shoulder Score and Oxford Shoulder Instability Score ((addendum) chapter 3)
3. Evaluation of management of acute first-time anterior shoulder dislocations in the Netherlands by means of a shoulder questionnaire (including treatment of recurrent shoulder instability) (chapter 4)
4. Clinical evaluation of the mid- and long term results after a labrum joint capsule (open Bankart) repair (chapter 5 & 6)
5. Evaluation of a novel technique addressing bony defects of the glenoid (chapter 7)

Outline of the thesis

Anatomical evaluation of the shoulder labrum, with its well-known Bankart lesion, being highly associated with shoulder instability is presented in **chapter 2**. Labral pathology with special focus on the role in shoulder instability and matching treatment options are being described. We also regard evolutional differences for the labrum of the shoulder, originating from the fact that humans evolved to assume an upright position. A comparison with the labrum of the hip joint is made, since both hip and shoulder are both essentially ball and socket joints.

Chapter 3 presents the validation study of the Dutch version of the Oxford Shoulder Score, including a discussion on the relation between the Oxford Shoulder Score and the Oxford Shoulder Instability Score. The Oxford Shoulder Score (OSS) is an internationally-used patient-based outcome score. Up to now, it was not validated in Dutch.

Chapter 4 presents the results of a nationwide survey on the management of traumatic anterior shoulder dislocation amongst Dutch public hospitals. We questioned how orthopaedic surgeons at that time would manage patients with this issue, ten years after the introduction of the Dutch national guideline: "acute primary shoulder dislocation, diagnostics and treatment" in 2005. Furthermore, we evaluated how these surgeons would treat recurrent instability after one or more (traumatic) anterior shoulder dislocation.

In **chapter 5 and 6**, the outcome of the conventional open Bankart repair is evaluated in two successive studies including mid- and long term follow-up. In chapter five, the outcome of open Bankart repair using suture anchors in 31 patients (31 shoulders) with a mean follow-up of 11 years (10 to 15) for patients with instability after one or more (traumatic) anterior shoulder dislocation is being reported. In chapter six, the outcome of the open Bankart repair using suture anchors in 39 patients (39 shoulders) is reported with a mean follow-up of 21 years (16 to 26).

A potential alternative treatment option for structural bony deficits is a 3D printing technique to augment the bony glenoid defect. To this end a biomechanical cadaver study is done (**chapter 7**). Ten fresh-frozen cadaveric shoulders were tested for stability under five different conditions, being: (1) in the anatomic situation, (2) after the creation of an anterior glenoid bone defect, (3) after implantation of a 3D patient specific titanium implant, (4) after a Latarjet procedure with (4) and without (5) 10N of load attached to the conjoined tendon.

References

1. Hovelius L. Incidence of shoulder dislocation in Sweden. *Clin Orthop Relat Res*. 1982;(166):127-131. http://www.ncbi.nlm.nih.gov/pubmed/7083659. Accessed November 10, 2017.
2. Slaa TRL. The acute first-time anterior shoulder dislocation (AFASD). 2003.
3. Nordqvist A, Petersson CJ. Incidence and causes of shoulder girdle injuries in an urban population. *J shoulder Elb Surg*. 4(2):107-112. http://www.ncbi.nlm.nih.gov/pubmed/7600160. Accessed June 8, 2019.
4. Shah A, Judge A, Delmestri A, et al. Incidence of shoulder dislocations in the UK, 1995–2015: a population-based cohort study. *BMJ Open*. 2017;7(11):e016112. doi:10.1136/bmjopen-2017-016112
5. Zacchilli MA, Owens BD. Epidemiology of Shoulder Dislocations Presenting to Emergency Departments in the United States. *J Bone Jt Surgery-American Vol*. 2010;92(3):542-549. doi:10.2106/JBJS.I.00450
6. Chahal J, Marks PH, MacDonald PB, et al. Anatomic Bankart Repair Compared With Nonoperative Treatment and/or Arthroscopic Lavage for First-Time Traumatic Shoulder Dislocation. *Arthrosc J Arthrosc Relat Surg*. 2012;28(4):565-575. doi:10.1016/j.arthro.2011.11.012
7. Simonet WT, Melton LJ, Cofield RH, Ilstrup DM. Incidence of anterior shoulder dislocation in Olmsted County, Minnesota. *Clin Orthop Relat Res*. 1984;(186):186-191. http://www.ncbi.nlm.nih.gov/pubmed/6723141. Accessed June 8, 2019.
8. Magee DJ. Orthopedic Physical Assessment. In: *Orthopedic Physical Assessment*. 5th ed. St. Louis MO; 2008.
9. Hill AM, Bull AMJ, Richardson J, et al. The clinical assessment and classification of shoulder instability. *Curr Orthop*. 2008;22(3):208-225. doi:10.1016/j.cuor.2008.02.006
10. Millett PJ, Clavert P, Hatch GFR, Warner JJP. Recurrent posterior shoulder instability. *J Am Acad Orthop Surg*. 2006;14(8):464-476. http://www.ncbi.nlm.nih.gov/pubmed/16885478. Accessed July 17, 2019.
11. Farrar NG, Malal JJG, Fischer J, Waseem M. An overview of shoulder instability and its management. *Open Orthop J*. 2013;7:338-346. doi:10.2174/1874325001307010338
12. Thomas SC, Matsen FA. An approach to the repair of avulsion of the glenohumeral ligaments in the management of traumatic anterior glenohumeral instability. *J Bone Joint Surg Am*. 1989;71(4):506-513. http://www.ncbi.nlm.nih.gov/pubmed/2703510. Accessed March 10, 2019.
13. Jaggi A, Lambert S. Rehabilitation for shoulder instability. *Br J Sports Med*. 2010;44(5):333- 340. doi:10.1136/bjsm.2009.059311
14. Lewis A, Kitamura T, Bayley JI. (ii) The classification of shoulder instability: new light through old windows! *Curr Orthop*. 2004;18(2):97-108. doi:10.1016/J.CUOR.2004.04.002
15. Di Giacomo G, Piscitelli L, Pugliese M. The role of bone in glenohumeral stability. *EFORT Open Rev*. 2018;3(12):632-640. doi:10.1302/2058-5241.3.180028
16. Matsen FA, Harryman DT, Sidles JA. Mechanics of glenohumeral instability. *Clin Sports Med*. 1991;10(4):783-788. http://www.ncbi.nlm.nih.gov/pubmed/1934096. Accessed November 9, 2017.
17. Blasier R, Guldberg R, elbow ER-J of shoulder and, 1992 undefined. Anterior shoulder stability: contributions of rotator cuff forces and the capsular ligaments in a cadaver model. *Elsevier*. https://www.sciencedirect.com/science/article/pii/105827469290091G. Accessed May 24, 2019.
18. O'Connell PW, Nuber GW, Mileski RA, Lautenschlager E. The contribution of the glenohumeral ligaments to anterior stability of the shoulder joint. *Am J Sports Med*. 1990;18(6):579-584. doi:10.1177/036354659001800604

19. Clavert P. Glenoid labrum pathology. *Orthop Traumatol Surg Res*. 2015;101(1):S19-S24. doi:10.1016/j.otsr.2014.06.028
20. Simons P, Joekes E, Nelissen RG, Bloem JL. Posterior labrocapsular periosteal sleeve avulsion complicating locked posterior shoulder dislocation. *Skeletal Radiol*. 1998;27(10):588-590. http://www.ncbi.nlm.nih.gov/pubmed/9840399. Accessed August 5, 2018.
21. Farrar NG, Malal JJG, Fischer J, Waseem M. An overview of shoulder instability and its management. *Open Orthop J*. 2013;7:338-346. doi:10.2174/1874325001307010338
22. Rabinowitz J, Friedman R, Eichinger JK. Management of Glenoid Bone Loss with Anterior Shoulder Instability: Indications and Outcomes. *Curr Rev Musculoskelet Med*. 2017;10(4):452- 462. doi:10.1007/s12178-017-9439-y
23. Gowd AK, Liu JN, Cabarcas BC, et al. Management of Recurrent Anterior Shoulder Instability With Bipolar Bone Loss: A Systematic Review to Assess Critical Bone Loss Amounts. *Am J Sports Med*. August 2018:036354651879155. doi:10.1177/0363546518791555
24. Williamson P, Mohamadi A, Ramappa AJ, DeAngelis JP, Nazarian A. Shoulder biomechanics of RC repair and Instability: A systematic review of cadaveric methodology. *J Biomech*. 2019;82:280-290. doi:10.1016/j.jbiomech.2018.11.005
25. Veeger HEJ, van der Helm FCT. Shoulder function: The perfect compromise between mobility and stability. *J Biomech*. 2007;40(10):2119-2129. doi:10.1016/J.JBIOMECH.2006.10.016
26. Pagnani MJ, Warren RF. Stabilizers of the glenohumeral joint. *J Shoulder Elb Surg*. 1994;3(3):173-190. doi:10.1016/S1058-2746(09)80098-0
27. Matsen FA, Chebli C, Lippitt S, American Academy of Orthopaedic Surgeons. Principles for the evaluation and management of shoulder instability. *J Bone Joint Surg Am*. 2006;88(3):648- 659. http://www.ncbi.nlm.nih.gov/pubmed/16541527. Accessed May 10, 2019.
28. Taylor DC, Arciero RA. Pathologic changes associated with shoulder dislocations. Arthroscopic and physical examination findings in first-time, traumatic anterior dislocations. *Am J Sports Med*. 1997;25(3):306-311. doi:10.1177/036354659702500306
29. Edwards TB, Boulahia A, Walch G. Radiographic analysis of bone defects in chronic anterior shoulder instability. *Arthroscopy*. 2003;19(7):732-739. http://www.ncbi.nlm.nih.gov/pubmed/12966381. Accessed May 7, 2019.
30. Moroder P, Damm P, Wierer G, et al. Challenging the Current Concept of Critical Glenoid Bone Loss in Shoulder Instability: Does the Size Measurement Really Tell It All? *Am J Sports Med*. January 2019:036354651881910. doi:10.1177/0363546518819102
31. Yamamoto N, Itoi E, Abe H, et al. Effect of an Anterior Glenoid Defect on Anterior Shoulder Stability: A Cadaveric Study. *Am J Sports Med*. 2009;37(5):949-954. doi:10.1177/0363546508330139
32. Steenbrink F, Meskers CGM, Nelissen RGHH, de Groot JH. The relation between increased deltoid activation and adductor muscle activation due to glenohumeral cuff tears. *J Biomech*. 2010;43(11):2049-2054. doi:10.1016/j.jbiomech.2010.04.012
33. Steenbrink F, Nelissen RGHH, Meskers CGM, van de Sande MAJ, Rozing PM, de Groot JH. Teres major muscle activation relates to clinical outcome in tendon transfer surgery. *Clin Biomech*. 2010;25(3):187-193. doi:10.1016/j.clinbiomech.2009.11.001
34. Myers JB, Wassinger CA, Lephart SM. Sensorimotor contribution to shoulder stability: effect of injury and rehabilitation. *Man Ther*. 2006;11(3):197-201. doi:10.1016/j.math.2006.04.002
35. Sanders RJ. Thesis: De habituele anterieure schouderluxatie. 1978.
36. Randelli P, Cucchi D, Butt U. History of shoulder instability surgery. *Knee Surgery, Sport Traumatol Arthrosc*. 2016;24(2):305-329. doi:10.1007/s00167-015-3947-3
37. Levy DM, Cole BJ, Bach BR. History of surgical intervention of anterior shoulder instability. *J Shoulder Elbow Surg*. April 2016. doi:10.1016/j.jse.2016.01.019

38. Bankart AS. Recurrent or habitual dislocation of the shoulder-joint. *Br Med J*. 1923;2(3285):1132-1133. http://www.ncbi.nlm.nih.gov/pubmed/20771383. Accessed November 10, 2017.
39. Zarins B. Bankart repair for anterior shoulder instability. *Tech Orthop*. 1989.
40. Altchek DW, Warren RF, Skyhar MJ, Ortiz G. T-plasty modification of the Bankart procedure for multidirectional instability of the anterior and inferior types. *J Bone Joint Surg Am*. 1991;73(1):105-112. http://www.ncbi.nlm.nih.gov/pubmed/1985978. Accessed January 13, 2019.
41. Regan WD, Webster-Bogaert S, Hawkins RJ, Fowler PJ. Comparative functional analysis of the Bristow, Magnuson-Stack, and Putti-Platt procedures for recurrent dislocation of the shoulder. *Am J Sports Med*. 1989;17(1):42-48. doi:10.1177/036354658901700107
42. Flatow EL, Miniaci A, Evans PJ, Simonian PT, Warren RF. Instability of the shoulder: complex problems and failed repairs: Part II. Failed repairs. *Instr Course Lect*. 1998;47:113-125. http://www.ncbi.nlm.nih.gov/pubmed/9571408. Accessed May 8, 2019.
43. Wolf EM, Pollack M, Smalley C. Hill-Sachs "Remplissage:" An Arthroscopic Solution For the Engaging Hill-Sachs Lesion. (SS-02). *Arthrosc J Arthrosc Relat Surg*. 2007;23(6):e1-e2. doi:10.1016/j.arthro.2007.03.015
44. Coughlin RP, Crapser A, Coughlin K, Coughlin LP. Open Bankart Revisited. *Arthrosc Tech*. 2017;6(1):e233-e237. doi:10.1016/j.eats.2016.09.027
45. Khatri K, Arora H, Chaudhary S, Goyal D. Meta-Analysis of Randomized Controlled Trials Involving Anterior Shoulder Instability. *Open Orthop J*. 2018;12(1):411-418. doi:10.2174/1874325001812010411
46. Miura K, Tsuda E, Tohyama H, et al. Can arthroscopic Bankart repairs using suture anchors restore equivalent stability to open repairs in the management of traumatic anterior shoulder dislocation? A meta-analysis. *J Orthop Sci*. 2018;23(6):935-941. doi:10.1016/j.jos.2018.06.016
47. Wheeler JH, Ryan JB, Arciero RA, Molinari RN. Arthroscopic versus nonoperative treatment of acute shoulder dislocations in young athletes. *Arthroscopy*. 1989;5(3):213-217. doi:0749- 8063(89)90174-6 [pii]
48. Arciero RA, Wheeler JH, Ryan JB, McBride JT. Arthroscopic Bankart repair versus nonoperative treatment for acute, initial anterior shoulder dislocations. *Am J Sport Med*. 1994;22(5):589- 594.
49. Kirkley A, Griffin S, Richards C, Miniaci A, Mohtadi N. Prospective Randomized Clinical Trial Comparing the Effectiveness of Immediate Arthroscopic Stabilization Versus Immobilization and Rehabilitation in First Traumatic Anterior Dislocations of the Shoulder. *Arthrosc J Arthrosc Relat Surg*. 1999;15(5):507-514. doi:10.1053/ar.1999.v15.015050
50. Bottoni CR, Wilckens JH, DeBerardino TM, et al. A prospective, randomized evaluation of arthroscopic stabilization versus nonoperative treatment in patients with acute, traumatic, first-time shoulder dislocations. *Am J Sports Med*. 2002;30(4):576-580. doi:10.1177/03635465020300041801
51. Arciero RA, Taylor DC. Primary anterior dislocation of the shoulder in young patients. A ten-year prospective study. *J Bone Joint Surg Am*. 1998;80(2):299-300. http://www.ncbi.nlm.nih.gov/pubmed/9486735. Accessed January 6, 2019.
52. Baker CL, Uribe JW, Whitman C. Arthroscopic evaluation of acute initial anterior shoulder dislocations. *Am J Sports Med*. 1990;18(1):25-28. doi:10.1177/036354659001800104
53. DeBerardino TM, Arciero RA, Taylor DC. Arthroscopic stabilization of acute initial anterior shoulder dislocation: the West Point experience. *J South Orthop Assoc*. 1996;5(4):263-271. http://www.ncbi.nlm.nih.gov/pubmed/8972449. Accessed January 6, 2019.
54. Hohmann E, Tetsworth K, Glatt V. Open versus arthroscopic surgical treatment for anterior shoulder dislocation: a comparative systematic review and meta-analysis over the past 20 years. *J shoulder Elb Surg*. 2017;26(10):1873-1880. doi:10.1016/j.jse.2017.04.009

55. Chen L, Xu Z, Peng J, Xing F, Wang H, Xiang Z. Effectiveness and safety of arthroscopic versus open Bankart repair for recurrent anterior shoulder dislocation: a meta-analysis of clinical trial data. *Arch Orthop Trauma Surg*. 2015;135(4):529-538. doi:10.1007/s00402-015-2175-0
56. Freedman KB, Smith AP, Romeo AA, Cole BJ, Bach Jr. BR. Open Bankart repair versus arthroscopic repair with transglenoid sutures or bioabsorbable tacks for Recurrent Anterior instability of the shoulder: a meta-analysis. *Am J Sport Med*. 2004;32(6):1520-1527. doi:10.1177/0363546504265188 [doi]0363546504265188 [pii]
57. Chalmers PN, Mascarenhas R, Leroux T, et al. Do arthroscopic and open stabilization techniques restore equivalent stability to the shoulder in the setting of anterior glenohumeral instability? a systematic review of overlapping meta-analyses. *Arthroscopy*. 2015;31(2):355- 363. doi:10.1016/j.arthro.2014.07.008
58. Mohtadi NG, Bitar IJ, Sasyniuk TM, Hollinshead RM, Harper WP. Arthroscopic versus open repair for traumatic anterior shoulder instability: a meta-analysis. *Arthroscopy*. 2005;21(6):652-658.
59. Virk MS, Manzo RL, Cote M, et al. Comparison of Time to Recurrence of Instability After Open and Arthroscopic Bankart Repair Techniques. *Orthop J Sport Med*. 2016;4(6):232596711665411. doi:10.1177/2325967116654114
60. Cohen BH, Thome AP, Tabaddor RR, Owens BD. Open Surgical Stabilization of Glenohumeral Dislocations. *JBJS Essent Surg Tech*. 2018;8(2):e17. doi:10.2106/JBJS.ST.17.00052
61. Provencher MT. Editorial Commentary: Is It Time to Take a Stand? When Arthroscopic Bankart Repair Is No Longer a Viable Option for Anterior Shoulder Instability. *Arthrosc J Arthrosc Relat Surg*. 2018;34(9):2537-2540. doi:10.1016/j.arthro.2018.06.021
62. Berendes TD, Pilot P, Nagels J, Vochteloo AJH, Nelissen RGHH. Survey on the management of acute first-time anterior shoulder dislocation amongst Dutch public hospitals. *Arch Orthop Trauma Surg*. 2015;135(4). doi:10.1007/s00402-015-2156-3
63. Beran MC, Donaldson CT, Bishop JY. Treatment of chronic glenoid defects in the setting of recurrent anterior shoulder instability: A systematic review. *J Shoulder Elb Surg*. 2010;19(5):769-780. doi:10.1016/j.jse.2010.01.011
64. Provencher MT, Bhatia S, Ghodadra NS, et al. Recurrent shoulder instability: current concepts for evaluation and management of glenoid bone loss. *J Bone Joint Surg Am*. 2010;92 Suppl 2(Suppl 2):133-151. doi:10.2106/JBJS.J.00906
65. Schmid SL, Farshad M, Catanzaro S, Gerber C. The Latarjet Procedure for the Treatment of Recurrence of Anterior Instability of the Shoulder After Operative Repair. *J Bone Jt Surgery- American Vol*. 2012;94(11):e75-e77. doi:10.2106/JBJS.K.00380
66. Shah AA, Butler RB, Romanowski J, Goel D, Karadagli D, Warner JJP. Short-term complications of the Latarjet procedure. *J Bone Joint Surg Am*. 2012;94(6):495-501. doi:10.2106/JBJS.J.01830
67. Latarjet M. Technic of coracoid preglenoid arthroereisis in the treatment of recurrent dislocation of the shoulder. *Lyon Chir*. 1958;54(4):604-607. http://www.ncbi.nlm.nih.gov/pubmed/13576973. Accessed May 7, 2019.
68. Hurley ET, Jamal MS, Ali ZS, Montgomery C, Pauzenberger L, Mullett H. Long-term outcomes of the Latarjet procedure for anterior shoulder instability: a systematic review of studies at 10-year follow-up. *J Shoulder Elb Surg*. 2019;28(2):e33-e39. doi:10.1016/j.jse.2018.08.028
69. Rollick N, Ono Yohei, kurji Hafeez, et al. Long-term outcomes of Bankart and Latarjet repairs: a systematic review. *J Sports Med*. 2017;8:97-105. doi:10.2147/OAJSM.S106983
70. Boileau P, Gendre P, Baba M, et al. A guided surgical approach and novel fixation method for arthroscopic Latarjet. *J Shoulder Elb Surg*. 2016;25(1):78-89. doi:10.1016/j.jse.2015.06.001

71. Galvin JW, Ernat JJ, Waterman BR, Stadecker MJ, Parada SA. The Epidemiology and Natural History of Anterior Shoulder Instability. *Curr Rev Musculoskelet Med*. 2017;10(4):411-424. doi:10.1007/s12178-017-9432-5
72. Glazebrook H, Miller B, Wong I. Anterior Shoulder Instability: A Systematic Review of the Quality and Quantity of the Current Literature for Surgical Treatment. *Orthop J Sport Med*. 2018;6(11):232596711880598. doi:10.1177/2325967118805983
73. Kavaja L, Lähdeoja T, Malmivaara A, Paavola M. Treatment after traumatic shoulder dislocation: a systematic review with a network meta-analysis. *Br J Sports Med*. 2018;52(23):1498-1506. doi:10.1136/bjsports-2017-098539
74. Wasserstein D, Dwyer T, Veillette C, et al. Predictors of Dislocation and Revision After Shoulder Stabilization in Ontario, Canada, From 2003 to 2008. *Am J Sports Med*. 2013;41(9):2034-2040. doi:10.1177/0363546513492952
75. Waterman BR, Burns TC, McCriskin B, Kilcoyne K, Cameron KL, Owens BD. Outcomes after bankart repair in a military population: predictors for surgical revision and long-term disability. *Arthroscopy*. 2014;30(2):172-177. doi:10.1016/j.arthro.2013.11.004
76. Mahure SA, Mollon B, Capogna BM, Zuckerman JD, Kwon YW, Rokito AS. Risk factors for recurrent instability or revision surgery following arthroscopic Bankart repair. *Bone Joint J*. 2018;100-B(3):324-330. doi:10.1302/0301-620X.100B3.BJJ-2017-0557.R1
77. Kim S-H, Ha K-I, Kim Y-M. Arthroscopic revision Bankart repair. *Arthrosc J Arthrosc Relat Surg*. 2002;18(5):469-482. doi:10.1053/jars.2002.32230
78. Levine WN, Arroyo JS, Pollock RG, Flatow EL, Bigliani LU. Open Revision Stabilization Surgery for Recurrent Anterior Glenohumeral Instability. *Am J Sports Med*. 2000;28(2):156-160. doi:10.1177/03635465000280020401
79. Meehan RE, Petersen SA. Results and factors affecting outcome of revision surgery for shoulder instability. *J shoulder Elb Surg*. 2005;14(1):31-37. doi:10.1016/j.jse.2004.05.005
80. Tauber M, Resch H, Forstner R, Raffl M, Schauer J. Reasons for failure after surgical repair of anterior shoulder instability. *J shoulder Elb Surg*. 13(3):279-285. doi:10.1016/S1058274604000254
81. Balg F, Boileau P. The instability severity index score. *J Bone Joint Surg Br*. 2007;89- B(11):1470-1477. doi:10.1302/0301-620X.89B11.18962
82. Burkhart SS, De Beer JF. Traumatic glenohumeral bone defects and their relationship to failure of arthroscopic Bankart repairs: significance of the inverted-pear glenoid and the humeral engaging Hill-Sachs lesion. *Arthroscopy*. 2000;16(7):677-694. http://www.ncbi.nlm.nih.gov/pubmed/11027751. Accessed July 1, 2018.
83. Boileau P, Villalba M, Héry J-Y, Balg F, Ahrens P, Neyton L. Risk factors for recurrence of shoulder instability after arthroscopic Bankart repair. *J Bone Joint Surg Am*. 2006;88(8):1755- 1763. doi:10.2106/JBJS.E.00817
84. Boileau P, O'Shea K, Vargas P, Pinedo M, Old J, Zumstein M. Anatomical and Functional Results After Arthroscopic Hill-Sachs Remplissage. *J Bone Jt Surgery-American Vol*. 2012;94(7):618-626. doi:10.2106/JBJS.K.00101
85. Sayegh ET, Mascarenhas R, Chalmers PN, Cole BJ, Verma NN, Romeo AA. Allograft Reconstruction for Glenoid Bone Loss in Glenohumeral Instability: A Systematic Review. *Arthrosc J Arthrosc Relat Surg*. 2014;30(12):1642-1649. doi:10.1016/j.arthro.2014.05.007
86. Ho AG, Gowda AL, Michael Wiater J. Evaluation and treatment of failed shoulder instability procedures. *J Orthop Traumatol*. 2016;17(3):187-197. doi:10.1007/s10195-016-0409-8
87. Plancher KD, Lipnick SL. Analysis of Evidence-Based Medicine for Shoulder Instability. *Arthrosc J Arthrosc Relat Surg*. 2009;25(8):897-908. doi:10.1016/j.arthro.2009.03.017

88. Kirkley A, Griffin S, McLintock H, Ng L. The Development and Evaluation of a Disease-Specific Quality of Life Measurement Tool for Shoulder Instability. *Am J Sports Med*. 1998;26(6):764- 772. doi:10.1177/03635465980260060501
89. Rowe CR, Patel D, Southmayd WW. The Bankart procedure: a long-term end-result study. *J Bone Jt Surg Am*. 1978;60(1):1-16.
90. Williams GN, Gangel TJ, Arciero RA, Uhorchak JM, Taylor DC. Comparison of the Single Assessment Numeric Evaluation method and two shoulder rating scales. Outcomes measures after shoulder surgery. *Am J Sports Med*. 27(2):214-221.
91. Richards RR, An K-N, Bigliani LU, et al. A standardized method for the assessment of shoulder function. *J Shoulder Elb Surg*. 1994;3(6):347-352. doi:10.1016/S1058-2746(09)80019-0
92. Skutek M, Fremerey RW, Zeichen J BU. Outcome analysis following open rotator cuff repair. Early effectiveness validated using four different shoulder assessment scales. - PubMed - NCBI. *Arch Orthop Trauma Surg*. 2000;120(7-8):432-436. https://www.ncbi.nlm.nih.gov/pubmed/10968533. Accessed May 19, 2019.
93. L'Insalata JC, Warren RF, Cohen SB, Altchek DW, Peterson MG. A self-administered questionnaire for assessment of symptoms and function of the shoulder. *J Bone Joint Surg Am*. 1997;79(5):738-748. http://www.ncbi.nlm.nih.gov/pubmed/9160947. Accessed May 19, 2019.
94. Vermeulen HM, Boonman DC, Schüller HM, et al. Translation, adaptation and validation of the Shoulder Rating Questionnaire (SRQ) into the Dutch language. *Clin Rehabil*. 2005;19(3):300- 311. doi:10.1191/0269215505cr811oa
95. Watson L, Story I, Dalziel R, Hoy G, Shimmin A, Woods D. A new clinical outcome measure of glenohumeral joint instability: The MISS questionnaire. *J Shoulder Elb Surg*. 2005;14(1):22-30. doi:10.1016/j.jse.2004.05.002
96. Hudak PL, Amadio PC, Bombardier C, et al. Development of an upper extremity outcome measure: the DASH (disabilities of the arm, shoulder and hand) [corrected]. The Upper Extremity Collaborative Group (UECG). *Am J Ind Med*. 1996;29(6):602-608. doi:10.1002/(SICI)1097-0274(199606)29:6<602::AID-AJIM4>3.0.CO;2-L
97. Veehof MM, Sleegers EJA, van Veldhoven NHMJ, Schuurman AH, van Meeteren NLU. Psychometric qualities of the Dutch language version of the Disabilities of the Arm, Shoulder, and Hand questionnaire (DASH-DLV). *J Hand Ther*. 15(4):347-354. http://www.ncbi.nlm.nih.gov/pubmed/12449349. Accessed March 5, 2019.
98. Kirkley A, Griffin S, McLintock H, Ng L. The Development and Evaluation of a Disease-Specific Quality of Life Measurement Tool for Shoulder Instability. *Am J Sports Med*. 1998;26(6):764- 772. doi:10.1177/03635465980260060501
99. Dawson J, Fitzpatrick R, Carr A. The assessment of shoulder instability. The development and validation of a questionnaire. *J Bone Joint Surg Br*. 1999;81(3):420-426. http://www.ncbi.nlm.nih.gov/pubmed/10872358. Accessed March 5, 2019.
100. van der Linde JA, van Kampen DA, van Beers LWAH, van Deurzen DFP, Terwee CB, Willems WJ. The Oxford Shoulder Instability Score; validation in Dutch and first-time assessment of its smallest detectable change. *J Orthop Surg Res*. 2015;10(1):146. doi:10.1186/s13018-015- 0286-5
101. Constant CR, Murley AH. A clinical method of functional assessment of the shoulder. *Clin Orthop Relat Res*. 1987;(214):160-164. http://www.ncbi.nlm.nih.gov/pubmed/3791738.
102. Tibone JE. Evaluation of treatment outcomes for the athlete`s shoulder. In: *The Shoulder: A Balance of Mobility and Stability*. 1993.
103. Amstutz HC, Sew Hoy AL, Clarke IC. UCLA anatomic total shoulder arthroplasty. *Clin Orthop Relat Res*. (155):7-20. http://www.ncbi.nlm.nih.gov/pubmed/7226634. Accessed May 19, 2019.

104. van Laarhoven HA, R te S, LM de B, Willems WJ. De Nederlandse Simpele Schouder Test, een efficiente wijze van schouderfunctie bepaling. *Ned Tijdschr voor Orthop*. 2001;8.
105. Lippitt SMF. A practical tool for the evaluation of function: the simple shoulder test. In: *The Shoulder: A Balance of Mobility and Stability*. 1993.
106. Dawson J, Fitzpatrick R, Carr A. Questionnaire on the perceptions of patients about shoulder surgery. *J Bone Joint Surg Br*. 1996;78(4):593-600. http://www.ncbi.nlm.nih.gov/pubmed/8682827. Accessed September 30, 2018.
107. Berendes T, Pilot P, Willems J, Verburg H, te Slaa R. Validation of the Dutch version of the Oxford Shoulder Score. *J Shoulder Elb Surg*. 2010;19(6). doi:10.1016/j.jse.2010.01.017

2

Chapter 2

Labral (pathologic) similarities for the human shoulder and hip joint

Thomas Berendes · Timon Geurkink · Koen Willemsen · Harrie Weimans · Rene Castelein · Rob Nelissen · Bart Van der Wal

Open Access J Ortho. 2018; 1:101.

Introduction

Large differences exist between two- and four-legged locomotion, major morphological changes occurred in the human musculoskeletal system to facilitate its new purpose. The shoulder (glenohumeral) joints' primary purpose shifted from stability to increase mobility. Contradictory, the hip (acetabulofemoral) joints' primary purpose shifted from mobility to increase stability. However, stability and mobility are opposing functions and an optimal new equilibrium needed to be generated by means of morphological changes.

These morphological changes had a noticeable effect on the shoulder and hip joints. The shoulder and hip joints are the largest ball- and socket joint in the human body and etiologically they possess, next to distinct differences, also many similarities. Both joints are assisted through static and dynamic stabilizers. The static stabilizers include the bony anatomy, the labrum, the joint capsule and the ligaments. The dynamic stabilizers are the surrounding muscles. Together the static and dynamic stabilizers form a perfect morphological compromise between mobility and stability. However, this perfect compromise differs for the shoulder and hip as their specific demands differ.

The labrum is such a static stabilizing structure which morphology changed when the specific demand changed. It is important to know why such changes occur and what their implications are for clinical practice in both shoulder and hip surgery. In this review, we aim to compare the labrum of the hip and shoulder. We want to evaluate the similarities and differences, with special focus on its anatomy, general development, pathology and therapy.

General development

The human shoulder joint is conceptually a simple ball and socket joint although with little congruency. It is part of a more complex anatomic unit with the mobile scapula attached to the sternum by means of the clavicular bone (i.e. the sternoclavicular joint). As humans evolved to assume an upright position, the scapulohumeral complex underwent changes to comply with the demands of a non-weight-bearing joint. Over time, the inherent osseous articular congruity of the upper limbs was sacrificed for soft tissue stability to achieve a greater degree of mobility at the glenohumeral joint (Fig. 1). The scapulohumeral complex changed into an anatomic entity with a well- developed clavicle and sternum on the ventromedial side and a flat and wide strong scapula on the dorsolateral side. In humans or animals that use their upper limbs for holding, grasping, and climbing, the clavicle allows the scapula and humerus to be held away from the body to help the limb move free of the axial skeleton. The acromion became a relative massive structure covering the humeral head, thereby increasing the role of

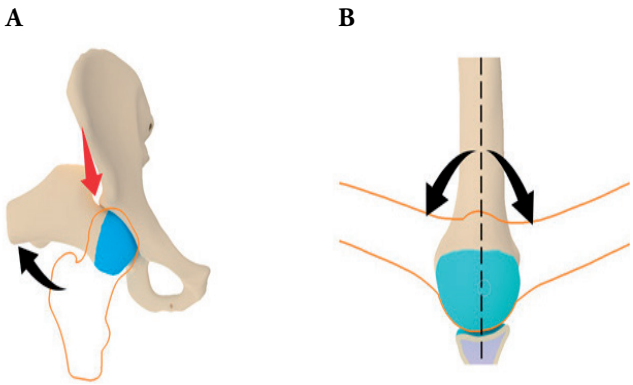

Fig. 1: Mobility of the hip and shoulder.
A. The intrinsic "stable" hip joint caused by the deep acetabular socket has a high stability at the expense of a limited mobility (red arrow).
B. The "mobile" shoulder joint is freely moveable over a wide range (black arrow) but lacks intrinsic stability.

the deltoid muscle in shoulder function. The coracoid extension over the glenohumeral joint increased in size over time and can mechanically limit anterior translation of the humerus relative to the glenoid in 90 degrees of shoulder abduction.

Like the shoulder, the hip is part of a complex system together with the pelvis and sacrolumbar spine. The human upright position, unlike other bipedal vertebrates, is characterized by lower extremities that are positioned right under the trunk. All other bipedals ambulate with flexed hips and knee joints. Therefore, in addition to the development of a lumbar lordosis, a pelvic lordosis developed and the hip joint was repositioned through both pelvic tilt and hip extension. This particular evolutionary process has enabled human fully upright ambulation with the trunk's center of gravity straight above the pelvis. This made the human hip an intriguing structure with a double extension, unique in nature.[1] As a result of this upright position, the hip became subjected to higher forces and developed in a vertical orientation as this decreases the necessary muscle force which is required to counteract gravity. The human pelvis changed from long, narrow and flat, to short wide and curved with a relatively long femur. This all has led to a remarkable efficiency of the human gait.[2] These bony alterations were accompanied by soft-tissue changes, especially changes in the muscle volume, moment arms and sometimes function. A typical example of these muscular changes is the transformation of the gluteus maximus, which transformed from a relatively small muscle into the strongest muscle of the human body, which straightens the hip.[3] In the shoulder the deltoid muscle doubled in its proportional representation and constitutes approximately 41% of the scapulohumeral muscle mass, making it an important stabilizer of the shoulder.[4]

The acetabulum has a crescent-moon morphology that wraps around the superior, anterior and posterior aspects of the femoral head, facilitating a better load distribution. In contrast, the glenohumeral joint is more or less like a golf ball on a tee. The larger the area of contact between the cup and ball, the more stable the joint is. As a result of this, the pelvis is a relatively rigid structure compared to the freely moveable structure of the scapula as a result of a bony mismatch.[5] This tendency towards instability of the shoulder is compensated for by many surrounding static and dynamic stabilizers, such as the labrum, joint capsule and glenohumeral ligaments and the deltoid and rotator cuff musculature.

A comparative overview between the two ball and socket joints has been made in Table 1.

Table 1: Comparison between two ball and socket joints, the shoulder and the hip[5-7]

	Shoulder	Hip
Primary function	Mobility	Stability
Primary stabilizers	Dynamic stabilizers	Static stabilizers
Shape	Inverted comma / pear	Crescent-moon
Average vertical dimension	36mm	51mm
Average transverse diameter	29mm	49mm
Average depth	3.4mm	13mm
Ball: socket ratio	3:1	1.2:1
Degrees of coverage ball	96	170
Peak forces (x bodyweight)	<1	2.7-4.3
Normal range of motion		
Flexion	150-180	100-120
Extension	50-60	30
Abduction	180	40-45
Adduction	0	20-30
External rotation	70-90	45-50
Internal rotation	70-90	40-45

Anatomy labrum

The anatomy of the glenoid and acetabular labrum has similarities but also some evident differences (Table 2). Both the glenoid and acetabular labrum are a rim of fibrocartilaginous structure, consisting of mostly type 1 collagen fibers, which is aligned along the outer ridge of both sockets.[6,7]

The glenoid labrum forms a complete circle and acts both as a vacuum seal for the glenohumeral socket as well as a fibrous anchor from which the biceps tendon and

glenohumeral ligaments take their origin. The long head of the biceps tendon passes intra-articularly and inserts into the supraglenoid tubercle. It is often continuous with the superior portion of the labrum. The glenoid labrum is loosely attached superiorly above the equator and significant anatomic variability exists in this particular region between individuals.[6] In contrast, the anterior inferior labrum is intimately attached to the glenoid rim and any detachment would indicate an abnormality.[8]

The human acetabular labrum is a horseshoe-like structure attached to the bony acetabular edge. Together with the inferiorly situated transverse acetabular ligament it forms a complete circle.[9]

Table 2: Comparison between the glenoid and acetabular labrum[13,20,23,25,30]

	Glenoid labrum	Acetabular labrum
Shape	Circle	Horseshoe (Forms a complete circle together with the transverse ligament)
Shape in cross section	Triangular	Triangular
Average thickness	3 mm	4.7 mm
Average width	4.0 mm (2.5 SD, range 1.1-9.3 mm)	5.5 mm
Variability	Lots of variation, such as Sublabral foramen and Buford complex	Lots of variation, such as Posterior labrum sulcus
Orientation	Circumferential around bony rim	Anteriorly: parallel Posteriorly: perpendicular
Innervation	Free nerve endings, mainly derived from the (C4), C5, C6, and C7 nerve roots	Free nerve endings, mainly derived from the Quadratus femoris nerve and Obturator nerve (L4, L5, S1, S2 nerve roots)
Vascularity	Small branches of suprascapular -, circumflex scapular and humeral circumflex artery (derived from a. axillaris)	Periacetabular vascular ring, with branches of gluteal (derived from a. iliaca intima) and circumflex arteries (derived from a. femoralis profunda)
Insertions	Long head of biceps Long head of triceps Glenohumeral ligaments	Transverse acetabular ligament

The collagen architecture of the glenoid labrum consists of three layers: (i) the superficial layer, with randomly orientated and loosely packed collagen fibres, considered to aid in lubrication; (ii) an intermediate layer; and (iii) the core layer, which forms the bulk of the tissue.[10] The acetabular labrum can be divided into two parts, the articular (internal) and non-articular (external) surface. On the articular surface the labrum indirectly connects to the bone via the hyaline cartilage, while the external part, mainly composed of dense connective tissue, attaches directly to the bony rim on the non- articular side.[7,9]

The morphology of the labrum differs depending on its localization and therefore the labrum is divided into different sections (Fig. 2). The fiber bundles of the glenoid labrum run in a circumferential orientation around the bony rim, with the anterior and inferior parts of the labrum smaller than the superior and inferior parts and most firmly attached posteriorly and inferiorly.[11] While the collagen fibers on the anterior side of the acetabular labrum have a parallel organization to the labral-chondral junction, the posterior fibers are oriented more perpendicularly.[12] The acetabular labrum is wider and thinner in the anterior region and thicker in the posterior region.[9]

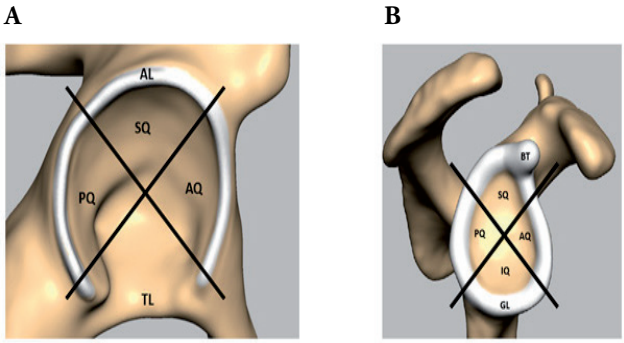

Fig. 2: Labral quadrants of (A) the hip and (B) shoulder.
A. AL: Acetabular Labrum, TL: Transverse Ligament, AQ: Anterior Quadrant, SQ: Superior Quadrant, PQ: Posterior Quadrant.
B. GL: Glenoid Labrum, BT: Biceps tendon, AQ: Anterior Quadrant, SQ: Superior Quadrant, PQ: Posterior Quadrant, IQ: Inferior Quadrant.

In the glenoid labrum, vascular supply occurs mainly in the peripheral attachment to the joint capsule.[6] The superior and anterosuperior regions are less vascularized.[6,7] As a result of this the labrum has limited ability to repair itself, however increased microvascularisation is found in case of a labral tear.[9] For the acetabular labrum again, there is a relatively poor vascular supply, in which there are also differences between the anatomic zones. At the capsular contribution zone (zone I), there is a better vascularity than at the articular side zone (zone II). However, here there are no differences in vascularity patterns in the anterior, superior, posterior, and inferior labral regions, nor were they different in torn versus intact specimens.[13] So, the internal part of the acetabular labrum is avascular as blood vessels are only seen in the peripheral one-third of the labrum, entering from the joint capsule. This may have implications for treatment, similar to those described for the meniscus of the knee.[13]

Corresponding with the vasculature the innervation of the labrum is unevenly distributed as well. The shoulder labrum is known to contain free nerve endings in its periphery, probably needed for proprioceptive feedback.[14] For the acetabular labrum, most free nerve endings can be found in the anterosuperior region.[15,16]

Anatomic variants of the labrum have been described in both the shoulder and hip. Often it is triangular in cross section, but it varies in size and thickness, sometimes being a prominent intra-articular structure with a free inner edge, sometimes round, flattened and at other times being virtually absent.[17,18] Known anatomic variations for the glenoid labrum are for example the sublabral sulcus or the Buford complex.[10] A sublabral foramen or hole is defined as a complete detachment of the labrum from the glenoid, as opposed to a sublabral recess or sulcus, where the labrum is lifted off the glenoid at the articular surface but there is still a deeper attachment.[10] The Buford complex is an example of one of these variants whereby the anterosuperior labral tissue is absent and the middle glenohumeral ligament takes on a cordlike appearance.[10] A common anatomic variant of the acetabular labrum is the posterior sublabral sulcus, often mistaken for labral pathology.[19]

Function labrum

As the anatomy of the glenoid and acetabular labrum are quite comparable, they show fundamental similarities in function as well. However, the exact functional role of the labrum is still undefined and discussed, it is known to function as an insertion site for other anatomical structures and to play a role in proprioception and nociception (Table 2). In addition to this, it is an essential part for stabilizing both the glenohumeral and acetabulofemoral joints.

The glenoid labrum, with the anteroinferior part being the major stabilizing part, increases the surface and volume of the shallow glenoid cavity (Table 3). Respectively the acetabular labrum fulfills the same function for the acetabular socket, however this function is less prominent in the hip as the bony acetabular socket is already deeper and much more stable than the glenoid socket.

Table 3: Comparison of labral functions between shoulder and hip[27,31]

Labral function	Shoulder	Hip
Increases surface	33%	28%
Increases volume	Up to 50%	Up to 33%
Tensile properties of intra-articular tissues elastic modulus (mean Mpa ± SD)	26.2 ± 7.3	66.4 ± 42.2
% of load carried by labrum	Not applicable	Normal: 1-2% DDH: 4-11%

Furthermore, it has been theorized that the labrum functions as a chock-block, limiting the translation of the ball within the socket, keeping the femoral and humeral head centralized, by forming a bumper around their socket.[20,21] Concavity compression is an extension of this hypothesis, whereby the humeral head is compressed into the cavity of the glenoid by the rotator cuff musculature, further stabilizing the shoulder. This mechanism has been calculated to increase stability with an intact labrum and may be due to its role in centralizing the head within the glenoid.[17] In addition, the labrum further stabilizes the joints by acting as a seal around the joint space, creating an intraarticular vacuum within the joint, which confers stability.[18,22] It enhances joint lubrication and due to this seal, a layer of pressurized fluid is kept in the joint cavity, as the labrum restrict the synovial fluid from flowing out of the central joint compartment.[23] This layer of pressurized fluid also keeps the cartilage layers of the head and socket separated, preventing solid-on-solid contact, and functions as a shock absorber and load distributor.[20,21,24] The labrum ensures a uniform distribution of forces over the cartilage, further helped by fluid in the cartilage giving it a cushioning function, resulting in a wider distribution of the transferred forces and lower cartilage strain.[20,25] Labral loss or labral pathology has been shown to decrease the contact area of the articular surface of the glenohumeral joint, increasing the contact pressure. Absence of the acetabular labrum can result in almost doubling of the cartilage-on-cartilage stresses.[20,24,26]

Labral pathology

Similarities / differences

The labrum often is involved in pathology. Labral pathology is more prevalent with advancing age. Beyond the age of 40, it commonly represents a natural degenerative process in the shoulder and hip, just as it is known for meniscal pathology in the knee.[27] By the 8th decade of life, up to 100% of cadaver specimens show signs of labral tearing in the hip and shoulder joint.[27] The presence of a labral tear does not in itself necessitate surgery.[27]

Labral tears may have a variety of clinical presentations associated with a wide degree of clinical findings. There may or may not be a history of trauma. In the presence of a recalled incident such as twisting or falling, the trauma can vary from severe to very mild. The injury is usually caused by the joint being stressed in rotation. On examination, range of motion may not be limited but there may be pain at the extremes. There are a number of clinical tests, but generally speaking the combined movement of flexion and rotation causes pain in the joint.

A clear difference in labral pathology for hip and shoulder is that the location of the labral tear has shown big differences in clinical symptoms for the shoulder, as it has no effect on patient outcome in acetabular lesions.[28]

The majority of acetabular labral lesions occur in the anterior region of the labrum, however Asian studies more often report the occurrence of labral tears in the posterior region, possibly due to a different lifestyle as they sit on the ground in a squatting position.[28-30] Possible explanations for this phenomenon are that the anterosuperior region of the acetabular labrum is exposed to the highest strains, has a relatively poor vascularization and because of its orientation of the collagen fibers.[12,18] In addition to this, it is thought that the acetabular labrum takes on a weight-bearing role at the extreme ranges of motion with excessive forces leading to tearing.[28]

The exact distribution of the different labral lesions for the shoulder and hip is summarized in Table 4.

Table 4: Distribution of labral tears of shoulder and hip[27,31,66,67]

Hip, Labral tears	Anterior	Posterior	Inferior	Superior
Western countries	61-92% (mainly anterosuperior)	7-25%	Not applicable	0-15%
Asian countries	0-20%	50-86%	Not applicable	0-10%
Shoulder, Labral tears	**Anterior**	**Posterior**	**Inferior**	**Superior**
Mondial	Rare	15-55%	0-6%	55-72% / 80-90%
Specific clinical lesions	Anterosuperior (1/2): SLAP lesions, Anatomic variants (sublabral or Weitbrecht's foramen, Bufford complex)	Posteroinferior (4/5): Reverse Bankart POLPSA, posterior GLAD, Kim's lesion	Anteroinferior (3/4): Bankart, ALPSA, Perthes, GLAD	SLAP lesions (6/1/2): mostly type II, Andrew lesion

Labral pathology correlated to age

Roughly, three groups of patients with corresponding pathology of the labrum for both hip and shoulder seems present. For reasons of clinical relevance, we classify them according to age.

1. young patients, in which no degenerative changes are being expected. (A-)traumatic instability is the most presented clinical symptom.
2. middle aged patients, in which early and distinct degenerative processes are being found. Impingement is the most related clinical symptom, often resulting in pain.
3. older patients, often having evidence of degeneration. Osteoarthritis is the most related clinical symptom, often resulting in stiffness and pain.

For the *younger patients*, a frequent cause of labral pathology is formed by the group of traumatic labral lesions. For the shoulder such a lesion often results in instability. Classic

examples are the Bankart, Perthes, ALPSA and GLAD lesions.[31] In the hip, traumatic lesions are less frequent for this age group.[32]

Traumatic hip dislocation sometimes will lead to recurrent instability after relocation.[33] This injury pattern show resemblance with that of traumatic shoulder instability. Matching lesions are: a Bankart-like lesion of the posterior labrum in the hip, a defect in the ischiofemoral ligament, similar to inferior glenohumeral ligament laxity of the shoulder; relative retroversion of femoral neck angle similar to loss of retroversion of the humeral neck and finally, Pipkin type 1 fracture of the femoral head, resembling a Hill-Sachs lesion of the humeral head.

Shoulder instability does not always mean labral pathology is present. Other pathologic conditions might lead to instability as well, such as Ehlers-Danlos / Marfan syndrome, neuromuscular disorders, muscle dysfunction or acquired or congenital bony defects.[34]

A major group of labral shoulder pathology often seen in the middle-aged patients, is that of the superior labrum (SLAP) lesions, mostly not resulting in instability problems of the shoulder. SLAP lesions combine labral lesion and lesion of the proximal insertion of the long head of the biceps brachii tendon. The most frequent form is a SLAP type II lesion. They can be due to recurrent impingement or due to traction of the long head of the biceps.[35-37] Another more degenerative type of labral pathology is seen in Walch's internal impingement, resulting in posterosuperior or posteroinferior lesions of the labrum. It is a result of repeated contact between the deep surface of the cuff and the posterosuperior aspect of the labrum, which in the end takes on a degenerative aspect, with a corresponding kissing lesion of the cuff.[38]

In this specific *middle-aged group*, the occurrence of acetabular labral tears can have a variety of causes. The majority of labral pathology is idiopathic.[39] The rest of acetabular labral tears is most commonly due to the so-called femoroacetabular impingement syndrome (FAI). However, the exact prevalence of labral pathology remains unclear as many other abnormalities match the aging process. High percentages of labral tears have been found in several cadaveric studies, with reports of prevalences up to 93-96%.[9,40] Most patients with acetabular labral tears complain about hip and/or groin pain, buttock pain, or radiating pain to the knee, with a long duration, often with a normal range of motion. In addition to this they can have mechanical symptoms such as clicking, locking, catching and giving way.[28,29]

For the *older patients*, pain associated with osteoarthritis is the most presented symptom for both shoulder and hip joints, whereby again similarities are present. Labral lesions are being associated with early onset of shoulder and hip osteoarthritis. In 74% of patients with labral fraying or a labral tear this is accompanied with chondral damage, which is often more severe in the affected quadrant.[40]

Similar labral pathology for both hip and shoulder can be seen in common clinical syndromes. For example, in cases of developmental dysplasia of the hip (DDH), the acetabulum is shallow, meaning that the femoral head not firmly fits into the socket. Developmental Dysplasia of the Hip (DDH) is commonly associated with labral hip pathology. DDH with an incomplete coverage of the femoral head show resemblance with pathology of shoulder instability. The role of the labrum as a weight carrier increases substantially in DDH compared to the normal situation.[41] A combination of typical bony abnormalities can result in anterior hip instability or pain and in time, early degenerative changes due to these abnormal hip joint forces, will occur.

The impingement syndrome for the shoulder (nowadays called subacromial pain syndrome or SAPS) show great resemblances with the femoroacetabular impingement syndrome (FAI) for the hip joint. These types of repetitive lesions show similarities in labral pathology, resulting in a probable cause for pain. FAI consists of a group of structural acetabular and femoral abnormalities that result in abnormal contact between the anterior and anterosuperior femoral head-neck junction and acetabular rim during hip flexion and internal rotation. This contact can directly cause pain but also results in compromise of the underlying articular structures including the acetabular labrum and articular cartilage of the hip joint. These conditions can eventually result in focal labral tears, labral detachment, and complex degenerative tears of the labrum in this region. Also, partial and/or full-thickness cartilage wear and delaminating cartilage lesions along the anterosuperior peripheral aspects of the acetabular articular surface can appear, possibly in time resulting in early appearance of coxarthrosis.

For the shoulder, cuff tear arthropathy is a degenerative condition caused by longstanding massive cuff tear problems resulting in a high position of the humeral head against the undersurface of the acromion. The loss of these important stabilizers can eventually lead to a complex pattern of joint degeneration, referred to as rotator cuff tear arthropathy. The often superior migrated position of the humeral head under the acromial arc, shows great resemblance with the ball and socket appearance of the hip joint with a full covering of the femoral head, creating a more intrinsic stable situation, compensating for the loss of surrounding tissues such as cuff, labrum and capsule over time.

Therapy

Appropriate management of labral pathology begins with an understanding of the anatomy, etiology of pathology, and clinical correlation of pathology with symptoms and shoulder or hip dysfunction, this to prevent inappropriate surgical procedures. Nevertheless, little research on labral pathology has been done. Some describe significant improvements with conservative therapy.[42,43] However, there are no studies investigating the long-term outcome of conservative management neither on surgical treatment.

Labral tears tend to occur on the articular non-vascular edge and may therefore not heal with conservative treatment.[40] It is not clear whether an "unhealed" labrum will remain symptomatic or whether it predisposes to early degenerative changes in the hip joint. In many patients, the labrum tear is associated with hip degeneration. However, in these patients the tear may have occurred as a result of degeneration instead of provoking it.[9,39,40,44]

In general, several different strategies of treatment have been utilized to treat labral tears. Conservative treatment, such as non- steroidal anti-inflammatory drugs, physical therapy, hip joint injection (with corticosteroids) and adjustment of the patient's activity patterns, are the first treatments of choice.

For the hip, arthroscopic management of hip disorders has received an increased amount of attention in the last few years. Although, the concept of hip arthroscopy was first introduced as early as 1931 by Burman.[45] When conservative treatment fails, operative treatment is increasingly proposed as the next treatment of choice. Surgical options are labral debridement or resection, labral repair or labral reconstruction. The way of thinking about these surgical interventions for labral tears has changed and is still subject to change. In the past, labral resection was the first treatment of choice. Partial labral debridement generally shows good results. However, this success significantly decreases in the presence of chondral lesions or FAI.[46] Nowadays, several studies indicate that a labral sparing treatment should be the golden standard, if the quality of the labrum allows it.[47] Not only labral repair or reconstruction can almost completely recover the labrum seal and protect the hip from increased cartilage strains, more importantly, it seems to protect the hip joint for a rapid progression of osteoarthritis as less cartilage damage was being found two-years postoperatively compared to a treatment with labral resection.[25,47,48] Up to present day, no prospective randomized trials have been performed to look at the long-term outcome of the different treatment options for labral hip pathology. However, short-term outcome in hip arthroscopy versus physiotherapy in patients with FAI has been looked at more recently.[49] They reported that hip arthroscopy and personalized hip (physio-)therapy both improved hip-related quality of life for patients with FAI, but hip arthroscopy led to a greater improvement than did personalized hip (physio-)therapy in their short time follow up study. Provisional short or mid-term studies performed so far, suggest that hip arthroscopy is an effective treatment option when appropriate patient selection and indications have been made.[46,50-53] Further follow-up and research are needed to look at the pros and cons for the patient.

For the shoulder, the same treatment algorithm is possible for labral pathology as for the hip. Again, conservative treatment is often the first treatment of choice, such as: activity modulation, anti-inflammatory medication and rest to relieve the symptoms. After that, patients may begin a rehabilitation program with the goals of improving glenohumeral and scapulothoracic motion and increasing the strength and endurance of the rotator cuff

and scapulothoracic muscles. Appropriate classification of the patient and the demands they place on their shoulder joint, helps to determine the best approach of management of labral tears. In many cases, nonsurgical methods are effective in relieving symptoms and if possible, helps with healing of the injured structures. Surgical options typically are being preserved for young high-demanding athlete patients or patients with heavy occupational demands involving frequent overhead activity, for whom conservative treatment methods are ineffective. Treatment varies depending on the type, size and location of labral tear and the degree of involvement of the long head of biceps tendon (LHBT) substance. Options include labral debridement, labral repair, LHBT tenodesis, and or tenotomy. A comparison between shoulder versus hip labral pathology treatment is summarized in Table 5.

Table 5: General comparison between shoulder versus hip labral pathology

	Shoulder	Hip
General treatment	Conservative treatment Operative treatment	Conservative treatment Operative treatment
Treatment options	Labral debridement, Labral repair, LHBT tenodesis / tenotomy, Bony reconstruction (ea. Latarjet procedure), Arthroplasty	Labral debridement, Labral resection, Labral repair, Osteotomies (periarticular (ea. Chiari / Triple)), Shelf procedure, Arthroplasty

For the shoulder, a clear review analysis of treatment options for labral tears is recently been published.[54] For the anterior or inferior lesions often associated with instability, a multitude of surgical techniques have been described. This subject of glenohumeral instability remains complicated. Controversy remains regarding etiology, pathophysiology and (after-) treatment. The role of open and arthroscopic treatment methods continues to be debated. Nonoperative management still maintains a role as an early treatment modality, but high recurrence rates are being reported.[55] Nowadays, the presence of bony deficiency is considered to be very important as a cause of glenohumeral instability. Some degree of bony injury either to the glenoid or humeral head (together called bipolar bony lesions) is thought to occur in almost every patient with (traumatic) instability of the shoulder. To address this problem, bony reconstruction is more and more recommended, especially in patients with glenoid bone loss more than (15 to) 20%, or in patients with absence of the labrum, such as in revision casus.[56-58]

For the group of superior labrum lesions, also referred to as SLAP lesions, treatment is also still highly debated. In the case of failed nonoperative management, surgical treatment can be performed, mainly being reserved for the young high demanding patients.[59,60] But results in literature of surgical treatment show great variation in success.[54,59,61] For low-demanding patients, or patients with concomitant rotator cuff pathology, a long head biceps tenodesis or tenotomy is the preferred treatment of choice.[62,63]

For posterior labral pathology, mainly presenting in pain more than instability, initial nonoperative treatment is also being applied. When this fails, arthroscopic treatment can be performed.[38,64]

Conclusion

In conclusion, there are clear similarities between the shoulder and hip labrum morphology. An important similarity is the role of the labrum as a seal around the joint, creating an intraarticular vacuum in combination with the enhancement of joint lubrication. This allows for protection of the cartilage layers of the head and socket, creating shock absorption and load distribution. Another similarity is the enlargement of the contact area at the glenohumeral and the acetabulofemoral joint.

Pathology of the labrum has showed to increase cartilage loss resulting in signs of early artrosis, which is more important in the hip joint, due to its weightbearing character. Treatment options for labral pathology for the shoulder and hip show great resemblances, including arthroscopic procedures such as labral debridement or repairs. However, there are different treatment indications, which are probably still subject to change since little clinical evidence with long term results is present for either intervention both conservative as well as surgical. For the shoulder labrum, instability and/or superior labral pathology including biceps tendinopathy is the most presented clinical symptom. For the hip labrum, femoroacetabular impingement is the most related clinical symptom.

No general advice for the management of labral pathology can be given. For any new technology or intervention, it is important to have phased introductions based on clinical evidence in order to create a safe and optimal treatment method for the patient.[65]

References

1. Schlösser TPC, Janssen MMA, Vrtovec T, et al, 2014 Evolution of the ischio-iliac lordosis during natural growth and its relation with the pelvic incidence. Eur Spine J 23: 7: 1433-1441.
2. Abitbol MM, 1988 Effect of posture and locomotion on energy expenditure. Am J Phys Anthropol 77: 2: 191-199.
3. Hogervorst T, Bouma HW, de Vos J, 2009 Evolution of the hip and pelvis. Acta Orthop Suppl 80: 336: 1-39.
4. Rockwood Charles A, Matsen III Frederick A, Wirth Michael A, Lippitt Steven B, Fehringer Edward V SJW. The Shoulder.
5. Abood A, Jaffar S, Qusay M, 2006 Biomechanical Aspects of Shoulder and Hip Articulations: A Comparison of Two Ball and Socket Joints. Biomechanical aspects of shoulder and hip articulations. A. Engineering 2: 1: 1-14.
6. Cooper DE, Arnoczky SP, O'Brien SJ, Warren RF, DiCarlo E, Allen AA, 1992 Anatomy, histology, and vascularity of the glenoid labrum. An anatomical study. J Bone Joint Surg Am 74: 1: 46-52.
7. Petersen W, Petersen F, Tillmann B, 2003 Structure and vascularization of the acetabular labrum with regard to the pathogenesis and healing of labral lesions. Arch Orthop Trauma Surg 123: 6: 283-288.
8. Dodson CC, Dines DM, Dines JS, Walch G, Williams GR, 2014 Controversies in Shoulder Instability. Wolters Kluwer.
9. Seldes RM, Tan V, Hunt J, Katz M, Winiarsky R, Fitzgerald RH, 2001 Anatomy, histologic features, and vascularity of the adult acetabular labrum. Clin Orthop Relat Re 382.
10. Smith C, Funk L, 2010 The glenoid labrum. Shoulder Elb 2: 2: 87-93.
11. De Coninck T, Ngai SS, Tafur M, Chung CB, 2016 Imaging the Glenoid Labrum and Labral Tears. RadioGraphics 36: 1628-1647.
12. Cashin M, Uhthoff H, Neill MO', Beaulé PE, 2008 Embryology of the acetabular labral- chondral complex. Bone Jt Surg [Br] 90: 8: 1019-1024.
13. Kelly BT, Shapiro GS, Digiovanni CW, Buly RL, Potter HG, Hannafin JA, 2005 Vascularity of the hip labrum: a cadaveric investigation. Arthroscopy 21: 1: 3-11.
14. Vangsness CT, Ennis M, Taylor JG, Atkinson R, 1995. Neural anatomy of the glenohumeral ligaments, labrum, and subacromial bursa. Arthroscopy 11: 2: 180-184.
15. Kim YT, Azuma H, 1995 The Nerve Endings of the Acetabular Labrum. Clin Orthop Relat Res 320: 176-181.
16. Alzaharani A, Bali K, Gudena R, et al, 2014 The innervation of the human acetabular labrum and hip joint: an anatomic study. BMC Musculoskelet Disord 15: 1: 41.
17. Fehringer EV, Schmidt GR, Boorman RS, et al, 2003. The anteroinferior labrum helps center the humeral head on the glenoid. J Shoulder Elb Surg 12: 1: 53-58.
18. Crawford MJ, Dy CJ, Alexander JW, et al, 2007 The 2007 Frank Stinchfield Award. The biomechanics of the hip labrum and the stability of the hip. Clin Orthop Relat Res 465: 465: 16-22.
19. Dinauer PA, Murphy KP, Carroll JF, 2004 Sublabral sulcus at the posteroinferior acetabulum: a potential pitfall in MR arthrography diagnosis of acetabular labral tears. AJR Am J Roentgenol 183: 6: 1745-1753.
20. Ferguson SJ, Bryant JT, Ganz R, Ito K, 2003 An in vitro investigation of the acetabular labral seal in hip joint mechanics. J Biomech 36: 2:171-178.
21. Ferguson SJ, Bryant JT, Ganz R, Ito K, 2000 The acetabular labrum seal: a poroelastic finite element model. Clin Biomech 15: 6: 463-468.

22. Habermeyer P, Schuller U, Wiedemann E, 1992 The intra-articular pressure of the shoulder: an experimental study on the role of the glenoid labrum in stabilizing the joint. Arthroscopy 8: 2: 166-172.
23. Dwyer MK, Jones HL, Hogan MG, Field RE, McCarthy JC, Noble PC, 2014 The acetabular labrum regulates fluid circulation of the hip joint during functional activities. Am J Sports Med 42: 4: 812-819.
24. Ferguson SJ, Bryant JT, Ganz R, Ito K, 2000 The influence of the acetabular labrum on hip joint cartilage consolidation: A poroelastic finite element model. J Biomech 33: 8: 953-960.
25. Greaves LL, Gilbart MK, Yung AC, Kozlowski P, Wilson DR, 2010 Effect of acetabular labral tears, repair and resection on hip cartilage strain: A7T MR study. J Biomech 43: 5: 858-863.
26. Greis PE, Scuderi MG, Mohr A, Bachus KN, Burks RT, 2017 Glenohumeral articular contact areas and pressures following labral and osseous injury to the anteroinferior quadrant of the glenoid. J shoulder Elb Surg 11: 5: 442-451.
27. Medicine A college of occupational and enviremental. Shoulder disorders guideline.
28. Groh MM, Herrera JA, 2009 Comprehensive review of hip labral tears. Curr Rev Musculoskelet Med 2: 2: 105-117.
29. Lewis CL, Sahrmann SA, 2006 Acetabular labral tears. Phys Ther 86: 1.
30. Bsat S, Frei H, Beaulé PE, 2016 The acetabular labrum: a review of its function. Bone Joint J 98B: 6: 730-735.
31. Clavert P 2015 Glenoid labrum pathology. Orthop Traumatol Surg Res 101: S19-S24.
32. Suarez-Ahedo C, Gui C, Rabe SM, Walsh JP, Chandrasekaran S, Domb BG, 2017 Relationship Between Age at Onset of Symptoms and Intraoperative Findings in Hip Arthroscopic Surgery. Orthop J Sport Med 5: 11: 232596711773748.
33. Mofidi A, Sankar R, Kutty S, Kaar K, Curtin W, 2002 Traumatic dislocation of hip joint following low-velocity trauma, similarities to glenohumeral instability. Eur J Orthop Surg Traumatol 12: 2: 108-114.
34. Krzyżanowski W, 2012 The use of ultrasound in the assessment of the glenoid labrum of the glenohumeral joint. Part I: Ultrasound anatomy and examination technique. J Ultrason 12: 49: 164-177.
35. Keener JD, Brophy RH, 2009 Superior labral tears of the shoulder: pathogenesis, evaluation, and treatment. J Am Acad Orthop Surg 17: 10: 627-637.
36. Beltran J, Jbara M, Maimon R, 2003 Shoulder: labrum and bicipital tendon. Top Magn Reson Imaging 14: 1: 35-49.
37. Musgrave DS, Rodosky MW, 2001 SLAP lesions: current concepts. Am J Orthop (Belle Mead NJ) 30: 1: 29-38.
38. Lévigne C, Garret J, Grosclaude S, Borel F, Walch G, 2012 Surgical Technique Arthroscopic Posterior Glenoidplasty for Posterosuperior Glenoid Impingement in Throwing Athletes. Clin Orthop Relat Res 470: 6: 1571-1578.
39. Santori N, Villar RN, 2000 Acetabular labral tears: result of arthroscopic partial limbectomy. Arthroscopy16: 1: 11-15.
40. McCarthy JC, Noble PC, Schuck MR, Wright J, Lee J, 2001 The Otto E. Aufranc Award: The role of labral lesions to development of early degenerative hip disease. Clin Orthop Relat Res 393: 25-37.
41. Henak CR, Ellis BJ, Harris MD, Anderson AE, Peters CL, Weiss JA, 2011 Role of the acetabular labrum in load support across the hip joint. J Biomech 44: 12: 2201-2206.
42. Yazbek PM, Ovanessian V, Martin RL, Fukuda TY, 2011 Nonsurgical treatment of acetabular labrum tears: a case series. J Orthop Sports Phys Ther 41: 5: 346-353.

43. Ikeda T, Awaya G, Suzuki S, Okada Y, Tada H, 1988 Torn acetabular labrum in young patients. Arthroscopic diagnosis and management. J Bone Jt Surg Br 70: 1: 13-16.
44. Dorrell JH, Catterall A, 1986 The torn acetabular labrum. J Bone Joint Surg Br 68: 400-403.
45. Burman MS, 2001 Arthroscopy or the direct visualization of joints: an experimental cadaver study 1931. Clin Orthop Relat Res 390: 5-9.
46. Safran MR, 2010 The acetabular labrum: anatomic and functional characteristics and rationale for surgical intervention. J Am Acad Orthop Surg 18: 338-345.
47. Espinosa N, Rothenfluh DA, Beck M, Ganz R, Leunig M, 2006 Treatment of Femoro-Acetabular Impingement. J Bone Jt Surg 88: 5: 925-935.
48. Philippon MJ, Nepple JJ, Campbell KJ, et al, 2014 The hip fluid seal-Part II: The effect of an acetabular labral tear, repair, resection, and reconstruction on hip fluid pressurization. Knee Surgery, Sport Traumatol Arthrosc 22: 4: 722-729.
49. Griffin DR, Dickenson EJ, Wall PDH, et al, 2018 Hip arthroscopy versus best conservative care for the treatment of femoroacetabular impingement syndrome (UK FASHIoN): a multicentre randomised controlled trial. Lancet (London, England) 391: 10136: 2225-2235.
50. Ross JR, Larson CM, Bedi A, 2017 Indications for Hip Arthroscopy. Sport Heal A Multidiscip Approach 9: 5: 402-413.
51. Harris JD, 2016 Hip labral repair: options and outcomes. Curr Rev Musculoskelet Med 9: 4: 361-367.
52. Clohisy JC, St John LC, Schutz AL, 2010 Surgical Treatment of Femoroacetabular Impingement: A Systematic Review of the Literature. Clin Orthop Relat Res 468: 2: 555-564.
53. Robertson WJ, Kadrmas WR, Kelly BT, 2007 Arthroscopic Management of Labral Tears in the Hip. Clin Orthop Relat Res 455: 88-92.
54. Cagle PJ, Olujimi V, Parsons BO, 2018 Arthroscopic Treatment of Labral Tears: A Critical Analysis Review. JBJS Rev 6: 4: e4.
55. Rhee YG, Cho NS, Cho SH, 2009 Traumatic anterior dislocation of the shoulder: factors affecting the progress of the traumatic anterior dislocation. Clin Orthop Surg 1: 4: 188-193.
56. Shin S-J, Kim RG, Jeon YS, Kwon TH, 2017 Critical Value of Anterior Glenoid Bone Loss That Leads to Recurrent Glenohumeral Instability After Arthroscopic Bankart Repair. Am J Sports Med 45: 9: 1975-1981.
57. Jeon YS, Jeong HY, Lee DK, Rhee YG, 2018 Borderline Glenoid Bone Defect in Anterior Shoulder Instability: Latarjet Procedure Versus Bankart Repair. Am J Sports Med 036354651877697.
58. Shaha JS, Cook JB, Song DJ, et al, 2015 Redefining "Critical" Bone Loss in Shoulder Instability. Am J Sports Med 43: 7: 1719-1725.
59. Provencher MT, McCormick F, Dewing C, McIntire S, Solomon D 2013 A Prospective Analysis of 179 Type 2 Superior Labrum Anterior and Posterior Repairs. Am J Sports Med 41: 4: 880-886.
60. Taylor SA, Degen RM, White AE, et al, 2017 Risk Factors for Revision Surgery After Superior Labral Anterior-Posterior Repair: A National Perspective. Am J Sports Med 45: 7: 1640-1644.
61. Park J-Y, Chung S-W, Jeon S-H, Lee J-G, Oh K-S, 2013 Clinical and Radiological Outcomes of Type 2 Superior Labral Anterior Posterior Repairs in Elite Overhead Athletes. Am J Sports Med 41: 6: 1372-1379.
62. Thorsness RJ, Romeo AA, 2017 Diagnosis and Management of the Biceps- Labral Complex. Instr Course Lect 66: 65-77.
63. Frank RM, Cotter EJ, Strauss EJ, Jazrawi LM, Romeo AA, 2018 Management of Biceps Tendon Pathology. J Am Acad Orthop Surg 26: 4: e77-e89.
64. Bottoni CR, Franks BR, Moore JH, DeBerardino TM, Taylor DC, Arciero RA, 2005 Operative stabilization of posterior shoulder instability. Am J Sports Med 33: 7: 996-1002.

65. McCulloch P, Feinberg J, Philippou Y, et al, 2018 Progress in clinical research in surgery and IDEAL. Lancet 392: 10141: 88-94.
66. Suarez-Ahedo C, Gui C, Rabe SM, Walsh JP, Chandrasekaran S, Domb BG. Relationship Between Age at Onset of Symptoms and Intraoperative Findings in Hip Arthroscopic Surgery.
67. Simons P, Joekes E, Nelissen RG, Bloem JL, 1998 Posterior labrocapsular periosteal sleeve avulsion complicating locked posterior shoulder dislocation. Skeletal Radiol 27: 10: 588-590.

3

Chapter 3

Validation of the Dutch version of the Oxford Shoulder Score

Thomas Berendes · Peter Pilot · Jaap Willems · Hennie Verburg · Ron te Slaa

J Shoulder Elbow Surg. 2010;19:829-836

Abstract

Background: The Oxford Shoulder Score (OSS) is an internationally used patient-based outcome score. Up to now, it was not validated in Dutch. The purpose of this study was to produce a Dutch translation of the OSS and to test this version in terms of reliability and validity.

Methods: Translation of the OSS was done according to the guidelines in literature. One hundred and three patients completed the Dutch version of the OSS. Additionally, the Constant-Murley shoulder score, the (Dutch) Simple Shoulder Test (DSST) score, and SF-36 were included into the validation process. Feasibility and patient-burden parameters were also tested.

Results: One-hundred and three patients with general shoulder problems age 55 years (min-max: 21-81 ± 13 yrs.), sex ratio 2/3 (f/m) completed the Dutch version of the OSS and the SF-36. Internal consistency tested by the Cronbach's alpha (0.921) was high. Intra-class correlation coefficient was R = .981 (95% confidence interval: .961–.993) and the mean difference between both tests was 2.7 points (0–8). Construct validity was also tested by the Pearson correlation coefficient and showed a significant correlation ($p < .01$) between the Dutch version of the OSS and the other scores (DSST 0.61; the Constant-Murley score 0.64 and with most of the SF-36 sub-scores, except for 2 psychometric subscales, namely, mental health (0.15 [$p = .123$]) and general health (0.10 [$p = .316$])

Conclusion: The instrument proved to be valid by demonstrating significant correlations predicted by standard clinical assessments (DSST and Constant-Murley scores) and a generic patient-based instrument (SF-36). Application and evaluation in clinical trial proved feasible and understandable.

Introduction

Outcome measures play an increasingly important role in medical practice. However, measuring these outcomes in a simple, reliable and valid way is important. Since the 1980s, a large body of research has been devoted to the development of health-related quality of life (HRQOL) measures.[17] One can make a distinction between generic instruments instead of joint-specific and disease-specific questionnaires. The generic instruments are developed for evaluation of the overall status of a patient (e.g., SF-36), and the latter is a measure that attempts to quantify function following disease, injury, or treatment of a specific joint or body part. Outcome instruments intended for patients need 2 essential requirements: 1) that it measures what it is supposed to, and 2) that this measure is made with the minimum of error, e.g., validity and reliability.[30]

To use an outcome instrument in a different language from which it was originally designed and validated, one must take into account cross-cultural differences. Cross-cultural adaptation has 2 components: the translation of the HRQOL measure and its adaptation, i.e. a combination of the literal translation of individual words and sentences from one language to another and an adaptation with regard to idiom and to cultural context and lifestyle.[17] For instance, by translation a double denial might enter, or the type of toilet used in a country might differ (French versus European toilets) giving different scores for this question in different countries. The presence of culturally equivalent instruments would allow direct international comparison of national studies.[17]

Regarding the shoulder, several patient oriented outcome measures are validated and available in Dutch. The most used are the Disabilities of the Arm, Shoulder and Hand Questionnaires (DASH), and Simple Shoulder Test (SST). The DASH is a 30-point patient-based, non-joint specific outcome measure.[21] In other words, it is a region specific outcome measure. The SST is a shoulder specific patient based outcome score consisting of 12 "yes or no" questions.[2-3,39] One of the other frequently used shoulder specific patient questionnaires is the Oxford Shoulder Score (OSS), an international widely used patient-based outcome score consisting of 12 questions.[11] However, up to now, it was not validated in Dutch. The purpose of this study was to produce a Dutch translation of the OSS and test the Dutch version in terms of reliability and validity.

Materials and methods

The study was divided into 2 phases: First, the original 12-item questionnaire was translated into Dutch. Second, this version, with the added questions, was then tested for psychometric quality in a prospective study involving 103 patients.

Translation procedure

The Questionnaire was translated by an experienced medical language editing company in the Netherlands (ISYS Prepress Services, Winkel, the Netherlands). After this process, a reverse translation was made by an English mother-tongue individual. The similarities and differences were then reviewed by a committee of 2 experienced orthopaedic shoulder surgeons, a health scientist, and a resident orthopaedic surgery. The committee debated the discrepancies, and, if needed, decided to repeat the translation-back-translation process. The complete questionnaire was then tested on 20 patients with shoulder problems in the Reinier de Graaf Gasthuis to check the comprehensibility by means of the probe technique and was then adjusted to form the final version of the Dutch Oxford Score.[17]

Prospective trial

All 103 patients were recruited into a prospective study during July 2008 to December 2008 in two departments of Orthopaedics and Traumatology in the Netherlands (RdGG / OLVG = 60 / 43). This gave us 2 groups of patients, that for this procedure (translation, cross-cultural adaptation, and validation of a measuring instrument in 2 different centers) has not been performed in other cases in the past.[11,23,29,32,43] The 103 patients suffering from degenerative and inflammatory changes, together with post-traumatic problems of the shoulder region (arthritis, cuff pathology, or tendinitis calcarean), were selected from the out-patient clinics (Table 1). All patients included were identified by 1 of the experienced shoulder surgeons (RtS, WJW). After inclusion, the patients completed the Dutch version of the OSS together with 2 other patient-based outcome questionnaires (SST, Medical Outcome Study Short Form-36). The clinician-based outcome score (Constant-Murley shoulder assessment) was completed by the orthopaedic surgeon.

Oxford Shoulder Score (OSS)

The OSS is a joint-specific patient reported outcome score, including 2 subscales, that was developed for patients with a degenerative or inflammatory state of the shoulder.[11] It is not suitable for patients with instability of the shoulder. It contains 12 items to be answered by the patient independently. There are 5 categories of response for every question, corresponding to a score ranging from 1 to 5. Scores are combined to give a single score, with a range from 12 (best) to 60 (worst). The questions deal with pain (degree, time point) and possible handicaps in private and professional life. It is divided 20/40 corresponding to pain/activities of daily living.

(Dutch) Simple Shoulder Test (DSST)

This patient-reported outcome score deals with pain and shoulder function. The (Dutch) Simple Shoulder Test (DSST) score consists of 13 simple questions of which one can choose “yes” or “no” as an answer.[39]

Table 1: Demographic data

N (patients)	103
RdGG / OLVG	60 / 43
Mean age (years ± SD)	55 (±13)
Minimum–maximum age (years)	21–81
Male–Female	52–51
Left–Right shoulder	59–44
Diagnosis	
Impingement syndrome without rotator cuff tear	35
Rotator cuff tear with/without impingement syndrome	26
Glenohumeral arthritis	12
Acromioclavicular related problems	9
Frozen shoulder	8
Cervicobrachialgy	4
Post-traumatic	9
Pseudo artrosis of clavicular fracture	3
Others (pseudo artrosis of humeral fracture; AVN after fracture of proximal humerus; malunion after fracture of proximal humerus; lateral clavicular fracture; undefined fracture, scapula lata)	6

MOS SF-36

MOS SF-36 is a generic patient reported outcome score, consisting of 36-items.[4,5,42] It is widely used to assess the general health of the patient. It provides scores on 8 dimensions or subscales: physical function, social function, limitations caused by physical symptoms, limitations caused by emotional problems, general mental health, vitality, pain, and perception of general health. Each subscale has a minimum score of 0 points and a maximum score of 100 points.

Constant-Murley shoulder assessment

The Constant-Murley functional assessment of the shoulder (1987) is a clinician based outcome score, consisting of 4 subscales (10 items).[7] The outcome of the Constant-Murley shoulder assessment score has been validated against: the OSS, the change in day-to-day life, improvement, success of operation, SF-36, DASH, ASES, and the DSST.[12,28,33]

The Dutch Oxford Score was investigated for reproducibility, internal consistency, and (construct) validity. The same set-up and statistical methods were used as with the German version of the OSS.[20] Furthermore, the results will be compared with those of the original English Oxford Shoulder Score and those of the German Oxford Shoulder score.[11,20]

Psychometric testing

Reliability

In research, the term reliability means "repeatability" or "consistency".[35] A measure is considered reliable if it would give us the same result over and over again (assuming that what we are measuring is not changing!).[36] Reliability assesses the error in an instrument. Others have referred to this as "consistency", as reliability may be confused with "trustworthy", which would not be appropriate if an instrument repeatedly yields the wrong results.[14] Like validity, reliability is not a fixed property but is dependent upon the context of the population studied.[34] However, reliability does not imply validity. That is, a reliable measure is measuring something consistently, but not necessarily what it is supposed to be measuring.[8,36]

Reproducibility

Reproducibility is a form of reliability that can be further subdivided into inter-observer and test-retest. How closely one observer agrees with another observer using the same instrument and the same patient is the essence of inter-observer reproducibility (applicable to clinician-based outcomes). Test-retest reproducibility is measured by administering the same instrument to the same patient on 2 different occasions when no important dimensions of health have changed.[35] A definition of reproducibility is: the closeness of agreement between independent results obtained with the same method on identical test material but under different conditions (different operators, different apparatus, different laboratories, and/or after different intervals of time).[26] To test reproducibility or test-retest reliability, we asked 27 of the patients included to answer the questionnaire again within 24–72 hours to see whether they completed it with the same answers. The reproducibility was investigated by calculating the intra-class correlation coefficient (ICC, 2-way random model for agreement) between the test and re-test.[25]

Internal consistency

Internal consistency is a measure based on the correlations between different items on the same test (or the same subscale on a larger test). It measures whether several items that propose to measure the same general construct produce similar scores. Internal consistency can be tested in various ways. However, Cronbach's alpha is the mostly used way.[9] High reliabilities (0.95 or higher) are not necessarily desirable, as this indicates that the items may be entirely redundant. The goal in designing a reliable instrument is for scores on similar items to be related (internally consistent), but for each to contribute some unique information as well.

Validity

Validity is an index of how well a test measures what it is supposed to measure. In this case, that meant assessing the validity of the Dutch version of the OSS. The Pearson correlation coefficient was calculated between the OSS and the Constant-Murley, DSST and SF-36. The Pearson correlation assumes that the 2 variables are measured on at least interval scales, and it determines the extent to which values of the 2 variables are "proportional" to each other. The value of correlation (i.e., correlation coefficient) does not depend on the specific measurement units used.[36]

Construct validity

There is an awful lot of confusion in the methodological literature that stems from the wide variety of labels that are used to describe the validity of measures. Any time a concept or construct is translated into a functioning and operating reality (the operationalization), there is a need to be concerned about how correct the translation is. This issue is as relevant when we are talking about treatments or programs as it is when we are talking about measures. (The population of interest in the study is the "construct" and the sample is your operationalization. If we think of it this way, we are essentially talking about the construct validity of the sampling!)[36]

Because there is no 'gold-standard', construct validity was determined by comparing the OSS with various subscales of the generic MOS SF-36, the Constant-Murley Assessment Score, and the DSST. Spearman rank correlation coefficients were calculated. To investigate whether the OSS of satisfied patients differed from the OSS of dissatisfied patients, the scores of every follow-up occasion were compared with each other. Convergent and divergent validity were measured by investigating the strength of the correlation coefficients. The OSS should converge, have high correlations, with similar metrics (VAS for pain, physical functioning) and diverge, have low correlations, from dissimilar domains from the RAND-36 (e.g., general perception of health, mental health).

Statistical evaluation

All analyses were carried out using the Statistical Package for the Social Sciences (SPSS; Gorinchem, the Netherlands), version 11.5.

Results

One-hundred and three patients completed the questionnaires and were investigated clinically (see Table 1 for the demographic data). Sixty patients were included in Delft, Reinier de Graaf Gasthuis. Forty-three patients were included in Amsterdam, Onze Lieve Vrouwe Gasthuis. The patients themselves completed all questionnaires, except

Table 2: Absolute values of the Dutch Simple Shoulder score (DSST), the Constant-Murley score (CM) for the injured and non-injured shoulder, the Dutch Oxford Shoulder score (OSS) and the MOS SF-36 with the different subscales

	DSST	CM score injured shoulder	CM score non injured shoulder	OSS	SF-36 PF	RF	BP	GH	VI	SF	RE	MH
N (patients)	103	103	103	103	103	103	103	103	103	103	103	103
Mean	6.3	60.7	86.5	32.5	69.1	41.8	44.5	66.1	64.1	72.5	48.2	74.4
Median	6.0	64	88	31	75	25	40	67	65	75	33	76
SD	3.8	20.2	10.3	9.5	21.8	39.5	22.0	19.0	18.2	24.8	42.5	17.7
Min	0	2	49	13	0	0	0	5	20	0	0	16
Max	13	95	100	55	100	100	100	100	100	100	100	100

Abbreviations: PF, physical function; RF, role physical; BP, bodily pain; GH, general health; VI, vitality; SF, social functioning; RE, role emotional; MH, mental health.

for the Constant-Murley score (which is a clinician-based outcome score). The absolute values of all scores are given in Table 2.

Reproducibility

The patients seen in Delft were asked to fill in the questionnaire twice for testing of test-retest reliability. Thirty-seven questionnaires were received. However, 10 were anonymous, leaving 27 for evaluation. The intra-class correlation coefficient was R = .981. The mean difference between both tests was 2.7 points (0–8), corrected for 1 outlier (17) (see Table 3).

Table 3: Reproducibility numbers: reliability statistics

Cronbach's Alpha	No. of Items
.981	54 (= 2 x 27)

The intraclass correlation[a] was .485[b] for the single measures and .981[c] for the average measures.
Two-way mixed effects model, where people effects are random and measures effects are fixed.
[a] Type C intraclass correlation coefficients using a consistency definition-the between-measure variance is excluded from the denominator variance.
[b] The estimator is the same, whether the interaction effect is present or not.
[c] This estimate is computed assuming the interaction effect is absent, because it is not estimable otherwise.

Internal consistency

Internal consistency was high (Cronbach's alpha, 0.921). Elimination of one item in all 12 cases did not result in a value < 0.907. Only 2 items had low correlations with the total correlation (0.460 and 0.384). All other items had a correlation of > 0.644 with the total correlation score (see Table 4).

Construct validity

The construct validity was tested by the Pearson correlation coefficient (= "R") (Table 5). As assumed, there was a significant correlation between the (Dutch) OSS and the individual total scores. Only the subscales mental health and general health of the MOS SF-36 did not have a significant correlation at the 0.01 level (2-tailed; p = .123 and p = .316, respectively) (see Table 5).

Table 4: Internal consistency of the Oxford shoulder score: Item-total statistics

Question	Mean score (SD)	Corrected item-total correlation	Cronbach's Alpha if item deleted
1	3.853 (0.78)	.460	.922
2	2.961 (0.86)	.644	.916
3	3.226 (0.97)	.648	.915
4	4.069 (1.15)	.384	.927
5	2.549 (0.98)	.752	.911
6	1.784 (0.97)	.682	.914
7	1.814 (1.10)	.744	.911
8	2.245 (1.19)	.713	.913
9	2.049 (1.20)	.689	.914
10	2.667 (1.32)	.824	.907
11	2.814 (1.22)	.764	.910
12	2.423 (1.24)	.783	.909

The intraclass correlation[a] was .492[b] for the single measures and .921[c] for the average measures.
Two-way mixed effects model, where people effects are random and measures effects are fixed.
[a] Type C intraclass correlation coefficients using a consistency definition-the between-measure variance is excluded from the denominator variance.
[b] The estimator is the same, whether the interaction effect is present or not.
[c] This estimate is computed assuming the interaction effect is absent, because it is not estimable otherwise.

Table 5: Correlations between (Dutch) Oxford shoulder score and Constant-Murley shoulder assessment, DSST score and MOS SF-36, compared with the original (English) and German validated versions (literature) of the OSS

	Correlation with OSS Dutch version	Correlation with OSS English version (literature)		Correlation with OSS German version (literature)	Mean correlation
		Pre ok	Post ok		
DSST score	0.61	-	-	-	-
Constant score	0.64	0.74	0.75	0.60	0.69
MOS SF-36					
Physical functioning	0.68	0.61	0.62	0.62	0.64
Role physical	0.46	0.41	0.61	0.56	0.52
Bodily pain	0.56	0.66	0.68	0.76	0.67
Vitality	0.20	0.52	0.59	0.49	0.47
Social functioning	0.25	0.55	0.61	0.45	0.48
Role emotional	0.38	0.37	0.51	0.27	0.39
Mental health	0.15 (p = 0.123)	0.39	0.54	0.54	0.41
General health	0.10 (p = 0.316)	0.34	0.42	039	0.33

Discussion

Shoulder problems are the third most frequent disorder of the locomotor system after back and neck problems.[10,27,38] Concerning these shoulder problems, there is considerable uncertainty as to the effectiveness of the various treatment methods.[10,27,38] However, we see lots of possible ways to evaluate the outcome of orthopaedic conditions: physical findings such as sensibility or strength, radiographic changes, electromyographic changes, and a variety of patient-satisfaction and functional criteria are all used. This is often well-defined and standardized.[1,24] Moreover, there is a demand for instruments enabling comparison of treatment results and, thereby, international studies. Nowadays, there are lots of different questionnaires, all with their own advantages and disadvantages.[35] There are, of course, comparative studies to evaluate and criticize between the different outcome measurement instruments. However, when comparing earlier performed studies, one is sometimes committed to 1 or 2 specific questionnaires. This gives an increasing need for outcome measurements overall, but also validated for the Dutch speaking countries. Therefore, most used questionnaires ought to be validated and available in different languages. Outcome scores are originally developed in specific languages and when translated must be validated in the native language of the patient before use. In the Anglo-Saxon area, several shoulder measurements instruments, like the Constant-Murley, UCLA rating scale, and Rowe scores, are available. Besides these clinician-based outcome scores, several patient based outcome scores are also available, such as DASH (quick-DASH), WOSI, Oxford instability score, and the OSS. All of these were tested psychometrically. All of the above-mentioned measurement instruments have their own differences, such as structure, size, and indication.

When looking at the concerns and priorities of patients and surgeons, we often see differences. Therefore, it is increasingly recognized that methods are required to elicit the patient's perception of the outcome.[44] Furthermore, patient-based outcome measures are less time consuming for the clinician. This is an important factor in treatment of patients. There are also advantages in using questionnaires designed to address the patient's perception of a single condition. These usually shorter questionnaires may be just as sensitive to changes of importance to patients and much simpler to use.[15,22] Another advantage of patient-based outcome scores is that they are easy to use in daily practice and are cheap applications for general use.

Then again, in 2003, Ragab showed us a source of discrepancy between self-administered patient outcome questionnaires and the outcome measures developed and administered by clinicians.[31] He also found that patients' expectations had changed from their pre-operative expectations. Although outcome measures developed and administered by clinicians are subject to bias from several sources, results of this study suggested that self-administered patient outcome measures also have their disadvantages. The validity of self-administered patient outcome questionnaires can be severely impacted by the

patients' understanding of the questions asked, as even the most seemingly simple questions are subject to misinterpretation. In our study, we tried to solve that problem by testing the understanding of the Dutch version of the OSS by means of the probe technique for the first 20 patients in the study.[17] The OSS has a 5-point Likert system specifically developed for the subjective evaluation of patients with degenerative or inflammatory changes of the shoulder, which enables quick answering by the patients as well as uncomplicated and time-saving evaluation by the investigator, offering a distinct advantage for clinical routine.[18,20] For the Dutch speaking area, there already exists translations of the Disabilities of the Arm, Shoulder and Hand (DASH), and the DSST.[39,40] But until now, the OSS has not been validated in Dutch and the OSS was chosen for the same reasons as Huber et al in his 2004 German translation.[20] The structure of the questions of the OSS is simple and easily understood resulting in an easy acceptance for patients (quick filling-in and time saving for the examiner and easy administration, especially when using computerized patient self-assessment software, with touchscreen possibilities).[6]

Reproducibility, or the test-retest reliability, was performed with 27 of the 103 patients (Table 3). When starting the study, the intentions were to use all the patients in Delft to reproduce a second form. The Delft patients were to answer the questionnaire again within 24-48 hours to see whether they completed it with the same answers. However, we ended up with 27 subjects for this sub population. Looking at the sub-group of responders (N = 27) compared to the total group (N = 76) after 24-48 hours, we saw no major differences in the outcome of the OSS (respectively, mean = 31.4 ± 8.6; min-max = 17–49 vs mean = 32.8 ± 9.9; min-max 13–55). It is not likely that their shoulder problems had changed in this short interim period. This was shown by the intra-class correlation coefficient of the test-retest population, R = .981. This is a very high outcome, nearly 1.0, meaning that almost all 27 answered their questionnaire exactly the same way at 2 different points of times.

When looking at the results of our study, we saw a high internal consistency (Table 4). Examination of reliability resulted in a Cronbach's coefficient alpha of R = .921, an excellent value. Elimination of 1 item in all 12 cases did not result in a value < 0.907. Questions 1 and 4 showed the lowest corrected item-total correlation scores, namely 0.460 and 0.384, respectively. This suggests that those 2 items are not closely related (internally consistent) to the rest of the OSS, but each gives their own unique information. If we look at the questions closely (see Appendix), we see that for all questions, except questions 1 and 4, it is a reflection of daily live activities. When looking precisely, question 1 is presented in the past tense related to general pain problems of the shoulder. It tries to give a reflection of the pain someone had experienced at any time in the past (not necessarily recently) regarding the shoulder. Question 4 also concerns pain problems of the shoulder, but at rest when lying in bed at night (different from

daily live activities). On the other hand, as said earlier, a very high Cronbach's coefficient alpha score of almost 1.0 is not necessarily good, because then the question becomes redundant. It will not give us new information.

In this study, we saw a fair to moderate correlation of the Dutch version of the OSS against the DSST, MOS SF-36, and Constant-Murley score. However, this is not unexpected, as these outcome assessments are not identical. Subsequently, one could have compared the (Dutch) OSS with the more likely assessment of the (Dutch) DASH. However, this was not done. The construct validity (Table 5), presented here with the correlation coefficients between the absolute values of the (Dutch) OSS, DSST, Constant-Murley, and the relevant sub-scores of the MOS SF-36, was generally high (R > .46). Again, the subscales for pain and physical functioning of the SF-36 score exhibited the highest values. In our study, again we noticed that the shoulder questionnaires DSST and Constant-Murley score performed substantial higher correlation rates for the Dutch OSS compared with most of the different non-physical subscales of the SF-36. This confirms the need to use both joint-specific and generic health-status measures to evaluate patients who have a problem related to the shoulder. Noting our Materials and Methods section, we can see from our results that indeed the (Dutch) OSS has high correlations with similar metrics (e.g., VAS for pain, DSST and Constant-Murley score) and lower correlations with dissimilar domains from the MOS SF-36 (e.g., general perception of health, mental health). The explanation for this difference seems logical due to the direct relation between function or dysfunction of the shoulder ("physical functioning", "role physical", "bodily pain" of a patient) and joint specific shoulder scores. It is not necessarily true that if someone has shoulder problems that he or she also has a diminished vitality or social functioning (same with "role emotional", "mental health" and "general health").

In 1996, Dawson et al came with the source of the OSS in which the patient population was tested in patients with chronic shoulder complaints.[11] In 2001, the OSS was tested in patients who underwent rotator cuff surgery.[12] More recently, Dawson et al published the OSS revisited.[13] Othman and Taylor tested the OSS in patients with frozen shoulders.[28] So, the OSS was tested in most type of shoulder complaints. Afterwards, the OSS was also validated in other languages. In 2004, Huber et al presented his German version of the OSS.[20] We validated the Dutch version of the OSS based on this study of Huber et al.[20]

As previously mentioned, it is necessary to validate a questionnaire into the native language. For the shoulder specific questionnaires, this was done for the Shoulder Disability Questionnaire, the DASH, DSST, and the Shoulder Rating Questionnaire (SRQ).[37,39-41] In Oxford scores for other parts of the body, this process of validation in Dutch was done for the Oxford Hip and the Oxford knee scores.[16,19]

Comparing our results with those of the original English Oxford Shoulder Score and those of the German Oxford Shoulder score, this study shows that the correlations between (Dutch) Oxford shoulder score and Constant-Murley shoulder assessment and DSST score and the physical health subscales of the MOS SF-36 are more or less comparable with the original (English) and German validated versions (literature) of the OSS. Again, the subscales for pain and physical functioning of the SF-36 exhibited the highest values, and thus corresponded with the values published for the English and German versions. An odd thing was that the Dutch correlations of the mental health subscales of the MOS SF-36 (vitality, social functioning, role emotional, mental health and general health) were somewhat lower compared with the values published for the English and German versions. Especially the subscales mental health (DOSS: 0.15 vs EOSS: 0.39 pre-op vs GOSS: 0.54) and general health (DOSS: 0.10 vs EOSS: 0.34 vs GOSS: 0.39) turned out to be substantially lower. The explanation for this is not clear. For the German study group, the demographic data was at least different from the Dutch and English groups for age characteristics (mean ages; DOSS: 55 ± 13 yrs. vs EOSS: 57 ± 15 yrs. vs GOSS: 54 ± 10 yrs.). But the Dutch and English groups were comparable for age. Another explanation might be that our study population consisted of 2 different sub-populations: rural (Delft) and urban (Amsterdam). However, these subgroups did not differ for the OSS (respectively, mean = 32.7 ± 9.4; min-max = 17–55 vs mean = 32.1 ± 9.8; min-max 13–55). A possible point of criticism is that we did not perform a power analysis when starting the study, but used the number reported by Huber et al.[20] However, looking at the post-hoc performed power analysis, we see that the decision error (= ß) is 0.1 when the sample size exceeds 70, assuming that our zero-hypothesis is that there is no difference between the different tests (for Confidence Interval [= C.I.] is 95% and effect size [= d] is 5%). Our sample size was 103. Furthermore, the composition of our study was a heterogeneous population if compared to the German population. One could debate whether this is a weakness or strength of the validation process. Finally, we did not include sensitivity to change in our study. "Sensitivity to change" or responsiveness is the ability of a measure to detect a change when a change has occurred, in particular, changes in response to some intervention. This would have added strength to the validation process.

Conclusion

We validated and tested the OSS short 12-item questionnaire in Dutch, which patients found easy to complete and proved to provide reliable, valid, and responsive data regarding their perception of general shoulder problems (excluding instability problems). Our results showed that the Dutch version of the OSS, which is intended for use as an outcome measure during specialist treatment, imposes very little burden on the patients.

References

1. Amadio PC. Outcomes measurements. J Bone Joint Surg Am 1993;75: 1583-4.
2. Beaton D, Richards RR. Assessing the reliability and responsiveness of 5 shoulder questionnaires. J Shoulder Elbow Surg 1998;7:565-72.
3. Beaton DE, Richards RR. Measuring function of the shoulder. A cross-sectional comparison of five questionnaires. J Bone Joint Surg Am 1996;78:882-90.
4. Brazier JE, Harper R, Jones NM, O'Cathain A, Thomas KJ, Usherwood T, et al. Validating the SF-36 health survey questionnaire: new outcome measure for primary care. BMJ 1992; 305:160-4.
5. Bullinger M. German translation and psychometric testing of the SF-36 Health Survey: preliminary results from the IQOLA Project. International Quality of Life Assessment. Soc Sci Med 1995; 41:1359-66.
6. Chinman M, Hassell J, Magnabosco J, Nowlin-Finch N, Marusak S, Young AS. The feasibility of computerized patient self-assessment at mental health clinics. Adm Policy Ment Health 2007; 34:401-9.
7. Constant CR, Murley AH. A clinical method of functional assessment of the shoulder. Clin Orthop Relat Res 1987; 214:160-4.
8. Cortina JM. What is coefficient alpha? An examination of theory and applications. J Appl Psychol 1993; 78:98-104.
9. Cronbach LJ. Coefficient alpha and the internal structure of tests. Psychometrica 1951:297-334.
10. Dalton SE. The conservative management of rotator cuff disorders. Br J Rheumatol 1994; 33:663-7.
11. Dawson J, Fitzpatrick R, Carr A. Questionnaire on the perceptions of patients about shoulder surgery. J Bone Joint Surg Br 1996;78:593-600.
12. Dawson J, Hill G, Fitzpatrick R, Carr A. The benefits of using patient-based methods of assessment. Medium-term results of an observational study of shoulder surgery. J Bone Joint Surg Br 2001; 83:877-82.
13. Dawson J, Rogers K, Fitzpatrick R, Carr A. The Oxford shoulder score revisited. Arch Orthop Trauma Surg 2009; 129:119-23.
14. Feinstein AR. Clinimetrics. Yale University Press, New Haven 1987.
15. Fitzpatrick R, Ziebland S, Jenkinson C, Mowat A. A comparison of the sensitivity to change of several health status instruments in rheumatoid arthritis. J Rheumatol 1993; 20:429-36.
16. Gosens T, Hoefnagels NH, de Vet RC, Dhert WJ, van Langelaan EJ, Bulstra SK, et al. The "Oxford Heup Score": the translation and validation of a questionnaire into Dutch to evaluate the results of total hip arthroplasty. Acta Orthop 2005; 76:204-11.
17. Guillemin F, Bombardier C, Beaton D. Cross-cultural adaptation of health-related quality of life measures: literature review and proposed guidelines. J Clin Epidemiol 1993; 46:1417-32.
18. Guyatt GH, Townsend M, Berman LB, Keller JL. A comparison of Likert and visual analogue scales for measuring change in function. J Chronic Dis 1987; 40:1129-33.
19. Haverkamp D, Breugem SJ, Sierevelt IN, Blankevoort L, van Dijk CN. Translation and validation of the Dutch version of the Oxford 12-item knee questionnaire for knee arthroplasty. Acta Orthop 2005; 76:347-52.
20. Huber W, Hofstaetter JG, Hanslik-Schnabel B, Posch M, Wurnig C. The German version of the Oxford Shoulder Score: cross-cultural adaptation and validation. Arch Orthop Trauma Surg 2004; 124:531-6.
21. Hudak PL, Amadio PC, Bombardier C. Development of an upper extremity outcome measure: the DASH (disabilities of the arm, shoulder and hand) [corrected]. The Upper Extremity Collaborative Group (UECG). Am J Ind Med 1996; 29:602-8.

22. Katz JN, Larson MG, Phillips CB, Fossel AH, Liang MH. Comparative measurement sensitivity of short and longer health status instruments. Med Care 1992; 30:917-25.
23. Kessler S, Pfander T, Nelitz M, Puhl W, Gunther KP. The Pediatric Musculoskeletal Functional Health Questionnaire. A function assessment questionnaire for detection of illnesses of the locomotor system in children and adolescents: initial results of validating a German version. Z Orthop Ihre Grenzgeb 2001; 139:134-7.
24. MacDonald DA. The shoulder and elbow. In: Pynsent PB, Fairbank JC, Carr A, editors. Outcome measures in orthopaedics. Oxford: Butterworth Heinemann; 1993. p. 144-73.
25. McGraw KO, Wong SP. Forming inferences about some intraclass correlation coefficients. Psychol Methods 1996; 1:30-46.
26. McNaught AD. IUPAC compendium of chemical terminology.2nd. United Kingdom: Blackwell Science; 1997.
27. Ogilvie-Harris DJ, Demaziere A. Arthroscopic debridement versus open repair for rotator cuff tears. A prospective cohort study. J Bone Joint Surg Br 1993; 75:416-20.
28. Othman A, Taylor G. Is the constant score reliable in assessing patients with frozen shoulder? 60 shoulders scored 3 years after manipulation under anaesthesia. Acta Orthop Scand 2004; 75:114-6.
29. Pose B, Sangha O, Peters A, Wildner M. Validation of the North Amer-ican Spine Society Instrument for assessment of health status in patients with chronic backache. Z Orthop Ihre Grenzgeb 1999; 137:437-41.
30. Pynsent PB, Carr AJ. Outcome Measures in Orthopaedics and Orthopaedic Trauma.2nd. Great Britain: Arnold; 2004.
31. Ragab AA. Validity of self-assessment outcome questionnaires: patient-physician discrepancy in outcome interpretation. Biomed Sci Instrum 2003; 39:579-84.
32. Rosales RS, Delgado EB. Diez de la Lastra-Bosch I. Evaluation of the Spanish version of the DASH and carpal tunnel syndrome health-related quality-of-life instruments: cross-cultural adaptation process and reliability. J Hand Surg [Am] 2002; 27:334-43.
33. Skutek M, Fremerey RW, Zeichen J, Bosch U. Outcome analysis following open rotator cuff repair. Early effectiveness validated using four different shoulder assessment scales. Arch Orthop Trauma Surg 2000; 120:432-6.
34. Streiner DL. Health measurement scales: a practical guide to their development and use. Oxford, UK: Oxford University Press; 1995.
35. Suk M, Hanson BP, Norvell DC, Helfet DL. Musculoskeletal Outcomes Measures and Instruments. AO Handbook. Switzerland: AO publishing; 2005.
36. Trochim WM, Donnelly JP. The Research Methods Knowledge Base. Mason, OH: Thomson Publishing; 2007.
37. van der Heijden GJ, Leffers P, Bouter LM. Shoulder disability questionnaire design and responsiveness of a functional status measure. J Clin Epidemiol 2000; 53:29-38.
38. van der Windt DA, van der Heijden GJ, Scholten RJ, Koes BW, Bouter LM. The efficacy of non-steroidal anti-inflammatory drugs (NSAIDS) for shoulder complaints. A systematic review. J Clin Epidemiol 1995; 48:691-704.
39. van Laarhoven HA, Te Slaa R, De Boer LM, Willems WJ. De Nederlandse Simpele Schouder Test, een efficiente wijze van schouderfunctiebepaling. NTvO 2001; Vol. 8.
40. Veehof MM, Sleegers EJ, van Veldhoven NH, Schuurman AH, van Meeteren NL. Psychometric qualities of the Dutch language version of the Disabilities of the Arm, Shoulder, and Hand questionnaire (DASH-DLV). J Hand Therapy 2002; 15:347-54.

41. Vermeulen HM, Boonman DC, Schuller HM, Obermann WR, van Houwelingen HC, Rozing PM, et al. Translation, adaptation and validation of the Shoulder Rating Questionnaire (SRQ) into the Dutch language. Clin Rehabil 2005; 19:300-11.
42. Ware JE Jr, Sherbourne CD. The MOS 36-item short-form health survey (SF-36). I Conceptual framework and item selection. Med Care 1992; 30:473-83.
43. Wiesinger GF, Nuhr M, Quittan M, Ebenbichler G, Wolfl G, Fialka-Moser V. Cross-cultural adaptation of the Roland-Morris questionnaire for German-speaking patients with low back pain. Spine 1999;24: 1099-103.
44. Wright JG, Rudicel S, Feinstein AR. Ask patients what they want. Evaluation of individual complaints before total hip replacement. J Bone Joint Surg Br 1994; 76:229-34.

APPENDIX

Discussion on instability specific measurement tools with attention to the Oxford Shoulder Score

Patient perception on shoulder instability (PROM's)

A well-designed study that clearly delineates superiority of one treatment over another may provide insufficient evidence or even be harmful if it fails to measure "important" outcomes. With the pressure to approve and recommend specific devices and interventions to the musculoskeletal clinical and research community, musculoskeletal outcome research has a unique opportunity to demonstrate its ability to validate the true clinical benefit of these modalities in appropriate patient populations using appropriate measures and instruments as endpoints.[1–3]

An increasing number of outcome measurement tools have been designed to report on the effectiveness of treatment for shoulder pathologies (shoulder specific questionnaires). This includes objective measures such as range of motion (ROM), strength testing, physical exam maneuvers, return to play, and complications such as redislocation, as well as subjective measures such as patient satisfaction and patient-reported outcome (PRO) tools. However, nowhere are there more insensitive, unreliable, unvalidated measurement tools than in the orthopaedic literature.[4] These metrics are being variably applied to (shoulder) patients in literature, with a lack of consensus regarding the most appropriate method of outcome assessment for patients with (surgically managed) anterior glenohumeral instability (condition-specific questionnaires).[5] For that matter, most of nowadays commonly used scoring systems show major deficiencies when applied to instability populations.[6,7] Yet, shoulder instability is the most common diagnosis in which condition-specific measurement tools are being used. The presentation of patients with symptomatic instability is actually different compared with other shoulder pathology. Normally, they do not present themselves having pain or a decreased function as is more common with other shoulder diagnoses. This leads to poor responsiveness and significant ceiling effects when general shoulder-specific measures are being used for patients with instability problems. Therefore, more condition-specific instability measurement tools have been developed to evaluate patients with shoulder instability aiming for more response to treatment effect.

The **Oxford Shoulder Score** (OSS) is being developed by Dawson et al. in 1996.[8,9] Two different questionnaires exist. One was originally constructed for shoulder operations other than instability (OSS) in 1996. This one was translated in Dutch in 2010 (*see **attachment A** for full Dutch version of questionnaire*).[10] The other was constructed in 1999 specifically for assessment of shoulder instability patients, now called the Oxford Shoulder Instability Score (OSIS) or Shoulder Instability Questionnaire. The latter being translated in Dutch in 2015 (*see **attachment B** for full Dutch version of questionnaire*).[11]

The OSS and OSIS are both patient-based, shoulder-specific scoring systems consisting of 12 questions each with 5-graded options. The total score is given as the sum of the 12 responses (min–max: 12–60 points). The OSS questionnaire deals with the perceptions of patients about shoulder surgery and assesses pain and activities of daily living (33.3% and 66.6% respectively). It was initially based on a sample of 111 patients undergoing shoulder surgery, but excluded patients with instability. Later on, the OSS was being tested on patients undergoing rotator cuff surgery and on patients with persistent stiffness of their shoulder undergoing mobilization of their shoulder under general anesthesia. The OSIS questionnaire is a self-reported outcome measurement more specific for patients with shoulder instability. It is based on a prospective study of 92 patients with shoulder instability with both the Oxford instability and Rowe scores showing excellent responsiveness in this cohort.[8,9] More recently, study outcome also supports the use of the OSIS in military patients undergoing shoulder stabilisation surgery, probably having increased demands of military service compared to civilian patients.[12]

When looking in details of both oxford shoulder questionnaires, only two out of twelve questions of the OSIS go specific into content of shoulder instability (namely questions 1 & 5 of the OSIS, *see attachments A and B for full Dutch versions of both questionnaires*). The rest of the OSIS questions and all of the OSS questions can be interpreted on all shoulder specific conditions (other than instability). While the primary complaint in the patient with shoulder instability, and sometimes the only complaint, is apprehension or avoidance of activity. So, one can debate about an insufficient number of items in the evaluation for the instability problem in the OSIS, creating a possible deficiency in both outcome tools for that matter. Almost all other questions are about things like pain and possible limitations in the personal and professional life of the patient, on account of problems on behalf of their shoulder. Where the original purpose of the OSIS measurement tool should be to evaluate subjects with an injury-specific condition, here (in-)stability of the shoulder.

Other shoulder specific scoring systems, currently being used in literature with the intention to address shoulder instability, in no particular order, include the American Shoulder and Elbow Surgeons (ASES) score;[13,14] the Melbourne Instability Shoulder Scale (MISS);[15] the Constant-Murley (CM) score;[16] the Athletic Shoulder Outcome Rating Scale (ASORS);[17] the University of California, Los Angeles (UCLA) score;[18] the Subjective Shoulder Rating System (SSRS);[19] the L'Ìnsalata shoulder rating system / Shoulder Rating Questionnaire (SRQ);[20,21] the Disabilities of the Arm, Shoulder and Hand (DASH) score;[22,23] the Western Ontario Shoulder Instability Index (WOSI);[24,25] and the Simple Shoulder Test (SST).[26,27] The latter four are, as well as the OSS and OSIS also translated and validated for the Dutch language. However, of all the above mentioned shoulder specific questionnaires, many are actually not condition-specific for shoulder instability. See Table 1 for an overview of these shoulder-specific shoulder scoring systems, including % of instability content.

Table 1: Overview of scoring systems that are being used in literature addressing shoulder instability

Outcome measure tool	% of instability content	Year of Dutch validation	No. of questions	Total score	S/O
Rowe / modified Rowe (rating sheet for Bankart repair)	50 of total 100 points	NA	3	100	S/O
American Shoulder and Elbow Surgeon (ASES) score	Instability (and impingement) do not contribute to the total score	NA	11	100	S
L'insalata shoulder rating system (Shoulder Rating Questionnaire (SRQ))	Originally not designed for instability	2005[20]	21	100	S
Melbourne Instability Shoulder score (MISS)	33 points	NA	24	100	S
Disabilities of the Arm, shoulder and Hand (DASH) score	Originally not designed for instability	2019[23]	30	100	S
Western Ontario Shoulder Instability Index (WOSI)	100 points; 1 specific instability question (subscale A Q8)	2014[24]	21	2100	S
Oxford Instability Score (OIS) / Shoulder Instability Questionnaire	10 of 60 points	2015[32]	12	60	S
Constant-Murley (CM) score	Not appropriate for instability	NA	7	100	S/O
Athletic Shoulder Outcome Rating Scale (ASORS)	Stability 10 points	NA	6	100	S/O
University of California, Los Angeles (UCLA) score	Originally not designed for instability	NA	5	35	S/O
Simple Shoulder test (STT)	Originally not designed for instability	2001[26]; 2012[27]	12	12	S
Subjective Shoulder Rating System (SSRS)	15 points	NA		100	

Abbreviations: NA, not applicable; S, subjective; O, objective.

Nowadays, the most common validated patient reported outcome measures for shoulder instability are the Western Ontario Shoulder Instability Index (WOSI), the Melbourne Instability Shoulder Scale (MISS) and the Oxford Shoulder Instability Score (OSIS).[9,15,25,28] However, the *most commonly used* score for the evaluation of instability, is the Rowe score, which was also the first shoulder score described in 1978.[29] The Rowe score, similar to the UCLA shoulder score, was described before modern psychometric development was implemented limiting its psychometric properties.[29] The WOSI, MISS and OSIS have been developed with recent psychometric evaluations. The properties of

these scores are being described in Table 2. The WOSI is more responsive to treatment of instability than the Rowe score in patients both non-operatively and operatively treated for traumatic instability. Overall, the WOSI has the strongest psychometric properties and has undergone the most rigorous testing despite the fact that the Rowe is the most commonly reported instability measure.[30] Plancher et al. recommends in his "analysis of evidence-based medicine for shoulder instability" study, to use both the WOSI and the MISS to evaluate patients with instability for reasons of clinical-decision making.[7] However, Sahinoglu suggested specific for Dutch users to use the WOSI and the OISS for the assessment of shoulder instability patients, probably due to the fact that the MISS is still not translated into Dutch until today.[31]

Table 2: Properties of the WOSI, OSIS, MISS and Rowe scores

Instability	Description	Validity	Reliability	Responsiveness	MCID
WOSI	21 items: Physical symptoms (10) Sport / recreation / work function (4) Lifestyle function (4) Emotional function (3); Score: 0–2100 (Lower = Better) (can be converted into 0%–100% scale)	Content validity: Items established by experts and patients Criterion validity: Excellent Correlate: VAS Function and DASH, good with CMS and Rowe	Excellent ICC: 0.87–0.98	Excellent effect size: 1.67 for stabilization	220 / 2100
OSIS	12 items: Score: 12–60 (Lower = Better)	Criterion validity: Correlated with Rowe and Constant scores	Excellent ICC: 0.97	Very good effect size: 0.8	Not reported
MIIS	22 items: Pain (4) Instability (5) Function (8) Occupation and sports (5) Score: 0–100 (lower = better)	Criterion validity: Low to moderate correlation with shoulder rating questionnaire. Otherwise untested	Excellent ICC: 0.98	Not reported	Not reported
Rowe score	3 items: Stability (50 points) Motion (20 points) Function (30 points) Score: 0–100 (both subjective and examination dependent)	Content Validity: poorly described development and methodology Criterion Validity: Correlated with WOSI and CMS	Fair ICC: 0.7	Very good effect size: 1.2	Not reported

Abbreviation: ICC, intraclass correlation coefficient.

References

1. Clancy CM, Eisenberg JM. HEALTH CARE POLICY:Outcomes Research: Measuring the End Results of Health Care. *Science (80-)*. 1998;282(5387):245-246. doi:10.1126/science.282.5387.245
2. Simmons BP, Swiontkowski MF, Evans RW, Amadio PC, Cats-Baril W. Outcomes assessment in the information age: available instruments, data collection, and utilization of data. *Instr Course Lect*. 1999;48:667-685. http://www.ncbi.nlm.nih.gov/pubmed/10098096. Accessed July 12, 2019.
3. Anderson C. Measuring what works in health care. *Science (80-)*. 1994;263(5150):1080-1080. doi:10.1126/science.8108722
4. Kirkley A, Griffin S. Development of disease-specific quality of life measurement tools. *Arthrosc J Arthrosc Relat Surg*. 2003;19(10):1121-1128. doi:10.1016/j.arthro.2003.10.028
5. Lukenchuk J, Sims LA, Shin JJ. Variability in Outcome Reporting for Operatively Managed Anterior Glenohumeral Instability: A Systematic Review. *Arthroscopy*. 2017;33(2):477-483. doi:10.1016/j.arthro.2016.07.027
6. Gerber C. Integrated scoring systems for the functional assessment of the shoulder. In: *The Shoulder: A Balance of Mobility and Stability.* Rosemont Il; 1992:531-550.
7. Plancher KD, Lipnick SL. Analysis of Evidence-Based Medicine for Shoulder Instability. *Arthrosc J Arthrosc Relat Surg*. 2009;25(8):897-908. doi:10.1016/j.arthro.2009.03.017
8. Dawson J, Fitzpatrick R, Carr A. Questionnaire on the perceptions of patients about shoulder surgery. *J Bone Joint Surg Br*. 1996;78(4):593-600. http://www.ncbi.nlm.nih.gov/pubmed/8682827. Accessed September 30, 2018.
9. Dawson J, Fitzpatrick R, Carr A. The assessment of shoulder instability. The development and validation of a questionnaire. *J Bone Joint Surg Br*. 1999;81(3):420-426. http://www.ncbi.nlm.nih.gov/pubmed/10872358. Accessed March 5, 2019.
10. Berendes T, Pilot P, Willems J, Verburg H, te Slaa R. Validation of the Dutch version of the Oxford Shoulder Score. *J Shoulder Elb Surg*. 2010;19(6). doi:10.1016/j.jse.2010.01.017
11. van der Linde JA, van Kampen DA, van Beers LWAH, van Deurzen DFP, Terwee CB, Willems WJ. The Oxford Shoulder Instability Score; validation in Dutch and first-time assessment of its smallest detectable change. *J Orthop Surg Res*. 2015;10(1):146. doi:10.1186/s13018-015- 0286-5
12. Middleton S, Guyver P, Boyd M, Brinsden M. Patient reported outcome measures in military patients with shoulder instability. *J R Army Med Corps*. 2013;159(4):271-273. doi:10.1136/jramc-2013-000050
13. Richards RR, An KN, Bigliani LU, et al. A standardized method for the assessment of shoulder function. *J shoulder Elb Surg*. 1994;3(6):347-352. doi:10.1016/S1058-2746(09)80019-0
14. Skutek M, Fremerey RW, Zeichen J BU. Outcome analysis following open rotator cuff repair. Early effectiveness validated using four different shoulder assessment scales. - PubMed - NCBI. *Arch Orthop Trauma Surg* . 2000;120(7-8):432-436. https://www.ncbi.nlm.nih.gov/pubmed/10968533. Accessed May 19, 2019.
15. Watson L, Story I, Dalziel R, Hoy G, Shimmin A, Woods D. A new clinical outcome measure of glenohumeral joint instability: The MISS questionnaire. *J Shoulder Elb Surg*. 2005;14(1):22-30. doi:10.1016/j.jse.2004.05.002
16. Constant CR, Murley AH. A clinical method of functional assessment of the shoulder. *Clin Orthop Relat Res*. 1987;(214):160-164. http://www.ncbi.nlm.nih.gov/pubmed/3791738.
17. Tibone JE. Evaluation of treatment outcomes for the athlete`s shoulder. In: *The Shoulder: A Balance of Mobility and Stability*. 1993.
18. Amstutz HC, Sew Hoy AL, Clarke IC. UCLA anatomic total shoulder arthroplasty. *Clin Orthop Relat Res*. (155):7-20. http://www.ncbi.nlm.nih.gov/pubmed/7226634. Accessed May 19, 2019.

19. Kohn D, Geyer M. The subjective shoulder rating system. *Arch Orthop Trauma Surg*. 1997;116(6-7):324-328. doi:10.1007/BF00433982
20. L'Insalata JC, Warren RF, Cohen SB, Altchek DW, Peterson MG. A self-administered questionnaire for assessment of symptoms and function of the shoulder. *J Bone Joint Surg Am*. 1997;79(5):738-748. http://www.ncbi.nlm.nih.gov/pubmed/9160947. Accessed May 19, 2019.
21. Vermeulen HM, Boonman DC, Schüller HM, et al. Translation, adaptation and validation of the Shoulder Rating Questionnaire (SRQ) into the Dutch language. *Clin Rehabil*. 2005;19(3):300- 311. doi:10.1191/0269215505cr811oa
22. Hudak PL, Amadio PC, Bombardier C, et al. Development of an upper extremity outcome measure: the DASH (disabilities of the arm, shoulder and hand) [corrected]. The Upper Extremity Collaborative Group (UECG). *Am J Ind Med*. 1996;29(6):602-608. doi:10.1002/(SICI)1097-0274(199606)29:6<602::AID-AJIM4>3.0.CO;2-L
23. Veehof MM, Sleegers EJA, van Veldhoven NHMJ, Schuurman AH, van Meeteren NLU. Psychometric qualities of the Dutch language version of the Disabilities of the Arm, Shoulder, and Hand questionnaire (DASH-DLV). *J Hand Ther*. 15(4):347-354. http://www.ncbi.nlm.nih.gov/pubmed/12449349. Accessed March 5, 2019.
24. van der Linde JA, Jaap Willems W, van Kampen DA, A H van Beers LW, van Deurzen DF, Terwee CB. *Measurement Properties of the Western Ontario Shoulder Instability Index in Dutch Patients with Shoulder Instability*. Vol 15.; 2014. doi:10.1186/1471-2474-15-211
25. Kirkley A, Griffin S, McLintock H, Ng L. The Development and Evaluation of a Disease-Specific Quality of Life Measurement Tool for Shoulder Instability. *Am J Sports Med*. 1998;26(6):764- 772. doi:10.1177/03635465980260060501
26. van Laarhoven HA, Te Slaa R, De Boer LM, Willems WJ. De Nederlandse Simpele Schouder Test, een efficiente wijze van schouderfunctie bepaling. *Ned Tijdschr voor Orthop*. 2001;8.
27. van Kampen DA, van Beers LWAH, Scholtes VAB, Terwee CB, Willems WJ. Validation of the Dutch version of the Simple Shoulder Test. *J Shoulder Elb Surg*. 2012;21(6):808-814. doi:10.1016/j.jse.2011.09.026
28. van der Linde JA, van Kampen DA, van Beers LWAH, van Deurzen DFP, Terwee CB, Willems WJ. The Oxford Shoulder Instability Score; validation in Dutch and first-time assessment of its smallest detectable change. *J Orthop Surg Res*. 2015;10(1):146. doi:10.1186/s13018-015- 0286-5
29. Rowe CR, Patel D, Southmayd WW. The Bankart procedure: a long-term end-result study. *J Bone Jt Surg Am*. 1978;60(1):1-16.
30. Wylie JD, Beckmann JT, Granger E, Tashjian RZ. Functional outcomes assessment in shoulder surgery. *World J Orthop*. 2014;5(5):623. doi:10.5312/wjo.v5.i5.623
31. Şahinoğlu E, Ergin G, Ünver B. Psychometric properties of patient-reported outcome questionnaires for patients with musculoskeletal disorders of the shoulder. *Knee Surgery, Sport Traumatol Arthrosc*. February 2019:1-15. doi:10.1007/s00167-019-05369-7
32. Van der Linde JA, van Kampen DA, van Beers LWAH, van Deurzen DFP, Terwee CB, Willems WJ. The Oxford Shoulder Instability Score; validation in Dutch and first-time assessment of its smallest detectable change. *J Orthop Surg Res*. 2015;10(1):146. doi:10.1186/s13018-015- 0286-5

Full Dutch versions of Oxford shoulder (A) and Oxford shoulder instability score (B)

A. Oxford Schouder score (Nederlandse versie, versie 2010)[8,10]

Datum: _ _/ _ _/ 20_ _

Iedereen die deze vragenlijst gebruikt dient dit te doen onder de conditie, dat het gaat om de ***situatie van de afgelopen 4 weken***.

De test bestaat uit 12 vragen die gaan over pijn en mogelijke beperkingen in het persoonlijke en professionele leven van de patiënt.

Een hoge score (hoogste score is 60) betekent veel pijn of beperking in het functioneren ten gevolge van schouderklachten en een lage score (laagste score is 12) betekent weinig pijn of beperking in het functioneren ten gevolge van schouderklachten.

Aangedane zijde		Dominante zijde	

1. Hoe zou u de ergste pijn, die u in uw schouder heeft gehad, willen beschrijven?

Ondraaglijk	Erg pijnlijk	Nogal pijnlijk	Beetje pijnlijk	Helemaal niet pijnlijk

2. Hoe zou u de pijn, die u meestal in uw schouder heeft, willen beschrijven?

Ondraaglijk	Erg pijnlijk	Nogal pijnlijk	Beetje pijnlijk	Helemaal niet pijnlijk

3. Hoeveel beïnvloedt de pijn aan de schouder uw dagelijkse werkzaamheden? (ook het dagelijks huiswerk).

Totaal	Grotendeels	Matig	Klein beetje	Geheel niet

4. Hebt u 's nachts als u in bed ligt pijn in de schouder?

Elke nacht	De meeste nachten	Sommige nachten	1 of 2 nachten	Nooit

5. Bent u in staat u aan- en uit te kleden met uw aangedane arm?

Nee, onmogelijk	Heel erg beperkt	Matig beperkt	Nagenoeg niet beperkt	Geen beperking

6. Bent u in staat in - en uit een auto te stappen, of gebruik te maken van het openbaar vervoer met uw aangedane arm?

Nee, onmogelijk	Heel erg beperkt	Matig beperkt	Nagenoeg niet beperkt	Geen beperking

7. Kunt u op hetzelfde moment mes en vork gebruiken?

Nee, onmogelijk	Met veel moeite	Enigszins moeilijk	Zonder veel moeite	Ja, eenvoudig

8. Kunt u de boodschappen voor het huishouden zelfstandig doen?

Nee, onmogelijk	Met veel moeite	Enigszins moeilijk	Zonder veel moeite	Ja, eenvoudig

9. Kon (kunt u) u een dienblad met daarop een bord eten door de kamer dragen?

Nee, onmogelijk	Met extreem veel problemen	Met nogal wat problemen	Met lichte problemen	Ja, eenvoudig

10. Kunt u met de aangedane arm uw haar borstelen of kammen?

Nee, onmogelijk	Met veel moeite	Enigszins moeilijk	Weinig moeite	Ja, eenvoudig

11. Kunt u uw kleding in de kledingkast hangen met de aangedane arm?

Nee, onmogelijk	Met veel moeite	Enigszins moeilijk	Weinig moeite	Ja, eenvoudig

12. Kunt u zichzelf onder beide oksels wassen en drogen?

Nee, onmogelijk	Met veel moeite	Enigszins moeilijk	Weinig moeite	Ja, eenvoudig

B. Oxford Schouder instabiliteit score (Nederlandse versie, versie 2015)[9,11]

Datum: _ _/ _ _ / 20_ _

De test bestaat uit 12 vragen die gaan over (in-)stabiliteit, pijn en mogelijke beperkingen in het persoonlijke en professionele leven van de patiënt.

Een hoge score (hoogste score is 60) betekent een instabiele schouder en/of pijn of beperking in het functioneren ten gevolge van schouderklachten en een lage score (laagste score is 12) betekent een stabiele schouder, weinig pijn of beperking in het functioneren ten gevolge van schouderklachten.

Aangedane zijde		Dominante zijde	

1. Hoe vaak is, **gedurende de afgelopen 6 maanden**, uw schouder uit de kom geschoten?

Niet	1 tot 2 keer in de laatste 6 maanden	1 tot 2 keer per maand	1 tot 2 keer per week	Meer dan 2 keer per week

2. Heeft u, **gedurende de afgelopen 3 maanden**, moeite gehad met of zich zorgen gemaakt om het aantrekken van een T-shirt vanwege uw schouder?

Geen moeite of zorgen	Een beetje moeite of zorgen	Matige moeite of zorgen	Extreme moeite of zorgen	Onmogelijk om te doen

3. Hoe zou u, **gedurende de afgelopen 3 maanden**, de pijn die u aan uw schouder had, zoals die op zijn ergst was, omschrijven?

Geen	Mild	Matig	Hevig	Ondraaglijk

4. In hoeverre werd u, **de afgelopen 3 maanden**, door uw schouder probleem beperkt in het uitvoeren van uw werk (inclusief school, studie, werk of huishoudelijk werk)?

Helemaal niet	Een klein beetje	Matig	Aanzienlijk	Totaal

5. Heeft u, **gedurende de afgelopen 3 maanden**, activiteiten vermeden door zorgen om uw schouder omdat u bang was dat deze uit de kom zou schieten?

Nee, helemaal niet	Heel af en toe	Sommige dagen	De meeste dagen of bij meer dan één activiteit	Elke dag of bij veel activiteiten

6. Heeft u, **gedurende de afgelopen 3 maanden**, vanwege uw schouder probleem activiteiten die belangrijk voor u zijn, niet uitgevoerd?

Nee, helemaal niet	Heel af en toe	Sommige dagen	De meeste dagen of bij meer dan één activiteit	Elke dag of bij veel activiteiten

7. In hoeverre heeft, **gedurende de afgelopen 3 maanden**, uw schouder probleem u belemmerd in uw sociale leven?

Helemaal niet	Af en toe	Sommige dagen	De meeste dagen	Elke dag

8. In hoeverre heeft, **gedurende de afgelopen 4 weken**, uw schouder probleem u belemmerd bij het uitvoeren van sport of hobby's?

Helemaal niet	Een klein beetje / af en toe	Soms	De meeste dagen	Altijd

9. Hoe vaak heeft u, **gedurende de laatste 4 weken**, aan uw schouder gedacht?

Nooit, of alleen wanneer iemand ernaar vroeg	Af en toe	Sommige dagen	De meeste dagen	Elke dag

10. In hoeverre heeft, **gedurende de afgelopen 4 weken**, uw schouder probleem u belemmerd om zware objecten op te tillen of u bereidheid tot tillen beïnvloed?

Helemaal niet	Af en toe	Sommige dagen	De meeste dagen	Elke dag

11. Hoe zou u, **gedurende de afgelopen 4 weken**, de pijn die u gewoonlijk aan uw schouder heeft ervaren, omschrijven?

Geen	Erg mild	Mild	Matig	Hevig

12. Heeft u, **gedurende de afgelopen 4 weken**, vanwege uw schouder, vermeden om 's nachts in bed in bepaalde posities te liggen?

Geen enkele nacht	1 of 2 nachten	Sommige nachten	De meeste nachten	Elke nacht

4

Chapter 4

Survey on the management of acute first-time anterior shoulder dislocation amongst Dutch public hospitals

Thomas Berendes · Peter Pilot · Jochem Nagels · Anne Vochteloo · Rob Nelissen

Arch Orthop Trauma Surg. 2015;135(4):447-454

Abstract

Introduction: The primary aim of this study was to record how orthopaedic surgeons are currently managing acute first-time anterior shoulder dislocation (AFASD) 8 years after introduction of the Dutch national guideline: "acute primary shoulder dislocation, diagnostics and treatment" in 2005. The second aim was to evaluate how these surgeons treat recurrent instability after AFASD.

Materials and methods: An online questionnaire regarding the management of AFASD and recurrent shoulder instability was held amongst orthopaedic surgeons of all 98 Dutch hospitals.

Results: The overall response rate was 60%. Of the respondents, 75% had a local protocol for managing AFASD, of which 28% had made changes in their treatment protocol after the introduction of the national guideline. The current survey showed wide variety in the overall treatment policies for AFASD. Twenty-seven percent of the orthopaedic surgeons were currently unaware of the national guideline. The variability in treatment for AFASD was present throughout the whole treatment from which policy at the emergency department; when to operate for recurrent instability; type of surgical technique for stabilization and type of fixation of the labrum. As for the treatment of recurrent instability, the same variability was seen: 36% of the surgeons perform only arthroscopic procedures, 7% only open and 57% perform both open and arthroscopic procedures.

Conclusions: Despite the introduction of the national guideline for the initial management of AFASD in 2005, still great variety among orthopaedic surgeons in the Netherlands was present. As for the surgical stabilization technique, the vast majority of the respondents are performing an arthroscopic shoulder stabilization procedure at the expense of the more traditional open procedure as a first treatment option for post-traumatic shoulder instability.

Introduction

Acute first-time anterior shoulder dislocation (AFASD) is an injury that is frequently seen on the Emergency Department (ED). Shoulder dislocations comprise approximately 10% of all shoulder trauma and approximately 50% of all joint dislocations.[1] Reported incidence rates of shoulder dislocation vary from 8 to 48 per 100,000 inhabitants per year.[2–6]

Previous studies showed a great variety of treatment options in managing AFASD.[7,8] A prior Dutch questionnaire demonstrated that there was no protocol for the management of AFASD in 35% of all consulted hospitals.[1] Therefore, it was proposed to develop a national evidence-based guideline for the management of AFASD. In 2005, the national guideline: "acute primary shoulder dislocation, diagnostics and treatment" was introduced, written by a Working Group commissioned by the Dutch Orthopaedic Association (NOV).[9] The flowchart of treatment of AFASD from this guideline is depicted in Fig. 1.

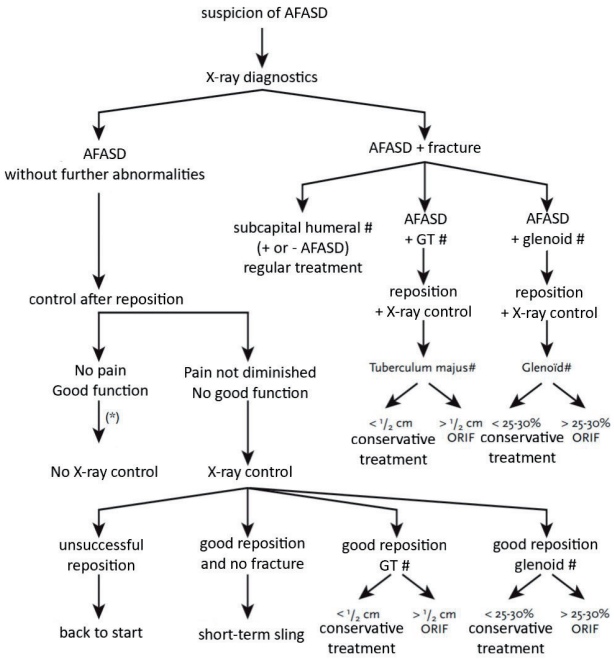

Fig. 1: Flowchart treatment of acute primary anterior shoulder dislocation according to Dutch national guideline 2005.
* in doubt, X-ray control; # = fracture; ORIF = open reduction internal fixation; GT = greater trochanter.

The guideline was at the request of this Working Group, assessed by a number of experts in the field. In the comment phase, the guideline was offered online to all members of the participating Dutch associations (General Surgery and its subdivision of Traumatology,

General Practitioners, Physiotherapy, Radiology and Sports Medicine) and to the Working Group Shoulder and Elbow within the Dutch Orthopaedic Association itself. Hereafter, the guideline was accepted in the general assembly of the Dutch Orthopaedic Association, followed by the publication in 2005.[9]

The primary aim of this study was to evaluate how orthopaedic surgeons are currently managing AFASD, 8 years after introduction of the guideline.[9] The second aim was to evaluate how these surgeons treat recurrent instability after AFASD.

Our hypothesis was that the impact of the new guideline was small and that we would not see a uniform treatment of AFASD despite the implementation of the guideline in 2005 in the Netherlands.

Materials and methods

An online questionnaire regarding the management of AFASD and recurrent shoulder instability was held amongst orthopaedic surgeons of all 98 Dutch hospitals (8 university hospitals, 21 teaching hospitals, 69 general hospitals). Orthopaedic healthcare is joint-oriented within orthopaedic groups in hospitals, thus 1–2 surgeons perform shoulder surgery, knee surgery, etc. Orthopaedic groups in the Netherlands are mandatory to have at least three or four consultants to guaranty quality and continuity. So, the reactions given in this study are per orthopaedic group.

The Questionnaire was based on the Dutch guideline on AFASD and was made by a panel of shoulder surgeons. It consisted of 27 multiple-choice questions and 1 open question.

The questionnaire (in Dutch) is available online (and an English translation is given in the appendix) (http://spreadsheets.google.com/viewform?formkey=dElONW5BWEFnaEpFcWtDUDFCTzVtTWc6MA) Furthermore, two case vignettes were used as for what treatment policy the orthopaedic surgeon would do in two distinct cases of AFASD (Ron te Slaa).[10] These case vignettes were a 17-year-old man, active high-level handball player, with persistent instability after an AFASD (after the initial dislocation, three or more dislocations or subluxations occurred) and a 47-year-old low-demanding housewife with the same clinical presentation.

Results

Fifty-nine (60%) orthopaedic groups of 98 orthopaedic groups (i.e. Dutch hospitals) completed the online questionnaire. As for the type of orthopaedic groups who responded, seven out of eight orthopaedic groups (88%) from university hospitals, 14

out of 21 (67%) orthopaedic groups from teaching hospitals and 38 of the 69 (55%) orthopaedic groups from general hospitals responded. No private clinics responded, since they do not participate in the management of the acute shoulder dislocation in the Netherlands. Fifty-eight of the 59 responding orthopaedic groups (98%) performed surgery for post-traumatic recurrent instability.

Table 1 shows the answers on the items of the questionnaire regarding the 2005 guideline, timing of radiographs and the treatment of AFASD. The most important findings were that 16 of the 59 (27%) orthopaedic groups are currently unaware of presence of a national guideline and that 44 (75%) had a local protocol for AFASD. Of these 44, 17 had adjusted their protocol after release of the national guideline in 2005. The majority of the orthopaedic groups (51/59, 86%) make radiographs of the shoulder both pre- and post-reduction and have a standardized treatment protocol after reduction (53/59). Visible from the responses given in this study, a great variation was present in the different hospital protocols for management of AFASD.

Table 1: Items of the questionnaire regarding the guideline of 2005, X-rays and treatment of AFASD

Questions	Yes	No	Unknown
Guideline			
Awareness of guideline for AFASD of 2005	43	13	3
Presence of protocol for AFASD in your hospital?	44	11	4
Adjustments of local protocol after release of guideline in 2005	17	17	25
X-rays			
PRE-reduction X-rays on ED	51	7	1
POST-reduction X-rays on ED	51	5	3
Treatment			
Subsequent standard treatment after AFASD	53	5	1
Immobilization of shoulder post-reduction?	52	6	1
Physiotherapy after AFASD?	32	25	2

N = 59 orthopaedic groups.
AFASD, acute first-time anterior shoulder dislocation; ED, emergency department.

The anesthetic technique for reduction of the dislocated shoulder showed large variability as well: the majority (46%) of the respondents use a combination of different anesthetic techniques at time of reduction, 20% only intravenous diazepam and 10% routinely used the intra-articular injection of lidocaine (IAL). In 4% fentanyl and/or midazolam is used. The solitary use of any combination of paracetamol, non-steroidal anti-inflammatory drugs (NSAIDs) or morphine is used in 2% and finally, general anesthesia is used by 2%. In 8% no form of anesthesia was used.

The reduction technique showed also variability. Forty-seven percent of the responders answered that they used some form of combination of the four classic reposition

techniques. In 17% the Hippocrates technique was used, in 14% the Kocher technique, 12% the Stimson technique and 5% the Milch technique.11 Five percent replied that they would use another technique besides the mentioned ones in the questionnaire to reduce a shoulder dislocation in the Emergency Department, but no further specification was done.

Immobilization technique and time showed less variability. The shoulder was immobilized for a maximum of 2 weeks by fifty-nine percent of the orthopaedic groups. The remaining 41% advises immobilization for 2–6 weeks. The majority (97%) immobilizes the shoulder in internal rotation, only three percent immobilizes the shoulder in external rotation.

Follow-up and aftercare after AFASD again were very variable within the groups. Fifty-four percent of our responders claimed to perform some form of subsequent treatment after AFASD, mostly physiotherapy.

Eighty-eight percent of the respondents claimed to routinely check patients at the outpatient clinic after AFASD; 46% within 1 week; 41% within 2 weeks and 14% after 6 weeks. Thirty-two surgeons (60%) routinely refer patients to a physiotherapist after AFASD.

Diagnostic investigation, timing and techniques for recurrent instability showed also variability. Thirty-nine percent (23/59) of the responding orthopaedic groups first refer the patient to a physiotherapist when symptoms of recurrent instability occur. Additional diagnostic evaluation before further (conservative) treatment was started by 36 orthopaedic groups (66%). A MRI scan is the favorite diagnostic tool (98%, 58/59), in the majority with intra-articular contrast (55/58).

The surgical treatment options for recurrent instability after AFASD showed remarkable variations. In four orthopaedic groups (7%), only an open stabilizing technique was used. 93% (54/58) used an arthroscopic technique as a primary treatment for recurrent instability. In the latter group, 61% (33/54) performs open stabilizing techniques as well, sometimes for primary cases.

The modified open Bankart repair is performed in the majority (54%) of cases. 16% of the surgeons prefer a Putti-Platt procedure; 14% a Bristow-Latarjet procedure; 14% a T-shaped capsular shift and 2% a Weber osteotomy.

For refixation of the labrum (either open or arthroscopically), 40% (23/57) of the respondents uses non-absorbable suture anchors as fixation technique, 47% (27/57) uses absorbable suture anchors and 13% (7/57) uses capsulolabral sutures (without an anchor).

Forty-five percent (26/58) of all surgeons use a standard postoperative follow-up of 6 months, fifty percent (29/58) 1 year and five percent of the surgeons (3/58) have a follow-up of more than 1 year.

Looking at the factors of influence on decision-making, logical differences were given. Eighty-eight (52/59) percent of the responders indicated that age was an important factor in decision-making for further treatment. Level of sport activity plays an important role in the treatment process in 86% (51/59) of the respondents, 84% makes a further differentiation in contact versus non-contact sports and throwing versus non-throwing.

On the question: "how many dislocations must a patient have been through to decide to intervene surgically?" two percent (1/50) of the respondents replied one dislocation; 34% (17/50) two or more, 40% (20/50) three or more and 24% (12/50) over four dislocations.

Spontaneous dislocation at rest or while sleeping is a reason to perform surgery for 83% (49/59) of the respondents.

As for the case vignette of the 17-year-old man, fifty-one out of 59 respondents (86%) answered to perform a stabilizing procedure, of which 47% (28/59) would perform an arthroscopic procedure, 8% (5/59) would perform an open procedure and 31% (18/59) would perform another type of stabilizing procedure. The remaining eight respondents (14%) preferred a conservative treatment.

As for the second case vignette, thirty out of 57 respondents (53%) would perform a stabilizing procedure, of which 33% (19/57) would perform this arthroscopically, 16% (9/57) would perform a non-defined type of stabilizing procedure and 4% (2/57) would perform an open procedure. The remaining twenty-seven respondents (47%) preferred a conservative treatment.

Discussion

A great variety among orthopaedic surgeons in the Netherlands for the initial management of AFASD was found, despite the introduction of the national guideline in 2005. A quarter of the Dutch orthopaedic groups are currently unaware of the presence of the national guideline implemented in 2005 and three quarters had a local protocol for AFASD in their hospital of which a minority had adjusted their protocol after release of the new guideline.

These findings are in line with our hypothesis that the impact of the new guideline would be small and would not lead to a uniform treatment of AFASD.

Several reviews have shown that guidelines have only been moderately effective in changing the process of care, and that there is much room for improvement.[12] Implementation of medical guidelines poses difficulty which can be related back to several constraints.[13-15] A prominent barrier for implementation is lack of agreement with guideline recommendations. Lack of applicability is another important barrier to

guideline adherence. Environmental barriers, particularly organizational constraints, are another often-perceived group of barriers to implementation. Moreover, lack of collaboration with other types of healthcare professionals and lack of motivation, time, resources and reimbursement are also shown as a barrier to implementation.[12] Carlson's conducted review in 2007 identified six themes of barriers to the implementation of guidelines among general practitioners (GP): the content and the format of a guideline, GPs individual experience, preserving the doctor-patient relationship, professional responsibility, and practical issues.[16]

So, one can imagine, with AFASD with its widespread clinical presentation of symptoms between different types and demanding patients with different types of treatment options, that a guideline for AFASD will be difficult to implement in daily practice, unless there is conclusive scientific evidence that a particular treatment is best for AFASD. And even then, it appears that the implementation of a protocol is difficult. If guidelines are made, effort has to be made on implementing them in daily practice.

A survey by te Slaa in 2003, prior to the introduction of the national AFASD guideline, demonstrated that 65 % of the reviewed Dutch hospitals had a protocol for AFASD (response rate 73%, of 74 Dutch hospitals).[1] These protocols were different, because they have been made individually per clinic based on their own interpretation of knowledge and understanding on dealing with AFASD at that time and place. Of course, this is accompanied by a degree of heterogeneity between the individual protocols. Our study found that currently 75% had an AFASD protocol that was adjusted in 29% after the introduction of the guideline. Therewith, the impact of the introduction of the guideline is small; a 10% increase of presence of an AFASD protocol. Furthermore, large differences in management of AFASD are still present.

A similar wide variety among trauma clinicians in managing AFASD was found in surveys conducted in the UK and Germany.[8,17]

Anesthetic technique

The guideline stated that it should be considered to give IAL as a local analgesic and that in case of a failed first reduction, enhanced analgesia, sedation and/or anesthesia might be used.

The UK survey (2006) showed also that 10% of respondents used intra-articular injection of lidocaine (IAL) prior to reduction, comparable to our findings.[8] The German survey (2001) does not describe the analgesic management.[17]

Two randomized controlled trials demonstrated that a combination of sedation and analgesia resulted in a higher reduction rate, but with more complications (respiratory depression, nausea and vomiting) when using sedation.[18,19] IAL is a safe and effective

method that contributes to a successful and less painful repositioning promoted by Matthews, Gleeson and Suder.[20-22] It has been shown that IAL has less side effects without differences in time to reposition, difficulty of repositioning or subjective pain perception and a shorter stay on the ED compared to intravenous sedation.[20,23]

Reduction technique

Reduction techniques can be divided into four groups as described by Riebel and McCabe.[11]

The traction method (Hippocrates, Stimson), the leverage method (Kocher, Milch), scapula manipulation method and the last group is the combination of the prior three.[11] The guideline states that no reduction technique is considered to be superior and to use the technique each practitioner is known and familiar with, which is in line with the findings of our survey.

Immobilization

If immobilized, the optimum position and duration of immobilization is still not known.[24]

With regard to the duration of immobilization, Kiviluoto showed that the redislocation rate was higher in patients under 30 years compared to older patients and that in the under 30-year group the redislocation rate was higher in those that were immobilized for 1 week compared to those subjected to 3 weeks' immobilization.[25] Itoi et al. showed a better outcome after a first-time anterior shoulder dislocation after immobilization of the shoulder in external rotation and abduction when the shoulder is immobilized for at least 3 weeks.[26-28] However, Liavaag et al. refute this later on in their article in 2011.[29] In our survey, we found a large preference for immobilization of the shoulder in internal rotation position. The guideline indicates that immobilization in general is not proven useful after AFASD as there is no correlation between recurrence and the length of immobilization and that there is no preference for the position of immobilization.[9,30,31]

Follow-up and aftercare after AFASD

The vast majority of the consulted clinics performed some kind of follow-up after AFASD, which is according to the guideline, stating that after the immobilization period, it is necessary to determine the extent of shoulder function both in an active and passive way. Patients should be able to be completely pain-free with a full active range of motion of the shoulder within 6 weeks after a shoulder dislocation. In the guideline, physiotherapy is not recommended for a patient with an uneventful course of AFASD. This is in conflict with the survey outcome. This is probably because of the expectations of most patients to receive some form of rehabilitation.

Recurrent instability: diagnostics

In the guideline, additional imaging is recommended in case of persistent pain and/or loss of function of the shoulder approximately 2–6 weeks after AFASD. In contrast to this, we found that in daily practice, patients are referred to a physiotherapist when signs of recurrent instability occur. If additional imaging is performed, MR arthrography is the examination of choice of the large majority, in line with guideline. Only when rotator cuff pathology is suspected, ultrasound examination is the first choice. This is in line with many (more recent) studies.[32-36]

Recurrent instability after AFASD: surgical treatment

The guideline does not advise on specific surgical techniques, only on timing. A 'wait and see' period after AFASD before deciding to operate, even in young athletes, is advised.

This advice is because of the relatively low redislocation rate in the average patient (26% in a normal population).[9] However, the redislocation rate is much higher (up to 68%) in younger physically active patients. Therewith, surgical stabilization after the first dislocation in this specific group is currently still subject of scientific debate.[37-39] In our study, arthroscopic procedures were clearly more performed than the (traditional) open stabilization procedures as surgical treatment for recurrent instability. As the results of arthroscopic repair have greatly improved, arthroscopic techniques have driven off the open techniques.[40,41] Historically, the open procedures had a lower recurrence rate compared to the present arthroscopic stabilizing techniques.[42-44] With newer studies, however, more evidence is found for similar long-term clinical outcomes, with no significant difference in the rate of recurrent instability and or clinical outcome scores.[45,46]

Looking at the open techniques in our survey, there was a clear preference for the open (modified) Bankart technique (54%) compared with the Bristow–Latarjet procedure (16%) reflecting international preferences.[7,47] Furthermore, it was interesting to see that the Putti-Platt procedure is still used quite often (16%), more than in the German survey (8%).[7,17] This procedure, however, has a high correlation rate with loss of motion (especially external rotation) and osteoarthritis on the long term.[48,49] Also notable was the number of surgeons (12%) using capsulolabral suture repairs which are proven inferior to (non-) absorbable suture anchors.[50-52]

Our findings with regard to timing of surgical treatment after AFASD were conflicting. In the survey itself, 2% of the respondents would perform direct surgical repair after one dislocation. However, only 14% of all surgeons were in favor of the 'wait and see' treatment for the active, young patient in case vignette 1. So, age and level or type of sport activity were found to be important issues in decision-making of (surgical) treatment.

In the German study, 73% of the surgeons would treat a young, athletic patient (< 30 years old) surgically already after the first dislocation (and 98 % in case of recurrent

instability). The same patient with a moderate level of sport activity would be treated conservatively in 67% of cases (14% in case of recurrent instability). The level of sports is therewith important in the German setting.[7]

Clinical practice guidelines are commonly regarded as useful tools for quality improvement. However, the impact of this guideline on clinical practice for management of AFASD is not optimal because of the many constraints for implementation. Uniformity in the treatment of AFASD is difficult to achieve, despite evidence-based medicine, which might be due to the fact that most advice in the guideline is based on level III or IV evidence or expert opinion. Second, even if level I evidence is present, implementation is difficult.

Based on current literature, we suggest a future guideline on AFASD should propagate the use of IAL as anesthetic technique and a short period of immobilization after AFASD. It should advise better on when (not) to use a specific surgical technique. Finally, it could be considered to treat young and competitive patients surgically more early as of their high recurrence rate.

To conclude, our survey revealed a great variety among Dutch orthopaedic surgeons with regard to the management of AFASD, despite the introduction of a national guideline in 2005.

As for the surgical stabilization technique, the vast majority of the respondents are performing an arthroscopic shoulder stabilization procedure at the expense of the more traditional open procedure as a first treatment option for post-traumatic shoulder instability.

References

1. Te Slaa RL, Wijffels MP, Marti RK. Questionnaire reveals variations in the management of acute first-time shoulder dislocations in the Netherlands. Eur J Emerg Med. 2003; 10:58–61. doi: 10.1097/00063110-200303000-00015.
2. Kroner K, Lind T, Jensen J. The epidemiology of shoulder dislocations. Arch Orthop Trauma Surg. 1989; 108:288–290. doi: 10.1007/BF00932317.
3. Simonet WT, Melton LJ, 3rd, Cofield RH, Ilstrup DM. Incidence of anterior shoulder dislocation in Olmsted County Minnesota. Clin Orthop Relat Res. 1984; 186:186–191.
4. Hovelius L. Incidence of shoulder dislocation in Sweden. Clin Orthop Relat Res. 1982; 166:127–131.
5. Milgrom C, Mann G, Finestone A. A prevalence study of recurrent shoulder dislocations in young adults. J Shoulder Elb Surg. 1998; 7:621–624. doi: 10.1016/S1058-2746(98)90011-8.
6. Nordqvist A, Petersson CJ. Incidence and causes of shoulder girdle injuries in an urban population. J Shoulder Elb Surg. 1995; 4:107–112. doi: 10.1016/S1058-2746(05)80063-1.
7. Tingart M, Bathis H, Bouillon B, Neugebauer E, Tiling T. Surgical therapy of traumatic shoulder dislocation. Are there evidence-based indications for arthroscopic Bankart operation? Unfallchirurg. 2001; 104:894–901. doi: 10.1007/s001130170064.
8. Chong M, Karataglis D, Learmonth D. Survey of the management of acute traumatic first-time anterior shoulder dislocation among trauma clinicians in the UK. Ann R Coll Surg Engl. 2006; 88:454–458. doi: 10.1308/003588406X117115.
9. Slaa RL et al (2005) Acute primaire schouderluxatie: diagnostiek en behandeling. CBO Guideline.
10. Slaa RL (2003) The acute first-time anterior shoulder dislocation (AFASD). PhD thesis AMC-UvA, Amsterdam.
11. Riebel GD, McCabe JB. Anterior shoulder dislocation: a review of reduction techniques. Am J Emerg Med. 1991; 9:180–188. doi: 10.1016/0735-6757(91)90187-O.
12. Lugtenberg M, Zegers-van Schaick JM, Westert GP, Burgers JS. Why don't physicians adhere to guideline recommendations in practice? An analysis of barriers among Dutch general practitioners. Implement Sci. 2009; 4:54. doi: 10.1186/1748-5908-4-54.
13. Hofstede SN, et al. Designing a strategy to implement optimal conservative treatments in patients with knee or hip osteoarthritis in orthopedic practice: a study protocol of the BART-OP study. Implement Sci. 2014; 9:22. doi: 10.1186/1748-5908-9-22.
14. Prior M, Guerin M, Grimmer-Somers K. The effectiveness of clinical guideline implementation strategies–a synthesis of systematic review findings. J Eval Clin Pract. 2008; 14:888–897. doi: 10.1111/j.1365-2753.2008.01014.x.
15. Swinkels RAHM, van Peppen RPS, Wittink H, Custers JWH, Beurskens AJHM. Current use and barriers and facilitators for implementation of standardized measures in physical therapy in the Netherlands. BMC Musculoskelet Disord. 2011; 12:106. doi: 10.1186/1471-2474-12-106.
16. Carlsen B, Glenton C, Pope C. Thou shalt versus thou shalt not: a meta-synthesis of GPs' attitudes to clinical practice guidelines. Br J Gen Pract. 2007; 57:971–978. doi: 10.3399/096016407782604820.
17. Tingart M, Bathis H, Bouillon B, Tiling T. Therapy of traumatic anterior shoulder dislocation: current status of therapy in Germany. Are there scientifically verified therapy concepts? Chirurg. 2001; 72:677–683. doi: 10.1007/s001040170123.
18. Kosnik J, et al. Anesthetic methods for reduction of acute shoulder dislocations: a prospective randomized study comparing intraarticular lidocaine with intravenous analgesia and sedation. Am J Emerg Med. 1999; 17:566–570. doi: 10.1016/S0735-6757(99)90197-3.

19. Uglow MG. Kocher's painless reduction of anterior dislocation of the shoulder: a prospective randomised trial. Injury. 1998; 29:135–137. doi: 10.1016/S0020-1383(97)00168-X.
20. Matthews DE, Roberts T. Intraarticular lidocaine versus intravenous analgesic for reduction of acute anterior shoulder dislocations. A prospective randomized study. Am J Sports Med. 1995; 23:54–58. doi: 10.1177/036354659502300109.
21. Gleeson AP, Graham CA, Meyer AD. Intra-articular lignocaine versus Entonox for reduction of acute anterior shoulder dislocation. Injury. 1999; 30:403–405. doi: 10.1016/S0020-1383(99)00105-9.
22. Suder PA, Mikkelsen JB, Hougaard K, Jensen PE. Reduction of traumatic primary anterior shoulder dislocation under local analgesia. Ugeskr Laeger. 1995; 157:3625–3629.
23. Orlinsky M, Shon S, Chiang C, Chan L, Carter P. Comparative study of intra-articular lidocaine and intravenous meperidine/diazepam for shoulder dislocations. J Emerg Med. 2002; 22:241–245. doi: 10.1016/S0736-4679(01)00475-9.
24. Paterson WH, Throckmorton TW, Koester M, Azar FM, Kuhn JE. Position and duration of immobilization after primary anterior shoulder dislocation: a systematic review and meta-analysis of the literature. J Bone Joint Surg Am. 2010; 92:2924–2933. doi: 10.2106/JBJS.J.00631.
25. Kiviluoto O, Pasila M, Jaroma H, Sundholm A. Immobilization after primary dislocation of the shoulder. Acta Orthop Scand. 1980; 51:915–919. doi: 10.3109/17453678008990894.
26. Itoi E, et al. A new method of immobilization after traumatic anterior dislocation of the shoulder: a preliminary study. J Shoulder Elb Surg. 2003; 12:413–415. doi: 10.1016/S1058-2746(03)00171-X.
27. Yamamoto N, Sano H, Itoi E. Conservative treatment of first-time shoulder dislocation with the arm in external rotation. J Shoulder Elb Surg. 2010; 19:98–103. doi: 10.1016/j.jse.2009.12.018.
28. Itoi E, et al. Is protecting the healing ligament beneficial after immobilization in external rotation for an initial shoulder dislocation? Am J Sports Med. 2013; 41:1126–1132. doi: 10.1177/0363546513480620.
29. Liavaag S, et al. Immobilization in external rotation after primary shoulder dislocation did not reduce the risk of recurrence: a randomized controlled trial. J Bone Jt Surg. 2011; 93:897–904. doi: 10.2106/JBJS.J.00416.
30. Hovelius L, et al. Primary anterior dislocation of the shoulder in young patients. A ten-year prospective study. J Bone Jt Surg Am. 1996; 78:1677–1684.
31. McLaughlin HL, MacLellan DI. Recurrent anterior dislocation of the shoulder. II. A comparative study. J Trauma. 1967; 7:191–201. doi: 10.1097/00005373-196703000-00002.
32. Smith TO, Drew BT, Toms AP. A meta-analysis of the diagnostic test accuracy of MRA and MRI for the detection of glenoid labral injury. Arch Orthop Trauma Surg. 2012; 132:905–919. doi: 10.1007/s00402-012-1493-8.
33. Chandnani VP, et al. Glenoid labral tears: prospective evaluation with MRI imaging, MR arthrography, and CT arthrography. AJR Am J Roentgenol. 1993; 161:1229–1235. doi: 10.2214/ajr.161.6.8249731.
34. Major NM, Browne J, Domzalski T, Cothran RL, Helms CA. Evaluation of the glenoid labrum with 3-T MRI: is intraarticular contrast necessary? AJR Am J Roentgenol. 2011; 196:1139–1144. doi: 10.2214/AJR.08.1734.
35. Magee T. 3-T MRI of the shoulder: is MR arthrography necessary? AJR Am J Roentgenol. 2009; 192:86–92. doi: 10.2214/AJR.08.1097.
36. Pavic R, Margetic P, Bensic M, Brnadic RL. Diagnostic value of US, MR and MR arthrography in shoulder instability. Injury. 2013;44(Suppl 3): S26–S32. doi: 10.1016/S0020-1383(13)70194-3.
37. Van der Heiden R, Bruinsma WE, Kerkhoffs GMMJ, Goslings JC, Schep NWL. Treatment of primary anterior shoulder dislocation; do not always treat conservatively. Ned Tijdschr Geneeskd. 2013;157: A5526.

38. Gigis I, Heikenfeld R, Kapinas A, Listringhaus R, Godolias G. Arthroscopic versus conservative treatment of first anterior dislocation of the shoulder in adolescents. J Pediatr Orthop. 2014;34:421–425.
39. Milewski MD, Nissen CW. Pediatric and adolescent shoulder instability. Clin Sports Med. 2013; 32:761–779. doi: 10.1016/j.csm.2013.07.010.
40. Parsons BO, et al. Surgical management of traumatic anterior glenohumeral instability: an international perspective. Instr Course Lect. 2010; 59:245–253.
41. Boileau P, Fourati E, Bicknell R. Neer modification of open Bankart procedure: what are the rates of recurrent instability, functional outcome, and arthritis? Clin Orthop Relat Res. 2012; 470:2554–2560. doi: 10.1007/s11999-012-2296-5.
42. Hiemstra LA, Sasyniuk TM, Mohtadi NG, Fick GH. Shoulder strength after open versus arthroscopic stabilization. Am J Sport Med. 2008; 36:861–867. doi: 10.1177/0363546508314429.
43. Lenters TR, Franta AK, Wolf FM, Leopold SS, Matsen FA. Arthroscopic compared with open repairs for recurrent anterior shoulder instability. A systematic review and meta-analysis of the literature. J Bone Joint Surg Am. 2007; 89:244–254. doi: 10.2106/JBJS.E.01139.
44. Freedman KB, Smith AP, Romeo AA, Cole BJ, Bach BR. Open Bankart repair versus arthroscopic repair with transglenoid sutures or bioabsorbable tacks for Recurrent Anterior instability of the shoulder: a meta-analysis. Am J Sports Med. 2004; 32:1520–1527. doi: 10.1177/0363546504265188.
45. Harris JD, et al. Long-term outcomes after Bankart shoulder stabilization. Arthroscopy. 2013; 29:920–933. doi: 10.1016/j.arthro.2012.11.010.
46. Godin J, Sekiya JK. Systematic review of arthroscopic versus open repair for recurrent anterior shoulder dislocations. Sports Health. 2011; 3:396–404. doi: 10.1177/1941738111409175.
47. Berendes TD, Wolterbeek R, Pilot P, Verburg H, te Slaa RL. The open modified Bankart procedure: outcome at follow-up of 10–15 years. J Bone Joint Surg Br. 2007; 89:1064–1068. doi: 10.1302/0301-620X.89B8.19280.
48. Hovelius L. Glenohumeral osteoarthrosis after Putti-Platt repair. J Shoulder Elb. Surg. 2000; 9:257. doi: 10.1067/mse.2000.105627.
49. Van der Zwaag HM, Brand R, Obermann WR, Rozing PM. Glenohumeral osteoarthrosis after Putti-Platt repair. J Shoulder Elb Surg. 1999; 8:252–258. doi: 10.1016/S1058-2746(99)90138-6.
50. Hecker AT, et al. Pull-out strength of suture anchors for rotator cuff and Bankart lesion repairs. Am. J Sports Med. 1993; 21:874–879. doi: 10.1177/036354659302100621.
51. Klein AH, Harner CD, Fu FH. The Bankart lesion of the shoulder: a biomechanical analysis following repair. Knee Surg Sports Traumatol Arthrosc. 1995; 3:117–120. doi: 10.1007/BF01552387.
52. Gohlke F, Schneider P, Siegel K, Balzer C. Tensile strength of various anchor systems in surgical correction of instability of the shoulder joint. Unfallchirurg. 1993; 96:546–550.

5

Chapter 5

The open modified Bankart procedure: outcome at follow-up of 10 to 15 years

Thomas Berendes · Ron Wolterbeek · Peter Pilot · Hennie Verburg · Ron te Slaa

J Bone Joint Surg Br. 2007;89(8):1064-1068

Abstract

We report the outcome of a modified Bankart procedure using suture anchors in 31 patients (31 shoulders) with a mean follow-up of 11 years (10 to 15).

The mean age of the patients was 28 years (16 to 39). At follow-up, the mean Rowe score was 90 points (66 to 98) and the Constant score was 96 points (85 to 100). A total of 26 shoulders (84%) had a good or excellent result. The rate of recurrence varied between 6.7% and 9.7% and depended on how recurrence was defined. Two patients had a significant new injury at one and nine years, respectively after operation. The overall rate of instability (including subluxations) varied between 12.9% and 22.6%. All patients returned to work, with 29 (94%) resuming their pre-operative occupation and level of activity. Mild radiological osteoarthritis was seen in nine shoulders (29%) and severe osteoarthritis in one.

We conclude that the open modified Bankart procedure is a reliable surgical technique with good mid to long-term results.

Introduction

The common form of instability of the shoulder is traumatic anterior dislocation,[1] and operative treatment is classified as anatomical or non-anatomical. The former was first described by Bankart[2] in 1938 and involves reconstruction of the labrum and/or capsular structures. Non-anatomical techniques include the Bristow-Latarjet procedure,[3] the Eden-Hybinette procedure,[4] the Magnusson-Stack procedure,[5] the Putti-Platt procedure[6] and the Weber osteotomy procedure.[7] More recently, the Bankart procedure has been described in association with a capsular shift, and arthroscopic techniques have also been developed.[8,9] However, recent reports have described a higher rate of failure in arthroscopic stabilisation.[10–13]

Many orthopaedic surgeons favor the open Bankart procedure because it has good long-term results with few complications.[10–17] However, despite its popularity, no long-term results in terms of glenohumeral arthritis[18–20] have been described. Long-term studies are needed because this disorder usually occurs in young patients.

We aimed to analyze the long-term clinical and radiological results of the modified Bankart repair in terms of stability and the incidence of glenohumeral osteoarthritis.

Patients and methods

In a retrospective single-surgeon (RTS) study 34 patients who had undergone stabilization of the shoulder between November 1989 and December 1993 were reviewed at a mean follow-up of 11 years (10 to 15). None had multi-directional instability or previous operative procedures on the shoulder. Three patients were lost to follow-up, leaving 31 for evaluation.

There were 26 males and five females with a mean age at the time of operation of 28 years (16 to 39). No patient had a bilateral procedure. Their mean age at follow-up was 40 years (29 to 50). Nine of the operations were on the dominant side and there were no operative complications. A standardized patient questionnaire in combination with a standardized physical examination of the shoulder and additional radiological examination were carried out.

The outcome was scored using the Rowe score,[21] the score of Constant and Murley[22] and the Dutch simple shoulder test (DSST).[23] Pain was scored using a visual analogue scale.[24] Overall patient satisfaction was determined by a four-point ordinal scale (excellent, good, moderate and poor) and the patients were asked whether they would undergo the same procedure again. Radiological evaluation was performed using the classification of Samilson and Prieto.[25] True internal and external rotation views, as well as an axillary view, were taken of both shoulders. At the final follow-up all assessments were done by an independent investigator (TDB).

Operative technique

The patient is under general anesthesia in a beach-chair position. The subscapularis tendon is incised vertically, approximately 1.5 cm medial to its insertion, leaving the inferior part intact. The capsule is incised vertically on the lateral side. A T-shaped capsular opening is created, raising a superior and an inferior capsular flap. The cortical layer of the glenoid rim is roughened with an osteotome to expose parts of bleeding cancellous bone. Three to four holes for bone anchors are made on the edge of the glenoid. Mitek I and later Mitek II (DePuy Mitek, Raynham, Massachusetts) anchors were used. The labrum (or its remnants) and the medial capsular flap are then reattached to the glenoid and the rotator interval closed. The two capsular flaps are then shifted, the superior flap inferiorly and the inferior flap superiorly, until it is sufficiently tight. The arm is held in neutral rotation and in abduction of approximately 30° during this manoeuvre. Finally, two additional sutures are placed between the two capsular flaps to close the horizontal T incision of the repair. The subscapularis muscle is reattached anatomically to its insertion. Post-operatively, the arm is placed in a shoulder immobilizer for six weeks.

Statistical analysis

This was performed using SPSS version 12.0.1 for Windows (SPSS Inc., Chicago, Illinois). Simple (fourfold) cross-table analysis was used to quantify the relationship between discrete outcome variables, such as instability and osteoarthritis, and various discrete risk factors, including age, gender, number of subluxations, function etc. We used the chi-squared test or Fisher's exact test for the binary variables. In cases of paired binary data (outcome variables) we used the McNemar test and a paired *t*-test for mean differences. In the case of a statistically significant association ($p \leq 0.05$), we used logistic regression to model the probability/odds of an outcome.

Results

Stability

At the final follow-up three patients (9.7%), all male, had encountered a re-dislocation, two after further trauma. One had fallen at high speed whilst water-skiing nine years after the initial operation. A further four patients (12.9%) complained of episodes of subluxation or had pain. Two of these described a sensation of subluxation during the first two years post-operatively, which then disappeared. The rate of instability varied between 12.9% and 22.6% depending on the definition (Table 1). Further reference to the instability group later in the text, relates to patients still experiencing instability at final follow-up (group B).

Three patients (9.7%) had a positive apprehension test during follow-up. All belonged to the instability group (B) and one had a further dislocation.

When using the (binary) multivariable logistic regression model with instability as the dependent variable, no significant correlation/regression was found for the covariates present, i.e. age (regression coefficient –1.240, $p = 0.291$), gender (regression coefficient 0.686, $p = 0.699$), length of follow-up (regression coefficient 0.197, $p = 0.665$), number of dislocations pre-operatively (regression coefficient 0.627, $p = 0.674$), presence of osteoarthritis at the time of follow-up (regression coefficient 1.360, $p = 0.289$) and external rotation at the time of follow-up (regression coefficient 0.601, $p = 0.696$).

Table 1: Summary of rate of instability at final follow-up vs during follow-up

Instability group*	Instability rate (%) (number of patients with dislocation + subluxation + pain)	Recurrence rate (%) (number of patients with dislocation)	Number of patients with subluxation + pain
Group A (n = 7)	22.6 (7)	9.7 (3)	4
Group B (n = 5)	16.1 (5)	9.7 (3)	2†
Group C (n = 4)	12.9 (4)	6.4 (2)‡	2†

* A, all patients with any episode of post-operative instability during follow-up; B, all patients with instability symptoms at the time of final review; C, as group B with the one late trauma patient excluded at the time of final review.
† Minus the 2 patients with no complaints of subluxation at final follow-up.
‡ Minus 1 trauma patient at 108 months after surgery.

Rowe score, Constant score and Dutch simple shoulder test

The mean Rowe score at final follow-up was 90 (66 to 98) and the mean Constant score for the operated side was 96 (85 to 100) and for the non-operated side 99 (82.5 to 100). The mean DSST was 12 of 13 (9 to 13). The mean results for each of the instability groups are presented in Table 2.

Table 2: Summary of mean (range) Rowe, Constant and Dutch simple shoulder test (DSST) scores for the different instability groups

Instability group*	Rowe score	Constant score (affected shoulder)	Constant score (unaffected shoulder)	DSST (maximum 13)
Group A (n = 7)	90 (66 to 98)	96 (85 to 100)	99 (82,5 to 100)	12 (9 to 13)
Group B (n = 5)	76 (66 to 89)	90 (85 to 95)	97 (89 to 100)	11 (9 to 13)
Group C (n = 4)	72 (66 to 78)	90 (85 to 95)	96 (89 to 100)	11 (9 to 13)

* A, all patients with any episode of post-operative instability during follow-up; B, all patients with instability symptoms at the time of final review; C, as group B with the one late trauma patient excluded at the time of final review.

Overall patient satisfaction / confidence / visual analogue score – pain

At the time of follow-up, 26 (84%) of the patients had excellent or good results. Two (6%) had poor results. Both belonged to the instability group. A total of 28 (90%) had no limitations in function. The mean visual analogue pain score was 0.5 (0 to 3) for the operated side compared with 0.2 (0 to 6) for the non-operated side. A total of 27 patients (87%) stated that they would have the operation again.

Functional results

The mean external rotation (in 0° of abduction) was 47° (10° to 75°) for the operated side compared with 53° (30° to 80°) for the non-operated side. Four patients (13%) had a difference of more than 15° of external rotation (5° to 35°) in 0° of abduction in the operated arm compared with the non-operated arm at follow-up. The mean external rotation in 90° of abduction was 89° in each arm (80° to 90°). All patients had a full range of flexion and abduction on the operated side. One showed minor restrictions (160° of flexion and abduction) on the non-operated side. In this patient, however, at the time of follow-up, radiographs showed severe signs of osteoarthritis (Samilson-Prieto[25] class III) on the non-operated side. We found a mean difference of 6° of external rotation (0° to 35°) in 0° of abduction in favor of the non-operated side (paired *t*-test, $p = 0.001$). No patient had signs of diminished strength or atrophy of the shoulder musculature on the non-operated side.

Post-operative glenohumeral osteoarthritis

At the time of follow-up, 30 (97%) of the contralateral shoulders had no signs of osteoarthritis according to the Samilson-Prieto[25] classification. As described, the remaining patient had severe unilateral osteoarthritis (Samilson-Prieto[25]-III). On the operated side, 21 shoulders (68%) had no signs of osteoarthritis (Samilson-Prieto[25]-0), nine (29%) had mild (Samilson-Prieto[25]-I) and one (3%) severe osteoarthritis (Samilson-Prieto[25]-III). The shoulders with signs of severe osteoarthritis occurred in separate patients. The incidence of osteoarthritis (Samilson-Prieto[25] class I to III) on the operated side compared with that on the non-operated side was statistically significant (McNemartest, p = 0.012). No statistically significant covariates were found regarding glenohumeral osteoarthritis on the operated side as the dependent variable (e.g. gender ($p = 0.522$), age at time of operation ($p = 0.958$), time until operation ($p = 0.686$), patient satisfaction ($p = 0.313$), instability ($p = 0.147$), number of dislocations pre-operatively ($p = 0.109$), external rotation at time of follow-up ($p = 0.525$)).

Work participation

Of the 31 patients, 29 (94%) returned to their former work or reached the same level of activity. Two (6%) changed occupation. However, these changes were not shoulder-

related. Post-operative restrictions during work were scored on a five-point ordinal scale (no problems, occasional problems, and minor, moderate and severe problems). A total of 22 patients (71%) had no restrictions at all at the time of follow-up and six (19%) had occasional problems, mainly during overhead work activities. One of these patients continued to experience instability and two showed minor signs of osteoarthritis (Samilson-Prieto[25] class I) on the operated side. Two patients (6%) had minor problems during work activities, one of whom had instability symptoms. Another patient with instability reported moderate problems during work. None of our patients described their problems as severe. In the logistic regression model no significant covariates were found with resumption of work as the dependent variable (gender $p = 0.178$, age at time of operation $p = 0.563$, time until operation $p = 0.521$, patient satisfaction $p = 0.701$, instability $p = 0.178$, number of dislocations pre-operatively $p = 0.338$, external rotation at time of follow-up $p = 0.579$, respectively).

Sports participation

Regarding the restrictions in sport activities the same ordinal scale was used. Pre-operatively, 28 patients (90%) participated in some form of sports activity, of whom 15 did contact and 13 non-contact sports. At the final follow-up, 22 (71%) participated in some form of sports activities, of whom 18 (82%) regained their pre-operative level of activity and eight (36%) resumed contact sports. Comparison of these groups (sport *versus* no sport) showed no major differences in regard to the age and the Rowe, DSST and Constant scores (Table 3).

At follow-up, one patient had severe difficulties during overhead sport activities such as tennis. This patient had no functional restrictions (external rotation > 45°), no instability or a positive apprehension test and no signs of osteoarthritis. Eight patients (26%) mentioned minor or moderate difficulties during overhead sport activities, five (16%) of whom described symptoms of instability and of these, one (3%) had severe signs of osteoarthritis (Samilson-Prieto[25] III) and three (10%) minor signs on the operated side.

Table 3: Sport *vs* no-sport group

	Sport (n = 22)	Non-sport (n = 9)
Mean age at time of follow-up (range)	41 (31 to 52)	42 (34 to 57)
Number of patients with instability complaints at time of follow-up	5	2
Mean Rowe score (range)	90 (67 to 98)	89 (67 to 97)
Mean DSST* (range)	12.5 (10 to 13)	11.9 (9 to 13)
Mean Constant score (range)	96 (85 to 100)	95 (86 to 100)

* DSST, Dutch Simple Shoulder test.

Discussion

Our study has shown that the rate of recurrent dislocation was 9.7%, all occurring after further trauma. The total rate of instability (dislocations and subluxations) was 22.6% at any stage post-operatively but by the time final review had reduced to 16.7% with inclusion of all patients.

There is always debate concerning recurrent dislocation after significant trauma regardless of timespan. Whether a dislocation after severe trauma without any foregoing shoulder complaints occurring years after stabilization should be classed as a failure is questionable. In two of the three patients with recurrence, this resulted from a new significant traumatic event and was probably not related to the stabilization procedure. One patient had a full functional shoulder without any complaints before the new injury nine years later. We believe that this patient should be classed as a recurrence, but not a failure of the operative technique.

If the rate of recurrence alone was used as an outcome of shoulder stabilization, then the success of the procedure is likely to be overestimated. Subluxation, pain and apprehension are also symptoms of instability and Kirkley et al.[26] have suggested that disease-specific measurement of quality of life should also be used. During follow-up, two patients reported feelings of instability during the first two years post-operatively, but these subsequently resolved. If we use the stringent definition of any form of post-operative instability then the outcome of the open Bankart procedure after ten years was good (12.9% (excluding high speed traumatic redislocation) to 22.6% instability), but if we use only recurrence, then the long-term results of the open Bankart procedure are excellent (6.7% (excluding high speed traumatic redislocation) to 9.7%).

Until now only short-term results of arthroscopic stabilization have been available.[27] Relatively high rates of instability (14% to 38%) are reported for arthroscopic Bankart repair with follow-up of more than five years compared with our ten-year results.[26,28]

The influence of shoulder surgery on the development of osteoarthritis is not well understood or well described in the literature.[20,25,29–34] It is unclear whether chondral injuries sustained during the episodes of instability contribute to the osteoarthritis or whether they are primarily caused by the stabilization procedure itself.[29] Generally, it is assumed that overtightening of the capsule and subscapularis lead to loss of external rotation and subsequent loss of cartilage. Stabilization techniques with a high risk of secondary glenohumeral osteoarthritis include the Putti-Platt, the Latarjet and the open Bankart procedures.[20,25,30–34] In 2004, Buscayret et al.[35] suggested that surgery did not influence the risk factors for arthritis. However, they did show a correlation between decreased external rotation after operation and glenohumeral arthritis. In their study, decreased external rotation correlated with arthritis, but this may have been secondary to glenohumeral osteoarthritis rather than a cause of it.

Our study showed that the incidence of radiological glenohumeral osteoarthritis after an open modified Bankart operation for traumatic unidirectional instability was 32% (10) for the operated side. However, nine shoulders showed mild (Samilson-Prieto[25]-I) and one severe signs of glenohumeral osteoarthritis (Samilson-Prieto[25]-III). The prevalence of osteoarthritis on the operated side after dislocation of the shoulder compared with that on the contralateral, was significantly different (10 *vs* 1, respectively, McNemar-test, $p = 0.012$). However, long-term follow-up (> 20 years) is needed to establish the degree of this mild osteoarthritis.

Van der Zwaag et al.[36] showed an increased rate of glenohumeral osteoarthritis after the Putti-Platt procedure and a positive correlation with the length of time after surgery. The number of dislocations before operation correlated with the severity of osteoarthritis but not with its incidence.[36] Our findings suggest that episodes of glenohumeral instability contribute to osteoarthritis, although the mechanism is unclear.

In our study, patients fully regained their work activities between three and six months after surgery. The general tendency is that most people can resume their pre-operative occupation and level of activity relatively quickly post-operatively.[37]

In one of the first reports concerning return to sports activities after a Bankart operation, Kjeldsen, Tordrup and Hvidt[38] found no differences in the range of movement, degree of disability or stability of the operated shoulders in two groups of patients who returned or did not return to sports activities. Of the reasons for not resuming sport, 71% gave sociopsychological causes such as anxiety or lack of time.

The results of the modified Bankart technique are rarely described in the literature,[19] but seem to show better results compared with the original Bankart or arthroscopic techniques (5% to 9% rate of recurrence, follow-up time two to five years). We found only three studies with a minimum follow-up period of ten years and these were reports of the original open Bankart procedure[12,20,39] in which the rate of recurrent dislocation varied between 0% and 10%. Our study has shown that the rate of recurrence varied between 6.7% and 9.7%, depending on how recurrence was defined.

We are aware of the limitations of the study. It is a retrospective study of a small series and there is no control group. However, we believe that our findings have shown that the modified open Bankart procedure for traumatic anterior glenohumeral dislocations is safe and effective with good objective and subjective long-term results and a high degree of patient satisfaction. As with the original procedure,[19] the modified open Bankart operation did not seem to prevent the onset of mild, asymptomatic radiological glenohumeral osteoarthritis.

References

1. Rockwood CA Jr, Matsen FA III, eds. The shoulder. Vol 1. Philadelphia: WB Saunders, 1990.
2. Bankart ASB. The pathology and treatment of recurrent dislocation of the shoulder joint. British Journal of Surgery 1938;26:23–9.
3. Latarjet M. A propos du traitement des luxations recidivantes de lápaule. Lyon Chir 1954;49:994–7.
4. Eden R. Zur operation der habutuellen schulterluxation unter mitteilung eines neuen verfahrens bei abriss am inneren pfannenrande. Dtsche Ztschr Chir 1918;144:269–80.
5. Magnuson PB, Stack JK, Peltier LF. Recurrent dislocation of the shoulder. Clin Orthop 1991;269:4–8.
6. Osmond-Clarke H. Habitual dislocation of the shoulder: The Putti-Platt operation. J Bone Joint Surg [Br] 1948;30-B:19–25. Abstract,
7. Weber BG, Simpson LA, Hardegger F. Rotational humeral osteotomy for recurrent anterior dislocation of the shoulder associated with a large Hill-Sachs lesion. J Bone Joint Surg [Am] 1984;66-A:1443–50.
8. Altcheck DW, Warren RF, Skyhar MJ, Ortiz G. T-plasty modification of the Bankart procedure for multidirectional instability of the anterior and inferior types. J Bone Joint Surg [Am] 1991;73-A:105–12.
9. Neer CS 2nd, Foster CR. Inferior capsular shift for involuntary inferior and multidirectional instability of the shoulder: a preliminary report. J Bone Joint Surg [Am] 1980;62-A:897–908.
10. Freedman KB, Smith AP, Romeo AA, Cole BJ, Bach BR Jr. Open Bankart repair versus arthroscopic repair with transglenoid sutures or bioabsorbable tacks for recurrent anterior instability of the shoulder: a meta-analysis. Am J Sports Med 2004;32:1520–7.
11. Mohtadi NG, Bitar IJ, Sasyniuk TM, Hollinshead RM, Harper WP. Arthroscopic versus open repair for traumatic anterior shoulder instability: a meta-analysis. Arthroscopy 2005;21:652–8.
12. Tingart M, Bathis H, Bouillon B, Neugebauer E, Tiling T. Surgical therapy of traumatic shoulder dislocation: are there evidence-based indications for arthroscopic Bankart operation? Unfallchirurg 2001;104:894–901 (in German).
13. Lenters TR, Franta AK, Wolf FM, Leopold SS, Matsen FA 3rd. Arthroscopic compared wih open repairs for recurrent anterior shoulder instability: a systematic review and meta-analysis of the literature. J Bone Joint Surg [Am] 2007;89-A:244–54.
14. Gill TJ, Zarins B. Open repairs for the treatment of anterior shoulder instability. Am J Sports Med 2003;31:142–53.
15. Pagnani MJ, Dome DC. Surgical treatment of traumatic anterior shoulder instability in american football players. J Bone Joint Surg [Am] 2002;84-A:711–15.
16. Rokito AS, Namkoong S, Zuckerman JD, Gallagher MA. Open surgical treatment of anterior glenohumeral instability: an historical perspective and review of the literature. Part I. Am J Orthop 1998;27:723–5.
17. Rokito AS, Namkoong S, Zuckerman JD, Gallagher MA. Open surgical treatment of anterior glenohumeral instability: an historical perspective and review of the literature. Part II. Am J Orthop 1998;27:784–90.
18. Hovelius LK, Sandstrom BC, Rosmark DL, et al. Long-term results with the Bankart and Bristow-Latarjet procedures: recurrent shoulder instability and arthropathy. J Shoulder Elbow Surg 2001;10:445–52.
19. Pelet S, Jolles BM, Farron A. Bankart repair for recurrent anterior glenohumeral instability: results at twenty-nine years' follow-up. J Shoulder Elbow Surg 2006;15:203–7.

20. Rosenberg BN, Richmond JC, Levine WN. Long-term follow up of Bankart reconstruction: incidence of late degenerative glenohumeral arthrosis. Am J Sports Med 1995;23:538–44.
21. Rowe CR, Patel D, Southmayd WW. The Bankart procedure: a long-term end-result study. J Bone Joint Surg [Am] 1978;60-A:1–16.
22. Constant CR, Murley AH. A clinical method of functional assessment of the shoulder. Clin Orthop 1987;214:160–4.
23. Lippitt S, Matsen F. Mechanisms of glenohumeral joint stability. Clin Orthop 1993;291:20–8.
24. Langley GB, Sheppeard H. The visual analogue scale: its use in pain measurement. Rheumatol Int 1985;5:145–8.
25. Samilson RL, Prieto V. Dislocation arthropathy of the shoulder. J Bone Joint Surg [Am] 1983;65-A:456–60. Crossref.
26. Kirkley A, Werstine R, Ratjek A, Griffin S. Prospective randomized clinical trial comparing the effectiveness of immediate arthroscopic stabilization versus immobilization and rehabilitation in first traumatic anterior dislocations of the shoulder: long-term evaluation. Arthroscopy 2005;21:55–63.
27. Calvo E, Granzio JJ, Fernández-Yruegas D. Criteria for arthroscopic treatment of anterior instability of the shoulder: a prospective study. J Bone Joint Surg [Br] 2005; 87-B:677–83. Abstract,
28. Kartus J, Kartus C, Matis N, Forstner R, Herbert H. Long term independent evaluation after arthroscopic extra-articular Bankart repair, with absorbable tacks: a clinical and radiological study with a seven to ten-year follow-up. J Bone Joint Surg [Am] 2007;89-A:1442–8.
29. Cameron ML, Kocher MS, Briggs KK, Horan MP, Hawkins RJ. The prevalence of glenohumeral osteoarthrosis in unstable shoulders. Am J Sports Med 2003;31:53–5.
30. Hawkins RJ, Angelo RL. Glenohumeral osteoarthrosis: a late complication of the Putti-Platt repair. J Bone Joint Surg [Am] 1990;72-A:1193–7.
31. Morrey BF, Janes JM. Recurrent anterior dislocation of the shoulder: long-term follow-up of the Putti-Platt and Bankart procedures. J Bone Joint Surg [Am] 1976;58-A:252–6.
32. O'Driscoll SW, Evans DC. Long-term results of staple capsulorrhaphy for anterior instability of the shoulder. J Bone Joint Surg [Am] 1993;75-A:249–58.
33. Trevlyn DW, Richardson MW, Fanelli GC. Degenerative joint disease following extracapsular anterior shoulder reconstruction. Contemp Orthop 1992;25:151–6.
34. Zuckerman JD, Matsen FA 3rd. Complications about the glenohumeral joint related to the use of screws and staples. J Bone Joint Surg [Am] 1984;66-A:175–80.
35. Buscayret F, Edwards TB, Szabo I, et al. Glenohumeral arthrosis in anterior instability before and after surgical treatment: incidence and contributing factors. Am J Sports Med 2004;32:1165–72.
36. van der Zwaag HM, Brand R, Obermann WR, Rozing PM. Glenohumeral osteoarthrosis after Putti-Platt repair. J Shoulder Elbow Surg 1999;8:252–8.
37. Gill TJ, Micheli LJ, Gebhard F, Binder C. Bankart repair for anterior instability of the shoulder: long-term outcome. J Bone Joint Surg [Am] 1997;79-A:850–7.
38. Kjeldsen SR, Tordrup PJ, Hvidt EP. Return to sport after a Bankart operation of the shoulder using the Mitek anchor system. Scand J Med Sci Sports 1996;6:346–51.
39. Chapnikoff D, Besson A, Chantelot C, et al. Bankart procedure: clinical and radiological long-term outcome. Rev Chir Orthop Reparatrice Appar Mot 2000;86:558–65 (in French).

6

Chapter 6

The open-modified Bankart procedure: a 16–26 years follow-up study

Thomas Berendes · Nina Mathijssen · Hennie Verburg · Gerald Kraan

Arch Orthop Trauma Surg. 2018;138(5):597-603

Abstract

Introduction: A Bankart procedure is a surgical technique for the repair of recurrent shoulder joint dislocations. This study reports the long-term results of the open-modified Bankart procedure.

Methods: We performed a retrospective cohort study in which patients were included who had open-modified Bankart surgery for posttraumatic instability problems of their shoulder in the absence of a substantial osseous glenoid defect, 16–26 years ago. Instability was measured with the Rowe and Oxford shoulder instability score. Furthermore, we measured physical functioning with the Constant–Murley score and the Dutch simple shoulder test. Pain was measured with the NRS for pain. Osteoarthritis was scored according the Samilson–Prieto score. Quality of life was measured with the SF-12 score. The operated shoulder was compared to the non-operated contralateral shoulder regarding instability and osteoarthritis.

Results: 39 patients were included with an average follow-up of 21 years (range 16–26 years). The number of patients with redislocations of their shoulder after surgery was 4 (10%). 23% of the study group described moments of subluxation or positive apprehension. Radiological signs of osteoarthritis were present in 20 shoulders (51%), of which 75% had grade 1 arthropathy according to the Samilson Prieto score. The incidence of osteoarthritis of the operated shoulder was significantly greater compared to the non-operated shoulder. The mean Rowe score was 85 points (25–100) and the Constant score 92 points (70–100).

Conclusion: We conclude that the open-modified Bankart procedure is a reliable surgical procedure with good long-term results, 16–26 years after surgery. However, it does not prevent the development of shoulder osteoarthritis, since a high number of patients had (mainly mild) radiological osteoarthritis.

Keywords: Shoulder · Joint instability · Surgery · Osteoarthritis

Introduction

Dislocation of the glenohumeral joint in anterior direction is the most common dislocation in human joints with a reported incidence of 1–2% in the general population.[1-12]

The recurrence rate after an acute first-time anterior shoulder dislocation (AFASD) in young patients under 20 years of age is high and reported up to 90%.[1-12] In patients older than 40 years, the incidence significantly drops to 10–15%.[3,13] The majority of all recurrences occur within the first 2 years after the primary dislocation.[2,14-17] The best treatment of AFASD in young patients remains a debated issue. Nowadays, a wide variety of pathologic entities has been described in association with shoulder instability, and many therapeutic strategies have been developed to address these. In young patients with recurrent dislocations or in selected patients who are active in sports, surgical treatment is propagated.[18] In the Netherlands, the operation of choice for this instability problem is until recently most often the Bankart repair.[19]

In our hospital (Reinier de Graaf, Delft, the Netherlands), the introduction of the open-modified Bankart-stabilizing procedure started in 1989 and was always carried out in the same way by two senior orthopedic surgeons. A mid-term follow-up study (10–15 years) for the same cohort of patients was previously been published in 2007.[20] Several other studies on the long-term outcome of the Bankart procedure have already been reported in literature.[21-24] They all had reliable results in restoring shoulder stability, demonstrated low rates of recurrent instability, dislocation, and reoperation. However, it seems that the procedure does not prevent the development of shoulder osteoarthritis. Therefore, further investigation is needed to assess the impact of Bankart procedures on the development of long-term osteoarthritis. Our current research focusses on the long-term results regarding stability and osteoarthritis at time of final follow-up, with a minimum follow-up of 16 years after surgery.

The goal of this study was to compare the results regarding stability, function, and osteoarthritis of the operated shoulder with the contralateral shoulder. Following the good results in 2007, it was hypothesized that patients had a restored shoulder joint stability and that the redislocation rate would be low. However, we expected to see an increase of radiological osteoarthritis.

Patients and methods

All patients operated on between January 1989 and January 2004 for stabilization of the shoulder with the open-modified Bankart technique were screened for participation in the study. The indication had to be persisting instability after *traumatic* anterior luxation of the shoulder in the absence of a substantial osseous glenoid defect. To be eligible to

participate in this study, a subject had to be 18 years or older. Subjects had to be willing and to be able to participate the current study and they had to speak and write the Dutch language. Patients who had previous surgery on their affected shoulder or had surgery on their contralateral shoulder were excluded for this study.

All included patients visited the hospital for physical and radiological examination. Physical examination was being carried out by two objective examiners. Standardized physical examination was performed including two validated clinician-based outcome measurements, being the Rowe shoulder score, also known as rating sheet for Bankart repair and the score of Constant and Murley.[24-27] In the Rowe scoring system, stability, range of movement, and shoulder function are assessed. The Constant-Murley shoulder score is a shoulder-specific outcome scoring system that assesses pain, activities of daily living, range of motion (abduction, anteflexion, internal, and external rotation), and power.[26,27] We used a Hand-held dynamometer to measure muscle strength.

Furthermore, two shoulder-related patient reported outcome measures (PROM's) were completed by the patient: the Oxford shoulder instability score (OSIS) and the Dutch simple shoulder test (DSST).[28-30] The Oxford instability score is a shoulder-specific, condition-specific, patient-based outcome measure that uses a 12-item questionnaire in which each question has five-graded responses. It addresses symptoms of instability, pain, and activities of daily living, with the overall score being obtained as the arithmetic sum of each graded response without any need for further calculation. The Dutch Simple shoulder test assesses post-operative function by means of 12 questions with yes or no answers. Furthermore, pain was scored using the Numeric Pain Rating Scale Instructions (NRS) and quality of life was measured using the 12-Item Short Form Health Survey (SF-12).[31] The SF-12 score provides glimpses into the mental and physical functioning and overall health-related-quality of life of our patient group. The mean outcome scores of the 12-Item Short Form Health Survey (SF12) for our study group are expressed in terms of two meta-scores, divided into the physical component summary (PCS) and the mental component summary (MCS).

Radiological evaluation was performed by one objective examiner using the classification system of Samilson and Prieto.[32] True internal and external rotation views, as well as an axillary view, were taken of both shoulders. The results of the operated shoulder regarding stability, function, and osteoarthritis were compared to the results of the contralateral shoulder. To calculate the sample size, data from the study of Pelet and Fabre et al. were used.[23,33] They determined the Rowe score for instability of the shoulder after surgery with the open-modified Bankart procedure. The mean Rowe score of the operated shoulder was 80.0 and the mean Rowe score of the non-operated shoulder was 99.8. Standard deviation was 23. Using power of 90% and alpha of 0.05, the required sample size was 29 patients per group.

This study has been approved by the local Medical Ethics Committee (NL52656.098.15. METC ZWH nr: 15-024) and all patients gave written informed consent.

Operative technique

The patient is under general anesthesia in a beach-chair position. Deltopectoral approach. The subscapularis tendon is incised vertically, approximately 1.5 cm medial to its insertion, leaving the inferior part intact. The capsule is incised vertically on the lateral side. A T-shaped capsular opening is created, raising a superior and an inferior capsular flap. The cortical layer of the glenoid rim is roughened with an osteotome to expose parts of bleeding cancellous bone.

Three-to-four holes for bone anchors are made on the edge of the glenoid. Mitek I and later Mitek II (DePuy Mitek, Raynham, Massachusetts) anchors were used. The labrum (or its remnants) and the medial capsular flap is then reattached to the glenoid and the rotator interval closed. The two capsular flaps are then shifted, the superior flap inferiorly and the inferior flap superiorly, until it is sufficiently tight. The arm is held in neutral rotation and in abduction of approximately 30° during this manoeuvre. Finally, two additional sutures are placed between the two capsular flaps to close the horizontal T incision of the repair. The subscapularis muscle is reattached anatomically to its insertion. Post-operatively, the arm is placed in a shoulder immobilizer for 6 weeks.

Statistical analysis

Statistical analysis was performed using SPSS (version 22 for Windows, SPSS Inc., Chicago, Illinois). Simple cross-table analysis was used to quantify the relationship between discrete outcome variables, such as instability and osteoarthritis. To determine differences between the operated and the contralateral shoulder, we used the Chi-squared test or Fisher's exact test for the binary variables. In cases of paired binary data, we used the McNemar test and a paired *t*-test for mean differences.

Results

106 patients were eligible for participation in this study of which 39 patients were included (Fig. 1). Median follow-up was 21 years (range 16–26 years). Most patients were male (32 out of 39, 82%) with an average age at time of operation of 31 years (range 18–47). Fourteen of the operations were on the dominant side (36%) and no complications were recorded.

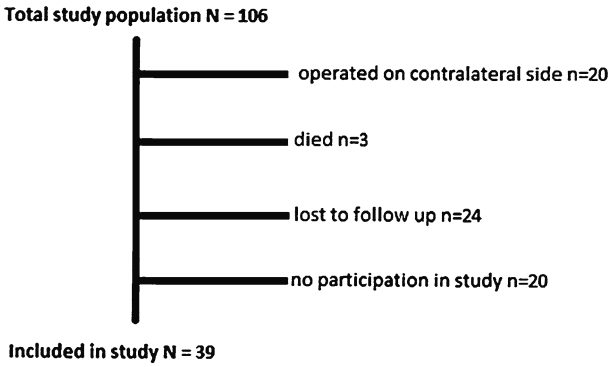

Fig. 1: Inclusion of patients.

Post-operative glenohumeral osteoarthritis

Twenty (51%) of the operated shoulders showed signs of osteoarthritis. Three (8%) of the contralateral shoulders showed signs of osteoarthritis (Table 1).

Stability

Four patients (10%), all male, had encountered a redislocation after surgery. Two patients declared only a single redislocation. One patient stated four redislocations after surgery, all of which during sports activities (soccer and swimming). The other patient reported three redislocations, again all initiated during sport activities (soccer and volleyball). No redislocations were present in activities of daily living or at night in rest. All four patients also described moments of fear of subluxation in upper movements, especially during sports activity. Another five patients, together 23% of the study group described moments of subluxation, again mostly during sports activity. For all above-mentioned patients, their instability feelings disappeared after stopping their sports activities.

We compared the unstable group with the stable group, regarding Constant score, oxford and Dutch simple shoulder test for the operated side. No differences in constant score could be found ($p = 0.642$; $p = 0.050$; and $p = 0.250$, respectively). The Rowe score was different between these groups ($p = 0.005$). The incidence of osteoarthritis between these groups was comparable ($p = 0.327$). All tests are performed with a Mann-Whitney U test. The incidence of OA between groups was tested with a Chi-squared test.

Shoulder scores

The mean Rowe score of the operated shoulder was 85 (range 25–100) and the mean Constant score for the operated side was 92 (range 70–100) (Table 1). The median Oxford shoulder instability score was 16 (range 11–31) and the median outcome of the Dutch simple shoulder test was 11 (range 7–12). The mean outcome scores of the

Table 1: Osteoarthritis, Rowe and Constant-Murley score and NRS for pain and functional results

	Operated shoulder	Contralateral shoulder	*p*-value
Osteoarthritis Grade I Grade II Grade III	20/39 15/39 4/39 1/39	3/39 1/39 1/39 1/39	$p < 0.0001$, McNemar test
Rowe score [mean (range) points]	85 (25-100)	97 (55-100)	0.002
Constant-Murley score [mean (range) points]	92 (70-100)	94 (82-100)	0.024
NRS pain (0/10) [mean (range) points]	1 (0-6)	0 (0-5)	0.071
External rotation [mean (range) ° in scapular plane]	70 (20-90)	80 (35-95)	< 0.001
Anteflexion [mean (range) ° in scapular plane]	176 (160-180)	177 (170-180)	0.096
Abduction [mean (range) ° in scapular plane]	175 (120-180)	178 (170-180)	0.090
Force [mean (range) kg]	16 (4-45)	16 (5-42)	0.483

SF-12 questionnaire for our study group divided into PCS SF-12 and MCS SF12 are, respectively, 42.5 (range 29–50) and 48.3 (range 31–58).

Functional results

The mean external rotation (in the scapular plane) was 70° (range 20°–90°) for the operated side compared with 80° (range 35°–95°) on the contralateral non-operated side. We found a mean difference of 10° of external rotation in line of the scapula in favor of the non-operated side ($p < 0.001$) (Table 1).

Twelve patients had a difference of 15° or more of external rotation in the scapular plane in the operated arm compared with the non-operated contralateral arm at time of follow-up. All patients had a minimum of 160° of anteflexion on the operated (and non-operated) arm. No patients had signs of diminished strength or atrophy of the shoulder muscle on the operated side (Table 1). No significant difference was found in external rotation in the scapular plane on the operated shoulders between two sub-groups of patients with versus without signs of osteo- arthritis [mean external rotation 71 (range 20–90) versus 70 (35–90), $p = 0.902$].

Sport participation

None of the patients in this study were high-active or top sport athletes, both before and after the operation. At time of the final follow-up, ten patients (26%) did not participate

in sport activities, mostly for other reasons than their shoulder. Three patients (8%) stated stopping their sport (soccer) by reasons of their shoulder, one of which being a goalkeeper. Twenty-nine patients (74%) stated to do sport, all at recreative level, varying in overhead, contact to non-contact sports. Comparison of these two sub-groups (sport versus no sport at time of follow-up) showed no major differences regarding age, Rowe score (p = 0.530) and Constant scores (p = 0.178) and the presence of signs of osteoarthritis (p = 0.728).

Case presentations

Here, we present the X-ray of the operated left shoulder from a 42-year-old patient, 26 years after surgery, with three bone anchors in place (Fig. 2). You can see mild signs of glenohumeral arthrosis, rated grade 1 according to the Samilson and Prieto classification, with inferior humeral and/or glenoid exostosis < 3 mm in height.

No more dislocation or subluxations occurred after surgery with VAS scores for pain of 0 (in rest and for activity). At the final follow-up, the shoulder showed good functional outcome scores, with an exorotation of 70° (in 0° of abduction of the arm) versus 90° on his contralateral non-operated right shoulder. His sports activities at final time of follow-up were hockey, fitness, and skiing.

Fig. 2: X-ray of left shoulder with three bone anchors in place.

Another X-ray of a right shoulder is from another 57-year-old patient, 22 years after surgery, with four bone anchors in place (Fig. 3). Here, no signs of glenohumeral arthrosis are present.

Again, no dislocation or subluxations occurred after surgery with VAS scores for pain of 0 (in rest and for activity). At the final follow-up, the shoulder showed good functional outcome scores, with an exorotation of 80° (in 0° of abduction of the arm) versus 90° on his contralateral non-operated right shoulder. His sports activities at the final time of follow-up were running and skiing. Remarkable was that he luxated his non-operated left shoulder after surgery by a fall with skiing, while his operated right shoulder remained stable.

Fig. 3: X-ray of right shoulder with four bone anchors in place.

Discussion

The purpose of this study was to describe the long-term results regarding stability and osteoarthritis 16–26 years after an open-modified Bankart procedure for persisting instability problems after AFASD. The Bankart lesion, or anterior labral detachment, is the most commonly recognized pathologic lesion of traumatic anterior instability. However, associated osseous deficiencies are also common, particularly in patients with recurrent instability or those with unsuccessful surgical stabilization. Osseous lesions may be present in up to 89% of failed stabilizations.[34] Until now, at least in the Netherlands, it is common to perform a reattachment procedure of the labral detachment possibly with a capsular procedure when no or only minor osseous defects are present.

Our study shows that the redislocation rate after the open-modified Bankart procedure is low, being 10% (4/39), 16–26 years after surgery, with an instability rate (dislocations and subluxations or positive apprehension) of 23% (9/39). This is in accordance with the long-term results of Pelet and Fabre with a mean follow-up of, respectively, 29 and 26 years.[23,33] In our earlier study (10–15 years follow-up), we had also a 10% (3/31) redislocation rate, with two redislocations after further trauma.[20] Therefore, in our study group of open-modified Bankart repairs, we do not see a decreasing effectiveness of the repair over time as in the study of Zimmermann in which he used an arthroscopic Bankart technique.[35] However, the definition of recurrence rate can be discussed. Whether a new dislocation after a severe trauma (i.e., contact sport) without any foregoing shoulder complaints occurring years after stabilization should be classified as a failure.[20] One can debate how we should define a failure after surgical treatment for anterior shoulder instability.[36] Subluxations are failures too, considering the fact that stable shoulder function is the purpose of treatment. The subjective experience of a shoulder subluxation or positive apprehension is very inconvenient and an adverse surgical outcome for patients. In addition, recurrent traumatic subluxation itself can be a reason for surgical treatment initially.[36]

Of course, one can also debate the term "acceptable outcome", but comparing with the literature, a 10% redislocation rate and 23% instability rate (including redislocations and subluxations) at more than 16 years after surgery (16–26 year follow-up) is to our knowledge still not being recorded for the arthroscopic group. Again, a reference is being made to the high failure rate of the arthroscopic Bankart repairs in the study of Zimmermann.[35] Instability or positive apprehension persisted or recurred in his late study after a minimum of 6 years follow-up in 113 (42%) of the 271 arthroscopic Bankart procedures.

Our mid-term results showed already that the open-modified Bankart procedure did not prevent the development of shoulder osteoarthritis (OA), with a significant difference in the prevalence of OA on the operated side after dislocation of the shoulder compared with that on the contralateral, non-operated side.[20] For the operated side, we saw radiological signs of arthrosis in 10 out of 31 shoulders (32%), of which nine classified grade 1 and one grade 3 according the Samilson–Prieto classification. For the non-operated shoulders, only one patient showed signs of osteoarthritis (Samilson–Prieto grade 3). Our current study showed a higher rate of (meanly minor) OA in the operated group, being 51% (n = 20 out of 39) versus OA of only 8% in the non-operated side in the same group. However, of those patients with arthropathy on the operated side, 15 patients (75%) had only minor signs of glenohumeral arthrosis (Samilson–Prieto stage I). Four shoulders were classified as grade 2 according the Samilson–Prieto classification and one shoulder grade 3. From this data, no certainty is given whether the stabilizing shoulder surgery itself is a potential contribution to the osteoarthritis process or the

(repetitive) chondral injuries sustained during the episodes of instability.[37-44] We did not see signs of functional loss in the group of OA in our study population comparing the non-OA group. The mean external rotation in the OA group was comparable to the mean external rotation in the non-OA group.

Our study had several limitations. This retrospective cohort study initially deals with people around the University city of Delft in The Netherlands. We do not know whether this will give a good reflection of the general Dutch population. This is probably a form of selection bias. However, we have no compared data with the rest of the population in The Netherlands.

Unfortunately, in our study, we see Attrition bias. It is a kind of selection bias caused by attrition (loss of participants) or dropouts. We had a high number of dropouts, with 24 patients being lost to follow-up, three patients died during the follow-up period and another 20 patients refused to participate with this study (not for reasons of their shoulder). Therefore, it gives biased results, where it is probably unequal in regard to outcome and results have to be interpreted with care.

However, we think that this study is of significant value because of its unique group of patients being operated on in the same manner by two senior orthopedic surgeons at a mean follow-up of 21 years (range 16–26 years). There is no management variation in patient pathways for AFASD in this cohort study, with a constant operative strategy through time. Thereby, we evaluated the patients included in the study in the same way compared with our earlier study in 2007, all with radiographic examination for both shoulders.[20] Our results of the open-modified Bankart procedure for traumatic anterior glenohumeral dislocations again showed that it is a safe and effective procedure with good long-term results. We think that it can serve as a golden standard for the nowadays frequently used arthroscopic procedures or the more osseous oriented reconstruction techniques.

In conclusion, the open-modified Bankart technique is a reliable surgical procedure with good long-term outcome, 16–26 years after surgery. However, it does not prevent the development of shoulder osteoarthritis, since a high number of patients had (mainly mild) radiological osteoarthritis.

References

1. Moseley HF (1962) Recurrent dislocation of the shoulder. Postgrad Med 31:23–29. http://www.ncbi.nlm.nih.gov/pub-med/14476433. Accessed 27 Nov 2016
2. Rowe CR (1956) Prognosis in dislocations of the shoulder. J Bone Jt Surg Am 38-A(5):957–977
3. McLaughlin HL, MacLellan DI (1967) Recurrent anterior dislocation of the shoulder. II. A comparative study. J Trauma 7(2):191–201
4. Simonet WT, Cofield RH (2010) Prognosis in anterior shoulder dislocation. Am J Sports Med 12(1):19–24. http://www.ncbi.nlm.nih.gov/pubmed/6703178. Accessed 19 Sep 2010
5. Rowe CR, Sakellarides HT (1961) Factors related to recurrences of anterior dislocations of the shoulder. Clin Orthop 20:40–48. http://www.ncbi.nlm.nih.gov/pubmed/13744116. Accessed 27 Nov 2016
6. McLaughlin HL, Cavallaro WU (2016) Primary anterior dislocation of the shoulder. Am J Surg 80(6):615–621. http://www.ncbi.nlm.nih.gov/pubmed/14790098. Accessed 27 Nov 2016 (passim)
7. Hovelius L (1987) Anterior dislocation of the shoulder in teen- agers and young adults. Five-year prognosis. J Bone Jt Surg Am 69(3):393–399
8. Kiviluoto O, Pasila M, Jaroma H, Sundholm A (1980) Immobilization after primary dislocation of the shoulder. Acta Orthop Scand 51(6):915–919. http://www.ncbi.nlm.nih.gov/pubmed/7211296. Accessed 3 Jan 2014
9. Arciero RA, Wheeler JH, Ryan JB, McBride JT (1994) Arthroscopic Bankart repair versus nonoperative treatment for acute, initial anterior shoulder dislocations. Am J Sport Med 22(5):589–594
10. Henry JH, Genung JA (2010) Natural history of glenohumeral dislocation revisited. Am J Sports Med 10(3):135–137. http://www.ncbi.nlm.nih.gov/pubmed/7114346. Accessed 19 Sep 2010
11. Hovelius L, Augustini BG, Fredin H, Johansson O, Norlin R, Thorling J (1996) Primary anterior dislocation of the shoulder in young patients. A ten-year prospective study. J Bone Jt Surg Am 78(11):1677–1684
12. Wheeler JH, Ryan JB, Arciero RA, Molinari RN (1989) Arthroscopic versus nonoperative treatment of acute shoulder dislocations in young athletes. Arthroscopy 5(3):213–217
13. Rowe CR, Sakellarides HT (1961) Factors related to recurrences of anterior dislocations of the shoulder. Clin Orthop 20:40–48
14. Rowe CR (1978) Instabilities of the glenohumeral joint. Bull Hosp Jt Dis 39(2):180–186. http://www.ncbi.nlm.nih.gov/pub-med/753446. Accessed 27 Nov 2016
15. Townley CO (1950) The capsular mechanism in recurrent dislocation of the shoulder. J Bone Jt Surg Am 32A(2):370–380. http://www.ncbi.nlm.nih.gov/pubmed/15412179. Accessed 27 Nov 2016
16. Moseley HF (1963) The basic lesions of recurrent anterior dislocation. Surg Clin N Am 43:1631–1634. http://www.ncbi.nlm.nih.gov/pubmed/14090212. Accessed 27 Nov 2016
17. Adams JC (1948) Recurrent dislocation of the shoulder. J Bone Jt Surg Br 30B(1):26–38. http://www.ncbi.nlm.nih.gov/pub-med/18864943. Accessed 27 Nov 2016
18. Handoll HHG, Almaiyah MA, Rangan A (2004) Surgical versus non-surgical treatment for acute anterior shoulder dislocation. Cochrane Database Syst Rev 2004(1):CD004325. https://doi.org/10.1002/14651858.CD004325.pub2
19. Berendes TD, Pilot P, Nagels J, Vochteloo AJH, Nelissen RGHH (2015) Survey on the management of acute first-time anterior shoulder dislocation amongst Dutch public hospitals. Arch Orthop Trauma Surg. https://doi.org/10.1007/s00402-015-2156-3

20. Berendes TD, Wolterbeek R, Pilot P, Verburg H, te Slaa RL (2007) The open modified Bankart procedure: outcome at follow-up of 10 to 15 years. J Bone Jt Surg Br 89(8):1064–1068. https://doi.org/10.1302/0301-620X.89B8.19280
21. Chapnikoff D, Besson A, Chantelot C, Fontaine C, Migaud H, Duquennoy A (2000) Bankart procedure: clinical and radio- logical long-term outcome. Rev Chir Orthop Repar Appar Mot 86(6): 558–565
22. Gill TJ, Micheli LJ, Gebhard F, Binder C (1997) Bankart repair for anterior instability of the shoulder. Long-term outcome. J Bone Jt Surg Am 79(6):850–857
23. Pelet S, Jolles BM, Farron A (2006) Bankart repair for recurrent anterior glenohumeral instability: results at twenty-nine years' follow-up. J Shoulder Elb Surg 15(2):203–207
24. Rowe CR, Patel D, Southmayd WW (1978) The Bankart procedure: a long-term end-result study. J Bone Jt Surg Am 60(1):1–16
25. Williams GN, Gangel TJ, Arciero RA, Uhorchak JM, Taylor DC (2016) Comparison of the single assessment numeric evaluation method and two shoulder rating scales. Outcomes measures after shoulder surgery. Am J Sports Med 27(2):214–221. http://www.ncbi.nlm.nih.gov/pubmed/10102104. Accessed 29 Apr 2016
26. Constant CR, Murley AH (1987) A clinical method of functional assessment of the shoulder. Clin Orthop Relat Res 214:160–164. http://www.ncbi.nlm.nih.gov/pubmed/3791738. Accessed 3 Feb 2016
27. Dawson J, Hill G, Fitzpatrick R, Carr A (2001) The benefits of using patient-based methods of assessment. Medium-term results of an observational study of shoulder surgery. J Bone Jt Surg Br 83(6):877–882
28. Dawson J, Fitzpatrick R, Carr A (1999) The assessment of shoulder instability. The development and validation of a questionnaire. J Bone Jt Surg Br 81(3):420–426
29. van der Linde JA, van Kampen DA, van Beers LWAH., van Deurzen DFP, Terwee CB, Willems WJ (2015) The Oxford Shoulder Instability Score; validation in Dutch and first-time assessment of its smallest detectable change. J Orthop Surg Res 10:146. https://doi.org/10.1186/s13018-015-0286-5
30. Constant CR, Murley AH (1987) A clinical method of functional assessment of the shoulder. Clin Orthop Relat Res 214:160–164
31. Ware J, Kosinski M, Keller SD (1996) A 12-Item Short-Form Health Survey: construction of scales and preliminary tests of reliability and validity. Med Care 34(3):220–233. http://www.ncbi.nlm.nih.gov/pubmed/8628042. Accessed 21 July 2016
32. Samilson RL, Prieto V (1983) Dislocation arthropathy of the shoulder. J Bone Jt Surg Am 65(4):456–460
33. Fabre T, Abi-Chahla ML, Billaud A, Geneste M, Durandeau A (2010) Long-term results with Bankart procedure: a 26-year follow-up study of 50 cases. J Shoulder Elb Surg 19(2):318–323. https://doi.org/10.1016/j.jse.2009.06.010
34. Schrumpf MA, Maak TG, Delos D et al (2014) The management of anterior glenohumeral instability with and without bone loss: AAOS exhibit selection. J Bone Joint Surg Am 96(2):e12. https://doi.org/10.2106/JBJS.L.01377
35. Zimmermann SM, Scheyerer MJ, Farshad M, Catanzaro S, Rahm S, Gerber C (2016) Long-term restoration of anterior shoulder stability: a retrospective analysis of arthroscopic Bankart repair versus open Latarjet procedure. J Bone Jt Surg Am 98(23):1954–1961. https://doi.org/10.2106/JBJS.15.01398
36. van der Linde JA, van Kampen DA, Willems JW (2013) How should we define failure after surgical shoulder stabilization? Arthroscopy 29(10):1602. https://doi.org/10.1016/j.arthro.2013.08.008

37. Rosenberg BN, Richmond JC, Levine WN (1995) Long-term follow-up of Bankart reconstruction. Incidence of late degenerative glenohumeral arthrosis. Am J Sport Med 23(5):538–544
38. Cameron ML, Kocher MS, Briggs KK, Horan MP, Hawkins RJ (2003) The prevalence of glenohumeral osteoarthrosis in unstable shoulders. Am J Sport Med 31(1):53–55
39. Hawkins RJ, Angelo RL (1990) Glenohumeral osteoarthrosis. A late complication of the Putti-Platt repair. J Bone Jt Surg Am 72(8):1193–1197
40. Morrey BF, Janes JM (1976) Recurrent anterior dislocation of the shoulder. Long-term follow-up of the Putti-Platt and Bankart procedures. J Bone Jt Surg Am 58(2):252–256
41. O'Driscoll SW, Evans DC (1993) Long-term results of staple capsulorrhaphy for anterior instability of the shoulder. J Bone Jt Surg Am 75(2):249–258
42. Trevlyn DW (1992) Degenerative joint disease following extracapsular anterior shoulder reconstruction. Contemp Orthop 25:151–156
43. Zuckerman JD, Matsen 3rd FA (1984) Complications about the glenohumeral joint related to the use of screws and staples. J Bone Jt Surg Am 66(2):175–180
44. Saxena V, D'Aquilla K, Marcoon S et al (2016) T1ρ magnetic resonance imaging to assess cartilage damage after primary shoulder dislocation. Am J Sports Med. https://doi.org/10.1177/0363546516655338

7

Chapter 7

A novel treatment for anterior shoulder instability

A biomechanical comparison between a patient-specific implant and the Latarjet procedure

Koen Willemsen · Thomas Berendes · Timon Geurkink · Ronald Bleys · Marius Leeflang · Harrie Weinans · Rene Castelein · Rob Nelissen · Bart van der Wal

J Bone Joint Surg Am. 2019;101(14):1-8

Abstract

Background: Anterior glenohumeral instability with > 20% glenoid bone loss is a disorder that can be treated with the Latarjet stabilizing procedure. However, complications are common. The purposes of this study were to (1) evaluate the effect of an anatomic-specific titanium implant produced by 3-dimensional (3D) printing as a treatment option for recurrent shoulder instability with substantial glenoid bone loss and (2) compare the use of that implant with the Latarjet procedure.

Methods: Ten fresh-frozen cadaveric shoulders (mean age at the time of death, 78 years) were tested in a biomechanical setup with the humerus in 30° of abduction and in neutral rotation. The shoulders were tested under 5 different conditions: (1) normal situation, (2) creation of an anterior glenoid defect, (3) implantation of an anatomic-specific titanium implant produced by 3D printing, and the Latarjet procedure (4) with and (5) without 10 N of load attached to the conjoined tendon. In each condition, the humerus was translated 10 mm anteriorly relative to the glenoid, and the maximum peak translational force that was necessary for this translation was measured.

Results: After creation of the glenoid defect, the mean translational peak force decreased by 30% ± 6% compared with that for the normal shoulder. After restoration of the original glenoid anatomy, the translational force needed to dislocate the humeral head from the glenoid significantly increased compared with that in the defect condition – to 119% ± 16% of normal ($p < 0.01$) with the 3D-printed anatomic-specific implant and to 121% ± 48% of normal ($p < 0.01$) following the Latarjet procedure. No significant differences in mean translational force were found between the anatomic-specific implant and the Latarjet procedure ($p = 0.72$).

Conclusions: The mean translational peak force needed to dislocate the humerus 10 mm anteriorly on the glenoid was higher after glenoid restoration with the 3D-printed anatomic-specific implant compared with when the glenoid had a 20% surface defect but also compared with when the glenoid was intact. No differences in mean translational peak force were found between the 3D-printed anatomic-specific glenoid implant and the Latarjet procedure, although there was less variability in the 3D-implant condition.

Clinical relevance: Novel 3D-printing technology could provide a reliable patient-specific alternative to solve problems related to traditional treatment methods for shoulder instability.

Introduction

Anterior glenohumeral instability is a common disorder, typically affecting the young and active population, with an overall prevalence of 2%.[1,2] The shoulder joint is the most mobile joint in the human body. However, this mobility comes at the expense of stability.[1] A first dislocation often has a traumatic origin and is often followed by a disabling course as recurrent (sub)luxations occur in up to 94% of patients, especially younger ones.[3] Eventually, this can lead to chronic anterior shoulder instability, with presentations ranging from minor symptoms to frequent (sub)luxations.[1] Without adequate treatment, this condition often leads to more rapid degenerative arthropathy of the shoulder and major limitations in daily life.[2,4] There are numerous surgical treatment options for the unstable shoulder joint, and they target different causes of a multifactorial problem. With all treatments, the aim is to lower the rate of recurrence of dislocations in combination with a low complication rate. The dynamic interactions of soft tissue lesions and bone loss are an important factor in the choice of treatment.[5] The arthroscopic Bankart repair and the Latarjet procedure are the 2 most commonly used techniques.[2,6] Soft-tissue repairs such as the Bankart procedure often fail in the presence of substantial bone loss (> 20% of the glenoid area), which is present in up to 67% of patients with recurrent shoulder instability.[7] In patients with severe glenoid bone loss, the Latarjet procedure seems to be the preferred treatment.[1,2,8] Currently, there are 2 commonly used and equivalent techniques for the Latarjet procedure: (1) the classic technique, with which the inferior surface of the coracoid is transferred to the anterior surface of the glenoid, and (2) the congruent-arc technique, with which the coracoid is rotated 90° and transferred with the medial side against the glenoid.[9,10]

The Latarjet procedure is known for its low rates of recurrent instability, even in high-intensity contact-sport athletes, but it can have severe complications in up to 30% of patients.[11-14] The recent literature contains claims of possible superiority of the Latarjet procedure relative to the Bankart repair.[14,15] However, although the split subscapularis tendon might provide dynamic stability by means of the sling effect by the coracobrachialis and short biceps tendon, the bone block of the coracoid within the subscapularis tendon also prevents normal function of the subscapular muscles, which are major shoulder muscles. Another possible long-term problem with the Latarjet procedure is resorption of the coracoid bone block while it is fixed by 2 titanium screws.[16] Complications, donor site problems, and the nonanatomic nature of this procedure have spurred research on other graft sources, such as iliac crest autograft, allograft, and synthetics.[17]

In this study, as part of the PRosPERoS (PRinting PERsonalized orthopaedic implantS) project group, the first author (K.W.) designed a 3-dimensional (3D)-printed titanium implant that could circumvent these potential issues. The implant is placed extracapsularly, flush with the bone, to fill in the exact defect and with the joint capsule acting as the articulating surface.

The primary aim of this study was to investigate, in a cadaveric model, if use of an anatomic-specific glenoid implant in a severe glenoid defect could restore glenohumeral morphology and stability. The secondary aim was to compare the anatomic implant and the classic Latarjet procedure with regard to the translational forces needed to dislocate the humerus 10 mm anteriorly on the glenoid after the operation.[9] Our hypothesis was that the anatomic implant would increase these translational forces relative to those after the creation of the glenoid bone defect and that the forces would be comparable with those in a normal shoulder and those after the classic Latarjet procedure.

Materials and methods

Thirteen fresh-frozen human shoulders were originally inspected for use in this study. Exclusion criteria were osseous defects (humeral and/or glenoid), rotator cuff tears, and moderate to severe osteoarthritis as demonstrated by direct inspection and computed tomography (CT). After exclusion, 10 shoulders (5 left and 5 right, and 5 from male donors and 5 from female donors) from 8 cadavers with a mean age at the time of death of 78 years (range, 71 to 86 years) were included.

All specimens were disarticulated at the scapulothoracic joint and transected at the humeral shaft, about 15 cm distal to the greater tubercle. The shoulder girdle was dissected, with the deltoid muscle removed and the rotator cuff muscles, conjoined tendon, and joint capsule left intact. The scapula was rigidly fixed in a self-centering vice that was secured on 4 linear railed platforms (TRS15VN; TBI Motion Technology) placed parallel to the glenoid's posterior-anterior axis and attached by pre-stretched rope (high-modulus polyethylene [HMPE]; Dyneema) to the crosshead of an LR5K universal testing machine equipped with an XLC 5kN load cell (Lloyd Instruments).

The proximal part of the humerus was rigidly fastened at its shaft with a custom-made fixture that allowed 30° of abduction and neutral rotation of the humerus in relation to the glenoid cavity. In this position, the osseous anatomy largely provides the stability, rather than the dynamic stabilizers and the capsuloligamentous structures.[18,19] The humeral fixture was attached to 4 vertically placed linear railed platforms and loaded with weights to allow a downward force of 50 N on the glenoid, ensuring that the humeral head found its original neutral anatomic position in the glenoid cavity.[18-20] This neutral position was defined as the starting position for each test. The glenoid platform moved posteriorly to cause anterior translation of the humerus at a set rate of 1.0 mm/sec for a total of 10 mm measured by calipers on the horizontal rail.[21,22] The loads were recorded with NEXYGEN data acquisition software (Lloyd Instruments) (Fig. 1).

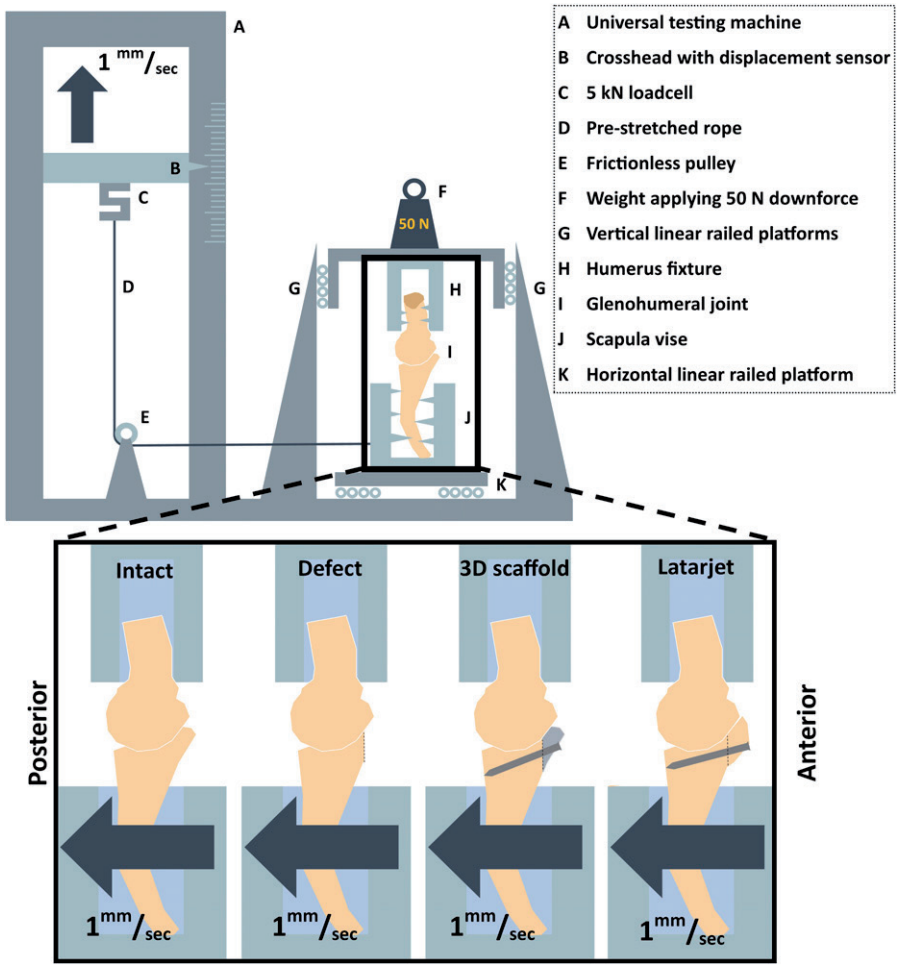

Fig. 1: Top Schematic overview of the components of the custom-designed testing device. **Bottom** (enlarged area) The different testing conditions.

At the start of the study, a CT-scan of the shoulder girdle was made. The images comprised the entire shoulder girdle and humerus with a slice thickness of 0.9 mm (250 mAs, 120 kV). The CT-scans were transferred to commercially available image processing software (Mimics Medical 20.0; Materialise), which was used to segment a pre-defect 3D-model of the osseous structures using standardized bone threshold values (≥ 226 Hounsfield units). After imaging, an anterior critical defect of 20% of the glenoid length was created as described by Yamamoto et al.[18,23,24] The anterior labrum was removed, and an osteotomy was made perpendicular to the joint surface using an anatomic-specific saw template (Fig. 2).

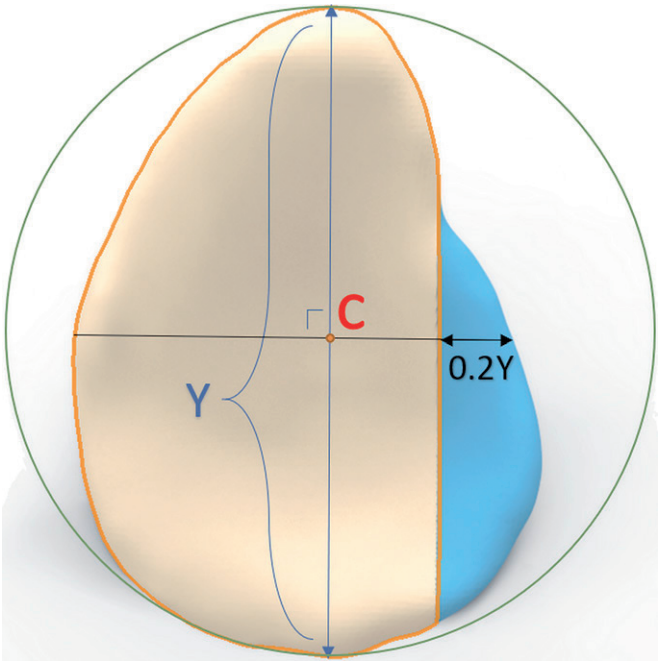

Fig. 2: Schematic representation of the simulated glenoid defect as described by Yamamoto et al.[18,24]
A circle was drawn around the pear-shaped glenoid. The y axis was drawn through the superior and inferior points. The x axis was drawn perpendicular to the y axis, through the center (C) of the glenoid circle. The osseous defect was created at the anterior side of the glenoid with a total width equal to 20% of the glenoid length (0.2Y).

As part of the PRosPERoS project, the defect-repairing titanium implants were designed by the first author (K.W.) using Geomagic Freeform Plus software (3D Systems). A simulation model of the glenoid defect was removed from the pre-defect model using CAD (computer-aided design) Boolean subtraction operatives, leaving the essential size of the implant. The created implant is therefore the size of the osteotomized glenoid rim and designed to be flush with the bone with the capsule as the overlying articulating surface. Additionally, 2 locking screws were added for angular stability, and their trajectories were digitally planned in the scaffold. The 3D printing was done with medical grade titanium (Ti-6Al-4V ELI [extra-low interstitial], grade 23) using an SLM (Selective Laser Melting) printer (ProX DMP 320; 3D Systems). Post-processing included polishing and screw wiretapping (Fig. 3). We tested 5 different conditions: (1) the "normal" situation, (2) after creation of an anterior glenoid bone defect, (3) after implantation of the 3D-printed titanium anatomic-specific implant (the "scaffold" condition), and after the classic Latarjet procedure (4) with and (5) without a 10-N load applied to the conjoined tendon by means of sutures to simulate the so-called sling effect (Fig. 4).[19] The specimens were tested in the situation with either the 3D implant first

(n = 5) or the Latarjet procedure first (n = 5), depending on the randomization. Every specimen was tested under all 5 conditions 5 times in 1 day. The specimens were sprayed with a 0.9% NaCl solution to prevent the quality of the soft tissue from deteriorating. A detailed description of the surgical technique is available in the Appendix (Supplementary Data 1).

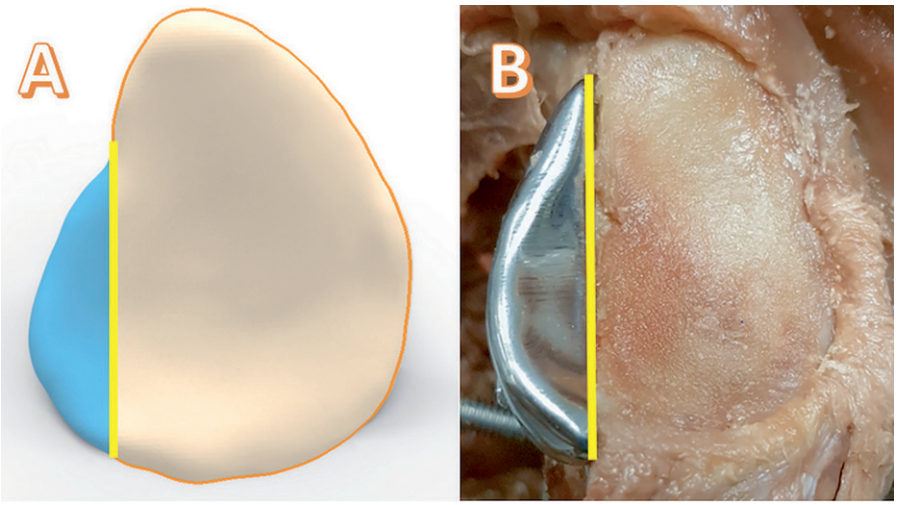

Fig. 3: (A) In silico simulation of the implant. The vertical line is the osteotomy or defect line. The implant is to the left of the osteotomy line, and the glenoid is to the right of the line. **(B)** A specimen with an implanted scaffold. The shoulder capsule was removed for visualization purposes.



Fig. 4: Left a 3D-printed sample used for optimizing the setup. **Right** a specimen that underwent a test cycle under condition 4: the Latarjet procedure with 10 N of pull on the conjoined tendon.

After stability testing, another CT scan was performed for 5 shoulders with the 3D-printed implant in situ and 5 shoulders after the Latarjet for evaluation of the geometry of the defect repair. The images were uploaded into Mimics Medical to compare the glenoid width (the widest anteroposterior diameter measured parallel to the superior-inferior axis) and the cavity depth (measured as described by Willemot et al.[25]) among the intact, defect, and post-reconstruction conditions.

Data analysis

A nonparametric Friedman test was performed to compare the mean peak translational forces needed to translate the humeral head 10 mm and the glenoid cavity width and depth among all of the different conditions. When a significant value was found, the related-samples Wilcoxon signed-rank test (SPSS, version 24; IBM) was used as a post-hoc analysis for the distinct research questions. The sample size was calculated on the basis of prior data.[22,26-28] A mean effect size of 30% and a standard deviation of 25% were chosen. A minimum of 8 samples was needed to show a significant difference in translational force with a power of 0.8 and an alpha of 0.05. Ten samples were included in this study.

Results

After dissection, all shoulder capsules and labra were found to be intact. During testing, no signs of damage to the specimens were observed. The mean superior-inferior glenoid diameter (and standard deviation [SD]) of the 10 specimens was 37.1 ± 3.9 mm as measured on CT-scans. Therefore, 7.4 ± 2.1 mm – or 20% of the superior-inferior glenoid diameter – was the desired average width of the glenoid defect. The actual created mean width of the glenoid defect was 7.4 ± 1.9 mm, equivalent to 19.9% of the glenoid diameter, which was not significantly different from the desired width (p = 0.80).

The glenoid width decreased significantly after creation of the bone defect in both the group that subsequently received the 3D-printed anatomic-specific scaffold (the "scaffold group") $p < 0.05$; n = 5) and the group that received the Latarjet procedure ($p < 0.05$; n = 5). The glenoid width increased to 100% and 96% of the normal width after restoration with the scaffold and Latarjet procedure, respectively. These widths did not differ significantly from the normal width in either the scaffold ($p = 0.50$) or Latarjet ($p = 0.14$) group (Fig. 5). The glenoid cavity depth decreased significantly after the creation of the bone defect in both the scaffold ($p < 0.05$) and the Latarjet ($p < 0.05$) group and increased to 118% of the normal depth after restoration with either procedure. This depth differed significantly from the normal depth in both the scaffold ($p = 0.05$) and the Latarjet ($p < 0.05$) group (Fig. 5).

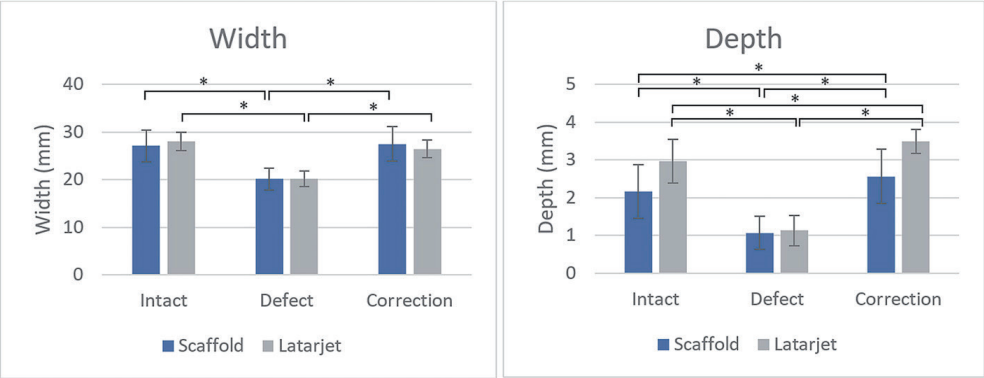

Fig. 5: The mean (and standard deviation [SD]) glenoid cavity width and depth (mm) in the normal, defect, and reconstructed (correction) conditions (scaffold or Latarjet procedure).
* A significant difference ($p \leq 0.05$).

Peak translational forces

The mean maximum peak force needed to translate the humeral head 10 mm anteriorly in the intact specimens was 48.6 ± 15.8 N, which decreased significantly (by 30% ± 6%) to 33.8 ± 10.1 N after creation of the bone defect ($p < 0.01$). The mean force in the defect condition significantly increased after reconstruction—to 56.0 ± 16.4 N ($p < 0.01$) in the scaffold group and to 55.0 ± 16.2 N ($p < 0.01$) in the Latarjet group. Also, the mean translational peak force was significantly higher after reconstruction with the scaffold compared with that in the normal situation ($p < 0.01$). No significant difference was found when the reconstructions with the scaffold and the Latarjet procedure were compared ($p = 0.72$) (Table 1). A box plot showing the peak forces, as percentages of the normal situation, under all of the different conditions is shown in Fig. 6.

Table 1: Results of related-samples Wilcoxon signed-rank test comparing various testing conditions*

	Z	*p* value*
Normal *vs* defect	-2.803†	< 0.01
Scaffold *vs* normal	-2.497‡	< 0.01
Scaffold *vs* defect	-2.803‡	< 0.01
Latarjet *vs* defect	-2.803‡	< 0.01
Latarjet *vs* scaffold	-0.357†	0.72
Latarjet *vs* Latarjet without sling	-2.666†	< 0.01

* The level of significance was $p < 0.05$. † Based on positive ranks. ‡ Based on negative ranks.

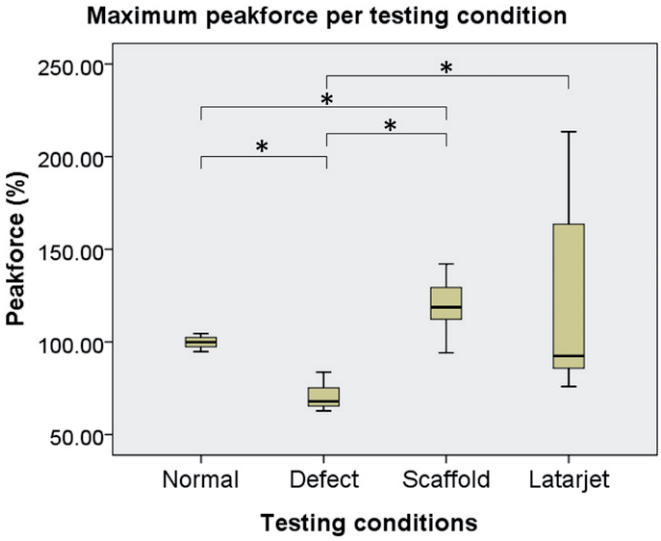

Fig. 6: Maximum peak force (%) needed to translate the humeral head 10 mm anteriorly with respect to the glenoid in the normal, defect, scaffold, and Latarjet conditions.
The humerus was in 30° of abduction and neutral rotation in all conditions. The normal healthy shoulder was used as the standard for the subsequent analyses. * A significant difference ($p < 0.05$). Horizontal line inside box = median, top and bottom of box = interquartile range, and top and bottom of whiskers = total range.

As an additional test, the translational forces were measured after the Latarjet procedure but without 10 N of load on the conjoined tendon. Under this condition, the force decreased by 21% ± 31%, compared with force in the Latarjet group with this load. This difference was significant ($p < 0.01$).

Discussion

The force necessary to translate the humeral head 10 mm anteriorly in the glenoid significantly decreased, to 70% ± 7% of normal, after the creation of the glenoid defect. After restoration of the original glenoid anatomy with an anatomic-specific 3D-printed scaffold, the translational forces increased to 119% ± 16% of the forces in the intact glenohumeral joint. This was not significantly different from the increase after the Latarjet procedure (to 121% ± 48% of normal). However, this does not imply that the 2 procedures are the same (Fig. 6).

In 1947, Moseley described a metallic rim that could be fixed to the neck of the scapula.[29] This implant, which contained holes for suturing of the capsule to the bone on the joint side of the prosthesis, was placed in an extracapsular position.[29] More recently, Diederichs et al. presented an in-silico method that compares the healthy contralateral

glenoid with the affected glenoid to simulate the optimal reconstruction of a glenoid rim defect.[30] However, the current study is the first to use biomechanical testing of 3D-printed anatomic-specific titanium implants for reconstruction of severe glenoid defects in the human shoulder.

Since the 3D-printed glenoid scaffold should recreate the intact glenoid exactly, it was expected that the mean translational peak force would be comparable between the 2 situations. However, several factors may have attributed to the greater forces measured after the scaffold reconstructions. First, although the bone cut used to create the glenoid defect was expected to be exactly parallel to the y-axis and perpendicular to the glenoid surface, if the implant was not positioned perfectly perpendicular to the joint surface (i.e., if it was at a slight angle) the glenoid cavity could have become too wide and too deep. Second, capsular interposition and capsular suturing contribute to the translational force, as shown by Yamamoto et al.[22] The capsule was envisioned to be as thick as the cartilage as the implant was placed and modeled to match the bone level. However, the thickness of the interpositioned capsule is difficult to predict as it is not visible on pre-defect CT. This might have affected the translational forces.

The secondary goal of this study was to compare the 3D-printed titanium implant with the classic Latarjet procedure, which is currently considered to be the standard for treating recurrent anterior glenohumeral instability when > 20% of the glenoid bone has been lost.[2,8] However, the Latarjet procedure is not anatomically precise and has a high rate of complications, including malpositioning, problems with the screw trajectory, loss of the range of motion, and eventually the development of arthrosis.[13] A patient-specific implant can be a solution for some of these problems, as all aspects of the reconstruction can be planned with the aid of 3D-design software. However, this study was not performed to show inferiority or superiority of 1 procedure over the other. More research is needed for comparison of the 2 techniques.

Both clinical and biomechanical studies have demonstrated the working mechanism of the Latarjet procedure.[15,19,22,26,27] The downside of the 3D-printed scaffold method might be the absence of a dynamic muscle stabilizer, which is created during the Latarjet procedure using the conjoined tendon.[22,27,31] In our study, the conjoined tendon contributed approximately 21% of the force needed to translate the humerus. However, the variability in the restoration of glenohumeral stability by the Latarjet procedure was relatively large (Fig. 6), whereas the titanium implant was more predictable (had less variability) in the restoration of glenohumeral stability.

Some limitations must be considered when interpreting our findings. We performed a biomechanical cadaver study, thus eliminating large dynamic stabilizers (i.e., muscles), which maybe 1 of the most important factors in shoulder instability. Also, the same specimens were used for both the Latarjet and the scaffold procedure, with the risk of

tissue elongation during testing. However, no significant differences were found between the shoulders in which the scaffold was implanted after the primary Latarjet procedure and those in which the procedures were done in the reverse order. In addition, it would have been preferable for us to have created the defect before the implants were designed. However, we made a cutting template to accurately create the glenoid defects, which were nearly the same as the planned defects, with widths of 7.4 ± 1.9 mm and 7.3 ± 2.1 mm, respectively. By designing the implants before the creation of the defects, we were always able to perform all procedures within 24 hours after defrosting the specimen, thereby preventing degradation of the tissues as much as possible. Another limitation of the 3D-printed implant is that no soft-tissue lesions such as labral injuries were directly targeted.

In conclusion, the purpose of our study was to determine whether use of a 3D-printed anatomic-specific titanium implant in a severe glenoid defect would increase the mean peak force needed to translate the humerus 10 mm anteriorly to levels comparable with those in the healthy normal situation. We found that the mean translational peak force after restoration with the anatomic-specific implant was significantly higher than that in the normal situation. No significant difference in results was identified between the 3D-printed anatomic-specific implant and the classic Latarjet procedure. Restoration of glenohumeral stability with the 3D-printed anatomic-specific implant is not the same as the normal situation, although it is very consistent and is comparable with that following the Latarjet procedure.

References

1. Dodson CC, Cordasco FA. Anterior glenohumeral joint dislocations. Orthop Clin North Am. 2008 Oct;39(4):507-18, vii.
2. Sofu H, Gu¨rsu S, Koc¸kara N, Oner A, Issın A, Camurcu Y. Recurrent anterior shoulder instability: review of the literature and current concepts. World J Clin Cases. 2014 Nov 16;2(11):676-82.
3. Leroux T, Wasserstein D, Veillette C, Khoshbin A, Henry P, Chahal J, Austin P, Mahomed N, Ogilvie-Harris D. Epidemiology of primary anterior shoulder dislocation requiring closed reduction in Ontario, Canada. Am J Sports Med. 2014 Feb;42(2): 442-50. Epub 2013 Nov 25.
4. Hovelius L, Saeboe M. Neer Award 2008: arthropathy after primary anterior shoulder dislocation—223 shoulders prospectively followed up for twenty-five years. J Shoulder Elbow Surg. 2009 May-Jun;18(3):339-47. Epub 2009 Feb 28.
5. Momaya AM, Tokish JM. Applying the glenoid track concept in the management of patients with anterior shoulder instability. Curr Rev Musculoskelet Med. 2017 Dec; 10(4):463-8.
6. Blonna D, Bellato E, Caranzano F, Assom M, Rossi R, Castoldi F. Arthroscopic Bankart repair versus open Bristow-Latarjet for shoulder instability: a matched-pair multicenter study focused on return to sport. Am J Sports Med. 2016 Dec;44(12): 3198-205. Epub 2016 Aug 8.
7. Pauzenberger L, Dyrna F, Obopilwe E, Heuberer PR, Arciero RA, Anderl W, Maz- zocca AD. Biomechanical evaluation of glenoid reconstruction with an implant-free J- bone graft for anterior glenoid bone loss. Am J Sports Med. 2017 Oct;45(12): 2849-57. Epub 2017 Aug 3.
8. Ramhamadany E, Modi CS. Current concepts in the management of recurrent anterior gleno-humeral joint instability with bone loss. World J Orthop. 2016 Jun 18; 7(6):343-54.
9. Montgomery SR, Katthagen JC, Mikula JD, Marchetti DC, Tahal DS, Dornan GJ, Dahl KD, Brady AW, Turnbull TL, Millett PJ. Anatomic and biomechanical comparison of the classic and congruent-arc techniques of the Latarjet procedure. Am J Sports Med. 2017 May;45(6):1252-60. Epub 2017 Feb 14.
10. Burkhart SS, De Beer JF, Barth JRH, Cresswell T, Roberts C, Richards DP. Results of modified Latarjet reconstruction in patients with anteroinferior instability and significant bone loss. Arthroscopy. 2007 Oct;23(10):1033-41.
11. Neyton L, Young A, Dawidziak B, Visona E, Hager JP, Fournier Y, Walch G. Surgical treatment of anterior instability in rugby union players: clinical and radiographic results of the Latarjet-Patte procedure with minimum 5-year follow-up. J Shoulder Elbow Surg. 2012 Dec;21(12):1721-7. Epub 2012 May 5.
12. Latarjet M. [Treatment of recurrent dislocation of the shoulder]. Lyon Chir. 1954 Nov-Dec;49(8):994-7. French.
13. Griesser MJ, Harris JD, McCoy BW, Hussain WM, Jones MH, Bishop JY, Miniaci A. Complications and re-operations after Bristow-Latarjet shoulder stabilization: a systematic review. J Shoulder Elbow Surg. 2013 Feb;22(2):286-92.
14. Longo U, Loppini M, Rizzello G, Ciuffreda M, Maffulli N, Denaro V. Latarjet, Bristow, and Eden-Hybinette procedures for anterior shoulder dislocation: system- atic review and quantitative synthesis of the literature. Arthroscopy. 2014;30(9): 1184-211.
15. An VVG, Sivakumar BS, Phan K, Trantalis J. A systematic review and meta- analysis of clinical and patient-reported outcomes following two procedures for recurrent traumatic anterior instability of the shoulder: Latarjet procedure vs. Bankart repair. J Shoulder Elbow Surg. 2016 May;25(5):853-63. Epub 2016 Jan 19.

16. Di Giacomo G, Costantini A, de Gasperis N, De Vita A, Lin BKH, Francone M, Rojas Beccaglia MA, Mastantuono M. Coracoid graft osteolysis after the Latarjet procedure for anteroinferior shoulder instability: a computed tomography scan study of twenty-six patients. J Shoulder Elbow Surg. 2011 Sep;20(6):989-95. Epub 2011 Mar 9.
17. Willemot LB, Elhassan BT, Verborgt O. Bony reconstruction of the anterior gle- noid rim. J Am Acad Orthop Surg. 2018 May 15;26(10):e207-18.
18. Yamamoto N, Itoi E, Abe H, Kikuchi K, Seki N, Minagawa H, Tuoheti Y. Effect of an anterior glenoid defect on anterior shoulder stability: a cadaveric study. Am J Sports Med. 2009 May;37(5):949-54. Epub 2009 Mar 4.
19. Wellmann M, Petersen W, Zantop T, Herbort M, Kobbe P, Raschke MJ, Hurschler C. Open shoulder repair of osseous glenoid defects: biomechanical effectiveness of the Latarjet procedure versus a contoured structural bone graft. Am J Sports Med. 2009 Jan;37(1):87-94. Epub 2008 Dec 4.
20. Itoi E, Lee SB, Berglund LJ, Berge LL, An KN. The effect of a glenoid defect on anteroinferior stability of the shoulder after Bankart repair: a cadaveric study. J Bone Joint Surg Am. 2000 Jan;82(1):35-46.
21. Itoi E, Yamamoto N, Kurokawa D, Sano H. Bone loss in anterior instability. Curr Rev Musculoskelet Med. 2013 Mar;6(1):88-94.
22. Yamamoto N, Muraki T, An KN, Sperling JW, Cofield RH, Itoi E, Walch G, Steinmann SP. The stabilizing mechanism of the Latarjet procedure: a cadaveric study. J Bone Joint Surg Am. 2013 Aug 7;95(15):1390-7.
23. Saito H, Itoi E, Sugaya H, Minagawa H, Yamamoto N, Tuoheti Y. Location of the glenoid defect in shoulders with recurrent anterior dislocation. Am J Sports Med. 2005 Jun;33(6):889-93. Epub 2005 Apr 12.
24. Yamamoto N, Itoi E. Osseous defects seen in patients with anterior shoulder instability. Clin Orthop Surg. 2015;7(4):425-9.
25. Willemot LB, Akbari-Shandiz M, Sanchez-Sotelo J, Zhao K, Verborgt O. Resto- ration of articular geometry using current graft options for large glenoid bone defects in anterior shoulder instability. Arthroscopy. 2017 Sep;33(9):1661-9. Epub 2017 Jun 15.
26. Patel RM, Walia P, Gottschalk L, Kuklis M, Jones MH, Fening SD, Miniaci A. The effects of Latarjet reconstruction on glenohumeral kinematics in the presence of combined bony defects: a cadaveric model. Am J Sports Med. 2016 Jul;44(7): 1818-24. Epub 2016 Apr 15.
27. Barrett Payne W, Kleiner MT, McGarry MH, Tibone JE, Lee TQ. Biomechanical comparison of the Latarjet procedure with and without a coracoid bone block. Knee Surg Sports Traumatol Arthrosc. 2016 Feb;24(2):513-20. Epub 2015 Dec 12.
28. Kephart CJ, Abdulian MH, McGarry MH, Tibone JE, Lee TQ. Biomechanical analysis of the modified Bristow procedure for anterior shoulder instability: is the bone block necessary? J Shoulder Elbow Surg. 2014 Dec;23(12):1792-9. Epub 2014 Jun 9.
29. Moseley HF. The use of a metallic glenoid rim in recurrent dislocation of the shoulder. Can Med Assoc J. 1947 Mar;56(3):320.
30. Diederichs G, Seim H, Meyer H, Issever AS, Link TM, Schro¨der RJ, Scheibel M. CT-based patient-specific modeling of glenoid rim defects: a feasibility study. AJR Am J Roentgenol. 2008 Nov;191(5):1406-11.
31. Giles JW, Boons HW, Elkinson I, Faber KJ, Ferreira LM, Johnson JA, Athwal GS. Does the dynamic sling effect of the Latarjet procedure improve shoulder stability? A biomechanical evaluation. J Shoulder Elbow Surg. 2013 Jun;22(6):821-7. Epub 2012 Sep 28.

APPENDIX

Supplementary Data 1

Test set-up

Triangular rigid fixation plates were screwed on the subscapular and infraspinous fossa of the scapula and fixed with a self-centring vice. The vice was secured on four linear railed platforms (TRS15VN, TBI Motion Technology, Taipei, Taiwan) placed parallel to the glenoid's posterioranterior axis and attached by pre-stretched rope (Dyneema HMPE) to the crosshead of a LR5K universal testing machine (Lloyd Instruments Ltd, Segensworth Fareham, England) equipped with a XLC 5KN loadcell (Lloyd Instruments Ltd, Segensworth Fareham, England) exceeding the requirement of EN ISO 7500-1 class 0.5. A frictionless pulley was used to transfer the crosshead motion in the vertical, load axis to the horizontal, posterior-anterior axis of the glenoid. The proximal humerus was rigidly fastened at its shaft with a tailor-made fixture that allowed precise placement of the humeral head in the glenoid cavity. The humeral fixture was attached to four vertically placed linear railed platforms and loaded with weights to allow a downforce of 50N[1–3] on the glenoid ensuring that the humeral head finds it original neutral anatomical position in the glenoid cavity. This neutral position was defined as the starting position for each test. During the mechanical test, a preload of 1N was applied, before the crosshead moved posteriorly to cause anterior translation of the humerus at a set rate of 1.0 mm/sec for a total of 10 mm.[4,5] The load and displacement were recorded with NEXYGEN data acquisition software (Lloyd Instruments Ltd, Segensworth Fareham, England). Afterwards the maximum translational peak force for each test was determined.

Supplementary data 2

Surgical method

One author and orthopedic surgeon (TB), with more than 5 years' shoulder surgery experience performed all the procedures. First, the dissected specimens were tested in the normal condition to evaluate the translational peak force in the anatomic situation. After this, the shoulders were made unstable by creating the anterior bone defect. To make such an anterior glenoid osteotomy, the subscapularis tendon was incised vertically, approximately 1.0 to 1.5 cm medial to its insertion, leaving the inferior part intact. The capsule was incised vertically on the lateral side. A blunt dissection of the capsule was made from the subscapularis tendon, after which a L-shaped capsular opening was made, raising one big superomedial capsular flap. By doing this, good visualization of the shoulder joint was reached with the intact labrum and biceps anchor on the

superior side of the glenoid. The glenoid bone defect was created perpendicular to the joint surface with a patient specific cutting template. Before testing every condition the arthrotomy (capsular flap and subscapularis tenotomy) was restored by means of single knotted vicryl stitches, followed by testing measurements of the situation.

To restore the original anatomy with the patient specific implant, the implant was fixated extraarticularly on top of the capsular flap on the anterior aspect of the glenoid defect by means of two locking screws (36 mm, ø 3.5 mm, DePuy Synthes). To enhance the glenohumeral stability with the classic Latarjet procedure, the inferior surface of the coracoid was fixed to the anterior surface of the glenoid as described by Montgomery et al.[6] The Latarjet procedure was performed by means of cannulated partially threated screws (ø 3.75), drill guide and wedge profile plates from a Latarjet set (Arthrex, Naples, USA).

References

1. Yamamoto N, Itoi E, Abe H, Kikuchi K, Seki N, Minagawa H, et al. Effect of an Anterior Glenoid Defect on Anterior Shoulder Stability: A Cadaveric Study. Am J Sports Med. 2009;37(5):949–54.
2. Wellmann M, Petersen W, Zantop T, Herbort M, Kobbe P, Raschke MJ, et al. Open Shoulder Repair of Osseous Glenoid Defects. Am J Sports Med. 2009;37(1):87–94.
3. Itoi E, Lee SB, Berglund LJ, Berge LL, An KN. The Effect of a Glenoid Defect on Anteroinferior Stability of the Shoulder After Bankart Repair: A Cadaveric Study. J Bone Jt Surg Am. 2000;82(1):35–46.
4. Itoi E, Yamamoto N, Kurokawa D, Sano H. Bone loss in anterior instability. Curr Rev Musculoskelet Med. 2013 Mar;6(1):88–94.
5. Yamamoto N, Muraki T, An KN, Sperling JW, Cofield RH, Itoi E, et al. The stabilizing mechanism of the latarjet procedure: A cadaveric study. J Bone Jt Surg - Ser A. 2013 Aug;95(15):1390–7.
6. Montgomery SR, Katthagen JC, Mikula JD, Marchetti DC, Tahal DS, Dornan GJ, et al. Anatomic and Biomechanical Comparison of the Classic and Congruent-Arc Techniques of the Latarjet Procedure. Am J Sports Med. 2017 May;45(6):1252–60.

8

Chapter 8

Summary, general discussion and future perspectives

Summary

In this thesis we performed an anatomical evaluation of one of the major passive constraints for shoulder instability, being the labrum and its phylogenetic counterpart at the hip joint. An evaluation of patient outcome measurement scores including a discussion on the Oxford Shoulder Score and the Oxford Shoulder Instability Score has been made (**Appendix Chapter 3**). An evaluation of management of acute first-time anterior shoulder dislocations in the Netherlands by means of a shoulder questionnaire (including treatment of recurrent shoulder instability) is being presented. A detailed clinical and radiological evaluation of the mid- and long term results after a labrum joint capsule (open Bankart) repair is given. And finally, we evaluated a novel technique addressing bony defects of the glenoid.

Chapter 2 mentions evolutionary changes of the shoulder, resulting from the fact that people have evolved to walk upright (e.g. Homo erectus, Homo neanderthalensis, Homo sapiens). One of the advantages of this bipedalism is having free hands, accompanied by new requirements for the shoulder as increased function & mobility. The similarities and differences of the labrum of shoulder (with its well-known Bankart lesion, being highly associated with shoulder instability) and hip joint are analysed with special attention to anatomy, pathology (labrum lesions, feeling of instability and degenerative abnormalities such as osteoarthritis) and therapeutic treatment options.

Chapter 3 evaluates the Dutch translation of the "Oxford Shoulder Score" (OSS), an internationally widely used patient-reported-outcome-measurement (PROM's) for shoulder pathology, including a discussion on the Oxford Shoulder Score and Oxford Shoulder Instability Score (addendum). The OSS-questionnaire assesses the pain and activity level of the affected shoulder in daily life (33% and 66% respectively). Originally, the score was used to assess 111 patients who had undergone shoulder surgery due to chronic shoulder complaints, excluding operations for instability. Later on, the OSS was tested in patients after rotator cuff surgery (surgery for a tear in one or more tendons of the four muscles around the shoulder) and in patients with a frozen shoulder (stiff shoulder capsule) which were being mobilized under general anesthesia. Our study indicates that after translation in Dutch, the measuring instrument proved valid and understandable, comparing with existing clinically validated shoulder questionnaires (namely: the Dutch simple shoulder test and Constant-Murley score) and the generic PROM SF-36 (Short Form 36 Health survey) for shoulder patients at the Reinier de Graaf Gasthuis (Delft, the Netherlands).

Chapter 4 evaluates how orthopaedic surgeons in the Netherlands treat an acute first-time anterior shoulder dislocation (AFASD). Secondly, it evaluates whether this is done according to the (then applicable) CBO-guideline. The effect of the introduction of the national (CBO and Dutch Orthopaedic Association (NOV)) guideline "Acute primary

shoulder luxations" in 2005 on general practice is also evaluated. Finally, orthopaedic surgeons were asked how to treat persistent (traumatic) anterior shoulder instability. The outcome of AFASD treatment was different, but surgical treatment options for recurrent instability after AFASD showed even more remarkable variations. The vast majority (93%) used an arthroscopic surgical technique for shoulder instability, the rest an "open" surgical technique. When an open stabilizing operation was carried out, the open (modified) Bankart repair was the most commonly used technique (54%). The Putti-Platt operation was being applied in 16% of the cases as well as the Latarjet procedure. A survey in 2003, prior to the introduction of the before mentioned CBO guideline "acute primary shoulder Luxations" (2005), showed that 65% of the assessed Dutch hospitals had a personalized hospital protocol for the treatment of shoulder luxations (response rate 73%, from 74 Dutch hospitals). The outcome of our study showed that after the introduction of the CBO-guideline, there was only a limited increase of 10% in hospital protocols for the treatment of shoulder luxations (75%). Only 29% of the respondents indicated that their existing hospital protocol had been adapted to reflect the newly introduced guideline.

Chapter 5 describes the mid-term clinical and radiological results in terms of stability and the incidence of glenohumeral osteoarthritis of a cohort of 31 patients undergoing modified open Bankart surgery with an average follow-up of 11 years (range 10–15 years) indicated for reasons of post traumatic shoulder instability. We report our surgical technique including the most important steps during this operation procedure. 26 patients (84%) indicated to have a good to very good end result. The recurrence rate varied between 7% and 10% depending on the definition of "recurrent luxation". In 2 patients a redislocation occurred due to a new adequate trauma 1 and 9 years after surgery. The recurrent instability risk (= subluxation sensation and/or dislocations) ranged between 13% and 23%. 32% of the shoulders showed signs of osteoarthritis at time of follow-up, of which 3% were Samilson-Prieto grade 3. The average Rowe score was 90 points (range 66–98) and Constant score 96 points (range 85–100). There were no other complications, such as wound infections.

In **Chapter 6**, the long-term clinical and radiological results in terms of stability and the incidence of glenohumeral osteoarthritis of a cohort of 39 patients undergoing modified open Bankart surgery with an average follow-up of 21 years (range 16–26 years) indicated for reasons of post traumatic shoulder instability is being described. Both studies (Chapter 5 & 6) show that the recurrence rate after an open modified Bankart procedure is low, being 10% at final follow-up. The recurrent instability risk (= subluxation sensation and/or dislocations) 23%. Twenty shoulders (51%) had radiological signs of osteoarthritis at time of final follow-up, of which 10% samilson-prieto grade 2 and 3% samilson-prieto grade 3. The average Rowe score was 85 points (range 25–100) and Constant score 92 points (range 70–100).

Chapter 7 evaluates whether a glenoid defect is to be augmented with a 3D printed scaffold. In A biomechanical cadaver study, several situations were simulated to test the stability of the shoulder. In ten fresh-frozen cadaver shoulders a defect was made in the glenoid, after which a 3D patient specific titanium implant (scaffold) was placed. All shoulders were being scanned before and after the procedure according to 3D CT-protocol (250mAs, 120kV, 0.9 mm coupes). After this, an imaging software package (Mimics Medical 20.0, Materialise, Leuven, Belgium) printed a 3D patient-specific titanium implant (SLM-Titanium printer, ProX DMP320, 3D Systems, Leuven, Belgium) for which a Freeform Plus software package (Geomagic, 3D Systems, Leuven, Belgium) was used. Fixation of the scaffold was being performed by means of two angle stable screws, of which also the screw hole position was optimized using the Freeform Plus software package. Our 3D implants are made of "medical" titanium (Ti6Al4v ELI grade 23). The peak translational force needed to translate the humeral head 10mm anteriorly was measured with a custom-designed shoulder testing device under 5 different conditions, being: (1) the "normal" intact situation, (2) after creation of a controlled anterior bone glenoid defect, (3) after implantation of our 3D Titanium patient specific implant, (4) after a Latarjet procedure with and (5) without 10N attached to mimic the sling effect of the conjoined tendon. The peak translational force needed to translate the humeral head 10mm anteriorly was reduced to 70% after creation of the glenoid bony defect compared to the "normal" intact glenoid. Both the augmentation with a 3D patient specific implant and the classic Latarjet procedure were adequate surgical techniques in restoring the glenohumeral stability in the presence of a bony glenoid defect. The peak translational force needed to translate the humeral head 10mm anteriorly was being restored to 119% ± 16% ($p < 0.01$) and 121% ± 48% ($p = 0.02$), respectively compared to the "normal" intact glenoid situation.

General discussion

The shoulder is the most common joint being prone for developing recurrent instability.[1–5] A traumatic shoulder dislocation is often accompanied by a labral lesion,[6–11] which predisposes the patient to developing chronic shoulder instability.[12–15]

Despite a great diversity in surgical treatment options for the unstable shoulder, there is still no unambiguous policy and the most optimal treatment remains controversial, including conservative management and what and when to do when operative treatment is to be done. This is due, among other things, to the wide variety of possible causes of shoulder instability (varying from functional, proprioceptive problems to anatomical abnormalities that may accompany it). Reasons supporting immediate stabilization over conservative treatment are: there is an unacceptable high risk of recurrence in the young athletic population; recurrent instability causes significant and progressive soft tissue

and bony damage and there is a clear improvement in the quality of life conferred by surgery.[16,17]

In the Netherlands, the arthroscopic Bankart procedure is currently the most performed surgery executed in patients with symptoms of posttraumatic shoulder instability.[18] The open Bankart operation, which was initially described by Bankart in 1923, currently seems to be performed to a lesser extent.[15] However, clear evidence that the arthroscopic version is better than the open surgical procedure, is not obvious.[19–24] The open Bankart operation is even likely to have a better outcome (with less new (sub) luxations) particular in the young (< 25 years) and active (high-demanding) patient who participates in contact or racket sport; physically demanding professions or in patients with bone loss of the glenoid (< 20%) or in patients with clinical signs of having hyperlaxity.[20,25,26] One of the considerable explanations could be the potential re-increase in anterior capsular volume or restretching trait of the anterior capsule over time, even after primary successful arthroscopic Bankart repair and/or capsular shift procedures.[24] In earlier studies, women, elite athletes, and those with frequent dislocations were at highest risk of capsular restretching. An increase in capsular volume was related to positive apprehension and redislocation as well with a lower outcome of the Rowe shoulder score (also known as rating sheet for Bankart repair).[24] These findings possibly correlate with the superior outcome of the open (modified) Bankart repair. This latter open Bankart approach allows surgeons to directly visualize the glenohumeral joint, accomplish a large capsular shift and guarantee a more complete repair of the anteroinferior capsulolabral tissue ending in diminution of elasticity of the anterior shoulder capsule due to conversion in less elastic scar tissue.[22]

Nowadays, identification of bone loss is increasingly emphasized in the optimal treatment of shoulder instability, both before, but even more after a failed initial stabilizing shoulder procedure.[27–32] This is probably partly due to the reports of Zimmerman in 2016 where he documented substantial superiority of the Latarjet procedure and a decreasing effectiveness of the arthroscopic performed Bankart repair over time.[33] Anteroinferior glenoid bone deficiency (even without consideration of presence of humeral bone loss) has been reported in 22% of initial traumatic anterior shoulder dislocations and in up to 90% of recurrent anteroinferior shoulder instability cases.[28,29] This is one of the reasons that some orthopaedic surgeons recommend surgical treatment after a first traumatic anterior shoulder luxation in the young active (male) patient.[16] Among other things because of this, more attention is being placed on bone block stabilization procedures, including even those performed arthroscopically as a definitive treatment for posttraumatic shoulder instability. In the Netherlands, the open Latarjet procedure seems to be the preferred treatment in the presence of glenoid bone loss of > 20%, or in revision casus.[18,34] Because soft-tissue repairs often fail in the presence of significant bone loss or when a deficient capsulabral situation is residual

as is often seen after primary surgery.[20,35] Other known bone block augmentational reconstructions include procedures described by Eden (1918), Hybbinette (1917 & 1932) and Bristow and other allografting techniques using (part of) iliac crest bone, femoral head or distal tibia.[36–41] However, one should be aware of the marked increase in complication rate for these bone block procedures over soft tissue arthroscopic surgery but also compared with the open Bankart procedure.[42–44] In this context we evaluated a potential novel treatment technique using a 3D printed scaffold for augmentation to the glenoid bony defect.[45] Usage of such a metallic rim device has been described only once in a preliminary case report in 1947. The surgeon implanted the scaffold anteroinferior to the glenoid in an extra-articular position, identical to our biomechanical cadaver set-up.[46] At that time, the scaffold was being introduced because of the potential technical difficulties to reattach the capsule and/or torn labrum by means of performing three or more drill holes adequately through the (sometimes dysplastic) bony rim of the glenoid.

Future perspectives

Shoulder instability needs a clear definition, which is internationally being accepted. Only then it is possible to carry out comparative (inter-) national studies on interventions (both conservative and operatively). In the presence of a large osseous defect, the patient experiences almost always instability problems of their shoulder. In these situations, provision of a stabilizing shoulder operation in a narrower sense is necessary. In cases with bone loss of more than 20%, a Latarjet operation is commonly being performed. This procedure not only has a high complication rate but also compromises the function of one of the prime movers of the shoulder, the musculus subscapularis. The use of 3D printing techniques in any case does not compromise to this extent the important subscapularis muscle. But "no surgical innovation without evaluation". The development of a new surgical technique should ideally pass through different stages. These stages are described by McCulloch, in its so-called IDEAL-model.[47] (IDEAL Consortium, Lancet see Fig. 1) This model provides a number of easy to implement recommendations for the assessment and implementation of new surgical procedures. After that, the IDEAL-D-model was introduced to evaluate and regulate the use of medical devices and implants in an implant register (e.g. the LROI, www.LROI.nl).[48]

Previously, we have seen that the implementation of guidelines, but also new surgical insights, can be complex, as demonstrated, for example, by the implementation of a new guideline concerning blood management around hip and knee arthroplastics.[49] In development stage 1, also known as the preclinical stage, ex-vitro proof is being provided that safety and reliability is ensured, as in our cadaver study (Chapter 7). At this stage, the surgeon must prove that the concept works (= Proof of concept) and only a few orthopaedic surgeons are involved. In Stage 2a, the new procedure is further developed

	1 Idea	2a Development	2b Exploration	3 Assessment	4 Long-term study
Purpose	Proof of concept	Development	Learning	Assessment	Surveillance
Number and types of patients	Single digit; highly selected	Few; selected	Many; may expand to mixed; broadening indication	Many; expanded indications (well defined)	All eligible
Number and types of surgeons	Very few; innovators	Few; innovators and some early adopters	Many; innovators, early adopters, early majority	Many; early majority	All eligible
Output	Description	Description	Measurement; comparison	Comparison; complete information for non-RCT participants	Description; audit, regional variation; quality assurance; risk adjustment
Intervention	Evolving; procedure inception	Evolving; procedure development	Evolving; procedure refinement; community learning	Stable	Stable
Method	Structured case reports	Prospective development studies	Research database; explanatory or feasibility RCT (efficacy trial); diseased based (diagnostic)	RCT with or without additions/modifications; alternative designs	Registry; routine database (eg, SCOAP, STS, NSQIP); rare case reports
Outcomes	Proof of concept; technical achievement; disasters; dramatic successes	Mainly safety; technical and procedural success	Safety; clinical outcomes (specific and graded); short-term outcomes; patient-centred (reported) outcomes; feasibility outcomes	Clinical outcomes (specific and graded); middle-term and long-term outcomes; patient-centred (reported) outcomes; cost-effectiveness	Rare events; long-term outcomes; quality assurance
Ethical approval	Sometimes	Yes	Yes	Yes	No
Examples	NOTES video	Tissue engineered vessels	Italian D2 gastrectomy study	Swedish obese patients study	UK national adult cardiac surgical database

Fig. 1: IDEAL model including different stages of surgical innovation.
Abbreviations: RCT, randomised controlled trial; SCOAP, Surgical Clinical Outcomes Assessment Programme; STS, Society of Thoracic Surgeons; NSQIP, National Surgical Quality Improvement Program; NOTES, natural orifice transluminal endoscopic surgery.

due to the need for a new solution to a clinical problem (here: shoulder instability with > 20% bone loss). The results must be described in detail. Stage 2b is the exploration and learning phase, in which the surgical procedure is being applied to a larger group of patients to gain experience with the first use and to refine the precise technique or implant. Stage 3 is the assessment phase. At this stage, the aim is to assess the effectiveness of the procedure compared to other procedures. Stage 4 is the last phase, after which the procedure can be used world-wide. The results should be monitored in the long term: does the implant still remains properly fixed in the bone defect? For this late evaluation, micromotion measurements are being needed between implant and bone (such as with RSA or CT) to predict late complications such as implant detachment.[50,51]

In my opinion, 3D printing can be a promising new technology with the potential of offering additional possibilities for orthopaedic surgeons, such as presented in our latest study (Chapter 7) for patients with instability problems of their shoulder due to bone loss. However, to make this specific implant a success, in the end, the titanium implant ideally needs to be replaced by a bioscaffold, in which bone cells can grow. After which incorporation of the implant into the native glenoid bone is possible. This means that the implant is not printed out of titanium, but from material which can be converted into bone by the body itself, such as calcium phosphate. On the other hand, the nanostructure properties of metal are more optimal in strength and stability than those of resorbable bioscaffolds. Ultimately, evaluation is required according to the IDEAL principle: Idea → Development → Exploration → Assessment → Long-term follow-up.[47,52,53] Only with this methodology, a meaningful improvement of quality of patient care can be created.

References

1. Hoelen MA, Burgers AMJ, Rozing PM. Prognosis of primary anterior shoulder dislocation inyoung adults. Arch Orthop Trauma Surg. 1990;110(1):51-54. doi:10.1007/BF00431367
2. Milgrom C, Mann G, Finestone A. A prevalence study of recurrent shoulder dislocations inyoung adults. J shoulder Elb Surg. 7(6):621-624. http://www.ncbi.nlm.nih.gov/pubmed/9883424. Accessed November 10, 2017.
3. Simonet WT, Melton LJ, Cofield RH, Ilstrup DM. Incidence of anterior shoulder dislocation in Olmsted County, Minnesota. Clin Orthop Relat Res. 1984;(186):186-191. http://www.ncbi.nlm.nih.gov/pubmed/6723141. Accessed June 8, 2019.
4. Zacchilli MA, Owens BD. Epidemiology of Shoulder Dislocations Presenting to Emergency Departments in the United States. J Bone Jt Surgery-American Vol. 2010;92(3):542-549.doi:10.2106/JBJS.I.00450
5. Veeger HEJ, van der Helm FCT. Shoulder function: The perfect compromise between mobility and stability. J Biomech. 2007;40(10):2119-2129. doi:10.1016/J.JBIOMECH.2006.10.016
6. Fabbriciani C, Milano G, Demontis A, Fadda S, Ziranu F, Mulas PD. Arthroscopic versus open treatment of Bankart lesion of the shoulder: A prospective randomized study. Arthrosc J Arthrosc Relat Surg. 2004;20(5):456-462. doi:10.1016/j.arthro.2004.03.001
7. Jakobsen BW, Johannsen HV, Suder P, Søjbjerg JO. Primary Repair Versus ConservativeTreatment of First-Time Traumatic Anterior Dislocation of the Shoulder: A Randomized Study With 10-Year Follow-up. Arthrosc J Arthrosc Relat Surg. 2007;23(2):118-123. doi:10.1016/j.arthro.2006.11.004
8. Kirkley A, Griffin S, Richards C, Miniaci A, Mohtadi N. Prospective Randomized Clinical Trial Comparing the Effectiveness of Immediate Arthroscopic Stabilization Versus Immobilization and Rehabilitation in First Traumatic Anterior Dislocations of the Shoulder. Arthrosc J Arthrosc Relat Surg. 1999;15(5):507-514. doi:10.1053/ar.1999.v15.015050
9. Netto NA, Tamaoki MJS, Lenza M, et al. Treatment of Bankart Lesions in Traumatic Anterior Instability of the Shoulder: A Randomized Controlled Trial Comparing Arthroscopy and Open Techniques. Arthrosc J Arthrosc Relat Surg. 2012;28(7):900-908. doi:10.1016/j.arthro.2011.11.032
10. Robinson CM, Jenkins PJ, White TO, Ker A, Will E. Primary Arthroscopic Stabilization for a First-Time Anterior Dislocation of the Shoulder. J Bone Jt Surgery-American Vol. 2008;90(4):708-721. doi:10.2106/JBJS.G.00679
11. Wintzell G, Haglund-Åkerlind Y, Ekelund A, Sandström B, Hovelius L, Larsson S. Arthroscopic lavage reduced the recurrence rate following primary anterior shoulder dislocation. Knee Surgery, Sport Traumatol Arthrosc. 1999;7(3):192-196. doi:10.1007/s001670050146
12. Bankart AS. The pathology and treatment of recurrent dislocation of the shoulder joint. Br J Surg.1938;26.
13. Bankart AS, Cantab MC. Recurrent or habitual dislocation of the shoulder-joint. 1923. Clin Orthop Relat Res. 1993;(291):3-6.
14. Rowe CR. Prognosis in dislocations of the shoulder. J Bone Jt Surg Am. 1956;38-A(5):957-977.
15. Rowe CR, Patel D, Southmayd WW. The Bankart procedure: a long-term end-result study. J Bone Jt Surg Am. 1978;60(1):1-16.
16. Avila Lafuente JL, Moros Marco S, García Pequerul JM. Controversies in the Management of the First Time Shoulder Dislocation. Open Orthop J. 2017;11(1):1001-1010. doi:10.2174/1874325001711011001
17. Baumgarten KM, Wright RW. Ease of tying arthroscopic knots. J Shoulder Elb Surg.2007;16(4):438-442. doi:10.1016/j.jse.2006.10.013

18. Berendes TD, Pilot P, Nagels J, Vochteloo AJH, Nelissen RGHH. Survey on the management of acute first-time anterior shoulder dislocation amongst Dutch public hospitals. Arch Orthop Trauma Surg. 2015;135(4). doi:10.1007/s00402-015-2156-3
19. Sanborn L, Arciero RA, Yang JS. Don't forget the open Bankart—Look at the evidence. Ann Jt.2017;2(11). http://aoj.amegroups.com/article/view/3888/4528. Accessed February 21, 2019.
20. Boileau P, Villalba M, Héry J-Y, Balg F, Ahrens P, Neyton L. Risk factors for recurrence of shoulder instability after arthroscopic Bankart repair. J Bone Joint Surg Am. 2006;88(8):1755-1763. doi:10.2106/JBJS.E.00817
21. Kim S-H, Ha K-I, Cho Y-B, Ryu B-D, Oh I. Arthroscopic anterior stabilization of the shoulder: two to six-year follow-up. J Bone Joint Surg Am. 2003;85-A(8):1511-1518. http://www.ncbi.nlm.nih.gov/pubmed/12925631. Accessed February 21, 2019.
22. Chen L, Xu Z, Peng J, Xing F, Wang H, Xiang Z. Effectiveness and safety of arthroscopic versus open Bankart repair for recurrent anterior shoulder dislocation: a meta-analysis of clinical trial data. Arch Orthop Trauma Surg. 2015;135(4):529-538. doi:10.1007/s00402-015-2175-0
23. Lenters TR, Franta AK, Wolf FM, Leopold SS, Matsen FA. Arthroscopic compared with open repairs for recurrent anterior shoulder instability. A systematic review and meta-analysis of the literature. J Bone Joint Surg Am. 2007;89(2):244-254. doi:10.2106/JBJS.E.01139
24. Park J-Y, Chung SW, Kumar G, et al. Factors affecting capsular volume changes and association with outcomes after Bankart repair and capsular shift. Am J Sports Med. 2015;43(2):428-438. doi:10.1177/0363546514559825
25. Voos JE, Livermore RW, Feeley BT, et al. Prospective evaluation of arthroscopic bankart repairs for anterior instability. Am J Sports Med. 2010;38(2):302-307. doi:10.1177/0363546509348049
26. Rhee YG, Ha JH, Cho NS. Anterior Shoulder Stabilization in Collision Athletes. Am J Sports Med.2006;34(6):979-985. doi:10.1177/0363546505283267
27. McNeil JW, Beaulieu-Jones BR, Bernhardson AS, et al. Classification and Analysis of Attritional Glenoid Bone Loss in Recurrent Anterior Shoulder Instability. Am J Sports Med.2017;45(4):767-774. doi:10.1177/0363546516677736
28. Provencher MT, Bhatia S, Ghodadra NS, et al. Recurrent shoulder instability: current concepts for evaluation and management of glenoid bone loss. J Bone Joint Surg Am. 2010;92 Suppl2(Suppl 2):133-151. doi:10.2106/JBJS.J.00906
29. Sayegh ET, Mascarenhas R, Chalmers PN, Cole BJ, Verma NN, Romeo AA. Allograft Reconstruction for Glenoid Bone Loss in Glenohumeral Instability: A Systematic Review. Arthrosc J Arthrosc Relat Surg. 2014;30(12):1642-1649. doi:10.1016/j.arthro.2014.05.007
30. Ellis HB, Seiter M, Wise K, Wilson P. Glenoid Bone Loss in Traumatic Glenohumeral Instability in the Adolescent Population. J Pediatr Orthop. 2017;37(1):30-35.doi:10.1097/BPO.0000000000000586
31. Rabinowitz J, Friedman R, Eichinger JK. Management of Glenoid Bone Loss with Anterior Shoulder Instability: Indications and Outcomes. Curr Rev Musculoskelet Med. 2017;10(4):452-462. doi:10.1007/s12178-017-9439-y
32. Saliken DJ, Bornes TD, Bouliane MJ, Sheps DM, Beaupre LA. Imaging methods for quantifying glenoid and Hill-Sachs bone loss in traumatic instability of the shoulder: a scoping review. BMC Musculoskelet Disord. 2015;16(1):164. doi:10.1186/s12891-015-0607-1
33. Zimmermann S, Scheyerer M, Pietsch C, Gerber C. Long-term results of bankart repair and Latarjet procedure for treatment of recurrent shoulder instability. Swiss Med Wkly. 2014;144:31S.
34. Van der Linde J, van Wijngaarden R, Somford M, van Deurzen D, van den Bekerom M. The Bristow-Latarjet procedure, a historical note on a technique in comeback. Knee Surg Sports Traumatol Arthrosc. 2016;24(2):470-478. doi:10.1007/s00167-015-3704-7

35. Balg F, Boileau P. The instability severity index score. J Bone Joint Surg Br. 2007;89-B(11):1470-1477. doi:10.1302/0301-620X.89B11.18962
36. Helfet AJ. Coracoid transplantation for recurring dislocation of the shoulder. J Bone Joint Surg Br. 1958;40-B(2):198-202. http://www.ncbi.nlm.nih.gov/pubmed/13539102. Accessed March 4, 2019.
37. Latarjet M. Treatment of recurrent dislocation of the shoulder. Lyon Chir. 1954;49(8):994-997. http://www.ncbi.nlm.nih.gov/pubmed/13234709. Accessed June 8, 2018.
38. Haaker RG, Eickhoff U, Klammer HL. Intraarticular autogenous bone grafting in recurrent shoulder dislocations. Mil Med. 1993;158(3):164-169.http://www.ncbi.nlm.nih.gov/pubmed/8487969. Accessed March 4, 2019.
39. Warner JJP, Gill TJ, O'hollerhan JD, Pathare N, Millett PJ. Anatomical glenoid reconstruction for recurrent anterior glenohumeral instability with glenoid deficiency using an autogenous tricortical iliac crest bone graft. Am J Sports Med. 2006;34(2):205-212. doi:10.1177/0363546505281798
40. Weng P-W, Shen H-C, Lee H-H, Wu S-S, Lee C-H. Open reconstruction of large bony glenoid erosion with allogeneic bone graft for recurrent anterior shoulder dislocation. Am J Sports Med. 2009;37(9):1792-1797. doi:10.1177/0363546509334590
41. Provencher MT, Ghodadra N, LeClere L, Solomon DJ, Romeo AA. Anatomic osteochondral glenoid reconstruction for recurrent glenohumeral instability with glenoid deficiency using a distal tibia allograft. Arthroscopy. 2009;25(4):446-452. doi:10.1016/j.arthro.2008.10.017
42. Williams HLM, Evans JP, Furness ND, Smith CD. It's Not All About Redislocation: A Systematic Review of Complications After Anterior Shoulder Stabilization Surgery. Am J Sports Med. December 2018:036354651881071. doi:10.1177/0363546518810711
43. Hurley ET, Jamal MS, Ali ZS, Montgomery C, Pauzenberger L, Mullett H. Long-term outcomes of the Latarjet procedure for anterior shoulder instability: a systematic review of studies at10-year follow-up. J Shoulder Elb Surg. 2019;28(2):e33-e39. doi:10.1016/j.jse.2018.08.028
44. Willemot L, De Boey S, Van Tongel A, Declercq G, De Wilde L, Verborgt O. Analysis of failures after the Bristow-Latarjet procedure for recurrent shoulder instability. Int Orthop.2019;43(8):1899-1907. doi:10.1007/s00264-018-4105-6
45. Willemsen K, Berendes TD, Geurkink T, et al. A Novel Treatment for Anterior Shoulder Instability. J Bone Joint Surg. Am. 2019;101(14):e68. doi:10.2106/JBJS.18.00892
46. Moseley HF. The use of a metallic glenoid rim in recurrent dislocation of the shoulder. Can Med Assoc J. 1947;56(3):320. http://www.ncbi.nlm.nih.gov/pubmed/20285282. Accessed June 8, 2018.
47. McCulloch P, Feinberg J, Philippou Y, et al. Progress in clinical research in surgery and IDEAL. Lancet. 2018;392(10141):88-94. doi:10.1016/S0140-6736(18)30102-8
48. Sedrakyan A, Campbell B, Merino JG, Kuntz R, Hirst A, McCulloch P. IDEAL-D: a rational framework for evaluating and regulating the use of medical devices. BMJ. 2016;353:i2372.doi:10.1136/bmj.i2372
49. Voorn VMA, Marang-van de Mheen PJ, van der Hout A, et al. The effectiveness of a de-implementation strategy to reduce low-value blood management techniques in primary hip and knee arthroplasty: a pragmatic cluster-randomized controlled trial. Implement Sci.2017;12(1):72. doi:10.1186/s13012-017-0601-0
50. Valstar ER, Gill R, Ryd L, Flivik G, Börlin N, Kärrholm J. Guidelines for standardization of radiostereometry (RSA) of implants. Acta Orthop. 2005;76(4):563-572.doi:10.1080/17453670510041574
51. Nelissen RGHH, Pijls BG, Kärrholm J, Malchau H, Nieuwenhuijse MJ, Valstar ER. RSA and registries: the quest for phased introduction of new implants. JBJS.2011;93(Supplement_3):62-65.

52. McCulloch P. Developing appropriate methodology for the study of surgical techniques. J R Soc Med. 2009;102(2):51-55. doi:10.1258/jrsm.2008.080308
53. McCulloch P, Altman DG, Campbell WB, et al. No surgical innovation without evaluation: the IDEAL recommendations. Lancet. 2009;374(9695):1105-1112. doi:10.1016/S0140-6736(09)61116-8

9

Chapter 9

Samenvatting
(summary in Dutch)

Doelen proefschrift

1. Anatomische evaluatie van het labrum van de schouder met vergelijken van het labrum van de heup
2. Evaluatie van uitkomst inclusief discussie over Oxford Shoulder Score en Oxford Shoulder Instability Score (addendum)
3. Evaluatie van behandeling van een eerste traumatische anterieure schouder luxatie in Nederland door middel van een schouder vragenlijst (inclusief behandeling van recidiverende schouderluxaties)
4. Midden- en lange termijn klinische en radiologische evaluatie van een cohort patiënten na een open Bankart operatie
5. Evaluatie van een nieuwe 3D-printing techniek om een glenoid defect te augmenteren

1. Inleiding

Het glenohumerale gewricht van het menselijk lichaam is een complex, mobiel, multiaxiaal, kogelgewricht die gecoördineerde bewegingen in de frontale, transversale en sagittale vlakken mogelijk maakt. Bovendien is het gewrichtskapsel relatief laks. Hierdoor bestaat er een verhoogd risico op het uit de kom gaan van de schouder (= luxatie danwel subluxatie). Een schouderluxatie gaat vaak gepaard met structurele schade aan aangrenzende weke delen, zoals het gewrichtskapsel, labrum, glenohumerale ligamenten, spieren en pezen. Hierdoor bestaat een grote recidief kans op (sub-)luxaties, de schouder instabiliteit.

Verschillende classificatiesystemen kunnen worden gebruikt om schouder instabiliteit te beschrijven. Grofweg wordt er onderscheid gemaakt tussen traumatische en atraumatische schouderluxaties. Schouderluxaties komen vooral voor tijdens privé- of sportongevallen.[1] In het algemeen worden er meer mannen dan vrouwen behandeld voor een schouderluxatie.[2] De meeste patiënten die uiteindelijk operatief worden behandeld voor recidiverende schouderluxaties, zijn jong en actief, vooral mannen tussen 15 en 35 jaar oud en vrouwen in de oudere leeftijdsgroepen.[1,3] De recidiefkans is beduidend hoger bij de jongere, actieve patiënt. Uitgaande van een jaarlijkse incidentie van schouderluxaties van 30 per 100.000 inwoners, kan men in Nederland met ongeveer 17 miljoen inwoners rekenen op ruim 5000 schouderluxaties per jaar.[1,4]

2. Chirurgische behandelopties

In het verleden zijn er veel verschillende chirurgische schouder stabiliserende procedures uitgevoerd en beschreven.[5] De stabiliserende schouder operaties kunnen grofweg worden onderverdeeld in: ingrepen aan de weke delen danwel ingrepen aan het bot. Veel

Tabel 1: Historisch overzicht van chirurgische behandelingen voor schouder instabiliteit

Weke delen procedures	*Kapsel procedures*	- *Injecties met jodium tinctuur/bloed*: Genzmer 1882; Mandel/ Kepler 1937 - *Inkorten van gewrichtskapsel*: Ricard 1894, Gerster 1883, Bardenheuer 1896, Mikulicz 1896, Putti-Platt 1923, inferieure Kapsel plastiek: Neer, Foster 1980 - *Gewrichtskapsel verstevigingen, gebruik makende van fascie, pees, periost of ander materiaal*: Gallie-le Mesurier 1948, Henderson 1943, Nicola 1929 - *Open Hill-Sachs "remplissage"*: Connolly 1972 - *Kapsuloligamentaire "retensioning" ingrepen*: Caspari 1987 - *Sluiten van het rotator interval*: Rowe 1987 - "*Suture-only" labrum refixatie*: Harryman 1994
	Rotator cuff spier/ pees procedures	- *Inkorten van subscapularis*: Quervain 1910, Röbke 1912, Putti 1923, Platt 1925, Matti 1936, Boicev 1938, Magnuson & Stack 1943, Boicev & Osmond-Clarke 1948 - *Transpositie deel deltoideusspier*: Clairmont-Ehrlich 1909 - *Open Hill-Sachs remplissage*: Connolly 1972
	Arthroscopische procedures	- K*apsel plastiek middels "stapling techniek"*: Johnson 1980 - *Labrum refixatie*: Morgan 1987 - *Labrum refixatie met "suture anchors"*: Snyder, Wolf 1990-1991 - K*apsel plastiek*: Duncan 1993 - "*Laser assisted/thermal capsular shrinkage"*: Thabit 1994 - *Sluiten van het rotator interval*: Field, Treacy 1995-1997 - *Revisie Bankart operatie*: Kim 2002 - *Hill-Sachs remplissage*: Wolf 2004, Purchase 2008
Ossale procedures	*Glenoid procedures*	- *Dieper maken van het cavum glenoidalis*: Hildebrand 1902 - *Ingrepen gericht op de rand van het cavum glenoidalis*: Perthes 1906, **Bankart** 1923 - *Bot augmentatie procedures op het glenoid*: Eden 1918, Hybbinette 1917&1932, Noordenbos 1938, Leguit 1942 - *Coracoid (augmentatie) procedures*: Oudard 1924, Noesske 1924, Latarjet 1954, Bristow 1958, Trillat 1954 - *Mini-open Bristow-Latarjet procedure*: Nourissat 2006
	Humerale procedures	- *Humeruskop resectie*: Cramer 1882 - *Glenohumerale arthrodese*: Albert 1888 - *Rotatie osteotomie van de humerus*: Weber 1969
	Arthroscopische procedures	- *Latarjet procedure*: Lafosse 2007 - *Eden procedure*: Taverna, Scheibel 2008 - *Augmentatie procedure middels autograft van distale deel clavicula*: Tokish 2014 - *Latarjet procedure met "guided surgical approach and suture endobutton" fixatie*: Boileau 2015 - *Dynamische anterieure stabilisatie mbv lange bicepspees icm Bankart procedure*: Mehl 2019

van deze ingrepen kunnen zowel via een open procedure danwel via een kijkoperatie (arthroscopisch) worden uitgevoerd.[6]

Voor een nauwkeurig overzicht van de tot nu toe meest bekende chirurgische behandelingen voor schouder instabiliteit wordt verwezen naar Tabel 1.[7,8]

Ondanks deze vele chirurgische behandelmethodes voor de instabiele schouder, bestaat er nog steeds geen eenduidig beleid en blijft de meest optimale behandeling controversieel, zowel wat conservatief als welk en wanneer welk operatief beleid gedaan moet worden.[9] Dit komt onder andere door de grote diversiteit aan mogelijke oorzaken van schouder instabiliteit (variërend van functionele, proprioceptieve problemen tot anatomische afwijkingen die hiermee gepaard kunnen gaan).

De arthroscopisch uitgevoerde Bankart operatie is in Nederland momenteel de behandeling die het meest frequent wordt gedaan bij patiënten met recidiverende posttraumatische schouderluxaties.[10] De open Bankart operatie, welke initieel werd beschreven door Bankart in 1923, wordt echter steeds minder uitgevoerd. Echter bewijs dat de arthroscopische uitvoering beter is dan de open chirurgische procedure, is er niet.[11–13] Het is zelfs zo, dat de open Bankart operatie waarschijnlijk een betere uitkomst (minder nieuwe luxaties) heeft bij de actieve (high-demanding) patiënt die deelneemt aan contact of racket sport, fysiek veeleisend werk heeft, jonger is dan 25 jaar, of botverlies van het glenoid heeft (< 20%).[12,14,15]

3. Arthur Sidney Blundell Bankart (1879–1951)

De naam van de Britse orthopedisch chirurg Arthur Sydney Blundell Bankart (Figuur 1) is onherroepelijk verbonden aan (recidiverende) schouder luxaties. De Bankart laesie en Bankart operatie zijn wereldwijd bij vrijwel alle (ook niet schouder) orthopeden van deze tijd bekend. De eerste beschrijvingen van een schouderluxatie zijn afkomstig van een Egyptisch papyrus, van 1522 voor onze jaartelling. De meest gedetailleerde beschrijving is van Hippocrates rond 400 voor Christus, die het branden van de zachte weefsels rond de schouder suggereerde met rood-heet verhit ijzer om op die manier stabiliserende littekens te genereren (vergelijk met de inmiddels obsolete arthroscopische schouder stabilisatie procedure d.m.v. “Laser assisted/thermal capsular shrinkage” (Thabit 1994).

Bankart letsel

Avulsie letsels van het labrum zijn al meerdere keren in de literatuur beschreven voordat Bankart het belang hiervan benadrukte. In 1887, beschreef Caird dat het anterieure labrum losscheurde na een voorste schouderluxatie, tevens beschreef hij een “defect of deuk” in de humeruskop (= Hill-Sachs lesie) als het resultaat van de botsing van de achterkant van de schouderkop tegen de voorzijde van het anteroinferieure glenoid. In

1890, beschreven Broca en Hartmann deze afscheuring van het voorste labrum samen met een klein botdeel met periost aan de voorrand van het glenoid (=sleeve avulsion/ ossale bankart lesie). Hierbij beschreven zij ook de posterolaterale deuk in de humeruskop (= Hill-Sachs lesie). In 1906, adviseerde Perthes het terughechten van het losgekomen labrum met behulp van boorgaten in het glenoid, indien noodzakelijk in combinatie met het repareren van de posterosuperiore rotator cuff. Bankart (1923) benadrukte de relevantie van het los gestripte kapsel en labrum (= Bankart lesie) voor de mate van instabiliteit. Hierop, beschreef Bankart de chirurgische refixatie van het los gestripte kapsel labrum complex als optimale behandeling voor posttraumatische glenohumerale instabiliteit.[16] Tevens beredeneert hij dat het inkorten van het voorste kapsel alleen, zoals tot dan gebruikelijk was, onvoldoende stabiliteit zou geven en ook zou leiden tot meer bewegingsbeperking (exorotatie verlies). Na deze "klassieke" beschrijving van een Bankart lesie, zijn er andere Bankart-achtige letsels beschreven. Hierbij is een grote verscheidenheid aan bot- en weke delen letsels van het labrum, periost, kapsel, glenohumerale ligamenten, (sub)chondrale oppervlak en de fossa glenoidalis beschreven.

Figuur 1: Arthur Sidney Blundell Bankart.

Klassieke Bankart operatieprocedure

Bij de "klassiek" uitgevoerde Bankart operatie wordt het geruptureerde anteroinferieure kapsel, met of zonder het bijbehorende labrum, gerefixeerd door middel van hechtingen door het bot (transossale hechtingen). Deze hechtingen worden geplaatst door boortunnels aan de voorzijde van de schouderkom (het glenoid). Hiervoor wordt een benadering tussen de spieren door (deltopectorale benadering) geadviseerd in combinatie met het doorzagen van het ravenbekuitsteeksel van de schouder (coracoid osteotomie) om zodoende een beter overzicht te krijgen over het voorste gedeelte van het schoudergewricht. Na de eerste beschrijving, zijn verschillende modificaties aangebracht zoals het gebruik van botankers in plaats van boortunnels alsook het achterwege laten van de coracoid osteotomie.

Onze huidige open "gemodificeerde versie" van de Bankart operatie
De patiënt bevindt zich onder algehele anesthesie in de strandstoel positie. Incisie in de voorste okselplooi (anterieure axillaire incisie), waarbij het interval tussen de spieren (deltopectorale interval) wordt opgezocht. De vena cephalica wordt hierbij zijwaarts (naar lateraal) beschermd weggehouden. Vervolgens wordt de clavipectorale fascia ingesneden en wordt de conjoined tendon naar mediaal getrokken en de subscapularis pees geïdentificeerd. De subscapularis pees wordt vanaf boven (craniaal), verticaal ingesneden, ongeveer 1,5 cm mediaal ten opzichte van de insertie, waarbij het inferieure deel intact blijft. Het gewrichtskapsel wordt aan de kant van de schouderkop (humerale zijde) verticaal ingesneden. Een T-vormige kapselincisie wordt gemaakt, waardoor er een bovenste (superieure) en een onderste (inferieure) kapselflap wordt gevormd. De corticale laag van het glenoïd aan de voorrand wordt opgeruwd met een osteotoom om bloedend bot te creëren. Drie tot vier gaten voor botankers worden gemaakt op de rand van het glenoïd. Het labrum (of zijn overblijfselen) en de mediale kapselflap worden dan opnieuw bevestigd aan het glenoïd. De twee kapselflappen worden vervolgens revend gesloten, waarbij de bovenste superieure flap naar onderen inferieur en de onderste inferieure kapselflap naar boven superieur wordt gebracht, zodat het voorste anterieure schouderkapsel voldoende strak is. De arm wordt tijdens deze manoeuvre in neutrale rotatie en abductie van ongeveer 30° gehouden. Ten slotte worden twee extra hechtingen geplaatst tussen de twee kapselflappen om de horizontale T-insnijding van de reparatie te sluiten. De subscapularisspier wordt anatomisch gerefixeerd aan het restante deel ervan. Uiteindelijk wordt het rotatorinterval spanningsvrij gesloten. Postoperatief wordt de arm gedurende zes weken in een schouder immobilizer geplaatst.

4. Botverlies

Met een goed uitgevoerde Bankart repair kan je veel instabiliteit problemen voorkomen. Echter, schouder instabiliteit gaat vaak gepaard met botverlies. De identificatie van aan- of afwezigheid van botverlies wordt tegenwoordig steeds meer benadrukt in de optimale behandeling bij schouder instabiliteit, zowel voor maar zeker na een "gefaalde" initiële stabiliserende schouder operatie.[17–20] Ter plaatse van het glenoid (anteroinferior) wordt tot wel 20% botverlies beschreven na een eerste traumatische anterieure schouder luxatie, wat kan toenemen tot maximaal 90% in situaties van recidiverende anteroinferieure schouder luxaties.[17,19] Dit is een van de redenen dat sommige chirurgen een operatieve behandeling adviseren na een eerste traumatische anterieure schouderluxatie bij de jonge actieve (mannelijke) patiënt.[21,22] Hoe groter het glenoid botdefect, hoe minder het stabiliserende effect van de Bankart operatie zal zijn.[23] In een kadaver studie van Itoi werd een afkapwaarde van 20–21% botverlies gemeld voor de Bankart operatie.[23] De Latarjet procedure wordt om die reden vaak uitgevoerd wanneer het glenoid botdefect groter is dan 20% of wanneer het risico op recidief luxaties groter is zoals bij mannelijke contact-of racket

sporters of in (revisie-) gevallen waarbij er een deficiënt kapsel/labrum overblijft, soms als gevolg van eerdere operaties ter plaatse.[9,24–28] Bij een Latarjet operatie wordt het coracoid waaraan de coracobrachialis- en korte bicepspees (= conjoined tendon) vastzit, aan de basis afgezaagd om vervolgens verplaatst te kunnen worden naar de voorrand van het glenoid. De gemeenschappelijke pees (conjoined tendon) wordt hierbij door de subscapularispees getunneld waardoor er een zogenaamd extra "sling-effect" optreedt wat de anterieure stabiliteit van de schouder extra ten goede komt.[29] De Latarjet procedure geeft het laagste recidief luxatie percentage, maar heeft ook het hoogste complicatie risico.[30] Hoewel het "sling-effect" bij deze Latarjet ingreep de dynamische stabiliteit van de schouder ten goede komt, zal het mogelijk de functionaliteit van deze belangrijke subscapularisspier verminderen en mogelijk zelfs pijnklachten veroorzaken bij de patiënt. Een eventueel aanwezig begeleidend humeraal botdefect van de schouderkop (= Hill-Sachs laesie) moet ook worden beoordeeld om een optimale inschatting te maken van het instabiliteit probleem. Bij aanwezigheid van bipolaire laesies (= glenoid + humeraal botverlies), wordt vaak het "glenoid-track" concept gebruikt om tot een optimale behandeling te komen.[20,26,31] Het percentage botverlies kan vrij goed worden ingeschat door middel van aanvullende röntgen opnames: "West Point radiographic view" (=soort axiale opname zonder overlap van het coracoid met het glenoid), danwel via 3D CT- of 3D MRI-scans.[32,33] Andere reeds bekende "bone block" augmentatie operatietechnieken zijn: de Bristow procedure; reconstructies waarbij gebruik wordt gemaakt van een botspaan uit de bekkenkam en augmentaties met allograft bot van heupkoppen of autograft van het distale deel van het scheenbeen (tibia) of sleutelbeen (clavicula).[34–40] Al deze augmentatie procedures kunnen gepaard gaan met donor-site problematiek, zowel op korte als lange termijn. Maar ook op de acceptor plaats tpv het glenoid, zoals osteosynthese problemen na remodellering en/of resorptie van het geaugmenteerde glenoid bot, maar ook afname van het sling-effect door atrofie danwel volledig verdwijnen (ruptuur) van de conjoined tendon.

5. Samenvatting resultaten manuscript

Hoofdstuk 2 vermeldt evolutionaire veranderingen van de schouder, voortkomend uit het feit dat mensen zich hebben ontwikkeld om rechtop te lopen (zoals bv homo erectus, homo neanderthalensis, homo sapiens). Een van de voordelen van dit bipedalisme is het hebben van vrije handen, gepaard gaande met nieuwe eisen voor de schouder zoals toegenomen functie & mobiliteit. De overeenkomsten en verschillen van het labrum van schouder en heupgewricht worden geanalyseerd met speciale aandacht voor anatomie, pathologie (labrum laesies, gevoel van instabiliteit en degeneratieve afwijkingen zoals artrose) en therapeutische behandelopties hiervan.

In **hoofdstuk 3** van dit proefschrift presenteren we onze Nederlandse vertaling van de "Oxford Shoulder Score" (OSS), een internationaal veel gebruikte patiënt-reported-

outcome-measurement (PROM's) voor schouder pathologie, inclusief een discussie over de Oxford Shoulder Score en Oxford Shoulder Instability Score (addendum). De OSS-vragenlijst beoordeelt de pijn en het activiteitenniveau van de aangedane schouder in het dagelijks leven (33% en 66% respectievelijk). Oorspronkelijk werd de score gebruikt voor het beoordelen van 111 patiënten die een schouderoperatie hadden ondergaan vanwege chronische schouderklachten, waarbij operaties voor instabiliteit werden uitgesloten.[41] Later werd de OSS nog getest bij patiënten na rotator cuff chirurgie (operatie voor een scheur in een of meerdere pezen van de 4 spieren rond de schouder) en bij patiënten met een frozen shoulder (stijf schouderkapsel) welke werden doorbewogen onder narcose.[42,43] Onze studie geeft aan dat het meetinstrument na vertaling in het Nederlands valide en begrijpelijk bleek waarbij een vergelijking werd gemaakt met bestaande klinisch gevalideerde schouder vragenlijsten (te weten: de Nederlandse simpele schouder test en Constant-Murley score) en de generieke PROM SF-36 (Short Form 36 health survey) bij schouder patiënten in het Reinier de Graaf gasthuis ziekenhuis te Delft.

Hoofdstuk 4 evalueert hoe orthopedisch chirurgen in Nederland eerste acute anterieure schouderluxaties (AFASD) behandelen. Ten tweede wordt geëvalueerd of dit volgens de (toen geldende) CBO-richtlijn wordt gedaan.[44] Het effect van de invoering van de nationale (CBO en Nederlandse Orthopedische Vereniging (NOV)) richtlijn "acute primaire schouderluxaties" in 2005 op de algemene praktijkvoering werd eveneens geëvalueerd.[4] Als laatste werd gevraagd hoe orthopedisch chirurgen recidiverende (traumatische) anterieure schouderluxatie(s) behandelen. De opvang en behandeling van (eerste) acute anterieure schouderluxaties (AFASD) op de spoedeisende hulp liet evenals de uiteindelijke chirurgische behandeling van recidiverende instabiliteit na AFASD grote verschillen zien. De overgrote meerderheid (93%) gebruikt bij een operatieve behandeling voor schouderinstabiliteit een arthroscopische operatietechniek, de rest een "open" operatietechniek. Wanneer er een open stabiliserende operatie werd uitgevoerd, was de open (gemodificeerde) Bankart repair de meest gebruikte techniek (54%). De Putti-Platt operatie werd in 16% van de gevallen toegepast evenals de Latarjet procedure.[29,45] Een enquête in 2003, voorafgaand aan de introductie van de bovengenoemde CBO-richtlijn "acute primaire schouderluxaties" (2005), toonde aan dat 65% van de beoordeelde Nederlandse ziekenhuizen een "eigen" ziekenhuis protocol had voor de behandeling van schouderluxaties (responspercentage 73%, van 74 Nederlandse ziekenhuizen).[46] De uitkomst van onze studie liet zien dat er na de invoering van de richtlijn, slechts een beperkte toename was van ziekenhuis protocollen voor de behandeling van schouderluxaties (75%). Slechts 29% van de respondenten gaf aan dat het bestaande ziekenhuis protocol was aangepast naar aanleiding van de toen nieuw geïntroduceerde richtlijn.

Hoofdstuk 5 beschrijft de middellange klinische en radiologische resultaten met een gemiddelde follow-up van 11 jaar (10–15 jaar) van een cohort van 31 patiënten die een gemodificeerde open Bankart operatie hebben ondergaan. We rapporteren de

belangrijkste stappen tijdens deze operatieprocedure. 26 patiënten (84%) gaven aan een goed tot zeer goed eindresultaat te hebben. De recidief luxatie kans varieerde tussen 7% en 10% afhankelijk van de definitie van "recidief luxatie". Bij 2 patiënten trad een recidief luxatie op ten gevolge van een nieuw adequaat trauma 1 en 9 jaar na operatie. Het totale instabiliteit risico (= subluxatie gevoel en/of dislocaties) varieerde tussen 13% en 23%. 32% van de schouders liet ten tijde van follow-up tekenen van artrose zien op de röntgenfoto, waarvan 3% ernstig (Samilson-Prieto graad 3). De gemiddelde Rowe score was 90 punten (66–98) en Constant score 96 punten (85–100). Er waren geen andere complicaties, zoals wondinfecties.

In **hoofdstuk 6** werden de klinische en radiologische resultaten van een cohort van 39 patiënten na een gemodificeerde versie van de "open Bankart operatie" geëvalueerd na een gemiddelde follow-up van 21 jaar (16–26 jaar). De recidief luxatiekans was 10%, het totale instabiliteit risico (= subluxatie gevoel en/of dislocaties) 23%. 20 schouders (51%) hadden radiologisch tekenen van artrose ten tijde van follow-up, waarvan 10% matig (Samilson-Prieto graad 2) en 3% ernstig (Samilson-Prieto graad 3). De gemiddelde Rowe score was 85 punten (25–100) en Constant score 92 punten (70–100).

Hoofdstuk 7 evalueert of een glenoid defect te augmenteren is met een 3D geprinte scaffold. In een biomechanische kadaverstudie werden verschillende situaties nagebootst om de stabiliteit van de schouder te testen.[17,19] In tien fresh-frozen kadaver schouders werd een defect gemaakt aan de voorzijde van het glenoid, waarna een 3D-patiënt specifiek titanium implantaat (scaffold) werd geplaatst. Alle schouders zijn zowel voor als na de ingreep gescand volgens een 3D CT-protocol (250 mAs, 120 kV, 0.9 mm coupes). Hierna werd met behulp van een imaging softwarepakket (Mimics Medical 20.0, Materialise, Leuven, Belgium) een 3D-patiënt specifiek titanium implantaat geprint (SLM-titanium printer, ProX DMP320, 3D systems, Leuven, Belgium) waarvoor een Freeform Plus softwarepakket (Geomagic, 3D systems, Leuven, Belgium) werd gebruikt. Fixatie van de scaffold werd gedaan door twee hoekstabiele schroeven, waarbij ook de schroefgat positie werd geoptimaliseerd d.m.v. het Freeform Plus softwarepakket. De 3D implantaten zijn gemaakt van "medisch" titanium (Ti6Al4v ELI grade 23). De kracht die nodig is om de humeruskop 10mm naar voren (anterieur) te transleren t.o.v. het glenoid, werd gemeten onder 5 verschillende condities: (1) de "normale" ongeschonden situatie, (2) na het maken van een gecontroleerd anterieur botdefect in het glenoid, (3) na plaatsing van een 3D Titanium patiënt-specifiek implantaat, (4) na een Latarjet procedure met en (5) zonder 10N sling-effect van de conjoined tendon. De kracht die nodig was om de humeruskop 10 mm naar anterieur te transleren na creatie van het glenoid botdefect was tot 70% afgenomen ten opzichte van het intacte glenoid. Na augmentatie van het botdefect door middel van het 3D specifiek implantaat, danwel middels een Latarjet procedure, normaliseerde de kracht om de humeruskop te luxeren naar respectievelijk 119% ± 16% ($p < 0{,}01$) en 121% ± 48% ($p = 0{,}02$) vergeleken met het intacte glenoid.

6. Toekomst

Het begrip schouderinstabiliteit heeft behoefte aan een duidelijker definitie, die internationaal geaccepteerd is, alleen dan is het mogelijk vergelijkende (inter-) nationale studies uit te voeren m.b.t. interventies (zowel conservatief als operatief). In de aanwezigheid van een groot ossaal defect, ontstaan er vrijwel altijd instabiliteit problemen. In die situaties is het verrichten van een stabiliserende schouder operatie in engere zin noodzakelijk. Indien het botverlies meer dan 20% is, wordt vooralsnog een Latarjet ingreep uitgevoerd, die niet alleen een hoog complicatie risico heeft maar ook de functie van een van de prime movers van de schouder, de musculus subscapularis, compromitteert. Het gebruik van 3D printing technieken compromitteert in ieder geval niet in die mate de belangrijke subscapularis spier. Maar "no surgical innovation without evaluation". De ontwikkeling van een nieuwe chirurgische techniek behoort idealiter verschillende stadia te doorlopen. Deze stadia worden beschreven door McCulloch, in zijn zogenaamde IDEAL-model. (IDEAL consortium, Lancet zie Figuur 2) Dit model geeft een aantal makkelijk te implementeren aanbevelingen voor de beoordeling en implementatie van nieuwe chirurgische ingrepen/technieken.[47,48] Nadien is het IDEAL-D-model geïntroduceerd ter evaluatie en regulatie van het gebruik van medische apparaten en implantaten in een implantaat register (zoals bv de LROI, www.LROI.nl).[47,51]

Eerder hebben we gezien dat implementatie van richtlijnen maar ook nieuwe chirurgische inzichten, complex kan zijn, zoals bijvoorbeeld bleek uit de implementatie van een nieuwe richtlijn met betrekking tot bloed management rondom heup- en kniearthroplastieken.[49,50] In ontwikkeling stadium 1, ookwel het preklinische stadium wordt er ex-vitro bewijs geleverd dat veiligheid en betrouwbaarheid zijn gewaarborgd, zoals bij onze kadaverstudie (hoofdstuk 7). In dit stadium moet de chirurg bewijzen dat het concept werkt (= Proof of concept) en zijn er maar een paar orthopedisch chirurgen bij betrokken. In stadium 2a wordt de nieuwe procedure verder ontwikkeld vanwege de behoefte aan een nieuwe oplossing voor een klinisch probleem (hier: schouderinstabiliteit met > 20% botverlies). De resultaten hiervan moeten gedetailleerd worden beschreven. Stadium 2b is de verkenning- en leerfase, waarbij de operatieprocedure bij een grotere groep patiënten wordt toegepast om ervaring met het eerste gebruik te krijgen en om de precieze techniek of het implantaat te verfijnen. Stadium 3 is de beoordelingsfase. In deze fase is het doel de effectiviteit van de procedure te beoordelen in vergelijking met andere procedures. Stadium 4 is de laatste fase, waarna de procedure wereldwijd kan worden gebruikt. De resultaten dienen ook op lange termijn te worden gecontroleerd: blijft het implantaat goed gefixeerd in het botdefect zitten? Voor deze laatste evaluatie zijn microbewegingsmetingen nodig tussen implantaat en bot (zoals met RSA of CT) om late complicaties zoals loslating van het implantaat te voorspellen.[52,53]

Naar mijn mening biedt 3D technologie mogelijkheden voor de orthopedie, zoals onze studie (hoofdstuk 7) bij instabiliteit klachten van de schouder ten gevolge van

	1 Idea	2a Development	2b Exploration	3 Assessment	4 Long-term study
Purpose	Proof of concept	Development	Learning	Assessment	Surveillance
Number and types of patients	Single digit; highly selected	Few; selected	Many; may expand to mixed; broadening indication	Many; expanded indications (well defined)	All eligible
Number and types of surgeons	Very few; innovators	Few; innovators and some early adopters	Many; innovators, early adopters, early majority	Many; early majority	All eligible
Output	Description	Description	Measurement; comparison	Comparison; complete information for non-RCT participants	Description; audit, regional variation; quality assurance; risk adjustment
Intervention	Evolving; procedure inception	Evolving; procedure development	Evolving; procedure refinement; community learning	Stable	Stable
Method	Structured case reports	Prospective development studies	Research database; explanatory or feasibility RCT (efficacy trial); diseased based (diagnostic)	RCT with or without additions/modifications; alternative designs	Registry; routine database (eg, SCOAP, STS, NSQIP); rare case reports
Outcomes	Proof of concept; technical achievement; disasters; dramatic successes	Mainly safety; technical and procedural success	Safety; clinical outcomes (specific and graded); short-term outcomes; patient-centred (reported) outcomes; feasibility outcomes	Clinical outcomes (specific and graded); middle-term and long-term outcomes; patient-centred (reported) outcomes; cost-effectiveness	Rare events; long-term outcomes; quality assurance
Ethical approval	Sometimes	Yes	Yes	Yes	No
Examples	NOTES video	Tissue engineered vessels	Italian D2 gastrectomy study	Swedish obese patients study	UK national adult cardiac surgical database

Figuur 2: IDEAL-model met de verschillende stadia van ontwikkeling van een chirurgische interventie.
Afkortingen: RCT, randomised controlled trial; SCOAP, Surgical Clinical Outcomes Assessment Programme; STS, Society of Thoracic Surgeons; NSQIP, National Surgical Quality Improvement Program; NOTES, natural orifice transluminal endoscopic surgery.

botverlies laat zien. Echter, om dit implantaat tot een succes te maken zal het titanium implantaat nog vervangen dienen te worden door een bioscaffold, waarin cellen kunnen groeien, waarna het implantaat geïncorporeerd is met het glenoid. Dit betekent dat het implantaat niet geprint wordt van titanium, maar van materiaal wat door het lichaam zelf kan worden omgebouwd in bot, zoals een calciumfosfaat. Aan de andere kant zijn de nanostructuur eigenschappen van metaal weer optimaler qua sterkte en stabiliteit dan voor de resorbeerbare bioscaffolds. Uiteindelijk blijft evaluatie nodig zoals volgens het IDEAL-principe: Idea → Development → Exploration → Assessment → Long-term follow-up. Mede hierdoor kan een zinvolle verbetering ontstaan in kwaliteit van patiëntenzorg.

References

1. Slaa te RL. The acute first-time anterior shoulder dislocation (AFASD). Thesis, Amsterdam. 2003.
2. Simonet WT, Melton LJ, Cofield RH, Ilstrup DM. Incidence of anterior shoulder dislocation in Olmsted County, Minnesota. Clin Orthop Relat Res. 1984;(186):186-191. http://www.ncbi.nlm.nih.gov/pubmed/6723141. Accessed June 8, 2019.
3. Magnuson JA, Wolf BR, Cronin KJ, et al. Sex-related differences in patients undergoing surgery for shoulder instability: a Multicenter Orthopaedic Outcomes Network (MOON) Shoulder Instability cohort study. J Shoulder Elb Surg. April 2019. doi:10.1016/j.jse.2019.02.020
4. CBO Richtlijn: acute primaire schouderluxatie: diagnostiek en behandeling. 2005.
5. Glazebrook H, Miller B, Wong I. Anterior Shoulder Instability: A Systematic Review of the Quality and Quantity of the Current Literature for Surgical Treatment. Orthop J Sport Med. 2018;6(11):2325967118805983. doi:10.1177/2325967118805983
6. Sanders RJ. DE habituele anterieure schouderluxatie. Thesis, Groningen. 1978.
7. Randelli P, Cucchi D, Butt U. History of shoulder instability surgery. Knee Surg Sports Traumatol Arthrosc. 2016;24(2):305-329. doi:10.1007/s00167-015-3947-3
8. Levy DM, Cole BJ, Bach BR. History of surgical intervention of anterior shoulder instability. J Shoulder Elb Surg. 2016;25(6):e139-e150. doi:10.1016/j.jse.2016.01.019
9. Garcia GH, Taylor SA, Fabricant PD, et al. Shoulder Instability Management: A Survey of the American Shoulder and Elbow Surgeons. Am J Orthop (Belle Mead NJ). 2016;45(3):E91-E97.
10. Berendes TD, Pilot P, Nagels J, Vochteloo AJH, Nelissen RGHH. Survey on the management of acute first-time anterior shoulder dislocation amongst Dutch public hospitals. Arch Orthop Trauma Surg. 2015;135(4). doi:10.1007/s00402-015-2156-3
11. Handoll HHG, Almaiyah MA, Rangan A. Surgical versus non-surgical treatment for acute anterior shoulder dislocation. Cochrane Database Syst Rev. 2004;(1):CD004325. doi:10.1002/14651858.CD004325.pub2
12. Kavaja L, Lähdeoja T, Malmivaara A, Paavola M. Treatment after traumatic shoulder dislocation: a systematic review with a network meta-analysis. Br J Sport Med. 2018;52:1498-1506. doi:10.1136/bjsports-2017-098539
13. Miura K, Tsuda E, Tohyama H, et al. Can arthroscopic Bankart repairs using suture anchors restore equivalent stability to open repairs in the management of traumatic anterior shoulder dislocation? A meta-analysis. J Orthop Sci. 2018;23(6):935-941. doi:10.1016/j.jos.2018.06.016
14. Khatri K, Arora H, Chaudhary S, Goyal D. Meta-Analysis of Randomized Controlled Trials Involving Anterior Shoulder Instability. Open Orthop J. 2018;12(1):411-418. doi:10.2174/1874325001812010411
15. Chahal J, Marks PH, MacDonald PB, et al. Anatomic Bankart Repair Compared With Nonoperative Treatment and/or Arthroscopic Lavage for First-Time Traumatic Shoulder Dislocation. Arthrosc J Arthrosc Relat Surg. 2012;28(4):565-575. doi:10.1016/j.arthro.2011.11.012
16. Bankart AS. Recurrent or habitual dislocation of the shoulder joint. Br Med J. 1923;2(3285):1132-1133. http://www.ncbi.nlm.nih.gov/pubmed/20771383. Accessed November 10, 2017.
17. Provencher MT, Bhatia S, Ghodadra NS, et al. Recurrent shoulder instability: current concepts for evaluation and management of glenoid bone loss. J Bone Joint Surg Am. 2010;92 Suppl 2(Suppl 2):133-151. doi:10.2106/JBJS.J.00906
18. Arciero RA, Parrino A, Bernhardson AS, et al. The Effect of a Combined Glenoid and Hill-Sachs Defect on Glenohumeral Stability. Am J Sports Med. 2015;43(6):1422-1429. doi:10.1177/0363546515574677

19. Sayegh ET, Mascarenhas R, Chalmers PN, Cole BJ, Verma NN, Romeo AA. Allograft Reconstruction for Glenoid Bone Loss in Glenohumeral Instability: A Systematic Review. Arthrosc J Arthrosc Relat Surg. 2014;30(12):1642-1649. doi:10.1016/j.arthro.2014.05.007
20. Itoi E, Yamamoto N, Kurokawa D, Sano H. Bone loss in anterior instability. Curr Rev Musculoskelet Med. 2013;6(1):88-94. doi:10.1007/s12178-012-9154-7
21. Marshall T, Vega J, Siqueira M, Cagle R, Gelber JD, Saluan P. Outcomes After Arthroscopic Bankart Repair: Patients With First-Time Versus Recurrent Dislocations. Am J Sports Med. 2017;45(8):1776-1782. doi:10.1177/0363546517698692
22. Rugg CM, Hettrich CM, Ortiz S, et al. Surgical stabilization for first-time shoulder dislocators: a multicenter analysis. J Shoulder Elb Surg. 2018;27(4):674-685. doi:10.1016/j.jse.2017.10.041
23. Itoi E, Lee SB, Berglund LJ, Berge LL, An KN. The Effect of a Glenoid Defect on Anteroinferior Stability of the Shoulder After Bankart Repair: A Cadaveric Study. J Bone Jt Surg Am. 2000;82(1):35-46. doi:10.1002/sim.5330
24. Gowd AK, Liu JN, Cabarcas BC, et al. Management of Recurrent Anterior Shoulder Instability With Bipolar Bone Loss: A Systematic Review to Assess Critical Bone Loss Amounts. Am J Sports Med. August 2018:036354651879155. doi:10.1177/0363546518791555
25. Hurley ET, Jamal MS, Ali ZS, Montgomery C, Pauzenberger L, Mullett H. Long-term outcomes of the Latarjet procedure for anterior shoulder instability: a systematic review of studies at 10-year follow-up. J Shoulder Elb Surg. 2019;28(2):e33-e39. doi:10.1016/j.jse.2018.08.028
26. Di Giacomo G, Itoi E, Burkhart SS. Evolving concept of bipolar bone loss and the hill-sachs lesion: From "engaging/non-engaging" lesion to "on-track/off-track" lesion. Arthrosc - J Arthrosc Relat Surg. 2014. doi:10.1016/j.arthro.2013.10.004
27. Yamamoto N, Muraki T, An K, et al. The stabilizing mechanism of the latarjet procedure: A cadaveric study. J Bone Jt Surg - Ser A. 2013;95(15):1390-1397. doi:10.2106/JBJS.L.00777
28. Montgomery SR, Katthagen JC, Mikula JD, et al. Anatomic and Biomechanical Comparison of the Classic and Congruent-Arc Techniques of the Latarjet Procedure. Am J Sports Med. 2017;45(6):1252-1260. doi:10.1177/0363546516685318
29. Latarjet M. [Technic of coracoid preglenoid arthroereisis in the treatment of recurrent dislocation of the shoulder]. Lyon Chir. 1958;54(4):604-607. http://www.ncbi.nlm.nih.gov/pubmed/13576973. Accessed May 7, 2019.
30. Allain J, Goutallier D, Glorion C. Long-term results of the Latarjet procedure for the treatment of anterior instability of the shoulder. J Bone Joint Surg Am. 1998;80(6):841-852.
31. Nakagawa S, Iuchi R, Hanai H, Hirose T, Mae T. The Development Process of Bipolar Bone Defects From Primary to Recurrent Instability in Shoulders With Traumatic Anterior Instability. Am J Sports Med. 2019;47(3):695-703. doi:10.1177/0363546518819471
32. Itoi E, Lee S-B, Amrami KK, Wenger DE, An K-N. Quantitative Assessment of Classic Anteroinferior Bony Bankart Lesions by Radiography and Computed Tomography. Am J Sports Med. 2003;31(1):112-118. doi:10.1177/03635465030310010301
33. Vopat BG, Cai W, Torriani M, et al. Measurement of Glenoid Bone Loss With 3-Dimensional Magnetic Resonance Imaging: A Matched Computed Tomography Analysis. Arthrosc J Arthrosc Relat Surg. 2018;34(12):3141-3147. doi:10.1016/j.arthro.2018.06.050
34. Helfet AJ. Coracoid transplantation for recurring dislocation of the shoulder. J Bone Joint Surg Br. 1958;40-B(2):198-202. http://www.ncbi.nlm.nih.gov/pubmed/13539102. Accessed March 4, 2019.
35. Latarjet M. Treatment of recurrent dislocation of the shoulder. Lyon Chir. 1954;49(8):994-997. http://www.ncbi.nlm.nih.gov/pubmed/13234709. Accessed June 8, 2018.

36. Haaker RG, Eickhoff U, Klammer HL. Intraarticular autogenous bone grafting in recurrent shoulder dislocations. Mil Med. 1993;158(3):164-169. http://www.ncbi.nlm.nih.gov/pubmed/8487969. Accessed March 4, 2019.
37. Warner JJP, Gill TJ, O'Hollerhan JD, Pathare N, Millett PJ. Anatomical glenoid reconstruction for recurrent anterior glenohumeral instability with glenoid deficiency using an autogenous tricortical iliac crest bone graft. Am J Sports Med. 2006;34(2):205-212. doi:10.1177/0363546505281798
38. Weng P-W, Shen H-C, Lee H-H, Wu S-S, Lee C-H. Open reconstruction of large bony glenoid erosion with allogeneic bone graft for recurrent anterior shoulder dislocation. Am J Sports Med. 2009;37(9):1792-1797. doi:10.1177/0363546509334590
39. Provencher MT, Ghodadra N, LeClere L, Solomon DJ, Romeo AA. Anatomic osteochondral glenoid reconstruction for recurrent glenohumeral instability with glenoid deficiency using a distal tibia allograft. Arthroscopy. 2009;25(4):446-452. doi:10.1016/j.arthro.2008.10.017
40. Tokish JM, Fitzpatrick K, Cook JB, Mallon WJ. Arthroscopic distal clavicular autograft for treating shoulder instability with glenoid bone loss. Arthrosc Tech. 2014;3(4):e475-81. doi:10.1016/j.eats.2014.05.006
41. Dawson J, Fitzpatrick R, Carr A. Questionnaire on the perceptions of patients about shoulder surgery. J Bone Joint Surg Br. 1996;78(4):593-600. http://www.ncbi.nlm.nih.gov/pubmed/8682827. Accessed September 30, 2018.
42. Dawson J, Hill G, Fitzpatrick R, Carr A. The benefits of using patient-based methods of assessment. Medium-term results of an observational study of shoulder surgery. J Bone Jt Surg Br. 2001;83(6):877-882.
43. Othman A, Taylor G. Is the constant score reliable in assessing patients with frozen shoulder? 60 shoulders scored 3 years after manipulation under anaesthesia. Acta Orthop Scand. 2004;75(1):114-116. doi:10.1080/00016470410001708230
44. Nederlandse Orthopaedische Vereniging. Acute primaire schouderluxatie: diagnostiek en behandeling. 2005. file:///C:/Users/tdber/Desktop/Literatuur schouder/cbo richtlijn Acute primaire schouderluxatie.pdf. Accessed May 7, 2019.
45. Osmond-Clarke H. Habitual dislocation of the shoulder; the Putti-Platt operation. J Bone Joint Surg Br. 1948;30B(1):19-25. http://www.ncbi.nlm.nih.gov/pubmed/18864942. Accessed May 8, 2019.
46. te Slaa RL, Wijffels MPJM, Marti RK. Questionnaire reveals variations in the management of acute first time shoulder dislocations in the Netherlands. Eur J Emerg Med. 2003;10(1):58-61. doi:10.1097/01.mej.0000043844.56375.5b
47. McCulloch P. Developing appropriate methodology for the study of surgical techniques. J R Soc Med. 2009;102(2):51-55. doi:10.1258/jrsm.2008.080308
48. McCulloch P, Altman DG, Campbell WB, et al. No surgical innovation without evaluation: the IDEAL recommendations. Lancet. 2009;374(9695):1105-1112. doi:10.1016/S0140-6736(09)61116-8
49. van Bodegom-Vos L, Voorn VM, So-Osman C, et al. Cell Salvage in Hip and Knee Arthroplasty. J Bone Jt Surgery-American Vol. 2015;97(12):1012-1021. doi:10.2106/JBJS.N.00315
50. Voorn VMA, Marang-van de Mheen PJ, van der Hout A, et al. The effectiveness of a de-implementation strategy to reduce low-value blood management techniques in primary hip and knee arthroplasty: a pragmatic cluster-randomized controlled trial. Implement Sci. 2017;12(1):72. doi:10.1186/s13012-017-0601-0
51. Sedrakyan A, Campbell B, Merino JG, Kuntz R, Hirst A, McCulloch P. IDEAL-D: a rational framework for evaluating and regulating the use of medical devices. BMJ. 2016;353:i2372. doi:10.1136/bmj.i2372

52. Valstar ER, Gill R, Ryd L, Flivik G, Börlin N, Kärrholm J. Guidelines for standardization of radiostereometry (RSA) of implants. Acta Orthop. 2005;76(4):563-572. doi:10.1080/17453670510041574
53. Nelissen RGHH, Pijls BG, Kärrholm J, Malchau H, Nieuwenhuijse MJ, Valstar ER. RSA and registries: the quest for phased introduction of new implants. JBJS. 2011;93(Supplement_3):62-65.

10

Chapter 10

Dankwoord

Eenieder die betrokken is geweest bij de totstandkoming van mijn proefschrift wil ik bedanken voor alle hulp in de afgelopen jaren. Dit geldt ook voor alle patiënten die hebben deelgenomen aan de studies. Een aantal mensen wil ik graag in het bijzonder noemen:

Hooggeleerde Prof. Dr. R.G.H.H. Nelissen, promotor, beste Rob, dank voor je vertrouwen en steun in met name de afronding van mijn proefschrift over de chirurgische behandeling van posttraumatische schouder instabiliteit in Nederland. Promoveren, op dit onderwerp in Leiden zie ik als een enorm voorrecht.

Weledelzeergeleerde Dr. B.C.H. van der Wal, co-promotor en oud-collega uit Amersfoort, beste Bart, je inzet voor mijn onderzoek, gecombineerd met je positiviteit en je relativeringsvermogen bewonder ik tot op de dag van vandaag. Altijd was je beschikbaar voor advies en heb je me geprikkeld door je wekelijkse telefoontjes en WhatsApp berichten om verder te gaan en te kijken naar het einddoel: mijn promotie! Hartelijk dank voor het vertrouwen in mij en je support voor mijn proefschrift.

Aanvullend klinisch werk werd mede verricht door een aantal arts-assistenten die de afgelopen jaren vanuit het Meander en UMCU mij hebben geholpen en gemotiveerd: Timon Geurkink en Koen Willemsen. Beiden dank ik voor de gezellige aanwezigheid in de anatomie kelders van het UMCU en voor de inzet en hulp tijdens de laatste twee studies.

De leden van de Promotiecommissie, bestaande uit Prof. Dr. I.B. Schipper, Prof. Dr. R.L. Diercks en Dr. A. van Noort wil ik bedanken voor de tijd die zij hebben genomen voor het doornemen en kritisch beoordelen van het manuscript.

Mijn eigen collega's van de sectie orthopedie & traumatologie in Amersfoort wil ik bedanken voor hun geduld en bereidheid om soms (financieel) deel te nemen aan schouder studies in onze dagelijkse praktijk in het Meander medisch centrum.

Mijn beide paranimfen:

Beste Beer, ik ben blij en trots dat jij als oudste van vier broers mijn paranimf wil zijn. Ondanks alle drukte, zowel privé maar zeker ook in deze gekke "corona-tijd" in je werk als longarts in België, weet ik dat jij er voor mij zal zijn en dat ik altijd op je kan rekenen. Bedankt hiervoor.

Beste Michiel, wat een mooie tijd hebben we samen gehad tijdens onze vooropleiding Heelkunde in Dordrecht. Dit heeft zich gelukkig voortgezet privé, maar ook binnen ons werk als orthopedisch chirurg, jij nu in Venlo/Venray en ik in Amersfoort. Ik ben ongelofelijk blij met je als vriend en als "amice collega".

Het laatste richt ik me tot mijn familie:

Als eerste wil ik mij richten tot mijn vader, die dit helaas niet meer mag meemaken. Ik weet zeker dat hij deze dag voor geen goud had willen missen. Bedankt voor de motivatie en de liefde die je mij gegeven hebt. Oneindig blij en trots ben ik op mijn moeder en broers: Toos, Berend-jan, Jurriaan, Roderik en Wijnand. Ik voel mij zeer bevoorrecht door jullie steun en aanwezigheid.

Lieve Bente, Julius, Boris en Mats, eindelijk is het klaar. Vaak hoorde ik: zit je nu alweer achter de computer of ben je nu alweer aan het werk? Jullie zijn mijn alles, ik ben trots op jullie.

Lieve Charlotte, zonder jou was het zeker niet gelukt. Ik dank je voor je onvoorwaardelijke steun, geduld en liefde. Naast de kinderen, onze honden, je sturing in de werkzaamheden op school en rond de sportvelden was en ben jij altijd weer het middelpunt in ons gezin. Jouw schouders hebben mij in de afgelopen 18 jaar vele kansen geboden. Ik ben waanzinnig trots op je.

11

Chapter 11

Curriculum vitae

Thomas Berendes was born in Leiden on the 17th of March in 1975. He grew up in a medical family in Nuenen and attended High School at Lorentz Lyceum in Eindhoven. After graduating in 1993, he went to Leuven (Belgium) were he started his medical carrier. In 1995, he served the Medical Troops Regiment being part of the Royal Dutch Army in Schaarsbergen. After that, he completed his Medical School at Utrecht University in 2002.

His enthusiasm for orthopaedic surgery arose during his internship of Orthopaedics and Traumatology at Universitair Ziekenhuis Pellenberg and Gasthuisberg, Leuven (Belgium) in 2001.

His first job as a doctor was at the orthopaedic department in Erasmus medical centre (Rotterdam) and later on Reinier de Graaf Gasthuis (Delft). The research on the open modified Bankart procedure started at this department under supervision of late dr. Ron te Slaa, serving as the prime initiator for this thesis.

In 2005, Thomas started his orthopaedic residency at the department of general surgery at Albert Schweitzer Ziekenhuis (Dordrecht), followed by the orthopaedic departments of Leiden University centre and Reinier de Graaf Gasthuis. During this period Thomas continued his research on shoulder pathology, evaluating management of acute first-time anterior shoulder dislocation and persisting instability problems amongst Dutch public hospitals, soon after the introduction of the Dutch national guideline on Shoulder dislocations in 2005.

Immediately afterwards his residency period, Thomas started working as a staff member at the department of Orthopaedics and Traumatology at Meander medical centre (Amersfoort), where he performed as a general orthopaedic surgeon in the first years. Later on, Thomas started focussing more on shoulder pathology being a team member of the shoulder & elbow section. In this period, he continued his research on the open modified Bankart procedure (long term follow-up) and wrote a review on labral pathologies for the human shoulder and hip joint. At the same time, he participated in a biomechanical study on human shoulders looking for a novel treatment for anterior shoulder instability for patients having significant glenoid bone loss, under supervision of promotor Prof. dr. Rob Nelissen (LUMC) and co-promotor dr. Bart van der Wal (UMCU), resulting in a publication at the journal of American journal of Bone and Joint surgery and the Dutch Shoulder and Elbow science prize 2019 (Zeist).

Thomas married Charlotte in 2005 and they have four children together: Bente, Julius, Boris and Mats. They live in Soest, where Thomas enjoys going to work every day.

12

Chapter 12

List of publications
Milestones

List of publications

- Large local variations in endothelial nitric oxide synthase along human atherosclerotic coronary arteries: a post mortem study.
  Eur Heart J. 2000 (21 abstract suppl); 271.
  AH Schoneveld, D de Kleijn, **TD Berendes**, G Pasterkamp, C Borst.

- The open modified Bankart procedure: outcome at 10-15 years follow up.
  J Bone Joint Surg Br. 2007 Aug; 89(8):1064-8.
  doi: 10.1302/0301-620X.89B8.19280.
  TD Berendes, H Verburg, R Wolterbeek, R te Slaa.

- Splenic abscesses caused by a reptile associated Salmonella infection.
  Dig Surg. 2007; 24(5):397-9. Epub 2007 Aug 29.
  doi: 10.1159/000107718.
  TD Berendes, JM Keijman, L te Velde, R Oostenbroek.

- A woman with right-sided lower abdominal pain due to intussusception of the appendix.
  Ned Tijdschr Geneeskd Nov 2008;152(47):2571-4.
  PMID: 19174940
  TD Berendes, F van der Straaten

- A boy with an unusual soccer injury.
  Ned Tijdschr Geneeskd 2010, 154(47): A1637.
  PMID: 21118598
  TD Berendes, J Nagels.

- Validation of the Dutch version of the Oxford Shoulder Score.
  Journal of Shoulder and Elbow Surgery, 2010 Sep; 19(6):829-36.
  doi:10.1016/j.jse.2010.01.017. Epub 2010 Apr 24.
  TD Berendes, P Pilot; J Willems; H Verburg; R te Slaa.

- Survey on the management of acute first-time anterior shoulder dislocation amongst Dutch public hospitals.
  Archives of Orthopaedic Trauma Surgery. 2015 Apr;135(4):447-54.
  doi: 10.1007/s00402-015-2156-3. Epub 2015 Feb 21.
  TD Berendes, P Pilot, J Nagels, AJ Vochteloo, RG Nelissen.

- The open-modified Bankart procedure: long-term follow-up (16-26-years).
  Archives of Orthopaedic Trauma Surgery. 2018 May;138(5):597-603.
  doi: 10.1007/s00402-017-2866-9.
  TD Berendes, N Mathijssen, H Verburg, G Kraan.

- Labral (pathologic) Similarities for the Human Shoulder and Hip Joint.
  Open Access J Ortho. 2018; 1:101.
  TD Berendes, T Geurkink, K Willemsen, H Weinans, RM Castelein, RG Nelissen, B van der Wal.
- A novel treatment for anterior shoulder instability: A biomechanical comparison between a patient-specific implant and the Latarjet procedure.
  JBJS Am 2019, Jul 17; 101(14)e68.
  doi: 10.2106/JBJS.18.00892.
  K Willemsen, **TD Berendes**, T Geurkink, R Bleys, H Weinans, RG Nelissen, B van der Wal.
- Early results of a novel treatment technique with autologous blood for chronic lateral epicondylitis.
  Journal of Shoulder and Elbow Surgery *submitted* May 2020.
  M Coopmans, H Sonneveld, **TD Berendes**.

Specific milestones

- Shoulder and Elbow science prize 2019, Slot Zeist, Netherlands
- Presentation NOV congress 2018, Den Bosch, Netherlands
- Presentation 19th congress Secec Esse 2005, Rome, Italy
- Presentation ROGO leiden
- Presentation NOV congress 2009, Utrecht, Netherlands
- Presentation Shoulder and Elbow working group, Nieuwegein, Netherlands
- Poster presentation 21nd congress Secec Esse 2008, Brugge, Belgium

Fixed milestones

- BROK-course 2018, Amersfoort, Netherlands
- Trauma registration NOV 2020