



Universiteit  
Leiden  
The Netherlands

## **Medication related osteonecrosis of the jaws (MRONJ): Diagnosis and treatment**

Pichardo, S.E.C.

### **Citation**

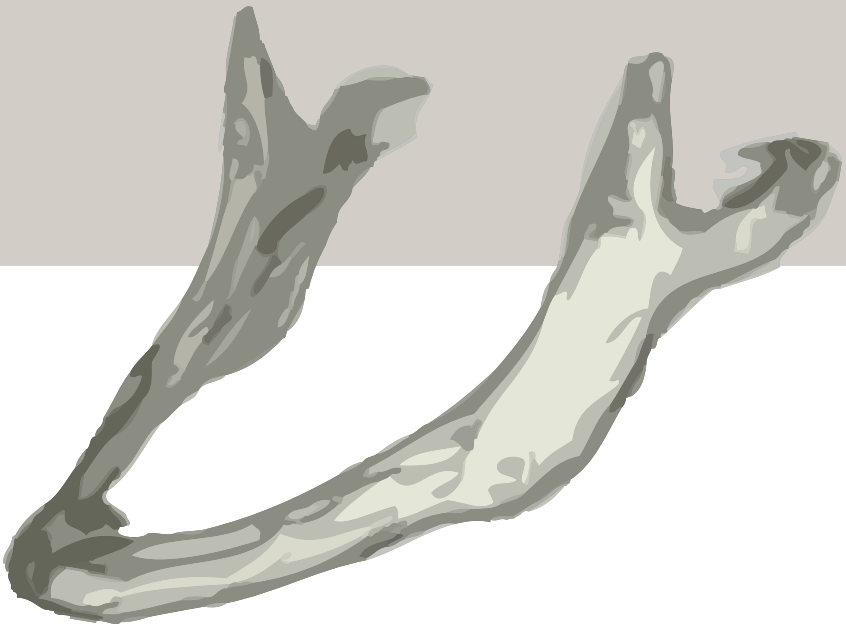
Pichardo, S. E. C. (2020, September 22). *Medication related osteonecrosis of the jaws (MRONJ): Diagnosis and treatment*. Retrieved from <https://hdl.handle.net/1887/136855>

Version: Publisher's Version

License: [Licence agreement concerning inclusion of doctoral thesis in the Institutional Repository of the University of Leiden](#)

Downloaded from: <https://hdl.handle.net/1887/136855>

**Note:** To cite this publication please use the final published version (if applicable).



Part II

# TREATMENT



Bisphosphonate-related  
osteonecrosis of the jaws:  
Cohort study of surgical  
treatment results in seventy-  
four stage II/III patients.

*J Craniomaxillofac Surg.* 2016 Sep;44(9):1216-20

Pichardo SE

Kuypers SCC

Van Merkesteyn JPR

## ABSTRACT

### INTRODUCTION

Bisphosphonates are used in the treatment of osteoporosis and bone metastases. They inhibit osteoclast function, thereby decreasing bone resorption. A side effect of these drugs is bisphosphonate-related osteonecrosis of the jaw (BRONJ), which can be difficult to treat. The purpose of this study was to evaluate the surgical treatment protocol used in our hospital for BRONJ patients. The patients were retrospectively analyzed and followed-up at the Leiden University Medical Center.

### METHODS

All patients who were referred to our hospital with therapy-resistant BRONJ between 2003 and 2014 were seen. At first presentation, the clinical features, medical and dental history, bisphosphonate use, and the use of other medications were recorded. Patients underwent surgical intervention, performed by senior surgeons, following the principles of our previously published protocol.

### RESULTS

Seventy-four patients were followed-up for 6-96 months. Curation was successful with this surgical approach in 93.2% of the patients.

### DISCUSSION

All the patients were cured with our surgical protocol, for up to 5 years after surgery. We conclude that this treatment protocol has a high success rate in treating all stages of BRONJ.

## INTRODUCTION

Bisphosphonates are medications used to treat osteoporosis and bone metastases. They decrease bone resorption by inhibiting the resorption function of the osteoclasts, and by causing apoptosis of the osteoblasts. In addition, they reduce pain, and resolve hypercalcemia in bone-metastasized cancer. Bisphosphonates are reported to have side effects, mainly gastrointestinal complaints. However, a rare but more severe side effect is the risk of developing bisphosphonate-related osteonecrosis of the jaw (BRONJ). Many authors have claimed BRONJ to be difficult to treat. The first cases were reported in 2003<sup>1</sup>. Although several reports have since been published, the exact pathogenesis remains unclear. While some authors state that it has a spontaneous origin<sup>2-4</sup>, others claim that it has a dental or a traumatic etiology<sup>5-8</sup>. Despite the difference in opinions on the etiology of BRONJ, the treatment recommendations are either, 1) non-invasive approaches<sup>9,10</sup>, which involve treatment with antibiotics, or a chlorhexidine mouth rinse, or removal of loosened sequestra, or 2) invasive approaches with sometimes aggressive surgical methods that often involve resection of large parts of the jaw with free-flap osseous reconstructions. BRONJ, if untreated at an early stage, involves worsening of the symptoms with possibly serious consequences such as pathological fractures<sup>9,11,12</sup>. Recently more authors have promoted early surgical intervention<sup>13-17</sup>.

The initial BRONJ patients in our institution were treated with a simple surgical intervention based on the treatment of chronic suppurative osteomyelitis (CSO) of the jaws. These patients seemed to respond very well to this treatment<sup>18,19</sup>. This treatment was based on the treatment of chronic suppurative osteomyelitis, which has a dental cause<sup>19</sup>. As mentioned earlier, BRONJ seems to show a dental cause, thereby strongly suggesting a similar pathogenesis of BRONJ and CSO. We believe that early surgical intervention produces the best treatment results in BRONJ. Therefore, the purpose of this study was to evaluate our combined surgical and antimicrobial method of BRONJ patients. Secondary outcomes were to characterize the patients by investigating clinical features, medication use, (dental) history and (previous) treatment.

## METHODS

In this cohort study, consecutive patients referred from other clinics, presenting with therapy-resistant BRONJ, were treated and retrospectively analyzed. The study population consisted of all patients presenting for evaluation of BRONJ between January 2003 and December 2014 in the department of Oral & Maxillofacial Surgery of the Leiden University Medical Center. At presentation, the clinical features, medical and dental history, bisphosphonate use, and the use of other medications were noted.

The inclusion criterion for this study was a BRONJ diagnosis according to the criteria stated by the American Association of Oral and Maxillofacial Surgeons (AAOMS)<sup>2</sup>. This implies a recent use of bisphosphonates, the presence of exposed or necrotic bone in the oral cavity for more than 8 weeks, and no history of radiation therapy to the jaws. Further, a minimum bisphosphonate use of at least 12 months intravenously or 24 months orally was necessary for inclusion. The patients who used both oral and intravenous (IV) bisphosphonates were considered as IV users, for the purpose of this study.

The first aim of this study was to observe the result of our combined surgical and antimicrobial treatment.

Curation was classified as present or absent and defined as a situation with no complaints, and the presentation of a healed, closed mucosa. Additionally healing was classified as ideal if there was a closed mucosa within 2 weeks of surgery and non-ideal if a closed mucosa was reached after this amount of time or if needed an extra intervention (antibiotics or surgery). The patients were followed-up for at least 6 months: weekly in the first postoperative month; monthly, a month after; every 3 months, after 3 months post-surgery, up to a maximum of 5 years. During the follow-up the main focus was on the mucosa, and whether dehiscence or recurrence of the exposed bone had developed.

Secondary aims were to characterize the patients with BRONJ. Variables studied consisted of sex, age, bisphosphonate indication, duration of bisphosphonate use and administration manner. The duration of complaints and other medication (immunosuppressants, steroids, cytostatics) were studied. Clinical features (location and stage), dental history (luxating moment) and (previous) treatment were investigated. The collected data were statistically analyzed with SPSS.

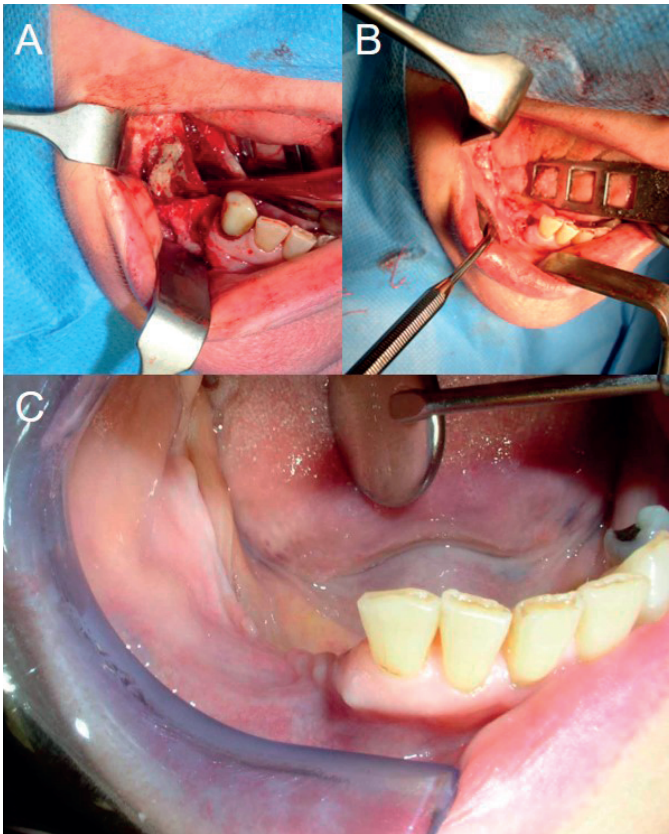
At presentation, panoramic radiographs were taken of all the patients to localize the lesion, and to gain a first impression of the lesion. Then, a computed tomography (CT) scan was used to determine the extent of the defect. The clinical features and the radiological findings, together, defined the stage of BRONJ, based on the AAOMS classification<sup>10</sup> (Table I). The patients with an absence of any radiological findings on the X-ray or CT scan, but with clinical bone exposure, were categorized as stage I. Radiological findings on the CT scans such as osteolysis and sequestra in the alveolar process were categorized as stage II. Osteolysis in large parts of the jaws or pathologic fractures was categorized as stage III.

The patients underwent surgical intervention as reported before<sup>18,19</sup>. Surgery was performed by senior surgeons. The surgical approach consisted of the removal of the sequestra, thorough surgical removal and saucerization of the non-vital bone until reaching the bleeding bone margins, and closing the defect primarily in layers (Fig. 1). This meant closing the periosteum as close to the bone as possible with mattress sutures, leaving no or as little dead-space as possible when



**Table I** Classification Stages BRONJ and recommendations by Ruggiero et al., 2009 (AAOMS)<sup>2</sup>.

BRONJ stage	Description	Treatment strategies
At risk category	No apparent necrotic bone in patients who have been treated with either oral or IV bisphosphonates	No treatment Patient education
Stage 0	No clinical evidence of necrotic bone, but nonspecific clinical findings and symptoms	Systemic therapies including pain medications and antibiotics
Stage I	No symptomatic lesions or bone exposure in the absence of signs of infection	Topical antiseptic therapy Follow-up
Stage II	Bone exposure with pain, infection, and swelling in the area of the lesion	Oral antibiotics, antibacterial mouth rinse, pain control Superficial debridement to relieve soft tissue irritation
Stage III	Bone exposure, pain, inflammation, maxillary sinus involvement, cutaneous fistulas, and pathological fractures	Antibacterial mouth rinse Antibiotic therapy and pain control Surgical debridement and resection for longer term palliation of infection and pain

**Figure 1** Surgery

A: Preoperative sequestra and persistent extraction socket, B: Defect closed primarily in layers, C: Six months post-operation.

closing the overlying mucosa in layers. During the surgery, no gastric tube was placed, culture samples were collected, and the resected bone was submitted for histopathological analysis.

The surgical treatment was supplemented by the administration of the antibiotics, penicillin G and metronidazole, intravenously for 1 week, and amoxicillin and metronidazole, orally for 3 weeks.

Panoramic radiographs were taken immediately after surgery, and every 3–6 months, for up to 1-year after the surgery, in order to monitor the condition of the bone margins and the healing of the bone. After 1-year, an annual radiographic follow-up was considered sufficient.

Overlying dentures were not allowed during the first 12 weeks in order to avoid pressure and damage to the mucosa, which could lead to dehiscence of the wound. The patients were instructed to maintain a liquid diet postoperatively for 2 weeks, and were permitted a soft diet after that period.

## RESULTS

Seventy-four patients were included in this retrospective cohort study. These patients were surgically treated and followed-up for 6–96 months.

### Patient characteristics (Table II)

Most patients (56.7%;  $n = 42$ ) had osteoporosis as an indication for bisphosphonate use. In this group, 26 patients used bisphosphonates because of the use of steroids such as prednisolone (in cases of rheumatoid arthritis). The most common malignancies ( $n = 30$ ) were breast cancer (60.0%;  $n = 18$ ), prostate cancer (16.7%;  $n = 5$ ), and multiple myeloma (20.2%;  $n = 6$ ).

The clinical features are listed in Table 1. The ages of the female (83.8%;  $n = 62$ ) and the male (16.2%;  $n = 12$ ) patients varied from 26 to 91 years, with a mean of 67.9 years.

BRONJ was located in the maxilla in 11 patients, in the mandible in 58 patients, and in both the jaws in 5 patients. Fifty-two patients were found to have stage III disease, and 22, stage II.

Oral bisphosphonates had been used in 40 cases, with a minimum of 24 months and a maximum of 120 months (mean = 68.0). Intravenous bisphosphonates had been used in 34 cases, including both oral and intravenous use ( $n = 6$ ), with a minimum of 12 months and a maximum of 96 months (mean = 31.2 months). In 45 patients, steroids, such as prednisone, or methotrexate were used as co-medication.

**Table II** Clinical features

Gender	Male	62	74
	Female	12	
Indication	Osteoporosis	42	74
	Multiple Myeloma	6	
	Prostate Cancer	5	
	Breast cancer	18	
	Other	3	
Intravenous use	Zoledronic acid	10	34
	Pamidronic acid	24	
Oral use	Alendronic acid	30	40
	Risedronic acid	9	
	Ibandronic acid	1	
Co-medication	None	29	45
	Steroids	19	
	Immunosuppressants	5	
	Cytostatics	11	
	Combination	10	
Location	Mandible	58	74
	Maxilla	11	
	Both	5	
Luxating moment	Extraction	54	74
	Implants	10	
	Pressure soar	4	
	Other dental cause (periodontitis, apical pathology)	6	

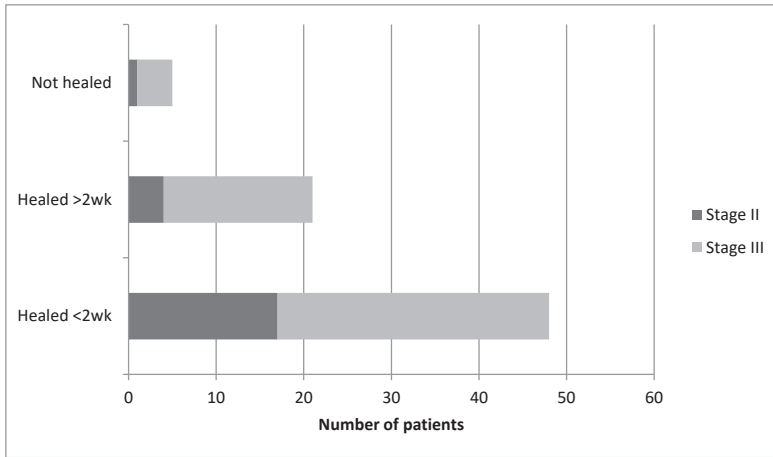
The luxating moments of the BRONJ were mainly extractions (73.0%; n = 54), implants (13.5%; n = 10), and pressure sores due to ill-fitting dentures (5.4%; n = 4). All BRONJ were retraceable to a dental surgery/origin.

### Surgical outcome

The majority of patients (n = 72) were treated under general anesthesia. After the surgery, all patients were followed-up for at least 6 months. In 69 patients (93.2%), curation was achieved by the senior surgeons using our previously established surgical approach (Table III). Of these, curation was achieved within 2 weeks (ideal healing) in 48 patients (31 cases of stage III). They presented a healed and closed mucosa with no pain or complaints.

During the follow-up, these patients had no extraordinary pain or recurrences. All panoramic radiographs taken during the follow-up showed an ingrowth of bone, without further osteolysis.

**Table III** Treatment results.



Healing:  
 ideal <2wks (n=48);  
 not ideal >2wks (n=21);  
 not healed (n=5)

Of these patients, 28 were using co-medications such as prednisolone, immunosuppressants, and cytostatics.

There were 21 patients (17 cases of stage III) who were not cured within 2 weeks. They all presented with small dehiscences or fistulae that were initially treated with antibiotics. Six patients were cured within a few weeks with an extended use of antibiotics. Thirteen patients still needed a minor second surgery. This involved a small curettage, and sequestrectomy under local anesthesia. Treatment under general anesthesia in this group was necessary in only a few cases. Of the patients with non-ideal healing, 53.9% (n = 14) were using co-medication.

Five patients were not cured. In one patient, a reconstruction plate had been placed, and the plate was visible intraorally. This patient died before another surgery. The other patients had small non-producing fistulas or dehiscences with no other complaints, despite antibiotics or a second surgery.

Four patients died of metastases. The remainder of the patients reported an acceptable quality of life following the first surgery, and therefore, refused any more surgery during the follow-up.

## DISCUSSION

In this study consecutive patients, referred from other clinics, presenting with therapy-resistant BRONJ, were treated and retrospectively analyzed. Secondary aims were to characterize the patients by investigating sex, age, medication use, medical and dental history, (previous) treatment and the duration of complaints.

This study demonstrates that our surgical method, reported earlier<sup>18,19</sup>, leads to curation in a high number (93.2%) of BRONJ patients without serious adverse events in the affected area. Our results are consistent with those of other recent reports<sup>13-17</sup>. These authors seem to have achieved, more or less, the same rate of healing with comparable surgical intervention. Removing the infected and non-vital bone thoroughly, closing the defect with vital periosteum, leaving as little dead-space as possible, and then closing in layers, allows the bone to be fully covered, and gives it the opportunity to heal under the most optimal conditions, thus increasing the chances for curation. The wound is more prone to dehiscences and delayed healing if the mucosa is not closed in layers.

Of the 74 patients, 45 used co-medication. Although it was expected that the use of co-medication such as steroids, immunosuppressants, and cytostatics could have a negative influence on bone healing<sup>20-23</sup>, we did not find any significant difference in bone healing ( $P = 0.366$ ) between the co-medication users and the non-users. We did see a tendency towards worse outcomes since four of the five patients with dehiscences were on co-medication, but of the 26 patients who did not have ideal healing, only 14 used co-medication. There is a tendency in co-medication cases to exhibit less than ideal outcomes. However, in contrast to previous reports<sup>20,22</sup>, we have not found a significant difference to establish that as a fact.

Another reason for dehiscences and the necessity for secondary procedures could be the advanced stage (stage III) of the BRONJ disease. In the non-ideal healing group, 16 of the 21 patients had stage III, and only five had Stage II BRONJ. Previous reports, and even the AAOMS, recommend large resections for stage III disease. However, we were able to cure most of our patients by a conservative surgical treatment with thorough saucerization of the bone. Despite the conservative surgery, no significant difference in healing was found between the stage III and stage II cases ( $P = 0.146$ ).

We noticed more mandibular cases than maxillary or bimaxillary cases. This is probably because the maxilla contains less cortical bone, and has a better vascularization than the mandible. However, its ability to heal was not significantly better, since the non-ideal group was even in the number of maxillae and mandibles.

The duration of bisphosphonate use and the duration of complaints were both not significant factors in the outcome. These values were comparable not only in both the closed and open groups, but also in the ideal and non-ideal group.

In contrast to some reports<sup>24</sup>, an association between the healing and the type of bisphosphonates, or the mode of administration ( $P = 0.157$ ) could not be found. The results of the comparison between the two variables were the same. Even zoledronic acid seemed to have a comparable outcome, as did alendronic acid or pamidronic acid. This could be, because once the bone is saturated with bisphosphonates, the result is similar.

There is still a lot of discussion on the treatment of BRONJ. However, a majority of the reports express reservations about surgical treatment. Some authors report worsening of symptoms, pathological fractures or even loss of parts of the jaw upon surgical treatment<sup>9-11</sup>. Although, treating the patients with only mouth-rinses or antibiotics might reduce the symptoms, and provide temporary relief, it will not resolve the problem. Instead, this may lead to a larger, therapy-resistant osteonecrosis, which will be difficult to treat. There are several examples in the literature, of the worsening of BRONJ in inadequately-treated patients<sup>12,17,25</sup>. Treatment under local anesthesia showed a tendency to lead to a second surgery under general anesthesia. This may be due to the fact that, under local anesthesia, thorough treatment with adequate saucerization could be more difficult.

Given these results and the ongoing debate on the treatment of BRONJ, our focus should change towards a better prevention of dental problems before starting with bisphosphonate treatment. In addition since the exact pathogenesis of BRONJ is still unknown, further research is mandatory.

## CONCLUSION

The high success rate of the combined surgical and antimicrobial treatment in this study, the relative long follow-up, and the fact that our findings are consistent with literature suggests that this combined surgical and antibiotic protocol is the treatment of choice at all stages of BRONJ. Hence, our results are of clinical relevance in the ongoing debate about the treatment of BRONJ.

## REFERENCES

1. Marx RE: Pamidronate (Aredia) and zoledronate (Zometa) induced avascular necrosis of the jaws: a growing epidemic. *J Oral Maxillofac Surg* 61:1115-1117, 2003.
2. Ruggiero SL, Dodson TB, Assael LA, Landesberg R, Marx RE, Mehrotra B: American Association of Oral and Maxillofacial Surgeons: American Association of Oral and Maxillofacial Surgeons position paper on bisphosphonate-related osteonecrosis of the jaws--2009 update. *J Oral Maxillofac Surg* 67:2-12, 2009.
3. Badros A, Terpos E, Katodritou E, Goloubeva O, Kastritis E, Verrou E, Zervas K, Baer MR, Meiller T, Dimopoulos MA. Natural history of osteonecrosis of the jaw in patients with multiple myeloma. *J Clin Oncol*. 2009;26:5904-5909.
4. Estilo CL, Van Poznak CH, Williams T, Bohle GC, Lwin PT, Zhou Q, Riedel ER, Carlson DL, Schoder H, Farooki A, Fornier M, Halpern JL, Tunick SJ, Huryn JM. Osteonecrosis of the maxilla and mandible in patients with advanced cancer treated with bisphosphonate therapy. *Oncologist*. 2008;13:911-920.
5. Bamias A, Kastritis E, Bamia C, Mouloupoulos LA, Melakopoulos I, Bozas G, Koutsoukou V, Gika D, Anagnostopoulos A, Papadimitriou C, Terpos E, Dimopoulos MA: Osteonecrosis of the jaw in cancer after treatment with bisphosphonates: incidence and risk factors. *J Clin Oncol* 23:8580-8587, 2005.
6. Bedogni A, Blandamura S, Lokmic Z, Palumbo C, Ragazzo M, Ferrari F, Tregnaghi A, Pietrogrande F, Procopio O, Saia G, Ferretti M, Bedogni G, Chiarini L, Ferronato G, Ninfo V, Lo Russo L, Lo Muzio L, Nocini PF: Bisphosphonate-associated jawbone osteonecrosis: a correlation between imaging techniques and histopathology. *Oral Surg Oral Med Oral Pathol Oral Radiol Endod* 105:358-364, 2008.
7. Otto S, Schreyer C, Hafner S, Mast G, Ehrenfeld M, Stürzenbaum S, Pautke C. Bisphosphonate-related osteonecrosis of the jaws - characteristics, risk factors, clinical features, localization and impact on oncological treatment. *J Craniomaxillofac Surg*. 2012 Jun;40(4):303-9
8. Pichardo SE and Van Merkesteyn JPR. Bisphosphonate related osteonecrosis of the jaws: spontaneous or dental origin? *Oral Surg Oral Med Oral Pathol Oral Radiol*. 2013 Sep;116(3):287-92
9. Marx RE, Sawatari Y, Fortin M, Broumand V. Bisphosphonate-induced exposed bone (osteonecrosis/osteopetrosis) of the jaws: risk factors, recognition, prevention, and treatment. *J Oral Maxillofac Surg*. 2005;63:1567-1575
10. Ruggiero SL, Dodson TB, Fantasia J, Goodday R, Aghaloo T, Mehrotra B, O’Ryan F: American Association of Oral and Maxillofacial Surgeons: American Association of Oral and Maxillofacial Surgeons position paper on medication-related osteonecrosis of the jaw--2014 update. *J Oral Maxillofac Surg* 72:1938-1956, 2014.
11. Marx RE, Cillo JE Jr, Ulloa JJ. Oral bisphosphonate-induced osteonecrosis: risk factors, prediction of risk using serum CTX testing, prevention, and treatment. *J Oral Maxillofac Surg*. 2007;65:2397-2410.
12. Vescovi P, Campisi G, Fusco V, Mergoni G, Manfredi M, Merigo E, Solazzo L, Gabriele M, Gaeta GM, Favia G, Peluso F, Colella G: Surgery-triggered and non-surgery-triggered Bisphosphonate-related Osteonecrosis of the Jaws (BRONJ): A retrospective analysis of 567 cases in an Italian multicenter study. *Oral Oncol* 47:191-194, 2011.
13. Fliefel R, Troltsch M, Kuhnish J, Ehrenfeld M, Otto S: Treatment strategies and outcomes of bisphosphonate-related osteonecrosis of the jaw (BRONJ) with characterization of patients: a systematic review. *Int J Oral Maxillofac Surg* 44:568-585, 2015.

14. Ristow O, Otto S, Troeltzsch M, Hohlweg-Majert B, Pautke C: Treatment perspectives for medication-related osteonecrosis of the jaw (MRONJ). *J Craniomaxillofac Surg* 43:290 293, 2015.
15. Voss PJ, Joshi Oshero J, Kovalova-Müller A, Veigel Merino EA, Sauerbier S, Al-Jamali J, Lemound J, Metzger MC, Schmelzeisen R: Surgical treatment of bisphosphonate-associated osteonecrosis of the jaw: technical report and follow up of 21 patients. *J Craniomaxillofac Surg* 40:719 725, 2012.
16. Wilde F, Heufelder M, Winter K, Hendricks J, Frerich B, Schramm A, Hemprich A: The role of surgical therapy in the management of intravenous bisphosphonates-related osteonecrosis of the jaw. *Oral Surg Oral Med Oral Pathol Oral Radiol Endod* 111:153 163, 2010.
17. Williamson RA: Surgical management of bisphosphonate induced osteonecrosis of the jaws. *Int J Oral Maxillofac Surg* 39:251 255, 2010.
18. Alons K, Kuijpers SC, de Jong E, van Merkesteyn JPR: Treating low- and medium-potency bisphosphonate-related osteonecrosis of the jaws with a protocol for the treatment of chronic suppurative osteomyelitis: report of 7 cases. *Oral Surg Oral Med Oral Pathol Oral Radiol Endod* 107:e1 e7, 2009.
19. van Merkesteyn JP, Groot RH, van den Akker HP, Bakker DJ, Borgmeijer-Hoelen AM: Treatment of chronic suppurative osteomyelitis of the mandible. *Int J Oral Maxillofac Surg* 26:450 454, 1997.
20. Khan AA, Morrison A, Hanley DA, Felsenberg D, McCauley LK, O’Ryan F, Reid IR, Ruggiero SL, Taguchi A, Tetradis S, Watts NB, Brandi ML, Peters E, Guise T, Eastell R, Cheung AM, Morin SN, Masri B, Cooper C, Morgan SL, Obermayer-Pietsch B, Langdahl BL, Al Dabagh R, Davison KS, Kendler DL, Sándor GK, Josse RG, Bhandari M, El Rabbany M, Pierroz DD, Sulimani R, Saunders DP, Brown JP, Compston J: International Task Force on Osteonecrosis of the Jaw: Diagnosis and management of osteonecrosis of the jaw: a systematic review and international consensus. *J Bone Miner Res* 30:3 23, 2015.
21. Lescaille G, Coudert AE, Baaroun V, Javelot MJ, Cohen-Solal M, Berald A, Goudot P, Azérad J, Ruhin B, Descroix V: Osteonecrosis of the jaw and nonmalignant disease: is there an association with rheumatoid arthritis. *J Rheumatol* 40:781 786, 2013.
22. Nisi M, La Ferla F, Karapetsa D, Gennai S, Miccoli M, Baggiani A, Grazziani F, Gabriele M: Risk factors influencing BRONJ staging in patients receiving intravenous bisphosphonates: a multivariate analysis. *Int J Oral Maxillofac Surg* 44:586 591, 2015.
23. O’Halloran M, Boyd NM, Smith A: Denosumab and osteonecrosis of the jaws - the pharmacology, pathogenesis and a report of two cases. *Aust Dent J* 59:516 519, 2014.
24. Shintani T, Hayashido Y, Mukasa H, Akagi E, Hoshino M, Ishida Y, Hamana T, Okamoto K, Kanda T, Koizumi K, Yoshioka Y, Tani R, Toratani S, Okamoto T: Comparison of the prognosis of bisphosphonate-related osteonecrosis of the jaw caused by oral and intravenous bisphosphonates. *Int J Oral Maxillofac Surg* 44:840 844, 2015.
25. Vescovi P, Merigo E, Meleti M, Manfredi M, Fornaini C, Nammour S, Mergoni G, Sarraj A, Bagan JV: Conservative surgical management of stage I bisphosphonate-related osteonecrosis of the jaw. *Int J Dent* 2014: 107690, 2014.



