



Universiteit
Leiden
The Netherlands

Medication related osteonecrosis of the jaws (MRONJ): Diagnosis and treatment

Pichardo, S.E.C.

Citation

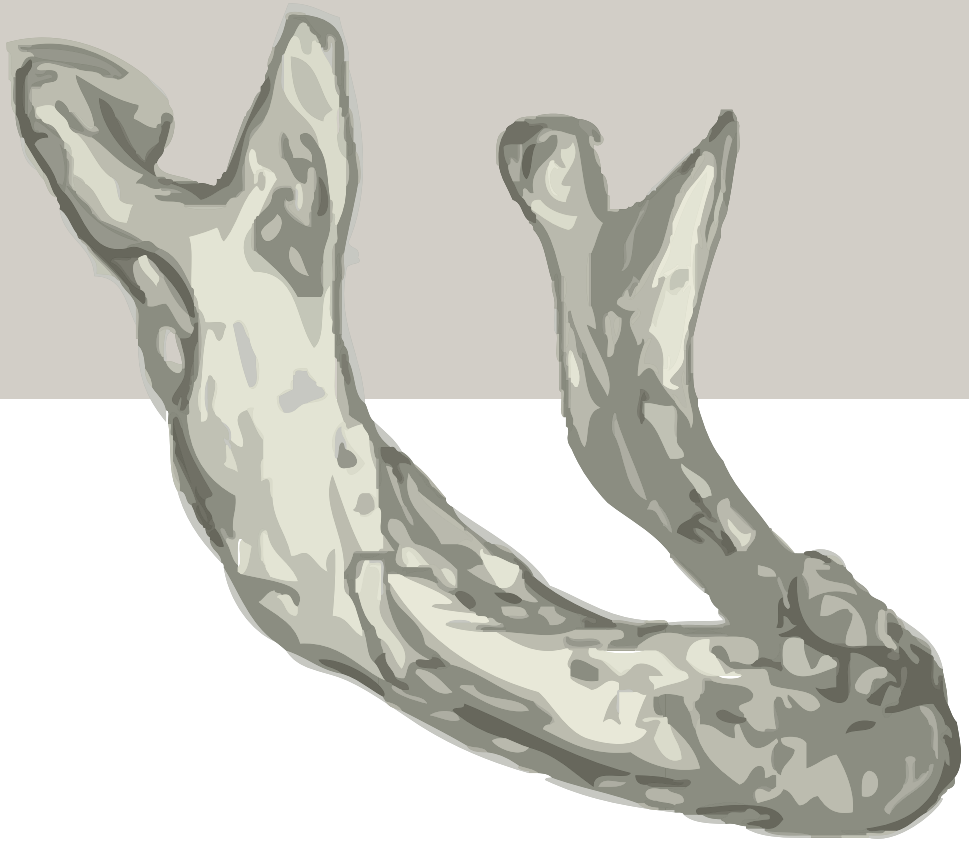
Pichardo, S. E. C. (2020, September 22). *Medication related osteonecrosis of the jaws (MRONJ): Diagnosis and treatment*. Retrieved from <https://hdl.handle.net/1887/136855>

Version: Publisher's Version

License: [Licence agreement concerning inclusion of doctoral thesis in the Institutional Repository of the University of Leiden](#)

Downloaded from: <https://hdl.handle.net/1887/136855>

Note: To cite this publication please use the final published version (if applicable).



Part I

DIAGNOSIS

| 2

Bisphosphonate related osteonecrosis of the jaws: spontaneous or dental origin?

Oral Surg Oral Med Oral Pathol Oral Radiol. 2013 Sep;116(3):287-92

Pichardo SE

Van Merkesteyn JPR

ABSTRACT

INTRODUCTION

Bisphosphonates are frequently used worldwide mostly in osteoporosis and skeletal bone metastases. However, a serious side-effect is bisphosphonate related osteonecrosis of the jaws (BRONJ). The mechanism behind BRONJ remains unclear. In literature several origins are suggested. Presence of the teeth in the jaws may play an important role. Therefore in this study 45 patients were analyzed retrospectively.

METHODS

Files of 45 patients with a diagnosis of BRONJ were analyzed, meaning clinical features, bisphosphonate use, dental history including luxating moment and (previous) treatment.

RESULTS

In 97.5% (n = 44) a certain or presumable dental focus, such as extractions, a previous dental treatment or prosthesis complaints were found as initiating factor of BRONJ.

CONCLUSION

In contrast to findings in literature, in our group of patients a dental focus was found in 44 of 45 cases. This implies a dentoalveolar start of BRONJ with subsequent spreading into the jaws in nearly all cases.

INTRODUCTION

Bisphosphonates are frequently used worldwide. There are several indications to prescribe bisphosphonates. The most important indications are osteoporosis and skeletal bone metastases in malignancies. Bisphosphonates decrease the function of osteoclasts and hence bone resorption. They stabilize the osteoporotic process, further growth and metastasizing in bone and improve complaints such as pain.

However, the use of bisphosphonates may have side effects. Most frequently described are gastrointestinal effects. In 2003 the first case of osteonecrosis of the jaw was reported¹. According to the definition of BRONJ given by the American Association of Oral and Maxillofacial Surgeons (AAOMS) patients may be considered to have BRONJ if 3 characteristics are present: current or previous treatment with a bisphosphonate, exposed, necrotic bone in the maxillofacial region that persisted for more than 8 weeks, no history of radiation therapy to the jaws². In addition, different stages of the disease according to signs of inflammation were developed (Table I).

Table I. Staging of bisphosphonate-related osteonecrosis of the jaw²

Stage	Clinical symptoms
At risk category	No apparent exposed or necrotic bone in patients who have been treated with either oral or IV bisphosphonates
Stage 0	Nonspecific clinical findings and symptoms such as jaw pain or osteosclerosis but no clinical evidence of exposed bone
Stage 1	Exposed or necrotic bone in patients who are asymptomatic and have no evidence of infection
Stage 2	Exposed or necrotic bone associated with infection as evidenced by pain and erythema in the region of the exposed bone with or without purulent drainage
Stage 3	Exposed or necrotic bone in patients with pain, infection, and one or more of the following: pathologic fracture, extra-oral fistula, or osteolysis extending to the inferior border or sinus floor

The precise mechanism of BRONJ still remains unclear. In the literature BRONJ is said to be resistant to therapy and may lead to serious loss of bone. Many authors including large dental associations as the AAOMS³, the American Dental Association^{4,5}, and the American Society of Bone and Mineral Research⁶ advise a conservative treatment, based on the fact that bisphosphonate use causes systemic changes in bone and may start spontaneously. However, since no bisphosphonate related osteonecrosis of other bones has been reported in the literature, it seems that the presence of teeth in the jaw plays an important role.

In literature there is no definition of the minimum duration of the use of oral bisphosphonates for developing BRONJ. According to the AAOMS³ the risk for developing BRONJ increases when the duration of oral bisphosphonate therapy exceeds 36 months. Marx⁷ and other authors^{8,9} include patients with a duration of oral use of at least 24 and even 128 months.

For the oral use of bisphosphonates in our group a minimum of 24 months was taken. For the use of intravenous bisphosphonates a minimum use of 12 months was taken.

In this study a distinction was made between spontaneous and dental causes of BRONJ. If the latter is the case, then treatment results could possibly be improved by using treatment used for chronic suppurative osteomyelitis (CSO), which nearly always has a dental cause. In CSO a thorough surgical intervention with primary closure in layers and an antibiotic protocol leads to good results and healing of the defect¹⁰. In the treatment of BRONJ, recent literature using this type of treatment shows also acceptable results.

METHODS

The files of 51 patients using bisphosphonates and with exposed bone of the jaws were reviewed. All patients were treated and followed in the Department of Oral and Maxillofacial Surgery of the Leiden University Medical Center. All patients were diagnosed with BRONJ according to the AAOMS definition. To be included into this study patients a minimum use of bisphosphonate for at least 12 months intravenously or 24 months orally. Considering these criteria 45 patients were included in this study.

Patient characteristics, bisphosphonate use, clinical features, dental history, and (previous) treatment were studied. Patients with a combination of oral and intravenous bisphosphonates were counted into the intravenous group.

In order to analyze the luxating moments of BRONJ, all initiating factors were categorized into 4 groups: a certain dental focus, a presumable dental focus, spontaneous and unknown.

A certain dental focus was defined as a recent dental procedure as an extraction, removal of retained roots, placing of implants, an apical inflammation or clear pre-existent periodontal problems in the region of the BRONJ.

A presumable dental focus was defined as an elevated mylohyoid ridge, a clear knife-edge ridge and (gingival) trauma caused by non-fitting dentures.

Spontaneous exposed bone was defined as no previous dental history, no previous therapy, no previous trauma, or no previous existing complaints related to dentures.

Patients were categorized as unknown dental focus when the previous history was unclear or not traceable.

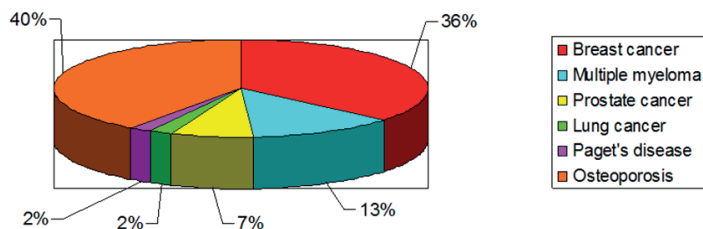
RESULTS

Patient characteristics

Most patients suffered from malignancies 57.8% (n = 26). From this group 61.6% (n = 16) had (metastasized) breast cancer, 23.1% (n = 6) had multiple myeloma, 11.5% (n = 3) had prostate

cancer and 3.8% (n = 1) had lung cancer. One patient (2.2%) had Paget's disease. Osteoporosis counted for 40.0% (n = 18) of the indications for bisphosphonate treatment (Figure 1).

Figure 1. Indications of bisphosphonate use in percentages.



The clinical characteristics of the 45 patients are listed in Table III. A total of 80.0% (n = 36) was female, 20.0% (n = 9) was male. Age varied from 45 to 84 with a mean of 66.1 years.

From 45 patients 77.8% (n = 35) had BRONJ of the mandible, 15.5% (n = 7) of the maxilla and 6.7% (n = 3) of both jaws.

Oral bisphosphonates were used in 16 cases (35.6%) with a minimum of 24 months and a maximum of 132 months and a mean of 57.3 months. Intravenous bisphosphonates were used in 29 cases (64.4%) with a minimum of 12 months and a maximum of 108 months and a mean of 30.8 months.

Table II. Features patients, indication and bisphosphonate use

Nr	Age	Sex	Indication	Bisphosphonate	Duration use	Administer manner	Location	Luxating moment	Category
1	83	F	OP	Pam	84	O	Mandible	Preprosthetic surgery	Presumable
2	84	F	Paget's disease	Pam	24	O	Both	Extraction	Certain
3	46	M	OP	Pam, Al	132; 12	O	Mandible	Extraction	Certain
4	84	F	OP	Pam	48	O	Maxilla	Extraction	Certain
5	88	F	OP	Pam, Al	24	O	Mandible	Extraction	Certain
6	77	F	OP	Pam, Al	72; 60	B	Both	Extraction	Certain
7	67	F	OP	Et, Al	9; 30	O	Mandible	Implants	Certain
8	84	F	Mult Myel	Pam	12	lv	Mandible	Implants	Certain
9	45	F	Breast ca	Clo	29	O	Mandible	Periodontal disease	Certain
10	59	F	Breast ca	Pam	36	lv	Mandible	Extraction	Certain
11	54	F	OP	Pam	108	lv	Mandible	Pressure sore	Presumable
12	65	F	Breast ca	Pam	53	lv	Mandible	Extraction	Certain
13	82	F	Mult Myel	Et, Pam	1; 72	B	Both	Extraction	Certain
14	83	F	OP	Pam	96	lv	Mandible	Extraction	Certain

Table II. Features patients, indication and bisphosphonate use (*continued*)

Nr	Age	Sex	Indication	Bisphosphonate	Duration use	Administer manner	Location	Luxating moment	Category
15	67	M	Mult Myel	Zol, Pam, Al	12; 10; 22	B	Mandible	Extraction	Certain
16	73	F	OP	Al	46	O	Mandible	Extraction	Unclear
17	75	F	OP	Pam, Al	84; 36	O	Mandible	Presumable extr	Presumable
18	53	F	Breast ca	Pam	24	lv	Mandible	Extraction	Certain
19	72	F	OP	Pam	24	lv	Mandible	Extraction	Certain
20	76	M	OP	Al	52	O	Mandible	Mylohyoid ridge	Presumable
21	80	F	Breast ca	Pam	54	lv	Mandible	Unknown	Unclear
22	57	F	Mult Myel	Pam	83	lv	Mandible	Knife-edge ridge	Presumable
23	66	F	Breast ca	Pam	24	lv	Mandible	Extraction	Certain
24	52	F	Breast ca	Pam	48	lv	Mandible	Extraction	Certain
25	60	F	Breast ca	Pam	24	lv	Maxilla	Extraction	Certain
26	51	F	Breast ca	Pam	45	lv	Mandible	Pressure sore	Presumable
27	59	M	Prostate ca	Pam, Zol	24; 26	lv	Mandible	Dental treatment	Presumable
28	84	M	Mult Myel	Pam	24	lv	Maxilla	Extraction	Certain
29	47	F	OP	Al	24	O	Mandible	Apical granuloma	Certain
30	68	M	Lung ca	Al	31	O	Mandible	Pressure sore	Presumable
31	61	F	Breast ca	Pam	24	lv	Maxilla	Implants	Certain
32	55	F	Breast ca	Pam	24	lv	Mandible	Extraction	Certain
33	70	F	OP	Ris	24	O	Mandible	Extraction	Certain
34	65	M	Prostate ca	Zol	36	lv	Mandible	Extraction	Certain
35	70	F	OP	Al	120	O	Mandible	Extraction	Certain
36	67	F	OP	Al	84	O	Mandible	Implants	Certain
37	60	M	Prostate ca	Zol	12	lv	Mandible	Extraction	Certain
38	54	F	Breast ca	Pam	38	lv	Mandible	Extraction	Certain
39	52	F	Breast ca	Pam, Iban	12;44	B	Maxilla	Implants	Certain
40	75	F	Breast ca	Pam	12	lv	Mandible	Extraction	Certain
41	71	F	OP	Pam	12	lv	Mandible	Extraction	Certain
42	71	F	Breast ca	Iban, Zol	48, 12	B	Maxilla	Extraction	Certain
43	56	F	Breast ca	Pam	38	lv	Mandible	Extraction	Certain
44	75	F	OP	Al	36	O	Maxilla	Implants	Certain
45	76	M	Mult Myel	Pam	18	lv	Mandible	Extraction	Certain

F, female; M, male; OP, osteoporosis; Mult Myel, multiple myeloma; ca, cancer; Al, Alendronic acid (Fosamax); Pam, Pamidronic acid; Ris, risedronate (Actonel; Procter & Gamble, Cincinnati, OH, USA); Et, etidronate (Didronel; Procter & Gamble); Zol, Zoledronic Acid (Zometa; Novartis); Iban, Ibandronate (Boniva; Roche, Basel, Switzerland); OR, orally; IV, intravenously; B, both orally and intravenously.

Table III. Overview literature origin BRONJ

Author	Year	Number patients	Admin manner	Spontaneous(%)	Dental Focus (%)
Badros ²⁰	2008	97	iv	53	47
Bagan ²¹	2006	20	iv	55	45
Bamias ¹¹	2005	17	iv	11,8	88,2
Bedogni ¹²	2008	11	iv	18,1	81,9
Boonyapakorn ²²	2007	22	iv	23	77
Dimopoulos ¹³	2006	15	iv	13,3	86,7
Durie ²³	2005	152	iv	19-31	69-81
Estilo ²⁴	2008	35	iv	40	51,4
Ficarra ¹⁴	2005	9	iv	0	100
Filleul ²⁵	2010	2400	b	26	74
Kos ¹⁵	2009	34	iv	0	91,2
Lugassy ²⁶	2004	3	iv	66,7	33,3
Maerevoet ²⁷	2005	9	iv	1	0
Manfredi ¹⁰	2011	25	b	28	72
Marx ⁸	2005	119	b	25,2	74,8
Marx ²⁸	2007	30	or	50	50
Mavrokokki ¹⁶	2007	112	b	21	79
Melo ¹⁷	2005	11	iv	9,1	91,85
Merigo ⁹	2006	29	b	48,3	51,7
Migliorati ²⁹	2005	17	iv	60	40
O’Ryan ³⁰	2012	30	or	33,3	66,7
Otto ¹⁸	2011	66	b	0	100
Pichardo	2013	45	b	0	97,8
Pires ³¹	2005	12	iv	33	67
Purcell&Boyd ³²	2005	13	b	62	38
Rugiero ³³	2004	63	b	14,1	86
Saad ³⁴	2011	89	iv	35,1	64,9
Then ³⁵	2012	29	b	34,5	65,5
Thumbigere-Math ³⁶	2012	576	iv	41	59
Vescovi ³⁷	2010	567	b	31,7	68,3
Vescovi ³⁸	2012	151	b	29,1	70,9
Wang ³⁹	2003	3	iv	33,3	66,7
Watters ⁴⁰	2012	109	iv	33,9	59,7
Woo ⁴¹	2007	368	b	40	60
Zarychanski ¹⁹	2006	12	iv	17	83

IV, intravenously; OR, orally; B, both orally and intravenously.

Pamidronate (Aredia; Novartis, East Hanover, NJ, USA) was the bisphosphonate most frequently used intravenously. In the oral group Alendronate (Fosamax; Merck & Co., Whitehouse Station, NJ, USA) was most frequently used. There were 9 patients who had used both oral and intravenous bisphosphonates (Table II). These patients were counted in the intravenous group, for intravenous bisphosphonates are far more potent than bisphosphonates taken orally and therefore more at risk for BRONJ.

Initiating factors

In Table II the luxating moments are listed. In 97.8% (n = 44) of the patients a dental focus was found. In 80.0% (n = 36) of the cases this was a certain dental focus. In 20.0% (n = 9) of the cases the dental focus was presumable according to the definitions listed earlier. In one case (2.2%) we were not able to trace a luxating moment, despite retracing the dental history. Case number 16 presented with a fistulating swelling underneath an ill-fitting denture. No patients were found with a history of spontaneous exposed bone.

DISCUSSION

In literature many authors show a high percentage of spontaneous causes of BRONJ. Recently there is a rising percentage of dental causes of BRONJ. Since the cause of BRONJ may influence the treatment choices we studied all possible initiating factors of BRONJ. They were categorized in: “a certain dental focus,” “a presumable dental focus,” “spontaneous,” and “an unknown dental focus” in order to give us more insight in the mechanisms of the etiology of BRONJ. In none of the patients we found a convincing spontaneous origin. In 97.8% of the patients a certain or presumable dental focus was found. In our series as well as in the literature, there seems to be no difference between the causes in the intravenous and the oral bisphosphonate group.

Our findings correspond with those of a few authors in the literature¹¹⁻¹⁹. Most of the authors report a higher percentages of spontaneous cases (Table III), varying from 14.1% to 60%^{2,20-40}. This may be due to the fact that it is difficult to establish the initiating factor in some patients. For example, in our series 1 patient (2.1% classified as ‘unknown dental focus’) presented with a fistulating swelling underneath an ill-fitting denture, making gingival trauma due to trauma likely. The question remains whether the swelling caused the denture not to fit, or the ill-fitting denture caused gingival trauma and hence an inflammation and swelling. In this case the information to make it ‘certain or presumable’ could not be traced.

In the category ‘certain dental origin’ patients had procedures, which created a direct port d’entree for microorganisms to enter the jaw. This is in line with the pathogenesis of osteomyelitis of the jaw with a common dentoalveolar start of the disease and subsequent spreading throughout the jaw. In these cases early treatment gives good results⁴¹⁻⁴⁴. When the pathogenesis of BRONJ resembles the pathogenesis of chronic osteomyelitis, early treatment according to

the principles of the treatment of osteomyelitis should give better results than those reported in the literature of BRONJ so far. In fact several authors as Alons⁴¹, Williamson⁴², Wilde⁴³, and Voss⁴⁴ already have shown to be able to cure a high percentages BRONJ, thus strongly suggesting a pathogenesis of the disease similar to the “ordinary” osteomyelitis. All patients of this series were treated according to the protocol reported by Alons⁴⁰.

In the category ‘presumable dental origin’ several patients were found with prosthetic problems leading to trauma to the overlying soft tissues thus presumably leading to a BRONJ. Possibly many of the ‘spontaneous’ cases found in the literature belong to this category^{2,20-40}.

In conclusion a spontaneous origin of BRONJ has not been found in this series of patients. In 44 patients (97.8%) a dental origin was found. This may lead to a treatment approach as in chronic osteomyelitis with more aggressive surgical intervention with better treatment results, which has already been suggested in the literature.

However, this conclusion is based on a relatively small, retrospective study. Further research is mandatory.

REFERENCES

1. Marx RE. Pamidronate (Aredia) and zoledronate (Zometa) induced avascular necrosis of the jaws: a growing epidemic. *J Oral Maxillofac Surg* 2003; 61:1115-1117.
2. American Association of Oral and Maxillofacial Surgeons position paper on bisphosphonate-related osteonecrosis of the jaws. *J Oral Maxillofac Surg* 2007; 65:369-376.
3. Ruggiero SL, Dodson TB, Assael LA, Landesberg R, Marx RE, Mehrotra B. American Association of Oral and Maxillofacial Surgeons position paper on bisphosphonate-related osteonecrosis of the jaws--2009 update. *J Oral Maxillofac Surg* 2009; 67:2-12.
4. Novince CM, Ward BB, McCauley LK. Osteonecrosis of the jaw: an update and review of recommendations. *Cells Tissues Organs* 2009; 189:275-283.
5. Dental management of patients receiving oral bisphosphonate therapy: expert panel recommendations. *J Am Dent Assoc* 2006; 137:1144-1150.
6. Khosla S, Burr D, Cauley J, Dempster DW, Ebeling PR, Felsenberg D, et al. Bisphosphonate-associated osteonecrosis of the jaw: report of a task force of the American Society for Bone and Mineral Research. *J Bone Miner Res* 2007; 22:1479-1491.
7. van Merkesteyn JP, Groot RH, van den Akker HP, Bakker DJ, Borgmeijer-Hoelen AM. Treatment of chronic suppurative osteomyelitis of the mandible. *Int J Oral Maxillofac Surg* 1997; 26:450-454.
8. Marx RE, Sawatari Y, Fortin M, Broumand V. Bisphosphonate-induced exposed bone (osteonecrosis/osteopetrosis) of the jaws: risk factors, recognition, prevention, and treatment. *J Oral Maxillofac Surg* 2005; 63:1567-1575.
9. Merigo E, Manfredi M, Meleti M, Guidotti R, Ripasarti A, Zanzucchi E. Bone necrosis of the jaws associated with bisphosphonate treatment: a report of twenty-nine cases. *Acta Biomed* 2006; 77: 109-117.
10. Manfredi M, Merigo E, Guidotti R, Meleti M, Vescovi P. Bisphosphonate-related osteonecrosis of the jaws: a case series of 25 patients affected by osteoporosis. *Int J Oral Maxillofac Surg* 2011; 40: 277-284.
11. Bamias A, Kastritis E, Bamia C, Mouloupoulos LA, Melakopoulos I, Bozas G, et al. Osteonecrosis of the jaw in cancer after treatment with bisphosphonates: Incidence and risk factors. *Journal of Clinical Oncology* 2005; 23:8580-8587.
12. Bedogni A, Blandamura S, Lokmic Z, Palumbo C, Ragazzo M, Ferrari F, et al. Bisphosphonate-associated jawbone osteonecrosis: a correlation between imaging techniques and histopathology. *Oral Surg Oral Med Oral Pathol Oral Radiol Endod* 2008; 105:358-364.
13. Dimopoulos MA, Kastritis E, Anagnostopoulos A, Melakopoulos I, Gika D, Mouloupoulos LA, et al. Osteonecrosis of the jaw in patients with multiple myeloma treated with bisphosphonates: evidence of increased risk after treatment with zoledronic acid. *Haematologica* 2006; 91:968-971.
14. Ficarra G, Beninati F, Rubino I, Vannucchi A, Longo G, Tonelli P, et al. Osteonecrosis of the jaws in periodontal patients with a history of bisphosphonates treatment. *J Clin Periodontol* 2005; 32: 1123-1128.
15. Kos M, Kuebler JF, Luczak K, Engelke W. Bisphosphonate-related osteonecrosis of the jaws: a review of 34 cases and evaluation of risk. *J Craniomaxillofac Surg* 2010; 38:255-259.

16. Mavrokki T, Cheng A, Stein B, Goss A. Nature and frequency of bisphosphonate-associated osteonecrosis of the jaws in Australia. *J Oral Maxillofac Surg* 2007; 65:415-423.
17. Melo MD, Obeid G. Osteonecrosis of the jaws in patients with a history of receiving bisphosphonate therapy: strategies for prevention and early recognition. *J Am Dent Assoc* 2005; 136:1675-1681.
18. Otto S, Schreyer C, Hafner S, Mast G, Ehrenfeld M, Stürzenbaum S. Bisphosphonate-related osteonecrosis of the jaws – Characteristics, risk factors, clinical features, localization and impact on oncological treatment. *J Craniomaxillofac Surg* 2011.
19. Zarychanski R, Elphee E, Walton P, Johnston J. Osteonecrosis of the jaw associated with pamidronate therapy. *Am J Hematol* 2006; 81:73-75.
20. Badros A, Terpos E, Katodritou E, Goloubeva O, Kastiris E, Verrou E et al. Natural history of osteonecrosis of the jaw in patients with multiple myeloma. *J Clin Oncol* 2009; 26(36):5904-5909
21. Bagan JV, Jimenez Y, Murillo J, Hernandez S, Poveda R, Sanchis JM, et al. Jaw osteonecrosis associated with bisphosphonates: multiple exposed areas and its relationship to teeth extractions. Study of 20 cases. *Oral Oncol* 2006; 42:327-329.
22. Boonyapakorn T, Schirmer I, Reichart PA, Sturm I, Massenkeil G. Bisphosphonate-induced osteonecrosis of the jaws: prospective study of 80 patients with multiple myeloma and other malignancies. *Oral Oncol* 2008; 44:857-869.
23. Durie BG, Katz M, Crowley J. Osteonecrosis of the jaw and bisphosphonates. *N Engl J Med* 2005; 353:99-102.
24. Estilo CL, Van Poznak CH, Williams T, Bohle GC, Lwin PT, Zhou Q, et al. Osteonecrosis of the maxilla and mandible in patients with advanced cancer treated with bisphosphonate therapy. *Oncologist* 2008; 13:911-920.
25. Filleul O, Crompton E, Saussez S. Bisphosphonate-induced osteonecrosis of the jaw: a review of 2400 patient cases. *J Cancer Res Clin Oncol* 2010; 136:1117-1124
26. Lugassy G, Shaham R, Nemets A, Ben-Dor D, Nahlieli O. Severe osteomyelitis of the jaw in long-term survivors of multiple myeloma: a new clinical entity. *Am J Med* 2004; 117:440-441.
27. Maerevoet M, Martin C, Duck L. Osteonecrosis of the jaw and bisphosphonates. *N Engl J Med* 2005; 353:99-102.
28. Marx RE, Cillo JE, Jr., Ulloa JJ. Oral bisphosphonate-induced osteonecrosis: risk factors, prediction of risk using serum CTX testing, prevention, and treatment. *J Oral Maxillofac Surg* 2007; 65:2397-2410.
29. Migliorati CA, Schubert MM, Peterson DE, Seneda. Bisphosphonate-associated osteonecrosis of mandibular and maxillary bone: an emerging oral complication of supportive cancer therapy. *Cancer* 2005; 104:83-93.
30. O’Ryan F and Lo J. Bisphosphonate-related osteonecrosis of the jaw in patients with oral bisphosphonate exposure: Clinical course and outcomes. *J Oral Maxillofac Surg* 2012; 70:1844-1853
31. Pires FR, Miranda A, Cardoso ES, Cardoso AS, Fregnani ER, Pereira CM, et al. Oral avascular bone necrosis associated with chemotherapy and bisphosphonate therapy. *Oral Dis* 2005; 11:365-369.
32. Purcell PM, Boyd IW. Bisphosphonates and osteonecrosis of the jaw. *Med J Aust* 2005; 182:417-418.
33. Ruggiero SL, Mehrotra B, Rosenberg TJ, Engroff SL. Osteonecrosis of the jaws associated with the use of bisphosphonates: a review of 63 cases. *J Oral Maxillofac Surg* 2004; 62:527-534

34. Saad F, Brown JE, Van Poznak C, Ibrahim T, Stemmer SM, Stopeck AT et al. Incidence, risk factors, and outcomes of osteonecrosis of the jaw: integrated analysis from three blinded active-controlled phase III trials in cancer patients with bone metastases. *Annals of Oncology* 2012; 23:1341-1347
35. Then C, Hörauf N, Otto S, Pautke C, Tresckow E, Röhnisch T et al. Incidence and risk factors of bisphosphonate-related osteonecrosis of the jaw in multiple myeloma patients having undergone autologous stem cell transplantation. *Onkologie* 2012; 35:658-664
36. Thumbigere-Math V, Tu L, Huckabay S, Dudek AZ, Lunos S, Basi DL et al. A retrospective study evaluating frequency and risk factors of osteonecrosis of the jaw in 576 cancer patients receiving intravenous bisphosphonates. *Am J of Clin Oncol* 2012;35:386-392
37. Vescovi P, Compisi G, Fusco V, Mergoni G, Manfredi M, Merigo E et al. Surgery-triggered and non surgery-triggered bisphosphonate-related osteonecrosis of the jaws (BRONJ): a retrospective analysis of 567 cases in an Italian study. *Oral Oncol* 2011; 47:191-194
38. Vescovi P, Merigo E, Meleti M, Manfredi M, Guidotti R, Nammour S. Bisphosphonates-related osteonecrosis of the jaws: a concise review of the literature and a report of a single centre experience with 151 patients. *J Oral Pathol Med* 2012;41:214-221
39. Wang J, Goodger NM, Pogrel MA. Osteonecrosis of the jaws associated with cancer chemotherapy. *J Oral Maxillofac Surg* 2003; 61:1104-1107.
40. Watters AL, Hansen HJ, Williams T, Chou JF, Riedel E, Halpern J et al. Intravenous bisphosphonate-related osteonecrosis of the jaw: long-term follow-up of 109 patients. *Oral Surg Oral Med Oral Pathol Oral Radiol* 2012; e-pub ahead of print.
41. Woo SB, Kalmar JR. Osteonecrosis of the jaws and bisphosphonates. *Alpha Omegan* 2007; 100: 194-202.
42. Alons K, Kuijpers SC, de Jong E, van Merkesteyn JP. Treating low- and medium-potency bisphosphonate-related osteonecrosis of the jaws with a protocol for the treatment of chronic suppurative osteomyelitis: report of 7 cases. *Oral Surg Oral Med Oral Pathol Oral Radiol Endod* 2009; 107:e1-e7.
43. Williamson RA. Surgical management of bisphosphonate induced osteonecrosis of the jaws. *Int J Oral Maxillofac Surg* 2010; 39:251-255.
44. Wilde F, Heufelder M, Winter K, Hendricks J, Frerich B, Schramm A, et al. The role of surgical therapy in the management of intravenous bisphosphonates-related osteonecrosis of the jaw. *Oral Surg Oral Med Oral Pathol Oral Radiol Endod* 2011 Feb;111(2):153-63.
45. Voss PJ, Oshero JJ, Kovalova-Muller A, Veigel Merino EA, Sauerbier S, Al-Jamali J et al. Surgical treatment of bisphosphonate-associated osteonecrosis of the jaw: Technical report and follow up of 21 patients. *J Cran Maxillofac Surgery* 2012; February 13, e-pub ahead of print
46. Manfredi M, Merigo E, Guidotti R, Meleti P, Vescovi P. Bisphosphonate-related osteonecrosis of the jaws: a case series of 25 patients affected by osteoporosis. *Int J Oral Maxillofac Surg* 2011; 40: 277-284
47. Otto S, Schreyer S, Hafner S, Mast G, Ehrenfeld M, Stürzenbaum S et al. Bisphosphonate-related osteonecrosis of the jaws – Characteristics, risk factors, clinical features, localization and impact on oncological treatment. *J Craniomaxillofac Surg* 2012; 40:303-309

