Universiteit Leiden
The Netherlands

Diagnostic procedures for assessing the severity of alloimmune fetal anemia

Sikkel, E.

Citation
Sikkel, E. (2006, March 2). *Diagnostic procedures for assessing the severity of alloimmune fetal anemia*. Retrieved from https://hdl.handle.net/1887/4542

Version:	Corrected Publisher's Version
License:	Licence agreement concerning inclusion of doctoral thesis in the Institutional Repository of the University of Leiden
Downloaded from:	https://hdl.handle.net/1887/4542

Note: To cite this publication please use the final published version (if applicable).

Cardiac ventricular wall thickness and cardio-thoracic ratio in fetuses with severe alloimmune anemia

Esther Sikkel, MD
Saskia Le Cessie, PhD
Katinka A.K. Teunissen, MD
Marieke Sueters, MD
Humphrey H.H.Kanhai, MD, PhD
Frank P.H.A. Vandenbussche, MD, PhD

6

Abstract

Objective: To test the diagnostic accuracy of cardiac ventricular wall thickness and cardio-thoracic ratio in the prediction of severe fetal alloimmune anemia.
Methods: The thickness of cardiac wall of the left and the right ventricles and the inter-ventricular septum were measured in diastole using M-mode ultrasound. The cardio-thoracic circumference ratio was measured on the B-screen. Reference ranges were obtained in 24 non-immunized control pregnancies. The measurements were then obtained in alloimmunized fetuses and two by two tables were constructed to compare the frequency of abnormal cardiac ultrasound measurements in severe and non-severe fetal alloimmune anemia. Ultrasound measurements were considered abnormal in case values were > 2 SD above the normal mean for gestational age. Severe anemia was defined as a hemoglobin concentration of > 5 SD below the normal mean for gestational age.
Results: Complete measurements were obtained in 15 alloimunized fetuses with severe anemia and in 16 alloimmunized fetuses without severe anemia. Sensitivities of cardiac ultrasound ranged between 0 en 47% and specificities between 77 and 97%.
Conclusion: Diagnostic accuracy of ventricular wall thickness and cardio-thoracic ratio in the prediction of severe fetal alloimmune anemia was disappointing. More than 50% of measurements in severely anemic fetuses were within the normal reference ranges.

Introduction

Fetal adaptation to chronic anemia includes changes, such as liver and spleen enlargement,[1-3] and a hyperdynamic circulation.[4] One of the signs of a hyperdynamic circulation is an increase in the peak systolic velocity of the middle cerebral artery. It is widely used as a diagnostic test, because peak systolic velocity of the middle cerebral artery is easy to measure and quite accurate in predicting severe anemia.[5] The hyperdynamic circulation is probably caused by a decrease in blood viscosity and by an increase in cardiac output. Several authors, did indeed find an increased cardiac output with the development of anemia in dogs, in fetal lambs and in human fetuses.[6-9]

We hypothesized that an increase in cardiac output would be accompanied by cardiac changes that are visible on ultrasound. In addition, our sonographers had the impression that severe anemia was accompanied by enlargement of the fetal heart, thickening of the ventricular walls and the interventricular septum, and hyperdensity of the myocard. Ouzounian et al. measured the biventicular outer dimension in alloimmunized patients.[10] They found a 50% sensitivity of the biventricular outer dimension / biparietal dimension ratio in predicting the necessity of neonatal transfusion. Oberhoffer et al. measured cardiac wall thickness in fetuses with anemia.[11] They found a significant increase in cardiac wall thickness in anemic fetuses compared to their own reference ranges.

We wanted to test the diagnostic value of cardiac ultrasound in fetal alloimmune anemia, and therefore measured cardiac ventricular wall thickness and cardio-thoracic ratio in non-anemic, moderately and severely anemic alloimmunized fetuses and in non-anemic controls. Thus, we hoped to expand our diagnostic possibilities for determining the need for fetal transfusion in red cell alloimmunized pregnancies.

Methods

Setting and Patients

Leiden University Medical Center is the national referral center for the management of fetal hematocytopenias in the Netherlands. Our methods for diagnosis and treatment of severe fetal alloimmune anemia have been described previously.[12] Briefly, patients with high antibody titres (> 1/16) and ADCC test > 50 % were followed with weekly ultrasound examinations for signs of fetal anemia.[13] These signs include hepatosplenomegaly, placental thickening, decreased fetal movements, increased maximum flow velocities in intrahepatic umbilical vein, increased mean velocity in the descending thoracic aorta, increased peak systolic velocity in the middle cerebral artery, or incipient hydrops. When severe anemia was suspected at or after 27 weeks, (repeated) amniocentesis for Δ OD 450 measurement was performed and fetal blood sampling was performed when Δ OD 450 was in zone 3 or the upper third of zone 2 and rising.[14] In pregnancies before 27 weeks, the decision to perform the first IUT was based on ultrasound findings alone.

Between March 2001 and May 2002, red cell alloimmunized women visiting our center were also followed with detailed fetal cardiac ultrasound. Exclusion criteria were: single consultation, and factors prohibiting cardiac ultrasound such as abundant fetal breathing or body movements, unfavorable fetal position, lack of time to perform the measurements, maternal obesity. Additional exclusion criteria were: fetuses negative for the offending antigen, hydrops fetalis, no intravascular acces and thus hemoglobin concentration unknown at IUT, or no cardiac measurements at the time severe anemia was diagnosed. Furthermore, 24 normal controls were followed with 4-weekly detailed cardiac ultrasound. The institutional review board approved this prospective study, and all women gave oral informed consent.

Measurements

Ultrasound measurements were performed at least every two weeks and 0-6 hours before IUT. M-mode measurements of fetal ventricular wall thickness and B-mode cardio-thoracic ratio were obtained in diastole. Ultrasound

measurements were both obtained in the absence of fetal breathing and body movements by one of two experienced operators (ES, KT) using an Acuson Sequoia (Acuson, Mountain View, CA) ultrasound machine with a 6.0 MHz probe. Sonographers were blinded for fetal hemoglobin measurements but not for Doppler measurements. The M-mode cursor was placed in the four-chamber view of the fetal heart perpendicular to the interventricular septum, just below the tips of the atrioventricular valves. The ventricular wall thickness of the left and the right ventricles and of the interventricular septum were then obtained (Figure 1). These cardiac wall measurements were only performed when there was no doubt about the definition of endocardial surfaces.

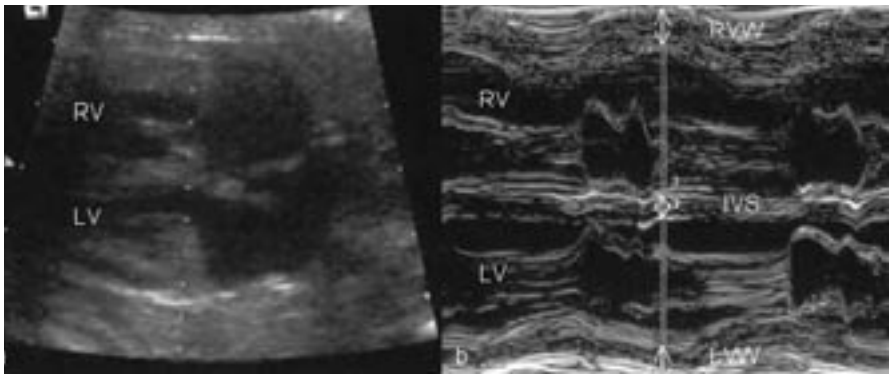

Figure 1 - Sonographic image of the fetal heart (a) and the orientation of the M-mode cursor, placed perpendicular to the interventricular septum, just below the tips of the atrioventricular valves. M-Mode measurement (b) in diastole of the left and the right ventricular walls and the septum.
LV = left ventricle, RV = right ventricle, RVW = right ventricular wall, LVW = left ventricular wall, IVS = inter-ventricular septum

Cardio-thoracic ratios were calculated after measuring the cardiac and thoracic circumferences at the level of the four-chamber view of the fetal heart (Figure 2). The cardiac circumference was measured on the outmost pericard of the heart and the thoracic circumference was measured on the outmost of the ribs of the fetus. This technique is slightly different from the one described by Paladini et al., who measured thoracic circumference at the level of the fetal skin.[15] In the alloimmunized patients, fetal hemoglobin was measured at the time of fetal blood sampling or in cord blood after birth.

Figure 2 - Sonographic image of the fetal thorax at the level of the four-chamber view of the heart during diastole and the ellipses for measuring cardiac and thoracic circumferences The cardiac circumference was measured on the outmost pericard of the heart and the thoracic circumference was measured on the outmost of the ribs of the fetus.

Normal values

M-mode ventricular wall thicknessand cardio-thoracic ratioswere also measured in 24 uncomplicated pregnancies with normal outcome.
Each patient was measured five times with an interval of 4 weeks, between 18 - 36 weeks by one of two experienced operators (ES, MS). Interobserver variability (SD of differences/mean of measurements) for wall thickness was 4.2% for the left ventricle, 6.1% for the right ventricle and 8.2% for the interventricular septum. Inter-observer limits of agreement (95 % confidence interval of differences) were +0.45 to -0.30 mm for ventricular wall thickness of the left ventricle and +0.28 to -0.23 mm of the right ventricle and +0.36 to –0.31 mm of the interventricular septum.[16]

Statistics

Statistical analyses were performed using SPSS 10.0 (SPSS, Chicago, IL) and SAS proc mixed (SAS, Cary, NC). To construct normal references ranges, linear mixed models were fitted to the data of the 24 uncomplicated pregnancies, assuming a linear relation between the fetal cardiac measurements and gestational age with a per person random intercept and slope. This yielded an estimate for the mean and standard deviation as function of gestational age. Values of > 2 SD above normal mean for gestational age were considered as abnormal (positive test result). Severe fetal anemia was defined as hemoglobin > 5 SD below the normal mean[17].
Four two by two tables were then created to assess the diagnostic accuracy of thickening of the left ventricle, right ventricle, interventricular septum, and the cardio-thoracic ratio in the prediction of severe fetal anemia. When there was a first fetal blood sampling that showed severe fetal anemia, the cardiac measurements from immediately before the IUT were used. If there was no need for an IUT all the cardiac measurements were used in the analyses.

Results

The left, right and interventricular septum ventricular wall thickness in the 24 normal control fetuses (120 measurements) increased between 17 and 37 weeks from 1.1 to 4.0, 1.4 to 4.1 and 1.0 to 3.7 mm respectively. The cardio-thoracic ratio in these 24 normal fetuses (120 measurements) increased between 17 and 37 weeks from 0.52 to 0.55.
During the study period, 81 alloimmunized women where followed in our center of which 31 did receive at least one IUT. After exclusion, 15 severely anemic and 16 moderate or non-anemic fetuses with complete measurements remained (Figure 3). Study population characteristics are shown in Table 1.

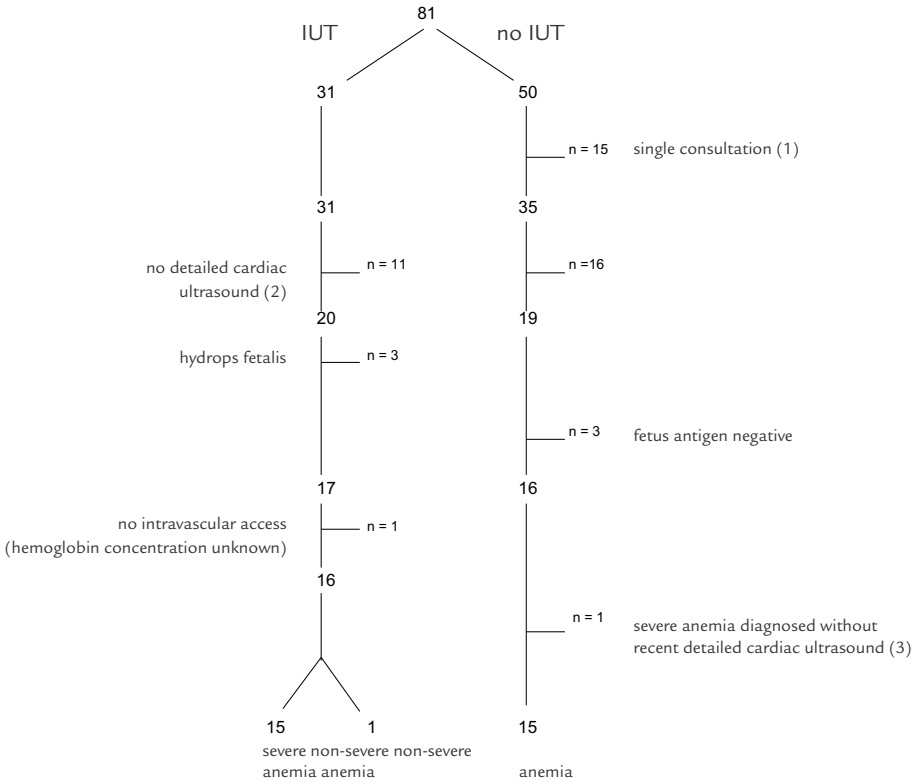

Figure 3 - Flow-chart of study population with exclusion criteria. After exclusion, 31 fetuses remained of which 15 were severely anemic and 16 were moderate or non-anemic.

(1) Because of antigen-negative fetus, low suspicion of anemia, or late referral
(2) Because of lack of time, maternal obesity, fetal breathing or position or body movements
(3) At the time of birth by cesarean section (36 weeks) severe anemia (hemoglobin concentration 7,5 g/dl) was diagnosed, whereas the last detailed prenatal cardiac ultrasound had taken place 5 weeks earlier (31 weeks).

Table 1 - Patient characteristics

	Contols (n = 24)	*Alloimmunized pregnancies without severe fetal anemia*	*Alloimmunized pregnancies with severe fetal anemia*
Maternal age			
(completed years), median (range)	33 (26 - 40)	31 (25 - 40)	31 (25 - 39)
Gestational age			
(completed weeks), median (range)			
at first visit	19 (17 - 21)	20 (13 - 28)	27 (14 - 33)
at birth	40 (36 - 42)	37 (33 - 38)	36 (35 - 37)
at first intrauterine transfusion	---	---	31 (17 - 34)
Type of alloimmunization			
D	---	14	12
c	---	1	3
E	---	1	---
Hemoglobin concentration			
before IUT (g/dl), median (range)	---	---	6.0 (3.7 - 9.3)
at birth (g/dl), median (range)	---	12.4 (10.0 - 21.6)	---
Number of detailed cardiac sonographic measurements included in analysis			
median (range)	5 (4-5)	4 (1 - 12)	1

Figure 4 shows reference ranges for left and right cardiac ventricular wall and interventricular septum thickness. Figure 5 shows reference ranges for cardio-thoracic ratio. Ventricular wall thickness and cardio-thoracic ratio of fetuses with and without severe anemia are plotted in these curves. Most measurements in alloimmunized pregnancies were within the normal reference ranges.

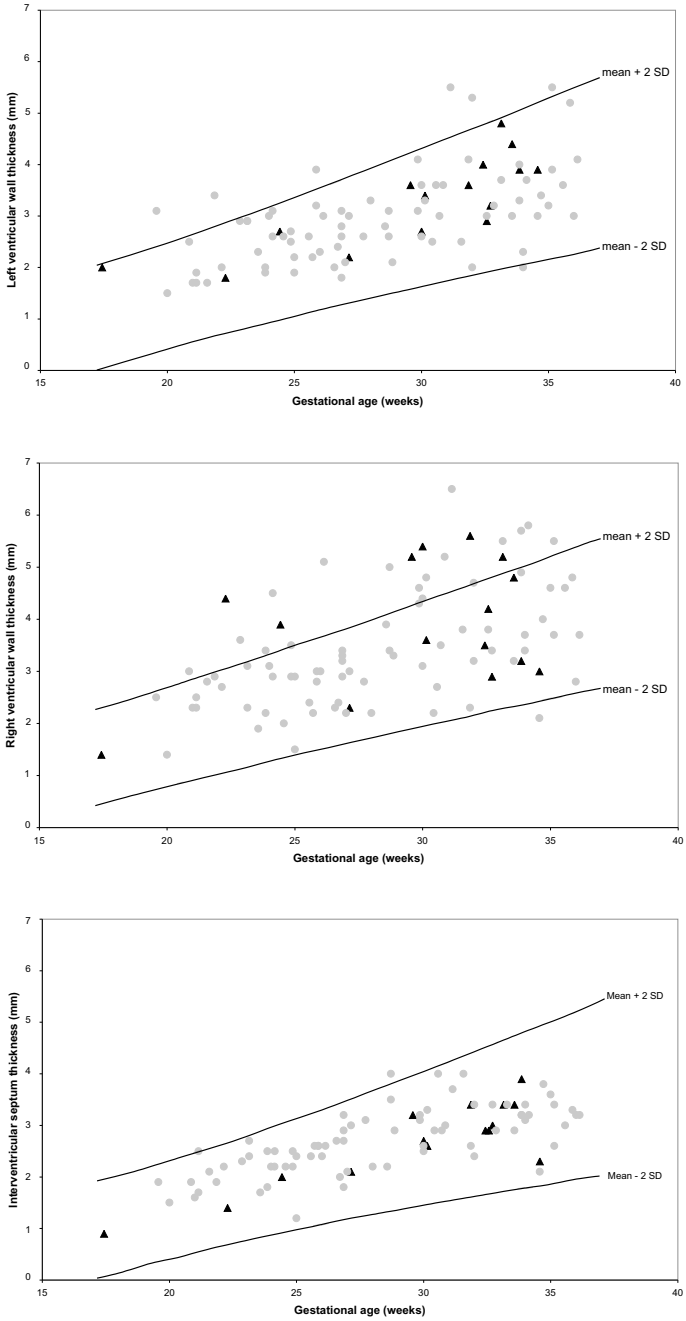

Figure 4 - Reference ranges for left and right cardiac ventricular wall and interventricular septum thickness (mean ± 2 SD). Cardiac ventricular wall thicknesses of fetuses with (black triangles) and without (grey circles) severe anemia were plotted in the curves.

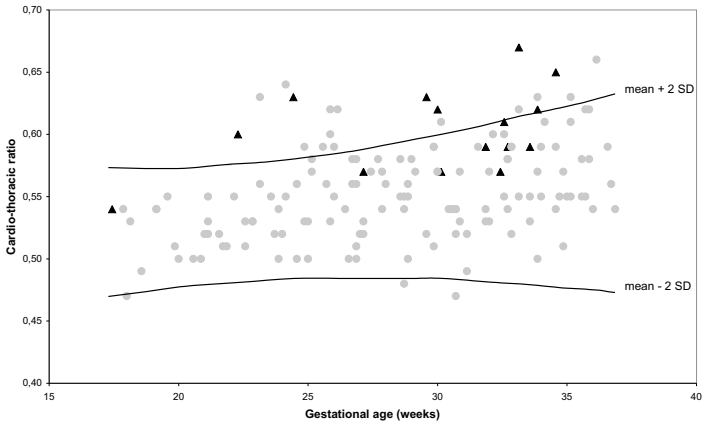

Figure 5 - Reference ranges for cardio-thoracic ratio (mean ± 2 SD). Cardio-thoracic ratios of fetuses with (black triangles) and without (grey circles) severe anemia were plotted in the curve.

Table 2 lists the sensitivities and specificities of the different cardiac ultrasound measurements in the prediction of severe fetal anemia. All sensitivities were below 50%.

Table 2 - Diagnostic accuracy of cardiac wall thickness and cardio-thoracic ratio in the prediction of severe fetal anemia in alloimmunized pregnancies.

	Sensitivity	Specificity
Cardiac wall thickness of:		
- left ventricle	0	92.0 %
- septum	0	97.3 %
- right ventricle	40.0 %	77.3 %
Cardio-thoracic ratio	46.7 %	90.4 %

Discussion

We measured the cardiac ventricular wall and interventricular septum thickness and the cardio-thoracic ratio in alloimmunized pregnancies with and without severe anemia and in non-anemic controls. We found that most of these measurements in alloimmunized pregnancies were within normal ranges. Their diagnostic accuracy is therefore too low to recommend them as a diagnostic tool in predicting severe fetal anemia.

Other authors have sonographically measured cardiac wall thickness. Alan et al. measured cardiac wall thickness in 200 normal fetuses using M-mode ultrasound.[18] They found an increase in left ventricular wall thickness from 1.3 to 4.1 mm between 16 and 39 weeks. Sutton et al. measured cardiac wall thickness in 16 normal fetuses using M-mode ultrasound.[19] They found a linear increase in left cardiac wall thickness from 2.0 to 3.5 mm and in right cardiac wall thickness from 2.0 to 3.0 mm between 20 to 40 weeks. Veille et al. measured cardiac wall thickness in 80 normal fetuses with M-mode ultrasound.[20] They found an increase in left ventricular wall thickness from 1.5 to 3.4 and right ventricular wall thickness from 1.6 to 3.3 between 17 and 41 weeks. Tan et al. measured cardiac wall thickness in 100 normal fetuses.[21] They used calipers on B-screen image for their measurements. They found an increase in left cardiac wall thickness from 1.4 to 3.3 mm and in right cardiac wall thickness from 1.3 to 3.3 mm between 17 and 37 weeks. Oberhoffer et al. measured cardiac wall thickness in 200 normal fetuses using M-mode ultrasound.[22] They found that the left ventricular wall thickness increased from 1.6 to 3.3 mm, the right ventricular wall thickness from 1.6 to 3.7 and the interventricular wall thickness from 1.6 to 3.7 mm between 19 and 40 weeks. Our normal reference ranges obtained in non-anemic controls are in agreement with the results of the five cited studies. Oberhoffer et al. also measured cardiac wall thickness in 30 anemic fetuses and found a symmetrical myocardial hypertrophy of the ventricular walls.[11] In arround 1/3 of their measurements, the interventricular septum thickness was above their normal range. In our study, however, the interventricular septum thicknesses in anemic fetuses were all within the normal range.

Other authors have sonographically measured cardio-thoracic ratio. Paladini et al. measured cardio-thoracic circumference ratio in 410 normal fetuses with gestational ages between 17 weeks and term.[15] They found a fairly constant circumference ratio throughout pregnancy, with a slight increase from 0.45 at 17 weeks to 0.50 at term. Respondec et al. measured cardio-thoracic area ratio in 99 normal fetuses and found this area ratio to remain relatively constant from 20 to 38 weeks. [23] Further, these authors measured the heart/chest antero posterior diameter and this measurement was also relatively stable throughout pregnancy. Oberhoffer et al. measured cardio-thoracic area ratios in 30 fetuses with anemia but they found that an increased cardio-thoracic ratio was not a consistent finding in this population.[11] Ouzounian et al. measured the biventricular outer dimension in diastole with M-mode in 63 alloimmunized patients without IUT.[10] They stated that this measurement is not ideal as a screening method or as a method of surveillance in the management of alloimmunized pregnancies. In our study, the slight increase in cardio-thoracic ratio in normal fetuses throughout pregnancy was similar to that in the cited studies. However, we found that the cardio-thoracic ratio was within the normal range in 8 of 15 severely anemic fetuses.

The strength of the present study is that we longitudinally studied cardiac wall thickness on both sides of the heart and cardio-thoracic ratio in a relatively large number of non-hydropic anemic fetuses. A weakness of our study is that the reproducability of M-mode measurements in the fetus has been described as poor.[24] However, Oberhoffer et al., found an intraobserver variability of cardiac wall thickness of ≤ 5.4%.[11] Tan et al. found an interobserver variability of 7%.[21] Veille et al. found an interobserver variability of ≤ 4.5%.[20] In our study, we found an interobserver variability of ≤ 8.2%. Another weakness is that we have not measured hemoglobin concentration during the pregnancy of fetuses with moderate anemia at birth. However, we think that it is very unlikely that a neonate with moderate anemia at birth has had periods of severe anemia due to alloimmunisation earlier in pregnancy.

In conclusion, we hypothesised that an increase in cardiac output in severe anemia would be accompanied by cardiac changes that are visible on ultrasound. These subjective signs included cardiac wall thickness, enlargement of the fetal heart and hyperdensity of the cardiac walls. However, we found no clear effect of severe fetal anemia on either M-mode measured cardiac ventricular wall thickness or B-mode measured cardio-thoracic ratio. Therefore, we think these measurements are not helpful in the diagnosis of severe fetal alloimmune anemia.

References

1. Oepkes D, Meerman RH, Vandenbussche FP, van Kamp IL, Kok FG, Kanhai HH. Ultrasonographic fetal spleen measurements in red blood cell-alloimmunized pregnancies. Am. J. Obstet. Gynecol. 1993;169:121-28.
2. Roberts AB, Mitchell JM, Pattison NS. Fetal liver length in normal and isoimmunized pregnancies. Am. J. Obstet. Gynecol. 1989;161:42-46.
3. Vintzileos AM, Campbell WA, Storlazzi E, Mirochnick MH, Escoto DT, Nochimson DJ. Fetal liver ultrasound measurements in isoimmunized pregnancies. Obstet. Gynecol. 1986;68:162-67.
4. Nicolaides KH, Bilardo CM, Campbell S. Prediction of fetal anemia by measurement of the mean blood velocity in the fetal aorta. Am. J. Obstet. Gynecol. 1990;162:209-12.
5. Mari G, Deter RL, Carpenter RL, Rahman F, Zimmerman R, Moise KJ, Jr. et al. Noninvasive diagnosis by Doppler ultrasonography of fetal anemia due to maternal red-cell alloimmunization. Collaborative Group for Doppler Assessment of the Blood Velocity in Anemic Fetuses. N. Engl. J. Med. 2000;342:9-14.
6. Copel JA, Grannum PA, Green JJ, Belanger K, Hanna N, Jaffe CC et al. Fetal cardiac output in the isoimmunized pregnancy: a pulsed Doppler- echocardiographic study of patients undergoing intravascular intrauterine transfusion. Am. J. Obstet. Gynecol. 1989;161:361-65.
7. Fan FC, Chen RY, Schuessler GB, Chien S. Effects of hematocrit variations on regional hemodynamics and oxygen transport in the dog. Am. J. Physiol. 1980;238:H545-52.
8. Kilby MD, Szwarc R, Benson LN, Morrow RJ. Left ventricular hemodynamics in anemic fetal lambs. J. Perinat. Med. 1998;26:5-12.
9. Rizzo G, Nicolaides KH, Arduini D, Campbell S. Effects of intravascular fetal blood transfusion on fetal intracardiac Doppler velocity waveforms. Am. J. Obstet. Gynecol. 1990;163:1231-38.
10. Ouzounian JG, Monteiro HA, Alsulyman OM, Songster GS. Ultrasonographic fetal cardiac measurement in isoimmunized pregnancies. J. Reprod. Med. 1997;42:342-46.
11. Oberhoffer R, Grab D, Keckstein J, Hogel J, Terinde R, Lang D. Cardiac changes in fetuses secondary to immune hemolytic anemia and their relation to hemoglobin and catecholamine concentrations in fetal blood. Ultrasound Obstet. Gynecol. 1999;13:396-400.

12. van Kamp IL, Klumper FJ, Meerman RH, Oepkes D, Scherjon SA, Kanhai HH. Treatment of fetal anemia due to red-cell alloimmunization with intrauterine transfusions in the Netherlands, 1988-1999. Acta Obstet. Gynecol. Scand. 2004;83:731-37.
13. Oepkes D, van Kamp IL, Simon MJ, Mesman J, Overbeeke MA, Kanhai HH. Clinical value of an antibody-dependent cell-mediated cytotoxicity assay in the management of Rh D alloimmunization. Am. J. Obstet. Gynecol. 2001;184:1015-20.
14. American College of Obstetricians and Gynecologists. Management of isoimmunization in pregnancy. ACOG technical bulletin no.227.Washington, DC: American College of Obstericians and Gynecologists 1996.
15. Paladini D, Chita SK, Allan LD. Prenatal measurement of cardiothoracic ratio in evaluation of heart disease. Arch. Dis. Child 1990;65:20-23.
16. Bland JM, Altman DG. Statistical methods for assessing agreement between two methods of clinical measurement. Lancet 1986;1:307-10.
17. Nicolaides KH, Soothill PW, Clewell WH, Rodeck CH, Mibashan RS, Campbell S. Fetal haemoglobin measurement in the assessment of red cell isoimmunisation. Lancet 1988;1:1073-75.
18. Allan LD, Joseph MC, Boyd EG, Campbell S, Tynan M. M-mode echocardiography in the developing human fetus. Br. Heart J. 1982;47:573-83.
19. John Sutton MG, Gewitz MH, Shah B, Cohen A, Reichek N, Gabbe S et al. Quantitative assessment of growth and function of the cardiac chambers in the normal human fetus: a prospective longitudinal echocardiographic study. Circulation 1984;69:645-54.
20. Veille JC, Sivakoff M, Nemeth M. Evaluation of the human fetal cardiac size and function. Am. J. Perinatol. 1990;7:54-59.
21. Tan J, Silverman NH, Hoffman JI, Villegas M, Schmidt KG. Cardiac dimensions determined by cross-sectional echocardiography in the normal human fetus from 18 weeks to term. Am. J. Cardiol. 1992;70:1459-67.
22. Oberhoffer R, Hogel J, Lang D. Normal characteristics of cardiac dimensions and function in the fetus. Eur. J. Ultrasound 1995;2:93-106.
23. Respondek M, Respondek A, Huhta JC, Wilczynski J. 2D echocardiographic assessment of the fetal heart size in the 2nd and 3rd trimester of uncomplicated pregnancy. Eur. J. Obstet. Gynecol. Reprod. Biol. 1992;44:185-88.
24. Simpson JM, Cook A. Repeatability of echocardiographic measurements in the human fetus. Ultrasound Obstet. Gynecol. 2002;20:332-39.