

Cover Page



Universiteit Leiden



The handle <http://hdl.handle.net/1887/18977> holds various files of this Leiden University dissertation.

Author: Filali, Mariam el

Title: Knowledge-based treatment in uveal melanoma

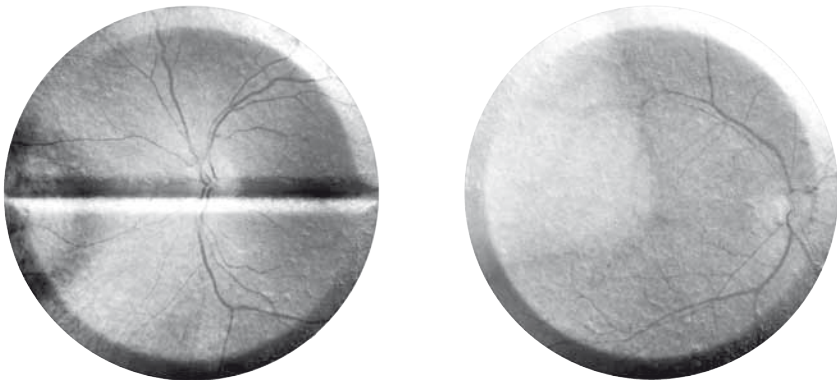
Date: 2012-05-22

CHAPTER 7

EXPRESSION OF THE SST RECEPTOR 2 IN UVEAL MELANOMA IS NOT A PROGNOSTIC MARKER

M. el Filali, E. Kilic, M. Melis, A. de Klein, M. de Jong, G.P.M Luyten

Graefes Arch Clin Exp Ophthalmol. 2008 Nov;246(11):1585-92



ABSTRACT

Introduction. Uveal melanoma (UM) cells and neurohormone-producing cells both originate from the neural crest. Somatostatin receptors subtype 2 (SSTR2) are over-expressed in several tumours, often from neuroendocrine origin, and synthetic antagonists like octreotide and octreotate are being used as diagnostic or therapeutic agents. We investigated the SSTR2 expression in uveal melanoma, and determined whether this expression was related to prognosis of the disease.

Material and Methods. UM cell lines and fresh primary UM samples were tested for SSTR2 expression by autoradiography (AR) using ^{125}I -Tyr3-octreotate. Furthermore, UM cell lines were analyzed for SSTR2 mRNA expression with quantitative PCR.

Results. Using AR, cell surface SSTR2 expression was demonstrated in two metastatic cell lines, but no expression was detected in three cell lines derived from primary tumours. However, all primary and metastatic cell lines showed mRNA expression levels for SSTR2 using quantitative PCR. Only three of 14 primary UM demonstrated moderate SSTR2 expression, and this expression was not significantly associated with tumour-free survival or any tested prognostic factor.

Conclusion. Based on the rare and low expression of SSTR2 found in primary UM specimens and in UM cell lines, we conclude that SSTR2 is not widely expressed in uveal melanomas. Furthermore, SSTR2 expression was not associated with tumour-free survival and prognostic factors. Therefore SSTR2 is not suited as prognostic marker or therapeutic target in UM.

INTRODUCTION

Uveal melanoma (UM) is the most common primary intraocular tumour, with an annual incidence of 0.7/100.000 in the Western population ¹. Although less than 2% of the patients have clinically detectable metastasis at presentation, 50% of all patients die due to metastatic disease. The median survival after the diagnosis of metastasis is extremely poor. Predictors of survival for UM patients have been identified in histologic cell type, tumour diameter, tumour location, age, gender ^{2,3} and cytogenetic parameters. Loss of chromosome 3 is one of the most significant predictors for uveal melanoma-related deaths ⁴⁻⁶.

Most of the uveal melanomas are treated by radiotherapy, thus material for histopathologic and cytogenetic examination has to be obtained by Fine Needle Aspiration Biopsy (FNAB) for example. Shields et al. showed that FNAB provides adequate DNA for genetic analysis of uveal melanoma using a microsatellite assay ⁷. Early and long-term complications following intraocular FNAB are rare ⁸. Nevertheless, one suspected clinical case of extrascleral recurrence has been recently reported after diagnostic intraocular transscleral FNAB ⁹. Therefore concern about tumour seeding due to this diagnostic procedure still exist ¹⁰, and FNAB is consequently not used routinely yet.

Conversely, neurohormone receptors as markers could be detected non-invasive and safe using scintigraphy, without the need to take a biopsy.

During embryogenesis, neural crest cells migrate to the diencephalon and to the uvea, where they give rise to pigmented melanocytes. Neural crest cells are able to produce neurohormones like somatostatin (SST). SST inhibits the release of growth hormone and thyroid-stimulating hormone. Its actions are mediated by specific G protein-coupled receptors, which are located in specific target cells of the gastrointestinal tract, the peripheral nervous system and several blood vessels ¹¹.

Moreover, SST could be involved in the inhibition of tumour growth ^{12,13}. SST receptors (SSTR) have been detected in human neuroendocrine tumours ¹⁴⁻¹⁶, human lung tumours such as bronchial carcinoids ¹⁷ and gastro-entero-pancreatic tumours like insulinomas, gastrinomas and ileal carcinoids ¹⁸. SST analogues, like octreotide and octreotate, can be radiolabelled with radionuclides via a chelator and are currently being used in the diagnosis (¹¹¹In) or therapy (⁹⁰Y or ¹⁷⁷Lu) of patients suffering from SSTR-expressing tumours ¹⁹⁻²².

Due to the common origin of SST and UM cells, a relation or interaction may be found. A relation between eye tissue and neurohormones has already been explored in several studies ²³⁻²⁵. In a previous study, Ardjomand et al. concluded that expression of SST₂ receptors (SSTR₂) in uveal melanomas is correlated with a better ad vitam prognosis of the patients ²⁶. Our aim was to further investigate the expression of SSTR₂ in uveal melanoma, in order to identify specific membrane receptors for diagnostic imaging and therapeutic targeting. Primary specimens and uveal melanoma cell lines, derived from primary or metastatic uveal melanomas were analyzed using in vitro AR and quantitative real-time RT-PCR techniques.

MATERIAL AND METHODS

Patient and tumour material

Informed consent was obtained prior to enucleation and the study was performed according to the tenets of the Declaration of Helsinki.

Fresh tumor tissue was obtained within 1 hour after enucleation, according to a standardized protocol. An incision was made through the tumor, leaving the optic nerve intact. A sample was taken from the side opposite the optic nerve and divided in three; one part was processed for fluorescent in situ hybridization (FISH), one part was fixed in 4 % paraformaldehyde overnight and the last part, as well as control tissues (rat brain, rat pancreas), were stored in liquid nitrogen for cryopreservation. Five-micrometer paraffin section were cut on a microtome (Microm HM 335^E), and put on uncoated slides (Menzel Superfrost) humidified with sterile water for haematoxylin-eosin (HE) and periodic acid-Schiff (PAS) staining. Five-micrometer cryosections of frozen tumour samples and control tissues were cut on a cryostat (Jung CM3000; Leica, Meyer Instruments, Inc. Houston, USA), and mounted on coated slides. Subsequently, the slides were air-dried and stored at -80°C and processed as below (see under 'autoradiography'). Conventional histopathologic examination was performed on all tumors and confirmed the origin of each one.

Cell lines

Mel 202, 92.1 and OCM-1, primary tumour-derived cell lines, were used as a model for human primary uveal melanoma. OMM1 and OMM2.3, skin and liver metastases-derived cell lines, were used as a model for human uveal melanoma metastasis. Rpe1 is a normal retinal pigment epithelium-derived cell line. OCM-1 was provided by dr. J. Kan-Mitchell, Mel202 and OMM2.3 by dr. B. Ksander, 92.1 by dr. M.J. Jager and OMM1 and Rpe1 were established in our laboratory²⁷⁻³¹. The SSTR-expressing CA20948 cell line originated from the solid CA20948 rat pancreatic tumour and served as positive control for autoradiography experiments since ocreotat detect both rodent and human SSTR₂, of which the homology is more than 90%^{19,32}. All cell lines were cultured in Dulbecco's Modified Eagle's Medium (DMEM) supplemented with 10% fetal calf serum and 1% penicillin/streptomycin (GIBCO, Life Technologies, Paisley, UK). The cells were passaged once or twice a week using trypsin (0.05%) or trypsin+EDTA (0.02%). Cells were centrifuged at 1,000 rpm for 10 min in DMEM, resuspended in 0.1 M DPBS and used to prepare cytopins on coated slides (Menzel Superfrost Plus Menzel-Gläser, Braunschweig, Germany) humidified with DPBS using a cytofuge (Nordic, Tilburg, The Netherlands).

Fluorescent In Situ Hybridization Analysis

Dual color FISH was performed on uncultured tumor tissue, by using centromeres, locus-specific cosmids, P1, or YAC as probes for chromosomes 1, 3, 6, and 8, respectively, as

described previously³³. Seven probes were used: p1-79 (mapped to chromosome band 1p36), P 3.5 (centromere 3), YAC 827D3 (3q24), cos85 (6p21), and cos52 (6q23) (all from Yusuke Nakamura, Tokyo, Japan) and D8Z2 (centromere 8) and ETO (8q22). The probes were validated on normal peripheral blood cell metaphase spreads, and 10 metaphases were analyzed for each probe. Cutoff limits were less than 3%. The concentration for centromeric probes was 5 ng per slide; for cosmid, P1, and YAC probes, 50 to 75 ng per slide was used. After hybridization and washing, the slides were counterstained with 4',6-diamidino-2-phenylindole (DAPI) and mounted in anti-fade medium (Dabco-Vectashield 1:1; Vector Laboratories, Burlingame, CA). Signals were counted in 300 interphase nuclei, according to the criteria of Hopman et al.³⁴. Scoring for deletion (>15% of the nuclei with one signal) or amplification (>10% of the nuclei with three or more signals) was adapted from the available literature³⁵.

Autoradiography

¹²⁵I-DOTA-Tyr³-octreotate (BioSynthema, St Louis Mo, USA), that has a high affinity binding to SSTR₂, was used for the autoradiography study³⁶. The autoradiographic experiments were performed on cryosections and cytopins using 10⁻⁹M or 10⁻¹⁰M ¹²⁵I-DOTA-Tyr³-octreotate, with or without a blockade of 10⁻⁶M unlabelled octreotide (Novartis, Basel, Switzerland), to investigate SSTR₂ specific binding as described in literature^{14,37}. After a 1 h incubation at room temperature and rinsing with Tris buffer to remove the non-bound radioactive octreotate, dried cryosection and cytopin slides were exposed to phosphor-imaging screens (Packard Instruments Co., Meriden, USA) in X-ray cassettes. After 24-72 hours, the screens were read using a Cyclone phosphor imager and analyzed with OptiQuant 03.00 image processing system (Packard Instruments Co., Groningen, The Netherlands). Binding of ¹²⁵I-DOTA-Tyr³-octreotate to cytopins and cryosections was expressed in digital light units (DLU)/mm². Net DLU/mm² represents binding of ¹²⁵I-DOTA-Tyr³-octreotate (specific binding) minus non-specific binding in adjacent sections incubated with ¹²⁵I-DOTA-Tyr³-octreotate plus 10⁻⁶M octreotide. Net DLU/mm² was considered positive when > 5000 DLU/mm².

Quantitative real-time RT-PCR

SSTR₂ mRNA expression was analyzed by real time-reverse transcriptase-polymerase chain reaction (real time RT-PCR). RNA was isolated using an Rneasy® Mini Kit (Qiagen, Valencia, USA). RNA samples were stored at -80°C until further processing. Approximately 1 µg of RNA per sample was reverse-transcribed using the iScript cDNA synthesis kit (Bio-Rad, Hercules, USA). The 20 µl solutions obtained this way were diluted by adding sterile water up till 100 µl. In 96-wells, 2 µl of this solution was added to a 15 µl solution of iQ SYBR Green Supermix, forward and reverse primers (10 µM solutions) for SSTR₂ or RPS-11 (control gene) and sterile water (volume ratio respectively 10:1:1:8). The primers had the following sequences: SSTR₂ forward 5'- TGCTGGGTCTGCCTTTCTTGG - 3', SSTR₂ reverse 5' - AGAAGATGCTGGTGAAGTATTGATG - 3', RPS-11 forward 5' - aagcagccgaccatcttca

– 3', RPS-11 reverse 5' – cgggagcttctccttggc – 3'³⁸. A quantitative analysis of the samples was then performed for SSTR2 and RPS-11 (control gene) expression by real time-PCR in a MyiQ iCycler real-time PCR system (Bio-Rad, Hercules CA). The PCR reaction settings were 95°C for 3 minutes, then 40 cycles at 95°C for 30 seconds and 60°C for 30 seconds, then 95°C for 1 minute and 60°C for 1 minute. To correct the sample-to-sample variation when determining gene expression, an accepted method is to select a cellular housekeeping gene that serves as an endogenous control, against which the target gene expression levels can be normalized³⁹. RPS-11 (ribosomal protein S11) is a housekeeping gene that has recently been introduced to normalize gene expression in uveal melanoma cells⁴⁰.

RESULTS

Patients and tumour material

In total, primary uveal melanomas from 14 patients (10 male and 4 female, with a mean age of 63 ± 10.1 years) were included in the study. Histopathologic analysis of HE and PAS stained paraffin sections was performed on all primary uveal melanomas. The mean tumour diameter was 12.6 ± 2.8 mm and their mean prominence was 8.5 ± 2.0 mm. Epithelioid cells were found in 10 of 14 cases, while in seven cases vascular loops and/or networks were detected. Furthermore, FISH analysis of all samples was performed; monosomy 3 as well as loss of chromosome 1p was found in 10 of 14 cases and gain of chromosome 8q was present in 7 of 14 cases. After a mean follow-up period of 36.1 ± 13.0 months, five patients had developed distant metastases (Table 1).

Autoradiography

Fresh primary uveal melanoma samples were tested for expression of SSTR2 by AR using ¹²⁵I-Tyr³-ocreotate. In three of the in total 14 primary uveal melanomas a positive albeit weak binding was observed (Table 2). Statistical analysis with the Kaplan Meier method and log-rank test did not show any significant relation between SSTR2 expression and tumour-free survival ($p=0,76$). In the univariate and multivariate Cox-regression analysis, SSTR2 expression was not significantly associated with tumour-free survival or other important prognostic factors (cell type, vascular patterns, tumour diameter, prominence, monosomy 3, loss of chromosome 1p and gain of chromosome 8q).

Uveal melanoma cell lines were tested for expression of SSTR2 by autoradiography using ¹²⁵I-Tyr³-ocreotate. All cell lines were tested in duplicate.

The positive control rat pancreatic tumour cell line (CA20948) showed a strong binding. Cell line 92.1 showed very low binding while none of the other primary UM derived cell lines (Mel202, OCM-1) or normal cell line (Rpe1) showed specific receptor binding. Both metastatic melanoma cell lines (OMM1, OMM2.3) showed high binding (Fig. 1, Table 3).

TABLE 1 Clinical features of included patients

Sex (male/female)	10/4
Age (mean \pm SD, years)	63.0 \pm 10.1
Diameter (mean \pm SD, mm)	12.6 \pm 2.8
Prominence (mean \pm SD, mm)	8.5 \pm 2.0
Cell type (epithelioid/non-epithelioid)	10/4
Vascular loops and/or networks (yes/no)	7/7
Pigmentation (yes/no)	8/6
Metastasis (yes/no)	5/9
Monosomy 3 (yes/no)	10/4
Loss of 1p (yes/no)	10/4
Gain of 8q (yes/no)	7/7
Follow-up (mean \pm SD, months)	36.1 \pm 13.0

TABLE 2 Autoradiography results of primary tumor samples

	METASTASIS ¹	AUTORADIOGRAPHY ²
		¹²⁵ I-Tyr ³ -OCREOTATE (SST ₂)
1	-	++
2	-	+
3	+	+
4	-	-
5	-	-
6	-	-
7	+	-
8	-	-
9	+	-
10	+	-
11	+	-
12	-	-
13	-	-
14	-	-
Control	NA ³	++++

¹ Metastasis present: +, No metastasis:-

² Netto Digital Light Units/mm²: <5000: -, 5000-10000: +, 10000-50000: ++, 50000-100000: +++, >100000:++++

³ Not assessed




FIGURE 1. Autoradiogram of cytopins with binding to SSTR2

1ste column: incubated cytopins

2de column: negative controls

OMM2.3, B. OMM1, C. Mel202, D. OCM-1, E. Rpe 1, F. CA20948, G. Rat brain.

(a few cell lines are shown in duplicate)

TABLE 3 Autoradiography results of uveal melanoma cell lines

	Cell line	Autoradiography ¹ 125I-Tyr3-Octreotate (SSTR2)
Primary	92.1	+
	Mel202	-
	OCM-1	-
Metastatic	OMM1	++
	OMM2.3	++
Normal Rpe2	Rpe1	-
Control	CA20948 ³	++++

¹ Netto Digital Light Units/mm²: <5000: -, 5000-10000: +, 10000-50000: ++, 50000-100000: +++, >100000:++++

² Normal retinal pigment epithelium cell line

³ Control cell line from the solid CA20948 rat pancreatic tumor

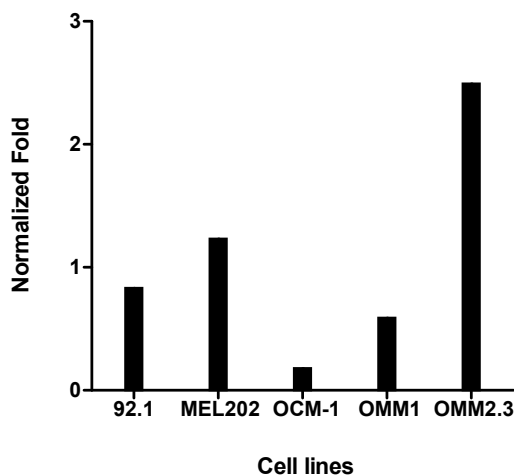


FIGURE 2. Expression of SSTR2 in uveal melanoma cell lines.

All five UM cell lines tested expressed SSTR2 mRNA. The expression levels were normalized to the housekeeping gene RPS-11. OMM2.3 shows a two to four times higher expression level of SSTR2 mRNA compared to OMM1, 92.1 and MEL202. Primary UM cell line OCM-1 had a very low expression level, and can therefore not be compared to the other UM cell lines.

Real-time quantitative RT-PCR in cell lines

Expression of SSTR2 mRNA in UM cell lines was evaluated by RT-PCR, with normalization of the expression levels to the housekeeping gene RPS-11. All five UM cell lines tested expressed SSTR2 mRNA, but the level of expression was quite variable. OMM 2.3 showed a two to four times higher expression level of SSTR2 mRNA compared to the other metastases derived UM cell line OMM1, and the primary UM cell lines 92.1 and Mel 202. The other tested primary UM cell line OCM-1 showed a very low SSTR2 mRNA expression level (Fig. 2).

DISCUSSION

Expression of somatostatin receptors in neuroendocrine tumours has been extensively investigated and led to the development of clinically relevant diagnostic and therapeutic strategies. Based on common embryonic origin, uveal melanoma could also be a candidate for such strategies, as many patients die from metastasized UM.

In this study, SSTR2 expression was studied in 14 primary UM tumour samples and several different uveal melanoma cell lines, either derived from primary or from metastized UM tumour samples. Primary tumours were tested at the protein level using in vitro autoradiography, cell lines were additionally analyzed on mRNA level. In only three primary specimens

moderate SSTR2 expression was demonstrated. One of these was a metastasized melanoma, while four other samples of metastasized UM did not express SSTR2.

Furthermore the relation between SSTR2 expression, tumour-free survival and prognostic factors was studied, although the number of samples we used was too small to perform reliable statistical analysis. With the data obtained thus far, no significant correlation between SSTR2 expression and tumour-free survival or any other important prognostic parameter could be found. Conversely, Ardjomand et al. detected by using immunohistochemistry on paraffin embedded UM tissue, that SSTR2 was expressed in nearly all of the 25 tested samples. When the prognosis of these 25 patients was compared with the expression level of SSTR2 in uveal melanoma tissue, a positive correlation was found between high SSTR2 and a better ad vitam prognosis ²⁶.

Since Ardjomand et. al used a different approach and techniques to determine SSTR2 expression, it is difficult to compare our results. An explanation for the differences could be that we used cryosections instead of paraffin sections, in antibody versus peptide targeting. Furthermore, in immunohistochemistry it is possible to discriminate positive staining in individual cells by using antibodies for specific subtypes of somatostatin receptors. In our AR experiments, we analyzed tissue cryosections and a peptide analogue that can be applied in vivo for PET or SPECT imaging, after labelling with an appropriate radionuclide. In AR a certain threshold had to be reached before tissue could be identified as positive; however this threshold is low due to the high sensitivity of the phosphor imaging read out system. For in vivo imaging this threshold would be much higher. Most of the tumours tested by Ardjomand et. al contained between 11 and 80% of SSTR2 expressing tumour cells. If the percentage of SSTR2 expressing tumour cells in our tested specimens was within this range, these should have been detected using in vitro autoradiography. Furthermore, Ardjomand et. al also argued the diagnostic value of SSTR expression, since in only two of four patients with UM in their study the affected eye could be visualized by ocreotide scintigraphy.

Besides primary UM samples, UM derived cell lines, originating either from primary or from metastasized UM tumours, were tested for SSTR2 expression. By using the in vitro AR technique with cytopins of UM cell line cells, it was found that three primary melanoma cell lines showed almost no specific binding of ¹²⁵I-Tyr³-octreotate, whereas both metastatic cell lines showed strong binding. This implied that expression of SSTR2 at the protein level could be associated with a bad prognosis and development of metastasis. This clear SSTR2 expression of the metastatic UM cell line OMM2.3 correlated with a four times higher expression level of SSTR2 mRNA compared to the primary UM line 92.1 in quantitative real-time RT-PCR. The primary UM cell line Mel 202 also showed a moderately high SSTR2 mRNA expression, but apparently this mRNA was not transcribed to protein. Apparently the correlation between SSTR2 expression at mRNA and protein level seems to be good in cell lines derived from metastasized UM, but less in lines from primary UM. Furthermore, there is a discrepancy between the SSTR2 expression in cell lines compared to that in primary

and metastasized uveal melanoma specimens, in which only a small percentage of low SSTR2 expressing samples was found. Expression of high SSTR2 levels might be favourable for deriving an in vitro growing cell line from a UM biopsy. Thus cell lines might not be really representative for in vivo circumstances ⁴¹.

Considering the low SSTR2 expression of the primary UM samples, we conclude that imaging with somatostatin analogues to perform scintigraphy is not feasible in uveal melanoma patients.

Although FNAB has been shown to accurately demonstrate genetic and histologic prognostic factors in the obtained tissue ⁷, finding another tumour-specific (neurohormone) receptor that can be used as an in vivo target for diagnosis (and therapy) is still an attractive, non-invasive option to improve the diagnosis of (metastasized) UM using specific radiolabelled peptide analogues. Metastasis is the single leading cause of death of patients with UM. Kaplan-Meier estimates of 5-year melanoma-related mortality range from 26% to 32% ⁴². The first site of metastasis is the liver in approximately 90% of patients, but later spread to the lungs, bone, and skin occurs frequently ⁴³⁻⁴⁵. It remains unknown to which extent current treatments for metastasis actually prolong survival compared to no treatment at all ^{42,46}. It is proposed that patients who develop clinical metastases from uveal melanoma often harbour micro metastases for years ⁴⁷. Targeting tumour-specific receptors might be used to treat these (micro) metastases in future when specific analogues are radiolabelled with therapeutic β -emitting radionuclides like ¹⁷⁷Lu.

Further investigation targeting other neural-crest derived hormone receptors may thus reveal new options. Several studies have shown that vasoactive intestinal peptide (VIP) and pituitary adenylate-cyclase-activating polypeptide (PACAP) have tumour-growth promoting activities in breast cancer and neuroblastoma for example. Furthermore, VIP and PACAP antagonists demonstrated growth-inhibitory properties ⁴⁸⁻⁵¹. VIP receptors have been found to be ubiquitous expressed in all ocular tissues, with highest concentrations occurring in the choroid of several different mammals ²³. Most uveal melanomas are strongly pigmented. Alpha-melanocyte-stimulating hormone is primarily responsible for the regulation of pigmentation and could therefore be linked to uveal melanoma ⁵².

In conclusion, additional exploration of neurohormone receptors is needed to identify a specific membrane receptor to be used in diagnostic imaging and therapeutic targeting.

REFERENCE LIST

1. Egan, K. M., Seddon, J. M., Glynn, R. J., Gragoudas, E. S., and Albert, D. M. *Epidemiologic aspects of uveal melanoma*. *Surv.Ophthalmol.* 1988. 32:239-251.
2. Mooy, C. M. and De Jong, P. T. *Prognostic parameters in uveal melanoma: a review*. *Surv.Ophthalmol.* 1996. 41:215-228.
3. Mudhar, H. S., Parsons, M. A., Sisley, K., Rundle, P., Singh, A., and Rennie, I. G. *A critical appraisal of the prognostic and predictive factors for uveal malignant melanoma*. *Histopathology* 2004. 45:1-12.
4. Prescher, G., Bornfeld, N., Hirche, H., Horsthemke, B., Jockel, K. H., and Becher, R. *Prognostic implications of monosomy 3 in uveal melanoma*. *Lancet* 1996. 347:1222-1225.
5. Sisley, K., Rennie, I. G., Parsons, M. A., Jacques, R., Hammond, D. W., Bell, S. M., Potter, A. M., and Rees, R. C. *Abnormalities of chromosomes 3 and 8 in posterior uveal melanoma correlate with prognosis*. *Genes Chromosomes.Cancer* 1997. 19:22-28.
6. Damato, B., Duke, C., Coupland, S. E., Hiscott, P., Smith, P. A., Campbell, I., Douglas, A., and Howard, P. *Cytogenetics of uveal melanoma: a 7-year clinical experience*. *Ophthalmology* 2007. 114:1925-1931.
7. Shields, C. L., Ganguly, A., Materin, M. A., Teixeira, L., Mashayekhi, A., Swanson, L. A., Marr, B. P., and Shields, J. A. *Chromosome 3 analysis of uveal melanoma using fine-needle aspiration biopsy at the time of plaque radiotherapy in 140 consecutive cases: the Deborah Iverson, MD, Lectureship*. *Arch. Ophthalmol.* 2007. 125:1017-1024.
8. Midena, E., Bonaldi, L., Parrozzani, R., Radin, P. P., Boccassini, B., and Vujosevic, S. *In vivo monosomy 3 detection of posterior uveal melanoma: 3-year follow-up*. *Graefes Arch.Clin.Exp.Ophthalmol.* 2007.
9. Caminal, J. M., Sanz, S., Carreras, M., Catala, I., Arruga, J., and Roca, G. *Epibulbar seeding at the site of a transvitreal fine-needle aspiration biopsy*. *Arch.Ophthalmol.* 2006. 124:587-589.
10. Kvanta, A., Seregard, S., Kopp, E. D., All-Ericsson, C., Landau, I., and Berglin, L. *Choroidal biopsies for intraocular tumors of indeterminate origin*. *Am.J.Ophthalmol.* 2005. 140:1002-1006.
11. Johnson, L. R. *Regulation of gastrointestinal mucosal growth*. *Physiol Rev.* 1988. 68:456-502.
12. Patel, Y. C. *Somatostatin and its receptor family*. *Front Neuroendocrinol.* 1999. 20:157-198.
13. Benali, N., Ferjoux, G., Puente, E., Buscail, L., and Susini, C. *Somatostatin receptors*. *Digestion* 2000. 62 Suppl 1:27-32.
14. Reubi, J. C., Krenning, E., Lamberts, S. W., and Kvols, L. *In vitro detection of somatostatin receptors in human tumors*. *Digestion* 1993. 54 Suppl 1:76-83.
15. Reubi, J. C., Kappeler, A., Waser, B., Laissue, J., Hipkin, R. W., and Schonbrunn, A. *Immunohistochemical localization of somatostatin receptors sst2A in human tumors*. *Am.J.Pathol.* 1998. 153:233-245.
16. Liu, Q., Reubi, J. C., Wang, Y., Knoll, B. J., and Schonbrunn, A. *In vivo phosphorylation of the somatostatin 2A receptor in human tumors*. *J.Clin.Endocrinol.Metab* 2003. 88:6073-6079.
17. Papotti, M., Croce, S., Bello, M., Bongiovanni, M., Allia, E., Schindler, M., and Bussolati, G. *Expression of somatostatin receptor types 2, 3 and 5 in biopsies and surgical specimens of human lung tumours. Correlation with preoperative octreotide scintigraphy*. *Virchows Arch.* 2001. 439:787-797.
18. Reubi, J. C. and Waser, B. *Concomitant expression of several peptide receptors in neuroendocrine tumours: molecular basis for in vivo multireceptor tumour targeting*. *Eur.J.Nucl.Med.Mol.Imaging* 2003. 30:781-793.
19. de Jong, M., Breeman, W. A., Valkema, R., Bernard, B. F., and Krenning, E. P. *Combination radionuclide therapy using 177Lu- and 90Y-labeled somatostatin analogs*. *J.Nucl.Med.* 2005. 46 Suppl 1:13S-17S.
20. Krenning, E. P., de Jong, M., Kooij, P. P., Breeman, W. A., Bakker, W. H., de Herder, W. W., van Eijck, C. H., Kwekkeboom, D. J., Jamar, F., Pauwels, S., and Valkema, R. *Radiolabelled somatostatin analogue(s) for peptide receptor scintigraphy and radionuclide therapy*. *Ann.Oncol.* 1999. 10 Suppl 2:S23-S29.

21. Krenning, E. P., Valkema, R., Kwekkeboom, D. J., de Herder, W. W., van Eijck, C. H., de Jong, M., Pauwels, S., and Reubi, J. C. *Molecular imaging as in vivo molecular pathology for gastroenteropancreatic neuroendocrine tumors: implications for follow-up after therapy.* J.Nucl.Med. 2005. 46 Suppl 1:76S-82S.
22. Kwekkeboom, D. J., Mueller-Brand, J., Paganelli, G., Anthony, L. B., Pauwels, S., Kvols, L. K., O'dorisio, T. M., Valkema, R., Bodei, L., Chinol, M., Maecke, H. R., and Krenning, E. P. *Overview of results of peptide receptor radionuclide therapy with 3 radiolabeled somatostatin analogs.* J.Nucl.Med. 2005. 46 Suppl 1:62S-66S.
23. Elbadri, A. A., Shaw, C., Johnston, C. F., Archer, D. B., and Buchanan, K. D. *The distribution of neuropeptides in the ocular tissues of several mammals: a comparative study.* Comp Biochem.Physiol C. 1991. 100:625-627.
24. Helboe, L. and Moller, M. *Immunohistochemical localization of somatostatin receptor subtypes sst1 and sst2 in the rat retina.* Invest Ophthalmol.Vis.Sci. 1999. 40:2376-2382.
25. Troger, J., Sellemond, S., Kieselbach, G., Kralinger, M., Schmid, E., Teuchner, B., Nguyen, Q. A., Schretter-Irschick, E., and Gottinger, W. *Inhibitory effect of certain neuropeptides on the proliferation of human retinal pigment epithelial cells.* Br.J.Ophthalmol. 2003. 87:1403-1408.
26. Ardjomand, N., Ardjomand, N., Schaffler, G., Radner, H., and El Shabrawi, Y. *Expression of somatostatin receptors in uveal melanomas.* Invest Ophthalmol.Vis.Sci. 2003. 44:980-987.
27. Chen, P. W., Murray, T. G., Salgaller, M. L., and Ksander, B. R. *Expression of MAGE genes in ocular melanoma cell lines.* J.Immunother.(1997.) 1997. 20:265-275.
28. Waard-Siebinga, I., Blom, D. J., Griffioen, M., Schrier, P. I., Hoogendoorn, E., Beverstock, G., Danen, E. H., and Jager, M. J. *Establishment and characterization of an uveal-melanoma cell line.* Int.J.Cancer 1995. 62:155-161.
29. Kan-Mitchell, J., Mitchell, M. S., Rao, N., and Liggett, P. E. *Characterization of uveal melanoma cell lines that grow as xenografts in rabbit eyes.* Invest Ophthalmol.Vis.Sci. 1989. 30:829-834.
30. Luyten, G. P., Naus, N. C., Mooy, C. M., Hagemeyer, A., Kan-Mitchell, J., Van Drunen, E., Vuzevski, V., De Jong, P. T., and Luiders, T. M. *Establishment and characterization of primary and metastatic uveal melanoma cell lines.* Int.J.Cancer 1996. 66:380-387.
31. Verbik, D. J., Murray, T. G., Tran, J. M., and Ksander, B. R. *Melanomas that develop within the eye inhibit lymphocyte proliferation.* Int.J.Cancer 1997. 73:470-478.
32. Melis, M., Forrer, F., Capello, A., Bijster, M., Bernard, B. F., Reubi, J. C., Krenning, E. P., and de Jong, M. *Up-regulation of somatostatin receptor density on rat CA20948 tumors escaped from low dose [(177) Lu-DOTA(0),Tyr(3)]octreotate therapy.* Q.J.Nucl.Med.Mol.Imaging 2007. 51:324-333.
33. Naus, N. C., Verhoeven, A. C., Van Drunen, E., Slater, R., Mooy, C. M., Paridaens, D. A., Luyten, G. P., and de Klein, A. *Detection of genetic prognostic markers in uveal melanoma biopsies using fluorescence in situ hybridization.* Clin.Cancer Res. 2002. 8:534-539.
34. Hopman, A. H., Ramaekers, F. C., Raap, A. K., Beck, J. L., Devilee, P., van der, P. M., and Vooijs, G. P. *In situ hybridization as a tool to study numerical chromosome aberrations in solid bladder tumors.* Histochemistry 1988. 89:307-316.
35. van Dekken, H., Pizzolo, J. G., Reuter, V. E., and Melamed, M. R. *Cytogenetic analysis of human solid tumors by in situ hybridization with a set of 12 chromosome-specific DNA probes.* Cytogenet.Cell Genet. 1990. 54:103-107.
36. Reubi, J. C., Schaer, J. C., and Waser, B. *Cholecystokinin(CCK)-A and CCK-B/gastrin receptors in human tumors.* Cancer Res. 1997. 57:1377-1386.
37. Bodei, L., Hofland, L. J., Feron, D., Mooy, C. M., Kros, J. M., Paridaens, D. A., Baarsma, S. G., Ferdeghini, M., Van Hagen, M. P., Krenning, E. P., and Kwekkeboom, D. J. *In vivo and in vitro detection of dopamine d2 receptors in uveal melanomas.* Cancer Biother.Radiopharm. 2003. 18:895-902.

38. Ferrara, N., Gerber, H. P., and LeCouter, J. *The biology of VEGF and its receptors*. *Nat.Med.* 2003. 9:669-676.
39. Bustin, S. A. *Absolute quantification of mRNA using real-time reverse transcription polymerase chain reaction assays*. *J.Mol.Endocrinol.* 2000. 25:169-193.
40. Zuidervaart, W., van der Velden, P. A., Hurks, M. H., van Nieuwpoort, F. A., Out-Luiting, C. J., Singh, A. D., Frants, R. R., Jager, M. J., and Gruis, N. A. *Gene expression profiling identifies tumour markers potentially playing a role in uveal melanoma development*. *Br.J.Cancer* 2003. 89:1914-1919.
41. Rubin, H. *The role of selection in progressive neoplastic transformation*. *Adv.Cancer Res.* 2001. 83:159-207.
42. Kujala, E., Makitie, T., and Kivela, T. *Very long-term prognosis of patients with malignant uveal melanoma*. *Invest Ophthalmol.Vis.Sci.* 2003. 44:4651-4659.
43. Eskelin, S., Pyrhonen, S., Summanen, P., Prause, J. U., and Kivela, T. *Screening for metastatic malignant melanoma of the uvea revisited*. *Cancer* 1999. 85:1151-1159.
44. *Assessment of metastatic disease status at death in 435 patients with large choroidal melanoma in the Collaborative Ocular Melanoma Study (COMS): COMS report no. 15*. *Arch.Ophthalmol.* 2001. 119:670-676.
45. Lorigan, J. G., Wallace, S., and Mavligit, G. M. *The prevalence and location of metastases from ocular melanoma: imaging study in 110 patients*. *AJR Am.J.Roentgenol.* 1991. 157:1279-1281.
46. Aoyama, T., Mastrangelo, M. J., Berd, D., Nathan, F. E., Shields, C. L., Shields, J. A., Rosato, E. L., Rosato, F. E., and Sato, T. *Protracted survival after resection of metastatic uveal melanoma*. *Cancer* 2000. 89:1561-1568.
47. Eskelin, S., Pyrhonen, S., Summanen, P., Hahka-Kemppinen, M., and Kivela, T. *Tumor doubling times in metastatic malignant melanoma of the uvea: tumor progression before and after treatment*. *Ophthalmology* 2000. 107:1443-1449.
48. Moody, T. W., Chan, D., Fahrenkrug, J., and Jensen, R. T. *Neuropeptides as autocrine growth factors in cancer cells*. *Curr.Pharm.Des* 2003. 9:495-509.
49. Zia, H., Hida, T., Jakowlew, S., Birrer, M., Gozes, Y., Reubi, J. C., Fridkin, M., Gozes, I., and Moody, T. W. *Breast cancer growth is inhibited by vasoactive intestinal peptide (VIP) hybrid, a synthetic VIP receptor antagonist*. *Cancer Res.* 1996. 56:3486-3489.
50. Jiang, S., Koprass, E., McMichael, M., Bell, R. H., Jr., and Ulrich, C. D. *Vasoactive intestinal peptide (VIP) stimulates in vitro growth of VIP-1 receptor-bearing human pancreatic adenocarcinoma-derived cells*. *Cancer Res.* 1997. 57:1475-1480.
51. Lilling, G., Wollman, Y., Goldstein, M. N., Rubinraut, S., Fridkin, M., Brenneman, D. E., and Gozes, I. *Inhibition of human neuroblastoma growth by a specific VIP antagonist*. *J.Mol.Neurosci.* 1994. 5:231-239.
52. Reubi, J. C. *Peptide receptors as molecular targets for cancer diagnosis and therapy*. *Endocr.Rev.* 2003. 24:389-427.