



Universiteit
Leiden
The Netherlands

Cochlear imaging in the era of cochlear implantation : from silence to sound

Verbist, B.M.

Citation

Verbist, B. M. (2010, February 10). *Cochlear imaging in the era of cochlear implantation : from silence to sound*. Retrieved from <https://hdl.handle.net/1887/14733>

Version: Corrected Publisher's Version

License: [Licence agreement concerning inclusion of doctoral thesis in the Institutional Repository of the University of Leiden](#)

Downloaded from: <https://hdl.handle.net/1887/14733>

Note: To cite this publication please use the final published version (if applicable).

6

Cochlear Coordinates in Regard to Cochlear Implantation: a Clinically Individually Applicable 3-dimensional CT-based Method

BM Verbist, RMS Joemai, JJ Briaire,
WM Teeuwisse, WJH Veldkamp, JHM Frijns

Otology & Neurotology, in press

Abstract

Setting: Cochlear implant/tertiary referral center.

Subjects: 25 patients implanted with an Advanced Bionics HiRes90K HiFocus1J CI.

Study Design/main outcome measures: A 3-dimensional cylindrical coordinate system is introduced using the basal turn of the cochlea as the x,y-plane and the center of the modiolus as the z-axis. The 0°-angle is defined by the most lateral point of the horizontal semicircular canal. It is applied to both pre-and postoperative CTs in 25 patients. The angular position of the round window (RW) is examined. Interobserver reproducibility is tested by localization of all electrode contacts within the coordinate system. To observe realignment over time electrode coordinates in postoperative images were projected on preoperative images. Additionally, comparison to existing imaging-related coordinate systems was made.

Results: The angular position of the center of the round window is $34.6^{\circ} \pm 0.4^{\circ}$ (SD) with an intraclass coefficient (ICC) of 1.00. The ICC for interobserver reproducibility of the 16 electrode contacts ranged from 0.74-1 for the rotational angle (φ) and 0.77-1 for the distance to the modiolus (ρ). In 21 out of 25 patients a perfect match or minimal displacement of up to 3 electrode contacts was seen. Comparison to existing systems showed good correlation.

Conclusion: A 3 dimensional cochlear coordinate system easily applicable in clinical patients is described, which fulfills the requirements set by an international consensus.

Introduction

Imaging of cochlear implants (CI) has become more demanding over the past decades. Whereas in the early years imaging served for confirmation of the intracochlear position and integrity of an implant, nowadays far more detailed information is sought for. The results of CI regarding speech perception vary considerably between implantees. Parameters known to influence the performance are duration of deafness, preoperative speech recognition abilities, age at implantation, electrode design and speech encoding strategies. [1-4] A recent report also indicated that electrode location and insertion depth are of major influence on the performance. [5] These have been studied intensely by amongst others histopathologists, physicist and ENT surgeons. To better understand the role of the positioning of electrode contacts along the organ of Corti it now becomes important to correlate histopathological *ex vivo* studies [6], computer simulations [7] and animal studies [8] with clinical imaging studies. The imaging parameters of importance are insertion depth and electrode contact – to –modiolar distance. Recently also the amount of cochlear trauma induced by electrode insertion has become an area of interest. To evaluate this high resolution volume imaging is required to obtain as much anatomical detail as possible as well as a cochlear coordinate system that can be applied in all clinical patients and renders data comparable to results in all fields of research involved. Such a coordinate system has to fulfill several requisites, which were formulated in 2 consensus meetings held by researchers with a background in the various fields of inner ear research as well as representatives of the different manufacturers of cochlear implants. [9,10] The panel agreed upon a 3-dimensional cylindrical coordinate system with its x,y-plane along the basal turn and the z-axis through the center of the modiolus. The 0-degree reference point should be related to the round window. Additionally the coordinate system must be applicable on both implanted and non implanted ears. In such a system all spatial information of the cochlea and the implant are present and the insertion depth of an implant can be expressed in angular measurements. Thus it can be used to examine prediction of optimal insertion depth thereby providing direct information to the surgeon. Post-operatively it provides a mean for assessment of cochlear trauma due to insertion and optimization of implant fitting based on its position within the cochlea. The first imaging related coordinate system has been described by Xu et al. [11] They applied a 2-dimensional coordinate system to conventional radiographs (cochlear view). Skinner et al. [12] developed a method for

application of a 3-dimensional coordinate system to CT images making use of fusion with very high resolution images of a template temporal bone.

Our goal was to develop an easily applicable 3-dimensional coordinate system for the assessment of the cochlea in individual clinical patients without the use of a predefined template and examine whether it fulfills the requirements set by the consensus panel. The coordinate system's applicability and the inter -and intraobserver reproducibility will be examined on multi detector row computed tomography (MDCT) images of 25 patients. The results are compared to coordinate systems described by Cohen and Xu and Skinner and coworkers. [11-14]

Materials and Methods.

Patients

First 25 patients were selected in alphabetical order from the cochlear implant database at our institution within the period October 2006 to June 2007. All patients were treated for severe sensorineural hearing loss (SNHL) or deafness with cochlear implantation (17 on the right side, 8 on the left). The age ranged from 1 year and 7 months to 83 years. Duration of deafness before implantation ranged from 1 to 58 years. One patient had a congenital ear malformation (incomplete partitioning and enlarged vestibular aqueduct. The etiologies of deafness included meningitis (n=3), nonsyndromic familial (n=8), nonsyndromic congenital (n=4), syndromic congenital (n=1), congenital infections (rubella and lues) (n=2), (acoustic) trauma (n=1), otosclerosis (n=1), progressive SNHL (n=2), Meniere disease (n=2) and of unknown origin (n=1). Subjects received a HiRes90K HiFocus 1J cochlear implant (Advanced Bionics, Sylmar, California, USA).

Image acquisition and reconstruction

All patients (n=25) underwent preoperative computer tomography (CT) scanning as part of the standard work up for cochlear implantation. Postoperative scans were obtained 1 day after the implantation of a HiRes90K HiFocus 1J electrode array. This electrode array consists of 16 electrode contacts, with contact 1 at the apex and contact 16 at the base of the electrode. The scans were performed on a multi detector row CT (Aquilion 4 or 16, Toshiba Medical Systems, Otawara, Japan) using the following parameters for both scanners: 4 X 0.5mm section thickness; 0.5 seconds rotation time; 0.75 pitch

factor; 120 kV tube voltage; 150mA tube current; and a 240mm scan field-of-view (FOV) as described by Verbist et al. [15] Images with a nominal thickness of 0.5mm were reconstructed by using a 0.3mm reconstruction increment, 90mm reconstruction FOV, 512 X 512 matrix and a high resolution reconstruction kernel. Multiplanar reconstructions (MPR) were obtained in preoperative scans and in postoperative scans (n=25). The MPRs were defined by a line parallel through the center of the modiolus and an orthogonal line parallel to the basal turn of the cochlea; this emulates the cochlear view as described by Xu and Cohen. [11,13,14] The MPRs were stored as consecutive slices with a slice thickness of 0.5mm. On these images the 3-dimensional cylindrical coordinate system was applied.

3D coordinate system and its implementation in computed tomography

Using an in-house developed MATLAB-software (MATLAB R2006a, MathWorks, Novi, Mich) program the 3-dimensional cylindrical coordinate system was applied to the MPRs of the cochleovestibular system. To define the coordinate system the most lateral point of the horizontal semicircular canal is registered by the user, this serves as a landmark for the 0° angle. (figure 1) By scrolling through the images the slice on which the modiolus is visualized the last time is identified and used to set the origin of the z-axis (at the level of the helicotrema, as agreed in the consensus). Positions indicated by the user within the cylindrical coordinate system are expressed in angular position (φ) and the radial distance (ρ).

Relationship between the organ of Corti and the chosen 0°-angle in the 3D coordinate system

The relationship between the defined 0°- baseline and the most basal part of the organ of Corti was examined. Since the organ of Corti itself cannot be directly visualized, the round window – known to have a fairly stable relationship to the end of the organ of Corti [16] – was used as a point of reference. The anterior and posterior lip of the round window were marked on all preoperative scans (n=25) by 4 observers and their position within the coordinate system was stored by the program. The values for the center of the round window were calculated ($\text{angle}_{\text{posterior lip}} + \text{angle}_{\text{anterior lip}}/2$).

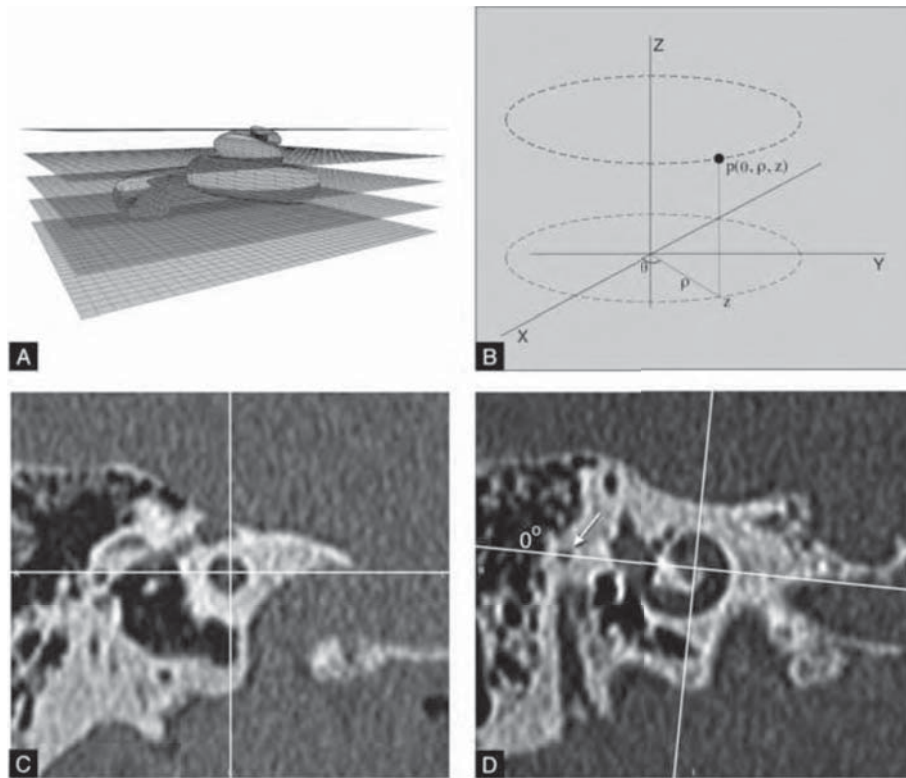


Figure 1. CT-based 3D cochlear coordinate system: a stack of reformatted CT images is made along the plane of the cochlear basal turn as shown schematically in (A). A 3D cylindrical coordinate system (B) can then be applied: the z-axis is placed through the modiolus and the 0° -angle is defined by the most lateral point of the horizontal SCC (arrow) (C, D).

Reproducibility of the CT-based 3D-coordinate system (interobserver)

To test the inter observer reproducibility of the coordinate system 4 observers applied the 3-dimensional coordinate system on all postoperative scans. Next the center of the 16 electrode contacts was marked and their position within the coordinate system was stored. The mean values and standard deviations were calculated over all observers.

Reproducibility of CT-based 3D-coordinate system over time (realignment)

In order to test the realignment of the newly applied coordinate system electrodes registered in the postoperative images were projected in the preoperative images. First the 3D coordinate system was applied to the postoperative scans and all 16 contacts

were marked. The slice on which the contact is optimally visualized was chosen and the center of the contact was indicated with a circle. Next the coordinate system was applied to the preoperative scan and the colour-coded markers were inserted. (figure 2) The resulting images were graded from I to III: a) grade I if the center of the contacts projected in the cochlear lumen, b) grade II if the center of 1 or more contacts project on the border of the cochlear lumen and c) grade III in case the center of 1 or more contacts project outside the cochlear lumen onto the otic capsule.

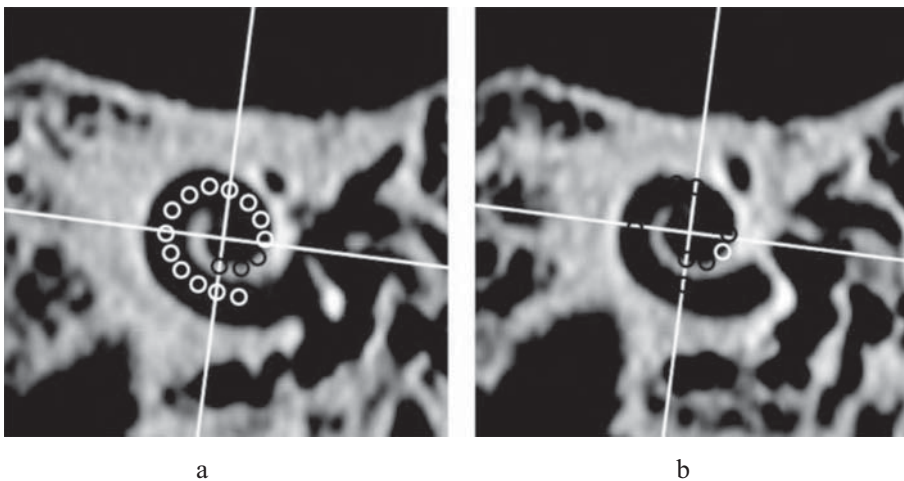


Figure 2: realignment of the CT-based 3D cochlear coordinate system: markers indicating the position of 16 electrode contacts were obtained from postoperative images and inserted into preoperative CT images (white: contacts marked in the current image, black: contacts marked on another image). In (a) all white markers project in the cochlear lumen (grade 1), corresponding to a perfect fit of the coordinatessystem applied on pre-and postoperative images. In (b) the center of the white marker projects outside the cochlear lumen (grade 3).

Statistical analysis

Interobserver variability was evaluated by two-way ANOVA analysis with random effects. Both the observers and the patients were modeled as random variable. Accordingly, the intraclass correlation coefficient (ICC) was calculated. The ICC expresses the variance by patients (due to variation between patients) as a proportion of the total variance (i.e. the sum of the patients' variance and the observers' variance). The ICC is a measure

of repeatability. Ideally, the ICC coefficient is close to 1 meaning that the variation by observers is low compared to the variation between patients.

Correlation to coordinate system described by Xu and Cohen

To investigate the relationship between the described method and existing methods the coordinate system as used in cochlear view [14] was applied to the preoperative CT datasets. To obtain an image comparable to x-ray images on which this 2-dimensional coordinate system is applied, a thick averaged MPR including the total cochleovestibular system was reconstructed. To account for variations in cochlear size mean spirals of the inner and outer walls of the scala tympani (obtained from Silastic[®] molds of temporal bones) and of the outer wall of the otic capsule (processed from digitized serial sections of a cochlea) are fitted to the cochlea in CView[®]. These mean spiral wall functions were made available by L Cohen and incorporated in newly developed software in MATLAB. The registered spiral of the outer wall of the otic capsule was scaled and rotated to obtain a best fit on the thick averaged MPRs of preoperative scans of each patient. The center of this spiral determines the z-axis. Next the apex of the superior semicircular canal and the estimated center of the vestibule were marked to apply the x,y-axes. (figure 3) Also the new defined cylindrical coordinate system was applied on the thick averaged MPR placing the x-axis through the superior SCC. Both the translation of the z-axis and the angular distance between the baseline 0°-angles of both coordinate systems were calculated. Measurements were performed by 3 observers.

Correlation to coordinate system described by Skinner et al

In order to compare the position of our 3D coordinate system to the method described by Skinner et al. [12] our CT datasets were analyzed by T Holden. The software package used, included a recording point at the center of the round window. In this way the difference between the 0° degree starting point used by Skinner et al. - defined as a line joining the midmodiolar axis in the middle of the cochlear canal entry – and the center of the round window were registered. Also the position of electrode contacts 1 and 16 were marked and stored. Using the φ of the round window in both coordinate systems a correction factor was determined for each individual patient. This correction factor was applied on the electrode contacts to achieve normalized electrode contact positions which enable comparisons of results in both coordinate systems. The difference between the two systems was determined for electrode contacts 1 and 16.




Figure 3. Application of the coordinate system described by Cohen, Xu and coworkers on our datasets: mean spiral cochlear wall functions were applied to a thick averaged MPR of a preoperative CT-dataset showing anatomical landmarks such as the superior SCC and the vestibule in 1 image. The center of outer wall spiral determines the z-axis. A line drawn through the superior SCC and vestibule determines the x,y-axes.

Results

Relationship between the round window and the chosen 0° -angle in the 3D cylindrical coordinate system

Figure 4a shows the mean rotational angle from the horizontal SCC to the calculated center point of the round window per observer. To evaluate the inter rater agreement two-way ANOVA analysis was used and a perfect agreement (ICC of 1.00) was found. The mean rotational angle (\pm -SD) was $34.6 \pm 0.4^\circ$ (range 28.3 - 40.7°).

The mean vector length (\pm -SD) from the z-axis to the calculated center of the round window was 5.92 ± 0.09 mm (range 5.29 - 6.52 mm, ICC of 0.72) (figure 4b).

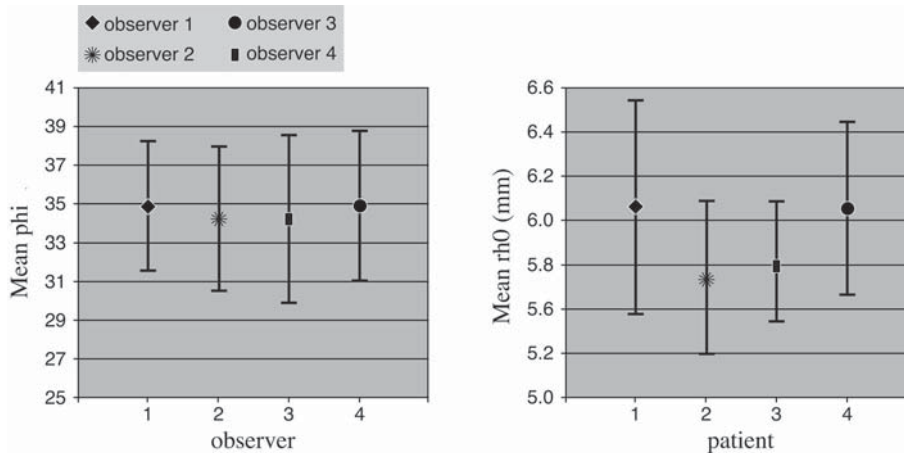


Figure 4. Mean angulation (a) and vector length (b) of the calculated center point of the round window for 4 observers. Error bars indicate the standard deviation.

Reproducibility of the CT-based 3D-coordinate system

Using two-way ANOVA analysis the ICC for each of the 16 electrode contacts localized by the 4 observers was calculated. The results are graphically shown in figure 5 a, b. ICC values for ϕ range from 0.74 (ϕ of contact 16) to 1 and the ICC for ρ ranges from 0.77 to 1.

Reproducibility of the CT-based 3D-coordinate system over time (realignment)

On postoperative scans all contacts showed an intracochlear position. After fusion of the electrode position and the preoperative scans 12 out of 25 patients showed a perfect match of preoperative and postoperative images (grade 1). In 9 patients minimal partial projection of 1 to 3 contacts outside the cochlear lumen were seen (grade 2). Almost all of those contacts were located at the apex or in the second half of the basal turn of the cochlea. Four patients were graded stage III since the center of 1 or more contacts projected outside the lumen. In 3 cases this concerned the most apical electrode contact and in one case contact 8.

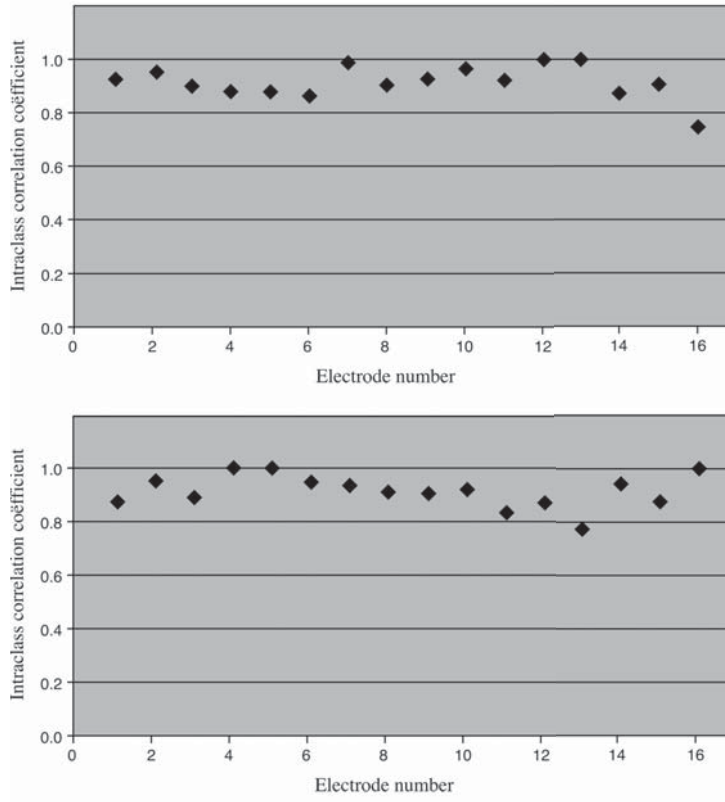


Figure 5. Reproducibility of the CT-based 3D-coordinate system: the ICC for ϕ (a) and ρ (b) of 16 electrode contacts localized by 4 observers.

Correlation to coordinate system described by Xu and Cohen

A systematic difference with minimal spreading between the two methods was found. Measurements obtained by 3 observers revealed a mean difference in orientation of $23.3^\circ \pm 2.3^\circ$. The mean difference in translation was $0.38\text{mm} \pm 0.14\text{mm}$ (SD).

Correlation to coordinate system described by Skinner et al

The mean difference (\pm SD) between the position of contact 1 and contact 16 measured by the 2 methods on the same patient data was $-3.29^\circ \pm 11.9$ and $3.96^\circ \pm 6.9$ SD, respectively.

Discussion

The cochlea is a complex structure with interindividual differences in size and form. Precise individualized assessment of its morphology has become of utmost importance for research applications and clinical patient care in regard to cochlear implantation. If this information can be obtained preoperatively the choice of an implant as well as the surgical approach and insertion depth could be tailored to the patients needs. Postoperative precise documentation of the location of an implant in relation to the 3-dimensional cochlear anatomical structures would be helpful to evaluate for insertion trauma to the cochlea and to optimize the function of the implant. In this study a 3-dimensional CT-based coordinate system which is easily applicable in daily clinical practice is tested and validated in comparison with existing imaging-based cochlear coordinate systems.

The coordinate system is linked to CT images. Computed tomography enables to image a volume and thus to add the third dimension into imaging studies. Moreover computed tomography provides detailed direct visualization of the cochlear anatomy. Thus, the anatomical landmarks to define the coordinate system can be discerned. Provided (near) – isotropic imaging is done, multiplanar reconstructions can be performed without loss of image quality. In this way the x, y – axes are placed in the plane of the basal turn of the cochlea emulating the cochlear view described by Marsh and Xu. [11,17] Since the CT-derived cochlear view is the result of post processing, malpositioning of the patient can be corrected for and the images can be reformatted until the desired result is obtained. The third dimension is added by a z-axis placed through the center of the modiolus at its tightest point in the apical 1.5 turns of the cochlea. In this 3-dimensional cylindrical coordinate system all spatial information is represented. The fact that the coordinates are individually applied without the use of any template ensures that eventual variations in the direction of the z-axis are taken into account. For indeed, it has been shown in a micro-CT study that the elevation (z-coordinate) of the basilar membrane along the cochlear duct has a non-monotonous path and varies between ears. [18]

The 0-degree reference angle was determined at the most lateral point of the horizontal semicircular canal. In this, the coordinate system differs from others reported in literature. [12,14,19] Ideally the 0°-baseline of the x-axis should be chosen at the end of the basilar membrane (BM). In clinical imaging however, the basilar membrane cannot

be visualized directly. The round window, known to have a close relationship to the end of the basilar membrane, could serve as a nearby anatomical landmark. Although the round window can be clearly identified on CT-images, some problems arise in clinical situations where only a postoperative scan is available. The normal anatomy can be distorted according to the surgical approach of the cochleostomy. Whereas in most cases the cochleostomy is performed anteriorly to the round window, some surgeons prefer to remove the anterior lip of the round window as well. For a-traumatic insertion a direct round window approach is favored. Therefore a well-defined anatomical structure with a close relationship to, but outside the cochlea was chosen: the most lateral point of the horizontal SCC. In this way the coordinate system becomes independent of surgical approach. Moreover, this part of the semicircular canal runs approximately perpendicular to the plane of the reconstructed axial oblique image. The position of the 0° – landmark will therefore only be minimally affected by the chosen slice level on which it is marked. Our data show an angular distance of this landmark to the center of the round window of $34.6 \pm 0.4^\circ$ (SD) with an excellent interobserver agreement (ICC 1.00). A possible drawback of this approach is that it might be difficult to be applied in severe cases of ossifying labyrinthitis with total obliteration of the vestibule and semicircular canals. However in our experience these cases are rarely good candidates for implantation of a single array cochlear implant. Also in patients with severe congenital inner ear malformations the anatomical landmarks will be obscured or absent. In such cases neither of the image based coordinate systems, referring to the vestibular system, will render reliable data. The standard deviation of the mean vector length to the round window (0.09 mm) corresponds to about 2 pixels. Given the the total size of the round window this seems within clinically acceptable limits (figure 6).

To be eligible as a cochlear coordinate system the reproducibility and realignment of a grid system also has to be solid. The interobserver reproducibility showed good to excellent intra class coefficients. To establish the reproducibility of the CT-based method in one individual over time, inpatient comparisons were made by matching preoperative and postoperative images. Our results show a perfect match or minimal displacement of up to 3 electrode contacts in 21 out of 25 patients. All contact centers overlapping the lateral wall of the cochlea are located at the apical side of the electrode. A possible explanation is that minimal overlay along the lateral wall might be the result of volume averaging. Additionally, the size of the cochlear lumen decreases gradually. Using a slab thickness of 0.5mm in the MPRs, a slight shift in the fusion of pre -and

postoperative images may result in a mismatch at the level of the most apical electrode contact.

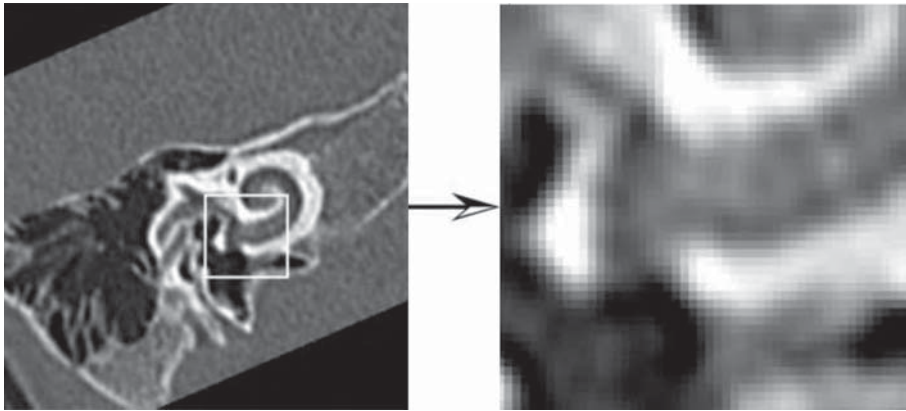


Figure 6. A magnification of a CT image at the level of the round window illustrates the relation between the pixelsize and the size of the round window.

Above mentioned results show that reliable and reproducible measurements of insertion depth and electrode location can be made. For patient-specific preoperative planning estimations of optimal (angular) insertion depth can be made on preoperative CT studies.

To ensure comparability of results obtained with our method and data from previous and forthcoming studies based on other coordinate systems we applied landmarks as described in Cview[®] to our data and had run them through the softwarepackage described by Skinner and coworkers. In the Cview[®] method the 0° rotation angle refers to the basilar membrane. The mean rotation between the 2 systems is $23.3^\circ \pm 2.3^\circ$. This is in line with the expected result based on the reported relationship between the round window and the BM of 10.3° by Cohen and the angular distance of $34.6^\circ \pm 0.4$ between the most lateral point of the horizontal SCC and the round window. The mean difference in translation between the 2 methods is beyond the maximal resolution of the scanner.

In comparison to the method described by Skinner et al mean contact positions differed $-3.29^\circ \pm 11.9^\circ$ SD for contact 1 and $3.96^\circ \pm 6.9^\circ$ SD for contact 16. The wider standard deviation at the apex might result from slight differences in the position of

the z-axis. Differences due to this will become more pronounced at deeper insertion angles where the distance of the electrode contacts to the modiolus (ρ) becomes smaller. Whereas the definition of the z-axis is based on 1 template in the method described by Skinner et al, the CT-based 3D-coordinate system uses individually defined z-axes. Keeping in mind the inter-individual variations of cochlear form and size this might be the underlying cause for this observation.

In this study an in-house developed custom made application in MATLAB was used for automatization of measurements. However, the presented CT-based coordinate system is easily applicable in daily clinical practice. In a recent study it has been shown that multislice CT scanners of major CT scanner manufacturers meet the technical requirements to visualize cochlear implants. The visualization of individual electrode contacts depends on scanner software (available range of gray values (Hounsfield units)) and the inter-contact distance. [20] Viewing stations feature oblique multiplanar reconstruction possibilities. Once the “cochlear view” reconstruction is made the most lateral point of the horizontal semicircular canal is looked for by scrolling through the volume of images. From this point angular measurements can be made and good estimates of optimal (on preoperative images) or achieved (on postoperative images) insertion depth can be obtained.

Conclusion

A 3-dimensional cochlear coordinate system easily applicable on both pre- and postoperative images of commercially available MSCT scanners without the need of cochlear templates and not influenced by postoperative round window distortion is presented. This coordinate system fulfills the requirements set by an international consensus. Taking into account a correction factor of $34.6^\circ \pm 0.4^\circ$ (SD) to the center of the round window, comparison to existing imaging based coordinate systems is possible.

Acknowledgment

We thank Laurie Cohen and Tim Holden for their advice and for making comparison to their respective coordinate systems possible. We also thank Tessa de Jager for her help in analyzing the data.

Reference List

1. Naito Y, Hirano S, Honjo I, et al. Sound-induced activation of auditory cortices in cochlear implant users with post- and prelingual deafness demonstrated by positron emission tomography. *Acta Oto-Laryngol* 1997;117:490-496
2. Nishimura H, Hashikawa K, Doi K, et al. Sign language 'heard' in the auditory cortex. *Nature* 1999;397:116
3. Gomma NA, Rubinstein JT, Lowder MW, Tyler RS, Gantz BJ. Residual speech perception and cochlear implant performance in postlingually deafened adults. *Ear Hear* 2003;24:539-544
4. Rubinstein JT, Parkinson WS, Tyler RS, Gantz BJ. Residual speech recognition and cochlear implant performance: effects of implantation criteria. *Am J Otol* 1999;20:445-452
5. Finley CC, Holden TA, Holden LK, et al. Role of electrode placement as a contributor to variability in cochlear implant outcomes. *Otol Neurotol* 2008;29:920-928
6. Stakhovskaya O, Sridhar D, Bonham BH, Leake PA. Frequency map for the human cochlear spiral ganglion: implications for cochlear implants. *J Assoc Res Otolaryngol* 2007;8:220-233
7. Briaire JJ, Frijns JH. The consequences of neural degeneration regarding optimal cochlear implant position in scala tympani: a model approach. *Hear Res* 2006;214:17-27
8. Shepherd RK, Hatsushika S, Clark GM. Electrical-Stimulation of the Auditory-Nerve - the Effect of Electrode Position on Neural Excitation. *Hear Res* 1993;66:108-120
9. Verbist BM, Skinner MW, Cohen LT, et al. Consensus panel on a cochlear coordinate system applicable in histological, physiological and radiological studies of the human cochlea. *Otology & Neurotology*, in press
10. Verbist BM, Briaire JJ, Ferarini L, et al. Pre- and postoperative assessment of cochlear implantees by means of multidetector row computed tomography . Conference on implantable auditory prostheses, Lake Tahoe, Ca, July 12-17, 2009.
11. Xu J, Xu SA, Cohen LT, Clark GM. Cochlear view: Postoperative radiography for cochlear implantation. *Am J Otol* 2000;21:49-56
12. Skinner MW, Holden TA, Whiting BR, et al. In vivo estimates of the position of advanced bionics electrode arrays in the human cochlea. *Ann Otol Rhinol Laryngol Suppl* 2007;197:2-24
13. Cohen LT, Xu J, Xu SA, Clark GM. Improved and simplified methods for specifying positions of the electrode bands of a cochlear implant array. *Am J Otol* 1996;17:859-865
14. Cohen LT, Xu J, Tycocinski M, Saunders E, Raja D, Cowan R. Evaluation of an X-ray analysis method: comparison of electrode position estimates with information from phase contrast X-ray and histology. 5th European Symposium on Paediatric Cochlear Implantation, Antwerp, Belgium, June 4-7, 2000.
15. Verbist BM, Frijns JHM, Geleijns J, van Buchem MA. Multisection CT as a valuable tool in the postoperative assessment of cochlear implant patients. *AJNR Am J Neuroradiol* 2005;26:424-429
16. Bredberg G. Cellular pattern and nerve supply of the human organ of Corti. *Acta Otolaryngol* 1968;Suppl 236:1-135

17. Marsh MA, Xu J, Blamey PJ, et al. Radiologic Evaluation of Multichannel Intracochlear Implant Insertion Depth. *Am J Otol* 1993;14:386-391
18. Verbist BM, Ferrarini L, Briaire JJ, et al. Anatomic considerations of cochlear morphology and its implications for insertion trauma in cochlear implant surgery. *Otol Neurotol* 2009;30:471-477
19. Kos MI, Boex C, Sigrist A, Guyot JP, Pelizzone M. Measurements of electrode position inside the cochlea for different cochlear implant systems. *Acta Oto-Laryngol* 2005;125:474-480
20. Verbist BM, Joemai RMS, Teeuwisse WM, Veldkamp WJH, Geleijns J, Frijns JHM. Evaluation of 4 multisection CT systems in postoperative imaging of a cochlear implant: A human cadaver and phantom study. *AJNR Am J Neuroradiol* 2008;29:1382-1388

