



Universiteit
Leiden
The Netherlands

Multimodality imaging of coronary artery bypass grafts

Salm, L.P.

Citation

Salm, L. P. (2006, November 7). *Multimodality imaging of coronary artery bypass grafts*. Retrieved from <https://hdl.handle.net/1887/4978>

Version: Corrected Publisher's Version

License: [Licence agreement concerning inclusion of doctoral thesis in the Institutional Repository of the University of Leiden](#)

Downloaded from: <https://hdl.handle.net/1887/4978>

Note: To cite this publication please use the final published version (if applicable).

CHAPTER 6

Validation of a high-resolution, phase contrast cardiovascular magnetic resonance sequence for evaluation of flow in coronary artery bypass grafts

Liesbeth P. Salm
Joanne D. Schuijf
Hildo J. Lamb
Jeroen J. Bax
Hubert W. Vliegen
J.Wouter Jukema
Ernst E. van der Wall
Albert de Roos
Joost Doornbos

Accepted for publication in J Cardiovasc Magn Reson

ABSTRACT

The aim was to validate a magnetic resonance high-resolution, phase-contrast sequence for quantifying flow in small and large vessels, and to demonstrate its feasibility to measure flow in coronary artery bypass grafts.

A breathhold, echo planar imaging (EPI) sequence was developed and validated in a flow phantom using a fast field echo (FFE) sequence as reference. In 17 volunteers aortic flow was measured using both sequences. In 5 patients flow in the left internal mammary artery (LIMA) and aorta was measured at rest and during adenosine stress, and coronary flow reserve (CFR) was calculated; in 7 patients vein graft flow velocity was measured.

In the flow phantom measurements, the EPI sequence yielded an excellent correlation with the FFE sequence ($r=0.99$; $p<0.001$ for all parameters). In healthy volunteers, aortic volume flow correlated well ($r=0.88$; $p<0.01$), with a minor overestimation. It was feasible to measure flow velocity in the LIMA and vein grafts of the 12 patients.

The high-resolution, breathhold MR velocity-encoded sequence correlated well with a free-breathing, FFE sequence in a flow phantom and in the aortae of healthy volunteers. Using the EPI sequence, it is feasible to measure flow velocity in both LIMA and vein grafts, and in the aorta.

INTRODUCTION

Coronary artery bypass grafting (CABG) is one of the therapeutic options in obstructive coronary artery disease. Over time, atherosclerosis may progress in these bypass grafts and graft stenosis may develop, requiring invasive angiography to assess the severity of the lesions. However, the hemodynamic consequences of the stenotic lesions cannot be assessed from angiography (1;2). Measurement of flow velocity and flow reserve by phase-contrast velocity-encoded cardiovascular magnetic resonance (CMR) has recently been demonstrated for the evaluation of vein graft disease (3;4). Imaging of arterial grafts remains challenging because of the small luminal diameter of the internal mammary arteries, and metal clip artefacts. Earlier studies demonstrated the feasibility to measure flow in left internal mammary artery (LIMA) grafts by free-breathing and breathhold CMR sequences, but these sequences generated a limited spatial and temporal resolution (5-7). The aim of the present study was to validate a recently developed velocity-encoded CMR sequence to measure flow velocity in small and large vessels, and to demonstrate its feasibility to measure flow in coronary artery bypass grafts.

METHODS

In Vitro Validation

In order to validate the velocity-encoded CMR sequence in small vessels, a calibrated flow simulator (UHDC flow simulator, Shelley Medical Imaging Technologies, London, Ontario, Canada) was used to create biphasic flow velocity patterns, such as observed in nonstenotic bypass grafts and coronary arteries, in a MRI compatible phantom. The design of the pump and its value in application for MR flow studies were described before (8;9). The simulator provided an ECG-signal to allow triggering by the MR-system. The phantom consisted of a cylindrical container filled with water, with a 4-mm-diameter glass tube running through the middle. The glass tube was connected to the flow simulator by two hoses, and filled with a blood-mimicking solution. The phantom was positioned in the bore of a 1.5 Tesla MRI scanner (Gyroscan ACS/NT, Philips Medical Systems, Best, the Netherlands) with Powertrak-6000 gradients (gradient strength 25mT/m, slow rate 100 T/m/s) and commercially available cardiac software (release 9). Scout scans of the glass tube were made, and a plane perpendicular to the tube was planned for the velocity measurements. A multishot echo planar imaging (EPI) velocity-encoded sequence yielded a field of view (FOV) of 60x150 mm with an acquisition matrix of 55x144 voxels. Per acquisition 55 k-lines were scanned. Multi-shot gradient echo EPI was performed by acquisition of 5 EPI-readouts twice per frame (Figure 6.1). For each time frame in the cardiac cycle a velocity-sensitive and a velocity-insensitive image was acquired, and for each image signals were averaged ($NE \times 2$), resulting in an acquisition time of 22 heartbeats. Number of phases to be acquired during the cardiac cycle was set to 30 by retrospective ECG-gating. The repetition time (TR), defined as the time to acquire 5 k-lines after one RF pulse, was 15 ms, rendering a temporal resolution of 30 ms ($2 \times TR$). Additional scan parameters were: echo time (TE) of 7 ms, in-plane resolution of 1.0x1.0 mm, interpolated to 0.29x0.29 mm by zero padding, slice thickness of 6 mm, flip angle of 40°, velocity encoding of 50-150 cm/s.

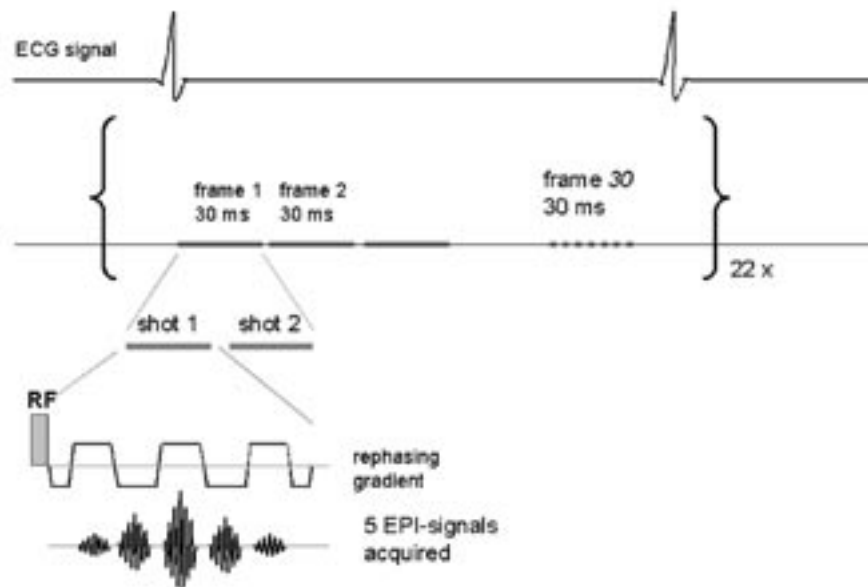


Figure 6.1.

Schematic presentation of the EPI sequence. Per heart beat 30 frames could be acquired, each consisting of two shots, each representing one radiofrequency pulse and 5 EPI-readouts. ECG-signal was recorded simultaneously for retrospective ECG-triggering.

Stepwise increasing velocities in a biphasic pattern resembling bypass graft flow were implemented in the simulator and subsequently imaged. The series of velocity measurements was repeated using a free-breathing fast field echo (FFE) sequence, previously validated at our institution (10), using the following parameters: TR/TE 5.5/3.5, FOV of 370 mm, RFOV 60%, acquisition matrix 77x128 voxels, temporal resolution of 30 ms, pixel size of 3x3 mm, interpolated to 1.45x1.45 mm, slice thickness of 6 mm, flip angle of 20°, retrospective ECG gating, scan duration of 256 heart beats. For determination of interstudy variability the velocity measurements were repeated using the EPI sequence.

Image analysis

Velocity image acquisition consisted of paired modulus and phase images. For the velocity analysis a region of interest (ROI) of 1 pixel (2.1 mm²) was placed in the center of the glass tube in each phase image for the free-breathing sequence, using FLOW software (version 4.0.4, Medis, Leiden, the Netherlands). Owing to the improved spatial resolution of the EPI sequence, 24 pixels (2.02 mm²) were selected in the center of the tube in order to compare the two sequences. The peak velocity was defined as the mean velocity in the ROI for each time frame. The average peak velocity (APV; cm/s) was then defined as the average velocity measured in the ROIs over the cardiac cycle. Systolic peak velocity (SPV; cm/s) and diastolic peak velocity (DPV; cm/s) were defined as the maximal peak velocity during the first and second peak, respectively.

In Vivo Validation

In 17 healthy volunteers aortic flow was measured using the EPI and FFE sequence. A scout scan in three planes of the thorax was made. Aortic flow was acquired in a transverse plane planned through the ascending aorta by both free-breathing FFE and EPI sequence. For this measurement FOV was increased to 370 mm in the EPI sequence, resulting in a voxel size of 2.6x2.6 mm, interpolated to 0.7x0.7 mm. All breathholds were initiated at end-expiration in order to avoid aortic flow changes due to high intrathoracic pressures (11).

Feasibility Study

In 10 healthy volunteers LIMA and aortic flow were measured using the EPI sequence. Two surface coils were used, one placed at the proximal native LIMA and one placed at the center of the thorax to measure aortic flow. First, a scout scan in three planes of the thorax was made. A transversal balanced turbo field echo (bTFE) survey scan of the proximal part of the LIMA was made to identify the arterial anatomy. The proximal portion of the LIMA was selected in order to avoid artefacts derived from metal clips in patients with LIMA grafts. The proximal part of the LIMA was scanned in plane in two perpendicular planes in order to plan a third plane orthogonally. The EPI sequence was applied to measure velocity in a single breathhold. The sequence validated in the phantom study was used. Then, aortic flow was acquired as described in the previous section.

In 5 randomly selected patients with LIMA grafts, who underwent coronary angiography because of recurrent chest pain, aortic and proximal LIMA graft flow was measured in the same manner. After acquiring the baseline aortic and LIMA flow, adenosine was administered intravenously in dosage of 140 µg/kg/min in order to achieve maximal hyperemia (12). Aortic and LIMA flow velocity scans were repeated during adenosine stress.

In 7 randomly selected patients with vein grafts, baseline flow velocity was measured. By means of the bTFE survey scan, vein grafts were visualized at the level of the ascending aorta. On two perpendicular survey images showing the graft in plane, a plane was planned perpendicular to the graft and velocity was obtained using the EPI sequence. Beforehand, the nature of the study was fully explained to the patients, and all patients gave informed consent. The study was approved by the medical ethics committee of our institution.

All patients underwent coronary angiography because of recurrent chest pain by a standard procedure prior to the CMR examination. The MR operators were blinded to the results of invasive angiography. Angiograms were evaluated by an experienced cardiologist for potential stenoses in the examined bypass grafts and recipient vessels. If more than one stenosis was present in either bypass graft or recipient vessel, the most severe stenosis was taken into account.

Image analysis

For the image analysis aortic and LIMA contours were traced by automatic contour detection, using FLOW 4.0.4 (Medis, Leiden, the Netherlands) (13;14). In the flow rate-

versus-time curves the area-under-the-curve was multiplied with the heart rate to obtain aortic and LIMA volume flow (ml/min). The maximal flow rate at systole and diastole were defined as the systolic peak flow (SPF; ml/s) and diastolic peak flow (DPF; ml/s), respectively. The diastolic-to-systolic flow ratio (DSFR) was defined as the ratio of DPF and SPF. The ratio of hyperemic to baseline volume flow was defined as coronary flow reserve (CFR). As values of LIMA flow are known to vary widely between individuals (5), LIMA flow was also expressed as a percentage of the aortic flow at rest and during stress.

For vein grafts it has been demonstrated previously that the accuracy of volume flow analysis and peak velocity analysis is similar (15). Therefore, only peak velocity analysis was performed, in which 4 pixels at the center of the vessel were selected and defined as the peak velocity for every phase in the cardiac cycle. APV, SPV, and DPV were derived from the velocity-versus-time curves, such as described for the flow simulator.

Statistical Analysis

Parameters were expressed as mean \pm SD. The velocity parameters, measured by the flow phantom, and the flow parameters, measured in healthy volunteers, were compared using Pearson correlation and Bland-Altman analysis. Interstudy variability was expressed as correlation and calculated as the mean difference divided by the mean of the two measurements. Baseline and stress values in LIMA grafts were compared using a paired Student t-test. A p-value <0.05 was considered significant.

RESULTS

In Vitro Validation

When comparing the FFE and EPI sequence with the flow simulator, an excellent correlation was demonstrated for APV ($y=1.06x-2.6$; $r=0.99$; $p<0.001$), as for SPV and DPV ($y=1.05x-2.1$; $r=0.99$ and $y=1.05x-1.3$; $r=0.99$; $p<0.001$). In the Bland-Altman analysis, the mean differences (95% limits of agreement) were for APV -1.26 cm/s (-2.89 to 0.36), for SPV -1.05 cm/s (-2.64 to 0.55), and for DPV 0.19 cm/s (-2.84 to 3.23), indicating good agreement. A good reproducibility of the EPI sequence was demonstrated, expressed by the following correlations: $y=x+0.2$ for APV, $y=x-0.5$ for SPV and $y=x+2.2$ for DPV ($r=0.99$ and $p<0.001$ for all correlations). Interstudy variabilities were -0.2% for APV, -2.4% for SPV, and 5.5% for DPV.

In Vivo Validation

In 17 healthy volunteers (mean age 30 years, range 20 to 60, male/female 7/10) aortic flow was measured by free-breathing FFE and breathhold EPI sequence. For 2 volunteers, image quality was insufficient due to inability to sustain the obligatory breathhold, and these individuals were excluded from further analysis. A good correlation was shown for the FFE and EPI sequences (Figure 6.2). The regression equation, $y=1.2x-301$, demonstrated a slight overestimation of volume flow, when the EPI sequence was used ($r=0.88$; $p<0.01$). The EPI sequence correlated well with the FFE sequence for SPF ($y=1.04x-21$; $r=0.94$; $p<0.001$). Bland-Altman analysis illustrated the overestimation of aortic flow with the EPI sequence with a mean difference of 560 ml/min (95% limits of agreement -872 to 1992). For SPF mean difference was -4.5 ml/s (95% limits of agreement -75.0 to 66.0).

Feasibility Study

In 10 volunteers native LIMA flow was adequately measured using the EPI sequence. Mean LIMA flow was 66.5 ± 22.3 ml/min (range 32.0 to 106.2), mean SPF was 5.2 ± 1.4 ml/s (range 3.1 to 7.3), and mean aortic flow was 5365 ± 1302 ml/min (range 3331 to 7493). When LIMA flow was expressed as percentage of aortic flow, the mean percentage was $1.2 \pm 0.4\%$ (range 0.6 to 2.0).

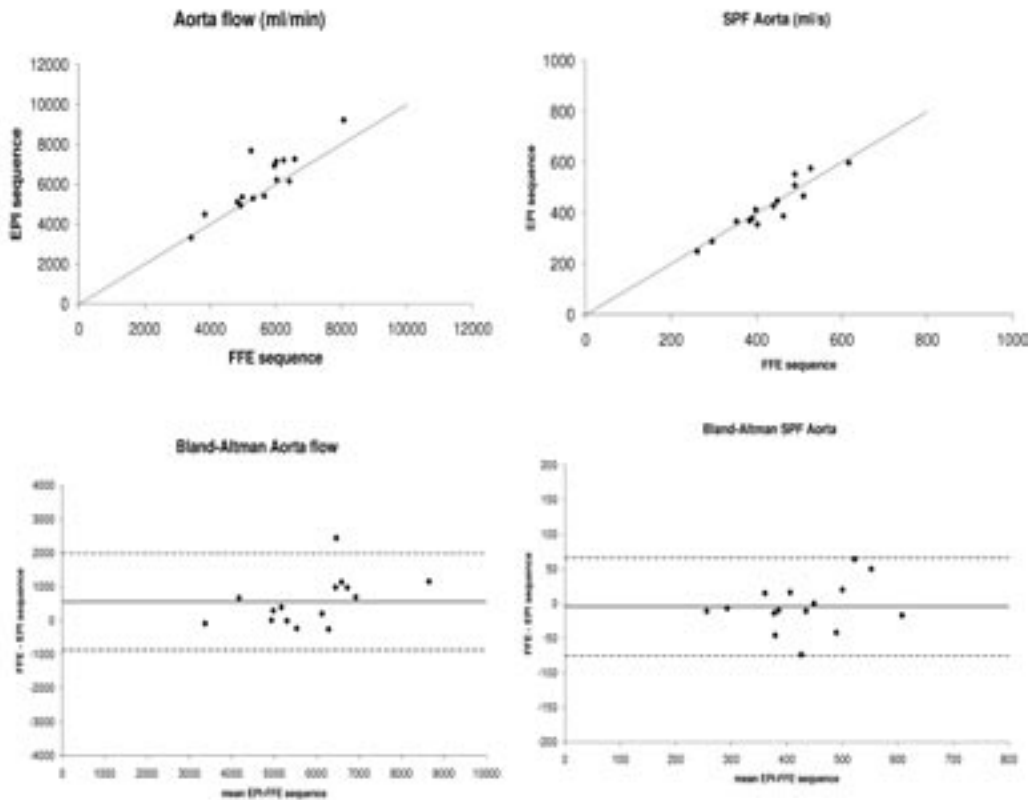


Figure 6.2.

Correlation and Bland-Altman analysis of the comparison of FFE and EPI sequence for aortic flow in healthy volunteers. Identity lines ($y=x$) are shown in the correlation plots in gray. In the Bland-Altman plots, solid lines represent the mean, and dotted lines represent the 95% limits of agreement.

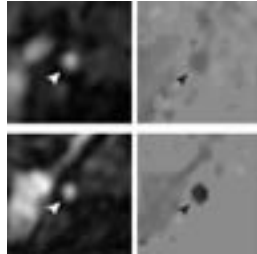


Figure 6.3. Modulus (left) and phase (right) images of a sequential LIMA graft (arrowheads) to anterolateral and obtuse marginal branch in diastole, acquired using the EPI sequence. Top images represent baseline flow velocity and bottom images flow velocity during adenosine stress.

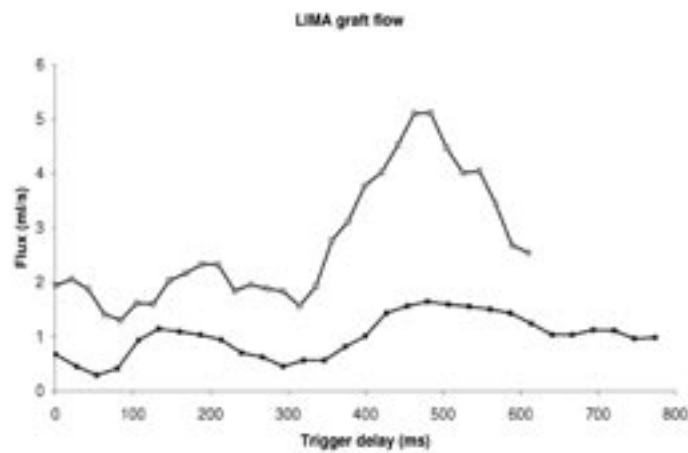


Figure 6.4. Flow curve of the LIMA graft depicted in Figure 3. Black squares represent the flow rate at baseline. Open squares characterize adenosine stress flow rate. LIMA volume flow was 58.3 ml/min at baseline and 159.5 ml/min during adenosine stress, resulting in a CFR of 2.7.

In 5 male patients (mean age 56 years, range 43 to 73) with 5 LIMA grafts, proximal LIMA graft and aortic flow were successfully measured at rest and during adenosine stress, see Figure 6.3. Grafts were anastomosed to the left anterior descending (LAD) artery (n=1), first diagonal branch and LAD (n=2), anterolateral branch and obtuse marginal (OM) branch (n=1). In one patient the LIMA was anastomosed to the first diagonal branch and LAD, and a free right IMA was anastomosed from the LIMA to the OM and posterior descending branch. Mean interval between bypass surgery and CMR examination was 48 months (range 8 to 104). A biphasic flow pattern was obtained in all grafts (Figure 6.4). The measured flow parameters are summarized in Table 6.1. All LIMA grafts were patent at coronary angiography. Stenoses in LIMA grafts or recipient vessels distal from the anastomosis were not observed.

In 7 male patients (mean age 67 years, range 57 to 75 years) flow velocity in 9 vein grafts at rest was obtained (mean time interval after CABG 9 years, range 5 to 15). Single vein grafts perfused the LAD (n=3), OM (n=2), or posterolateral branch (n=1). Sequential vein grafts were anastomosed to OM and posterior descending branch (n=3). The velocity parameters are presented in Figure 6.5. At coronary angiography 7 grafts had no significant stenosis ($\geq 50\%$), in 2 single grafts a diameter stenosis of 80% was observed. In concordance with previous studies (3;16), the velocity parameters of single vein grafts were lower than sequential vein graft values. Two grafts with significant stenosis showed low velocity values at rest. Using the EPI sequence it is feasible to measure flow velocity in both arterial and vein grafts.

DISCUSSION

In this study validation of a high-resolution, phase contrast CMR sequence was described. This sequence correlated well with a previously validated FFE sequence in a flow phantom and for aortic flow measured in healthy volunteers. In addition, the feasibility to measure LIMA and vein graft flow velocity using the proposed sequence was demonstrated.

In Vitro and in Vivo Validation

MR phase contrast imaging has successfully been used before to measure flow velocity in arterial and vein bypass grafts (3-7). In the current study an improved phase contrast EPI sequence was validated in vitro and in vivo against an established FFE sequence (10), and the feasibility to measure bypass graft flow velocity was demonstrated. The EPI sequence used segmented filling of k-space (factor 5), and had an in-plane resolution of 1.0x1.0 mm, interpolated to 0.29x0.29 mm, with a temporal resolution of 30 ms. The measurements were obtained at breathholding, and with the use of retrospective ECG-gating, data could be collected during the full cardiac cycle.

	Baseline	Stress
LIMA flow (ml/min)	37.1±13.9 (22.3-58.3)	101.1±45.6 (39.7-159.5) *
SPF LIMA (ml/s)	1.28±0.49 (0.70-2.03)	2.88±0.72 (2.33-4.05) *
DPF LIMA (ml/s)	1.03±0.42 (0.54-1.64)	2.79±1.55 (0.96-5.11) *
DSFR	0.89±0.44 (0.38-1.44)	1.03±0.70 (0.31-2.19)
Aortic flow (ml/min)	5142±901 (4116-6185)	6275±1208 (4237-7116)
SPF aorta (ml/s)	406±51 (334-473)	442±59 (397-524)
LIMA/aortic flow (%)	0.71±0.17 (0.52-0.94)	1.56±0.52 (0.94-2.27) †
CFR	2.70±0.88 (1.78-4.14)	

Table 6.1.

LIMA graft and aortic flow

*Results are presented as mean ± SD (range). LIMA= left internal mammary artery, SPF= systolic peak flow, DPF= diastolic peak flow, DSFR= diastolic-to-systolic flow ratio, CFR= coronary flow reserve. * p<0.05, † p<0.01.*

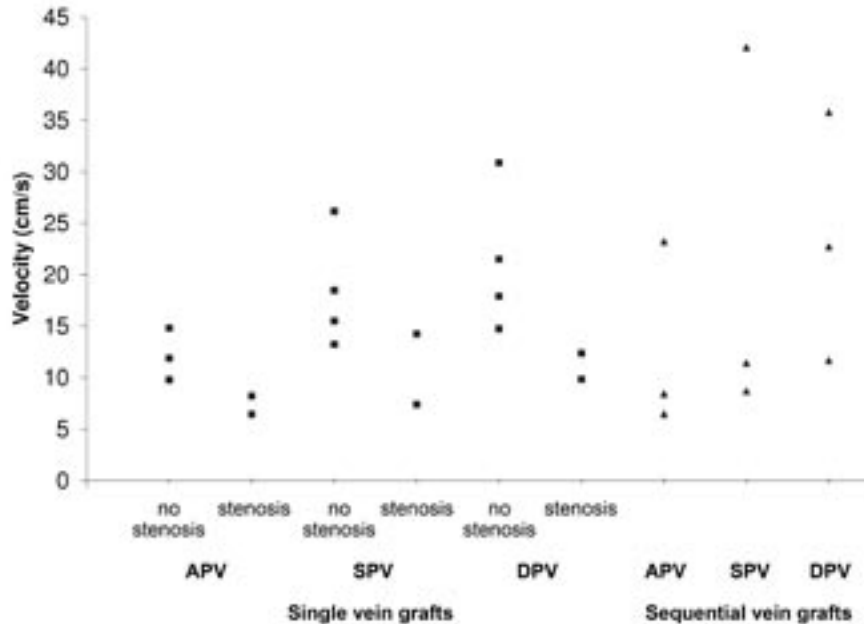


Figure 6.5.

Diagram of the velocity parameters, measured in the vein grafts. APV = average peak velocity, SPV = systolic peak velocity, DPV = diastolic peak velocity.

In comparison, spatial and temporal resolution of formerly established breathhold phase contrast sequences were 2.5x1.9 mm and 128 ms (6), 1.6x0.8 mm and 112 ms (7), 1.6x1.6 mm and 23 ms (3), and 0.9x1.5 mm and 125 ms(4), respectively. In LIMA grafts with a mean diameter of 2.42±0.45 mm (17), an improvement of 0.5 mm in in-plane spatial resolution is of important benefit. A temporal resolution of 30 ms is adequate to accurately measure the systolic and diastolic peak in peak flow velocity measurements (18). The formerly established breathhold sequences all used prospective ECG-triggering, with which the flow of late diastole may not be measured correctly. The presented sequence used retrospective gating, providing data collection throughout the whole cardiac cycle. Particularly in bypass grafts, where flow is maximal during diastole, this is an important improvement.

For validation purposes, quantitative flow velocity measurements with FFE phase contrast imaging have been shown to be accurate (19-22). An excellent agreement between the EPI sequence and the conventional sequence was demonstrated in vitro, and the sequences correlated well in vivo.

In healthy volunteers aortic volume flow showed a minor overestimation using the EPI sequence, which may be explained in part by the fact that the EPI sequence had a better spatial resolution, causing partial volume effects to be less prominent (23). Also, eddy current effects or Maxwell concomitant terms may be more prominent using an EPI

approach. These artefacts were not specifically investigated in this study. Moreover, at end-expiration left ventricle stroke volume was previously demonstrated to be higher than the average stroke volume in healthy volunteers (24). Thus, when aortic volume flow is measured over 22 heart beats in an end-expiratory breathhold, measured volume flow may be higher than averaged over 256 heart beats in normal breathing, due to low intrathoracic pressure.

The phase-contrast EPI sequence was initially developed for measuring flow velocity in bypass grafts. The results of the current study showed that this sequence may additionally be used in large arteries as part of an integrated CMR approach.

CMR Flow Velocity in Bypass Grafts

Arterial grafts

Absolute LIMA graft flow ranged considerably between patients without stenoses in the graft or recipient vessel of the graft. Standardized thresholds of the flow parameters are necessary to be able to detect flow-limiting stenoses. Ishida et al. studied volume flow by CMR in 24 LIMA grafts at rest and during dipyridamole stress in patients shortly after CABG, and the authors proposed threshold values for the detection of >70% stenosis of 35 ml/min for baseline LIMA volume flow, 1.0 for diastolic-to-systolic velocity ratio, and 1.5 for CFR (7). These parameters however are known to change over time (17;25). Langerak et al. formulated a regression model to detect $\geq 50\%$ and $\geq 70\%$ stenoses in vein grafts by using CMR with velocity mapping (3). Arterial grafts (n=41) were additionally investigated, but a sufficient number of stenoses to formulate a model for the identification of graft disease was lacking. Future studies are necessary to formulate a model to detect significant stenoses in arterial grafts noninvasively by velocity-encoded CMR. Such a study may be performed using the currently presented sequence.

Another application of LIMA flow measurements by CMR is assessment before and after surgical revascularization to evaluate patency of the graft. Stauder et al. (26) demonstrated the feasibility of a combined CMR protocol, including contrast-enhanced MR angiography and phase contrast flow measurements, for assessment of patency in 42 LIMA grafts. The presented CMR flow velocity sequence may also be used for this purpose.

Metal clips used in bypass graft surgery formed no obstacle in the present study, since proximal CMR measurements were performed. Metal clip artefacts did however prevent the acquisition of distal flow measurements. As CMR imaging gains acceptance as noninvasive follow-up after surgery, MR compatible clips, e.g. titanium clips, may be used at CABG in a standard fashion.

Vein grafts

Vein graft flow velocity has been studied more extensively by CMR in previous studies (3;4;27;28). Two models were described to identify diseased vein grafts yielding a sensitivity and specificity of 94% and 63%, and 78% and 80%, respectively, using velocity-encoded CMR (3;4). Measurement of flow velocity in vein grafts using this sequence was demonstrated to be feasible.

Study Limitations

In this study the results in patients are to show the feasibility of the EPI sequence to be used to measure flow velocity in bypass grafts. A future study validating this sequence to measure bypass grafts flow compared with a prospectively-triggered, breathhold sequence with similar spatial resolution is needed.

Also, artefact sensitivity of EPI was not specifically investigated. Future studies may further focus on this issue.

CONCLUSION

In conclusion, the presented velocity-encoded CMR sequence allows accurate measurements of velocity in small vessels with good reproducibility, demonstrated by means of a flow simulator. The presented sequence correlated well with a conventional sequence for measurement of aortic flow in healthy volunteers. In addition, the feasibility to quantify flow velocity in LIMA and vein grafts was demonstrated.

REFERENCES

1. Topol EJ, Nissen SE. Our preoccupation with coronary luminology. The dissociation between clinical and angiographic findings in ischemic heart disease. *Circulation* 1995;92:2333-42.
2. White CW, Wright CB, Doty DB et al. Does visual interpretation of the coronary arteriogram predict the physiologic importance of a coronary stenosis? *N Engl J Med* 1984;310:819-24.
3. Langerak SE, Vliegen HW, Jukema JW et al. Value of magnetic resonance imaging for the noninvasive detection of stenosis in coronary artery bypass grafts and recipient coronary arteries. *Circulation* 2003;107:1502-8.
4. Bedaux WL, Hofman MB, Vyt SL, Bronzwaer JG, Visser CA, van Rossum AC. Assessment of coronary artery bypass graft disease using cardiovascular magnetic resonance determination of flow reserve. *J Am Coll Cardiol* 2002;40:1848-55.
5. Debatin JF, Strong JA, Sostman HD et al. MR characterization of blood flow in native and grafted internal mammary arteries. *J Magn Reson Imaging* 1993;3:443-50.
6. Sakuma H, Globits S, O'Sullivan M et al. Breath-hold MR measurements of blood flow velocity in internal mammary arteries and coronary artery bypass grafts. *J Magn Reson Imaging* 1996;6:219-22.
7. Ishida N, Sakuma H, Cruz BP et al. Mr flow measurement in the internal mammary artery-to-coronary artery bypass graft: comparison with graft stenosis at radiographic angiography. *Radiology* 2001;220:441-7.
8. Frayne R, Holdsworth DW, Gowman LM et al. Computer-controlled flow simulator for MR flow studies. *J Magn Reson Imaging* 1992;2:605-12.
9. Holdsworth DW, Rickey DW, Drangova M, Miller DJ, Fenster A. Computer-controlled positive displacement pump for physiological flow simulation. *Med Biol Eng Comput* 1991;29:565-70.
10. Rebergen SA, Chin JG, Ottenkamp J, van der Wall EE, de Roos A. Pulmonary regurgitation in the late postoperative follow-up of tetralogy of Fallot. Volumetric quantitation by nuclear magnetic resonance velocity mapping. *Circulation* 1993;88:2257-66.
11. Sakuma H, Kawada N, Kubo H et al. Effect of breath holding on blood flow measurement using fast velocity encoded cine MRI. *Magn Reson Med* 2001;45:346-8.
12. Wilson RF, Wyche K, Christensen BV, Zimmer S, Laxson DD. Effects of adenosine on human coronary arterial circulation. *Circulation* 1990;82:1595-606.
13. van der Geest RJ, Niezen RA, van der Wall EE, de Roos A, Reiber JH. Automated measurement of volume flow in the ascending aorta using MR velocity maps: evaluation of inter- and intraobserver variability in healthy volunteers. *J Comput Assist Tomogr* 1998;22:904-11.
14. van der Geest RJ, Reiber JH. Quantification in cardiac MRI. *J Magn Reson Imaging* 1999;10:602-8.
15. Salm LP, Langerak SE, Vliegen HW et al. Blood flow in coronary artery bypass vein grafts: volume versus velocity at cardiovascular MR imaging. *Radiology* 2004;232:915-20.
16. Langerak SE, Vliegen HW, Jukema JW et al. Vein graft function improvement after percutaneous intervention: evaluation with MR flow mapping. *Radiology* 2003;228:834-41.
17. Gurne O, Chenu P, Polidori C et al. Functional evaluation of internal mammary artery bypass grafts in the early and late postoperative periods. *J Am Coll Cardiol* 1995;25:1120-8.
18. Lotz J, Meier C, Leppert A, Galanski M. Cardiovascular flow measurement with phase-contrast MR imaging: basic facts and implementation. *Radiographics* 2002;22:651-71.
19. Boesiger P, Maier SE, Kecheng L, Scheidegger MB, Meier D. Visualization and quantification of the human blood flow by magnetic resonance imaging. *J Biomech* 1992;25:55-67.
20. Meier D, Maier S, Boesiger P. Quantitative flow measurements on phantoms and on blood vessels with MR. *Magn Reson Med* 1988;8:25-34.
21. Firmin DN, Nayler GL, Kilner PJ, Longmore DB. The application of phase shifts in NMR for flow measurement. *Magn Reson Med* 1990;14:230-41.
22. Hoogeveen RM, Bakker CJ, Viergever MA. MR phase-contrast flow measurement with limited spatial resolution in small vessels: value of model-based image analysis. *Magn Reson Med* 1999;41:520-8.
23. Tang C, Blatter DD, Parker DL. Accuracy of phase-contrast flow measurements in the presence of partial-volume effects. *J Magn Reson Imaging* 1993;3:377-85.
24. van den Hout RJ, Lamb HJ, van den Aardweg JG et al. Real-time MR imaging of aortic flow: influence of breathing on left ventricular stroke volume in chronic obstructive pulmonary disease. *Radiology* 2003;229:513-9.
25. Akasaka T, Yoshikawa J, Yoshida K et al. Flow capacity of internal mammary artery grafts: early restriction and later improvement assessed by Doppler guide wire. Comparison with saphenous vein grafts. *J Am Coll Cardiol* 1995;25:640-7.
26. Stauder NI, Scheule AM, Hahn U et al. Perioperative monitoring of flow and patency in native and grafted internal mammary arteries using a combined MR protocol. *Br J Radiol* 2005;78:292-8.

27. Galjee MA, van Rossum AC, Doesburg T, van Eenige MJ, Visser CA. Value of magnetic resonance imaging in assessing patency and function of coronary artery bypass grafts. An angiographically controlled study. *Circulation* 1996;93:660-6.
28. Hoogendoorn LI, Pattynama PM, Buis B, van der Geest RJ, van der Wall EE, de Roos A. Noninvasive evaluation of aortocoronary bypass grafts with magnetic resonance flow mapping. *Am J Cardiol* 1995;75:845-8.

