



Universiteit
Leiden

The Netherlands

Compensatory muscle activation in patients with glenohumeral cuff tears

Steenbrink, F.

Citation

Steenbrink, F. (2010, May 27). *Compensatory muscle activation in patients with glenohumeral cuff tears*. Retrieved from <https://hdl.handle.net/1887/15556>

Version: Corrected Publisher's Version

License: [Licence agreement concerning inclusion of doctoral thesis in the Institutional Repository of the University of Leiden](#)

Downloaded from: <https://hdl.handle.net/1887/15556>

Note: To cite this publication please use the final published version (if applicable).

Chapter 6

Teres major muscle activation relates to scapula lateral rotation in patients with a glenohumeral cuff tear

Frans Steenbrink^{1,2}, Carel G.M. Meskers^{1,3}, Rob G.H.H. Nelissen^{1,2}, Jurriaan H. de Groot^{1,3}

¹ *Laboratory for Kinematics and Neuromechanics, Leiden University Medical Center*

² *Department of Orthopaedics, Leiden University Medical Center*

³ *Department of Rehabilitation Medicine, Leiden University Medical Center*

Clinical Biomechanics, submitted.

Abstract

Scapula lateral rotation in patients with a glenohumeral cuff tear is increased during arm elevation, which might be the consequence of teres major activation, resulting in a pain avoidance compensatory response to decreased glenohumeral rotations. The teres major may, amongst other muscles, be responsible, which can be investigated by studying the effect of transfer surgery of either the scapulo-humeral teres major or the scapulo-thoracic latissimus dorsi on scapula lateral rotation.

Scapula lateral rotation was measured relative to the thorax during arm *abduction* elevation, using an electromagnetic tracking device. Lateral rotation in cuff tear affected shoulders was compared to the non-affected side and re-assessed after teres major or latissimus dorsi tendon transfer. Additionally preoperative lateral rotation was related to teres major and latissimus dorsi activation and pain scores.

Patients with a glenohumeral cuff tear exhibited increased scapula lateral rotation during arm *abduction*, which was proportional to teres major activation as opposed to latissimus dorsi activation. Increased lateral rotation persisted after teres major transfer, while it normalized after latissimus dorsi transposition. Preoperatively pain scores reduced with increased lateral rotation.

The teres major likely plays a role in both lateral rotation of the scapula (this study) and downward traction on the humerus. After latissimus dorsi transfer, teres major contribution to glenohumeral stability is redundant and scapula lateral rotation normalizes. Scapula lateral rotation may have an additional contribution to pain reduction in patients with a glenohumeral cuff tear.

6.1 Introduction

In patients with a glenohumeral cuff tear, increased lateral rotation of the scapula is considered to be a scapula-thoracic compensation for decreased gleno-humeral rotation (McClure et al., 2001). Increased lateral rotation, which occurs mainly during elevation onset, seems to be triggered by pain (Scibek et al., 2008). In previous research we found that pain in patients with a glenohumeral cuff tear induced large arm *adductor* muscles to co-activate with the prime mover, i.e. deltoid muscle, during arm elevation tasks (Steenbrink et al., 2006; de Groot et al., 2006). This so-called ‘out-of-phase’ activation of *adductor* muscles, like the teres major and latissimus dorsi, is considered to be an attempt to stabilize or center the humeral head onto the glenoid fossa (Steenbrink et al., 2009). By *adductor* muscle activation during arm elevation tasks, the humeral head is prevented from proximal migration and thus (painful) tissue inclination due to subacromial space reduction (Deutsch et al., 1996; Graichen et al., 1999a). Next to centering the humeral head, scapula rotation is a requisite to maintain an optimal contact between the glenoid fossa and the humeral head during arm *abduction* elevation (Bagg and Forrest, 1988). Alike humeral head suppression, scapula lateral rotation, resulting in acromion toppling, enlarges the subacromial space (Flatow et al., 1994; Meskers et al., 2002).

The scapula-thoracal trapezius and the serratus anterior muscles are suggested to dictate scapular motion in terms of lateral rotation (Flatow et al., 1994; Ludewig and Cook, 2000). The scapula-humeral teres major also has a direct scapula lateral rotating moment because of its origin at the inferior angle of the scapula and insertion on the intertubercular sulcus on the humerus. The scapula-thoracal latissimus dorsi is a multi-articular muscle, originating from the thoracic spinous processes (T7-T12), also inserting on the intertubercular sulcus on the humerus, which has a scapula medial rotation moment (via sterno-clavicular and acromio-clavicular joints).

The teres major in patients with a glenohumeral cuff tear is active while generating arm elevation moments (de Groot et al., 2006; Steenbrink et al., 2006). If scapula lateral rotation is related to teres major activation, lateral rotation in the affected scapula will be increased, compared to the non-affected shoulder. Transfers of either the scapulo-humeral teres major or scapulo-thoracic latissimus dorsi, both known successful and pain relieving salvage procedures in irreparable cuff tears changing their original *adduction* to an *abduction* contribution (Celli et al., 2005; Gerber et al., 2006) may potentially reveal the contribution of teres major activation to scapula lateral rotation. By transfer, both muscles are expected to activate dur-

ing arm elevation tasks (Irlenbusch et al., 2008a, Steenbrink et al., 2009), pulling down the humeral head, preventing proximal migration and subsequent painful subacromial space reduction. After latissimus dorsi transfer, additional teres major *adductor* muscle contributions to glenohumeral stability as observed prior to surgery are assumed to be redundant. ‘Out-of-phase’ teres major activation is expected to decrease, which should normalize scapula lateral rotation.

The purpose of this study is to investigate whether scapula lateral rotation in case of a cuff tear is altered. Scapula lateral rotation of the affected shoulder is examined and compared with scapula lateral rotation of the non-affected shoulder. Scapula lateral rotation after teres major and latissimus dorsi tendon transfer surgery is assessed and preoperative scapula lateral rotation is related to teres major and latissimus dorsi muscle activation and pain scores. We hypothesize that scapula lateral rotation is increased in case of a cuff tear, which is related to pain decrease and affected by teres major as opposed to latissimus dorsi activation.

6.2 Methods

6.2.1 Subjects

Thirty-two patients were sequentially recruited from the Leiden University Medical Center department of Orthopaedics’ out-patient clinic in the period between June 2005 and November 2009. All selected patients had a MRI proven full thickness retracted rotator cuff tear larger than 4cm including at least the supraspinatus and infraspinatus tendons. Patients had Goutallier grade 3-4 fatty degeneration, excluding primary cuff repair (Goutallier et al., 1994). Patients underwent a tendon transfer of either the teres major (n=11) as described by Celly and co-workers (1998)(Celli et al., 1998) or the latissimus dorsi (n=10) as described by Gerber and co-workers (Gerber et al., 1988), allocated in order of appearance. Three cases of bi-lateral pathology and in which the maximum elevation of the non-affected arm was restricted below 100°, were excluded. Six patients refrained from surgery due to personal factors and five patients experienced per-or postoperative complications and were therefore lost for follow-up.

6.2.2 Kinematics

Scapula lateral rotation of shoulders with cuff tears was compared to scapula rotation of the non-affected side. After transfer of either the teres major or latissimus dorsi, scapula lateral

rotation was re-assessed (follow up range 6-12 months). A Flock of Birds electromagnetic tracking device (Ascension Technology, Burlington, VT, USA) with an extended range transmitter (Meskers et al., 1998) was used. Measurements were performed simultaneously on both arms according to the standardized motion recording protocol for the shoulder of the International Shoulder Group (Wu et al., 2005). Five sensors, size $25.4\text{mm} \times 25.4\text{mm} \times 20.3\text{mm}$, were used. One sensor was attached on the middle of the sternum using tape and one on each side distally on the dorsal area of the upper arm using straps. In order to allow for dynamic measurements, acromion sensors were used on both sides (Karduna et al., 2001; Meskers et al., 2007). The acromion sensor was taped on the skin directly above the flat part of the acromion in the most latero-caudal corner, just above the angulus acromial (McClure et al., 2001; McQuade and Smidt, 1998; Meskers et al., 2007; Karduna et al., 2001). Initial measurements were performed to define 3D positions of bony landmarks (Wu et al., 2005) in the local co-ordinate system of the receivers by using a freely movable sensor attached to a pointer of 0.05cm (Meskers et al., 1998a). The glenohumeral center of rotation was determined using a regression method from scapular bony landmarks (Meskers et al., 1998b). Subsequently, subjects were asked to perform a bilateral maximal arm abduction elevation at a comfortable (low) speed with eternally rotating the arm when elevating. Data acquisition rate was about 6Hz.

6.2.3 Data processing

Scapula lateral rotation was expressed as a function of humeral *abduction* elevation. This relation may not be linear, i.e. lateral rotation at small arm elevation angles may differ from lateral rotation at high arm elevation angles. Therefore lateral rotation between the affected and non-affected side was compared at equal humerus elevation angles, ranging from rest angle to the maximal elevation angle of the affected side. Angles above 100° were discarded because of the risk of invalid recordings as a consequence of the use of an acromion sensor (Meskers et al., 2007). The relation of scapula lateral rotation to humerus elevation angle was quantified by the slope (β) of a first order function fit through the individual data points.

6.2.4 Pain

Preoperative shoulder pain, experienced by the patients to be typical, was quantified by a *Visual Analog Score* (VAS) for pain (0: no pain; 100: worst pain ever imaginable).

6.2.5 Muscle activation

Preoperative teres major and latissimus dorsi muscle activations were expressed in *activation ratios* (Steenbrink et al., 2009). Subjects were seated with their injured arm in a splint with the elbow in 90° flexion. The plane of elevation was about 60°, elevation about 45° and external rotation about 30°. Each recording session the teres major and latissimus dorsi were palpated and the electrodes placed on the middle of the muscle belly. During isometric contraction in *ab-* and *adduction* directions, surface electromyography (*EMG*) of the teres major and latissimus dorsi was collected. *EMG* was recorded using a DelSys system (Bagnoli-16 Boston MA, USA). The dimensionless normalized *activation ratio* ($1 \leq AR_{muscle} \leq 1$, Eq. 6.1) indicates the ratio for muscle of ‘in-phase’ activation (A^{IP} , the expected attribution according to the muscles positive moment arm, being for both teres major and latissimus dorsi during arm *adduction*) reduced with the ‘out-of-phase’ activation (A^{OP} , the non-expected attribution, e.g. during *abduction*) over the summed ‘in-phase’ and ‘out-of-phase’ activation, Eq. 6.1.

$$AR_{muscle} = \frac{A_{muscle}^{IP} - A_{muscle}^{OP}}{A_{muscle}^{IP} + A_{muscle}^{OP}} \quad [-1 \leq AR_{muscle} \leq 1] \quad (6.1)$$

Where A^{IP} is ‘in-phase’ activation (*EMG* during *adduction* task - *EMG* at rest); A^{OP} is ‘out-of-phase’ activation (*EMG* during *abduction* task - *EMG* at rest) for the *muscles* teres major or latissimus dorsi.

6.2.6 Statistics

Scapula lateral rotation slopes of the affected and the contra-lateral non-affected shoulders at equal motion ranges were statistically compared using a paired samples t test. Pre- and postoperative scapula lateral rotation slopes as of either the teres major or latissimus dorsi patients were compared using a paired samples t-test. Linear regression was applied to assess the relation of preoperative scapula lateral rotation slopes to teres major and latissimus dorsi *activation ratio* and VAS scores. The slope coefficient of the regression line was tested to significantly differ from zero. The level of significance was $\alpha = 0.05$ and all statistical tests were performed using SPSS 16.0 (SPSS Inc, Chicago, IL).

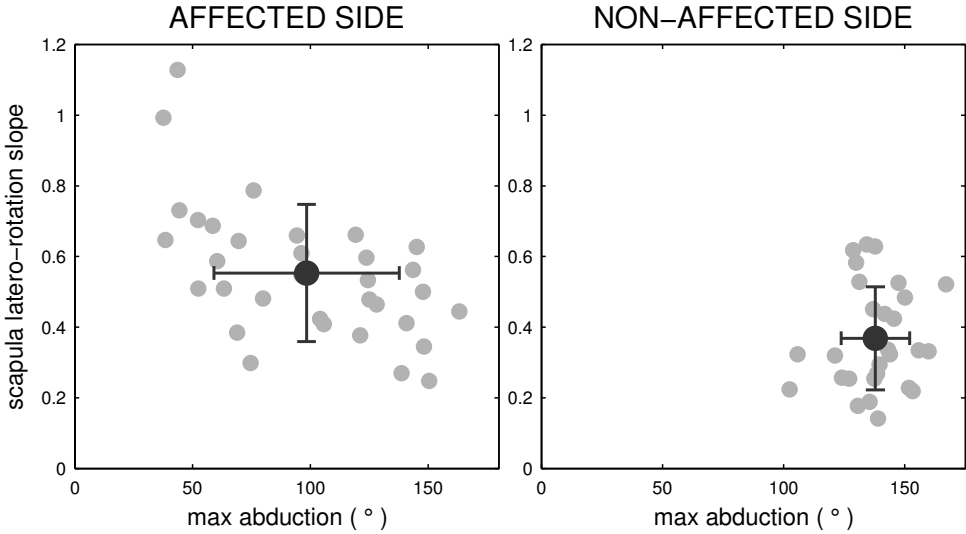


Figure 6.1: Pre-operative slopes (β) of scapula lateral rotation in patients with a glenohumeral cuff tear (grey circles) of the affected and non-affected contra-lateral side (mean: black circles; standard deviation: black vertical line) for *abduction* angles, not exceeding 100° . In order to avoid clustering at 100° , slopes were plotted against maximal *abduction* elevation (mean: black circle; standard deviation: black horizontal line). Slopes of the non-affected side were computed over the same range as the affected side.

6.3 Results

In shoulders with rotator cuff tears ($n=32$) scapula lateral rotation was significantly increased (mean $\beta = 0.57$ SD 0.21) compared to the non-affected shoulder (mean $\beta = 0.37$ SD .15, 95% confidence interval of the difference: $CI_d = [0.10, 0.32]$, $p = 0.001$, Fig. 6.1). In two cases, scapula lateral rotation was nearly equal to humerus elevation ($\beta \approx 1$), i.e. no glenohumeral rotation. In the teres major group ($n=11$) preoperative scapula lateral rotation (mean $\beta = 0.56$ SD 0.21) was not affected by the teres major transfer (mean $\beta = 0.51$ SD 0.19, 95% confidence interval of the difference: $CI_d = [0.07, 0.17]$, $p = 0.38$) (Table 6.1). Latissimus dorsi tendon transfers ($n=10$) resulted in significant decrease from preoperative (mean $\beta = 0.57$ SD 0.25) to postoperative (mean $\beta = 0.44$ SD 0.14) scapula lateral rotation (95% confidence interval of the difference: $CI_d = [0.01, 0.24]$, $p = 0.03$) (Table 6.1). The linear regression estimate and 95% CI's of preoperative scapula lateral rotation to *activation ratios* of teres major and latissimus dorsi are presented in Figure 6.2. The slope coefficient of the

Table 6.1: Scapula lateral rotation slopes (β) of patients with a glenohumeral cuff tear and mean (standard deviation) prior to and after transfer of either teres major (TM) or latissimus dorsi (LD) tendons. Preoperative augmented lateral rotation persisted in the teres major group as opposed to the latissimus dorsi group.

Patients	Scapula lateral rotation over abduction angle (β)			
	TM transfer group		LD transfer group	
	Pre	post	pre	Post
1	0,61	0,89	0,59	0,40
2	0,46	0,48	0,30	0,19
3	0,25	0,35	0,48	0,37
4	0,73	0,72	0,48	0,45
5	0,69	0,23	1,13	0,61
6	0,70	0,42	0,79	0,65
7	0,44	0,38	0,65	0,52
8	0,55	0,62	0,53	0,49
9	0,51	0,49	0,38	0,37
10	0,60	0,65	0,35	0,37
11	0,27	0,41	X	X
Mean	0,56	0,51	0,57	0,44
SD	0,21	0,19	0,25	0,13

estimate linear fit for the teres major differed significantly from zero ($p = 0.02$) in contrast to the non-significant latissimus dorsi fit ($p = 0.99$). The linear regression estimate and 95% CI's for the scapula lateral rotation to VAS scores is presented in Figure 6.3. The (negative) slope coefficients of the estimate linear fit illustrate increased pain experience with decreased scapula lateral rotation. This differed significantly from zero ($p = 0.04$).

6.4 Discussion

Goal of this study was to assess scapula kinematics before and after teres major and latissimus dorsi tendon transfer in order to investigate the potential roll of the teres major to lateral rotation. We found enhanced lateral rotation of the scapula in the affected, cuff tear shoulder, which persisted after teres major transposition as opposed to transposition of the latissimus dorsi. A relation between enhanced scapular lateral rotation and teres major activity could be established, as well as a relation between lateral rotation and pain.

Reports on increased scapula lateral rotation in patients suffering rotator cuff tears (Graichen et al., 1999b; Mell et al., 2005; Paletta, Jr. et al., 1997; Scibek et al., 2009; Deutsch et al., 1996) coincide with our results. Increased lateral rotation in these patients was related to

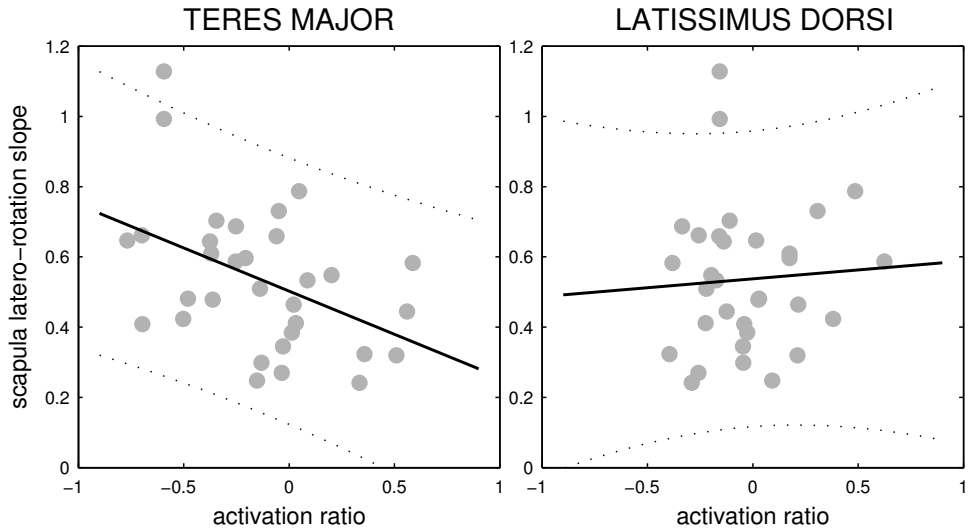


Figure 6.2: Regression lines of scapula lateral rotation over pre- and post surgery arm elevation ratio slope (β) as a function of *activation ratio* of patients with a glenohumeral cuff tear (grey circles). The slope of the regression line (β) in case of teres major *activation ratio* differed significantly from zero in contrast to the latissimus dorsi *activation ratio*.

pain (Scibek et al., 2008), which can be explained by a teres major co-activation to prevent painful subacromial tissue inclination due to lost glenohumeral stability (Steenbrink et al., 2006), and its correspondent contribution to scapula lateral rotation. Scapula lateral rotation was previously related to lost stabilizing cuff forces in experimental simulation of a rotator cuff tear, using a suprascapular nerve block (McClure et al., 2001), and surgical repair of the rotator cuff (Paletta, Jr. et al., 1997). In these studies respectively increased lateral rotation and ‘normalization’ of increased scapula lateral rotation was found. Lost stabilizing forces, and subsequent painful subacromial space width decrease, requires compensational muscle activation and scapula orientation changes. Because of the small subacromial space, even subtle changes in scapula-humeral orientation potentially result in subacromial space width changes (Nordt III et al., 1999; Graichen et al., 1999b; Meskers et al., 2002). Therefore even a small increase in scapula lateral rotation enlarges the subacromial space width, contributing to painful tissue inclination avoidance. Also, a lack of scapula lateral rotation, causing early subacromial space width reduction, is reported to be associated with the subacromial impingement syndrome (Ludewig and Cook, 2000; Su et al., 2004).

The recorded scapula lateral rotation persisted after a teres major tendon transfer as opposed to observations after a latissimus dorsi transfer. Functional transfers, i.e. activation of the transferred muscle during elevation moment exertion, were observed after teres major transposition, involving predominant teres major activation during upwards arm force exertion (Steenbrink et al., 2009c), pulling down the humeral head, compensating lost glenohumeral stability. Equivalent teres major forces work on the scapula, which contributes to the enhanced scapula lateral rotation. Like the teres major, the transposed latissimus dorsi also delivers a downwards pull on the humeral head to prevent humeral head migration. In this case, the regained stabilizing forces of the transferred latissimus dorsi cause less need for additional teres major ‘out-of-phase’ activation explaining reduced scapula lateral rotation in the latissimus dorsi transfer group. Analysis of teres major *activation ratios* after latissimus dorsi tendon transfer indeed showed that 8 out of 10 patients did not show preoperative observed ‘out-of-phase’ teres major activation postoperatively. Without teres major activation during arm *abduction* tasks the increased scapula lateral rotation normalizes, which substantiates scapula lateral rotation to be affected by teres major activation. The observed relation between preoperative scapula lateral rotation and teres major *activation ratios* in contrast to latissimus dorsi *activation ratios* also illustrates the potential role of teres major activation in lateral rotation.

The relation between preoperative scapula lateral rotation and VAS scores for pain could relate to a subacromial space width reduction (or insufficient downward forces) causing painful tissue inclination at lower scapula lateral rotation angles. The reported pain reduction after latissimus dorsi transposition (Irlenbusch et al., 2008b) demonstrate the predominant effect of caudal directed stabilizing glenohumeral forces of the transferred muscle over muscle force contribution to lateral rotation to affect the subacromial space width.

Activation ratios to describe muscle function of the teres major and latissimus dorsi were determined in a static set-up. Suppositions towards dynamics in the relation between scapula lateral rotation and teres major activation should be reserved. The negative relation between scapula lateral rotation and pain was explained by a subacromial space reduction at increasing humerus elevation with low scapula lateral rotation, causing painful subacromial tissue inclination. However, subacromial space width decrease was not determined in this study, but was previously observed in combination with decreased scapula lateral rotation to arm elevation (Graichen et al., 1998; Solem-Bertoft et al., 1993; Graichen et al., 1999b; Karduna et al., 2005). The role of scapula kinematics in glenohumeral joint pathologies requires an extensive study towards the determinants of shoulder function in these patients. Studying the

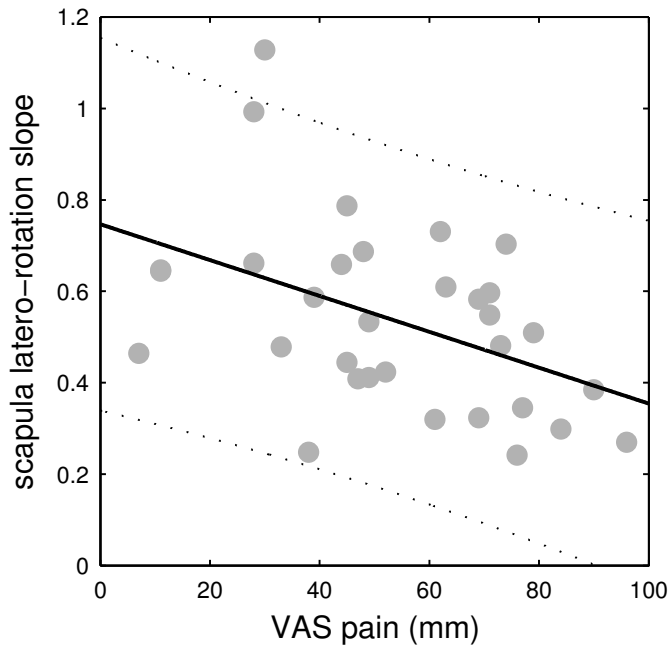


Figure 6.3: Regression lines of preoperative scapula lateral rotation over arm elevation ratio slope (β) as a function of a *Visual Analog Scale* for pain assessed by patients with a glenohumeral cuff tear (grey circles). 0 indicates no pain; 100 indicated worst pain ever imaginable.

contribution of scapula kinematics on outcome after tendon transfer surgery requires a randomized clinical trial with teres major and latissimus dorsi tendon transfers, combined with analysis of muscle activation and kinematics of the entire shoulder, i.e. scapulo-thoracal and gleno-humeral rotations.

6.5 Conclusion

Enhanced scapula lateral rotation persisted after teres major tendon transfer and decreased after latissimus dorsi transfer, substantiating teres major contribution to scapula kinematics. After latissimus dorsi transfer, the preoperative observed teres major activation during arm elevation tasks in compensating lost glenohumeral stability is redundant and teres major activation and consequences for scapula lateral rotation decrease. When activating during arm

elevation tasks, teres major activation thus might prevent a painful subacromial space reduction in patients with a glenohumeral cuff tear by simultaneous pulling down the humeral head and increasing lateral rotation of the scapula. Such secondary effect of the teres major, after the preventing the humeral head from proximal migrating by pulling it down during arm elevation tasks, could be an argument in preferring the teres major over the latissimus dorsi in tendon transfer surgery for patients suffering glenohumeral cuff tears. To draw any conclusions on this matter requires additional comparative research.