



Universiteit
Leiden
The Netherlands

Vectorcardiographic diagnostic & prognostic information derived from the 12-lead electrocardiogram

Man, Sum-Che

Citation

Man, S. -C. (2016, February 11). *Vectorcardiographic diagnostic & prognostic information derived from the 12-lead electrocardiogram*. Retrieved from <https://hdl.handle.net/1887/37621>

Version: Corrected Publisher's Version

License: [Licence agreement concerning inclusion of doctoral thesis in the Institutional Repository of the University of Leiden](#)

Downloaded from: <https://hdl.handle.net/1887/37621>

Note: To cite this publication please use the final published version (if applicable).

Cover Page



Universiteit Leiden

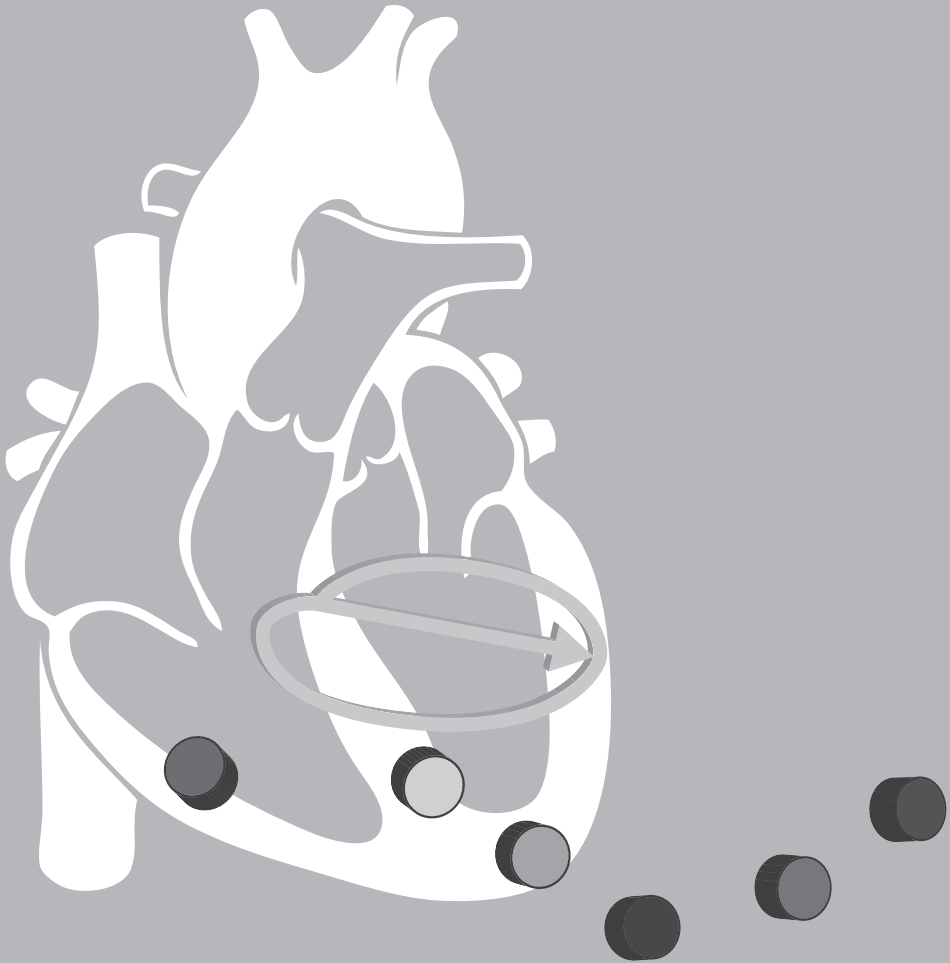


The handle <http://hdl.handle.net/1887/37621> holds various files of this Leiden University dissertation

Author: Sum-Che Man

Title: Vectorcardiographic diagnostic & prognostic information derived from the 12-lead electrocardiogram

Issue Date: 2016-02-11



Chapter 5

Acute coronary syndrome with a totally occluded culprit artery: relation of the ST injury vector with ST-elevation and non-ST elevation ECGs

Sum-Che Man, Chinar Rahmattulla, Arie C. Maan, Niek H.J.J. van der Putten, W. Arnold Dijk, Erik W. van Zwet, Ernst E. van der Wall, Martin J. Schalij, Anton P. Gorgels, Cees A. Swenne

J Electrocardiol. 2014; 47: 183-90

Abstract

Background

In acute coronary syndrome (ACS), ST-segment elevation (STE), often associated with a completely occluded culprit artery, is an important ECG criterion for primary percutaneous coronary intervention (PCI). However, several studies showed that in ACS a completely occluded culprit artery can also occur with a non-ST-elevation (NSTEMI) ECG. In order to elucidate reasons for this discrepancy we examined ST injury vector orientation and magnitude in ACS patients with and without STE, all admitted for primary PCI and having a completely occluded culprit artery.

Methods

We studied the ECGs of 300 ACS patients (214/86 STE/NSTEMI; 228/72 single/multi-vessel disease) who had a completely occluded culprit artery during angiography prior to primary PCI. The J+60 injury vector orientation and magnitude were computed from Frank XYZ leads derived from the standard 12-lead ECG.

Results

Demographic and anthropomorphic characteristics of the STE and NSTEMI patients did not differ. STE patients had a higher rate of right coronary artery occlusions, and a lower rate of left circumflex occlusions than NSTEMI patients (43 vs. 31%, and 13 vs. 22%, respectively; $P < 0.05$). Injury vector elevation and magnitude were larger in STE than in NSTEMI patients ($32 \pm 37^\circ$ vs. $6 \pm 39^\circ$, and $304 \pm 145 \mu\text{V}$ vs. $134 \pm 72 \mu\text{V}$, respectively; $P < 0.0001$).

Conclusion

STE criteria favor certain injury vector directions and larger injury vector magnitudes. Obviously, several ACS patients with complete culprit artery occlusions requiring primary PCI do not fulfill these criteria. Our study suggests that STE-NSTEMI-based ACS stratification needs further enhancement.

Introduction

The ECG is of major importance in diagnosis and triage in acute coronary syndrome (ACS), especially in the hyperacute phase. According to the guidelines¹, an important triaging decision concerning the initial treatment is based on the presence of a new ST elevation (STE) pattern in the ECG. In that case, the current guidelines¹ mention primary percutaneous coronary intervention (PCI) as the therapy of first choice (and thrombolytic therapy when there is no, or delayed, access to PCI). In case of ACS without persistent ST-elevation (non ST elevation, NSTEMI) the current guidelines² recommend antithrombotic (anticoagulant, antiplatelet) therapy rather than emergency PCI. The guidelines¹ mention, however, situations in which the ECG is non-diagnostic while there is still an urgent indication for PCI: "In any case, ongoing suspicion of myocardial ischemia— despite medical therapy—is an indication for emergency coronary angiography with a view to revascularization, even in patients without diagnostic ST-segment elevation."

Patients with STE-ACS are assumed to be in the process of developing a larger, transmural, infarction, caused by complete occlusion of a major segment of the culprit coronary artery, while NSTEMI-ACS patients are thought to be in the process of developing a smaller, non-transmural infarction caused by incomplete occlusion of a segment of the culprit artery³. This concept is nowadays challenged and nuanced⁴⁻⁶. Many more ACS patients with NSTEMI admission ECGs might have a complete occlusion, and might require primary PCI than what generally is believed^{7;8}. Koyama and colleagues⁷ found a completely occluded (TIMI flow grade 0) culprit artery in 47% of patients with an NSTEMI admission ECG (vs. 57% in patients with a STE admission ECG). In a database of elective PCI procedures with long (several minutes) balloon occlusions, actually a model of human ACS, only 55% of the patients had developed an STE ECG after three minutes of occlusion⁸, a number comparable to the results of Koyama and colleagues.

Birnbaum *et al.*⁹ give an overview of the many similarities between the pathology underlying STE and NSTEMI ECGs and explain the physical concepts underlying the genesis of the ECG and why ischemia at certain locations manifests with STE and at other locations manifests as NSTEMI. Whether ischemia in a given ECG lead manifests as ST depression or ST elevation depends on the direction of the ST injury vector in relation to the lead vector. *E.g.*, an ischemia vector in the right

superoposterolateral direction will likely yield an NSTEMI ECG because there are almost no lead vectors in the standard 12-lead ECG that form an acute angle with that ischemia vector and, hence, most leads will show negative ST amplitudes. An ischemia vector in this direction may result from transmural posterior wall ischemia, but may also be caused by subendocardial anterior wall ischemia that results from a complete occlusion in combination with collateral circulation. Ischemia on the basis of a complete occlusion may also manifest as NSTEMI ECG when a complete occlusion generates only a small ischemia vector that does not meet the elevation-amplitude criteria. This may happen in case of a distal occlusion, in case of a preexisting significant lesion that may have led to compensatory collateral formation, and in case of massive ischemia, where cancellation effects reduce the ischemia vector magnitude.

NSTEMI-ACS may comprise high-risk conditions, amongst others posterior wall infarction¹⁰. Hence, the role of the ECG in diagnosing an impending myocardial infarction is crucial. The purpose of our study was to demonstrate, with a vectorcardiographic approach, that ACS patients with a completely occluded culprit artery may have either STE or NSTEMI ECGs. To this end, we analyzed a set of STE and NSTEMI ECGs recorded in a group of patients hospitalized for primary PCI because of ACS.

Methods

Study population

We analyzed standard 10-second 12-lead ECGs of 300 ACS patients admitted to three University Medical Centers in The Netherlands. All patients were triaged for primary PCI, and were selected because the catheterization immediately preceding the actual PCI procedure showed a completely occluded culprit artery (TIMI flow grade equal to zero). Patients in one center were additionally selected on the basis of single vessel disease (N=174); patients in the two other centers (N=126) were additionally selected on the basis of a single stent implantation. The ECGs were made within 2 hours before PCI. When within this time frame multiple ECGs were available, the ECG nearest to PCI was selected (hence, the ECG analyzed is not necessarily the index ECG for primary PCI). Patients with technically inferior ECGs, with previous myocardial infarction, or with right or left bundle branch block were excluded.

Electrocardiogram processing

The ECGs were recorded using electrocardiographs with a sampling frequency of 500 samples per sec (25 mm/s, 10 mm/mV). Vectorcardiographic analysis was performed by using the custom-made program LEADS¹¹. VCGs were synthesized from the 8 independent ECG leads I, II, V1-V6 by using the Kors matrix¹². In brief, LEADS removes baseline wander, deselects noisy beats, defines end QRS (J point) according to the Minnesota code procedure¹³, and computes the J+60 vector size and orientation (azimuth and elevation) in accordance with the American Heart Association standard¹⁴.

Finally, the ECGs were transferred to the LUMC departmental ECG management system (Infinity® MegaCare, Dräger Medical System Inc., Telford, USA) and then analyzed by the University of Glasgow ECG Analysis Program¹⁵. The measurement matrix data of this program was used to characterize the ECG as either STE or NSTE. STE was diagnosed as an elevation at the J-point of ≥ 0.2 mV in two or more contiguous leads in leads V1, V2 or V3, and of ≥ 0.1 mV in other contiguous leads. Contiguity in the frontal plane is defined by the lead sequence aVL, I, inverted aVR, II, aVF and III. Also, a depression of ≥ 0.1 mV in leads V2 or V3 was counted as STE. When the ECG did not qualify as STE, it qualified as NSTE.

Statistical analysis

Characteristics of patients with STE- and with NSTE ECGs were compared, when appropriate, with the unpaired t-test or chi-square test; level of significance $P=0.05$. Analyses were done using PASW Statistics (SPSS), version 20.0 (PASW Statistics; SPSS Inc).

Results

The major characteristics of the study group have been listed in Table 1. Demographic and anthropomorphic characteristics of the STE and NSTE patients did not differ. Of the 300 studied patients, 86 (28.7 %) had NSTE ECGs; 72/300 (24%) had multivessel disease. In patients with STE and NSTE ECGs, 25% and 21% had multivessel disease, respectively ($P=NS$). As compared to STE patients, patients with NSTE ECGs had less frequently an RCA occlusion and more frequently a LCX occlusion. The average injury vector elevation in the NSTE ECG patients was

TABLE 1. Group characteristics

	STE-ACS	NSTE-ACS
N	214	86
Sex (% male)	75	74
Age (years)	59 ± 13	57 ± 13
Height (cm)	177 ± 10	175 ± 13
Weight (kg)	89 ± 23	82 ± 19
BMI(kg/m ²)	28 ± 8	27 ± 7
Culprit artery		
RCA	91(43)	27(31)*
LAD	95(44)	40(47)
LCX	28(13)	19(22)*
VCG variables		
J+60 injury vector azimuth (°)	-56 ± 71	-46 ± 95
J+60 injury vector elevation (°)	32 ± 37	6 ± 39 [†]
J+60 injury vector magnitude (μV)	304 ± 145	134 ± 72 [†]

Data between parentheses are percentages. Data separated by a ± sign are mean ± SD. STE-ACS = ST-elevation acute coronary syndrome; NSTE-ACS = non ST-elevation acute coronary syndrome; RCA = right coronary artery; LAD = left anterior descending artery; LCX = Left circumflex coronary artery; BMI = body mass index. *Significantly (P<0.05) different from the STE-ACS group. [†]Significantly (P<0.0001) different from the STE-ACS group.

smaller (*i.e.*, more in the horizontal direction) than in the STE ECG patients (*i.e.*, more in the downward direction). The average injury vector magnitude in the NSTE ECG patients was smaller than in the STE ECG patients (this is according to expectation, because there is no amplitude criterion for NSTE).

Figure 1 shows the spatial orientation of the injury vectors in relation to the culprit arteries (panels A, B and C), in relation to the STE/NSTE characterization (panel D) and in relation to the injury vector magnitudes in STE (panel E) and NSTE (panel F) cases.

Panels A-C show that the culprit arteries determine to a high extent which directions the injury vectors can assume: LAD culprits generate mainly injury vectors in the anterior and left anteroinferior directions; LCX culprits generate mainly posterolateral and left inferoposterolateral directions; RCA culprits generate mainly right lateral and inferolateral directions. There is considerable overlap, and also directions relatively far from the main clusters are seen. Injury vector direc-

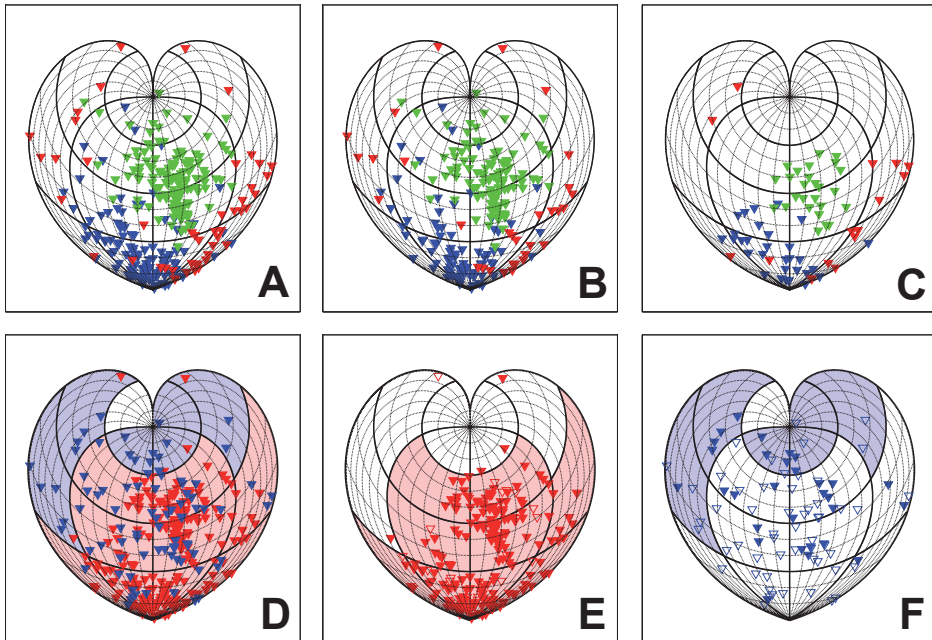


FIGURE 1. *General.* Spatial orientation of the J+60 injury vectors in the study group. The Figure shows the directions of the injury vectors on a sphere, here depicted in the 2D plane by cordiform Stab-Werner projections. Graticule spacing: meridians and parallels 15°. The crossing of the equator and the frontal meridian running from the North Pole to the South Pole represents a pure anterior direction. The “cut” in the sphere has been made along the opposite meridian running from the North Pole to the South Pole, and is, hence, visible at the left and right sides of the Stab-Werner projections; crossing with the equator represents a pure posterior direction. Crossing of the equator with the meridians at $\pm 90^\circ$ with respect to the frontal meridian represent pure lateral directions. *Panels A, B and C* show how the injury vector orientations are related to the culprit coronary arteries (green = LAD, red = LCX, blue = RCA). *Panel A* shows the data of the complete study group, *panels B and C* give the injury vectors of patients with single vessel disease and multivessel disease, respectively. *Panel D* shows the conventional 12-lead ECG ischemia characterization: red = STE, blue = NSTE. Filling colors of the $90^\circ \times 45^\circ$ patches denote predominance of STE (red) or NSTE (blue), respectively. *Panels E and F* depict uniquely the STE or NSTE injury vectors, respectively. In both panels, closed triangles represent relatively large vectors (magnitudes $> 150 \mu\text{V}$) and open triangles represent relatively small vectors (magnitudes $> 150 \mu\text{V}$).

tions do not differ much between patients with single vessel disease and patients with multivessel disease (panels B and C).

Panel D shows that anterior, left inferoposterior and inferior injury vector directions are predominantly ($>50\%$) occurring with STE ECGs, while right inferoposterior, left and right superoposterior and superior injury vector directions are predominantly ($>50\%$) occurring with NSTE ECGs. However, in the predominantly STE areas, there is a remarkable number of NSTE ECGs, and panel F shows that this

is mainly caused by the magnitude of the injury vectors (small magnitudes lead to NSTEMI qualification of the ECG).

Discussion

In our study group of ACS patients with primary PCI and a completely occluded culprit artery, 28.7% of the patients had an NSTEMI ECG. This is a considerable percentage, but not unexpectedly high. Koyama and colleagues⁷ found, in a study where primary invasive treatment was equally assigned to NSTEMI ACS and STE ACS patients, that 47% of NSTEMI ACS patients and 57% of STE ACS patients had a completely occluded culprit artery. In ACS, NSTEMI ECGs are more often seen (60%) than STE ECGs (40%)¹⁶. Hence, one might expect slightly more NSTEMI ECGs than STE ECGs in ACS patients with a complete occlusion. In daily clinical practice, different from the Koyama study, and according to the guidelines, NSTEMI ACS patients oftentimes get primary antithrombotic treatment instead of primary invasive treatment, and this explains our lower percentage of NSTEMI ECGs.

Basically, the participating centers where our study group was admitted are following the ACS guidelines^{1,2}. Hence, NSTEMI ECGs are not immediately expected to be abundantly present among the primary PCI patients. There are, however, several reasons why it is possible that NSTEMI ECGs were recorded prior to primary PCI. First of all, the guidelines offer the option to triage NSTEMI-ACS patients for primary PCI if initial repeated administration of nitrates fails to resolve anginal complaints. Second, we divided the ECGs into STE and NSTEMI after careful consultation of the measurement matrix of the Glasgow program¹⁵, while the actual triaging decisions were manually made. Third, we have analyzed the ECG closest in time prior to PCI. Hence, the index ECG for primary PCI triage may have been made earlier, and may have had a different STE/NSTEMI classification as the ECG analyzed in our study. Goal of our current study was not to scrutinize the local ACS triaging procedure, but rather to link electrocardiographic and angiographic findings. In our view, this is a valid goal because in different circumstances the ECG preceding PCI could have been the index ECG for ACS triaging in the same patient.

It has been suggested that at least part of the explanation that NSTEMI ECGs occur in ACS patients with a completely occluded culprit artery segment can be found

in the direction of the injury vector. Therefore, we have studied the relation between the injury vector orientation and the STE-NSTE classification of the ECG. Our study shows that this “projection effect” indeed exists: STE vectors only occur in a restricted area (Figure 1, panel E). This area includes the “STE-equivalent” cases with precordial ST depressions. However, for greater part of the spatial orientations that the injury vector can assume this projection hypothesis does not seem straightforwardly to explain the fact that several ECGs are classified as NSTEMI ECGs. The NSTEMI ECGs in Figure 1, panel F have not only injury vectors outside the typical STE area seen in Figure 1, panel E, but also inside this typical STE area. This can likely be explained by the magnitude of the injury vectors. As can readily be seen in Figure 1, panels E and F, the larger injury vector magnitudes in the typical STE area are almost uniquely associated with STE ECGs (panel E) while NSTEMI ECGs in the typical STE area have smaller injury vector magnitudes (panel F). Indeed, the STE criteria require minimal amplitudes in certain leads, and this increases the possibility that smaller injury vectors be classified as NSTEMI. The STE amplitude criteria mentioned in the guidelines imply the requirement of a minimal injury vector magnitude. This requirement may rest upon the idea that large areas at risk generate large injury vectors. However, in a recent study¹⁷, in which the injury vector magnitude was compared to the extent of the myocardial ischemia as assessed by myocardial perfusion imaging, a rather significant, but very low ($r=0.29$) correlation was found. This finding implies that only 9% of the variation in the area at risk over the studied population could be related to variations in the injury vector magnitude.

We have insufficient data to separately treat the patients with single and multivessel disease. Figure 1, panels B (single vessel disease) and C (multivessel disease) do not suggest remarkable differences in the distributions of the injury vector directions of the culprit arteries between patients with single and multivessel disease, although it may be expected that patients with multivessel disease may have developed different collateral circulations, that can alter the effects of coronary occlusions. On the other hand, separate analysis of the single and multivessel disease groups is unlikely to change the basic message of our study, which primarily aims to illustrate how, caused by directional effects and by the injury vector magnitude, an emergency condition, *i.e.*, a completely occluded

coronary artery segment, can lead to either an STE or NSTEMI ECG, thus hampering triaging in hyperacute ACS.

A clinical consequence of our study could be that PCI should also be considered as primary treatment in NSTEMI-ACS. The newest guidelines for NSTEMI-ACS¹⁸ state that immediate PCI in NSTEMI-ACS patients has no advantages but also no disadvantages for the patients. The evidence for this statement is limited: it is based on a single investigation, in which the outcome was based on the peak troponin level¹⁹. Some reports have been published^{5;7;20;21} about the experience with primary PCI in NSTEMI-ACS patients, and compared the results with those in STE-ACS patients (Knot *et al.*²⁰ have restricted the NSTEMI-ACS group to patients with ST depression). Their results suggest that primary PCI in NSTEMI-ACS patients is recommendable. Katritsis *et al.*²² demonstrated that PCI soon after admission of the NSTEMI-ACS patient significantly reduced the risk for recurrent ischemia (relative risk 0.59) and the duration of hospital stay (by 28%). Furthermore, there was a decrease in major bleeding events (relative risk 0.78) and less death, MI or stroke (relative risk 0.91).

Limitations

It is a limitation that the ECGs were not recorded during, but before the PTCA procedure. Hence, in spite of the complete occlusion observed during catheterization, there remains a possibility that during the ECG recording the culprit artery was not completely occluded.

Conclusion

Notwithstanding the above mentioned limitations, our study once more underscores that better ECG criteria are needed for the purpose of ACS triaging. Especially, the STE/NSTEMI classification appears to be of limited value in discerning complete from incomplete occlusions. The challenge is to find not only criteria with sufficient sensitivity, but also with sufficient specificity, because false-positive catheterization-room activation opposes a serious medical, logistic and financial burden.

Appendix

Conventions in vectorcardiography and the 2D representation of 3D vector orientations

Typically, vectorcardiography makes use of both Cartesian and spherical coordinate systems, whatever is most convenient for the discussed matter. Up to now, a generally accepted convention regarding the spatial orientation of these coordinate systems is lacking. Historically²³, Einthoven, who studied the ECG in the frontal plane, defined the *x*-axis from right to left for the patient, *i.e.*, from left to right in the frontal plane as seen by the observer, and defined the *y*-axis in the craniocaudal direction. As a consequence of this choice, the QRS-complex and T-wave polarities in the Einthoven leads are usually positive in healthy subjects. Later, Frank added the third dimension; he defined the *z*-axis in the backward direction, thus creating a right-handed rectangular coordinate system. This coordinate system became the American Heart Association (AHA) standard¹⁴. In this standard, the associated spherical coordinate system has, against mathematical convention, the azimuth in the *xz*-plane (transversal plane), and the elevation is the angle between a vector and its projection on the *xz*-plane.

Other, more consistent rectangular and spherical coordinate systems have been proposed, specifically by Malmivuo *et al.*^{23;24}, but have never gained general acceptance. Lacking such a more consistent standard, we and others have adopted the AHA recommendations¹⁴, of which the rectangular and spherical coordinate systems have been depicted in Figure A1.

When displaying heart vectors, it must be realized that a momentaneous heart vector is the resultant of the electrical activity on that very moment in all structures of the heart. Moreover, electrocardiographic signals represent the electrical heart activity not in the geometrical/anatomic space, but rather in the electrical/image space²⁵. Hence, it is inappropriate to map heart vectors straightforwardly on an anatomical representation of the heart, like the bull's eye plot²⁶ (the representation of the left ventricle from apex to base divided in 17 segments and developed for tomographic imaging of the heart).

Classically, when vector directions are considered irrespective of their magnitude, they are expressed in azimuth and elevation, and visualized on the surface of a sphere. Two-dimensional rendering of such a 3D image inevitably involves errors²⁷: faithful 2D projection of a set of 3D vector directions is impossible and choices between various sorts of errors have to be made, like in geographical mapping. Multiple projection methods are in use, typically either preserving direction (“azimuthal”, possible only from one or two points to every other point), shape (“conformal”, only possible when area is not preserved), area (“equal area”, only possible when shape is not preserved), distance (“equidistant”, possible only between one or two fixed points and every other point) or shortest route (“gnomonic”). Actually, there is no projection standard in vectorcardiography, and when choosing a display modality we should be aware of the compromise that is inherent to the selected projection method.

Often, in vectorcardiography, spherical projections are displayed in such a way that:

- the center of the figure represents vectors with an anterior direction;
- going from the center to both sides of the figure brings us via lateral directions to posterior directions;
- going from the center up or down brings us to the superior and inferior directions, respectively.

Examples of spherical projections are shown in Figures A2 and A3. Purpose of these figures is to demonstrate till what extent the selection of a mapping method influences the appearance of the data. Figure A2 shows the Mercator projection (conformal), equirectangular cylindrical projection (compromise), equidistant azimuthal projection, Hammer projection (equal area), Stab-Werner projection (equal area). Figure A3 shows, in the same projections, the data of Figure 1 panel A. Disadvantages of the Mercator projection are that the areas inflate strongly with increasing latitude, and that the pure superior and inferior directions (North Pole and South Pole) cannot be rendered at all. The equirectangular cylindrical projection has similar but less extreme inflation problems as the Mercator projection has, and still cannot indicate the poles, basically, the North and South Poles are represented by the upper and lower boundaries of the figure, respectively. The equidistant azimuthal projection gives a nice view on the poles, however, has

unacceptable distortion at the border and cannot render the posterior direction (that is represented by the complete circumference of the projection).

In our current study, we selected the Stab-Werner projection for data display in Figure 1, because of its equal-area property, and because it is more suggestive of a complete 3D object than the equal-area Hammer projection. The latter projection, given as an example projection by Malmivuo *et al.*^{23;24}, might suggest that there is still a back side (which is obviously not true, because the left and right borders of the Hammer projection both represent the posterior meridian). Moreover, the spatial relation between data points at either side of the posterior meridian (the posterior “cut” in the 3D structure) is easier to assess in the Stab-Werner projection than in the Hammer projection. It should be stressed, however, that our choice, like choices made in this regard by others, is still a certain extent an arbitrary one, and that the choice of a projection modality is defensible as long as it gives a fair impression of the study data.

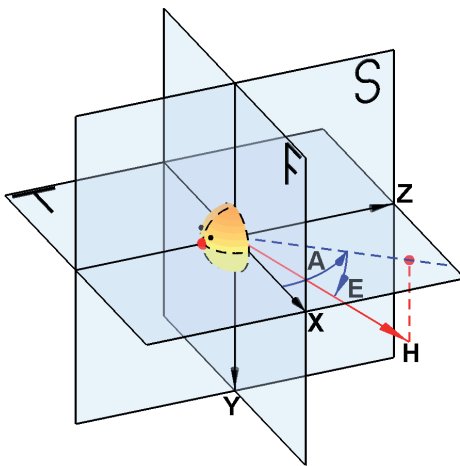


FIGURE A1. Pictorial summary of definitions of vectorcardiographic axes, planes and angles according to the AHA standardization recommendations (14). X = vectorcardiographic x axis (the arrow denotes the positive x direction); Y = y axis; Z = z axis; F = frontal plane; T = transversal plane; S = sagittal plane. As an example, an arbitrarily chosen momentaneous heart vector, H (red) is projected on the transversal plane (blue dotted line). The angle between the x axis and this projection is the azimuth, A, of that heart vector (positive when turning in the direction of the positive z axis). The angle between this projection and the heart vector is the elevation, E, of that heart vector (positive when turning in the direction of the positive y axis). Hence, the heart vector as drawn in this Figure has a positive azimuth, a positive elevation, and positive amplitudes in the x-, y-, z directions.

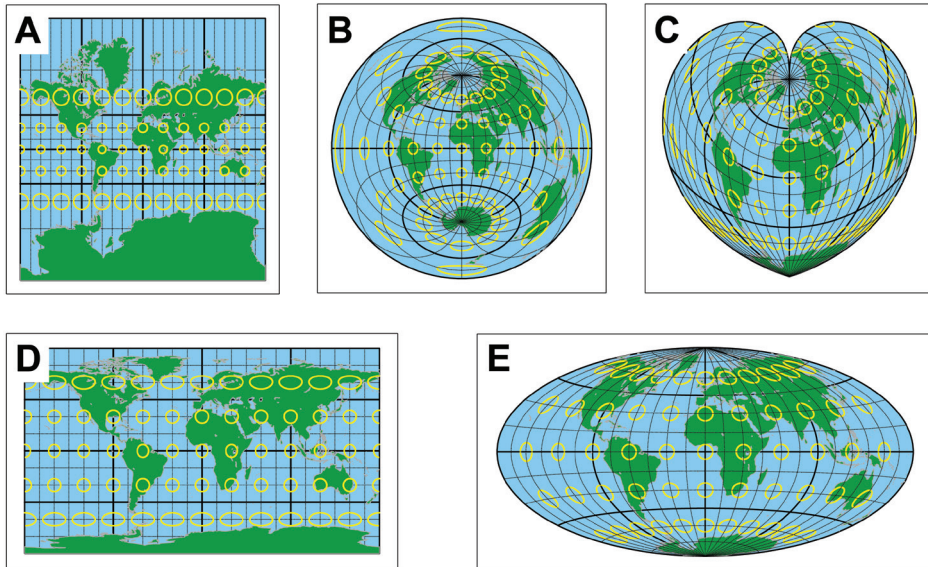


FIGURE A2. Example of five projections of a sphere on a plane. Panel A: Mercator projection (conformal); panel B: equidistant azimuthal projection; panel C: Stab-Werner projection (equal area); panel D: equirectangular cylindrical projection (compromise); panel E: Hammer projection (equal area). To demonstrate the typical distortions of these projections, Tissot indicatrices (yellow) have been superimposed on an image of the world. Tissot indicatrices are circles of identical true radius on the surface of the sphere. The conformal Mercator projection (panel A) is distorted by inflation that is symmetrical with respect to the equator and that is tremendously increasing when travelling towards the poles. The poles themselves cannot be depicted in the Mercator projection. In the equidistant azimuthal and equirectangular cylindrical projections (panels B and D, respectively), that are not conformal and not equal area, there is shape distortion and inflation distortion at the edges: in panel B this is symmetrical around the middle of the projection, in panel D this is symmetrical with respect to the equator. The Tissot indicatrices in the equal-area Stab-Werner and Hammer projections (panels C and E, respectively) all have the same area. In the center of the projections their shapes are close to circular, but at the borders the indicatrices are shape distorted. Compare Figures A2 and A3 to assess the impact of the typical distortions of the various projection modalities on the visual impression of the study data distribution.

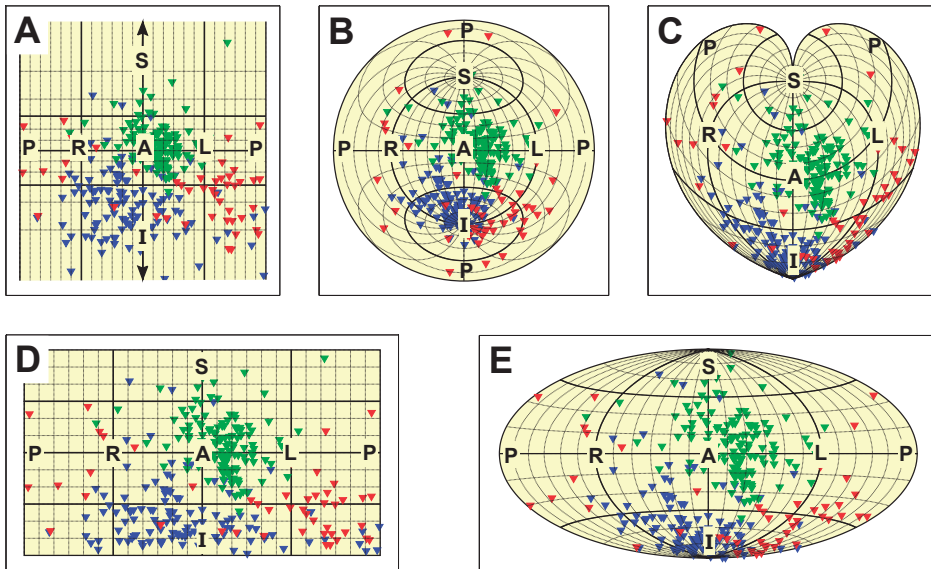


FIGURE A3. The data of Figure 1 panel A (injury vector orientations of the complete study group related to the culprit coronary arteries: green = LAD, red = LCX, blue = RCA) depicted in the five projection modalities as shown in Figure A2. Panel A: Mercator projection; panel B: equidistant azimuthal projection; panel C: Stab-Werner projection; panel D: equirectangular cylindrical projection; panel E: Hammer projection. Major projection directions: A = anterior; P = posterior; R = right; L = left; S = superior; I = inferior. Note that: 1) in the Mercator projection (panel A) the superior and inferior directions cannot be depicted; 2) in the equidistant azimuthal projection (panel B) the posterior direction is basically represented by the complete circumference of the projection; 3) in the equirectangular cylindrical projection (panel D) the superior and inferior directions are basically represented by the complete upper and lower borders of the projection. In all projection modalities, the vectorcardiographic azimuth and elevation can be determined by using the meridians and the parallels of the graticule, respectively. Following the AHA standard, the azimuth of the anterior meridian is minus 90°, becomes less negative when going to the left lateral side meridian, and further becoming positive when going to the posterior meridian; elevations inferior of the equator are positive, and superior of the equator are negative. Compare Figures A2 and A3 to assess the impact of the typical distortions of the various projection modalities on the visual impression of the study data distribution.

References

1. Steg PG, James SK, Atar D, *et al.* ESC guidelines for the management of acute myocardial infarction in patients presenting with ST-segment elevation. *Eur Heart J* 2012;33:2569.
2. Hamm CW, Bassand JP, Agewall S, *et al.* ESC guidelines for the management of acute coronary syndromes in patients presenting without persistent ST-segment elevation: the Task Force for the management of acute coronary syndromes (ACS) in patients presenting without persistent ST-segment elevation of the European Society of Cardiology (ESC). *Eur Heart J* 2011;32:2999.
3. Antman EM, Anbe DT, Armstrong PW, *et al.* ACC/AHA guidelines for the management of patients with ST-elevation myocardial infarction; a report of the American College of Cardiology/American Heart Association Task Force on Practice Guidelines (Committee to Revise the 1999 Guidelines for the Management of Patients With Acute Myocardial Infarction). *J Am Coll Cardiol* 2004;44:E1.
4. Birnbaum Y, Bayes de Luna A, Fiol M, *et al.* Common pitfalls in the interpretation of electrocardiograms from patients with acute coronary syndromes with narrow QRS: a consensus report. *J Electrocardiol* 2012;45:463.
5. de Belder MA. Interventional management of acute coronary syndromes: applying the lessons of ST-elevation services to non-ST-elevation myocardial infarction. *Heart* 2012;98:1407.
6. Gorgels AP. ST-elevation and non-ST-elevation acute coronary syndromes: should the guidelines be changed? *J Electrocardiol* 2013;46:318.
7. Koyama Y, Hansen PS, Hanratty CG, *et al.* Prevalence of coronary occlusion and outcome of an immediate invasive strategy in suspected acute myocardial infarction with and without ST-segment elevation. *Am J Cardiol* 2002;90:579.
8. Ter Haar CC, Maan AC, Warren SG, *et al.* Difference vectors to describe dynamics of the ST segment and the ventricular gradient in acute ischemia. *J Electrocardiol* 2013;46:302.
9. Birnbaum Y, Zhou S, Wagner GS. New considerations of ST segment "elevation" and "depression" and accompanying T wave configuration in acute coronary syndromes. *J Electrocardiol* 2011;44:1.
10. Neill J, Owens C, Harbinson M, *et al.* Early detection of acute posterior myocardial infarction using body surface mapping and SPECT scanning. *Coron Artery Dis* 2010;21:420.
11. Draisma HH, Swenne CA, van de Vooren H, *et al.* LEADS: an interactive research oriented ECG/VCG analysis system. *Comput Cardiol* 2005;32:515.
12. Kors JA, Sittig AC, van Bommel JH. Reconstruction of the Frank vectorcardiogram from standard electrocardiographic leads: diagnostic comparison of different methods. *Eur Heart J* 1990;11:1083.
13. Prineas R, Crow R, Blackburn H. The Minnesota code manual of electrocardiographic findings. Littleton, MA: John Wright-PSG, Inc.;1982.
14. Report of committee on electrocardiography, American Heart Association. Recommendations for standardization of leads and of specifications for instruments in electrocardiography and vectorcardiography. *Circulation* 1967;35:583.

15. Macfarlane PW, Devine B, Latif S, *et al.* Methodology of ECG interpretation in the Glasgow program. *Methods Inf Med* 1990;29:354.
16. Balzi D, Di Bari M, Barchielli A, *et al.* Should we improve the management of NSTEMI? Results from the population-based "acute myocardial infarction in Florence 2" (AMI-Florence 2) registry. *Intern Emerg Med* 2013;8:725–33.
17. Andersen MP, Terkelsen CJ, Sorensen JT, *et al.* The ST injury vector: electrocardiogram-based estimation of location and extent of myocardial ischemia. *J Electrocardiol* 2010;43:121.
18. Jneid H, Anderson JL, Wright RS, *et al.* 2012 ACCF/AHA focused update of the guideline for the management of patients with unstable angina/non-ST-elevation myocardial infarction (updating the 2007 guideline and replacing the 2011 focused update): a report of the American College of Cardiology Foundation/American Heart Association Task Force on Practice Guidelines. *Circulation* 2012; 126:875.
19. Montalescot G, Cayla G, Collet JP, *et al.* Immediate vs delayed intervention for acute coronary syndromes: a randomized clinical trial. *JAMA* 2009;302:947.
20. Knot J, Kala P, Rokyta R, *et al.* Comparison of outcomes in ST-segment depression and ST-segment elevation myocardial infarction patients treated with emergency PCI: data from a multicentre registry. *Cardiovasc J Afr* 2012;23:495.
21. Wang TY, Zhang M, Fu Y, *et al.* Incidence, distribution, and prognostic impact of occluded culprit arteries among patients with non-ST-elevation acute coronary syndromes undergoing diagnostic angiography. *Am Heart J* 2009;157:716.
22. Katritsis DG, Siontis GC, Kastrati A, *et al.* Optimal timing of coronary angiography and potential intervention in non-ST-elevation acute coronary syndromes. *Eur Heart J* 2011;32:32.
23. Malmivuo J, Plonsey R. Consistent system of rectangular and spherical coordinates for electrocardiology and magnetocardiology. 1995:449.
24. Malmivuo JA, Wikswo Jun JP, Barry WH, *et al.* Consistent system of rectangular and spherical coordinates for electrocardiology and magnetocardiography. *Med Biol Eng Comput* 1977;15:413.
25. Van Herpen, G. In memory of Professor Burger (1893–1965). *J Electrocardiol* 2014;47:168–174.
26. Cerqueira MD, Weissman NJ, Dilsizian V, *et al.* Standardized myocardial segmentation and nomenclature for tomographic imaging of the heart. A statement for healthcare professionals from the Cardiac Imaging Committee of the Council on Clinical Cardiology of the American Heart Association. *Circulation* 2002;105:539.
27. Gauss CF. Disquisitiones generales circa superficies curvas. Commentationes Societatis Regiae Scientiarum Gottingensis Recentiores 1828;6:99–146.

